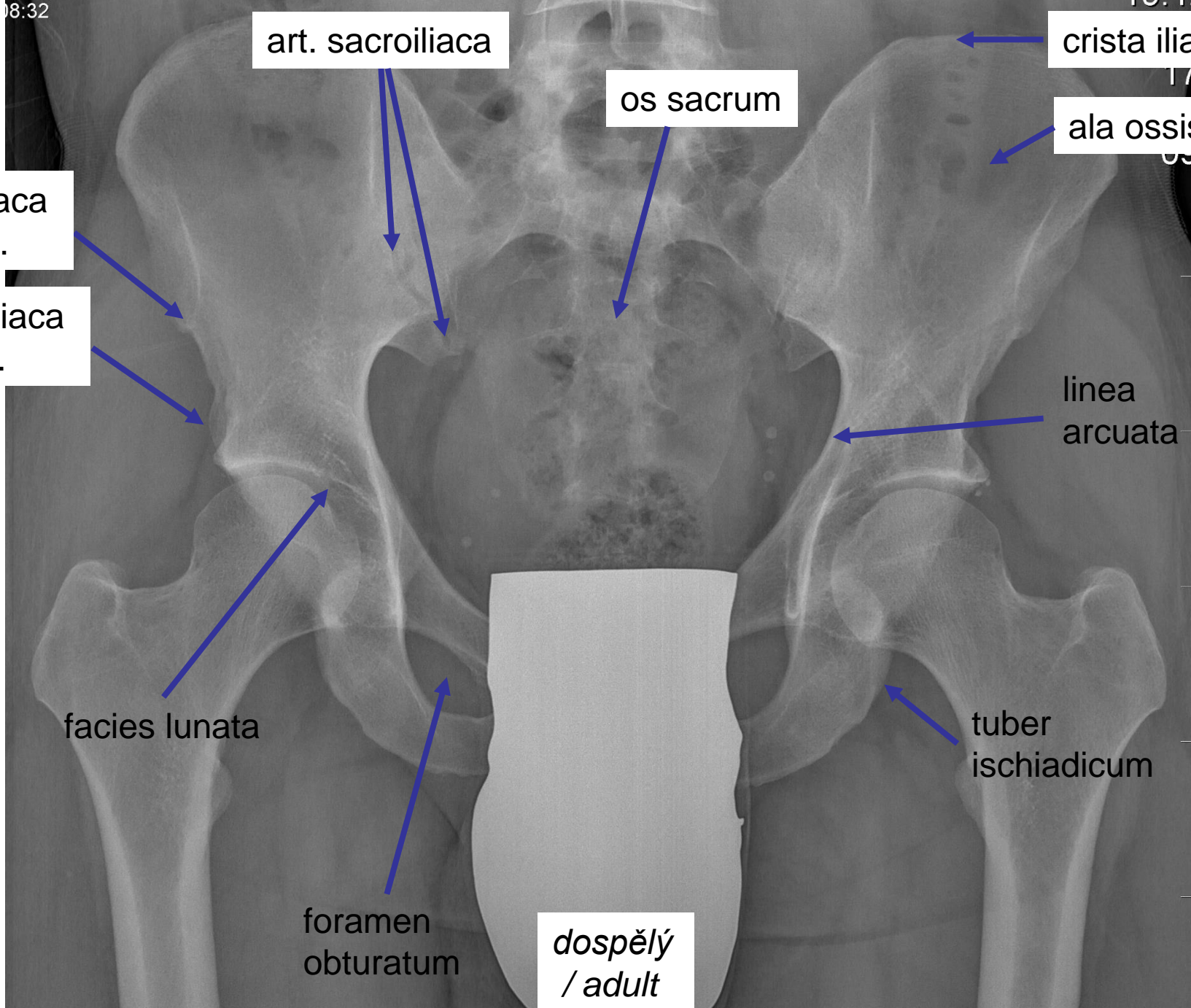


**Kosti a klouby
dolní končetiny**

**Bones and joints
of lower extremity**

08:32

10:12



art. sacroiliaca

os sacrum

crista iliaca

ala ossis ilii

spina iliaca
ant. sup.

spina iliaca
ant. inf.

linea
arcuata

facies lunata

tuber
ischiadicum

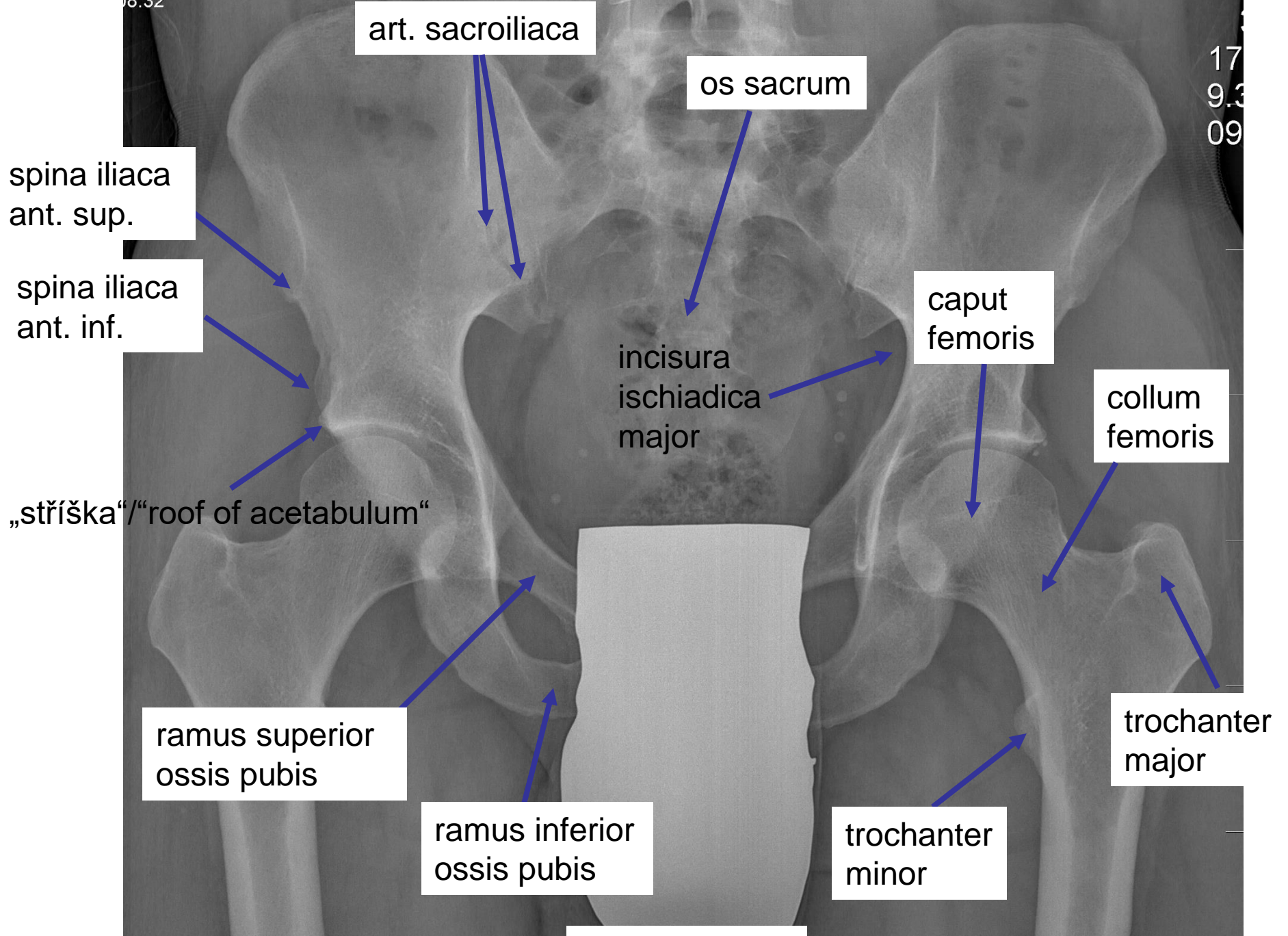
foramen
obturatum

dospělý
/ adult

08:32

10:12

17
9.3
09



art. sacroiliaca

os sacrum

spina iliaca
ant. sup.

spina iliaca
ant. inf.

caput
femoris

collum
femoris

incisura
ischiadica
major

„stříška“/“roof of acetabulum“

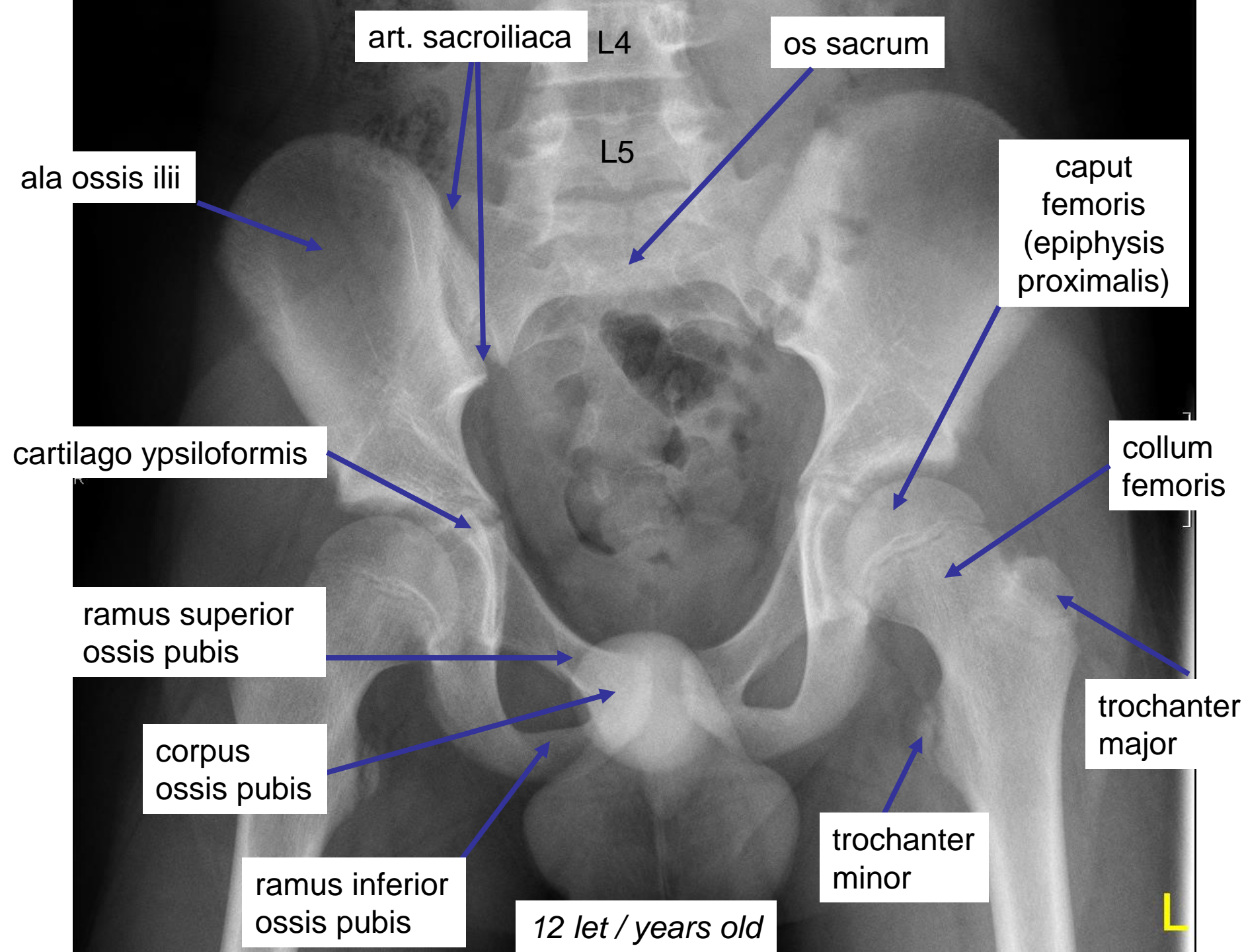
ramus superior
ossis pubis

ramus inferior
ossis pubis

trochanter
minor

trochanter
major

dospělý / adult



ala ossis ilii

os pubis

os ischii

os sacrum

1,00

collum femoris

1 day / den

MarkOnFilter

W: 03375
C: 01688

caput femoris (epiphysis proximalis)

collum femoris

os ischii

cartilago ypsiloformis

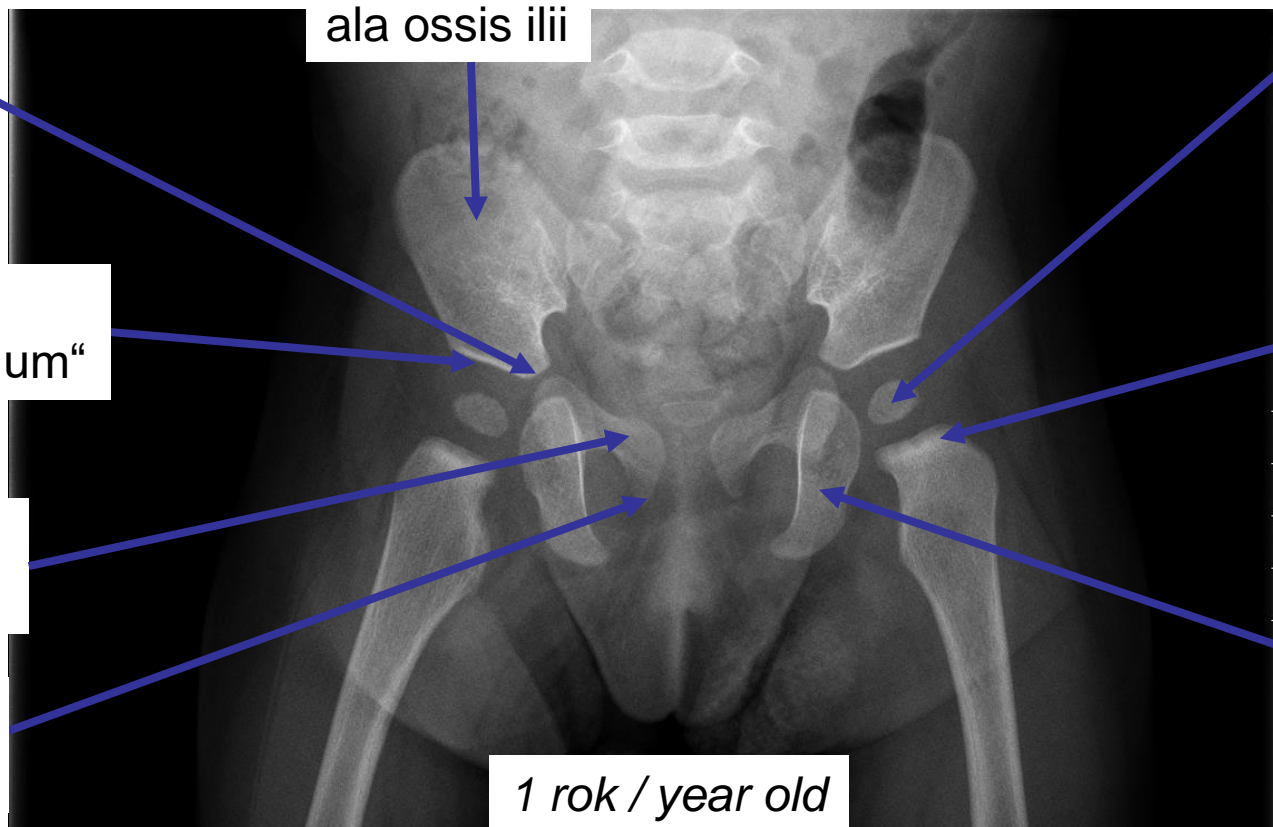
ala ossis ilii

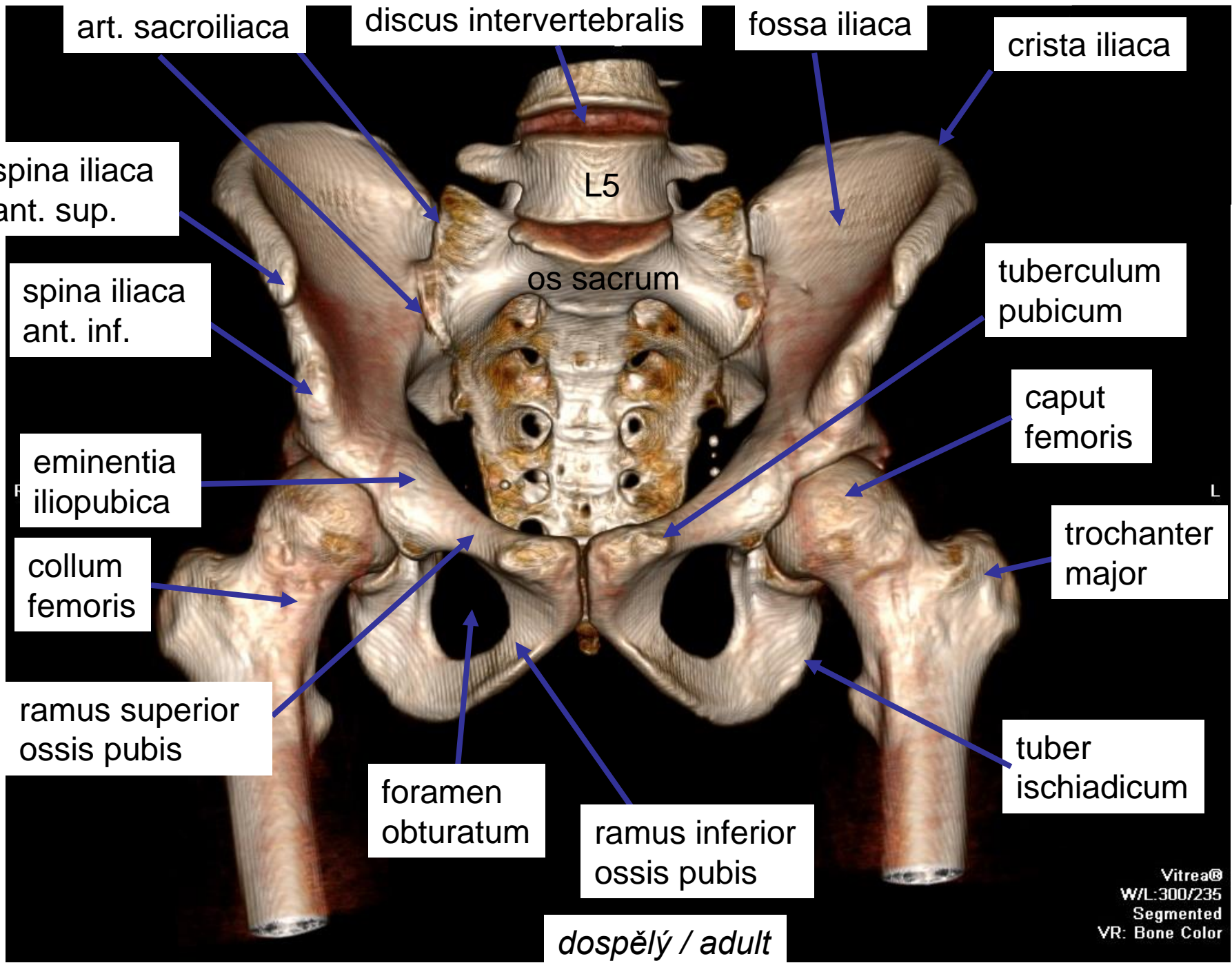
„stříška“ /
“roof of acetabulum“

ramus superior ossis pubis

ramus inferior ossis pubis

1 rok / year old





art. sacroiliaca

discus intervertebralis

fossa iliaca

crista iliaca

spina iliaca
ant. sup.

L5

spina iliaca
ant. inf.

os sacrum

tuberculum
pubicum

eminentia
iliopubica

caput
femoris

collum
femoris

trochanter
major

ramus superior
ossis pubis

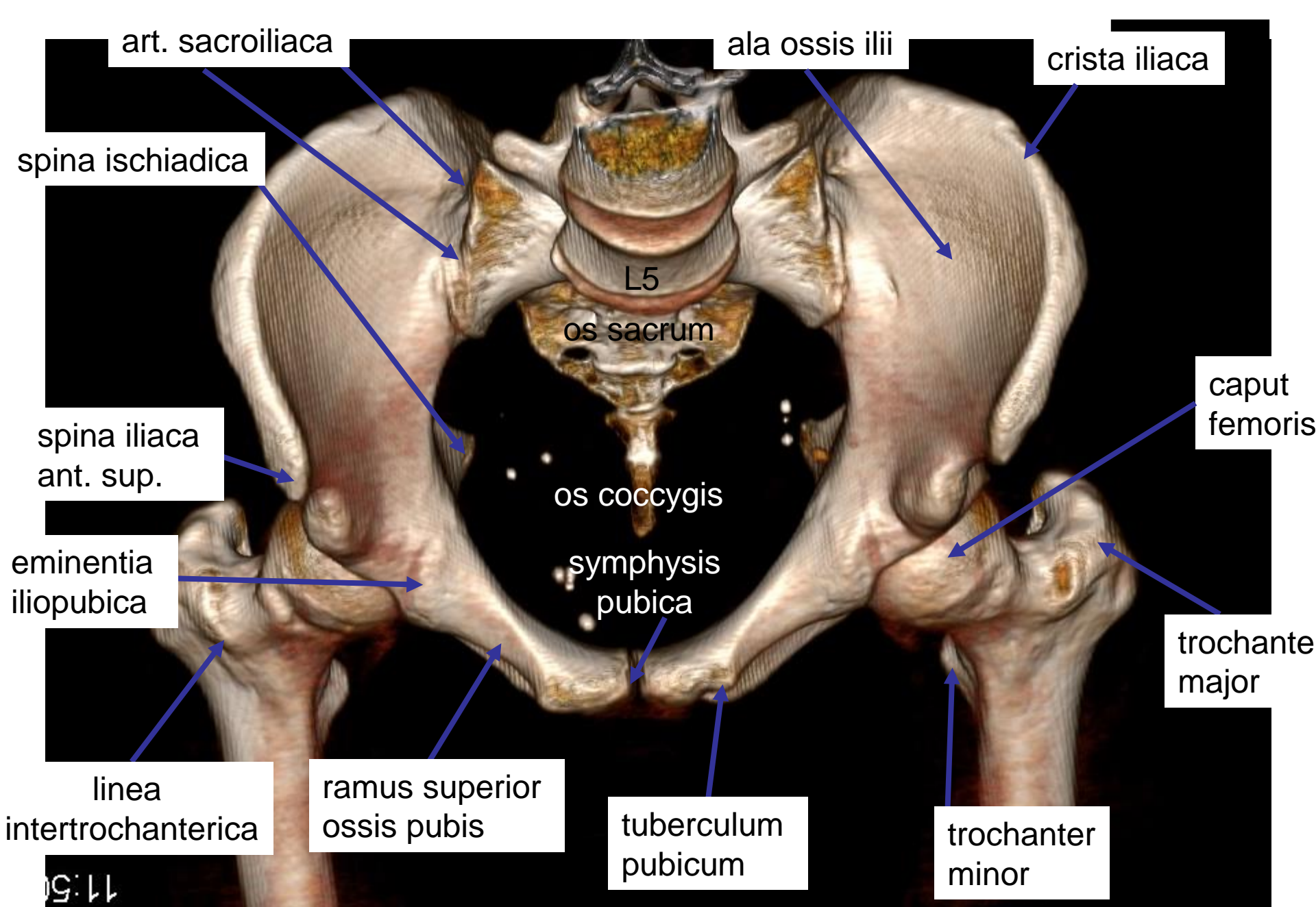
tuber
ischadicum

foramen
obturatum

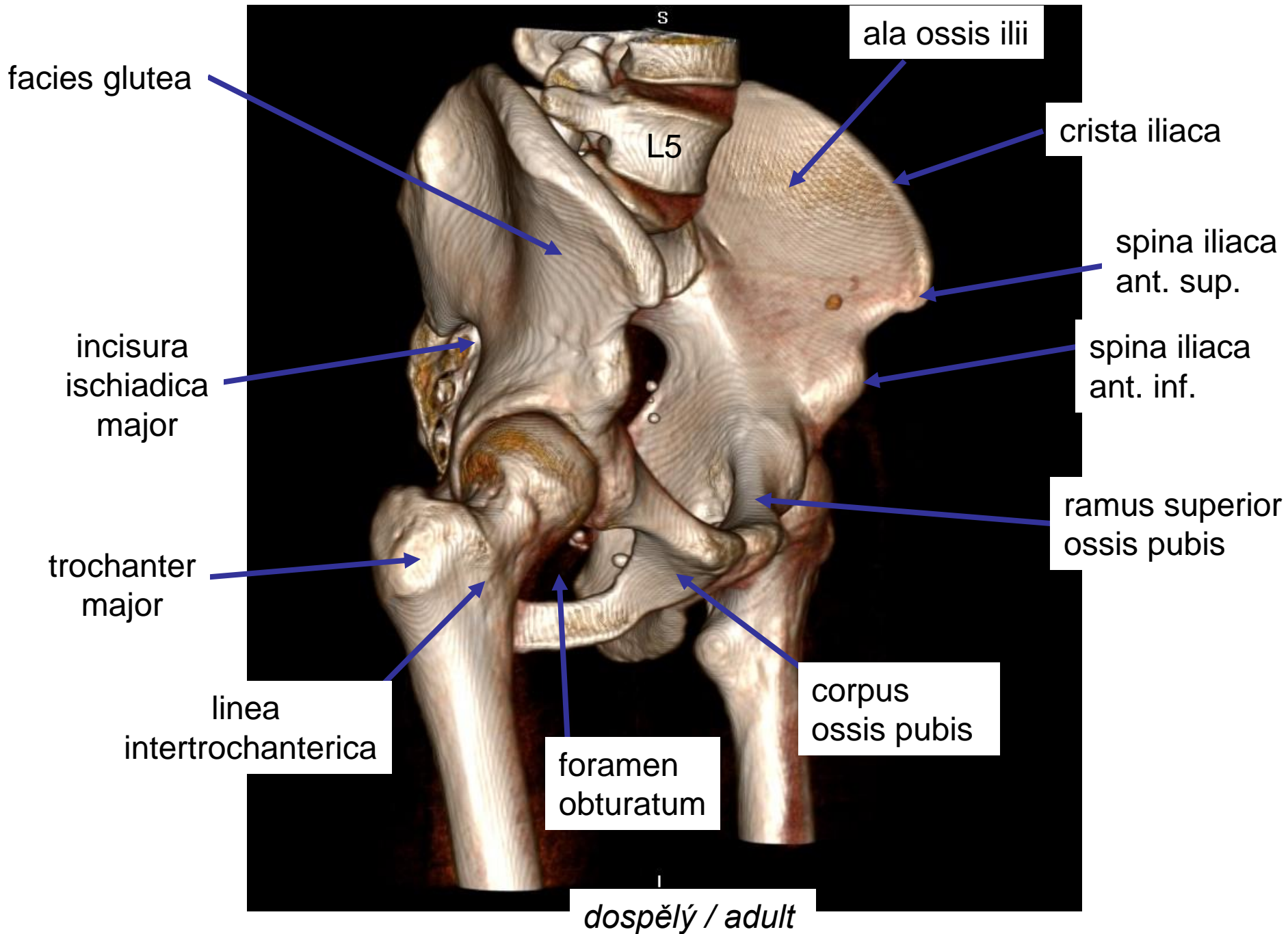
ramus inferior
ossis pubis

dospělý / adult

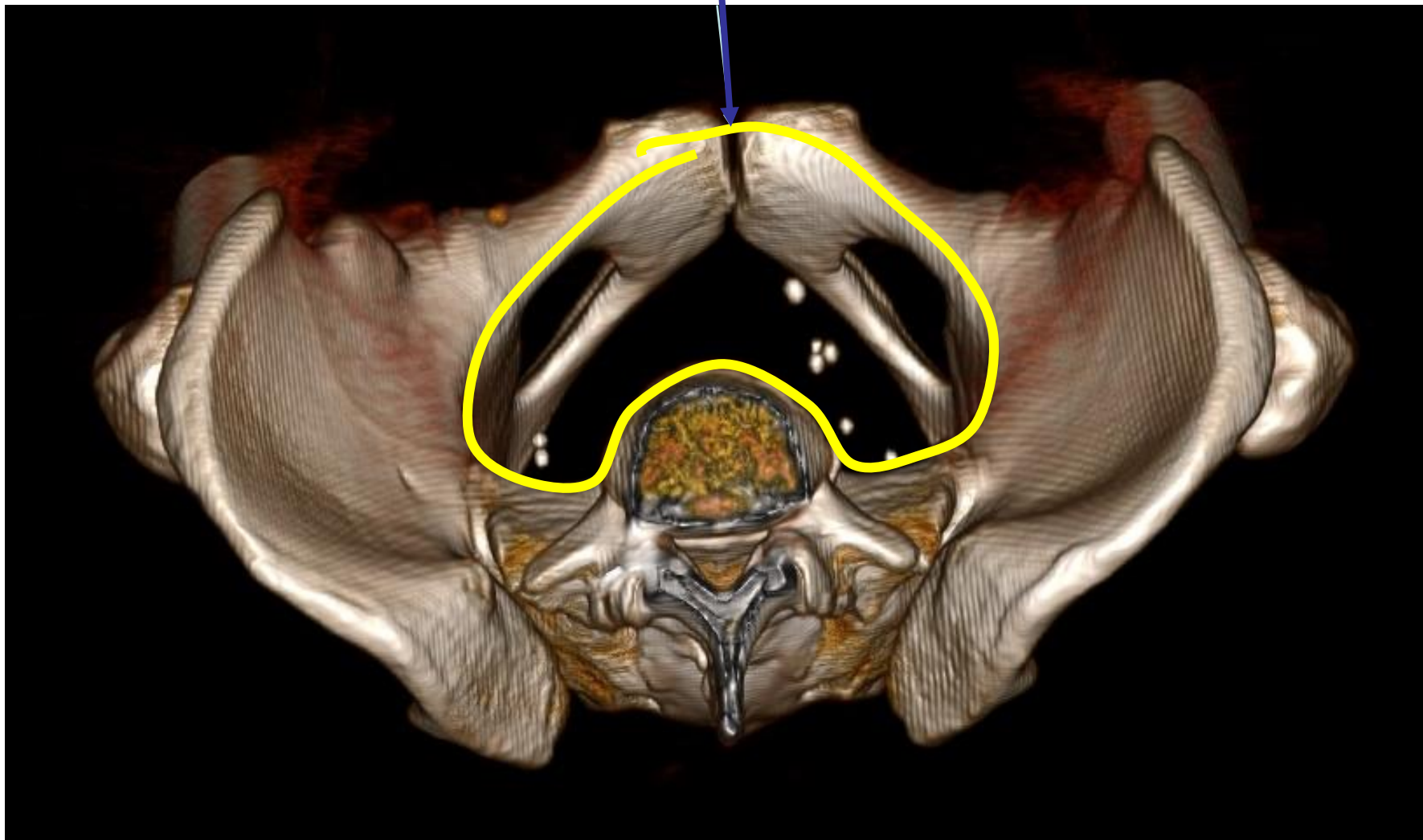
Vitrea®
W/L:300/235
Segmented
VR: Bone Color



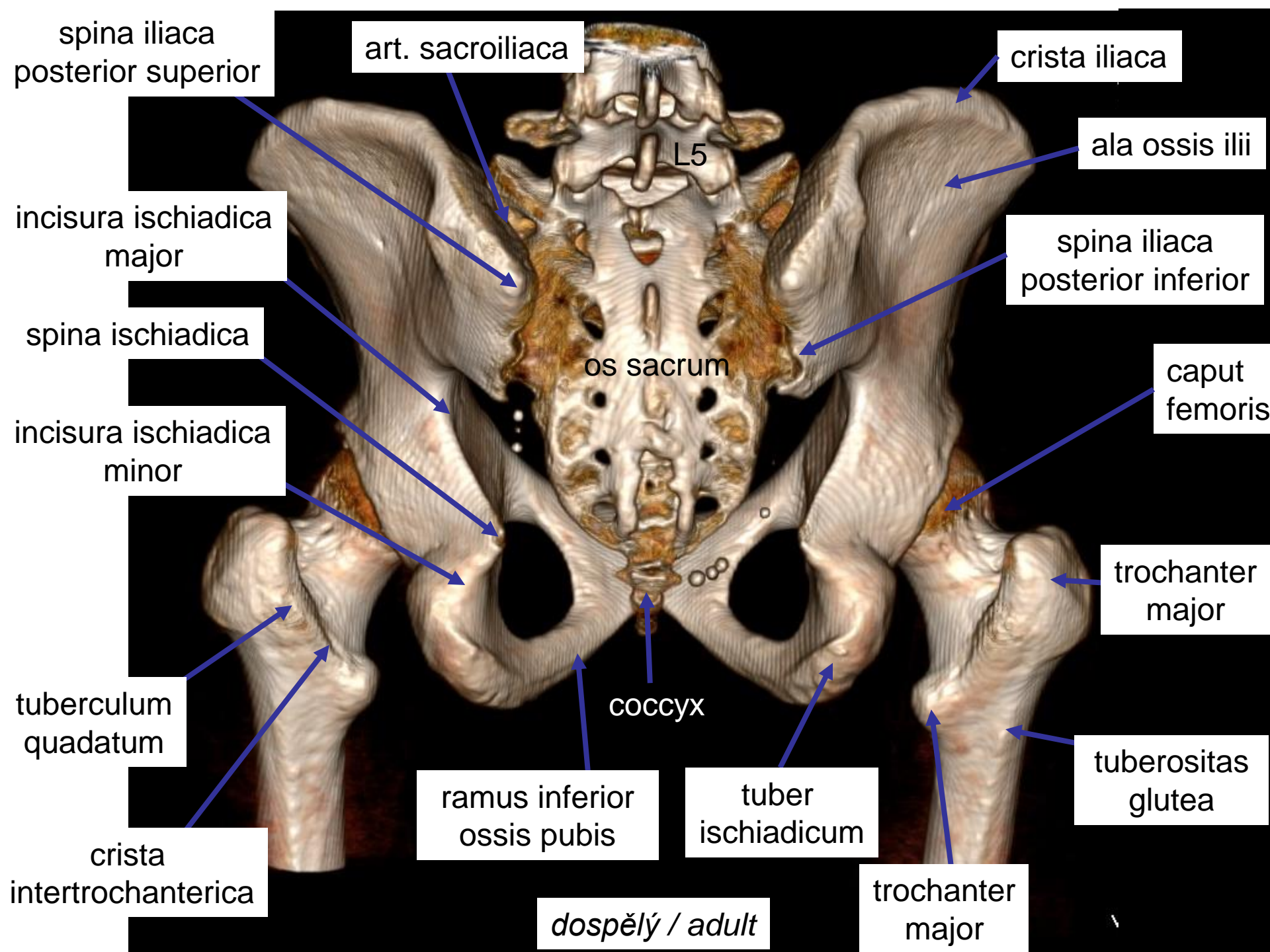
dospělý / adult

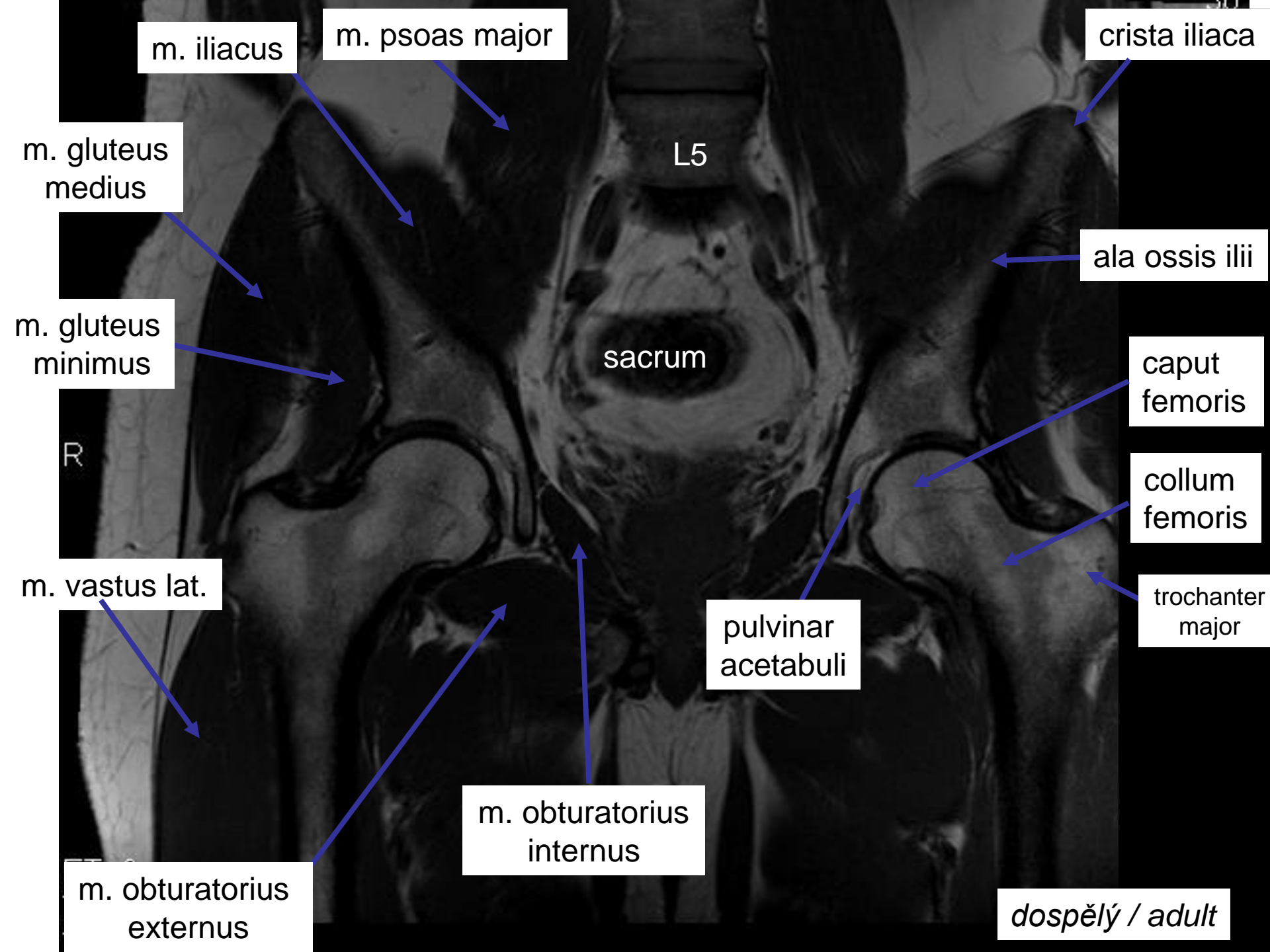


Aditus pelvis



dospělý / adult





m. iliacus

m. psoas major

crista iliaca

m. gluteus medius

L5

ala ossis ilii

m. gluteus minimus

sacrum

caput femoris

R

collum femoris

m. vastus lat.

pulvinar acetabuli

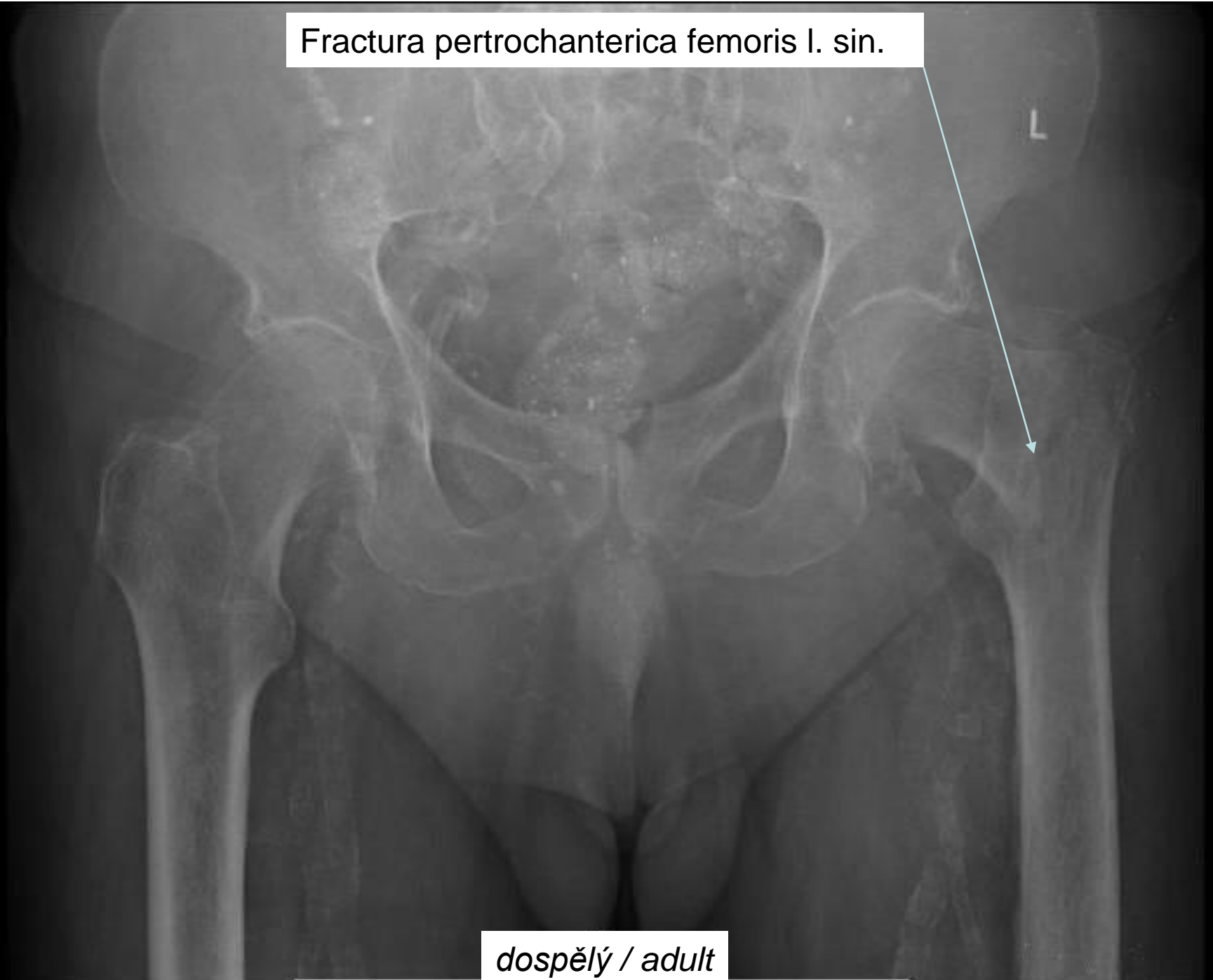
trochanter major

m. obturatorius internus

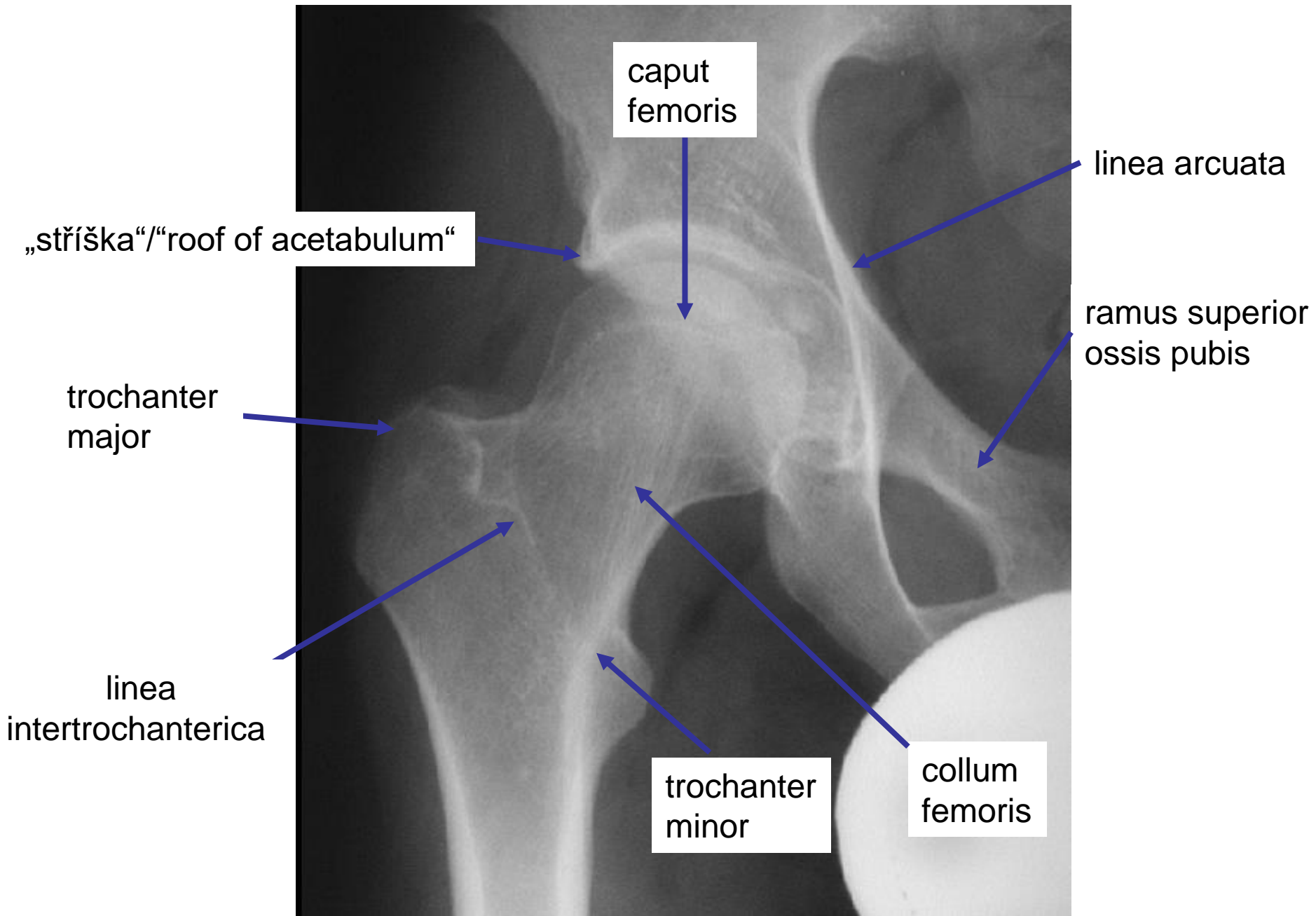
m. obturatorius externus

dospělý / adult

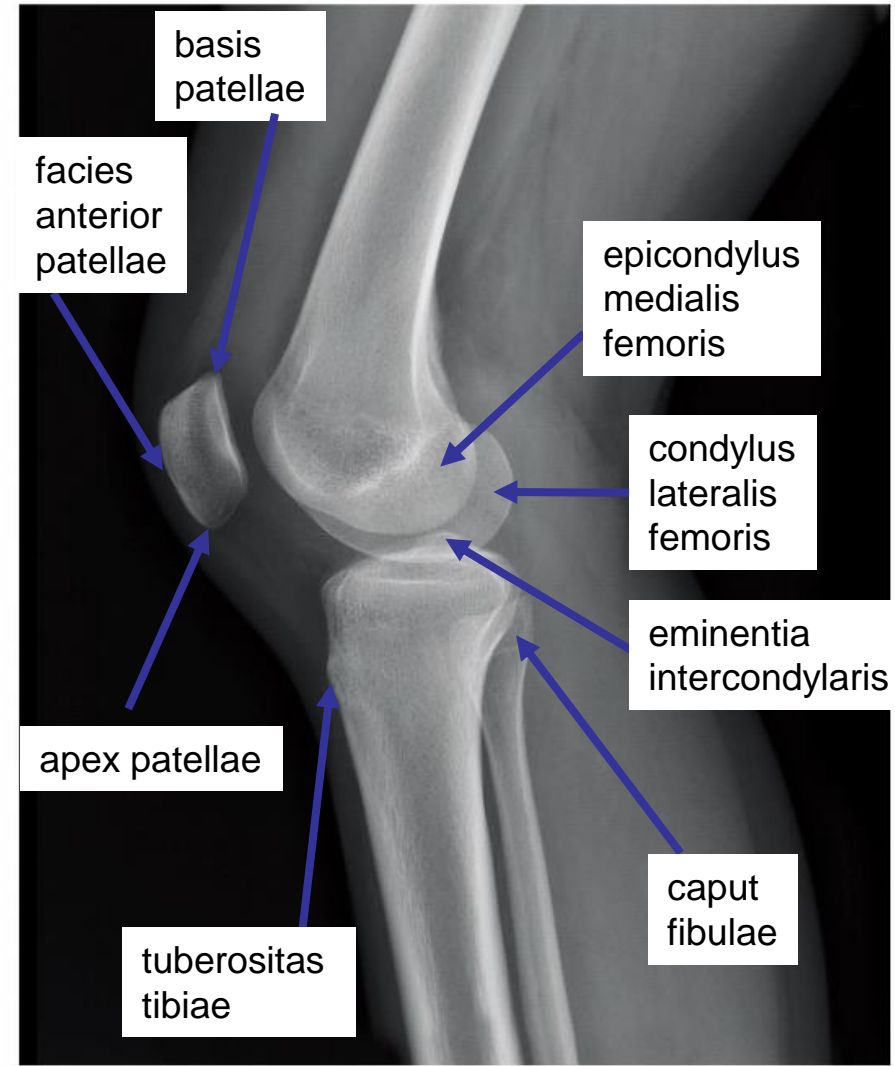
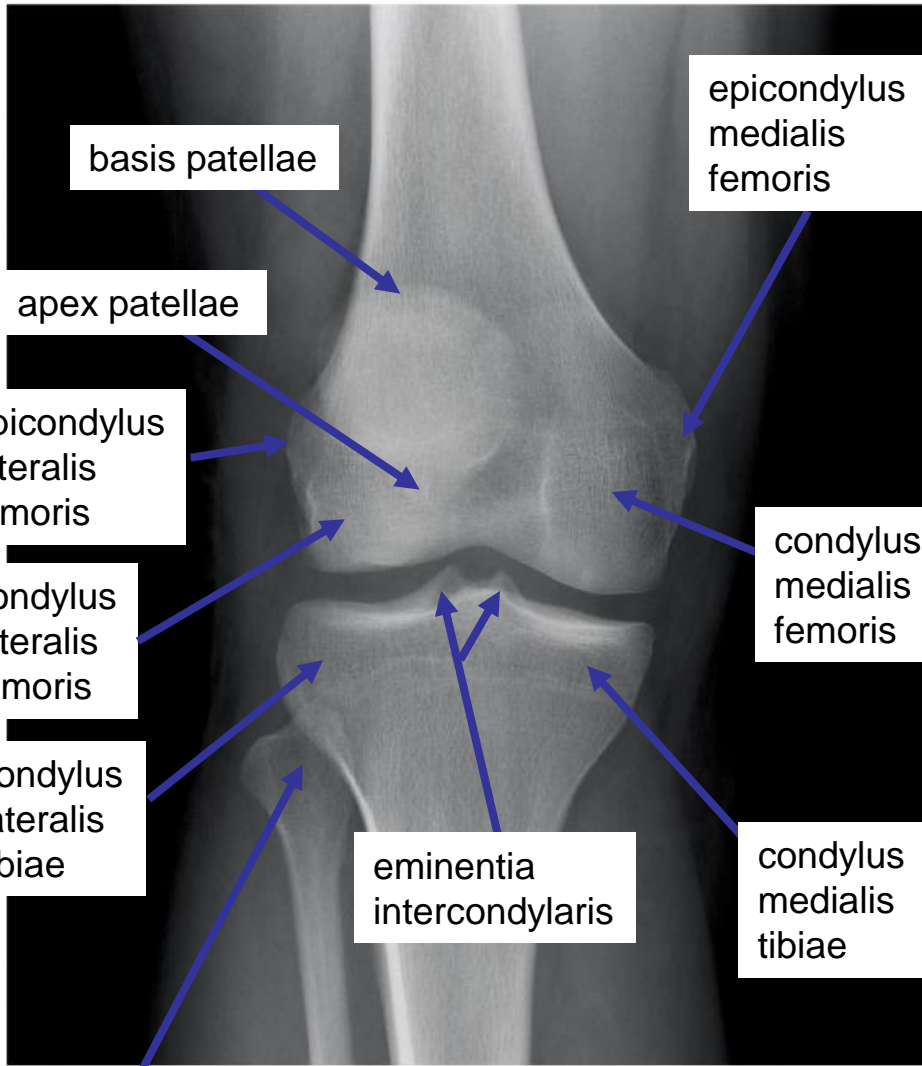
Fractura pertrochanterica femoris l. sin.



dospělý / adult

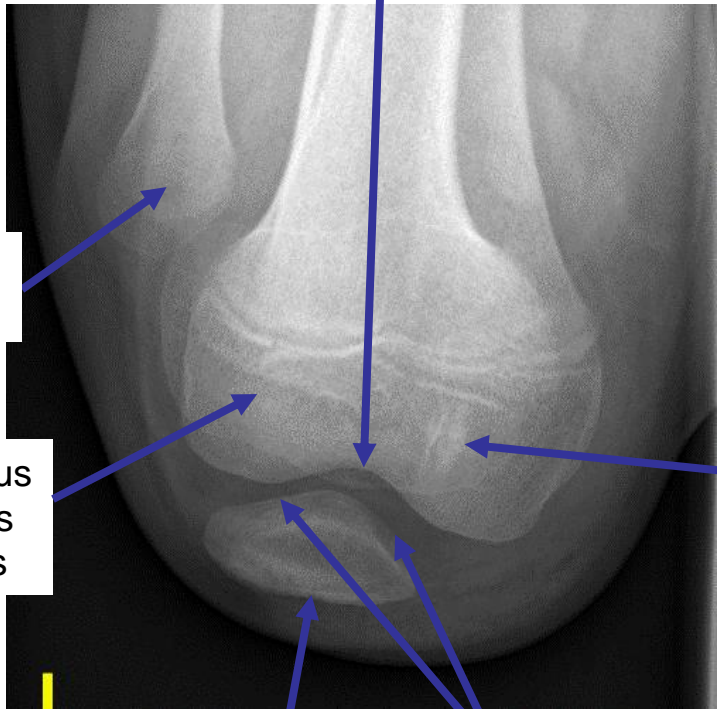


dospělý / adult

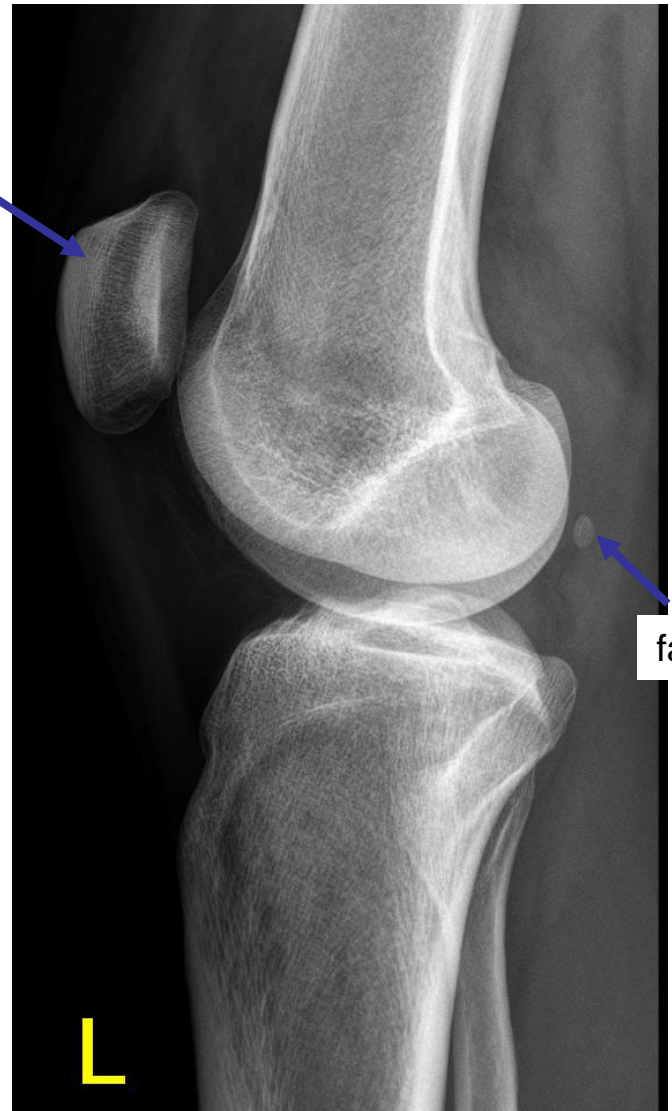


dospělý / adult

facies patellaris femoris

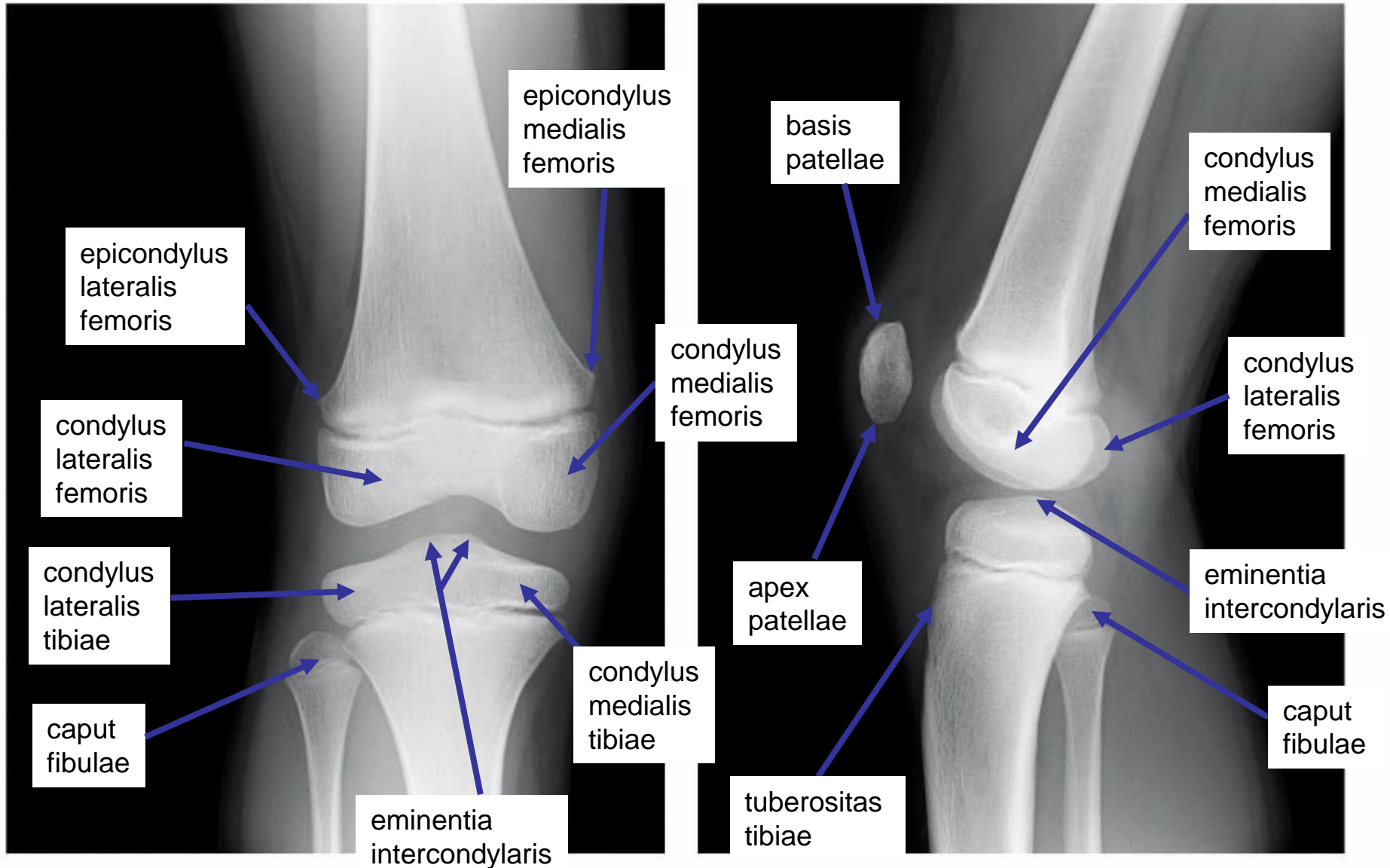


patella

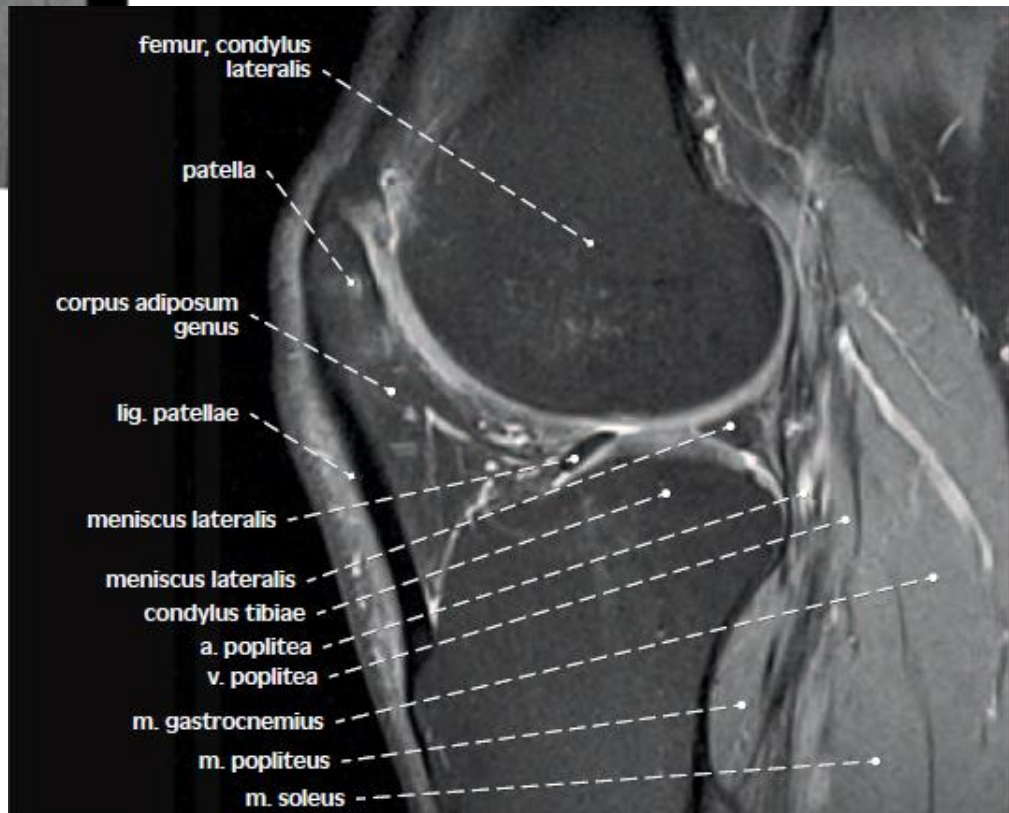
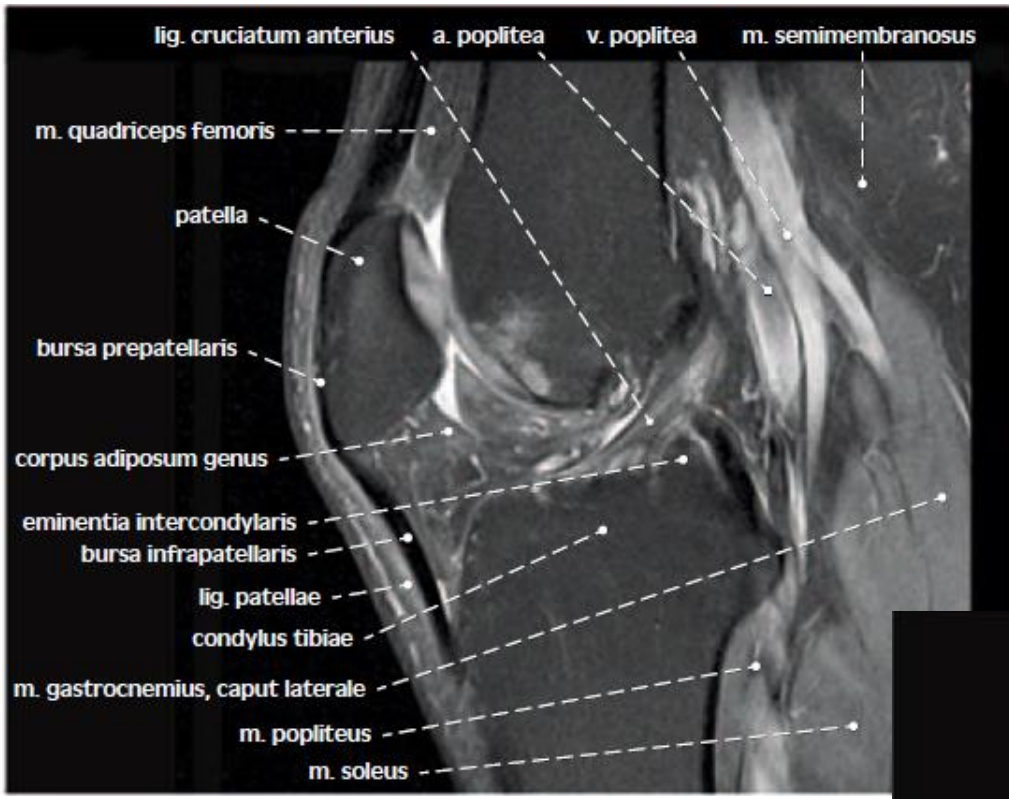


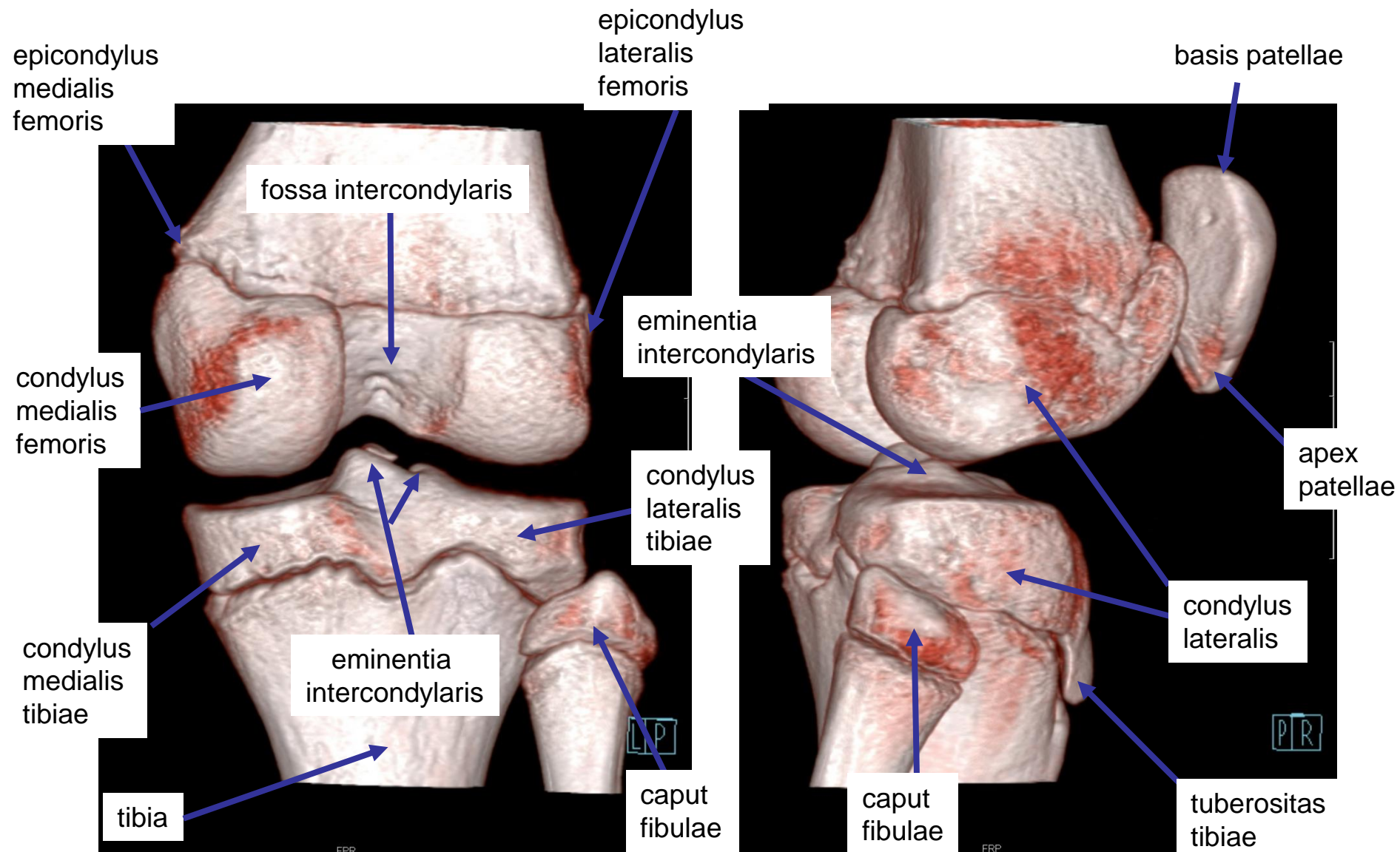
condylus medialis femoris

fabella



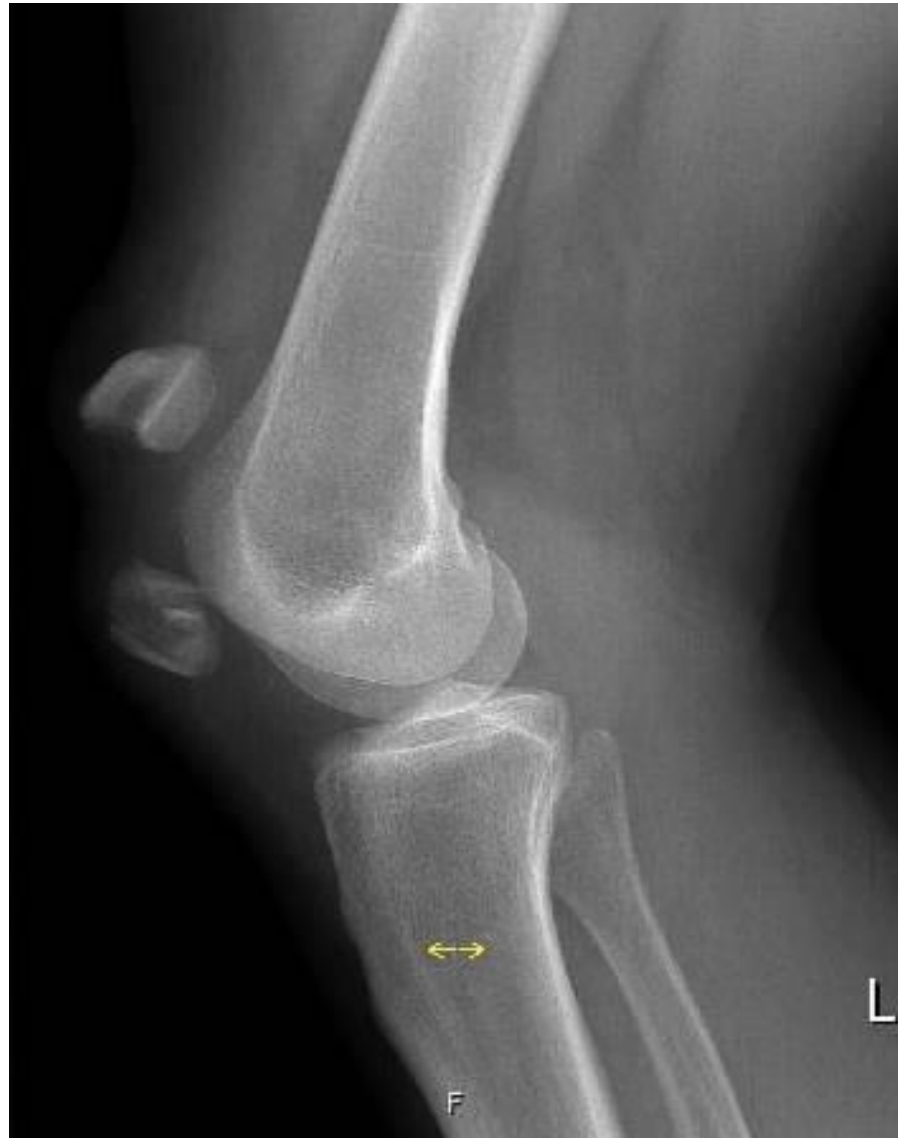dítě 8 let / child 8 years old





dítě 8 let / child 8 years old

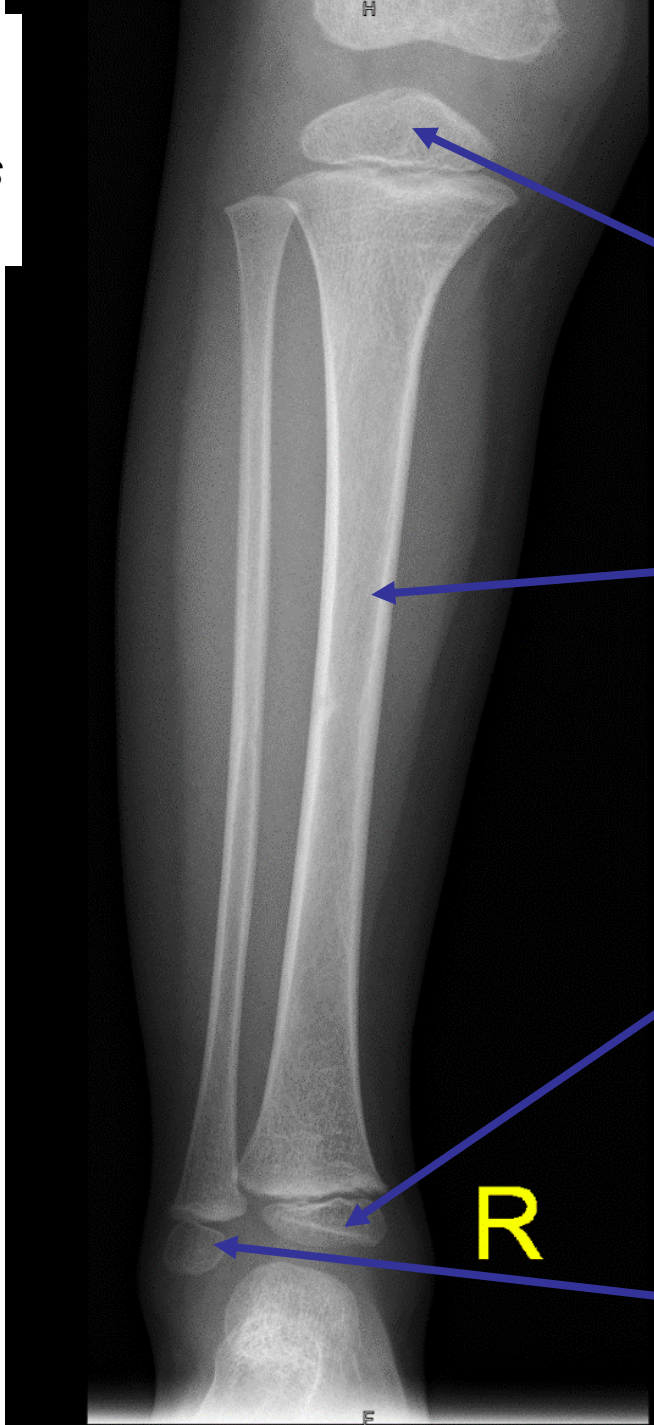
Fractura patellae dislocata



dospělý /adult

4 roky

4 years old



epiphysis distalis femoris

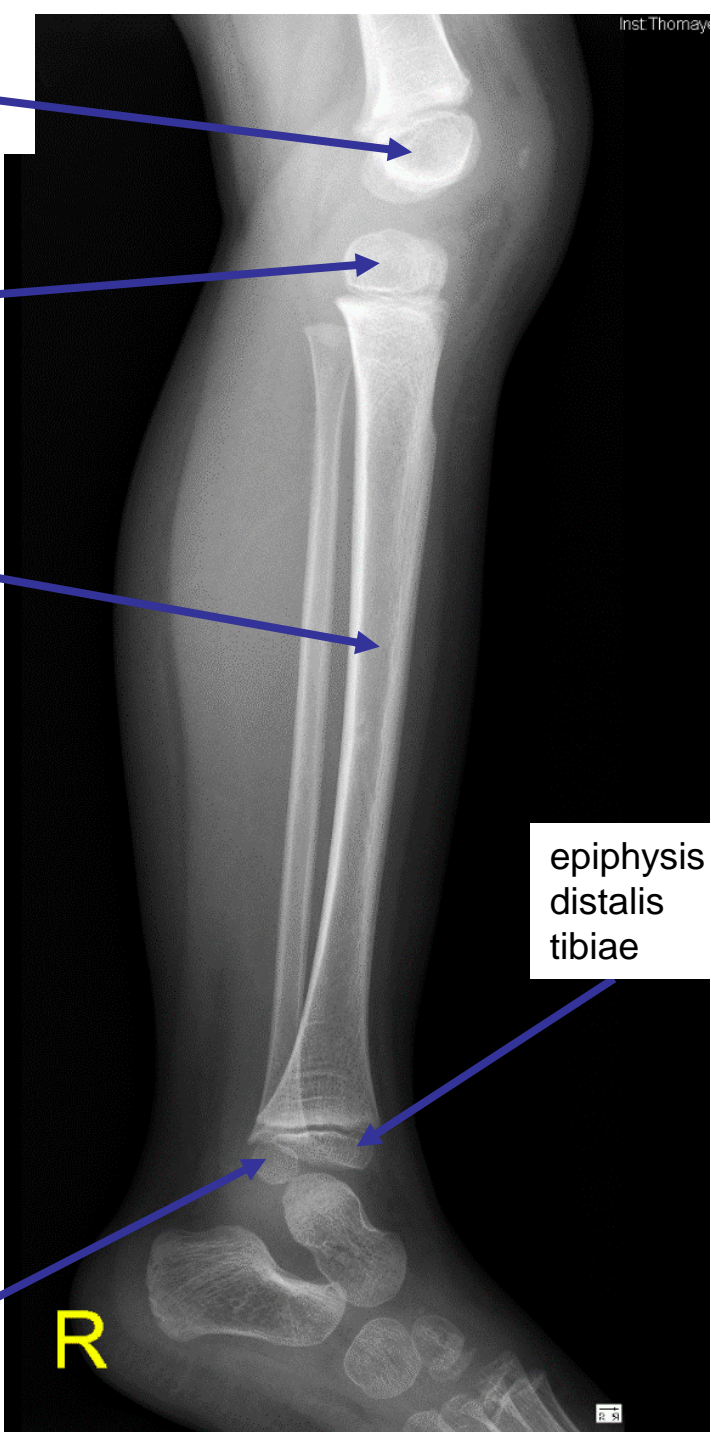
epiphysis proximalis tibiae

diaphysis tibiae

epiphysis distalis tibiae

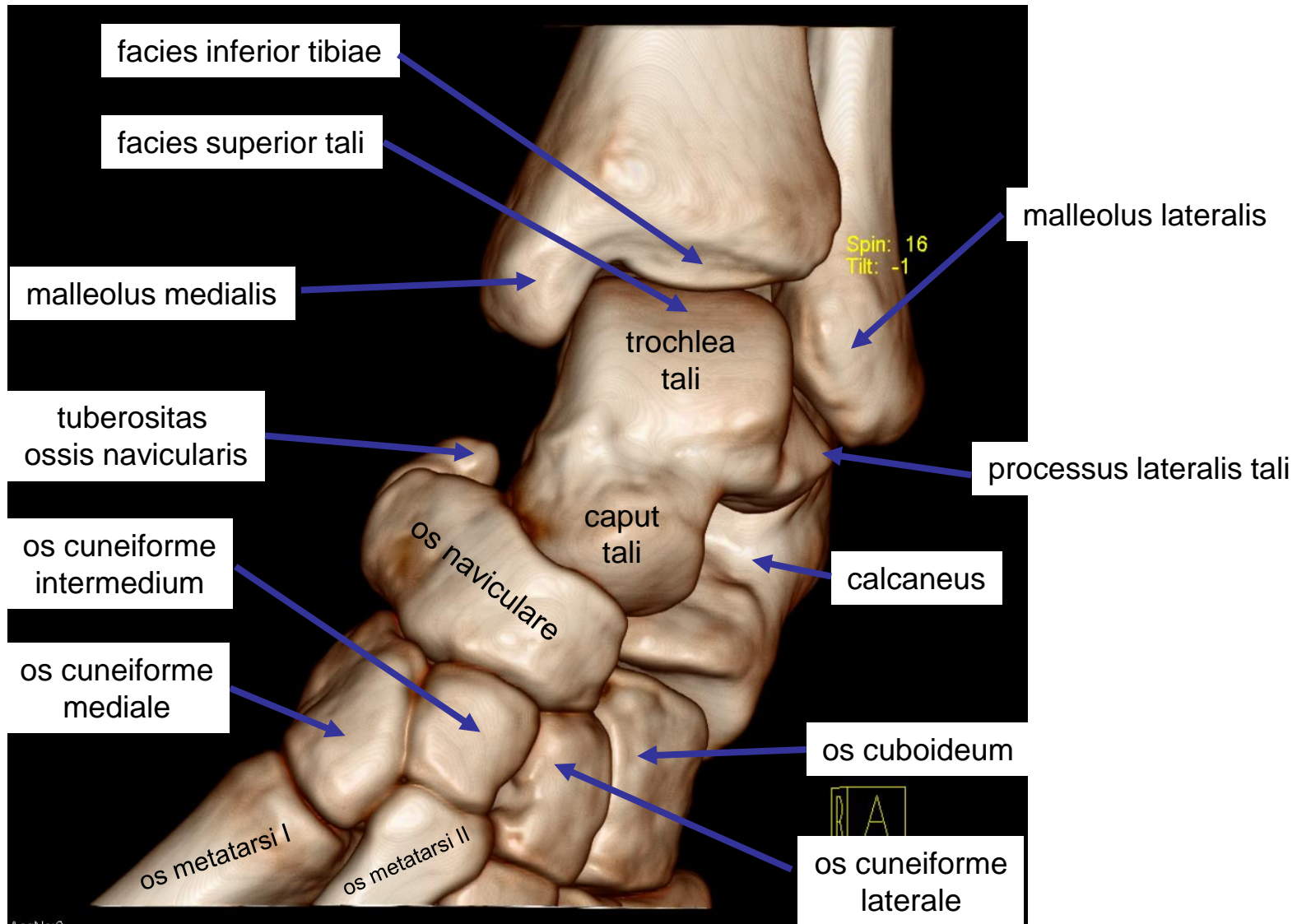
epiphysis distalis fibulae

R

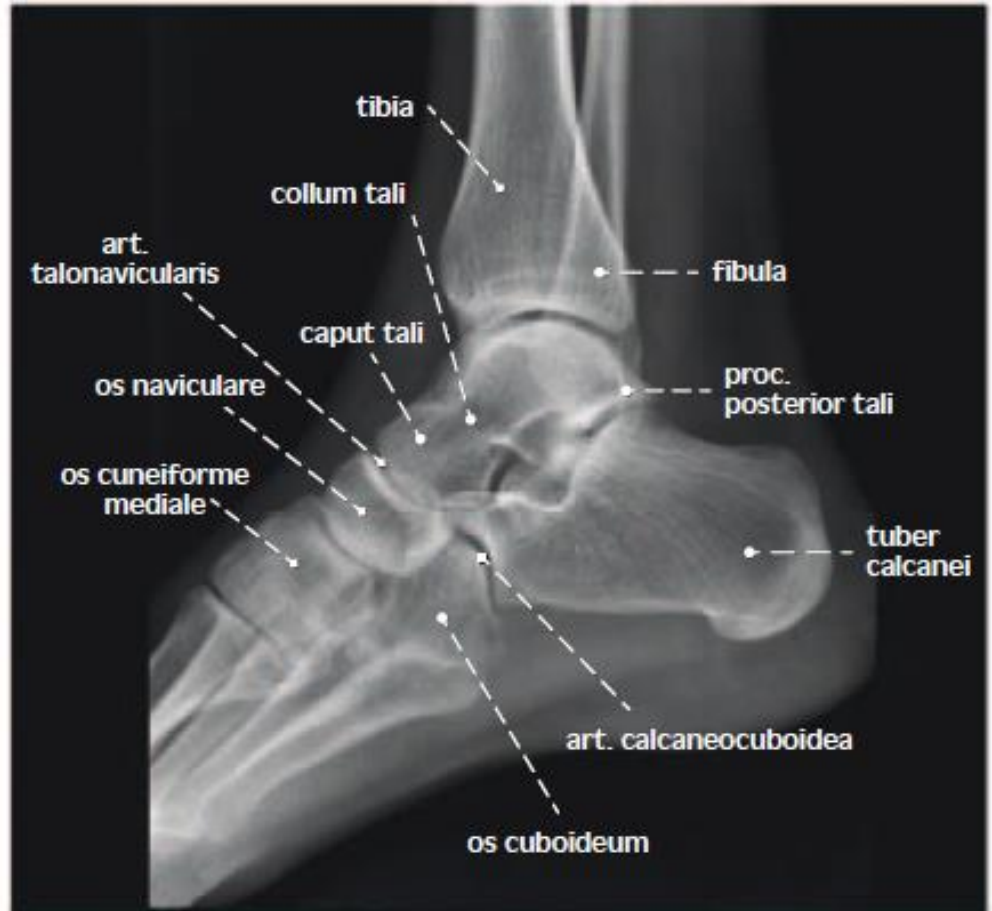
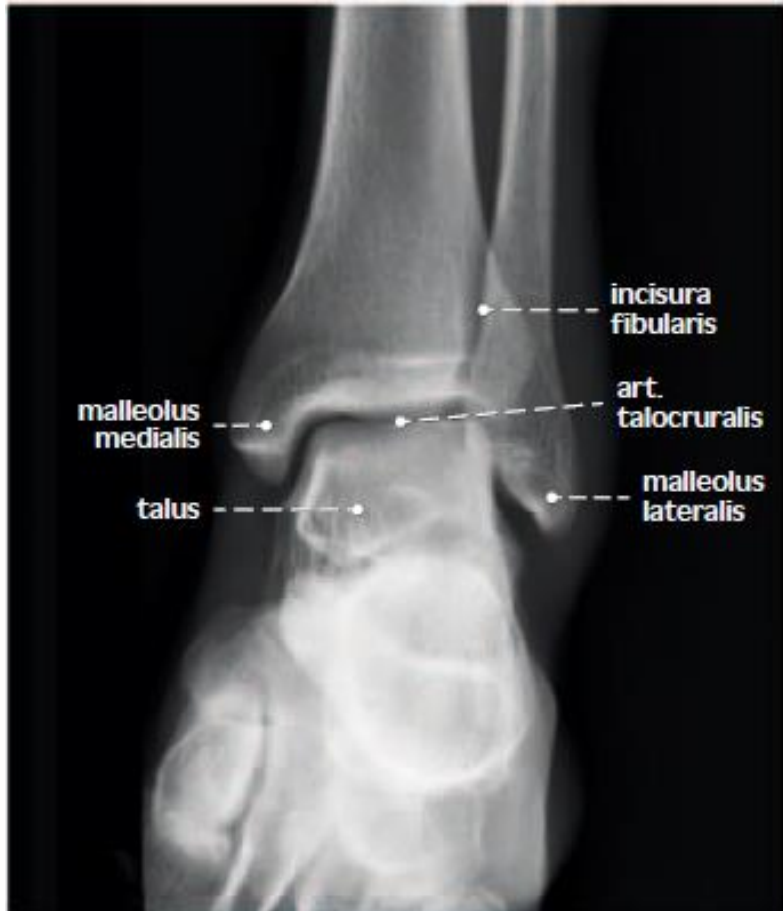

epiphysis distalis tibiae

R

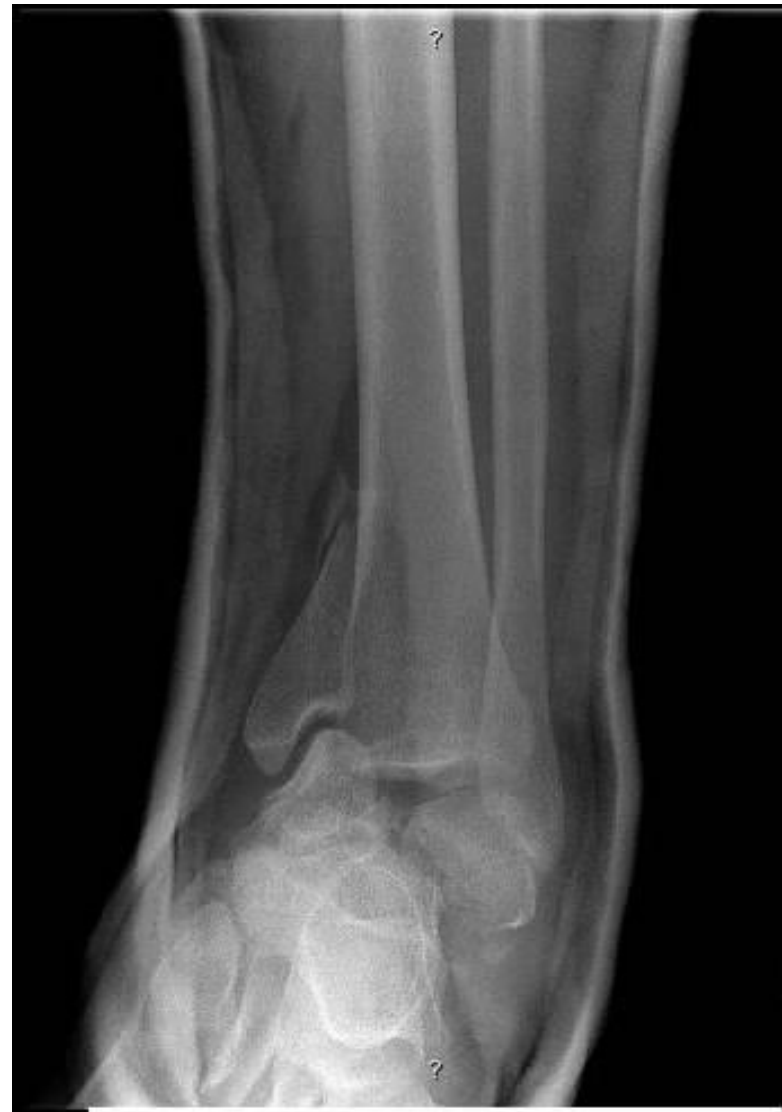
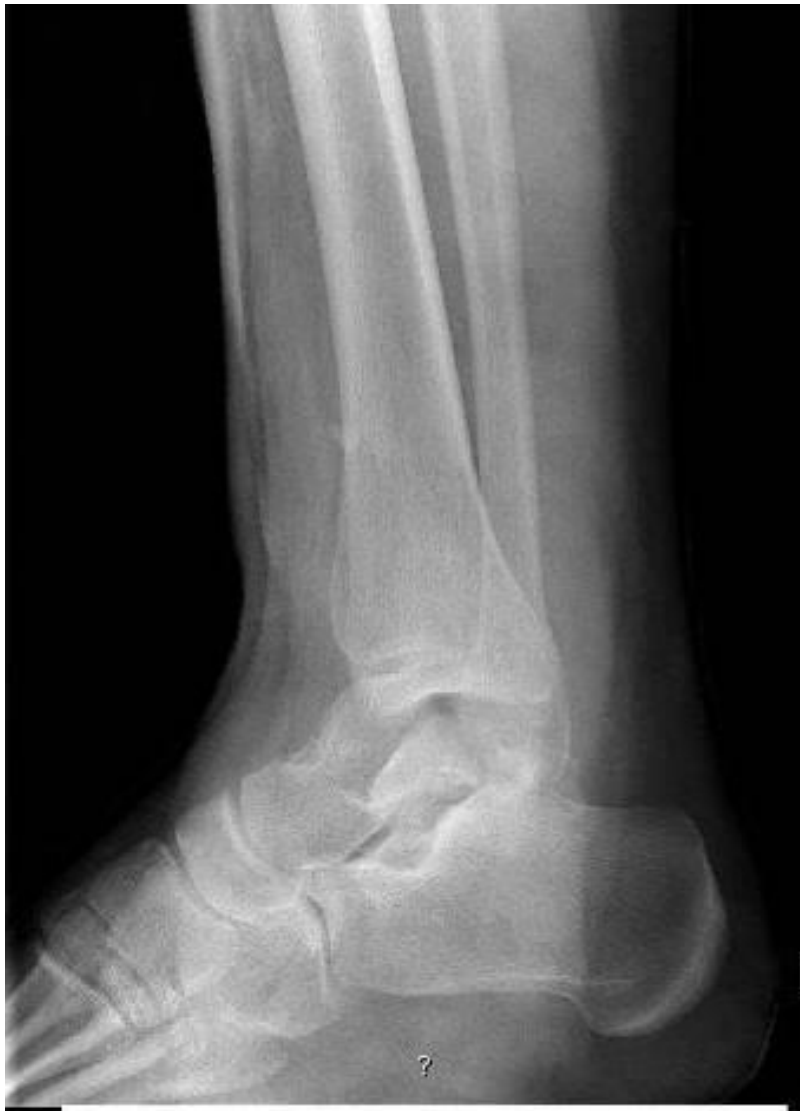
dospělý / adult

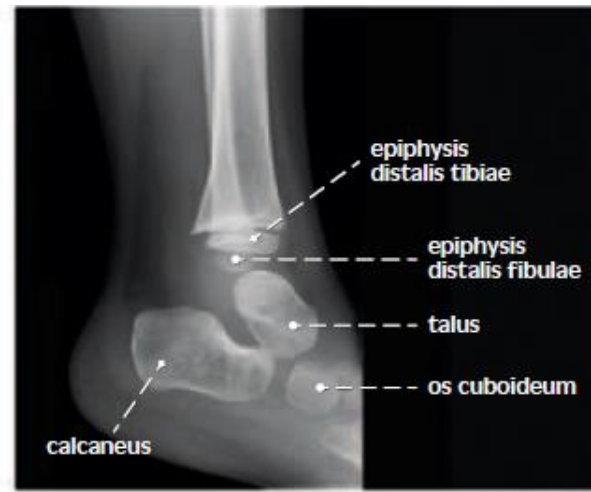
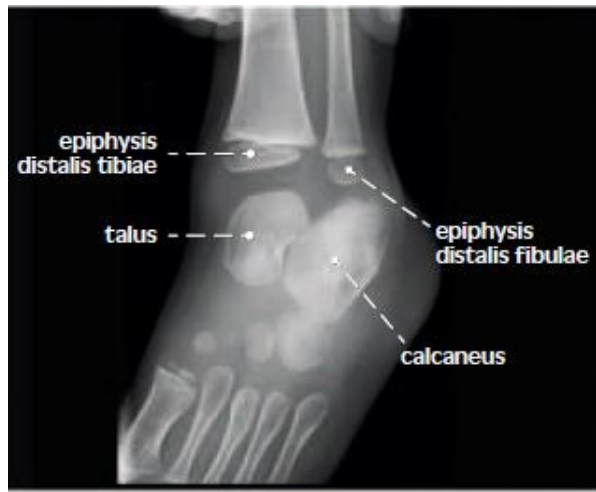

dospělý / adult

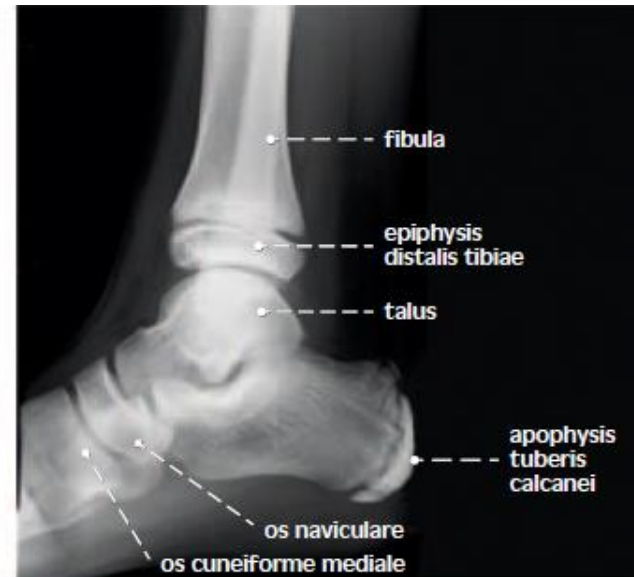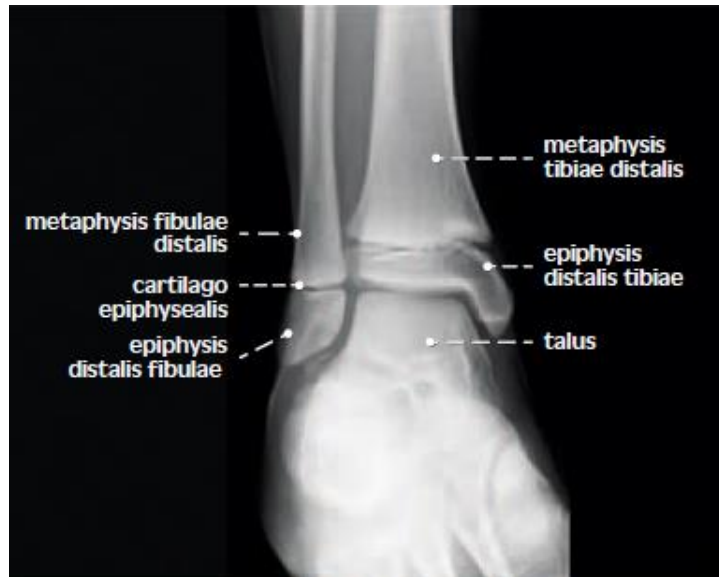Fractura malleoli medialis tibiae dislocata



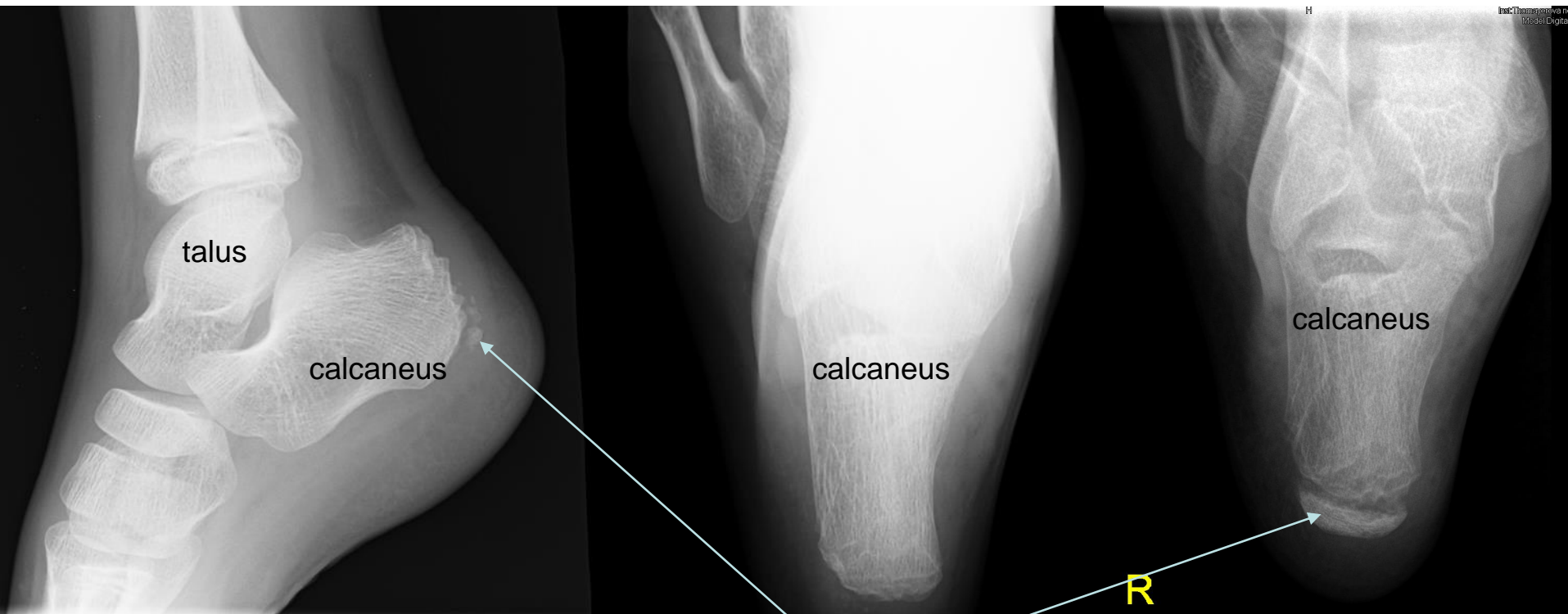
dospělý / adult



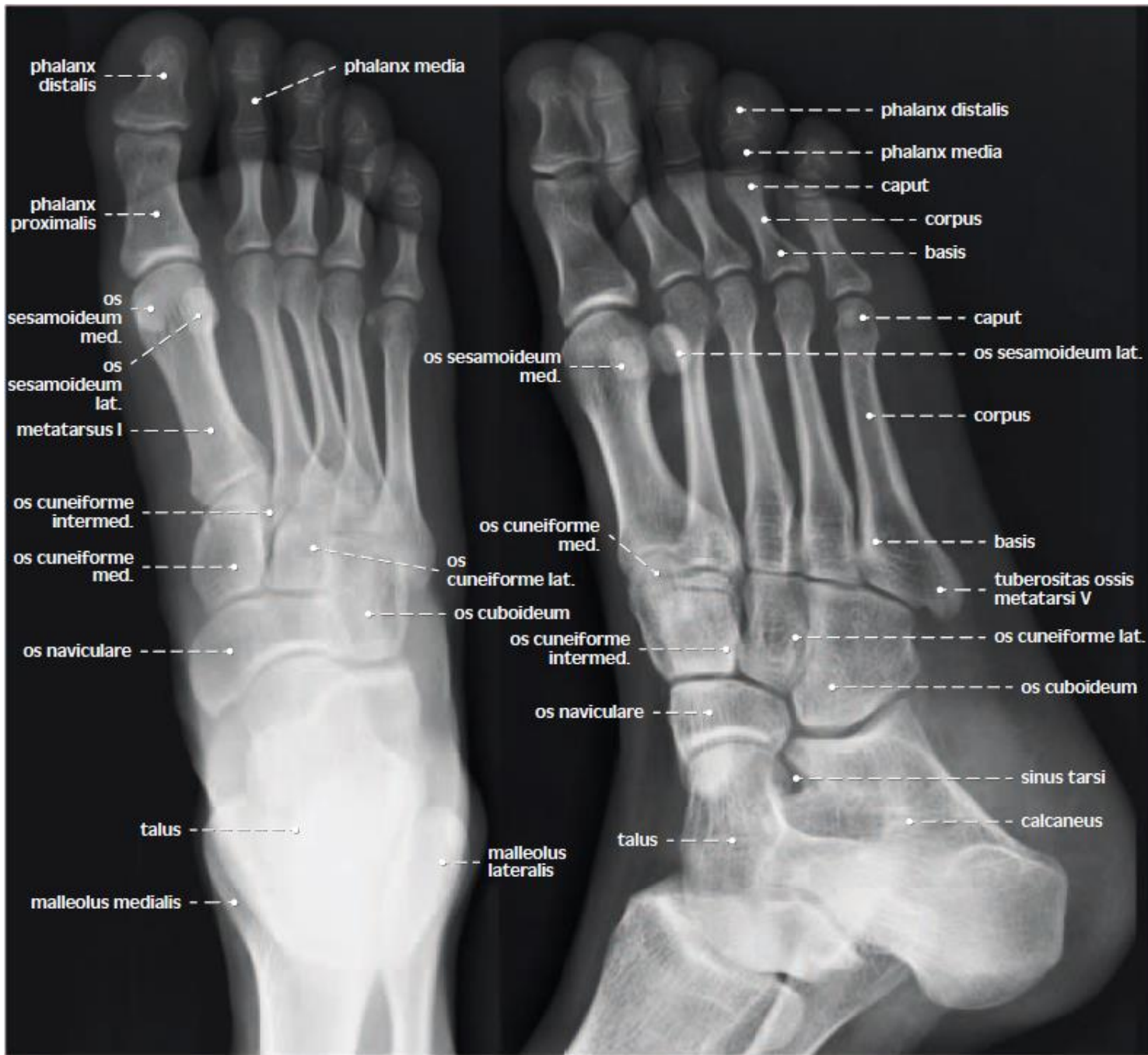3 roky + 9 měsíců / 3 years and 9 months

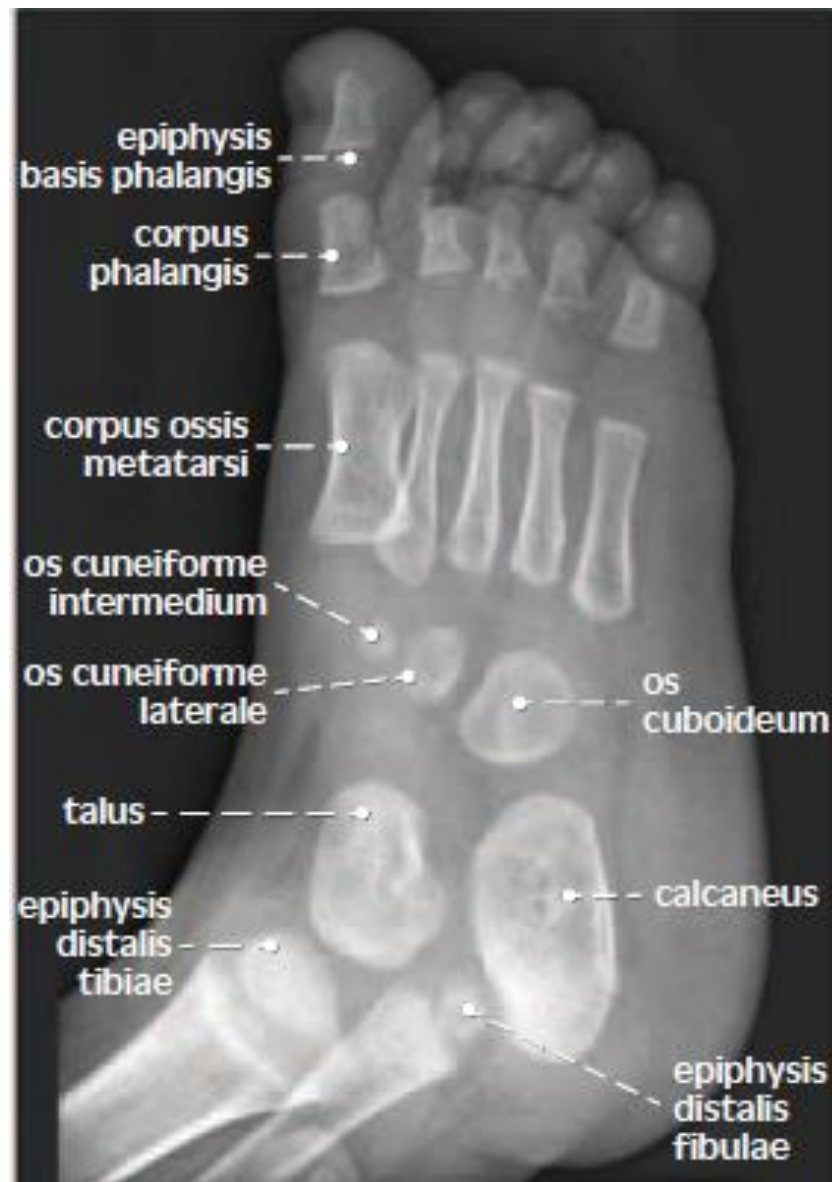

10 let / 10 years



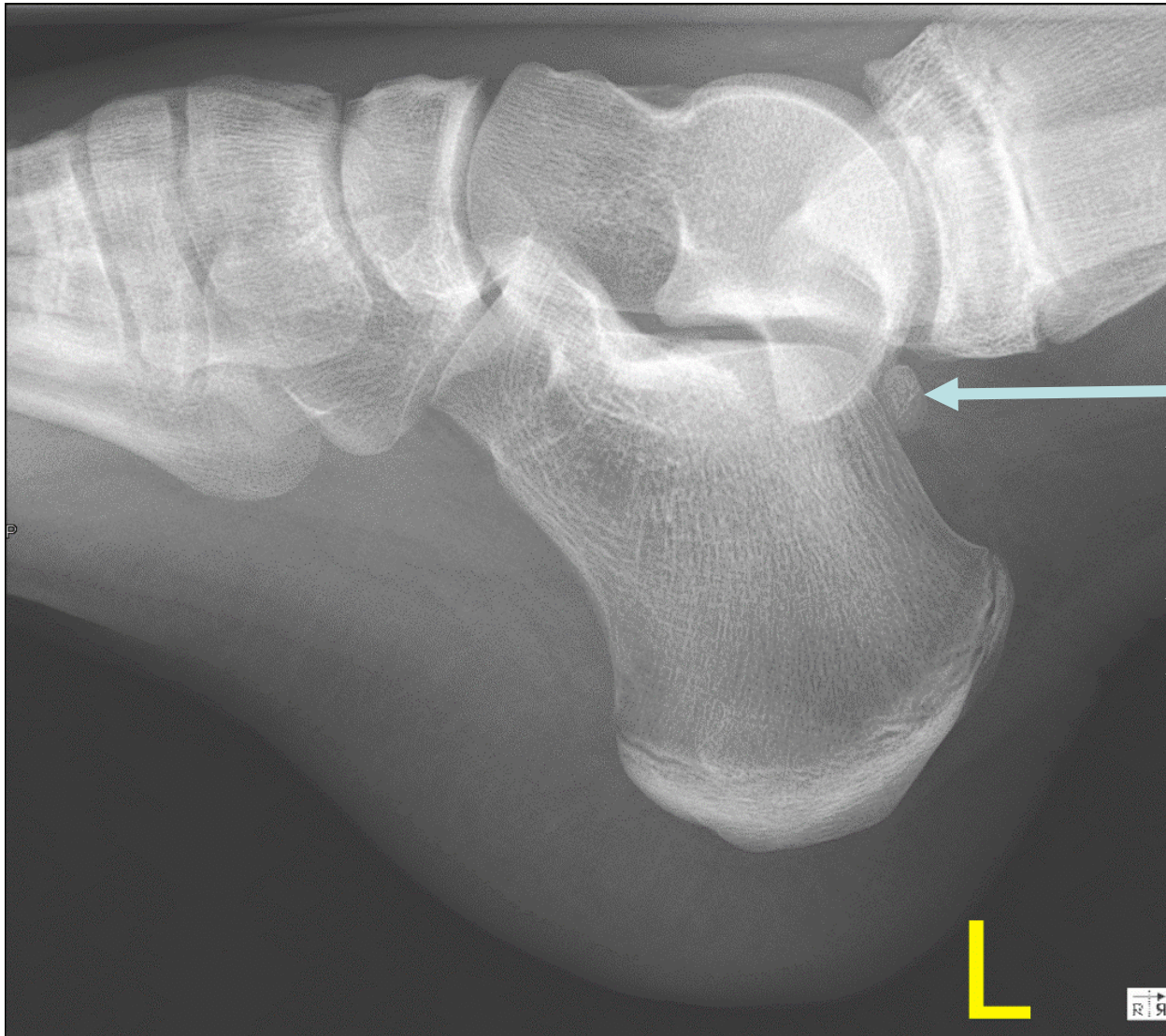dětský věk / childhood





*laterální projekce
chlapec 16 měsíců / boy 16 months*

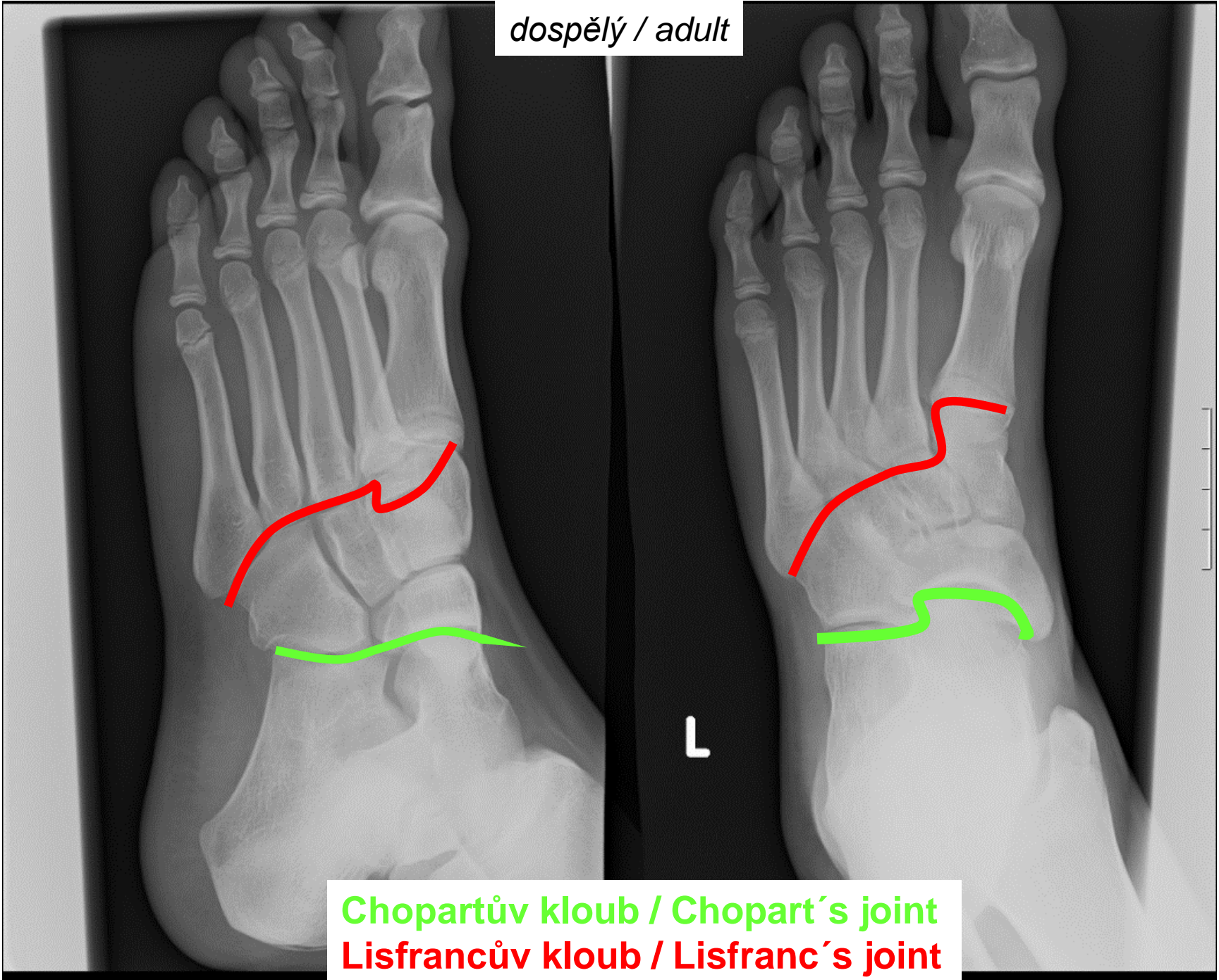
Nadpočetná zánártní kost



os trigonum

11 let / 11 years old

dospělý / adult



Chopartův kloub / Chopart's joint
Lisfrancův kloub / Lisfranc's joint