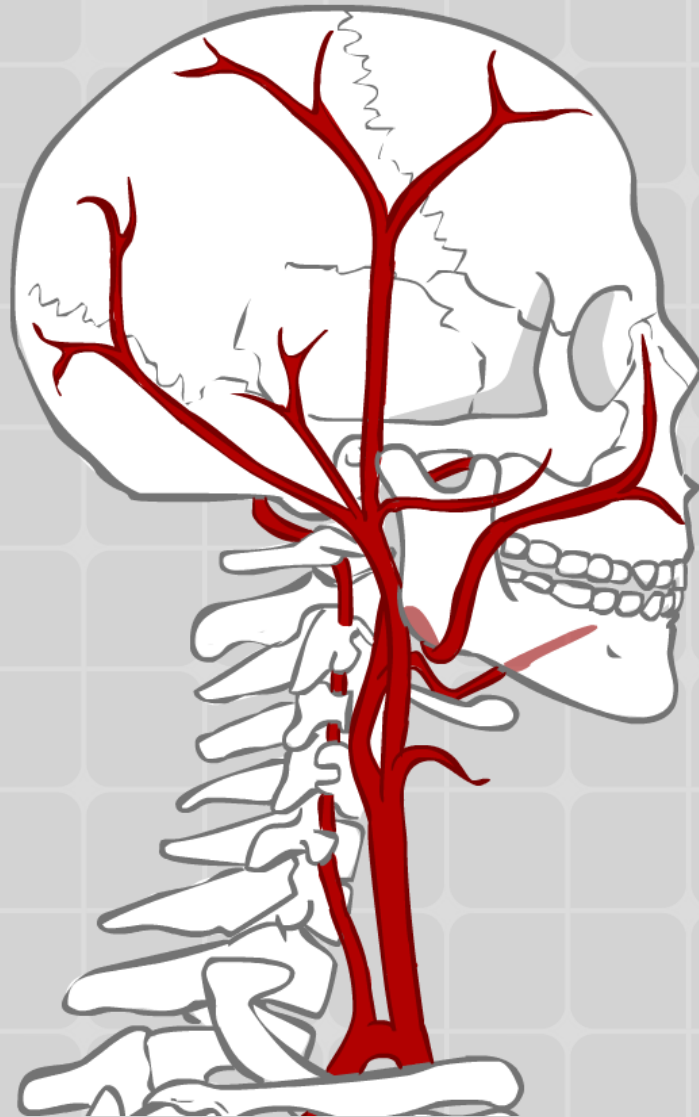


Krevní a lymfatické cévy



MUDr. Radovan Hudák

**Tato prezentace je určena studentům 1. ročníku
Bc. Fyzioterapie na 2. lékařské fakultě Univerzity Karlovy.**

Zdroj popisů:

- HUDÁK, Radovan, KACHLÍK, David. Memorix anatomie.
3. vydání. Praha: Triton, 2015, 632 s. ISBN: 978-80-7387-959-4

Zdroj obrázků:

- HUDÁK, Radovan, KACHLÍK, David. Memorix anatomie.
3. vydání. Praha: Triton, 2015, 632 s. ISBN: 978-80-7387-959-4
- NETTER F.H. Atlas of human anatomy: the anatomical basis of clinical practice, 5th Edition. Philadelphia : Elsevier/Saunders, 2010.

Osnova

1. Tepny

1. Srdce (cévní zásobení)
2. Přehled tepen hrudníku, břicha a pánve
3. Přehled tepen hlavy a krku
4. Tepny horní končetiny
5. Tepny dolní končetiny

2. Žíly

1. Žíly dolní končetiny
2. Žíly horní končetiny
3. Žíly hlavy a krku
4. Žilní systém horní a dolní duté žíly
5. Systém veny portae

3. Lymfatický systém

1. Lymfatický systém (orgány, hlavní kmene, skupiny mízních uzlin)
2. Lymfatická drenáž končetin

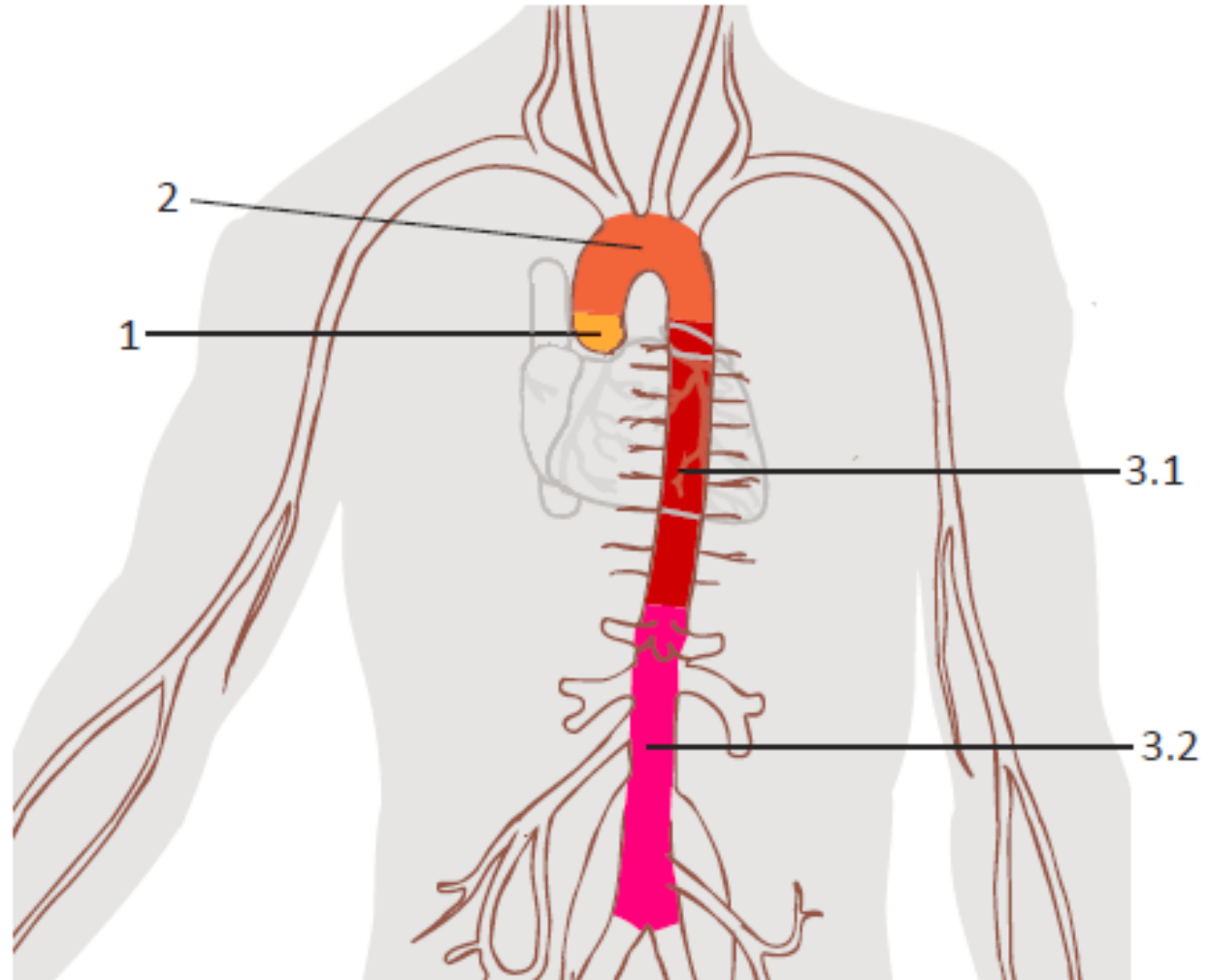
Tepny a žíly

Tepny

1. Začátek
2. Průběh
3. Větve
4. Oblast zásobení

Žíly

1. Začátek
2. Přítoky
3. Průběh
4. Oblast sběru krve



1.1 Srdce – cévní zásobení

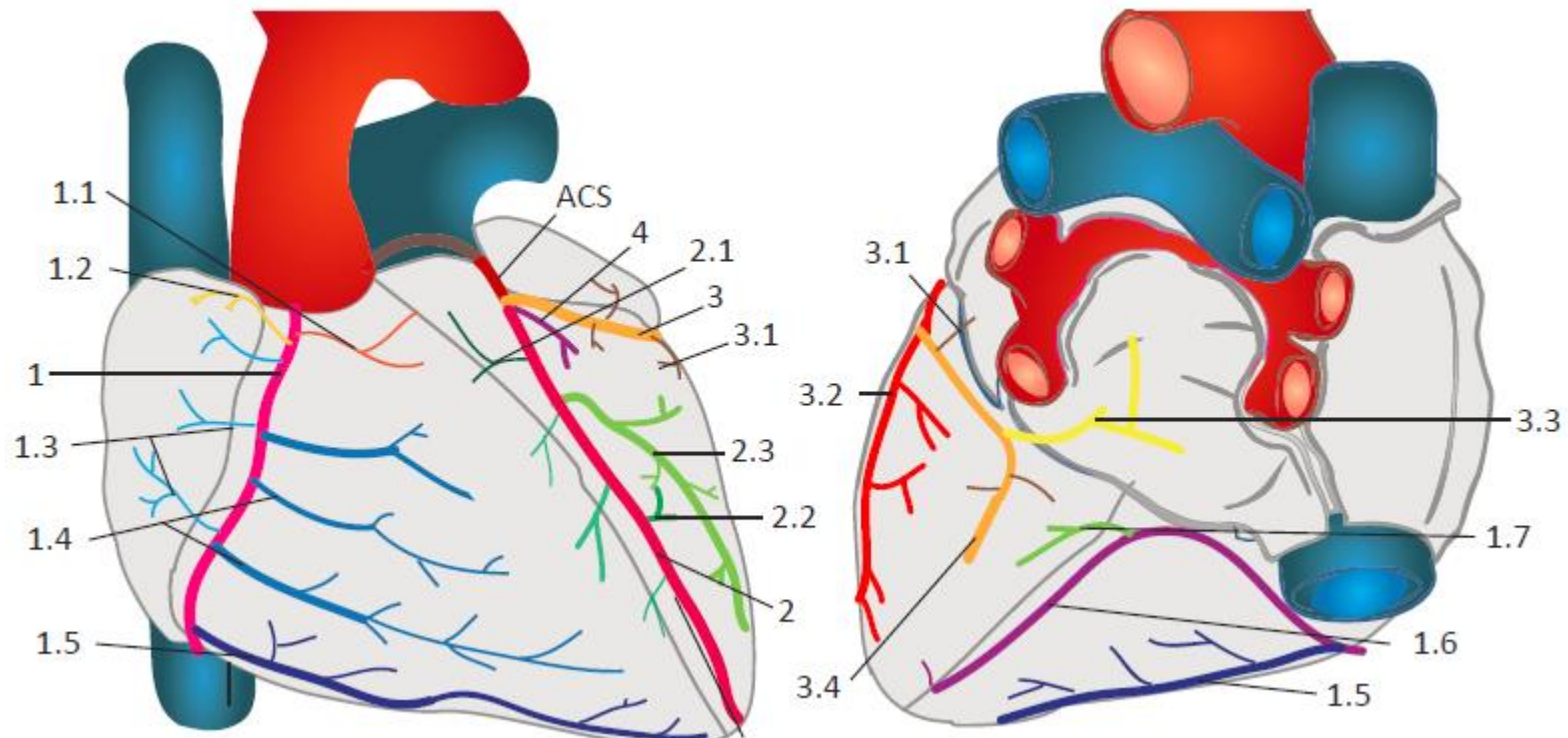
Tepny srdce:

1 Arteria coronaria dextra

Arteria coronaria sinistra

2 Ramus interventricularis anterior (RIA)

3 Ramus circumflexus



1.1 Srdce – cévní zásobení

Žíly srdce

1 Sinus coronarius

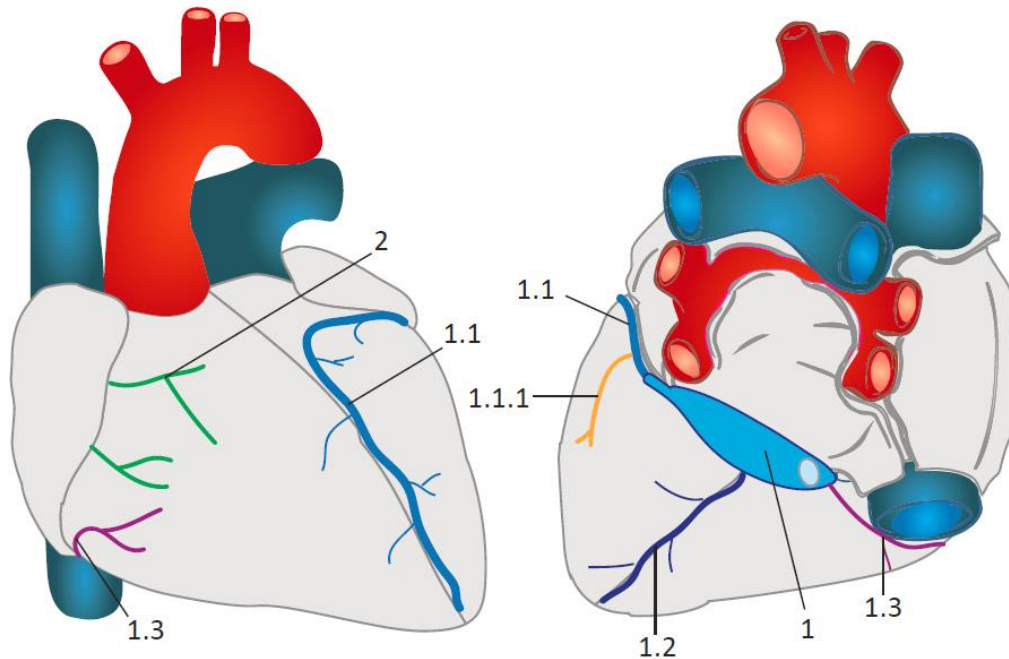
1.1 Vena cardiaca magna

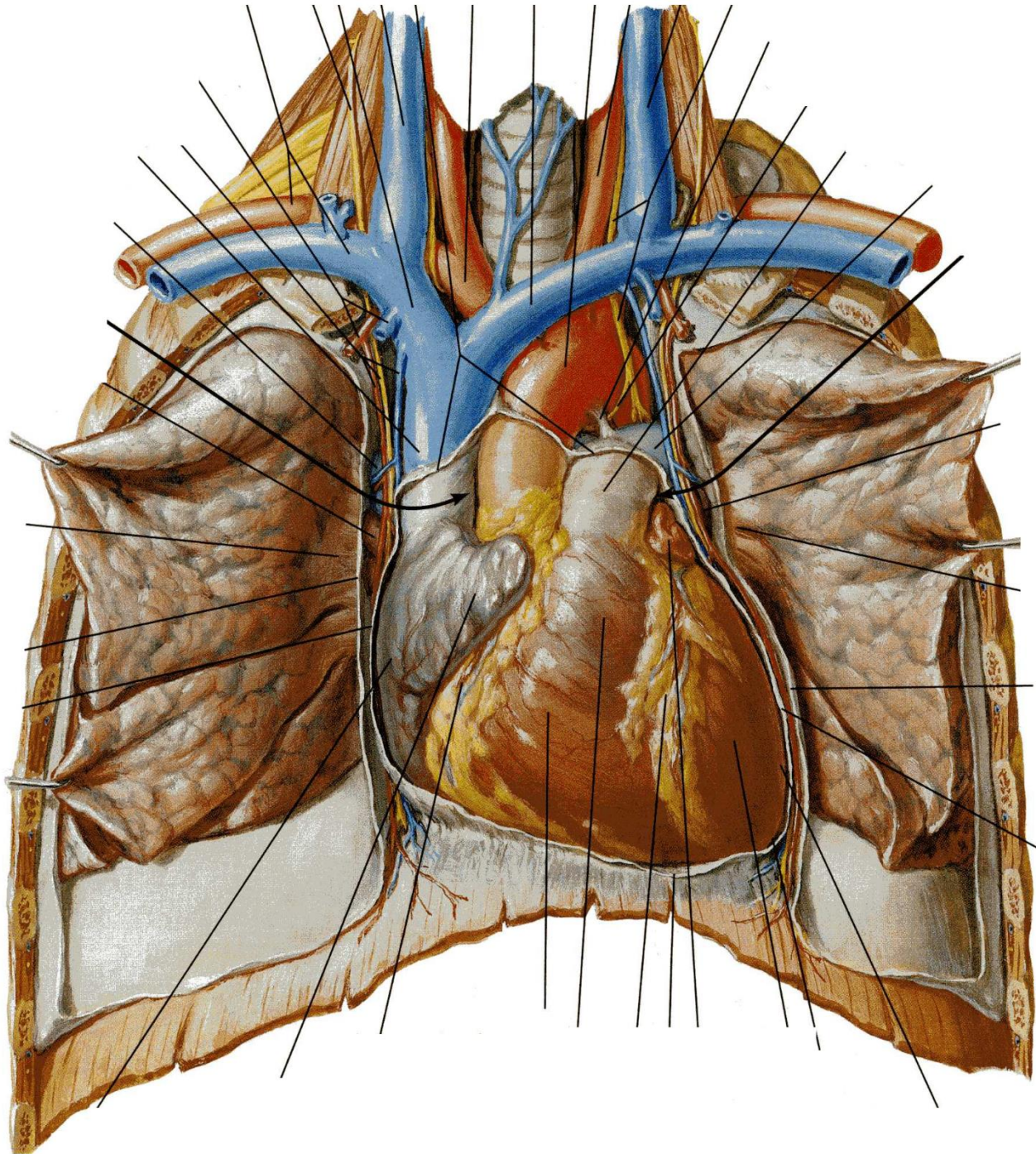
1.2 Vena cardiaca media

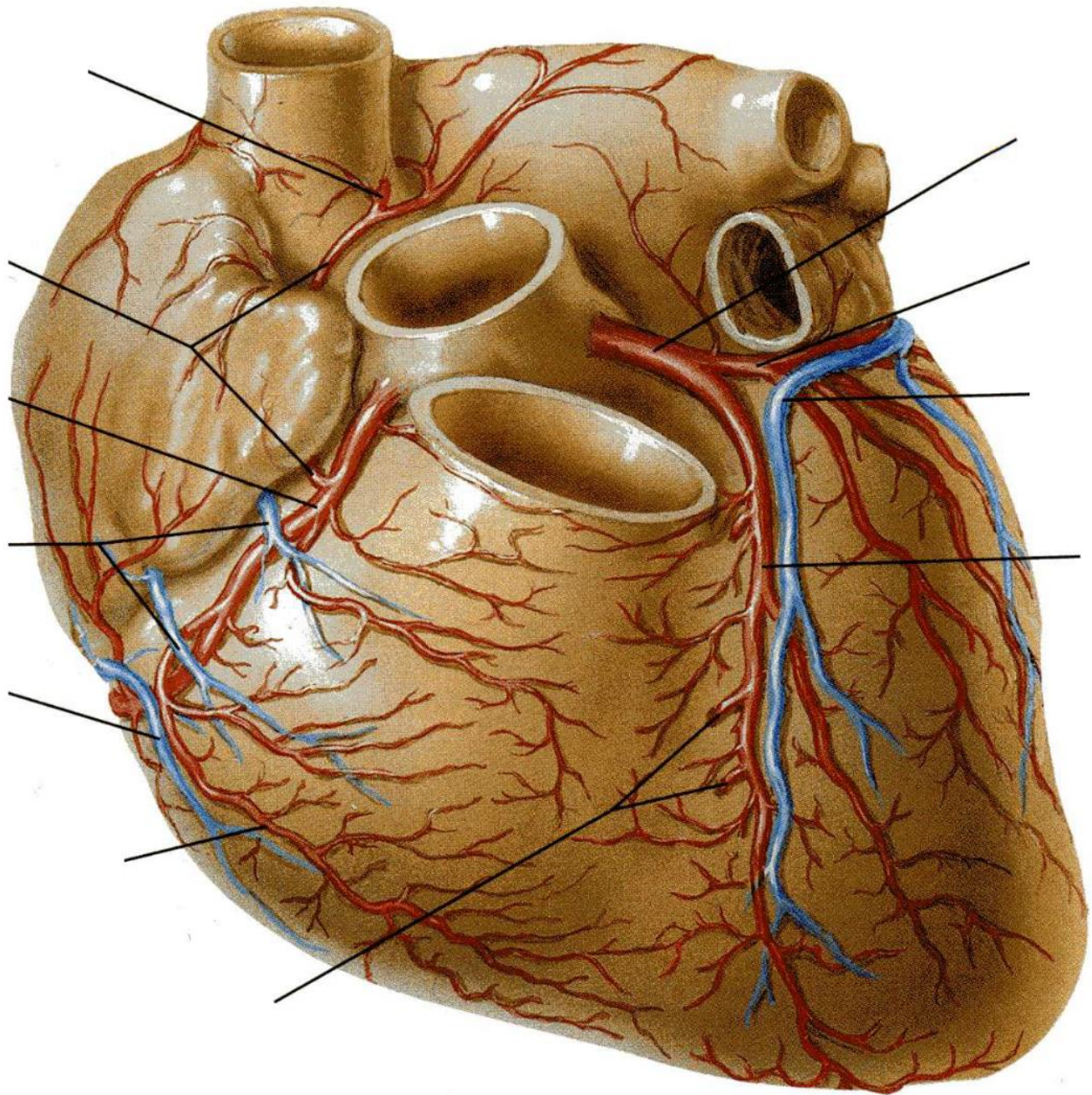
1.3 Vena cardiaca parva

2 Venae ventriculi dextri anteriores

3 Venae cardiaca minimae







1.2 Přehled tepen hrudníku, břicha a pánve

Aorta:

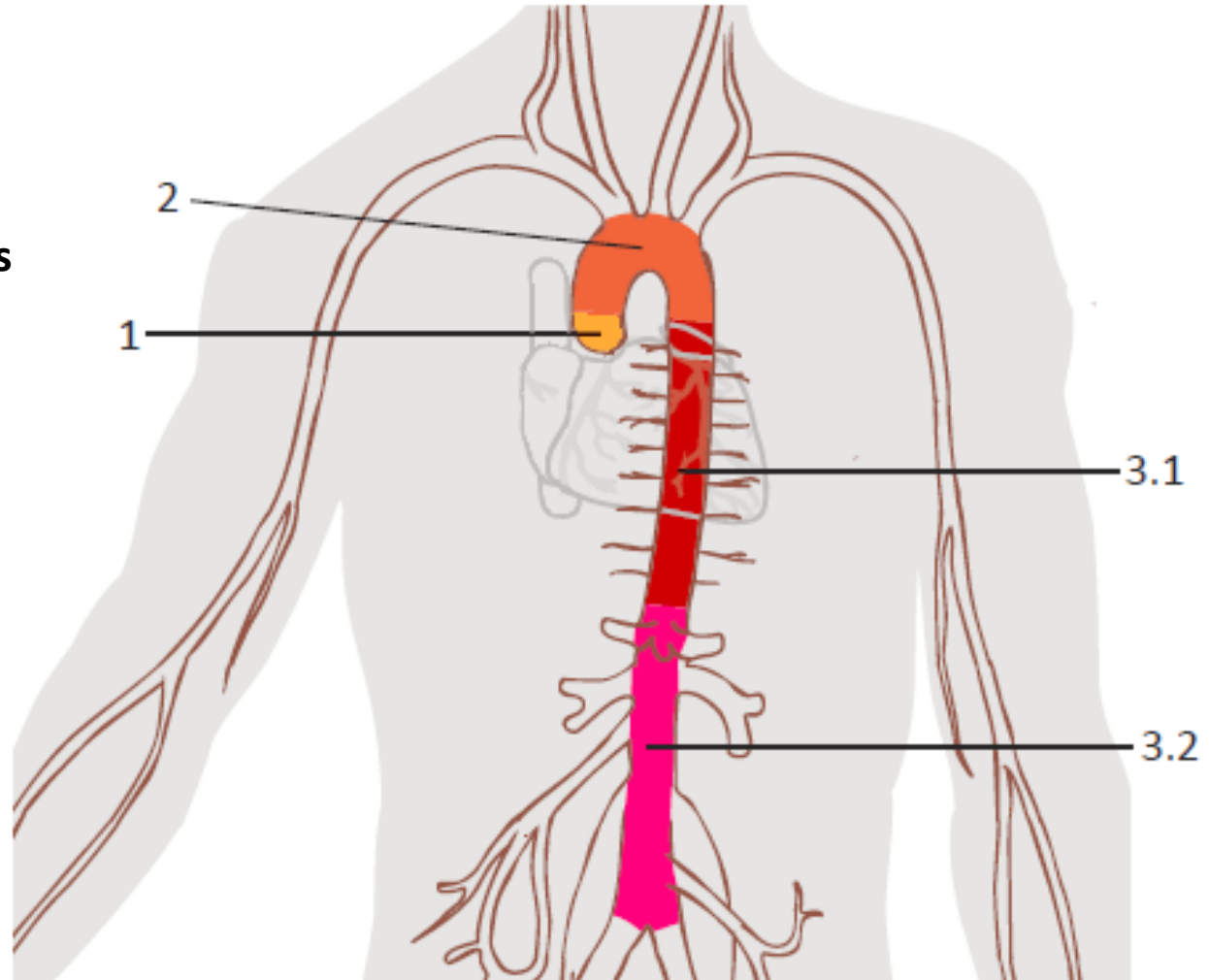
1 Aorta ascendens

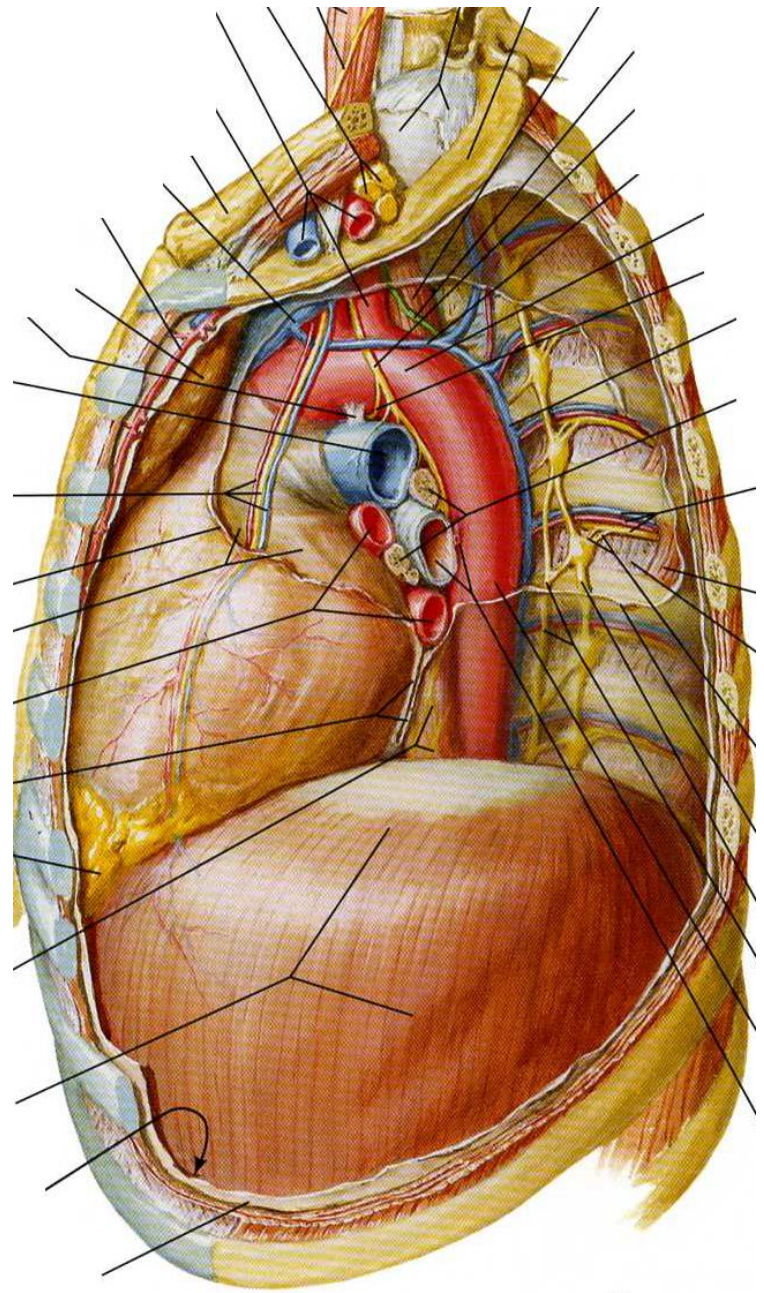
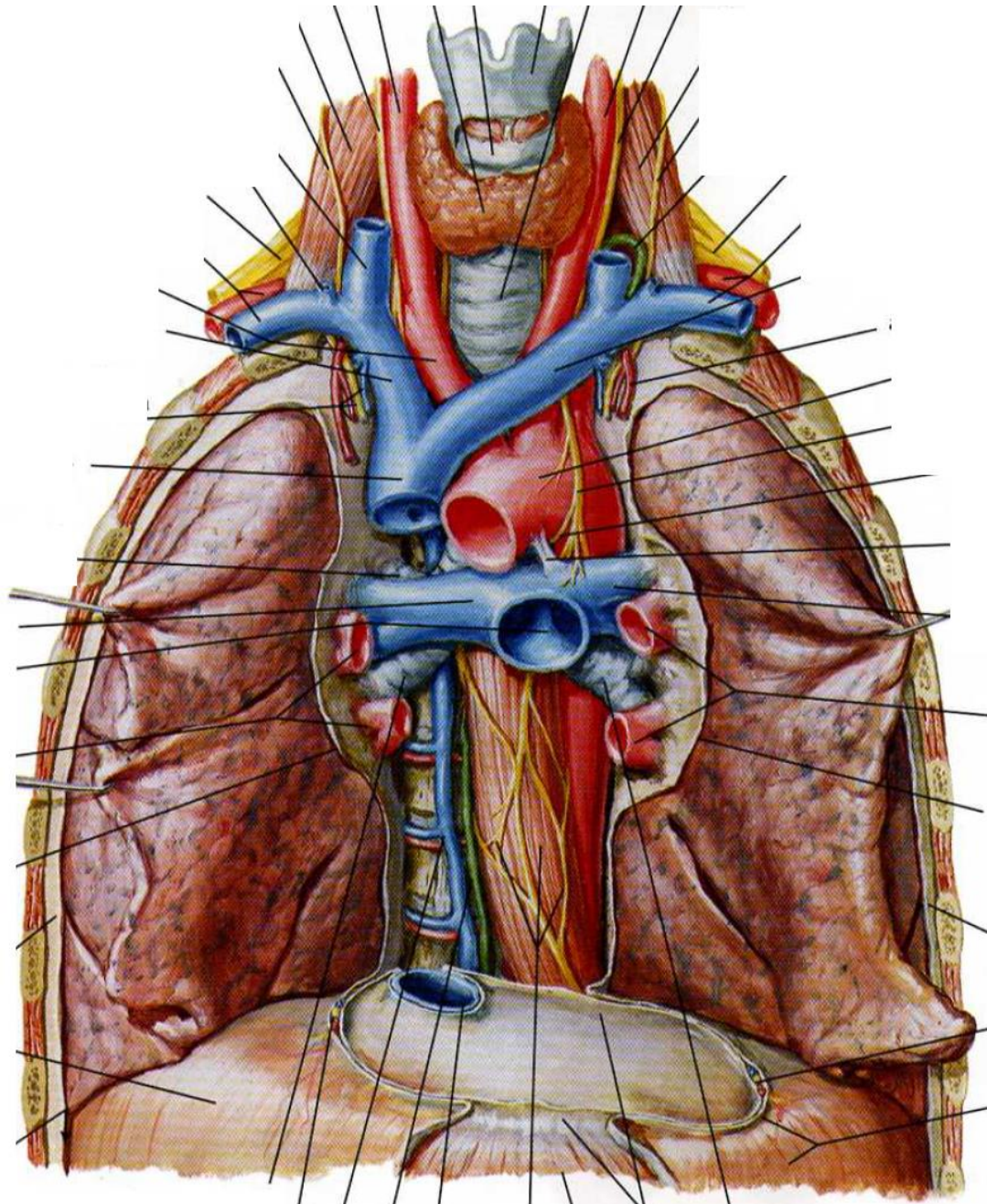
2 Arcus aortae

3 Aorta descendens

3.1 Aorta thoracica

3.2 Aorta abdominalis





1.2 Přehled tepen hrudníku, břicha a pánve

Arcus aortae

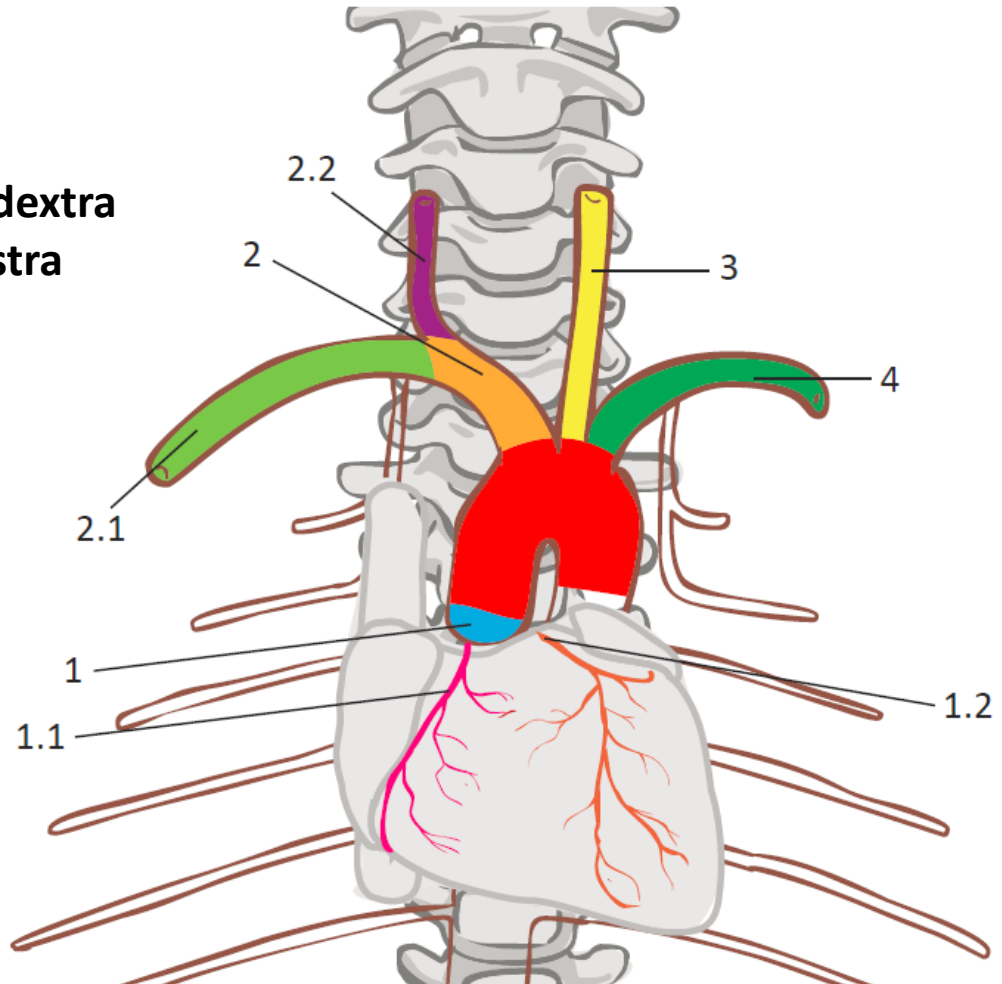
2 Truncus brachiocephalicus

2.1 Arteria subclavia dextra

2.2 Arteria carotis communis dextra

3 Arteria carotis communis sinistra

4 Arteria subclavia sinistra



1.2 Přehled tepen hrudníku, břicha a pánve

Tepny hrudníku:

Parietální větve aorta thoracica

1 **Arteriae intercostales posteriores**

2 **Arteriae phrenicae superiores**

Viscerální větve aorta thoracica

3 **Rami bronchiales**

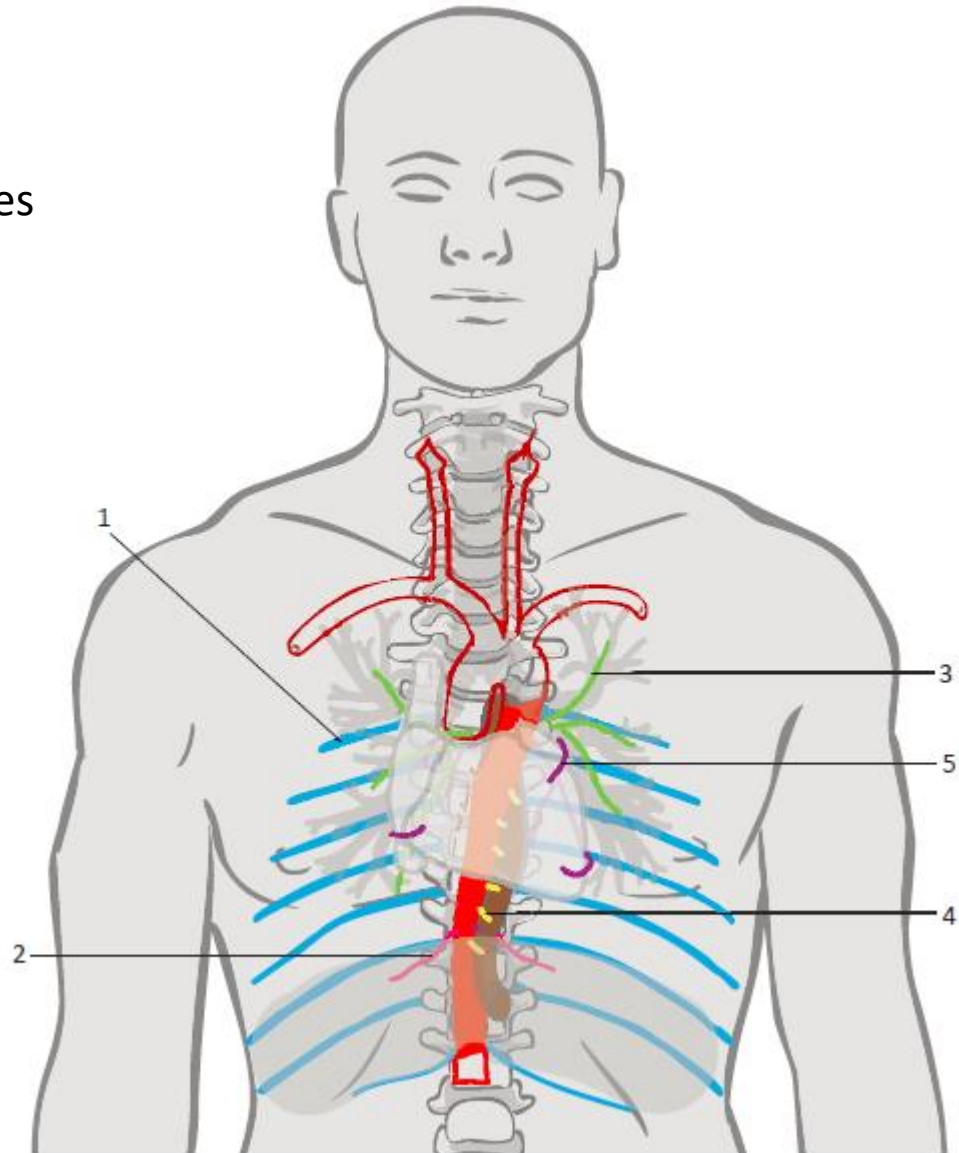
4 **Rami oesophageales**

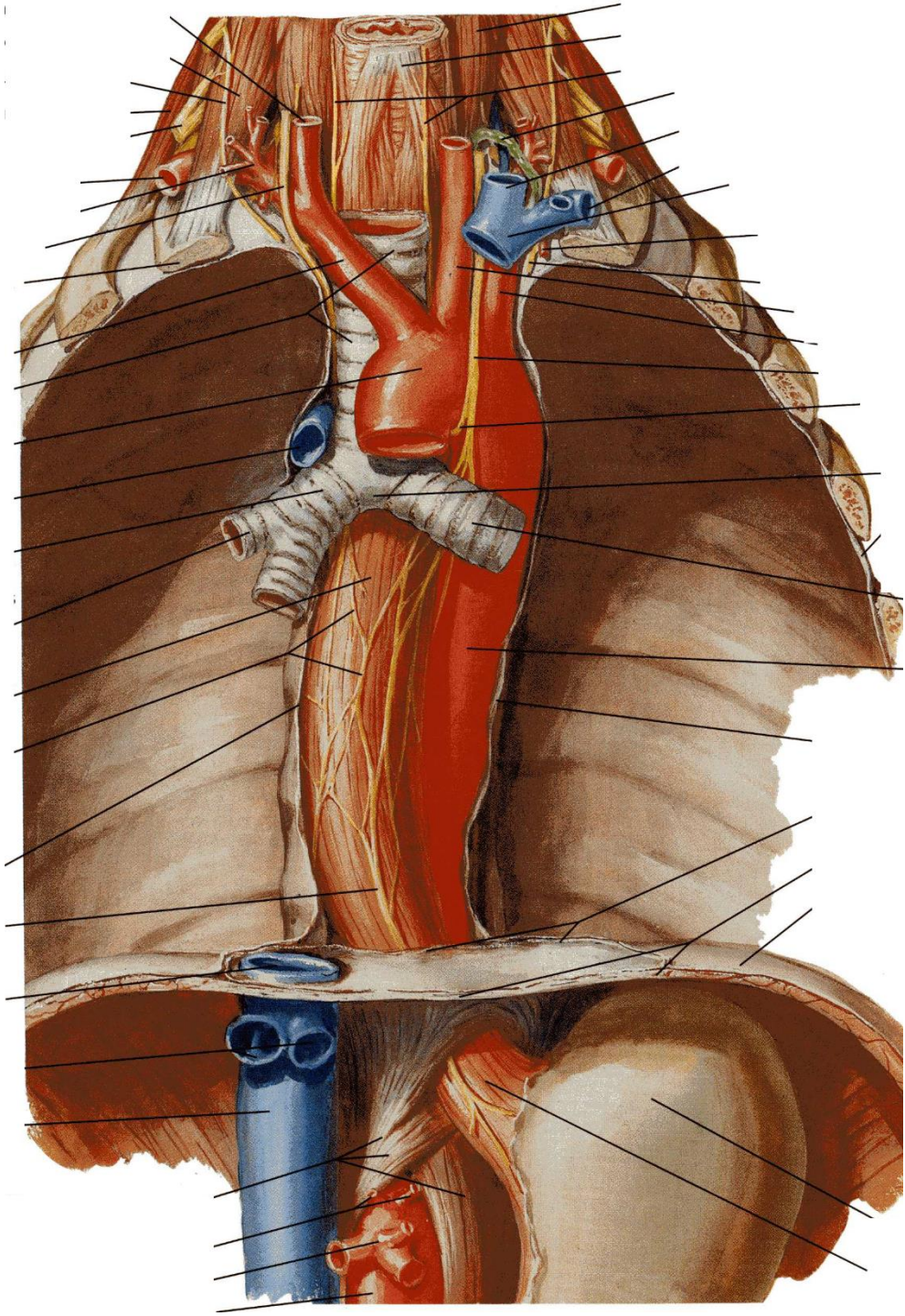
5 **Rami pericardiaci**

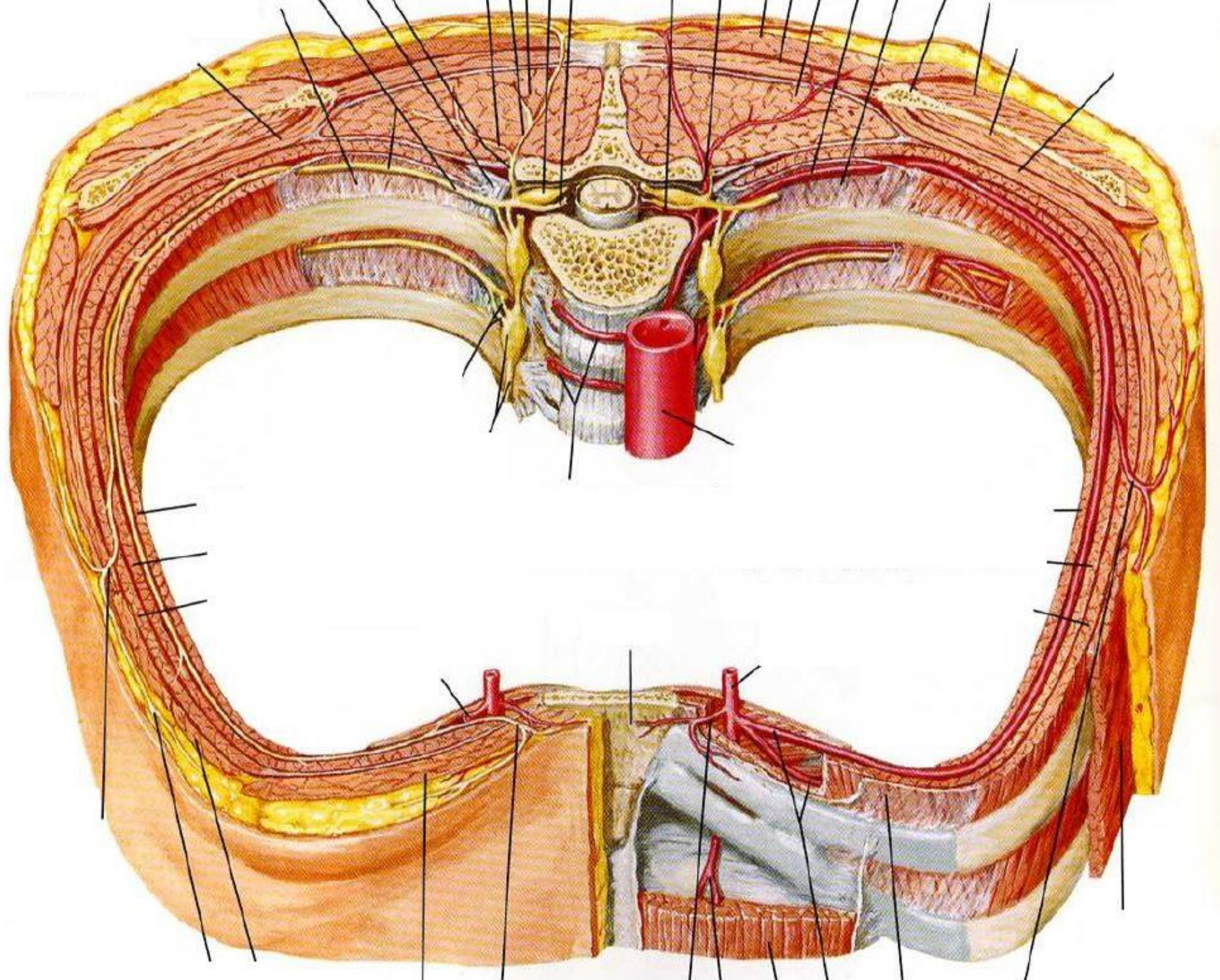
6 **Rami mediastinales**

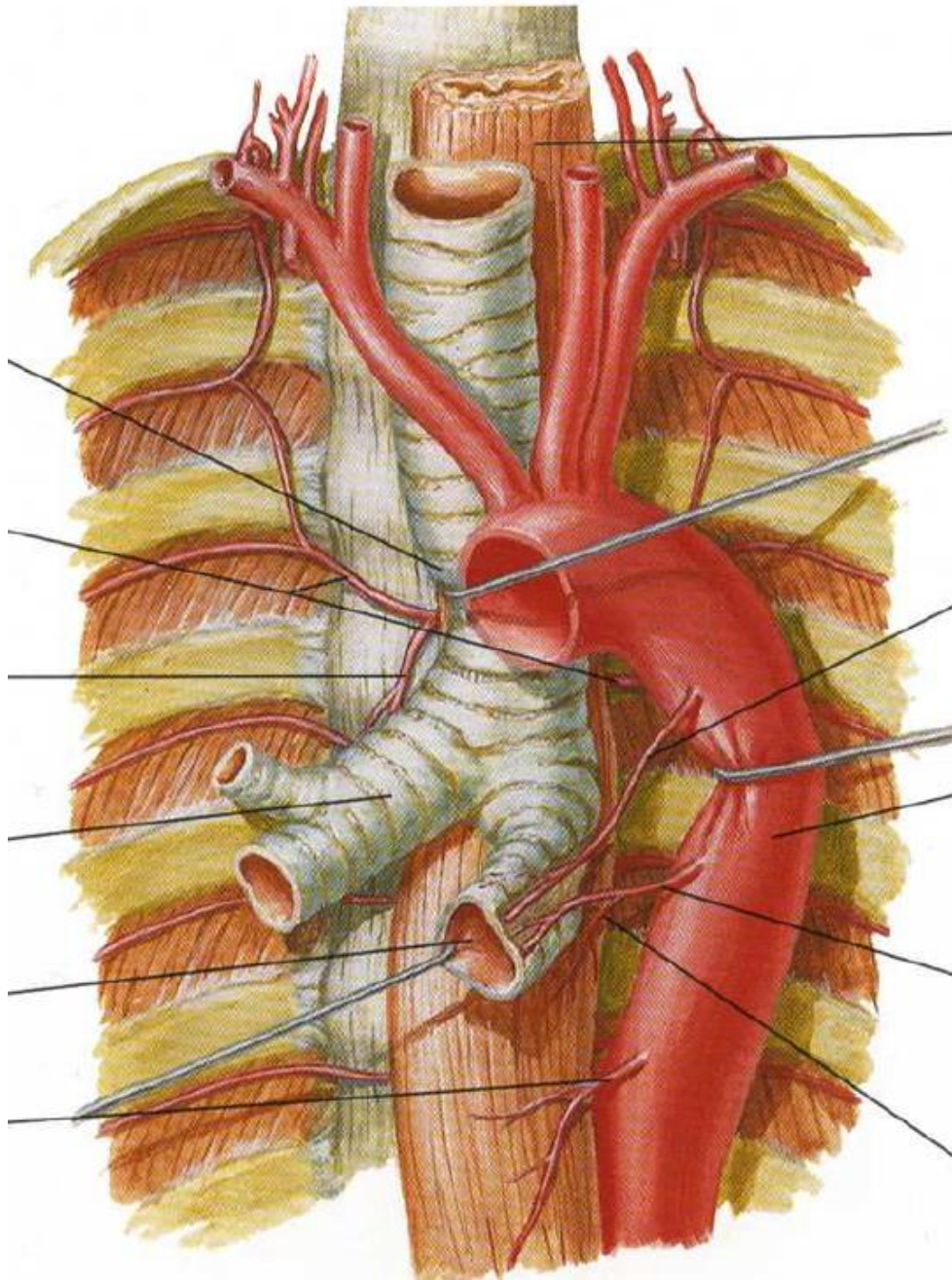
Větev arteria subclavia

Arteria thoracica interna









1.2 Přehled tepen hrudníku, břicha a pánve

Tepny břicha:

Parietální větve aorta abdominalis

1 Arteriae phrenicae inferiores

2 Arteriae lumbales

3 Arteria sacralis mediana

Viscerální párové větve

4 Arteria suprarenalis media

5 **Arteria renalis**

6 **Arteria ovarica** (u ženy)

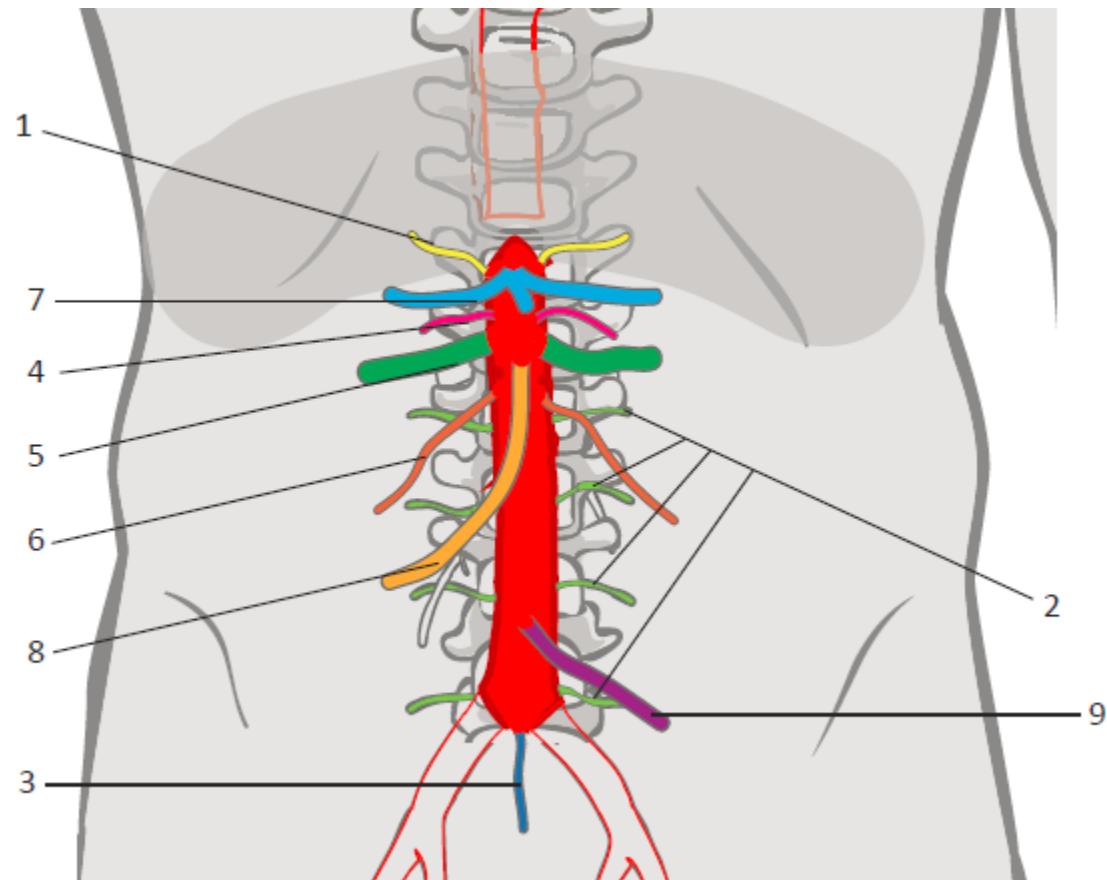
Arteria testicularis (u muže)

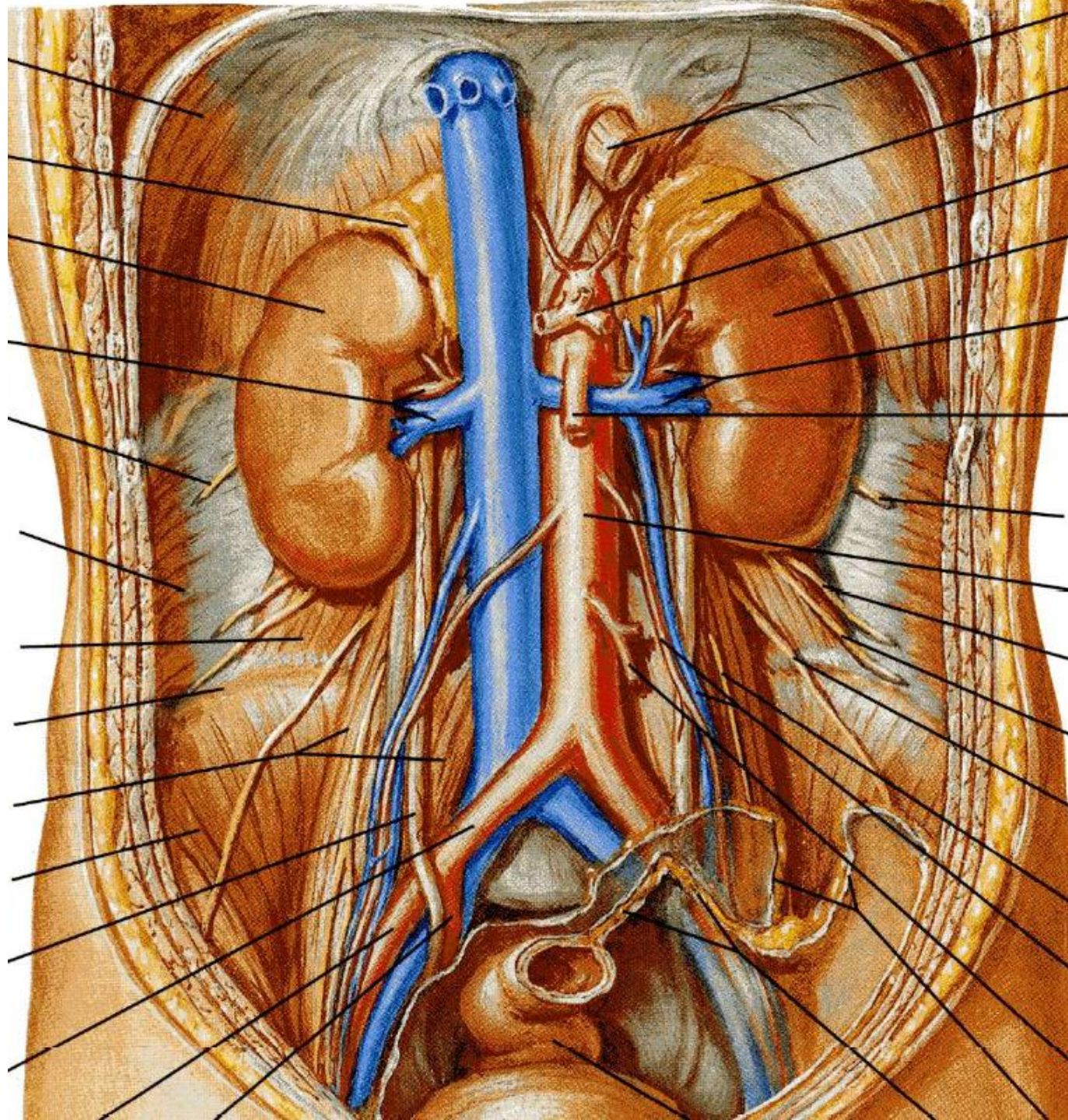
Viscerální nepárové větve

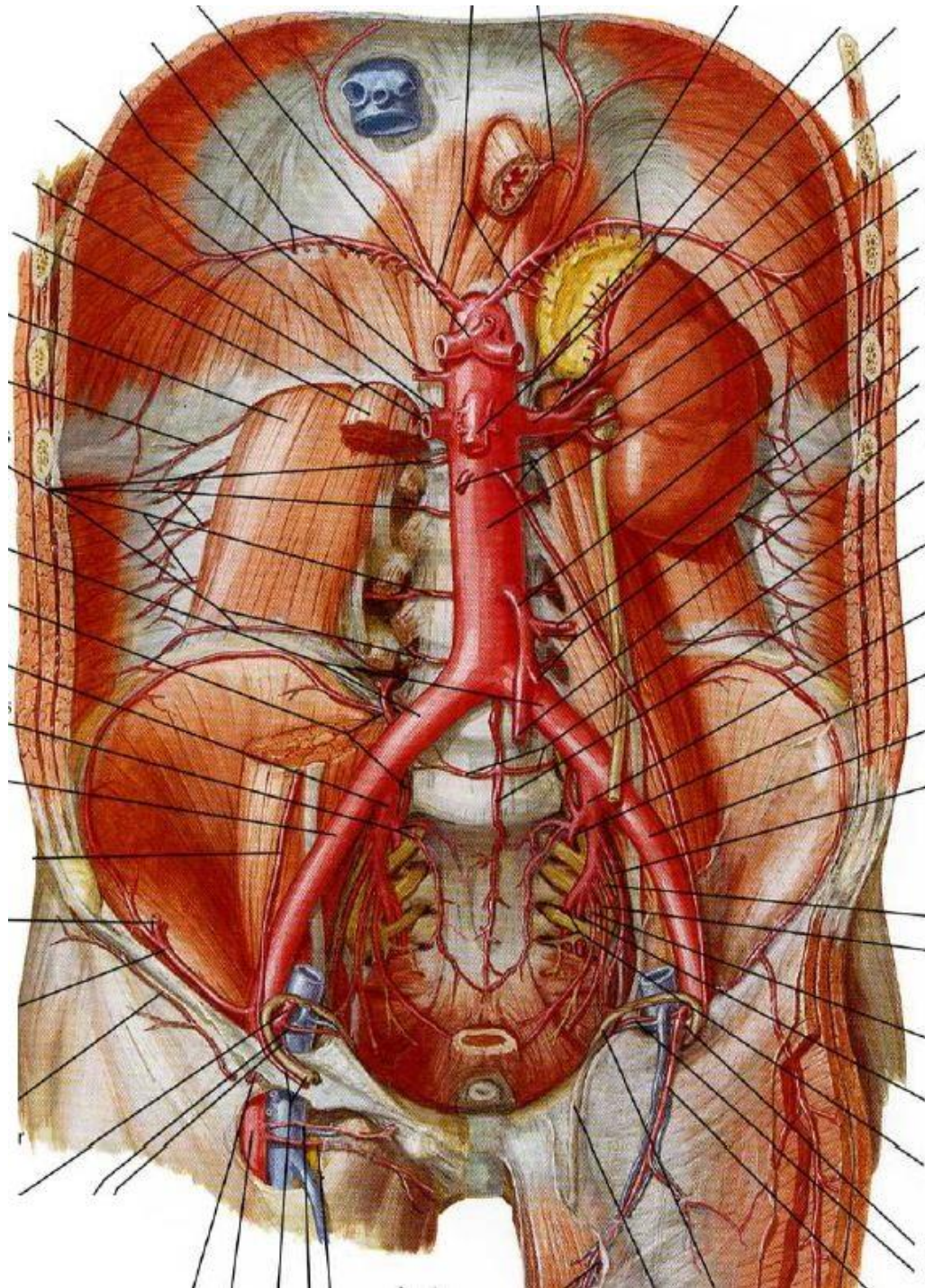
7 **Truncus coeliacus**

8 **Arteria mesenterica superior**

9 **Arteria mesenterica inferior**







1.2 Přehled tepen hrudníku, břicha a pánve

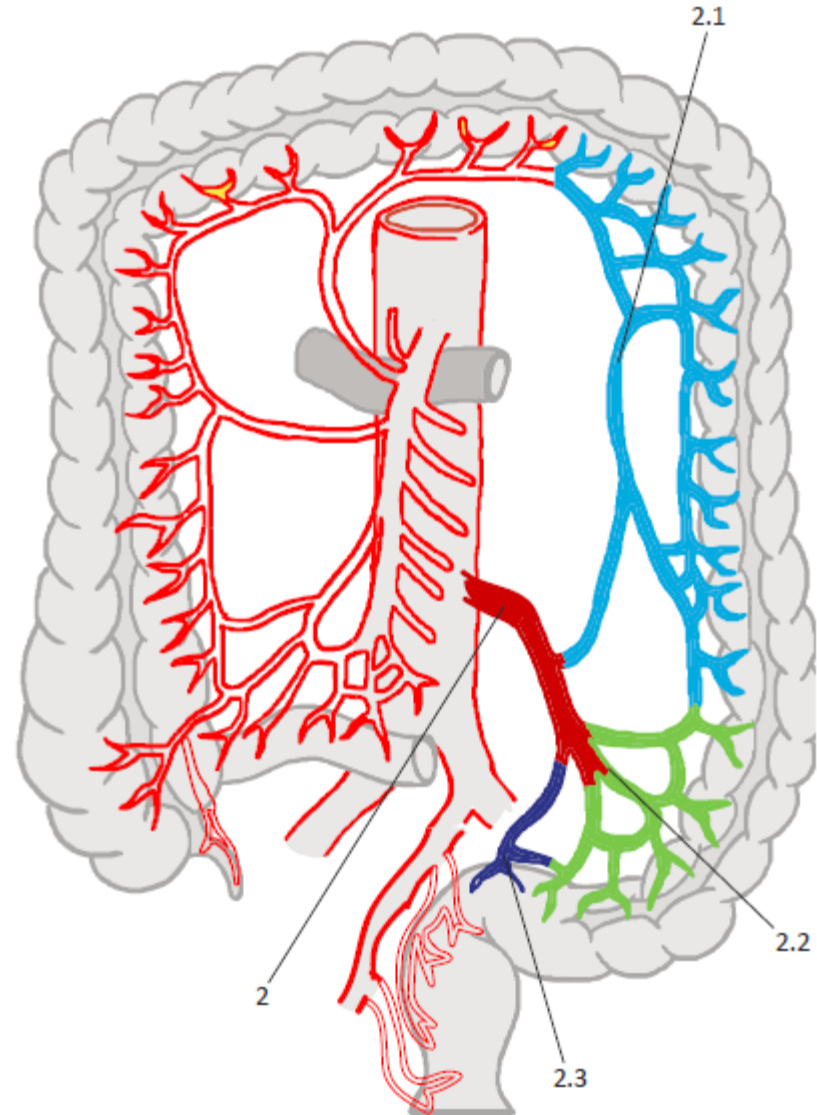
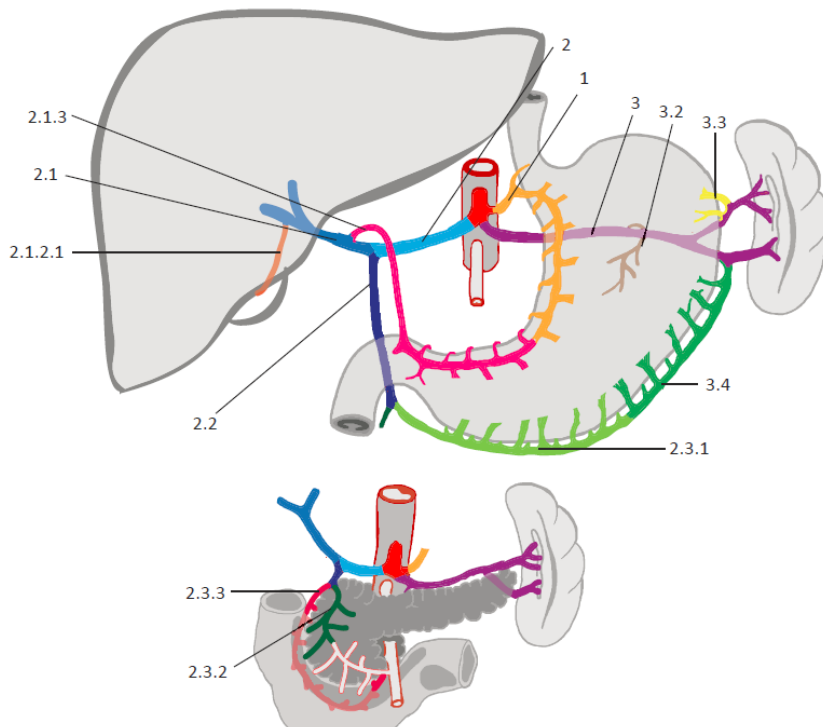
Tepny břicha:

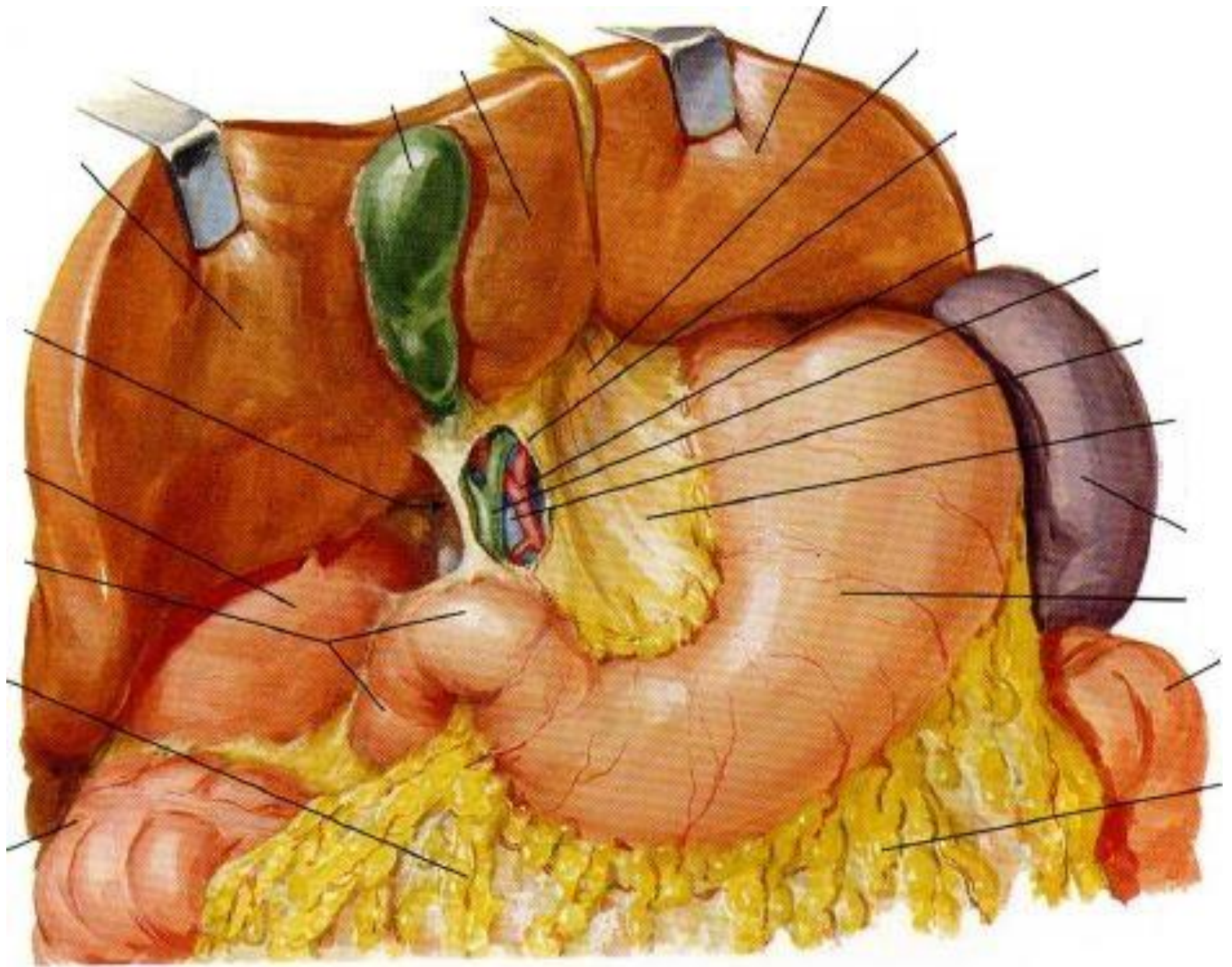
Viscerální nepárové větve

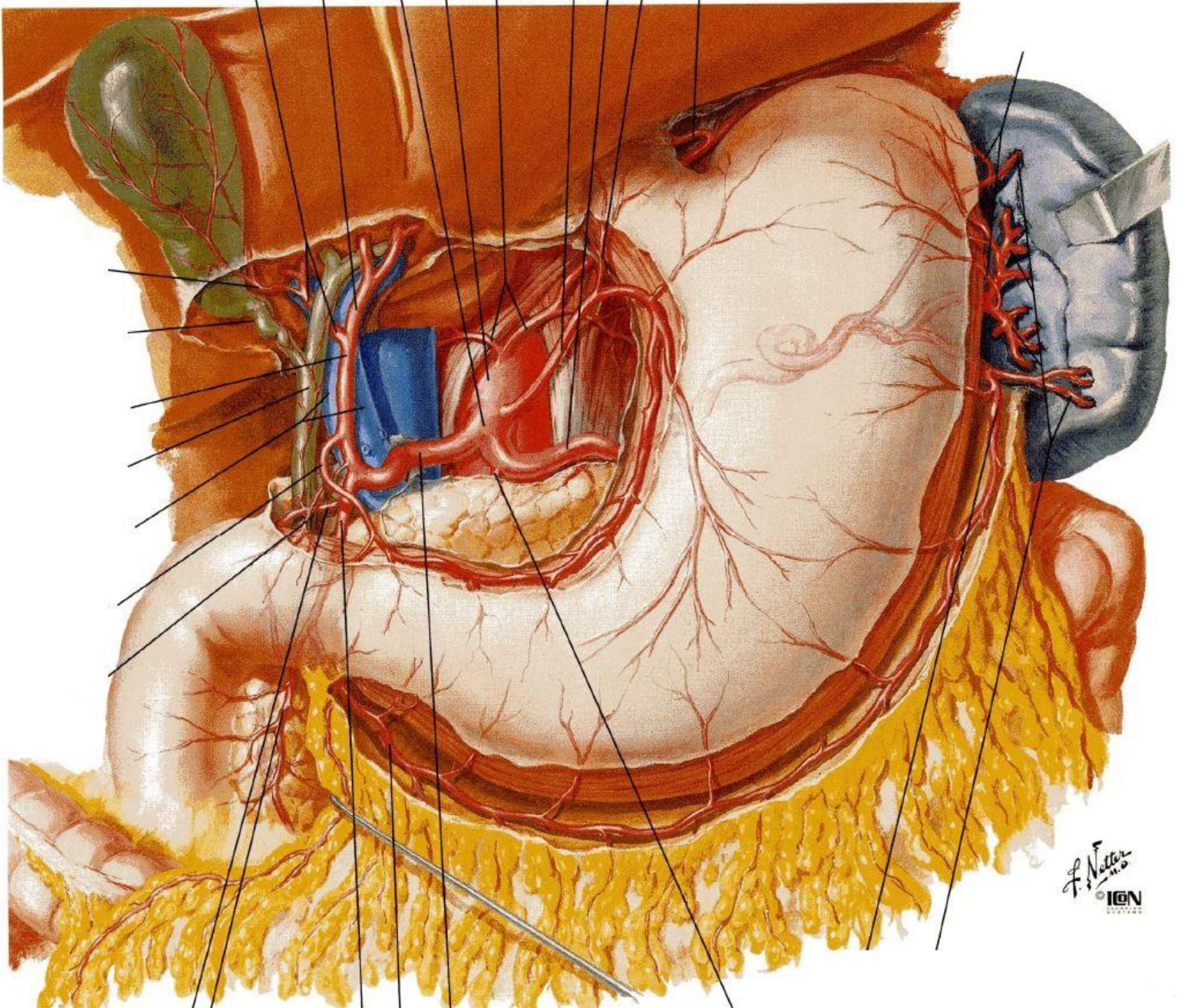
Truncus coeliacus

Arteria mesenterica superior

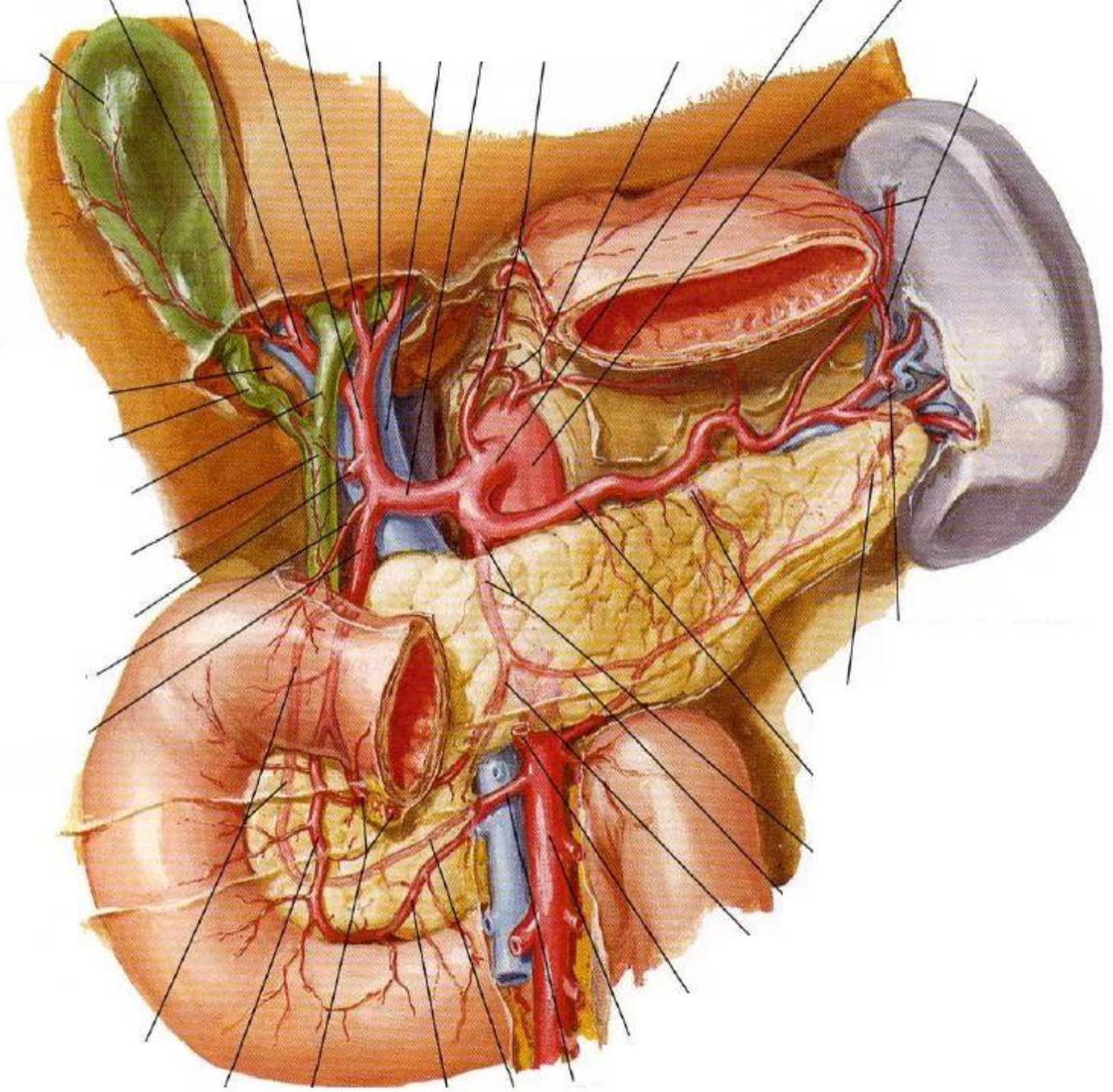
Arteria mesenterica inferior

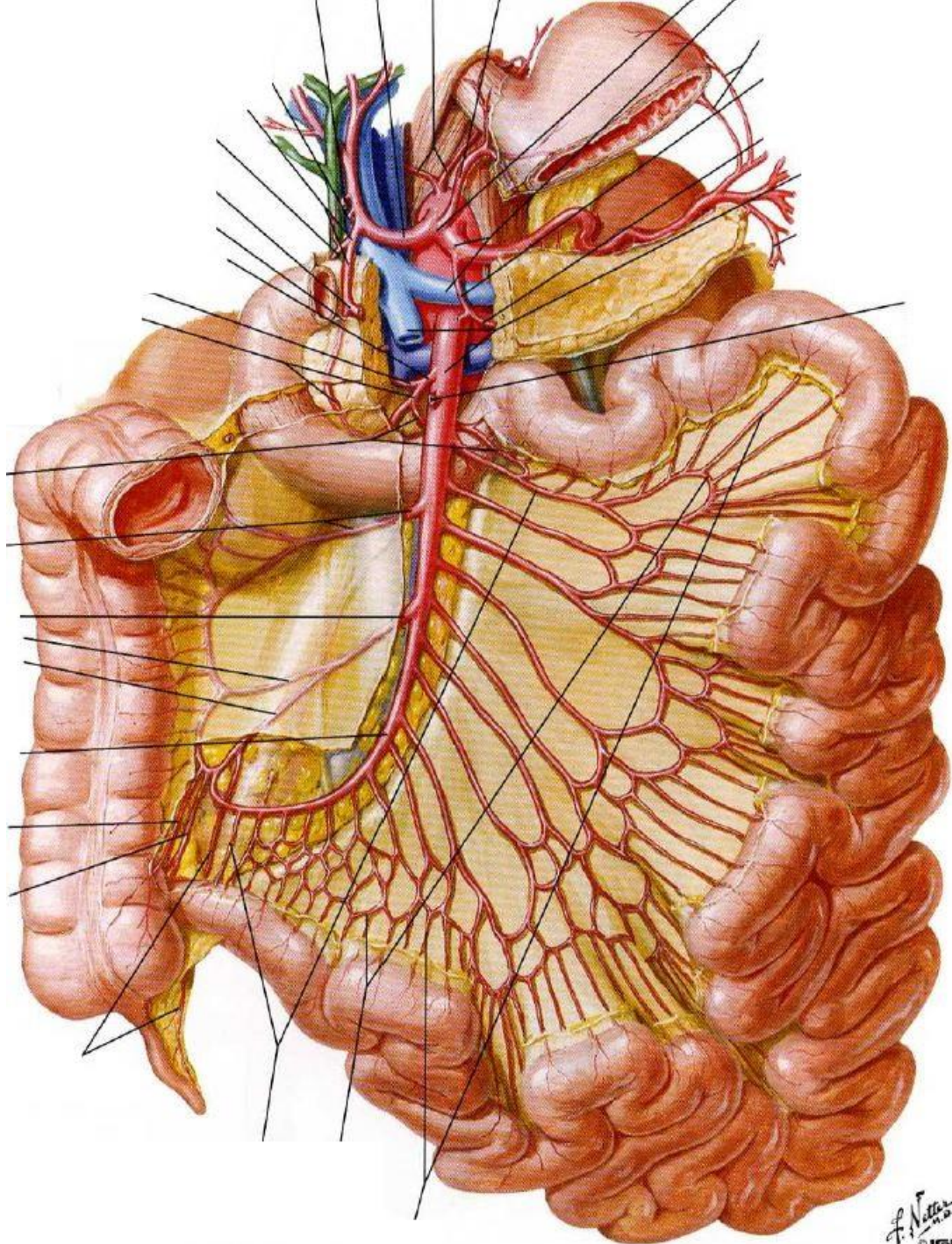


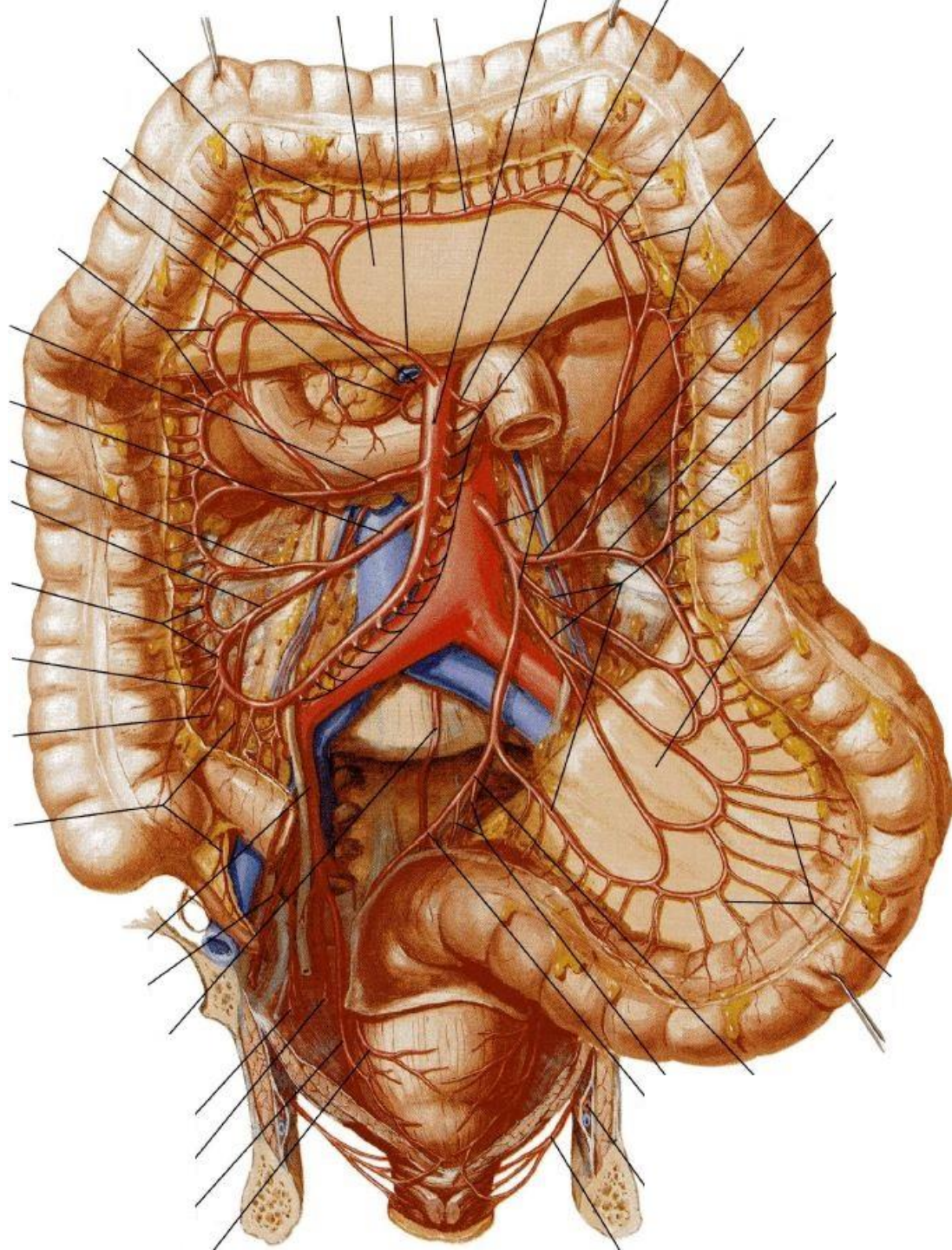




F. Netter
M.D.
© IGV
1998







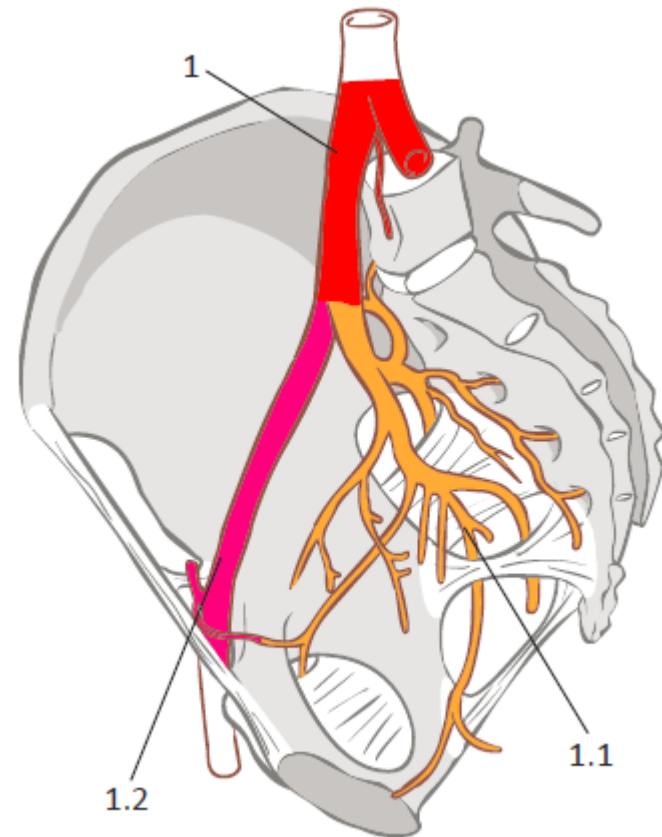
1.2 Přehled tepen hrudníku, břicha a pánve

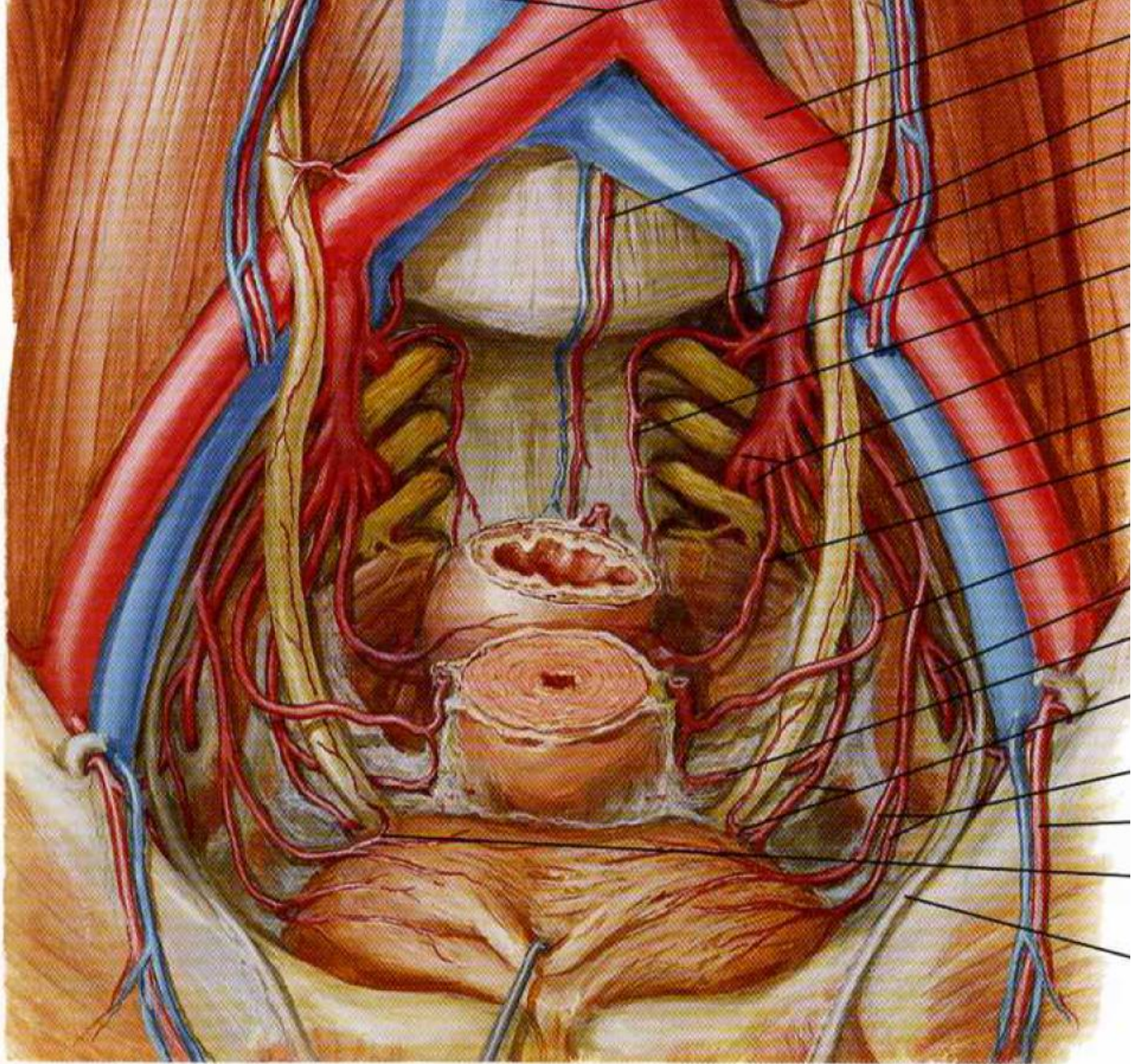
Tepny pánve

1 **Arteria iliaca communis** dextra et sinistra

1.1 **Arteria iliaca interna**

1.2 **Arteria iliaca externa**





1.2 Přehled tepen hrudníku, břicha a pánve

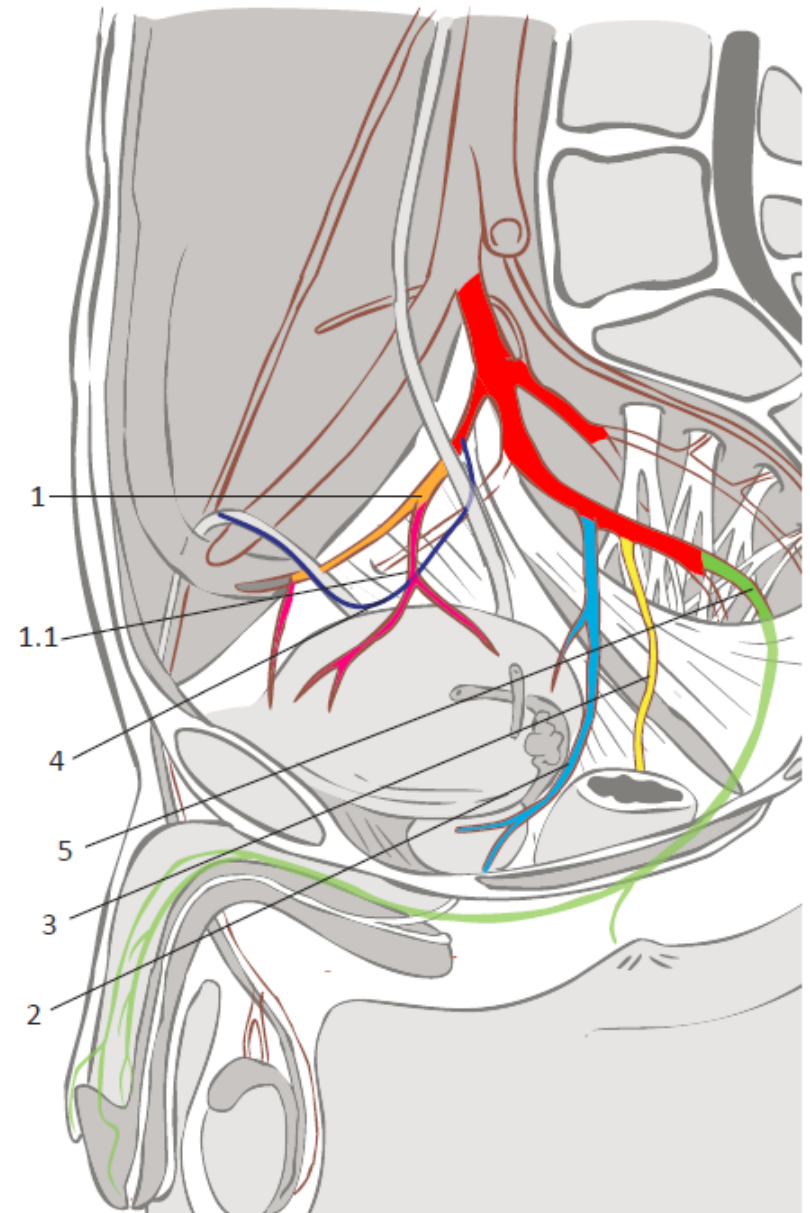
Tepny pánve (Větve arteria iliaca interna)

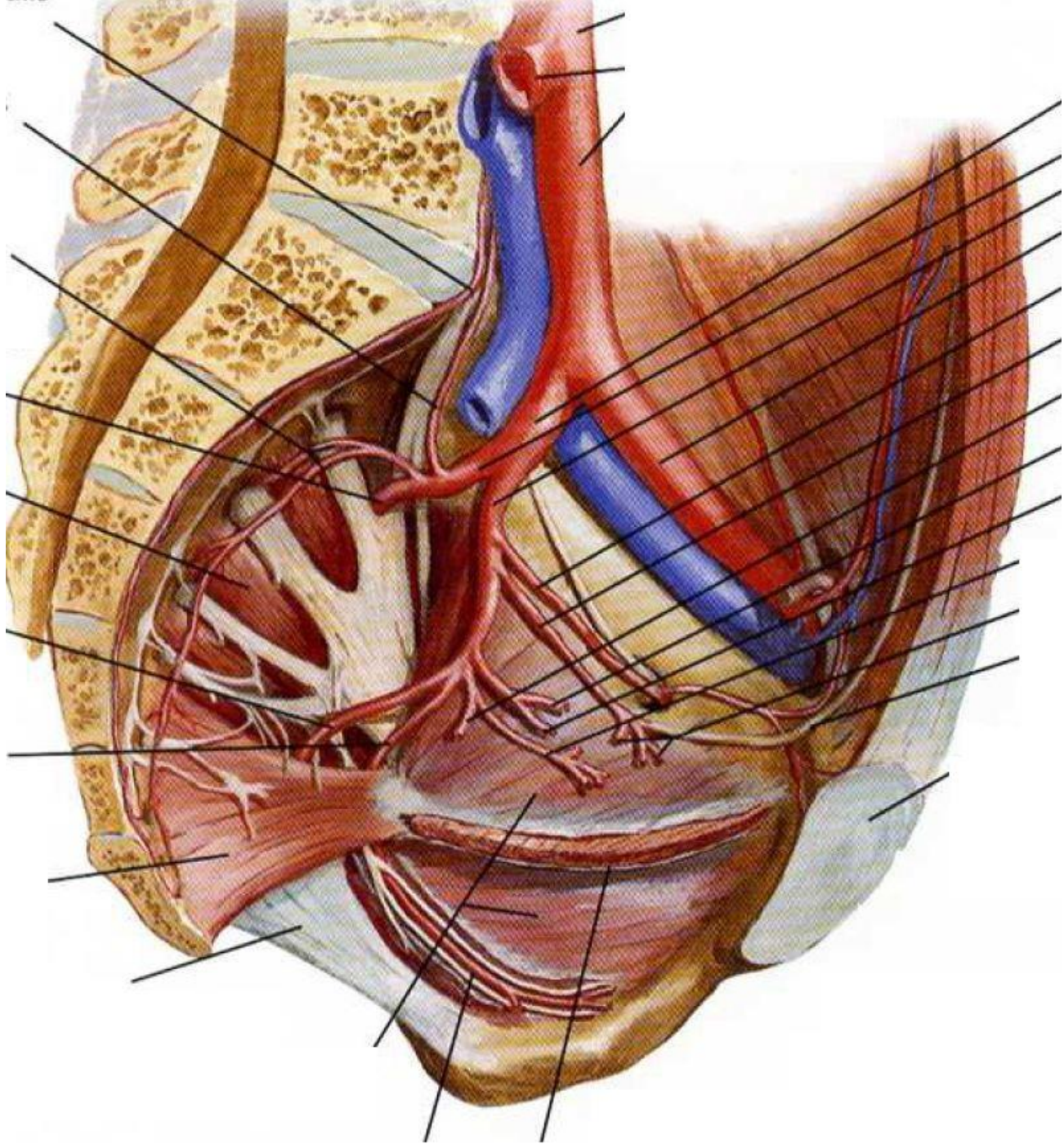
Parietální větve:

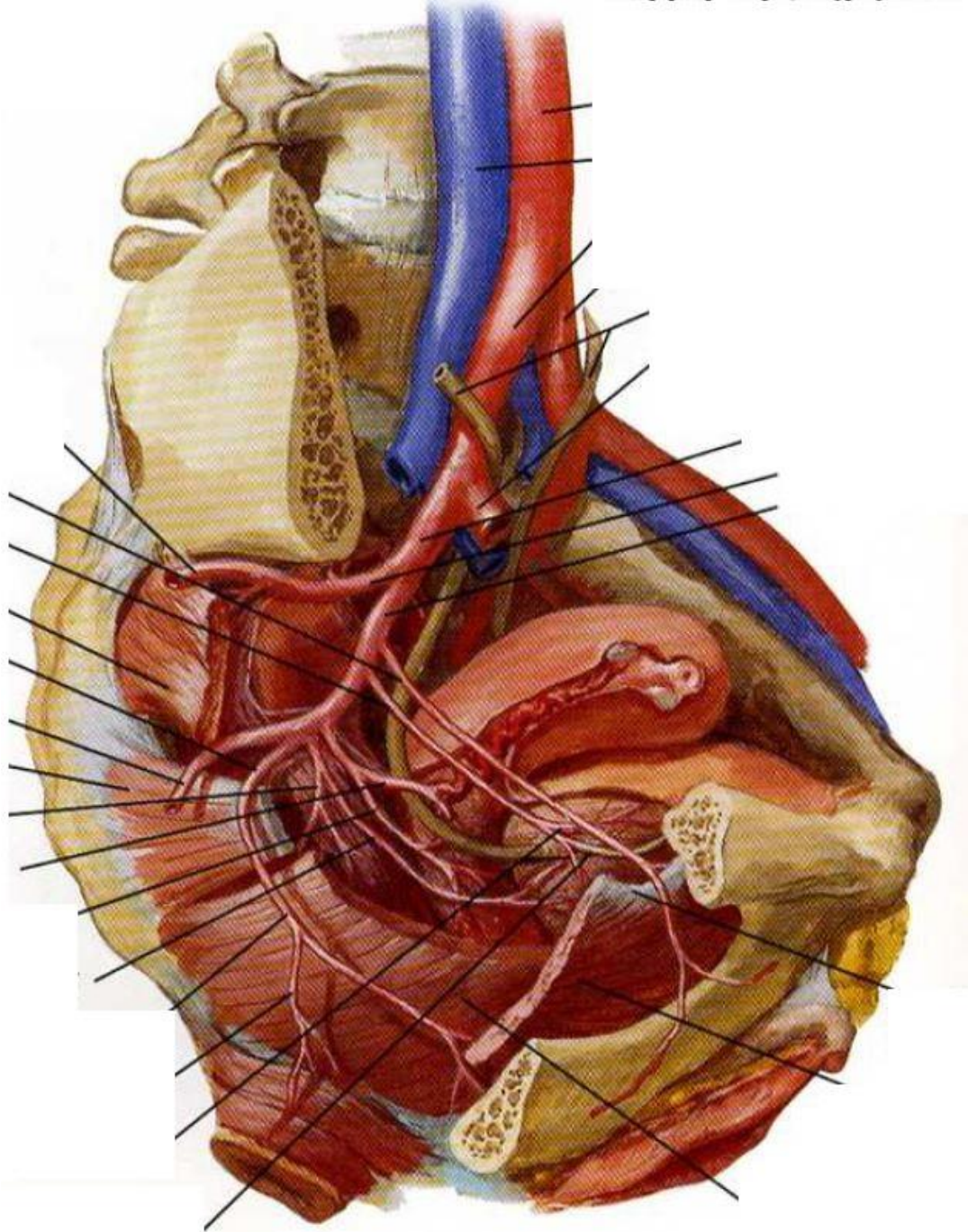
- 1 Arteria iliolumbalis
- 2 Arteriae sacrales
- 3 Arteria obturatoria
- 4 Arteria glutea superior
- 5 Arteria glutea inferior

Viscerální větve:

- 1 Arteria umbilicalis
- 2 **Arteria vesicalis inferior**
- 3 **Arteria rectalis media**
- 4 **Arteria ductus deferentis** (u muže)
Arteria uterina (u ženy)
- 5 **Arteria pudenda interna**

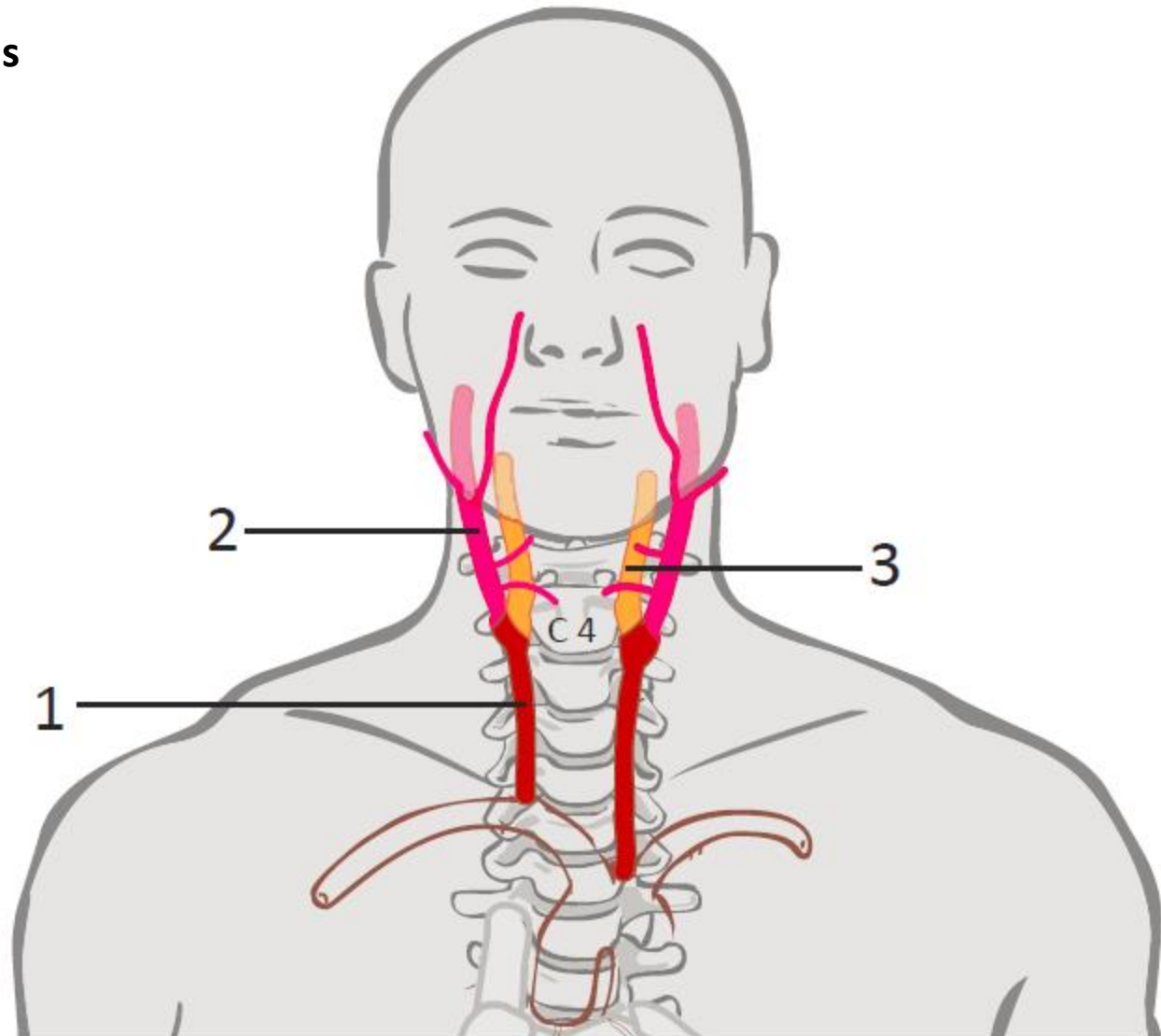


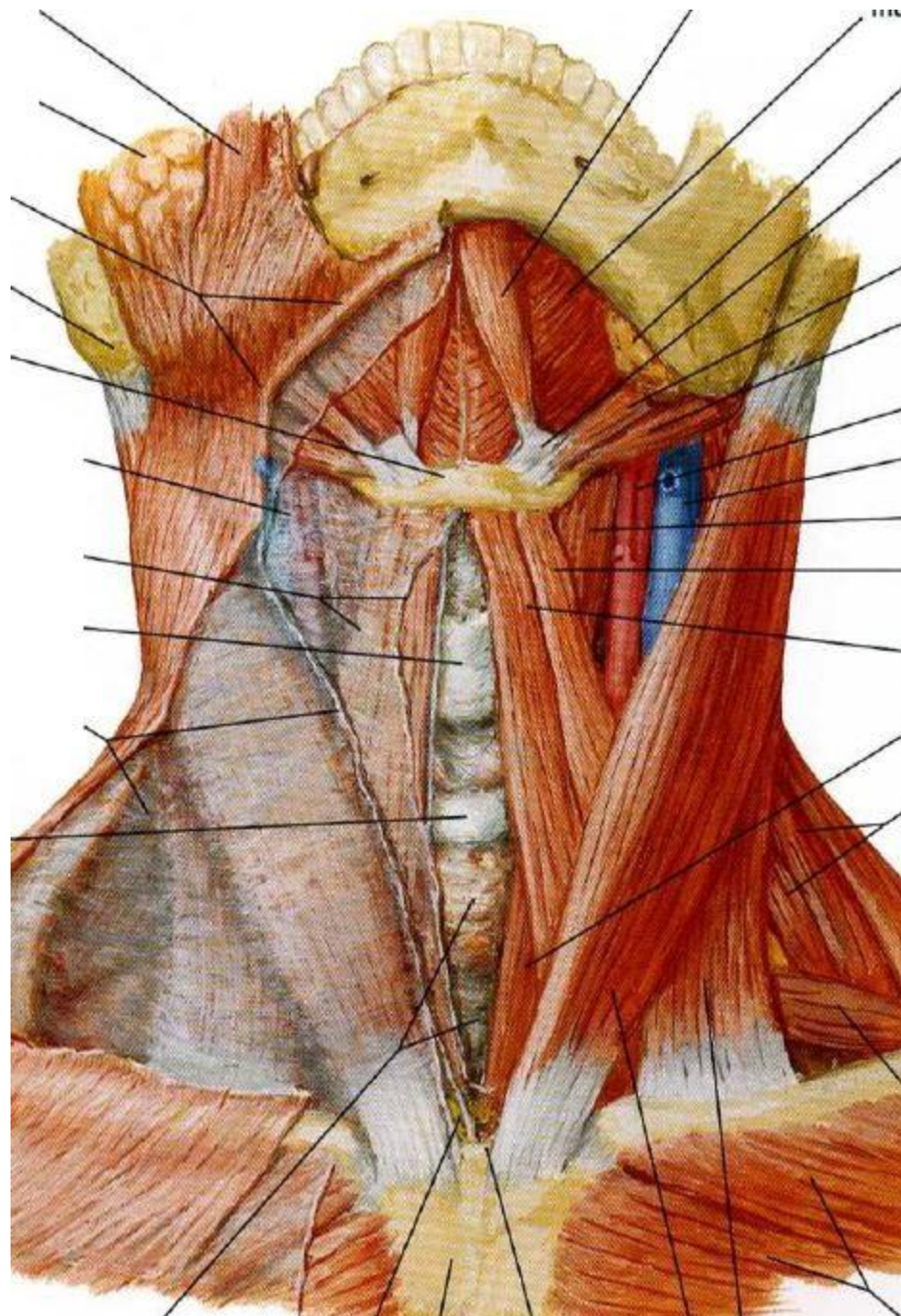




1.3 Přehled tepen hlavy a krku

- 1 Arteria carotis communis
- 2 Arteria carotis externa
- 3 Arteria carotis interna

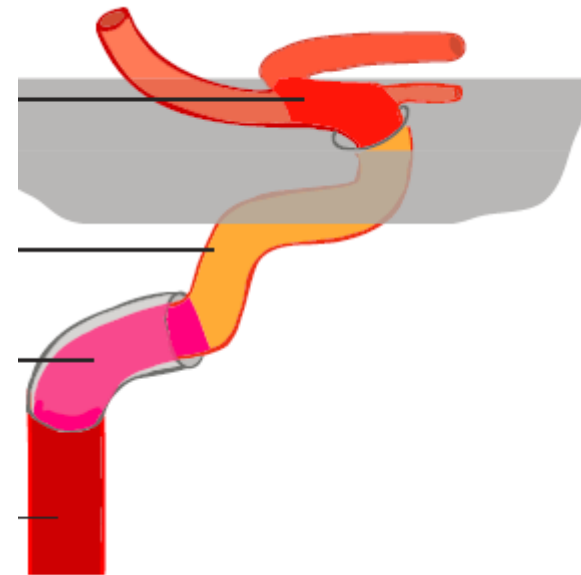




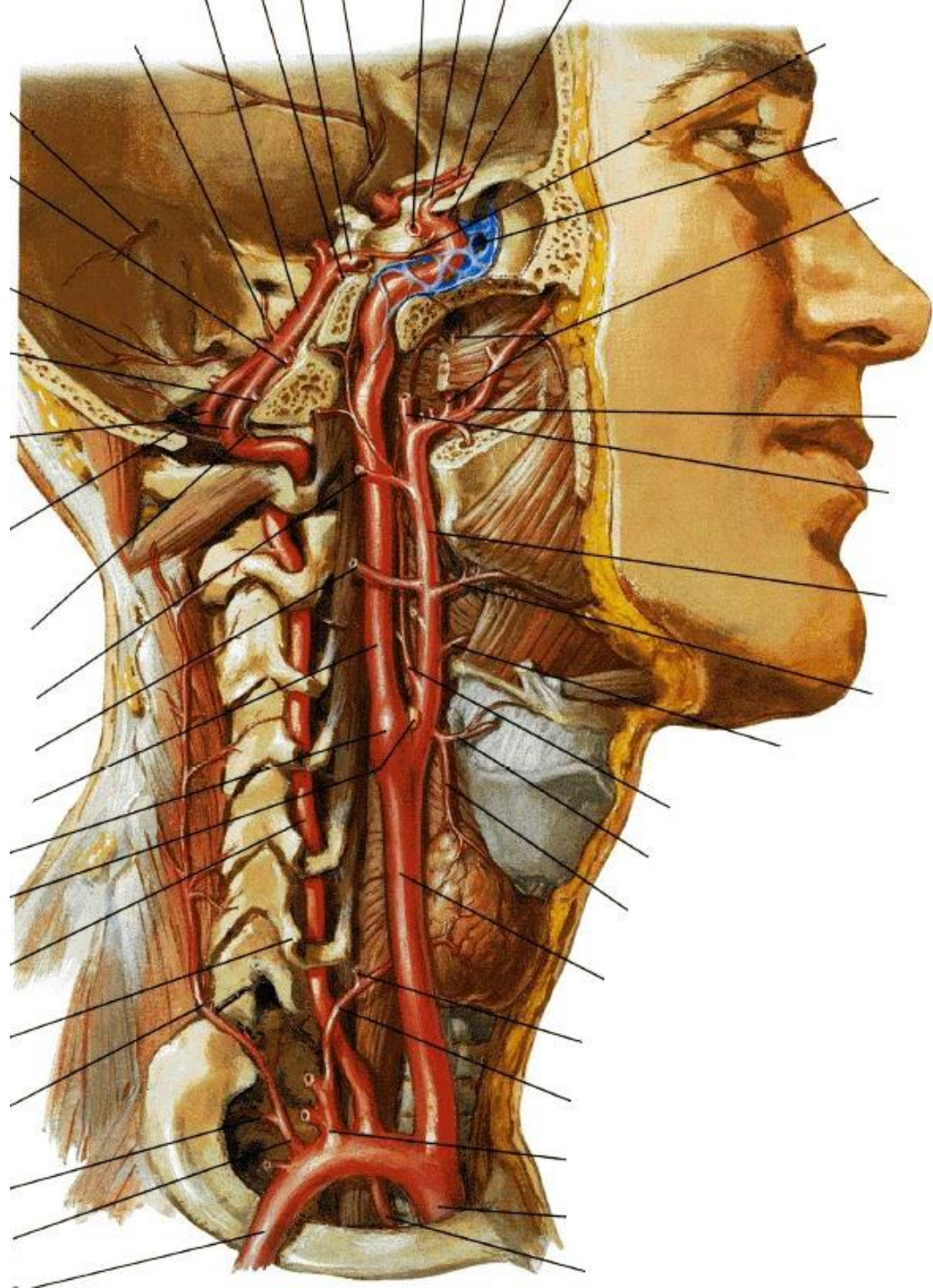
1.3 Přehled tepen hlavy a krku

Arteria carotis interna

- 1 Arteria ophthalmica
- 2 Arteria cerebri media
- 3 Arteria cerebri anterior



Karotický sífón



1.3 Přehled tepen hlavy a krku

Arteria carotis externa

1 Arteria thyroidea superior

2 **Arteria lingualis**

3 **Arteria facialis**

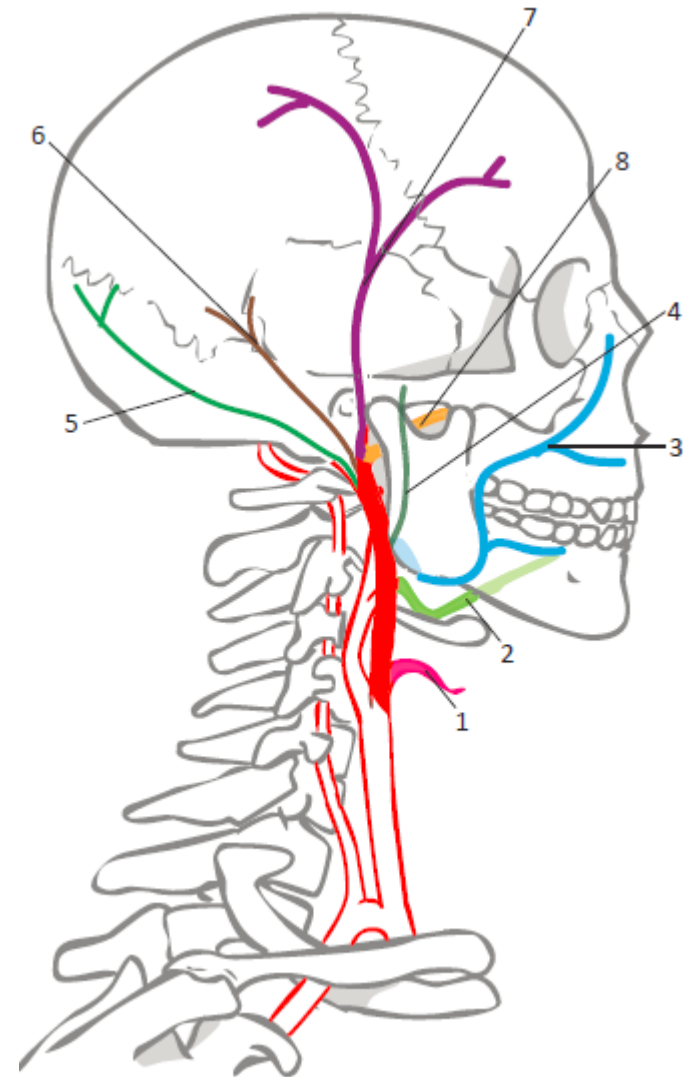
4 Arteria pharyngea ascendens

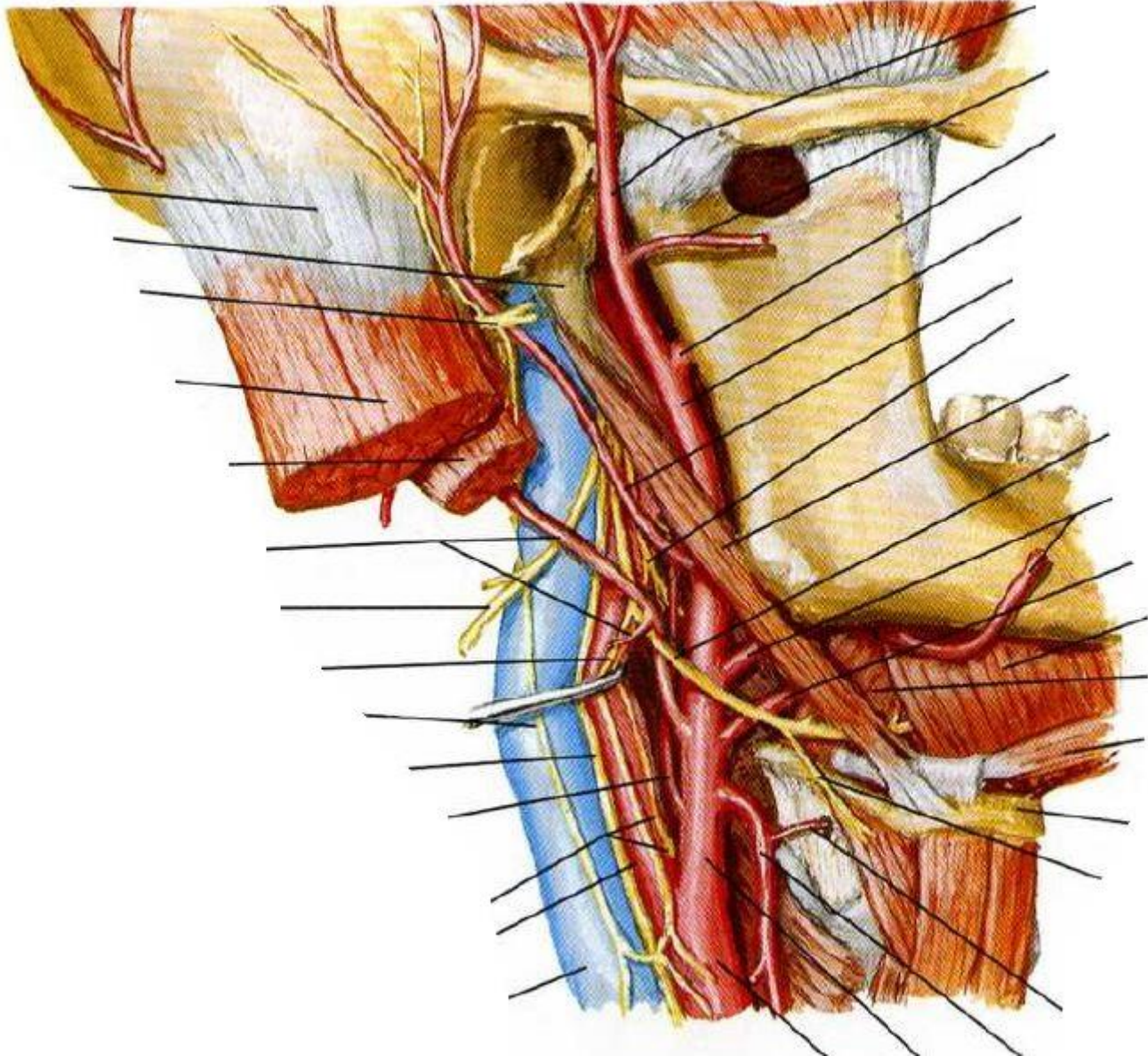
5 Arteria occipitalis

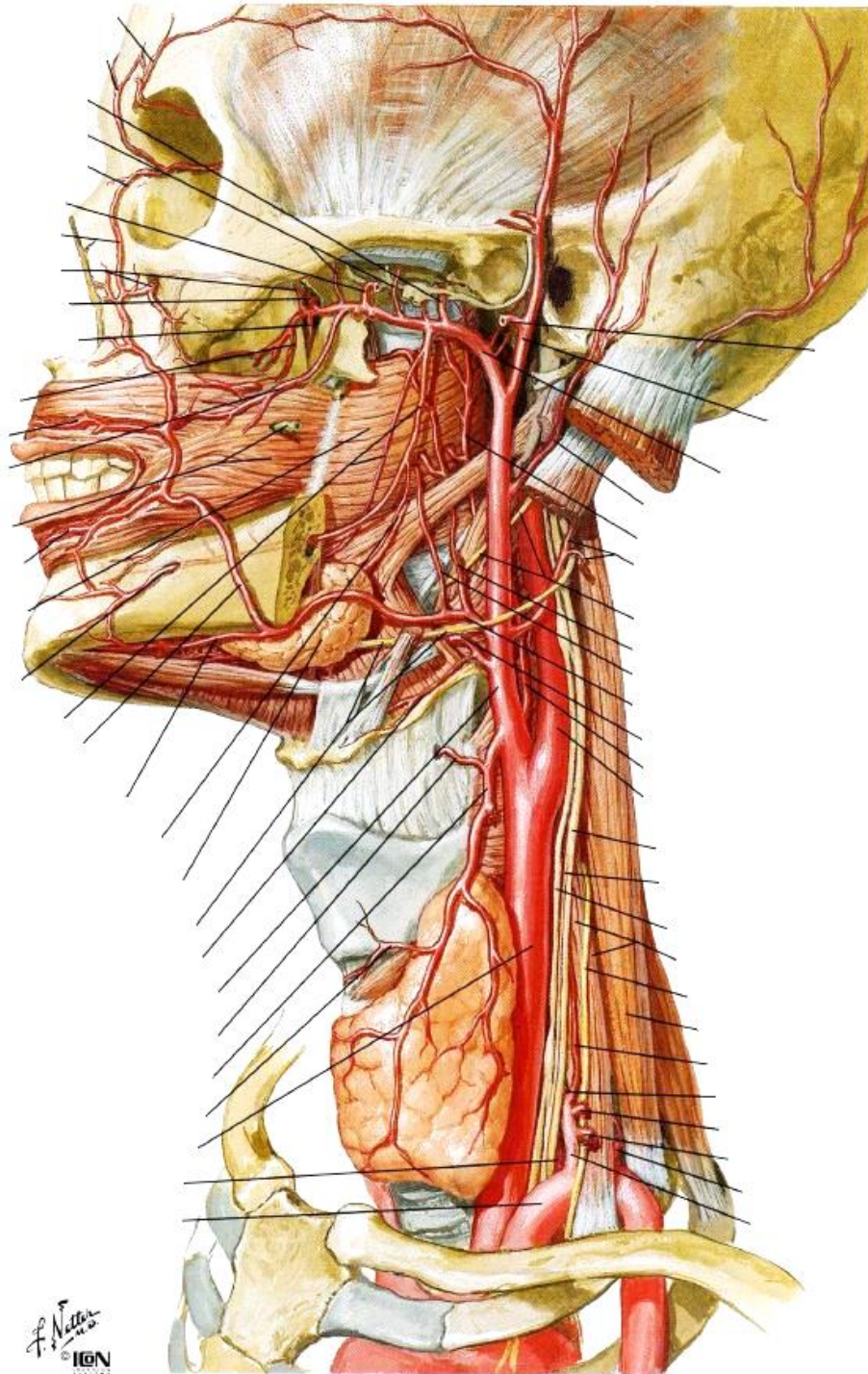
6 Arteria auricularis posterior

7 **Arteria temporalis superficialis**

8 **Arteria maxillaris**

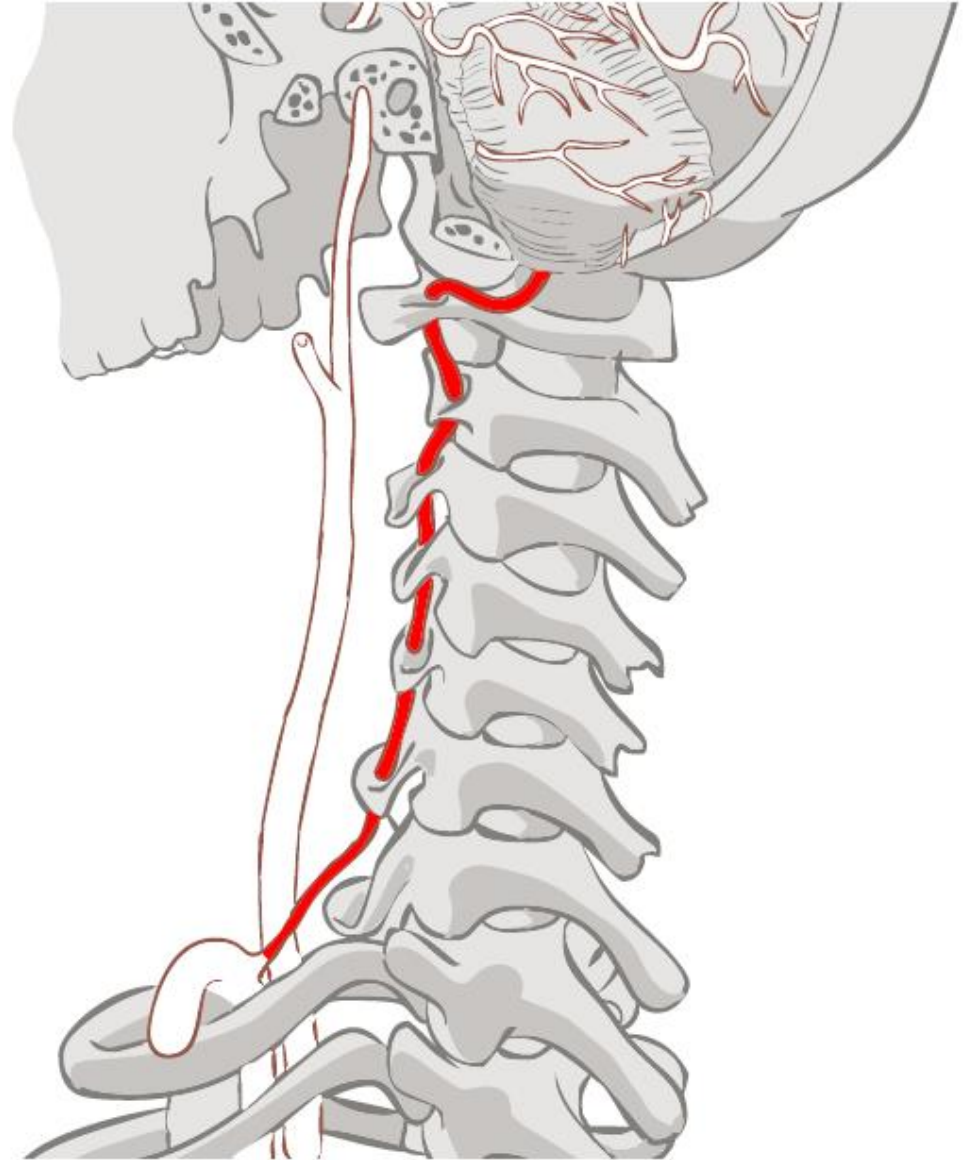






1.3 Přehled tepen hlavy a krku

Z arteria subclavia
Arteria vertebralis



1.3 Přehled tepen hlavy a krku

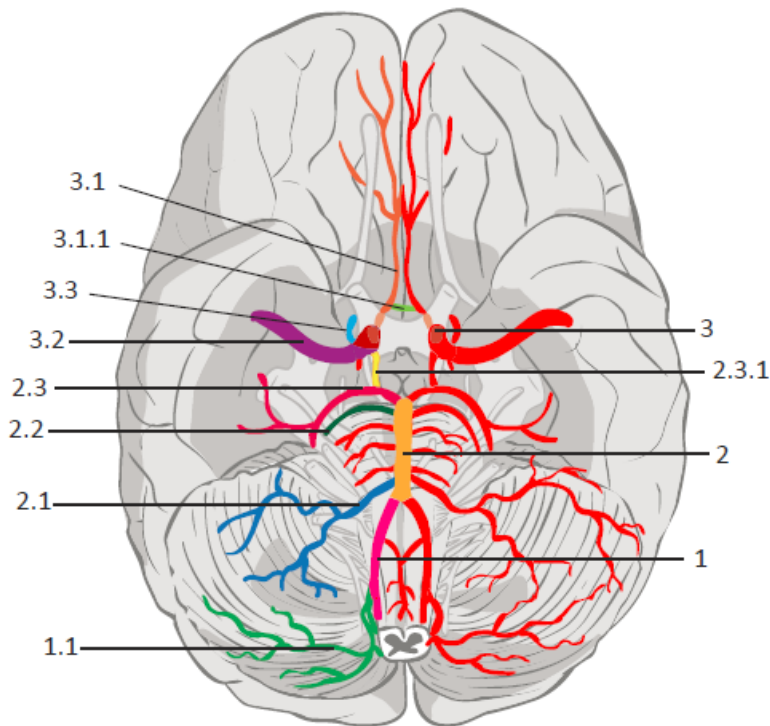
1 Arteria carotis interna

1.1 Arteria cerebri anterior

1.2 Arteria cerebri media

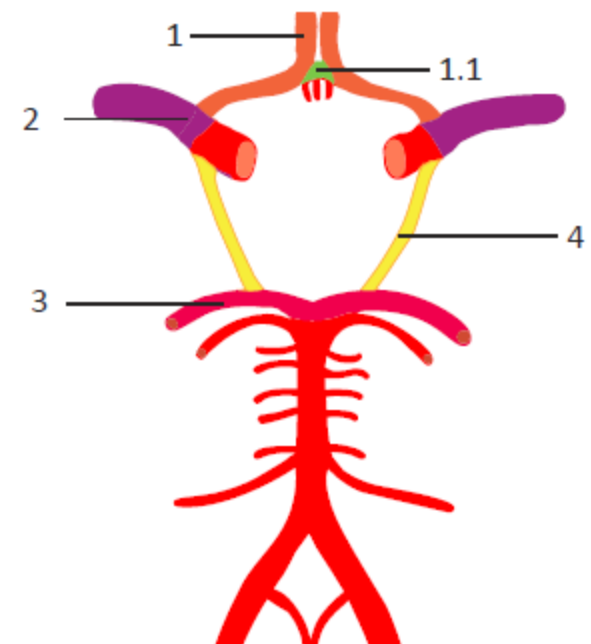
2 Arteria basilaris (z arteria vertebralis dextra et sinistra)

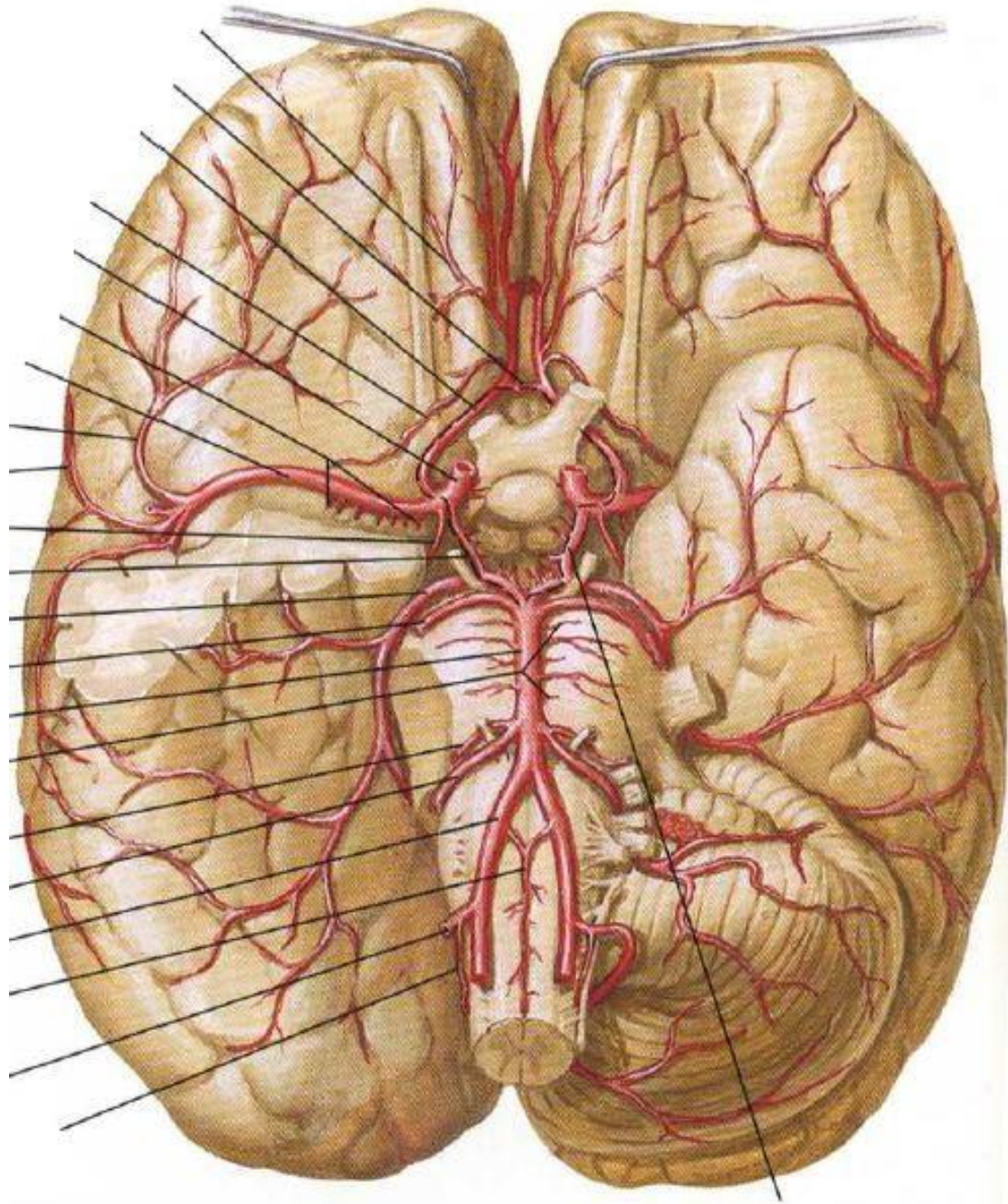
2.1 Arteria cerebri posterior



Willisův tepenný okruh

Spojení mozkových tepen





1.4 Tepny horní končetiny

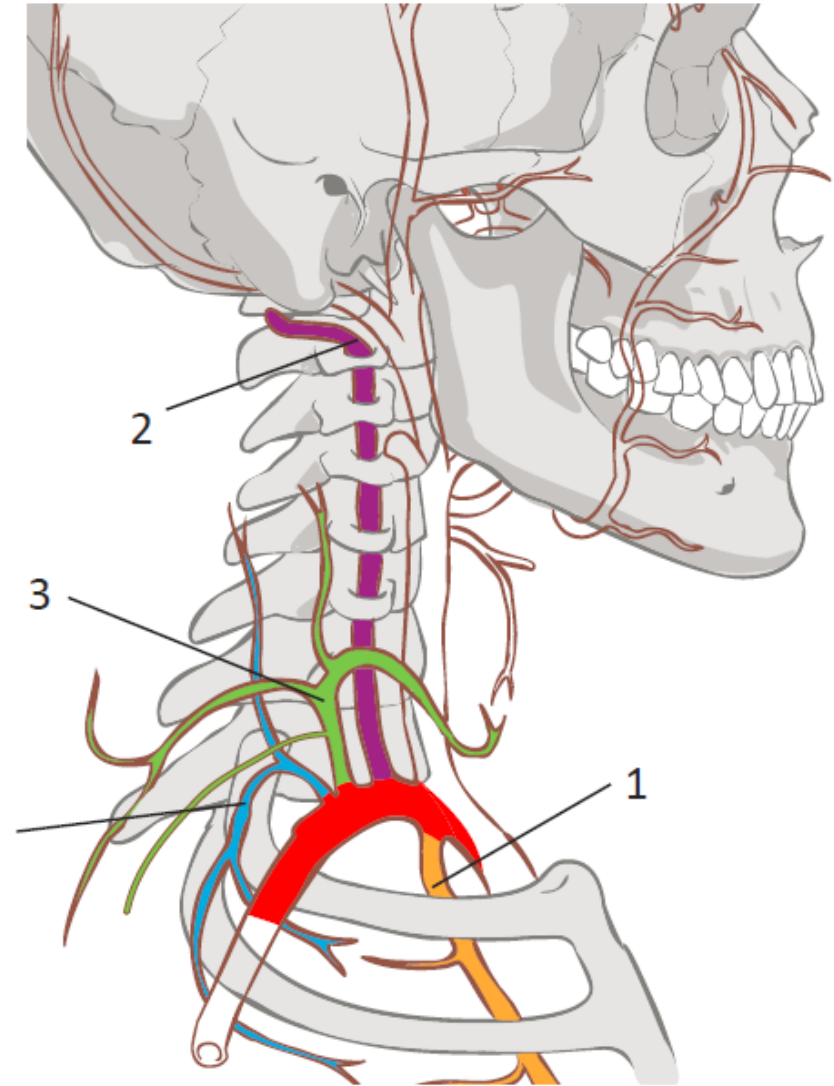
Arteria subclavia

Arteria axillaris

Arteria brachialis

Arteria radialis et ulnaris

Arcus palmaris superficialis et profundus

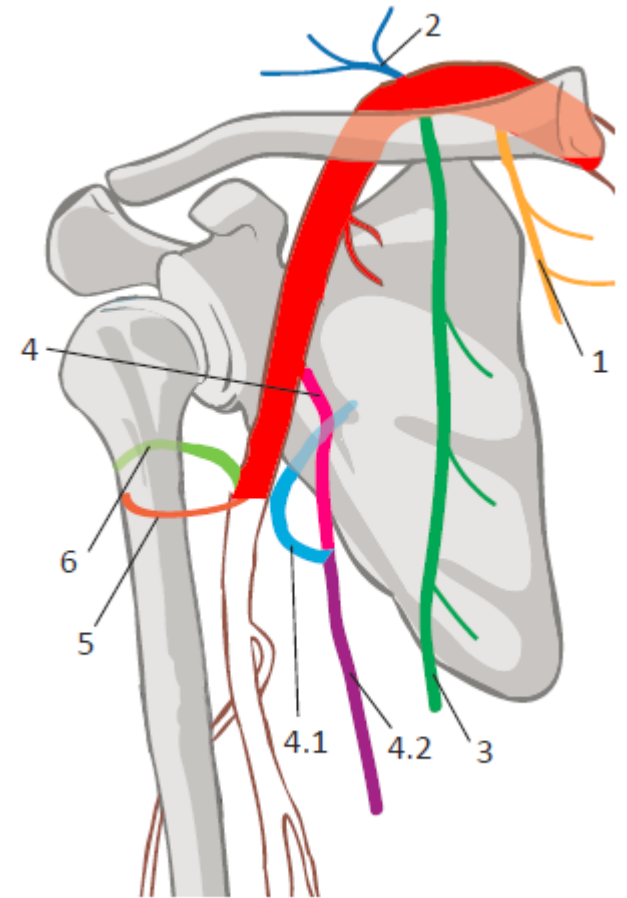


1.4 Tepny horní končetiny

Arteria axillaris

4 Subscapularis

6 Arteria circumflexa humeri posterior

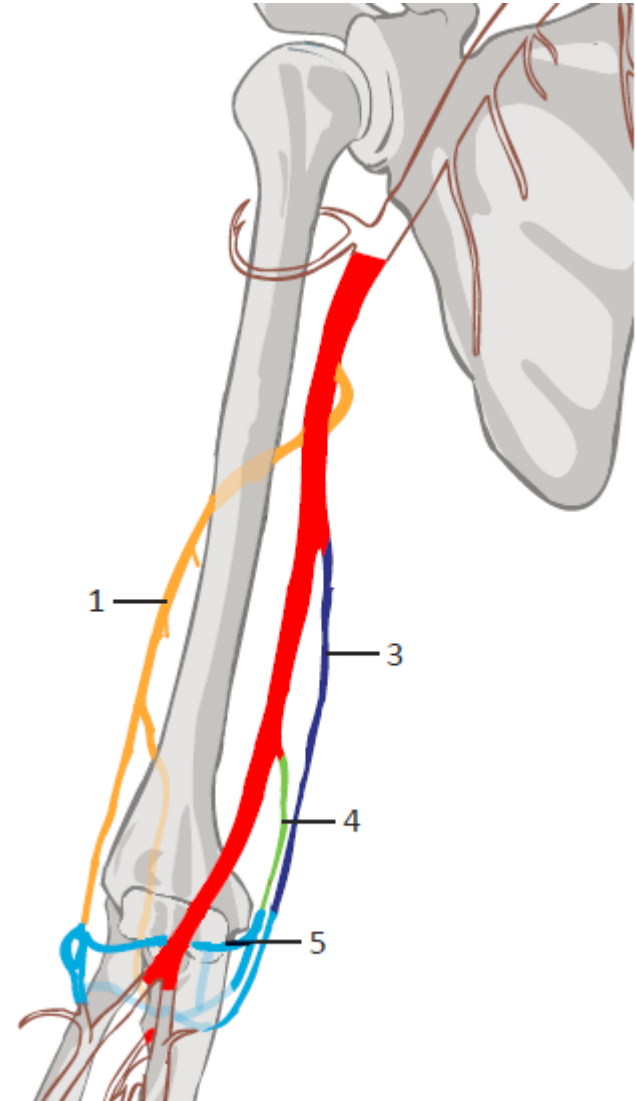


1.4 Tepny horní končetiny

Arteria brachialis

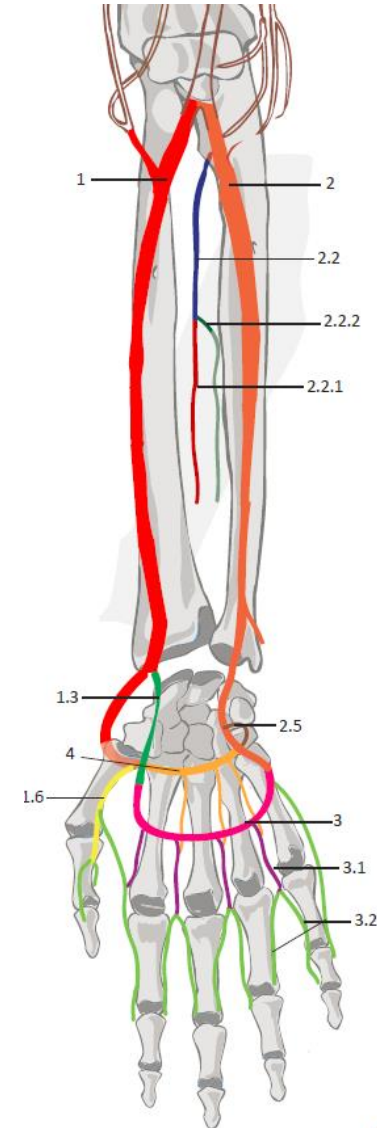
1 Arteria profunda brachii

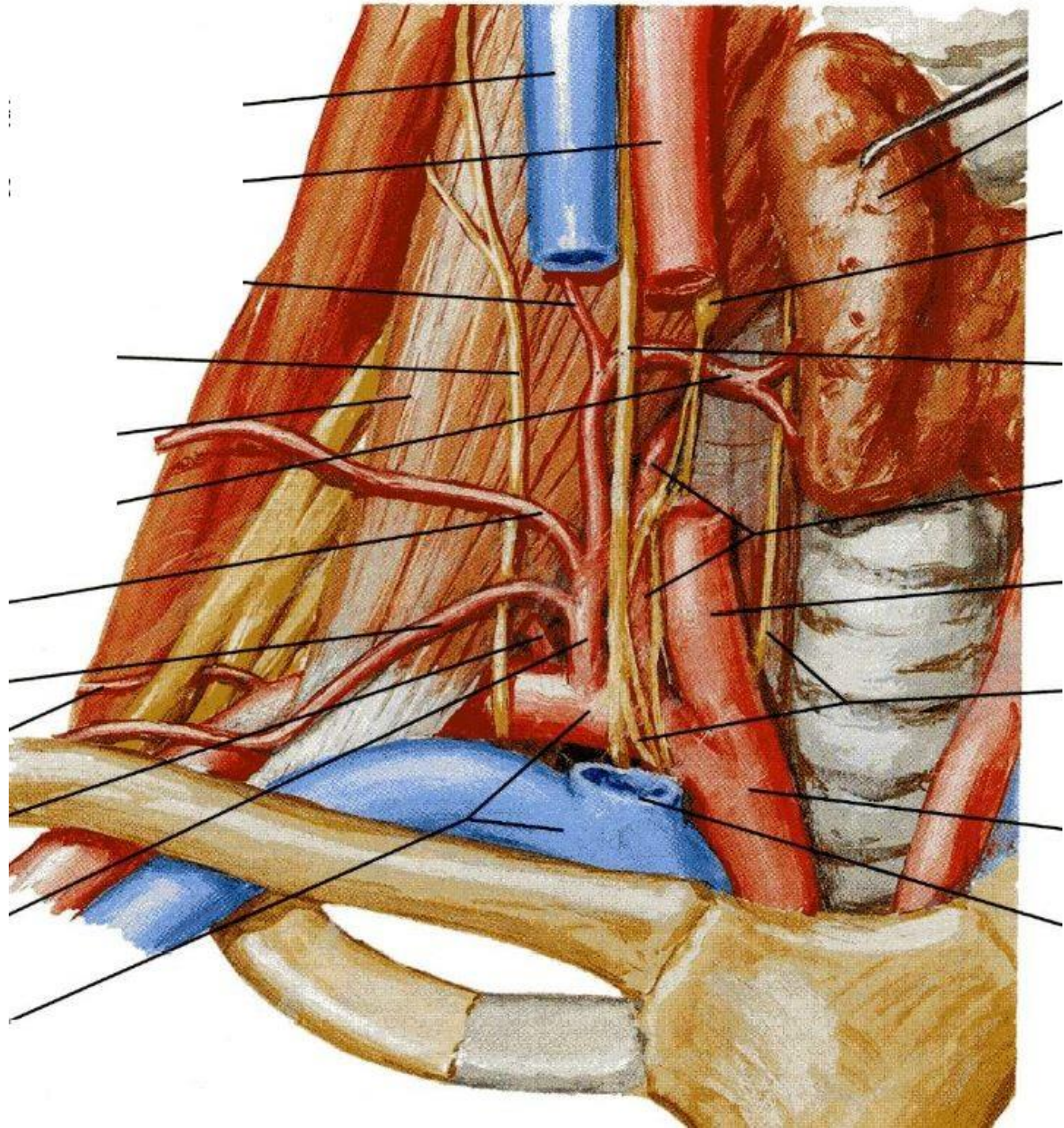
5 Rete articulare cubiti

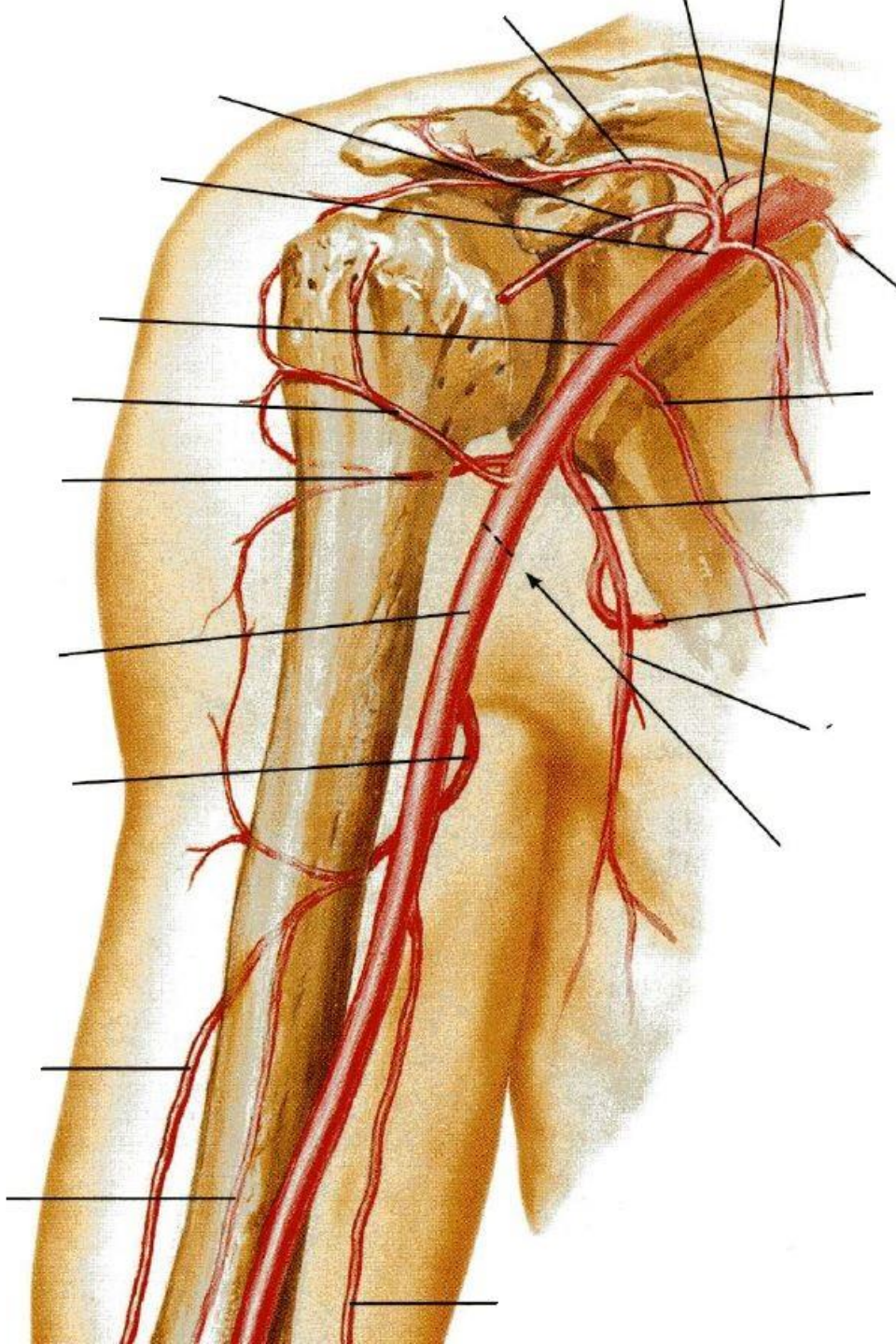


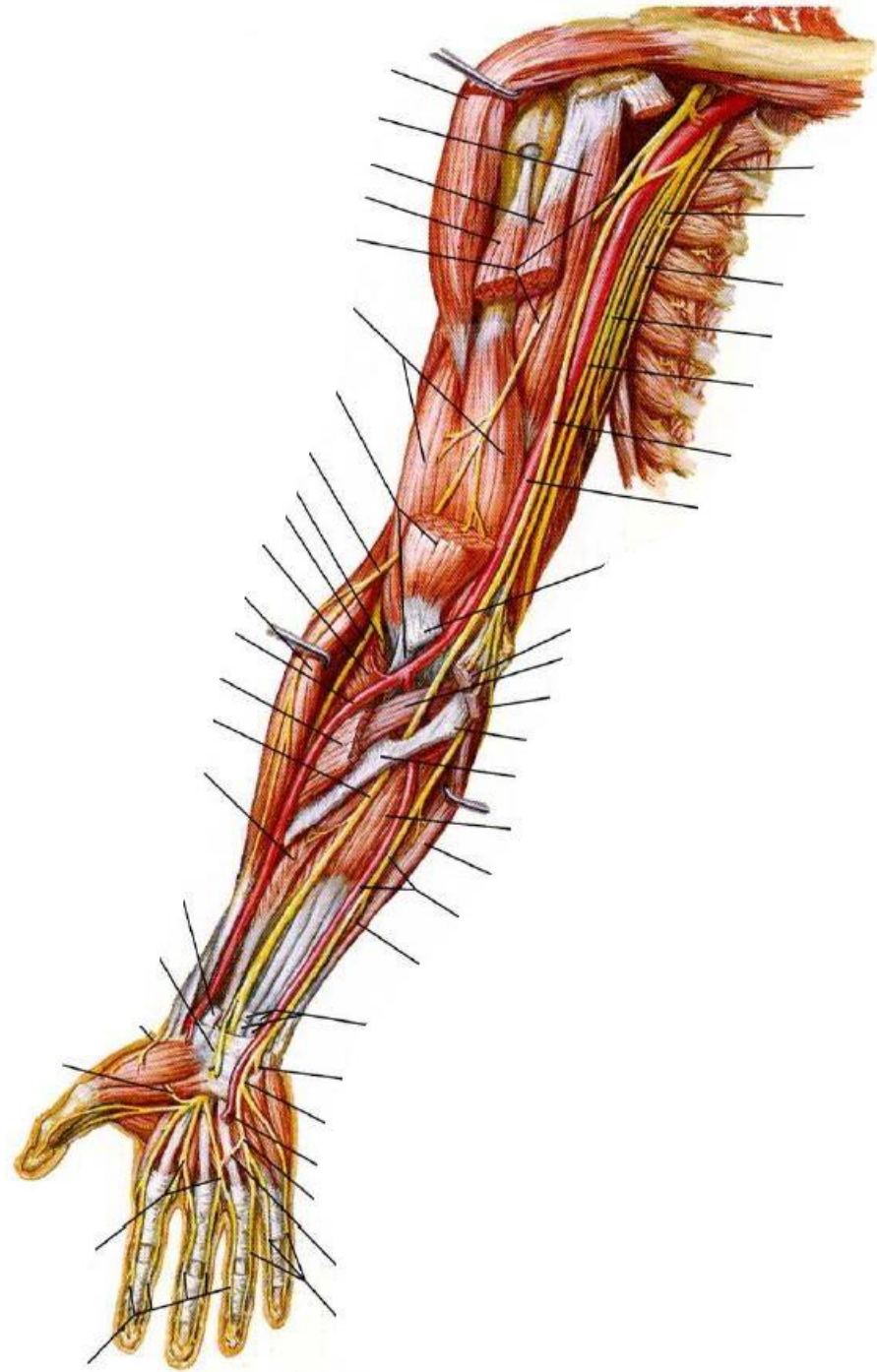
1.4 Tepny horní končetiny

- 1 Arteria radialis
- 2 Arteria ulnaris
- 3 Arcus palmaris superficialis
- 4 Arcus palmaris profundus









1.5 Tepny dolní končetiny

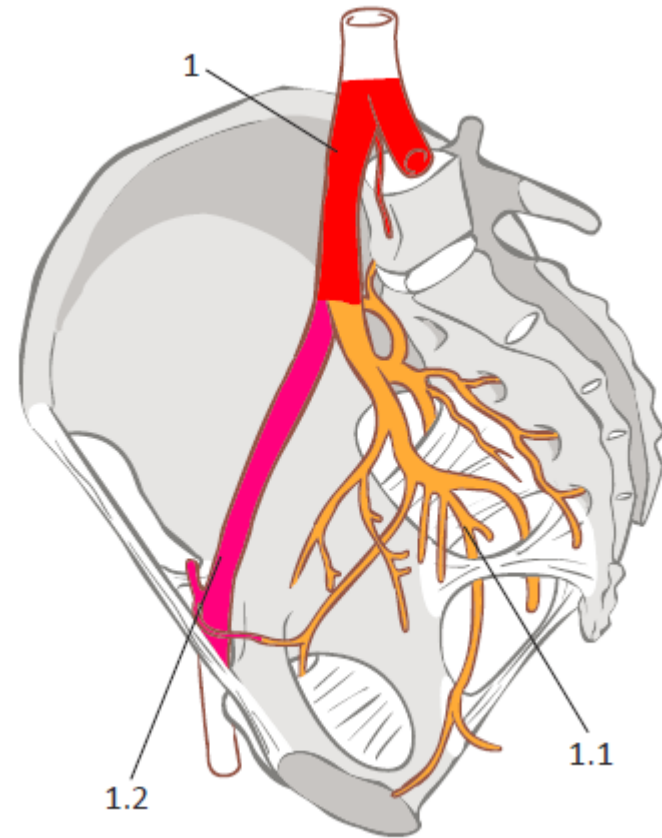
Arteria iliaca externa

Arteria femoralis

Arteria poplitea

Arteria tibialis anterior et posterior

Arcus plantaris



1.5 Tepny dolní končetiny

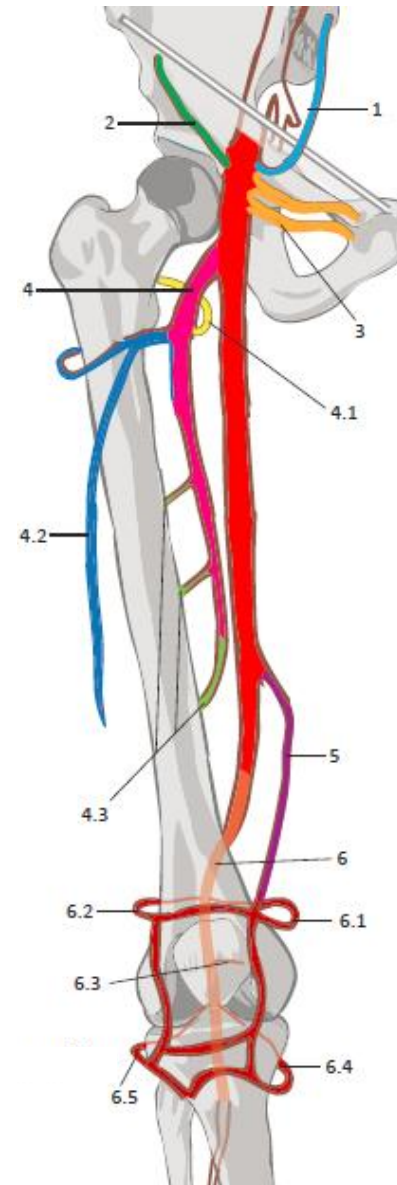
Arteria femoralis

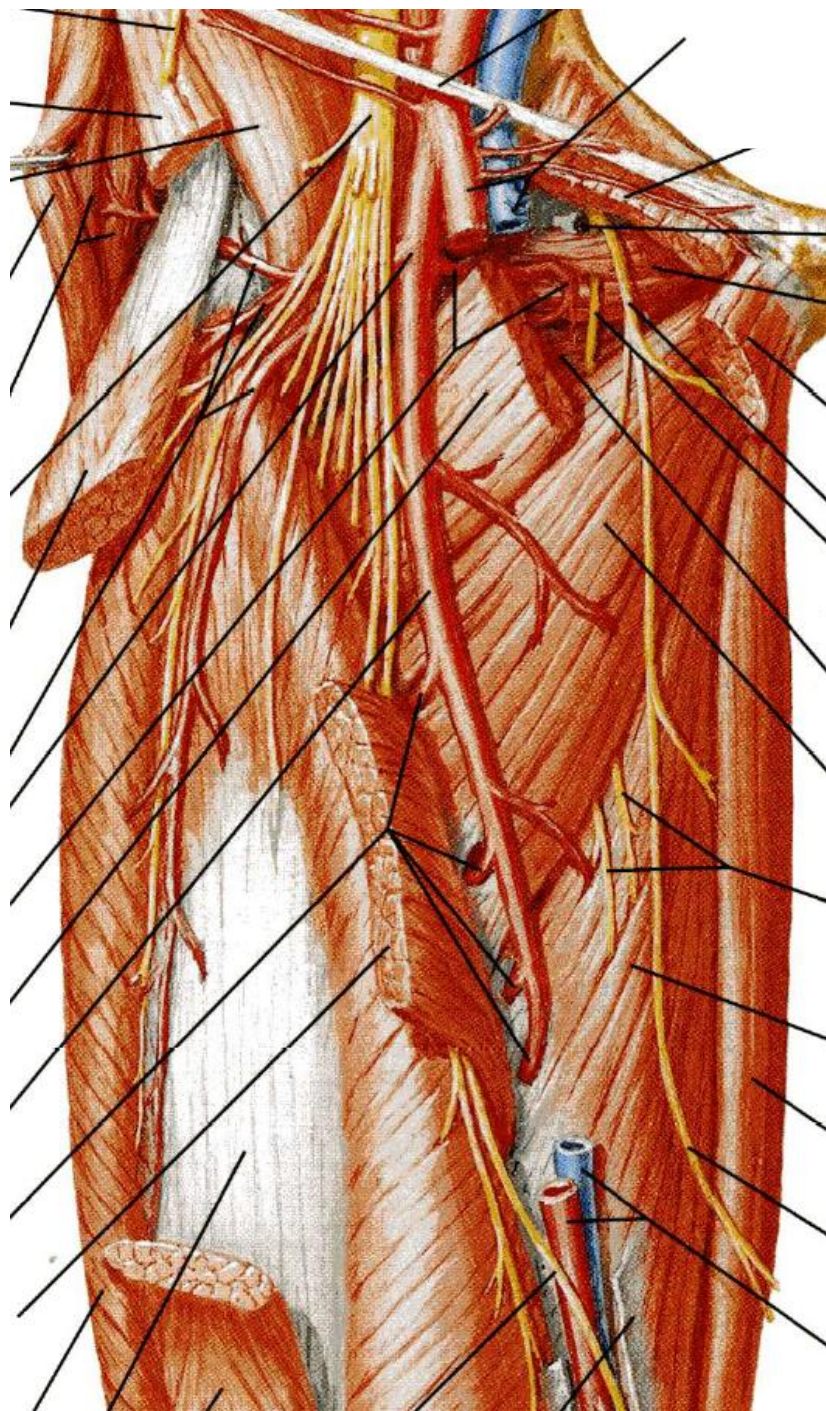
4 Arteria profunda femoris

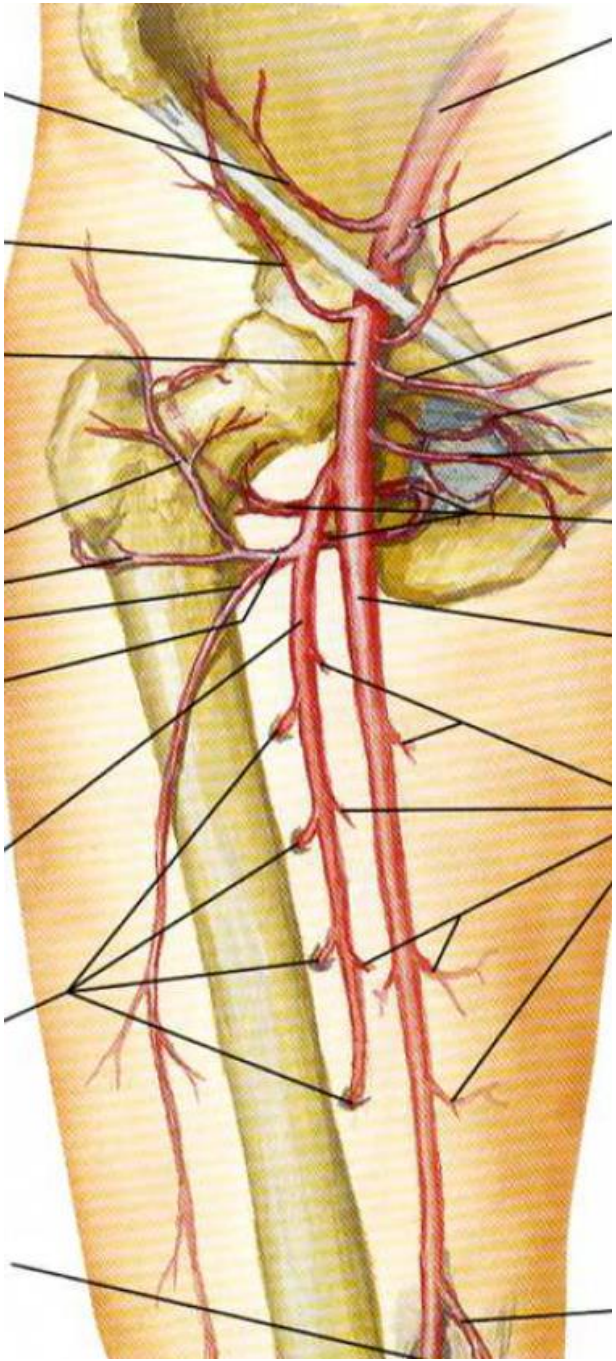
4.1 Arteria circumflexa femoris medialis

4.3 Arteriae perforantes

Arteria poplitea







1.5 Tepny dolní končetiny

Arteria tibialis anterior

Arteria dorsalis pedis

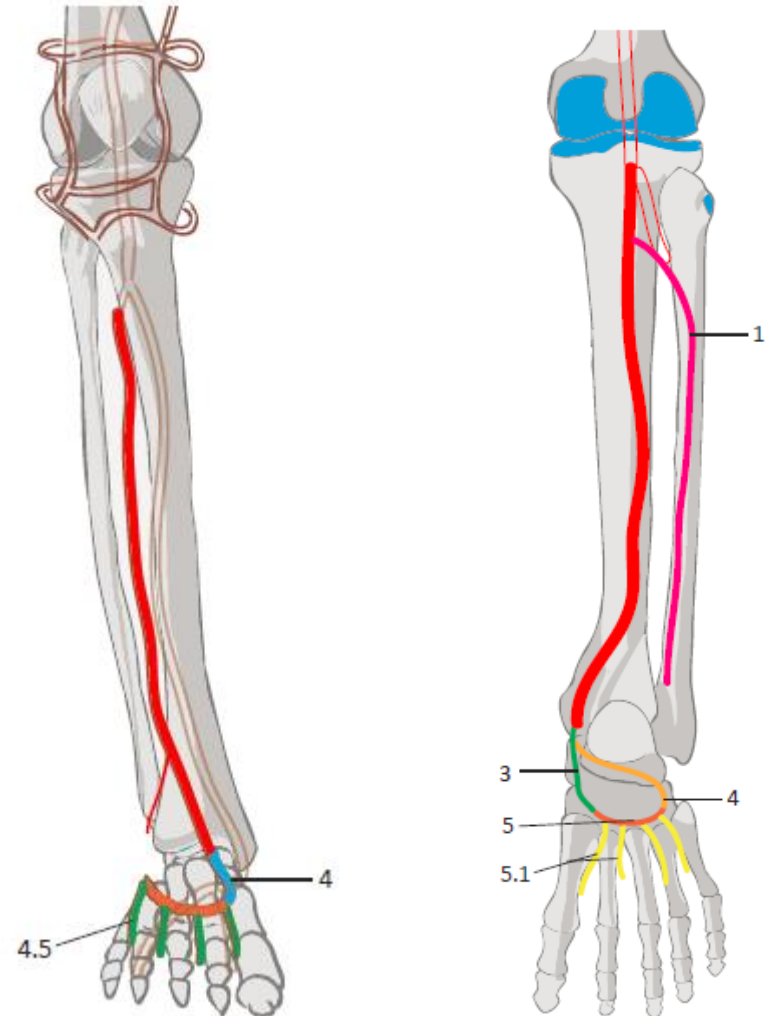
Arteria tibialis posterior

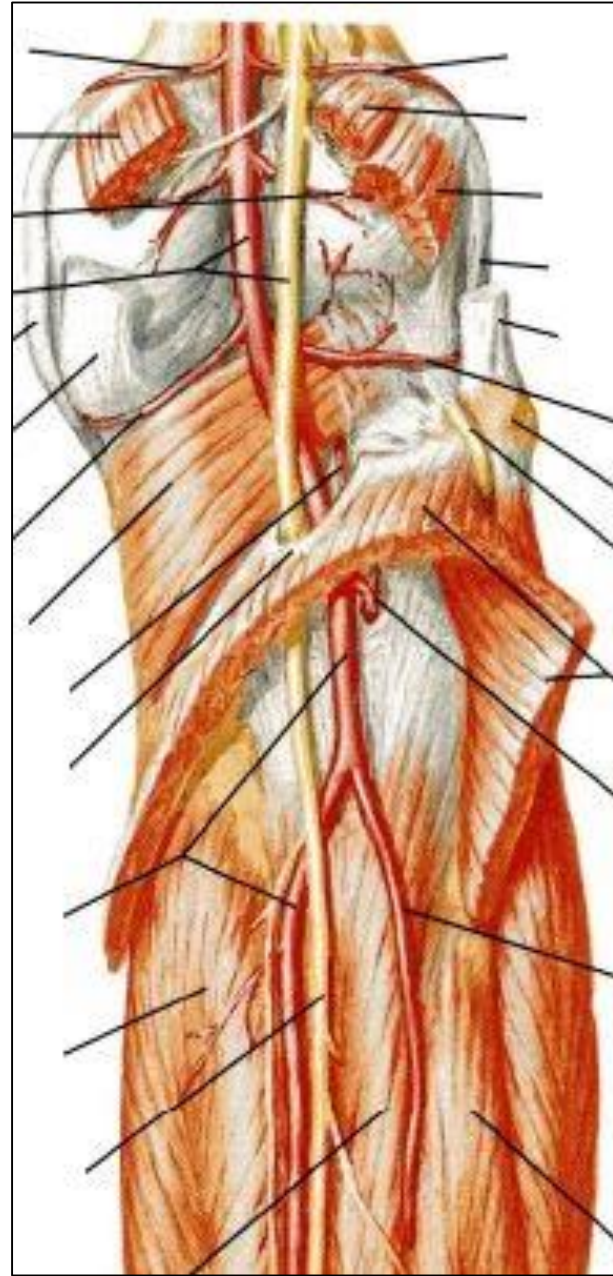
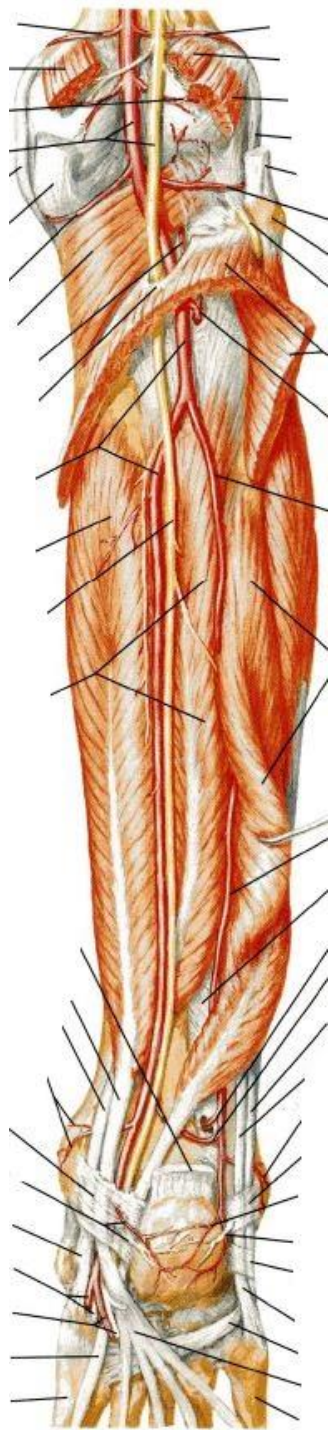
Arteria fibularis

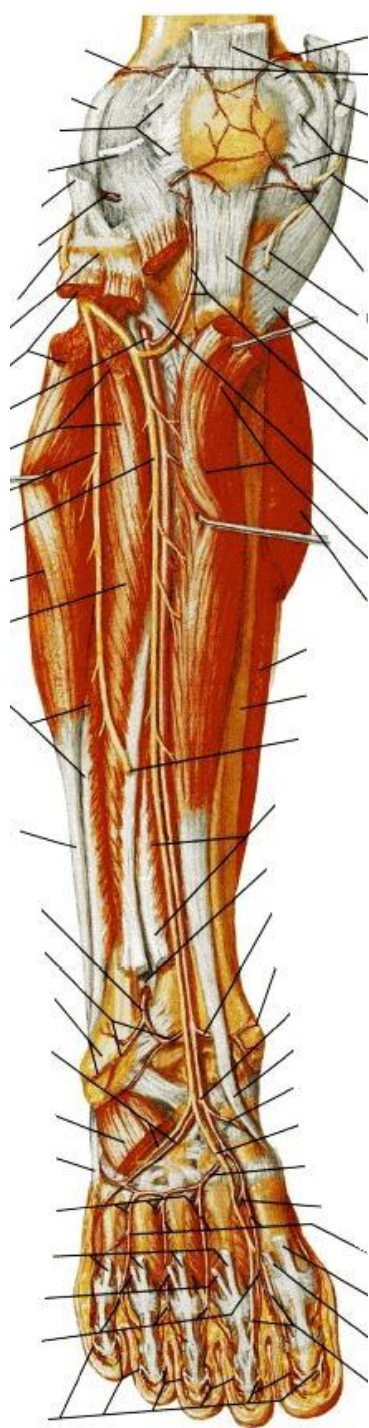
Arteria plantaris medialis

Arteria plantaris lateralis

Arcus plantaris







2.1 Žíly dolní končetiny

Hluboký systém:

Venae tibiales

Vena poplitea

Vena femoralis

Vena profunda femoris

Vena femoralis communis

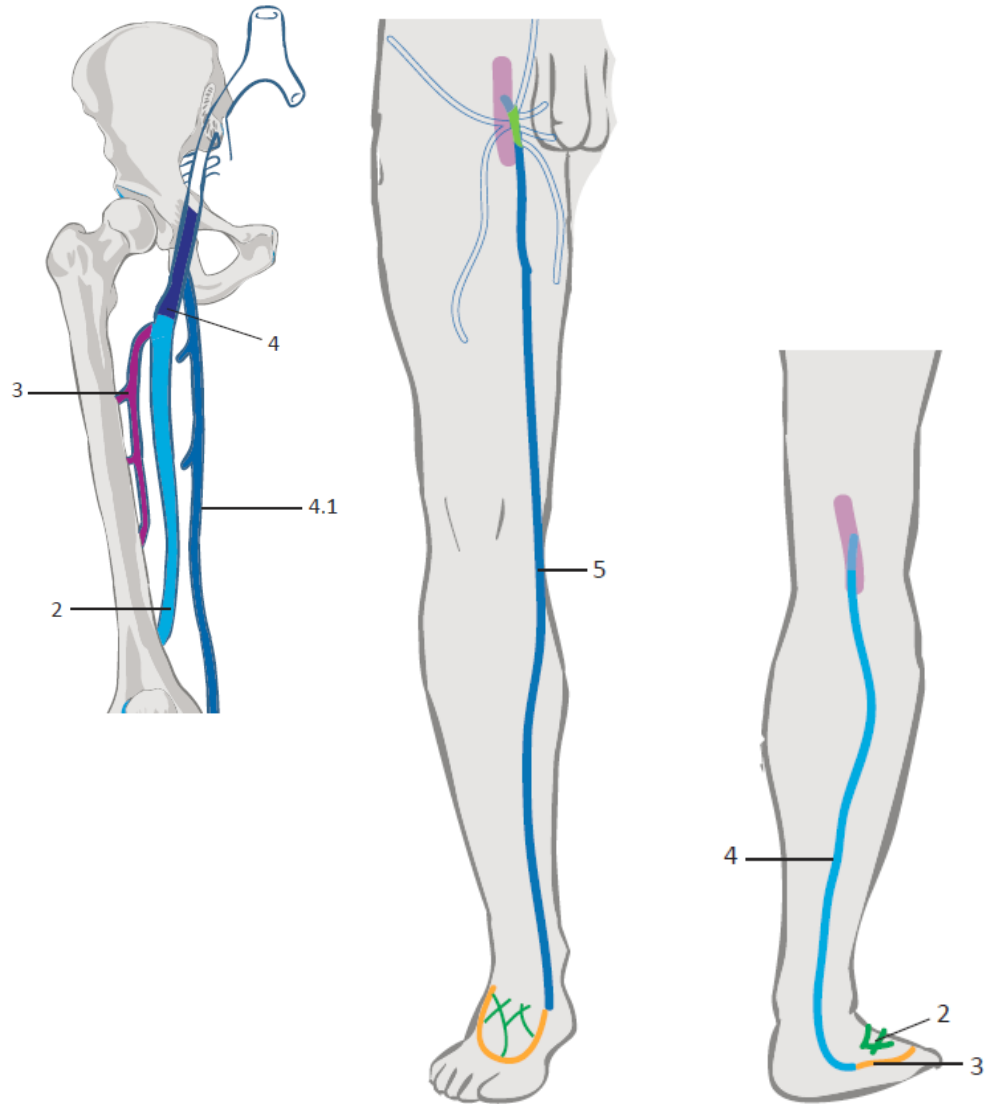
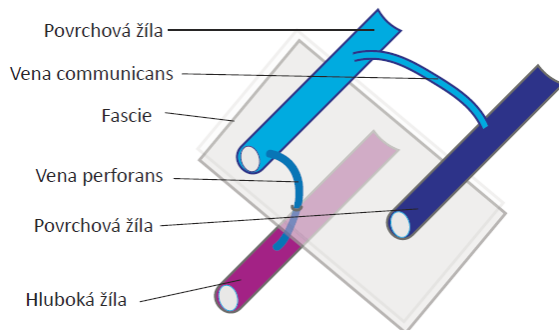
Povrchný systém:

Rete venosum dorsale pedis

Vena saphena parva

Vena saphena magna

Žilní perforátory



2.2 Žíly horní končetiny

Hluboký systém:

Arcus venosus palmaris profundus

Venae radiales

Venae ulnares

Venae brachiales

Vena axillaris

Vena subclavia

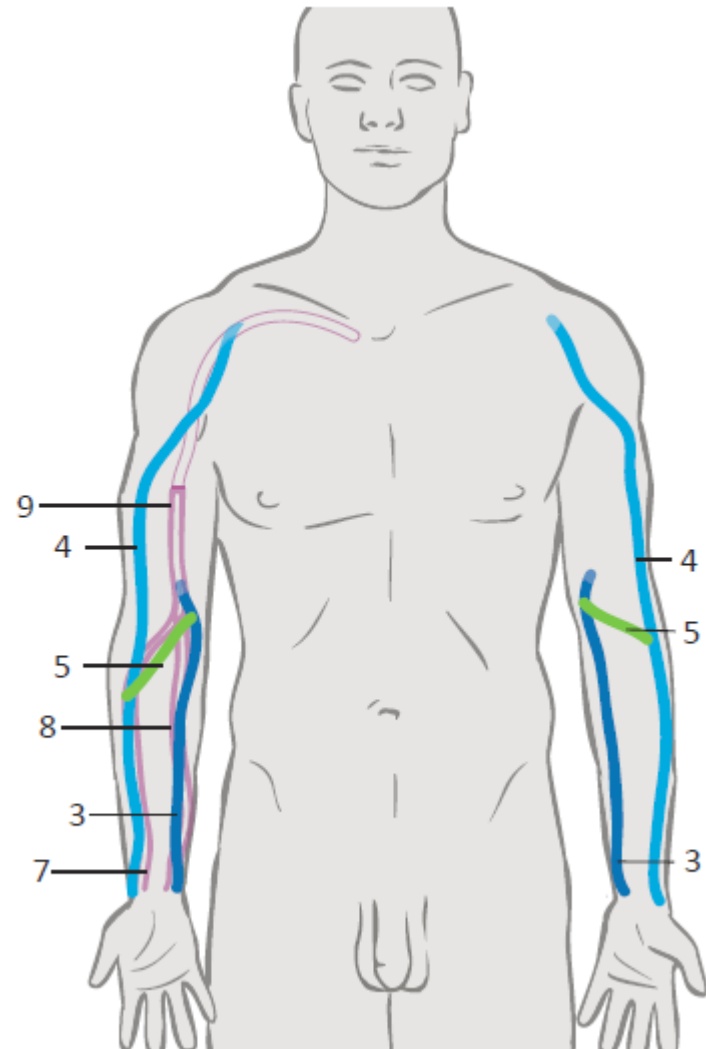
Povrchový systém:

Rete venosum dorsale manus

Vena basilica

Vena cephalica

Vena mediana cubiti



2.3 Žíly hlavy a krku

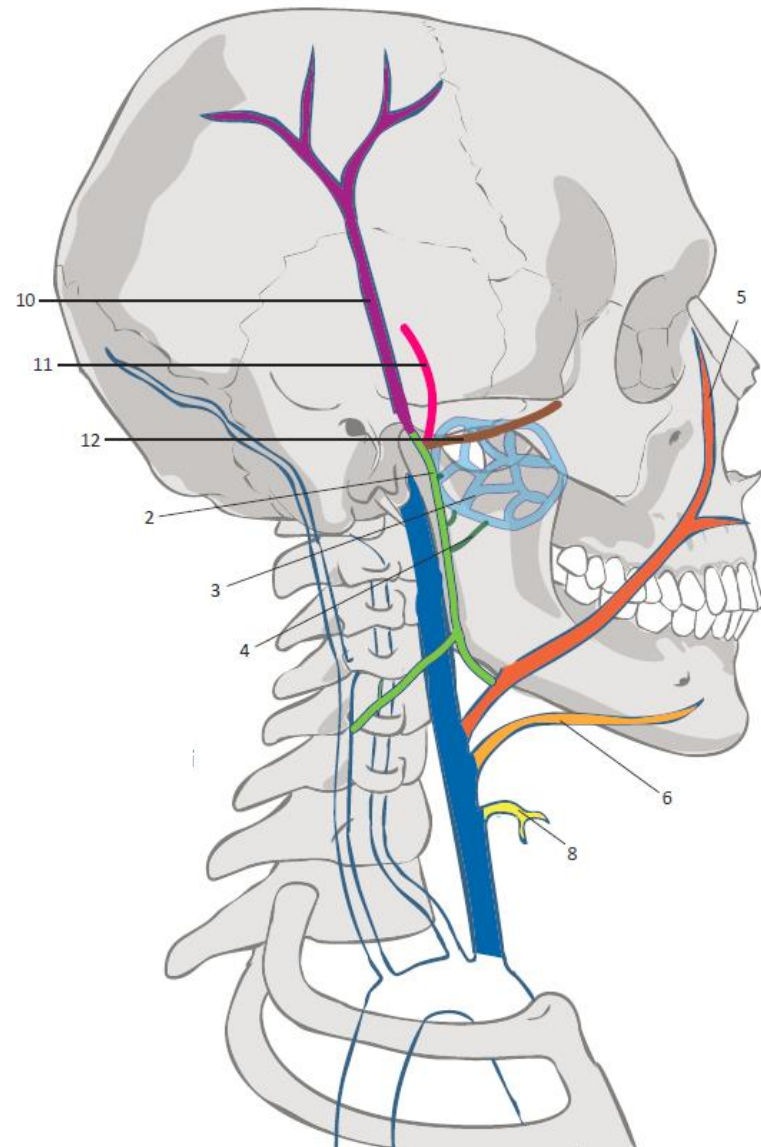
Vena jugularis interna

Intrakraniální přítoky:

- 1 **Venae cerebri**
- 2 **Venae meningeae**
- 3 **Sinus durae matris**
- 4 **Venae emissariae**

Extrakraniální přítoky:

- 1 **Venae ophthalmicae**
- 2 **Vena retromandibularis**
- 3 **Plexus pterygoideus**
- 4 **Venae maxillares**
- 5 **Vena facialis**
- 6 **Vena lingualis**



2.3 Žíly hlavy a krku

Vena jugularis externa

1 Vena retromandibularis

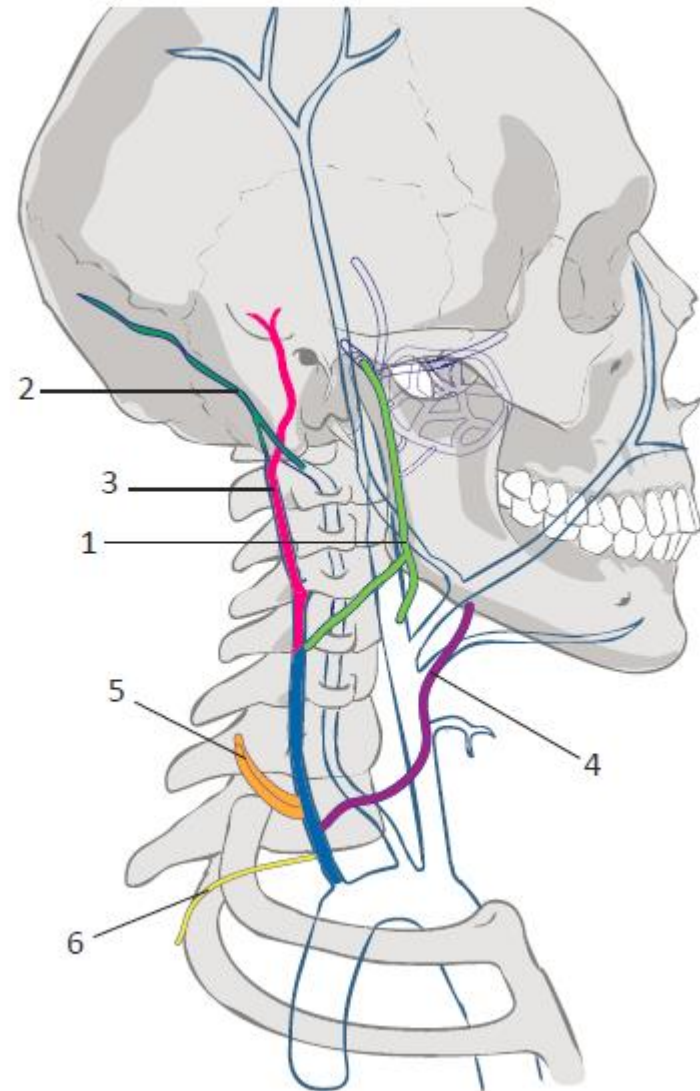
2 Vena occipitalis

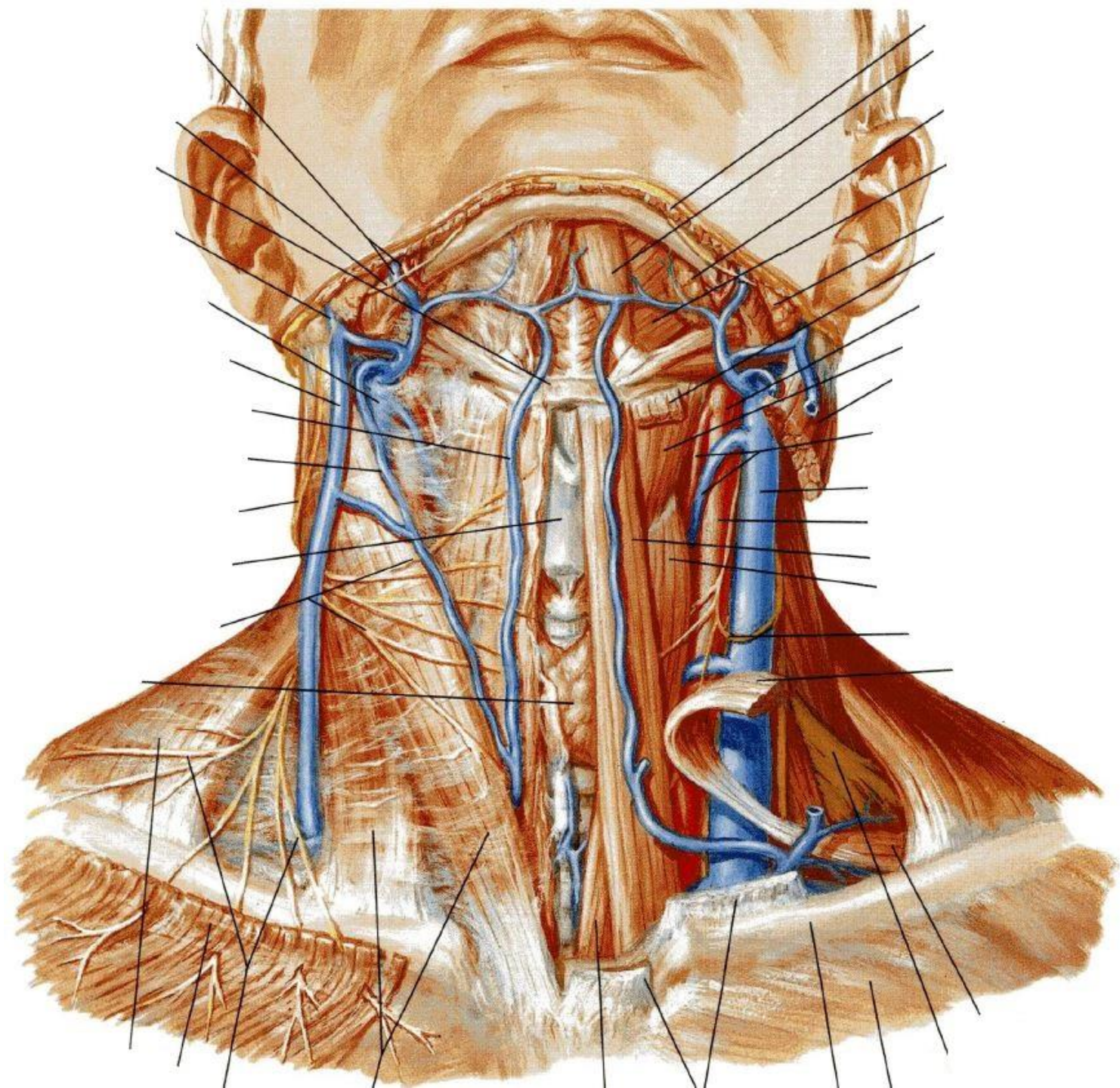
3 Vena auricularis posterior

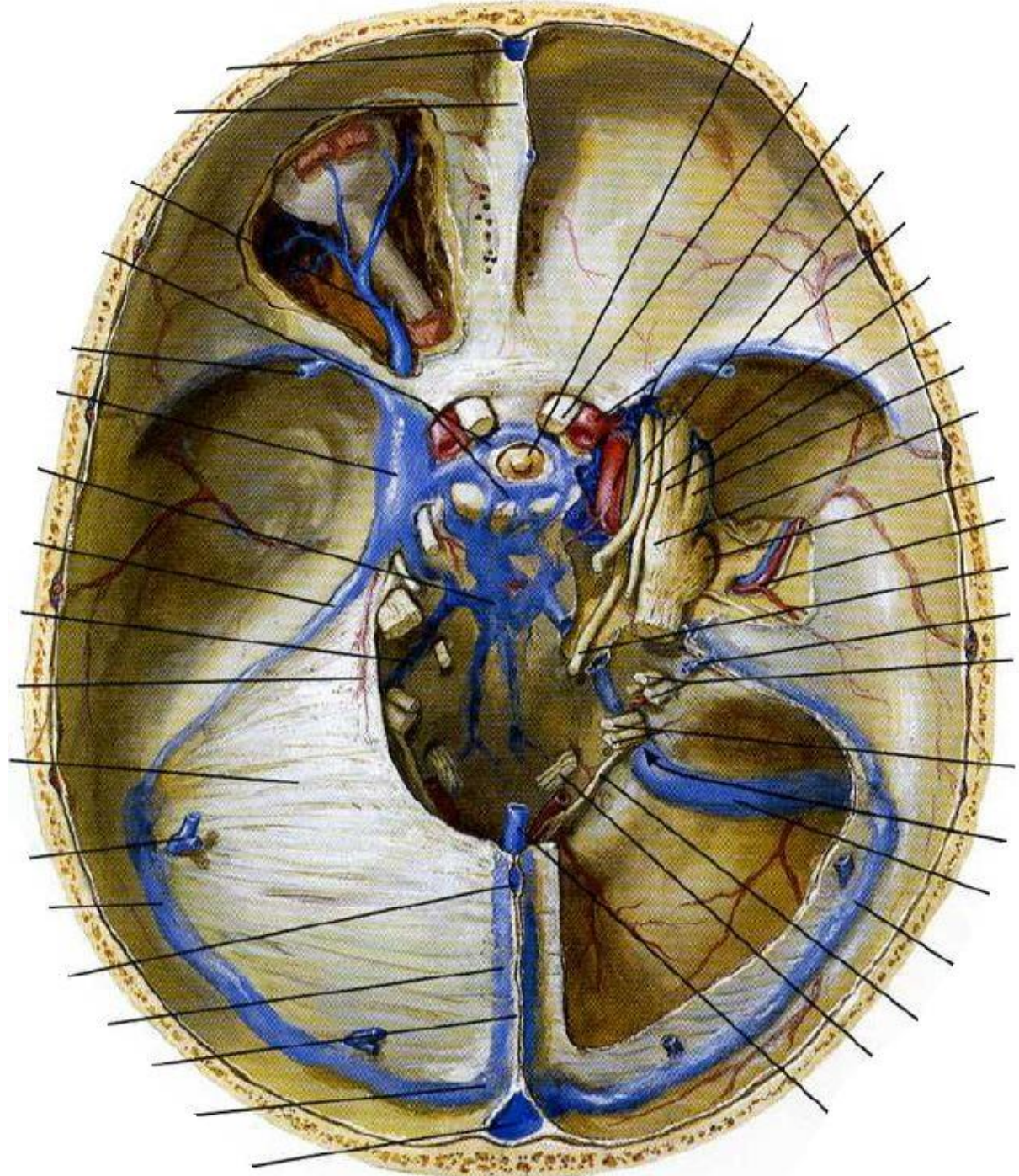
4 Vena jugularis anterior

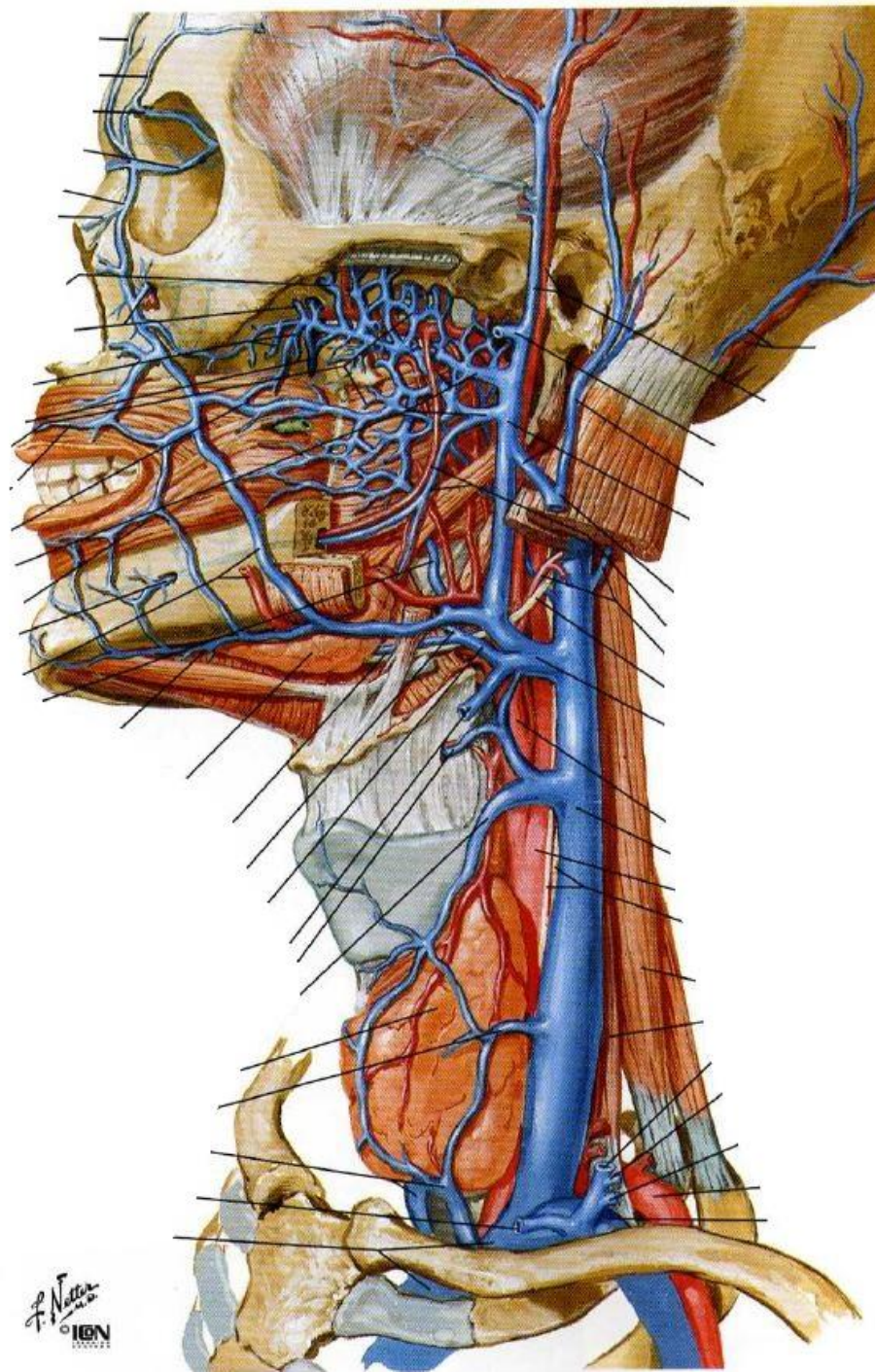
5 Venae transversae colli

6 Vena supraclavicularis









F. Netter
© IGM

2.4 Horní a dolní dutá žíla

Vena cava superior

Vzniká z:

1 Vena brachiocephalica dextra

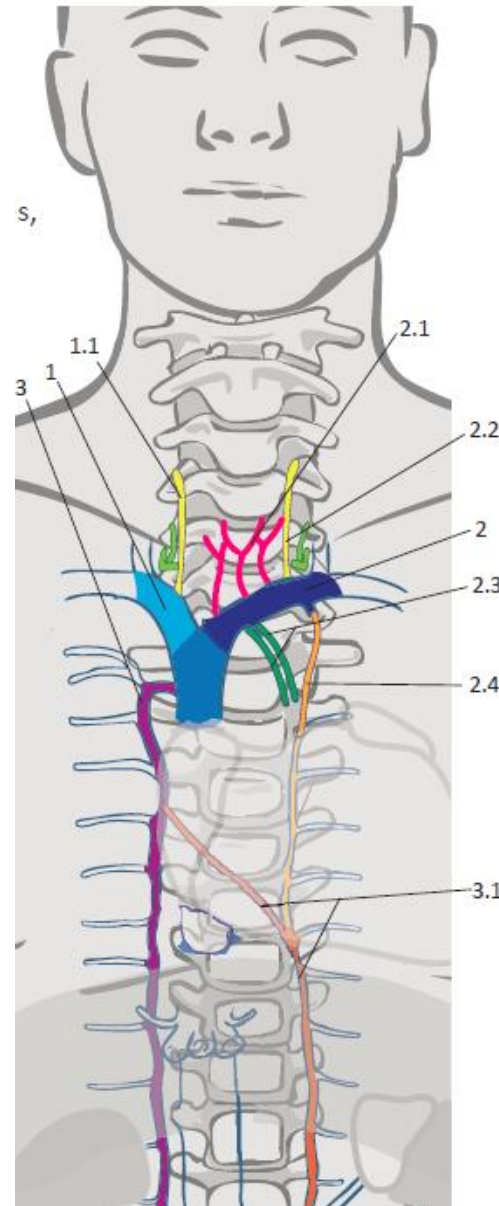
- 1.1 Vena subclavia
- 1.2 Vena jugularis interna

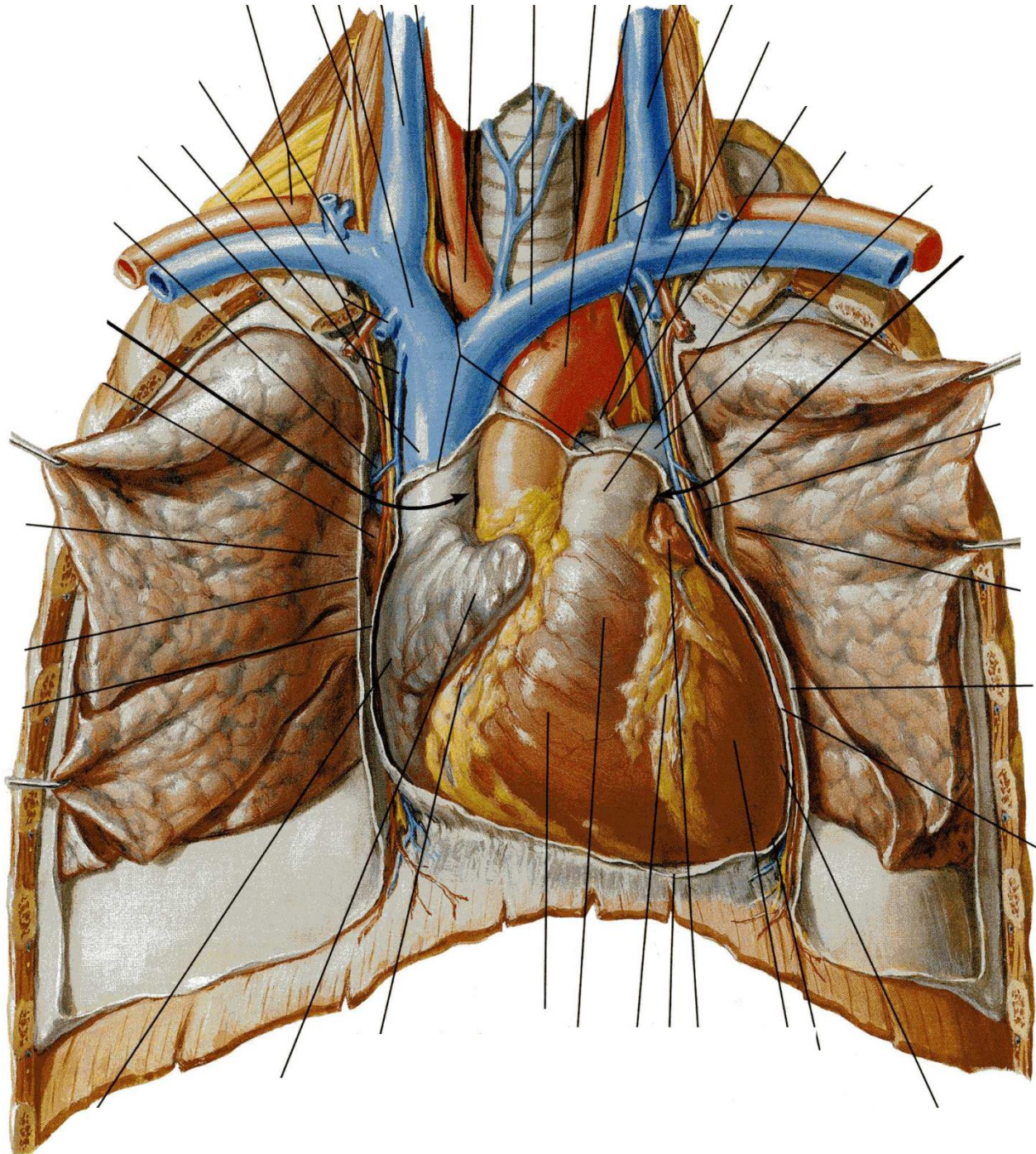
2 Vena brachiocephalica sinistra

- 2.1 Vena subclavia
- 2.2 Vena jugularis interna

Přítoky:

3 Vena azygos et hemiazygos





2.4 Horní a dolní dutá žíla

Vena cava inferior

Vzniká z:

1 Vena iliaca communis dextra

1.1 Vena iliaca interna

1.2 Vena iliaca externa

2 Vena iliaca communis sinistra

2.1 Vena iliaca interna

2.2 Vena iliaca externa

Parietální přítoky

1 Venae lumbales

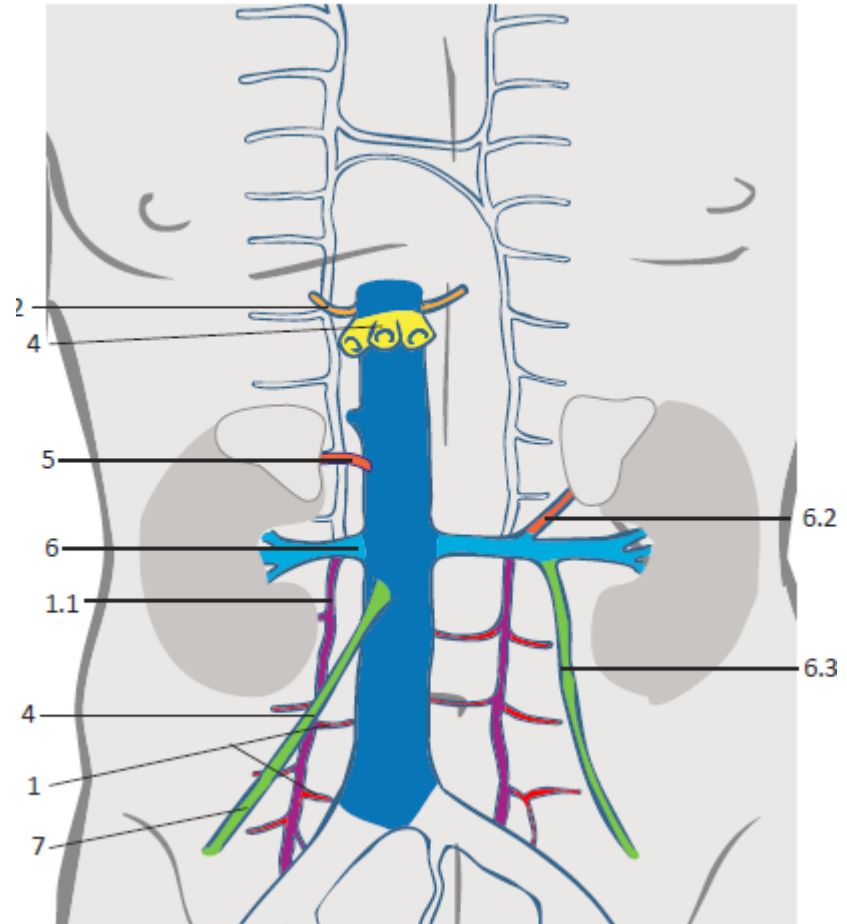
Viscerální přítoky

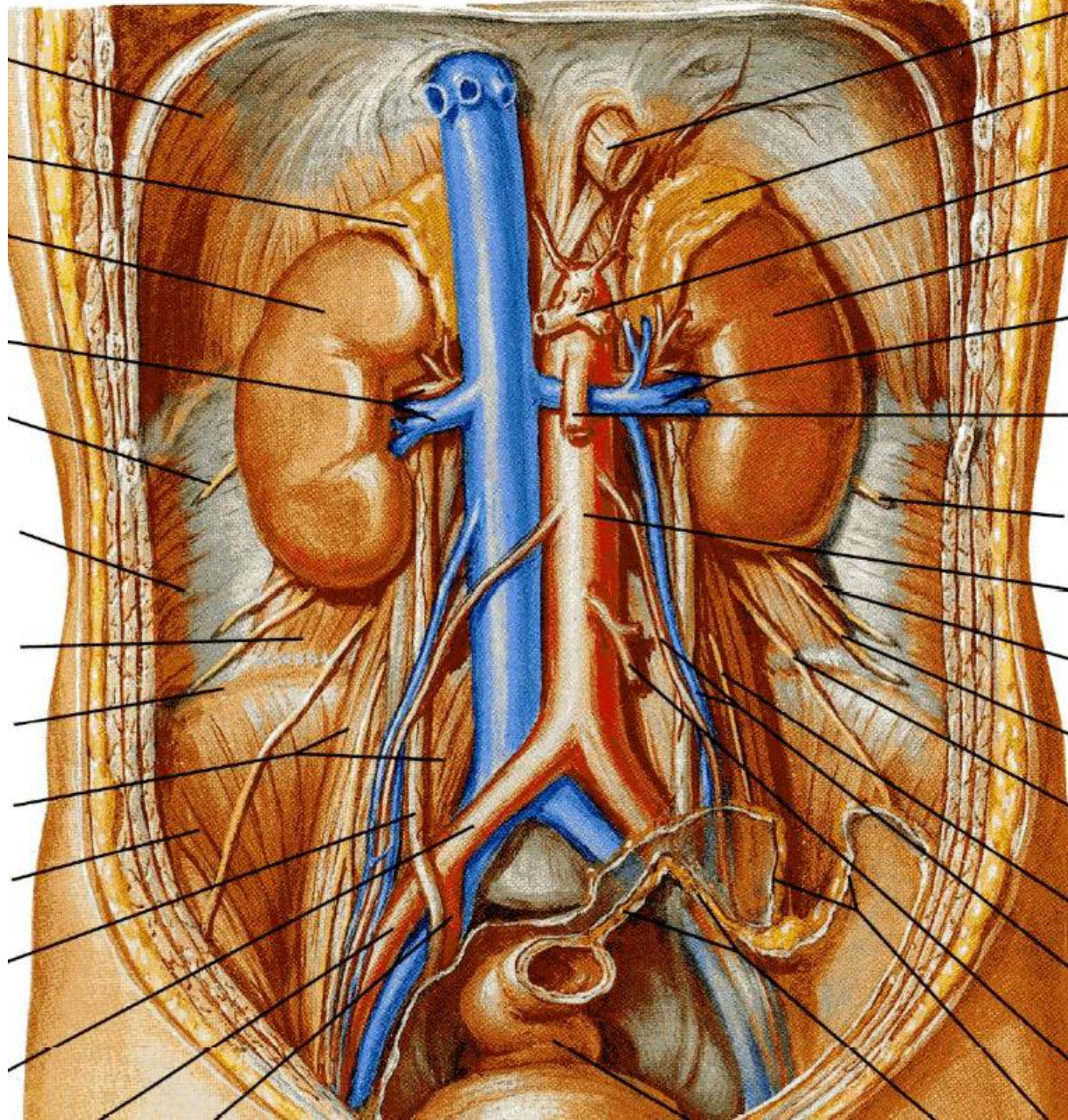
4 Venae hepaticae

6 Venae renales

7 Vena testicularis (u muže)

Vena ovarica (u ženy)



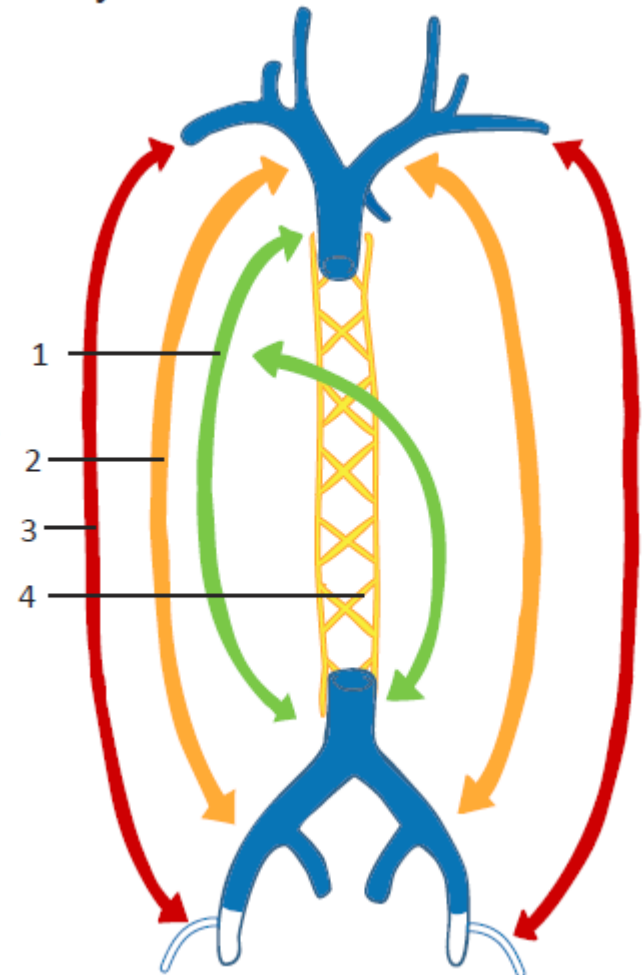


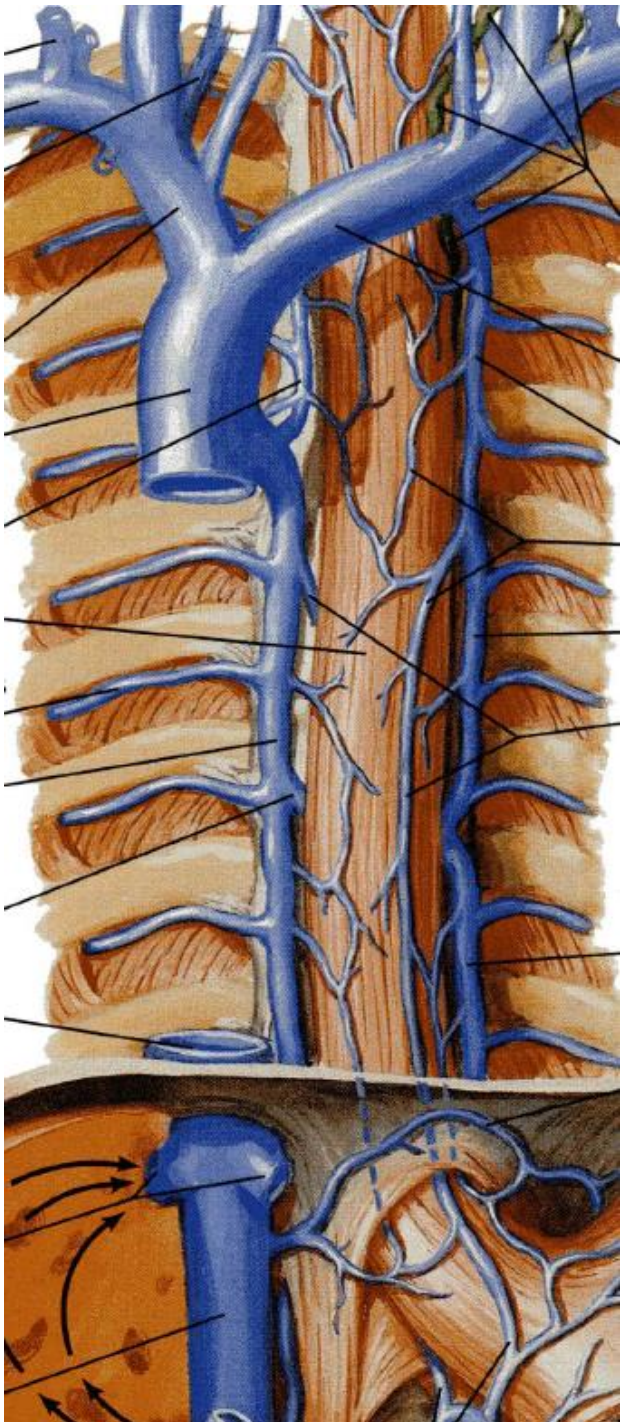
2.4 Horní a dolní dutá žíla

Kavokavální anastomózy

- spojky mezi horní a dolní dutou žílou

1 Vena azygos et hemiazygos





2.5 Vrátnicová žíla

Vena portae

1 Vena mesenterica superior

2 Vena splenica

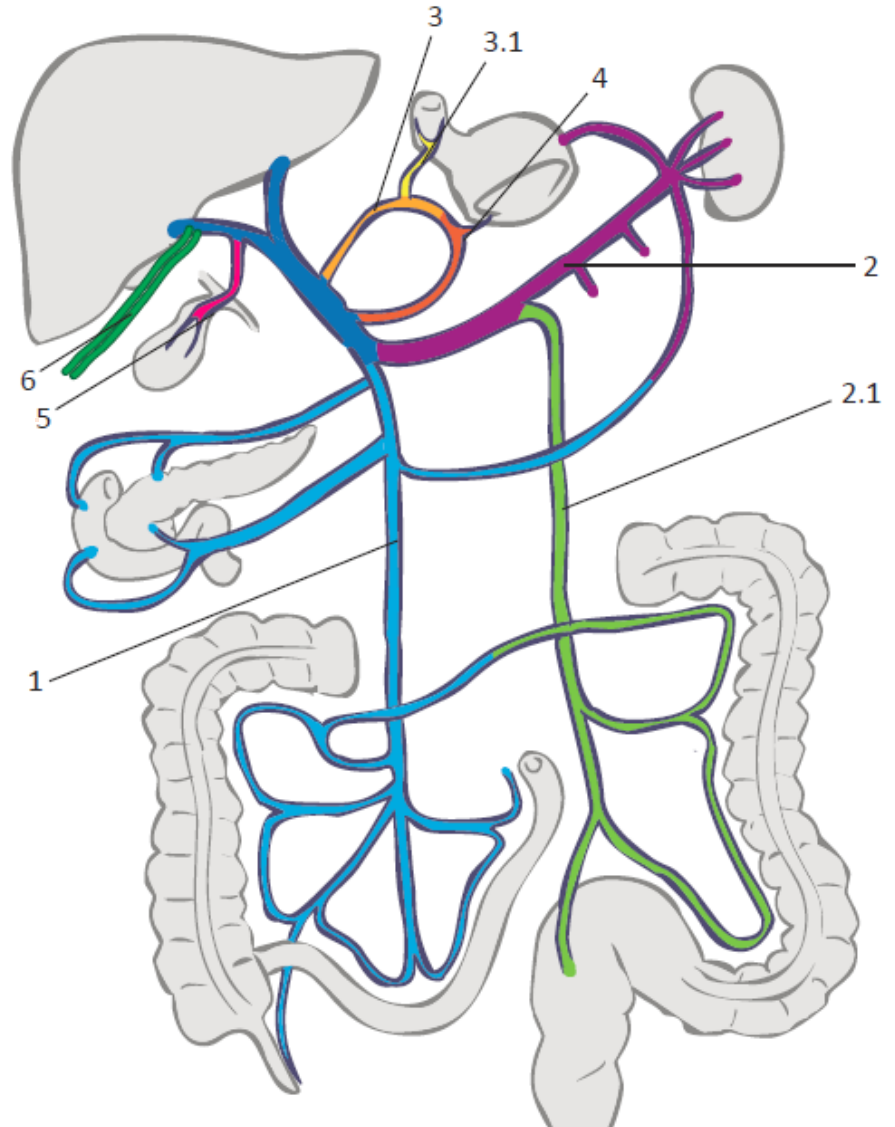
2.1 Vena mesenterica inferior

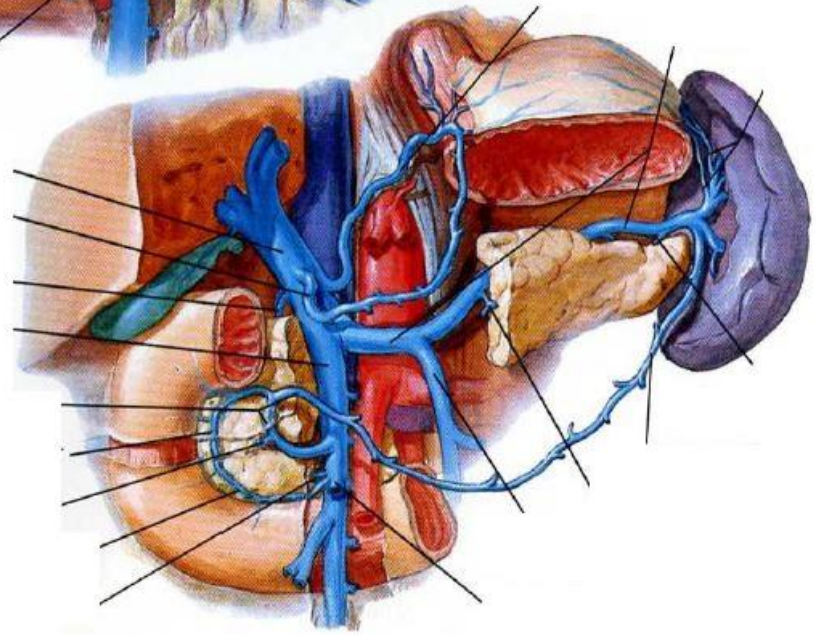
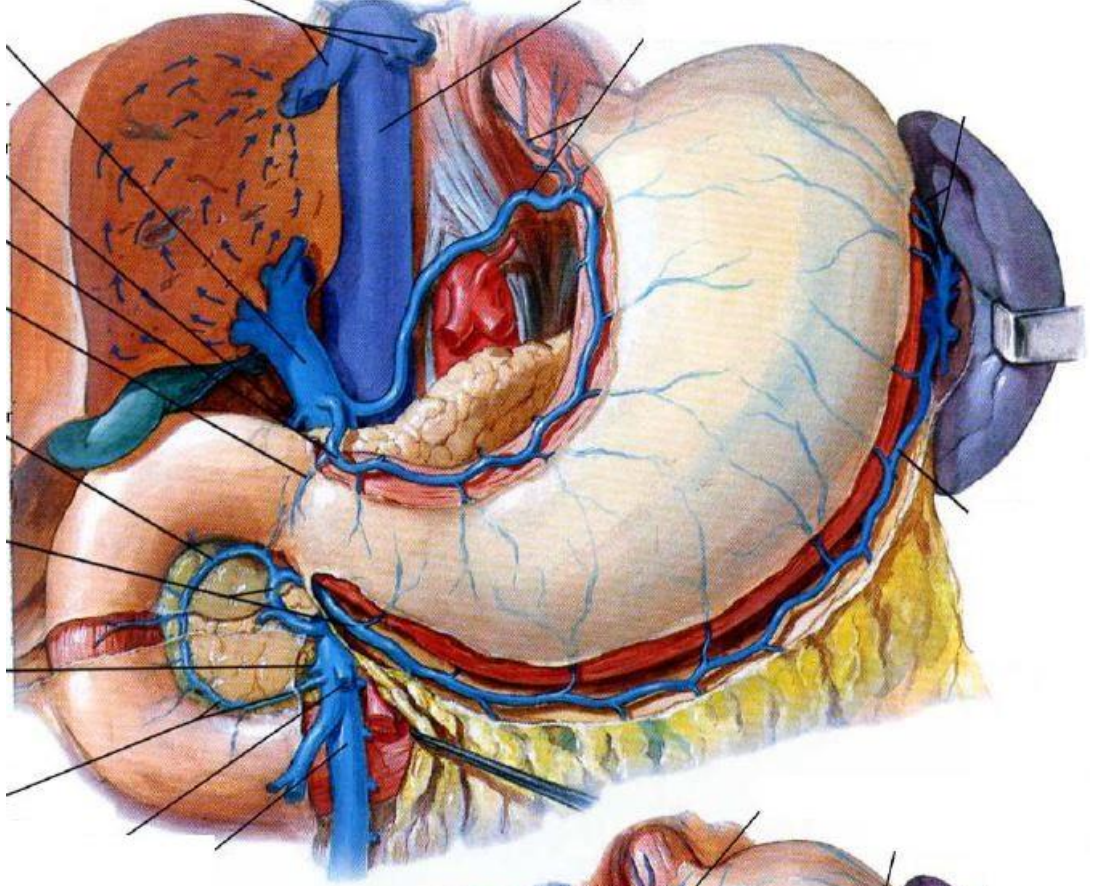
3 Vena gastrica sinistra

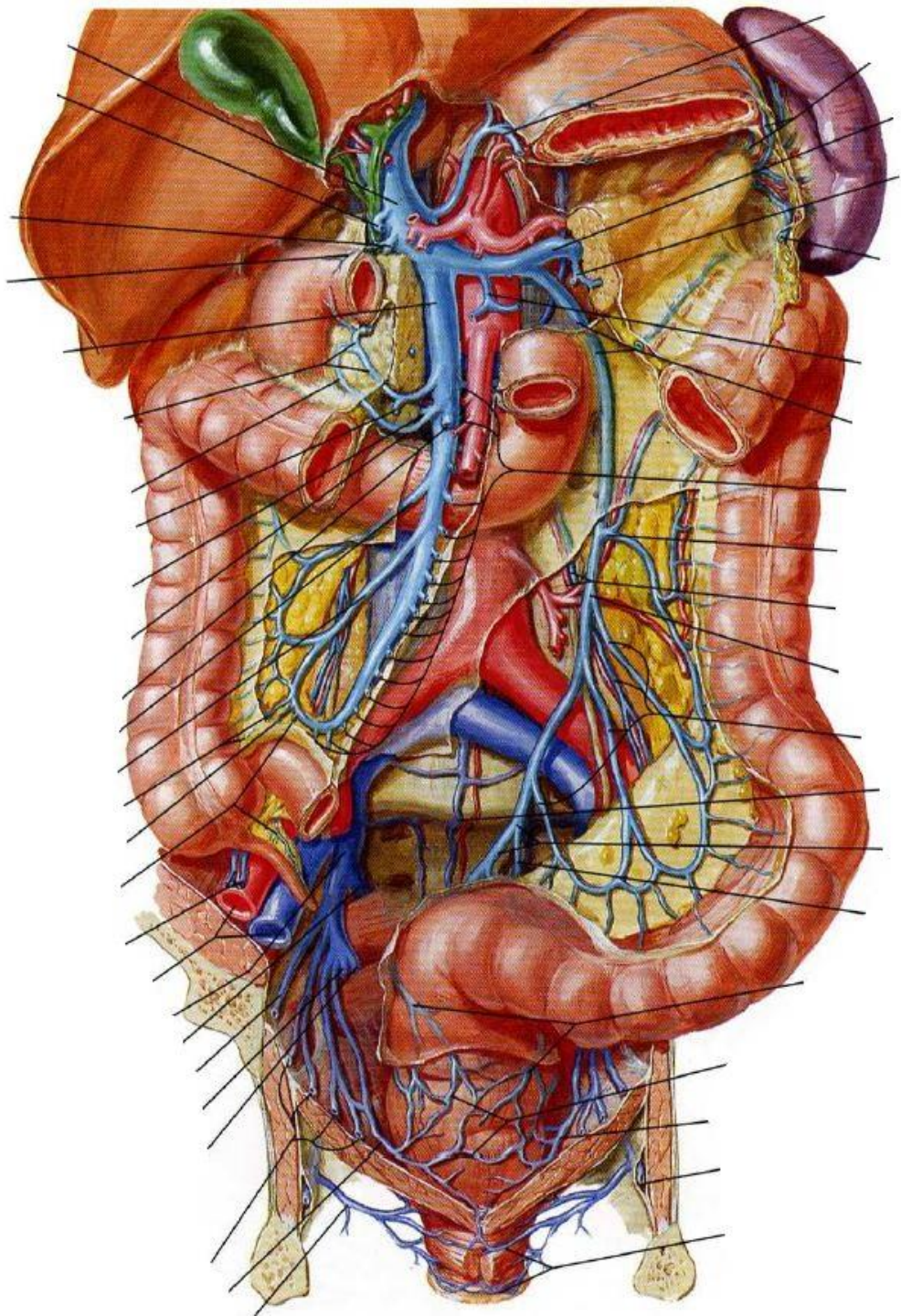
4 Vena gastrica dextra

5 Vena cystica

6 Venae paraumbilicales



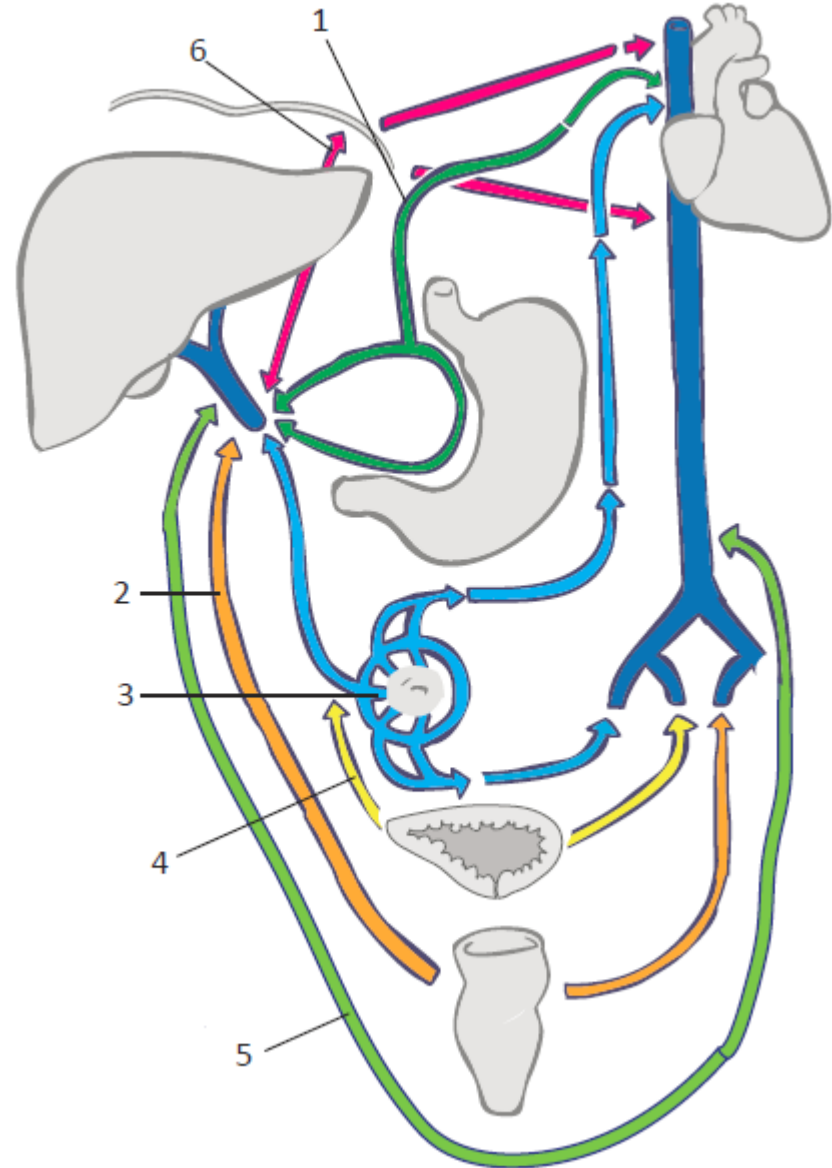




2.5 Vrátnicová žíla

Portokavální anastomózy

- 1 Spojky mezi žíly žaludku a jícnu
- 2 Spojky v oblasti konečníku
- 3 Spojky kolem pupku
- 4 Spojky kolem močového měchýře
- 5 Spojky v retroperitoneu
- 6 Spojky mezi žíly jater a bránice



3 Lymfatický a imunitní systém

Primární (centrální) orgány

1 **Thymus** – brzlík

2 **Medulla ossium** – kostní dřeň

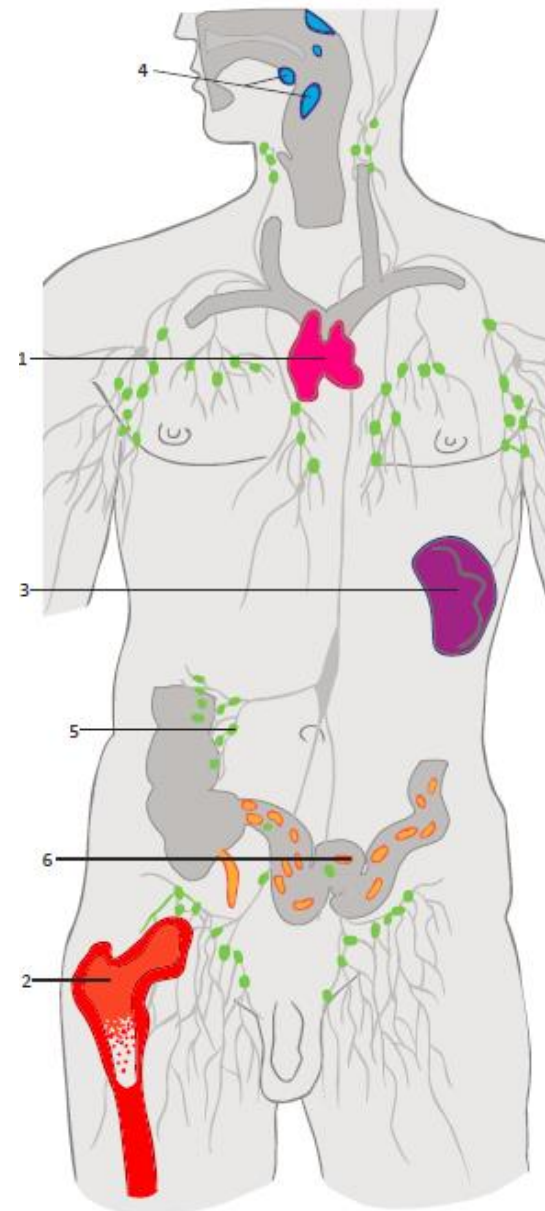
Sekundární (periferní) orgány

3 **Splen (lien)** – slezina

4 **Tonsillae** – mandle

5 **Nodi lymphoidei** – mízní uzliny

6 **Noduli lymphoidei** – mízní uzlíky



3 Lymfatický a imunitní systém

Mízní cévy

1 Mízní vlásečnice

2 Mízní cévy

2.1 Kolektory horních končetin

2.2 Kolektory dolních končetin

3 Mízní kmeny

3.1 Truncus jugularis

3.2 Truncus subclavius

3.3 Truncus bronchomediastinalis

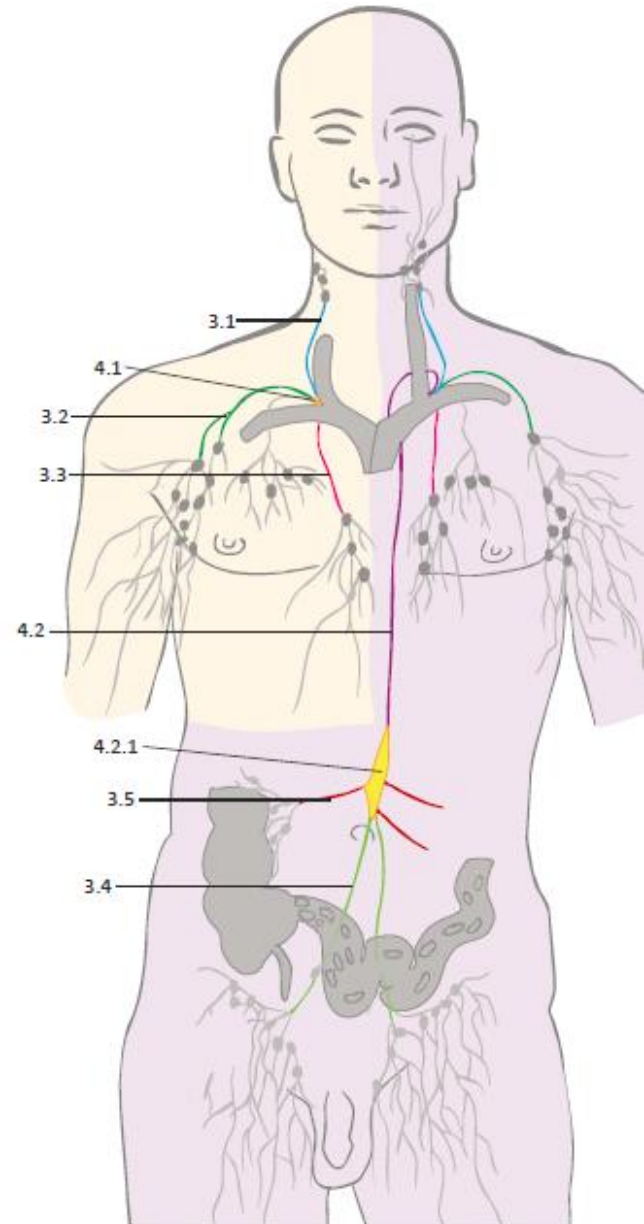
3.4 Truncus lumbalis

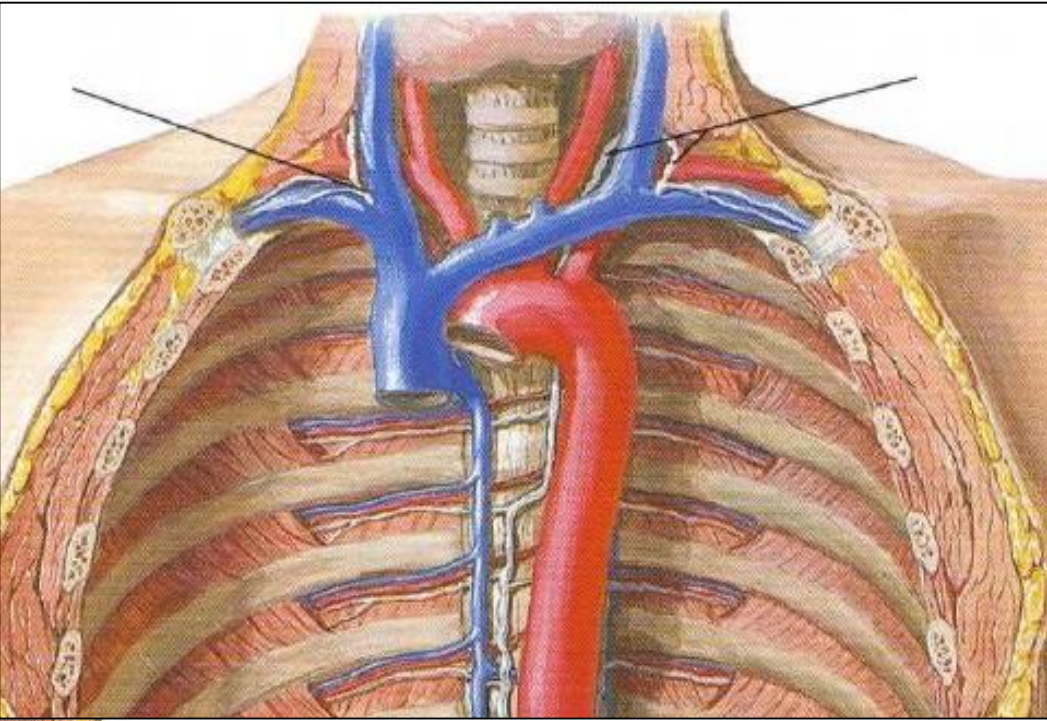
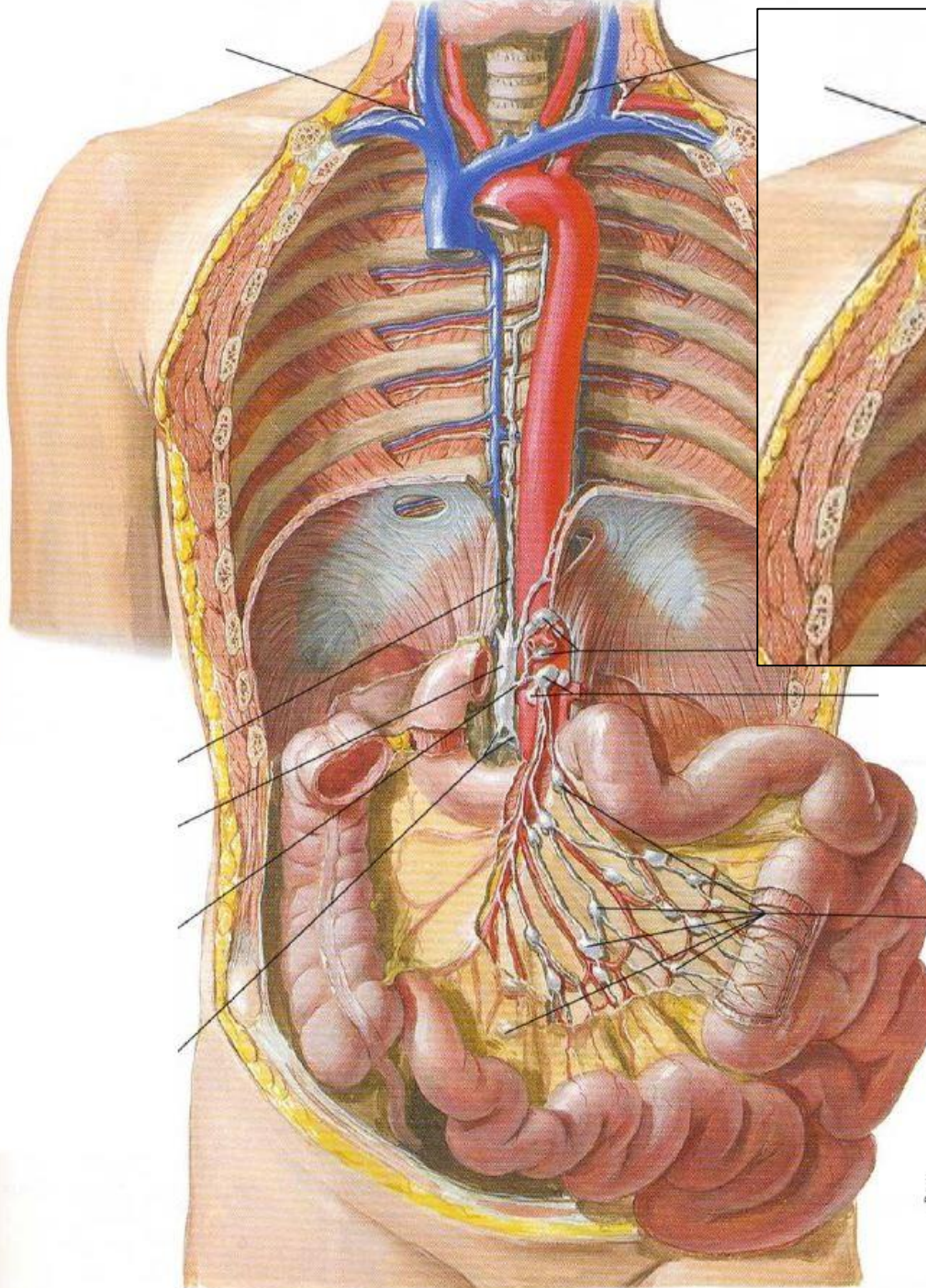
3.5 Trunci intestinales

4 Mízovody

4.1 Ductus lymphaticus dexter

4.2 Ductus thoracicus





F. Netter
C. Machado
1910

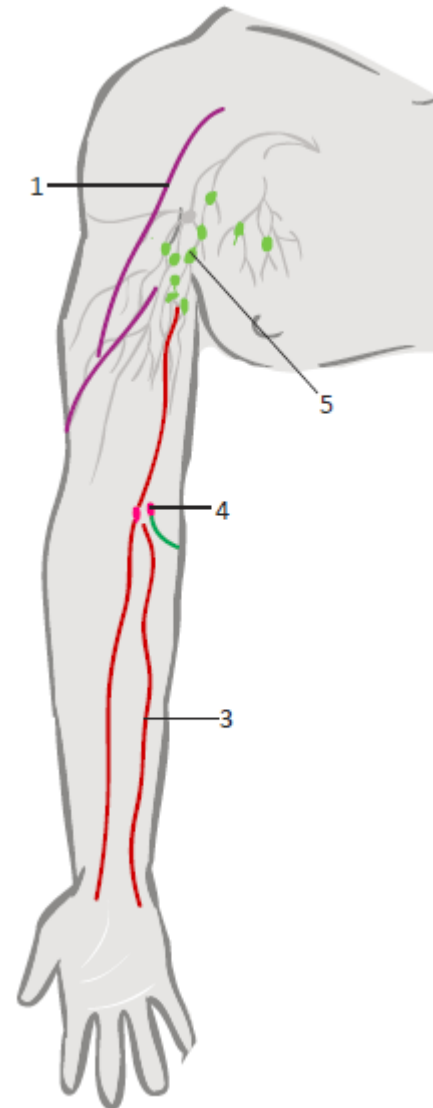
3 Lymfatický a imunitní systém

Kolektory horní končetiny:

- 1 Laterální
- 2 Mediální
- 3 Přední

Uzliny horní končetiny:

- 4 **Nodi lymphoidei cubitales superficiales et profundi**
- 5 Nodi lymphoidei brachiales
- 6 Nodi lymphoidei deltopectorales
- 7 Nodi lymphoidei interpectorales
- 8 **Nodi lymphoidei axillares**



3 Lymfatický a imunitní systém

Kolektory dolní končetiny:

- 1 Mediální
- 2 Laterální
- 3 Zadní

Uzliny dolní končetiny:

- 4 **Nodi lymphoidei poplitei**
profundi et superficiales
- 3 **Nodi lymphoidei inguinales**
 - 3.1 Nodi lymphoidei inguinales
superficiales (8–12)
 - 3.2 Nodi lymphoidei inguinales profundi

