GIT III

Anatomický ústav 2. LF

Druga

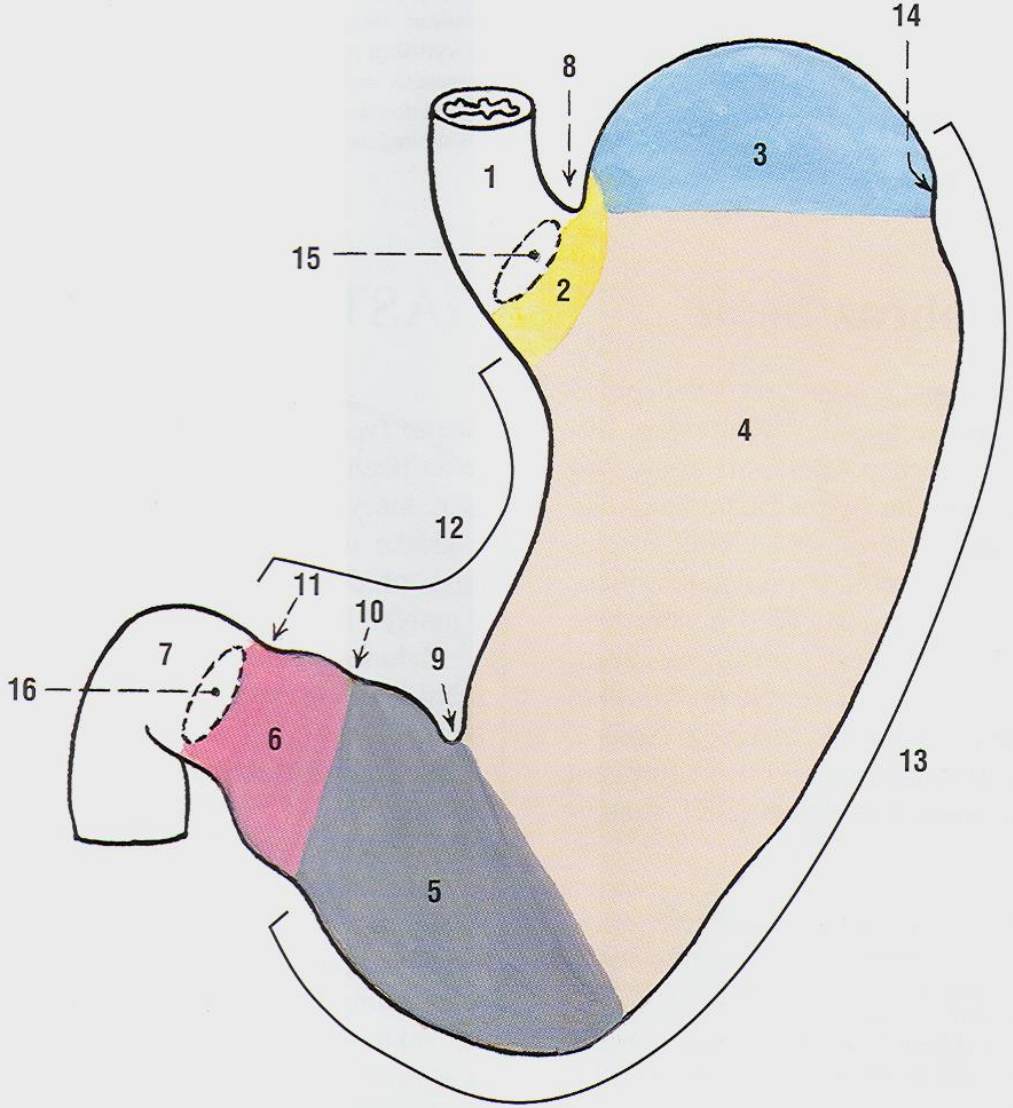

Obr. 47. FUNKČNÍ ÚSEKY A HLAVNÍ ÚTVARY ŽALUDKU; schéma

1 jícen
2 pars cardiaca
3 fundus gastricus
4 corpus gastricum
5 antrum pyloricum
6 canalis pyloricus
7 pars superior duodeni
8 incisura cardiaca
9 incisura angularis
10 sulcus intermedius
11 pylorus
12 curvatura minor
13 curvatura major
14 incisura major
15 ostium cardiacum
16 ostium pyloricum

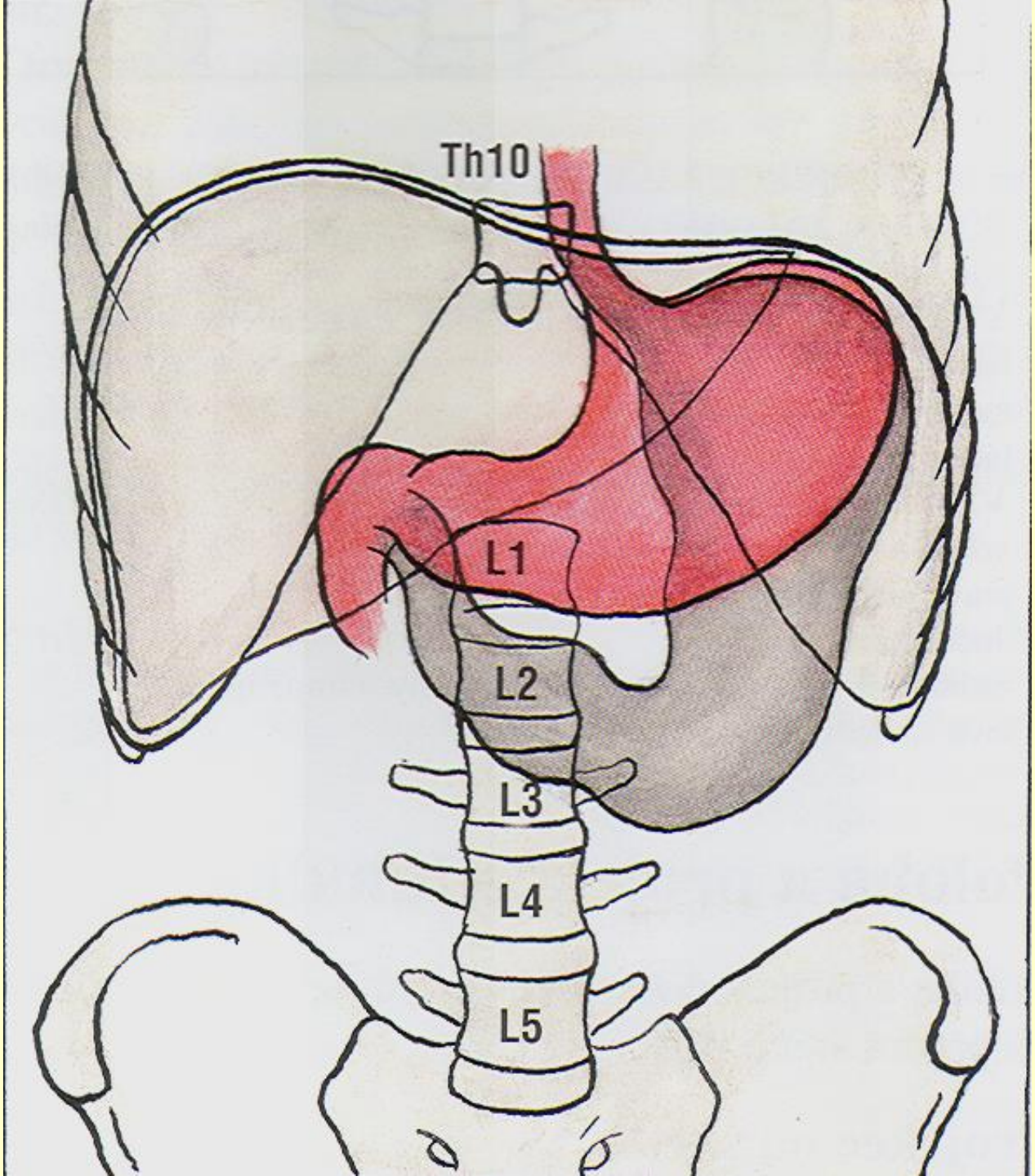
Th10
L1
L2
L3
L4
L5

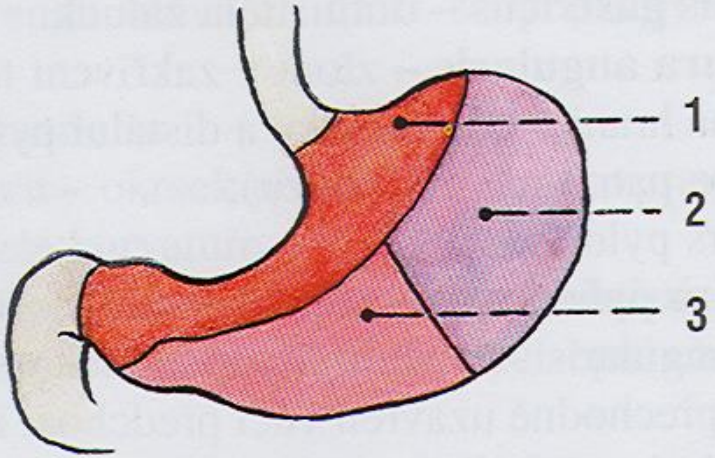
1
2
3

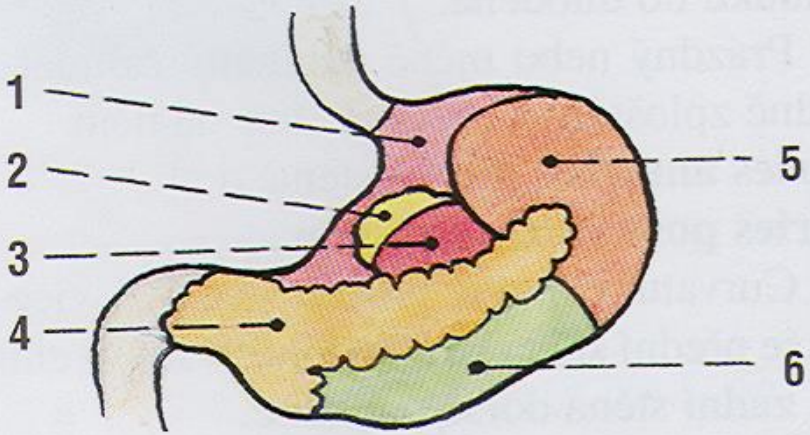
1
2
3
4
5
6

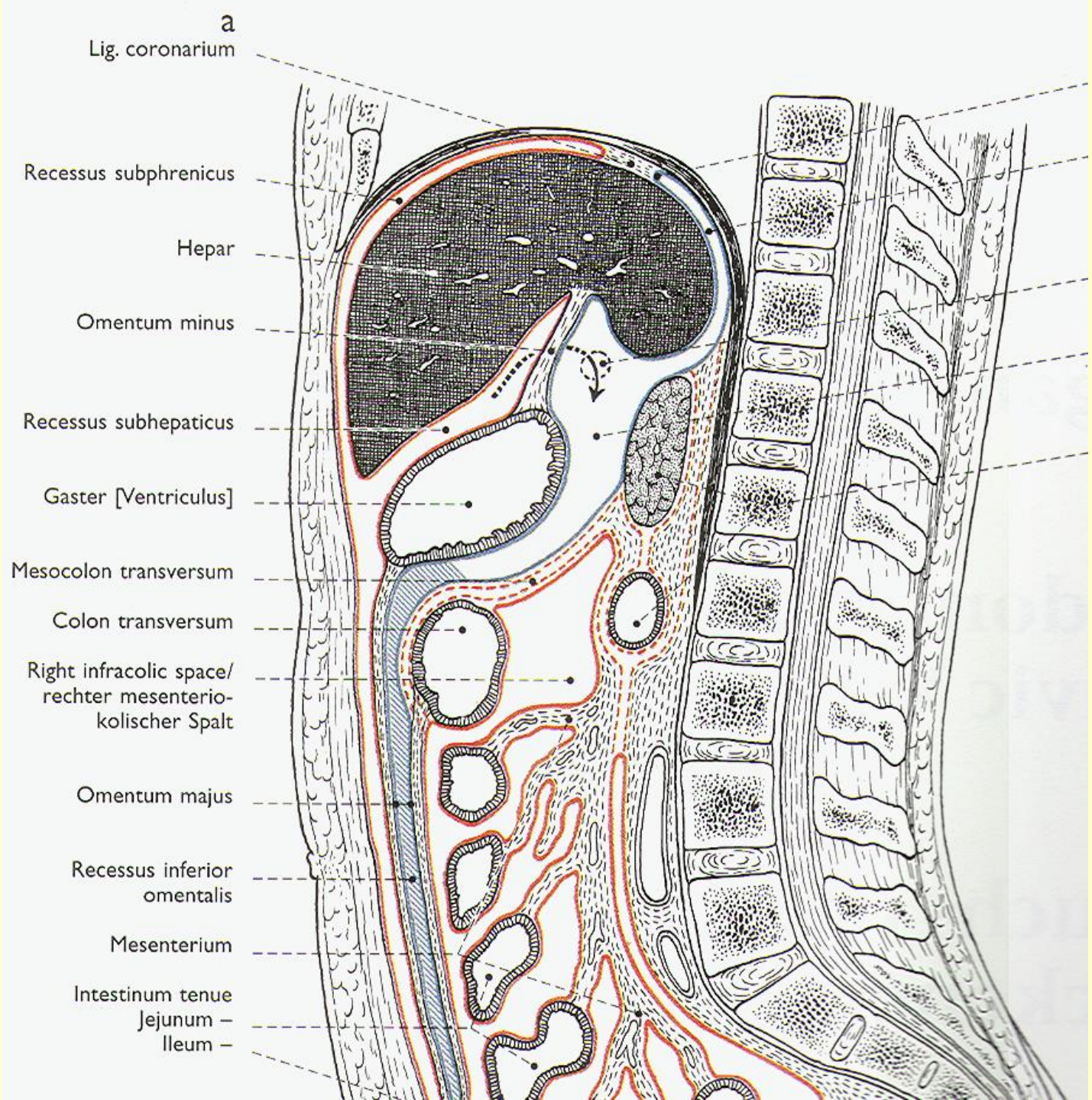
a
Lig. coronarium
Recessus subphrenicus
Hepar
Omentum minus
Recessus subhepaticus
Gaster [Ventriculus]
Mesocolon transversum
Colon transversum
Right infracolic space/
rechter mesenterio-
kolischer Spalt
Omentum majus
Recessus inferior
omentalis
Mesenterium
Intestinum tenue
Jejunum –
Ileum –

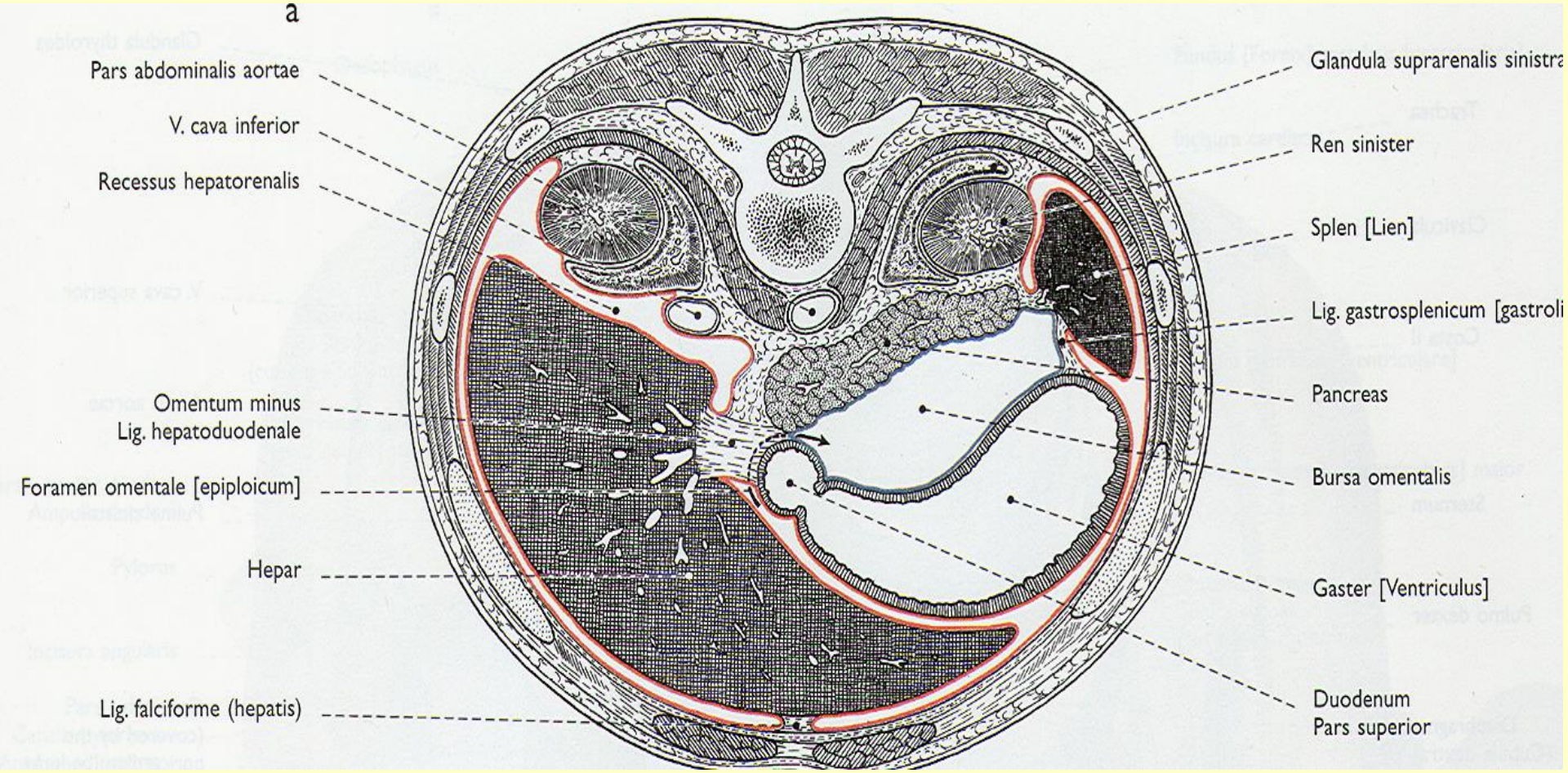
a
Pars abdominalis aortae
V. cava inferior
Recessus hepatorenalis
Omentum minus
Lig. hepatoduodenale
Foramen omentale [epiploicum]
Hepar
Lig. falciforme (hepatis)
Glandula suprarenalis sinistra
Ren sinister
Splen [Lien]
Lig. gastrosplenicum [gastroli
Pancreas
Bursa omentalis
Gaster [Ventriculus]
Duodenum
Pars superior

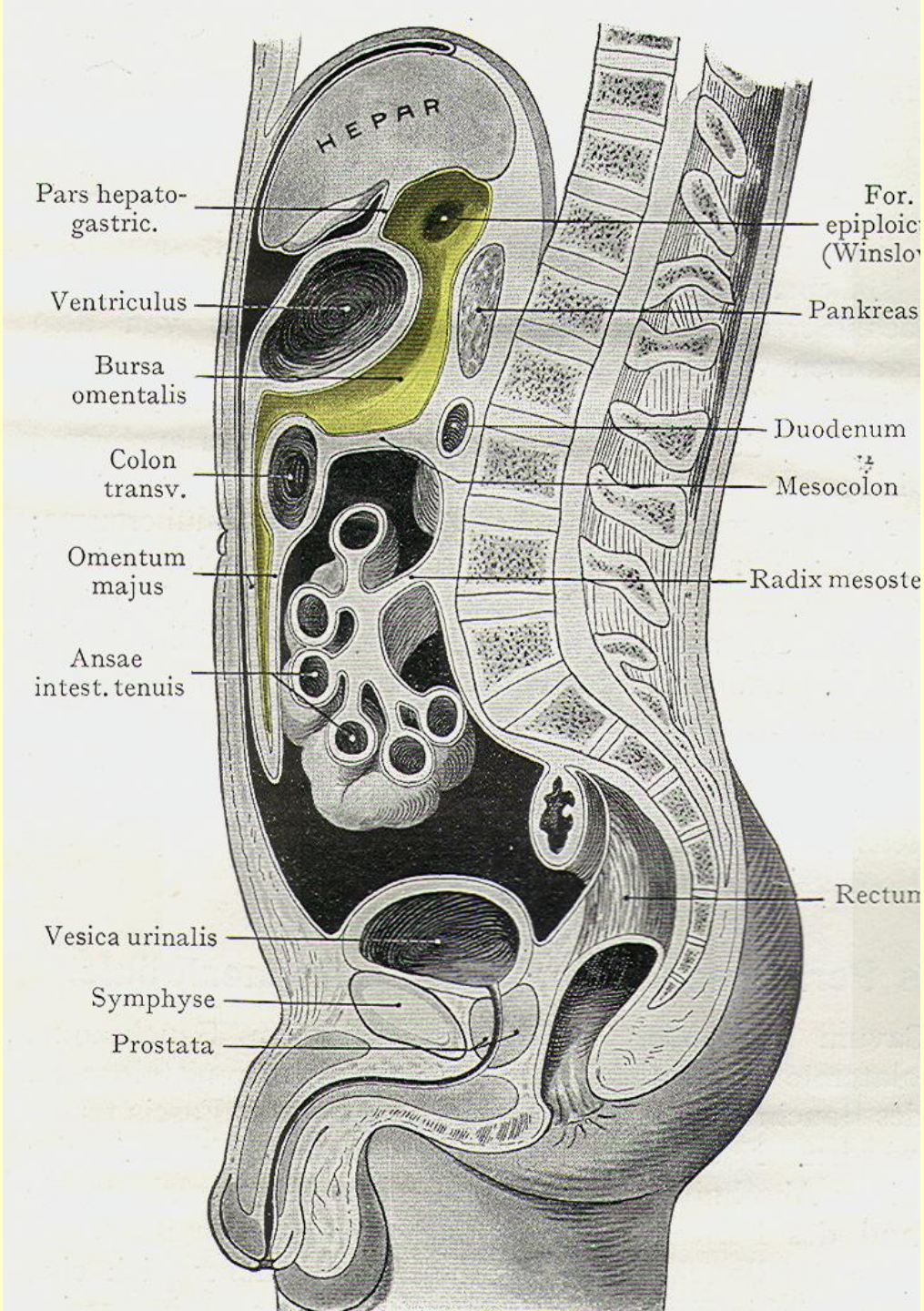
HEPAR
Pars hepato-gastric.
Ventriculus
Bursa omentalis
Colon transv.
Omentum majus
Ansae intest. tenuis
Vesica urinalis
Symphyse
Prostata
For. epiploic (Winslo
Pankreas
Duodenum
Mesocolon
Radix mesoste
Rectum

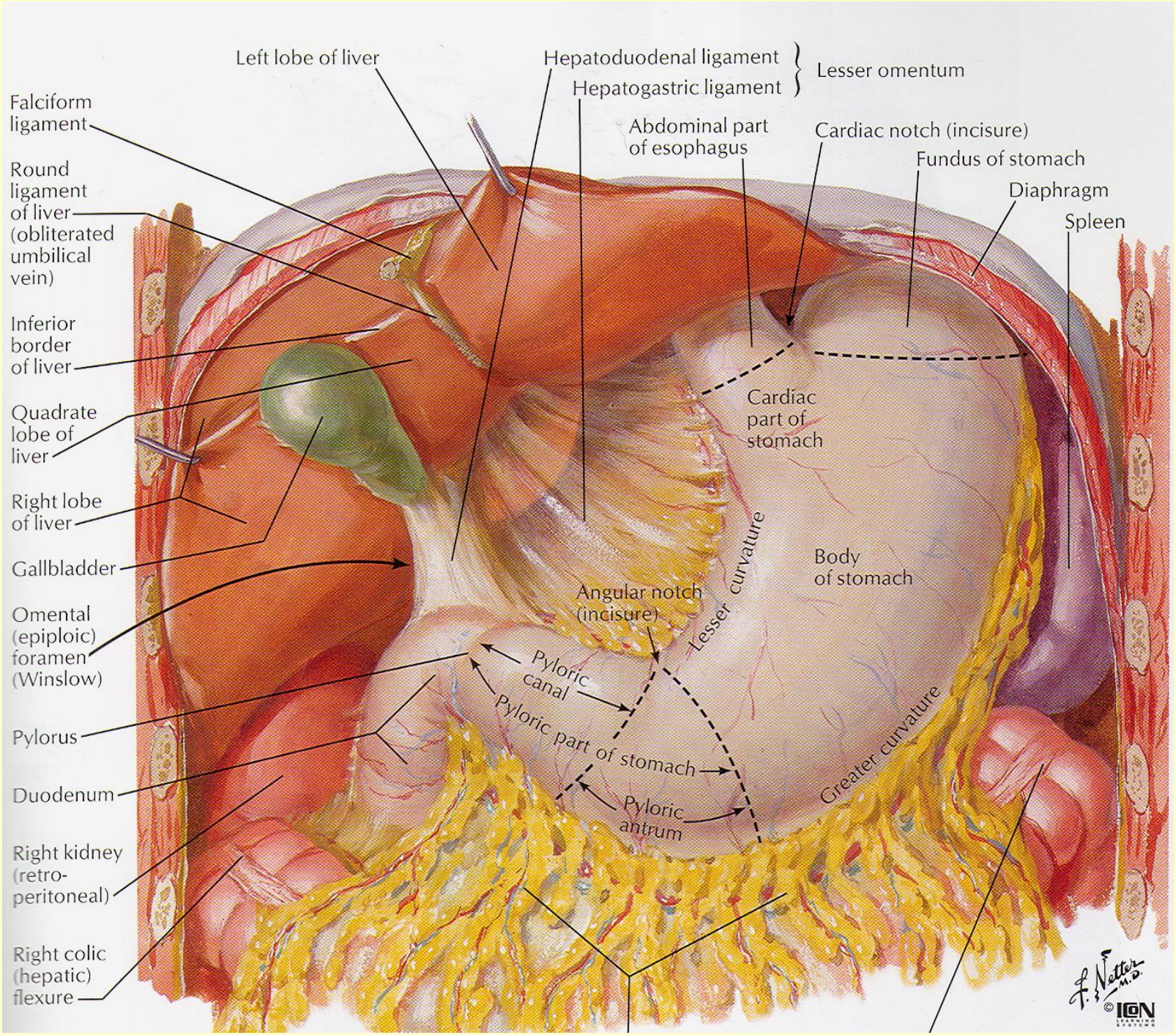
Left lobe of liver
Hepatoduodenal ligament
Hepatogastric ligament
Lesser omentum
Falciform ligament
Abdominal part of esophagus
Cardiac notch (incisure)
Fundus of stomach
Diaphragm
Spleen
Round ligament of liver (obliterated umbilical vein)
Inferior border of liver
Quadrate lobe of liver
Cardiac part of stomach
Right lobe of liver
Gallbladder
Lesser curvature
Body of stomach
Angular notch (incisure)
Omental (epiploic) foramen (Winslow)
Pyloric canal
Pylorus
Pyloric part of stomach
Greater curvature
Duodenum
Pyloric antrum
Right kidney (retro-peritoneal)
Right colic (hepatic) flexure
F. Netter M.D.
©

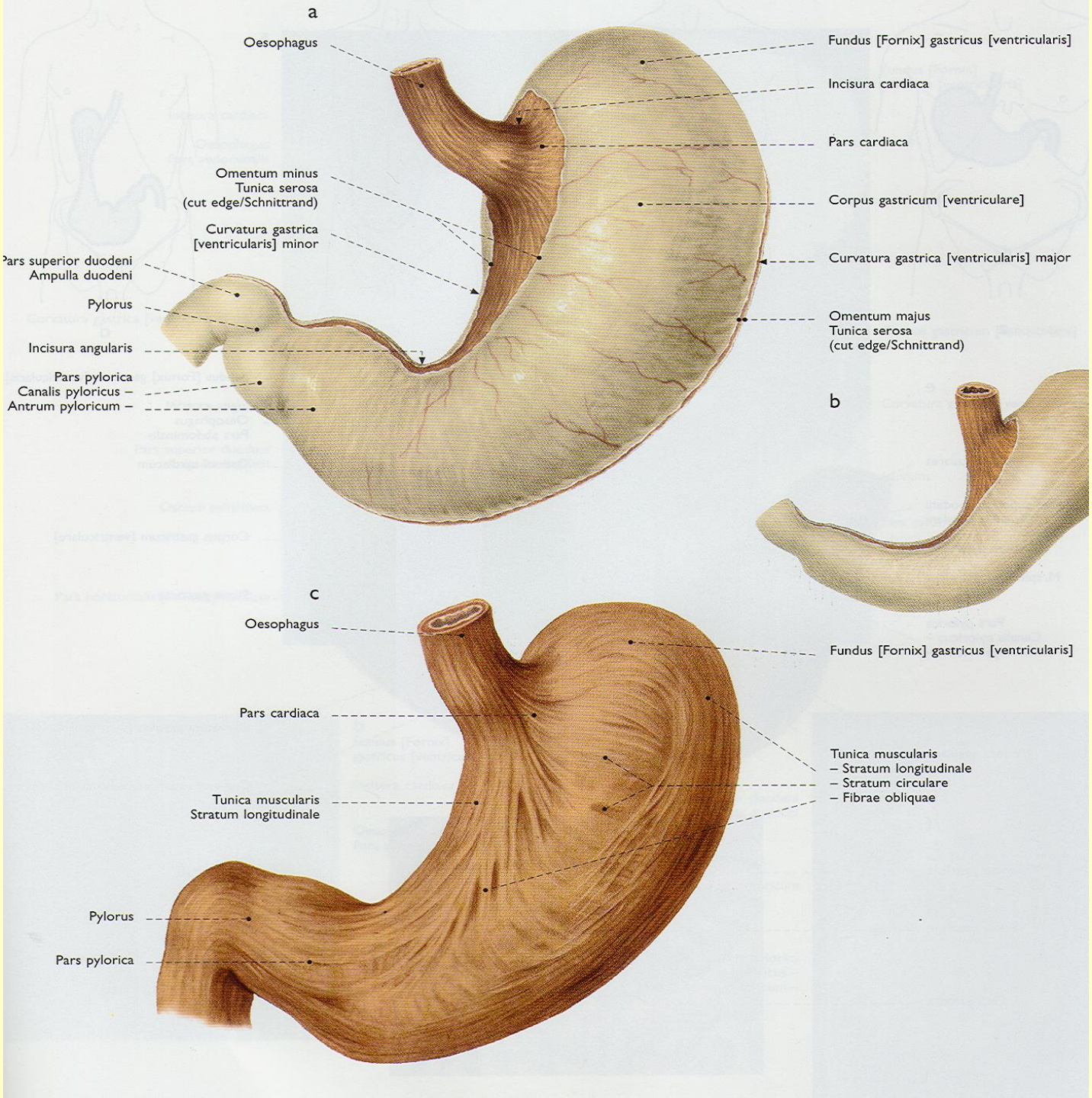
a
Oesophagus
Fundus [Fornix] gastricus [ventricularis]
Incisura cardiaca
Pars cardiaca
Omentum minus
Tunica serosa
(cut edge/Schnittrand)
Corpus gastricum [ventriculare]
Curvatura gastrica
[ventricularis] minor
Curvatura gastrica [ventricularis] major
Pars superior duodeni
Ampulla duodeni
Pylorus
Omentum majus
Tunica serosa
(cut edge/Schnittrand)
Incisura angularis
Pars pylorica
Canalis pyloricus –
Antrum pyloricum –
b
c
Oesophagus
Fundus [Fornix] gastricus [ventricularis]
Pars cardiaca
Tunica muscularis
– Stratum longitudinale
– Stratum circulare
– Fibrae obliquae
Tunica muscularis
Stratum longitudinale
Pylorus
Pars pylorica

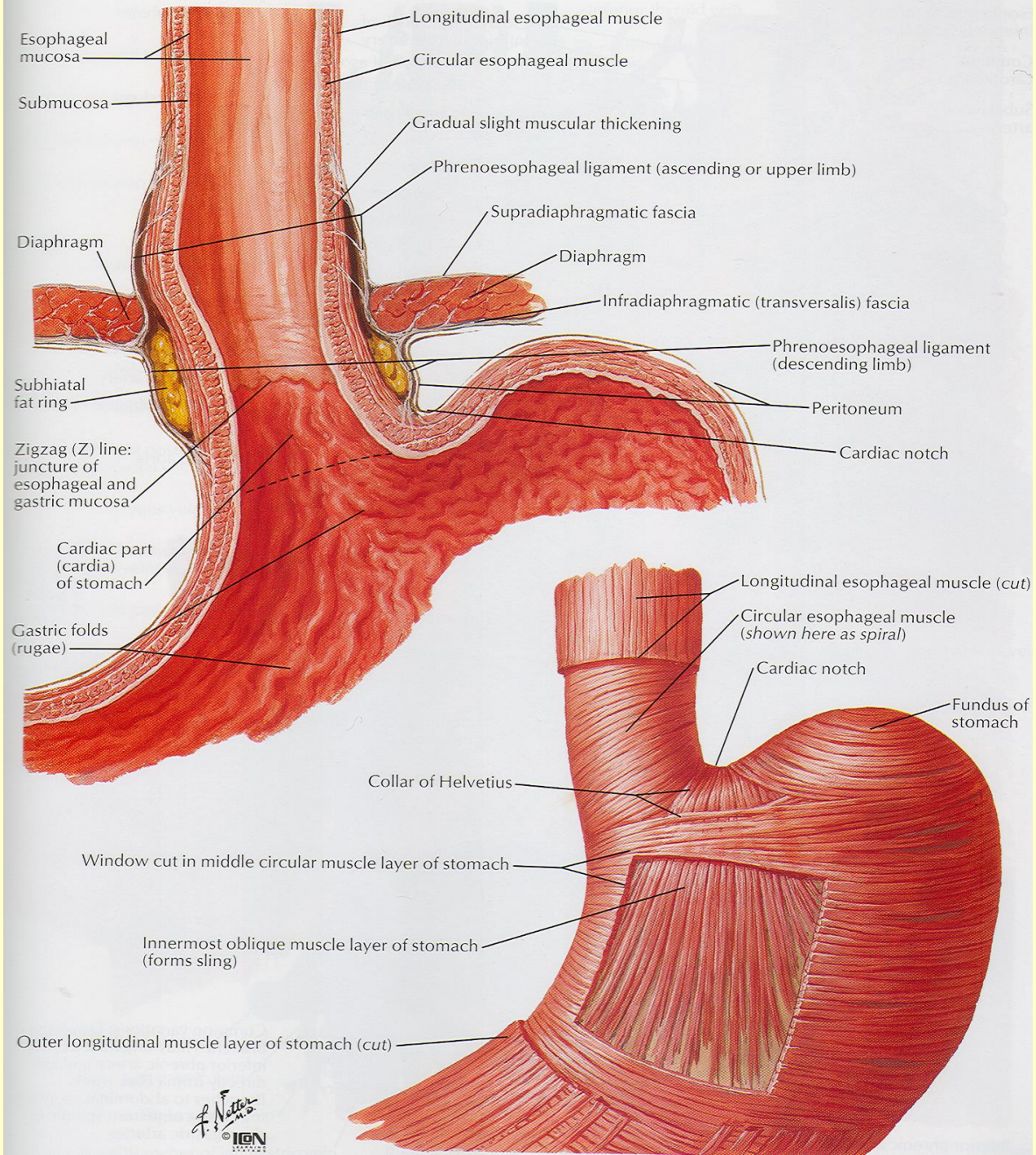
Esophageal mucosa
Submucosa
Diaphragm
Subhiatal fat ring
Zigzag (Z) line: juncture of esophageal and gastric mucosa
Cardiac part (cardia) of stomach
Gastric folds (rugae)
Longitudinal esophageal muscle
Circular esophageal muscle
Gradual slight muscular thickening
Phrenoesophageal ligament (ascending or upper limb)
Supradiaphragmatic fascia
Diaphragm
Infradiaphragmatic (transversalis) fascia
Phrenoesophageal ligament (descending limb)
Peritoneum
Cardiac notch
Longitudinal esophageal muscle (cut)
Circular esophageal muscle (shown here as spiral)
Cardiac notch
Fundus of stomach
Collar of Helvetius
Window cut in middle circular muscle layer of stomach
Innermost oblique muscle layer of stomach (forms sling)
Outer longitudinal muscle layer of stomach (cut)
F. Netter M.D.
©ION

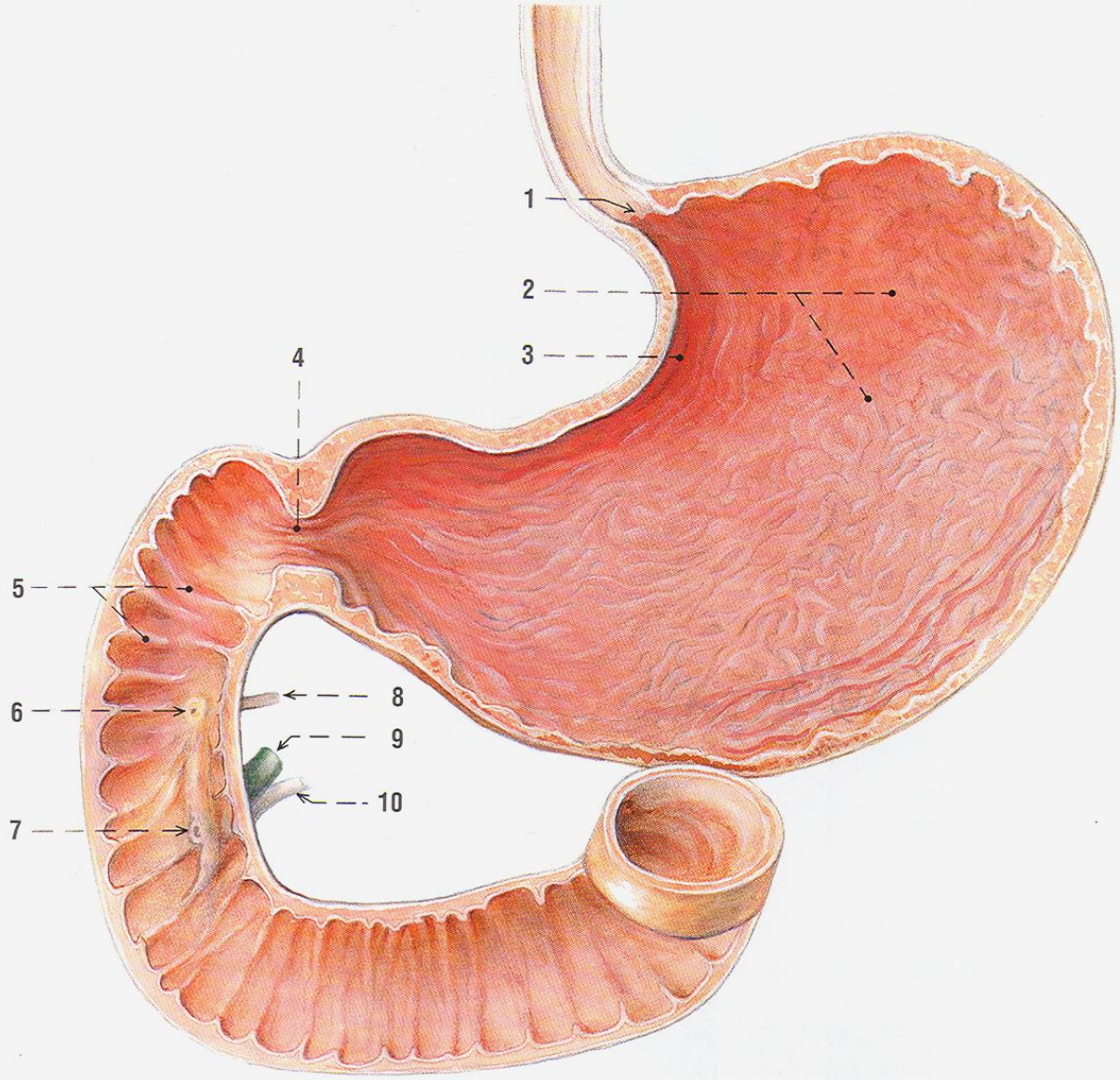

Obr. 52. RELIÉF SLIZNICE ŽALUDKU A DUODENA

1 rozhraní sliznice jícnu a žaludku
2 řasy ve fundu žaludku
3 podélné řasy při malé kurvatuře (Waldeyerova cesta)
4 ostium pyloricum
5 cirkulární řasy duodena
6 papilla duodeni minor na plica longitudinalis duodeni
7 papilla duodeni major na plica longitudinalis duodeni
8 ductus pancreaticus accessorius
9 ductus choledochus
10 ductus pancreaticus

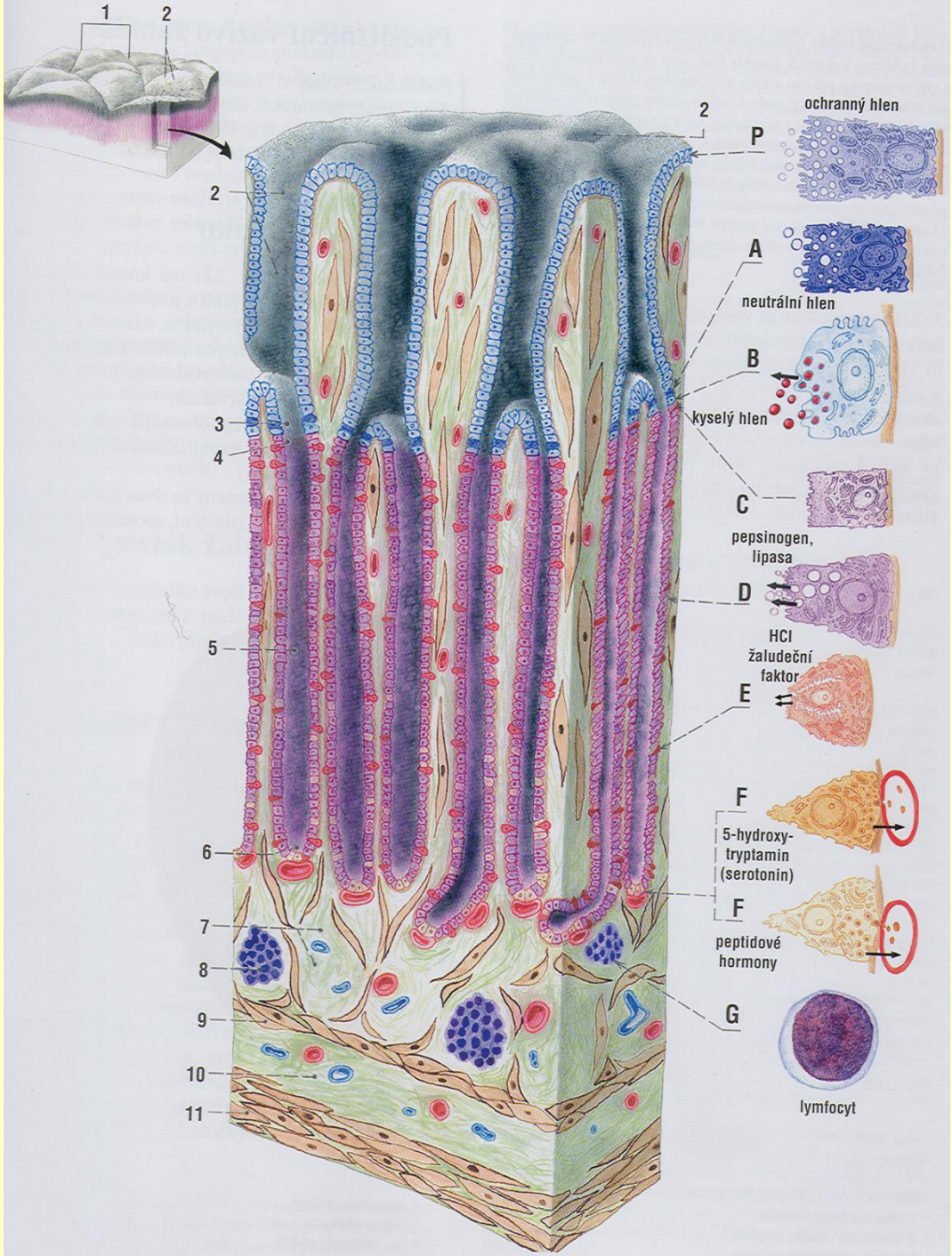
1
2
2
2
3
4
5
6
7
8
9
10
11
P
ochranný hlen
A
neutrální hlen
B
kyselý hlen
C
pepsinogen,
lipasa
D
HCl
žaludeční
faktor
E
F
5-hydroxy-
tryptamin
(serotonin)
F
peptidové
hormony
G
lymfocyt

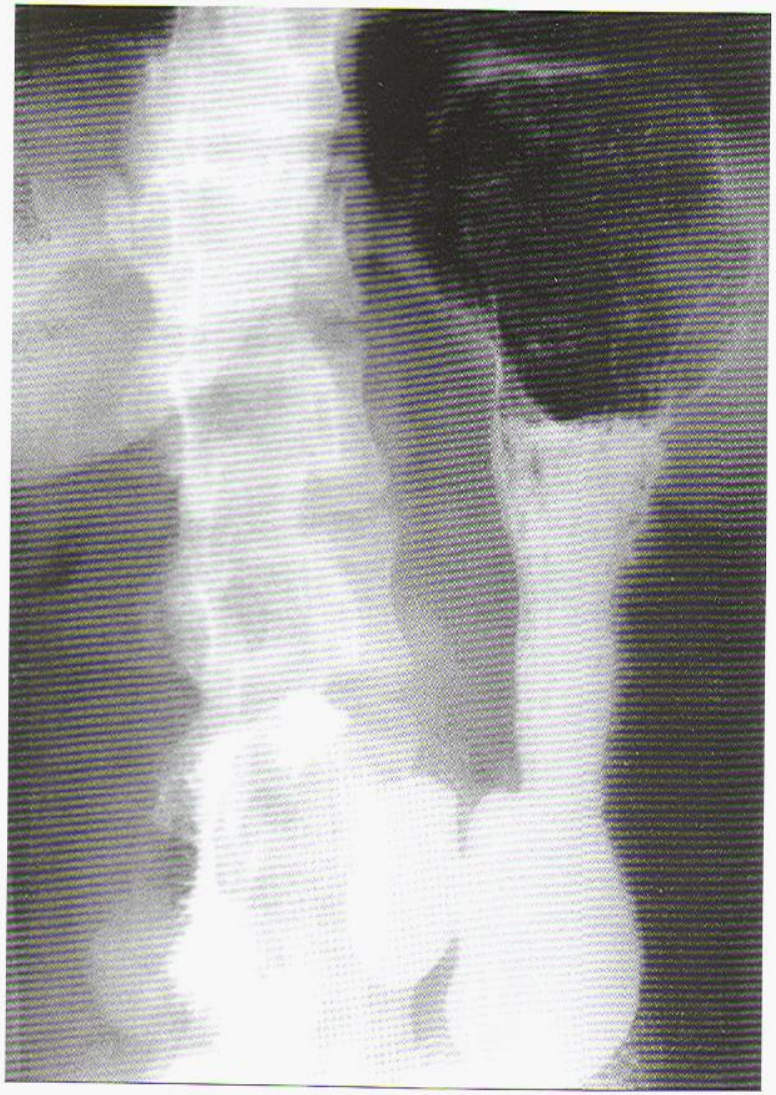

A



D

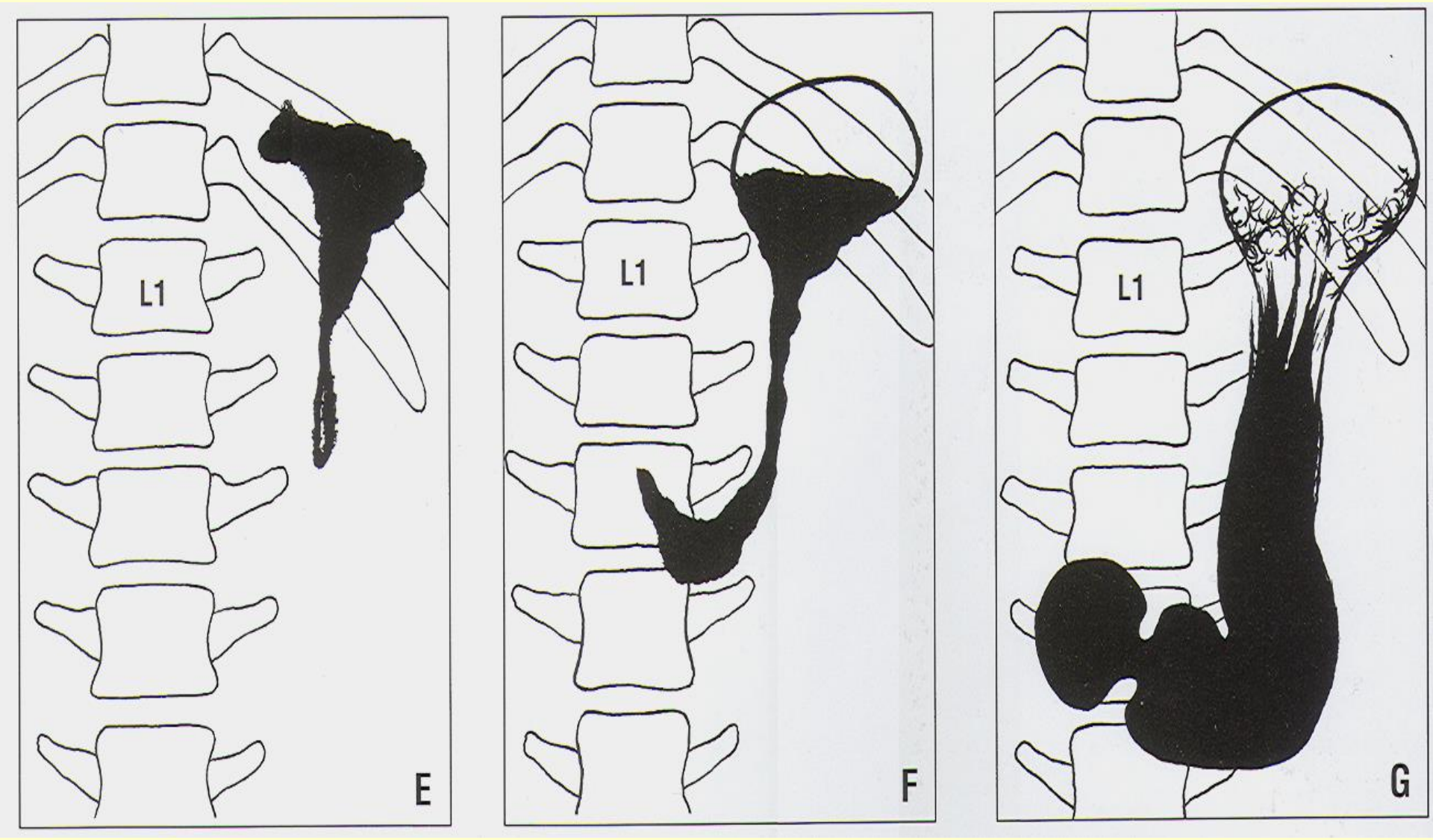
L1
E
L1
F
L1
G

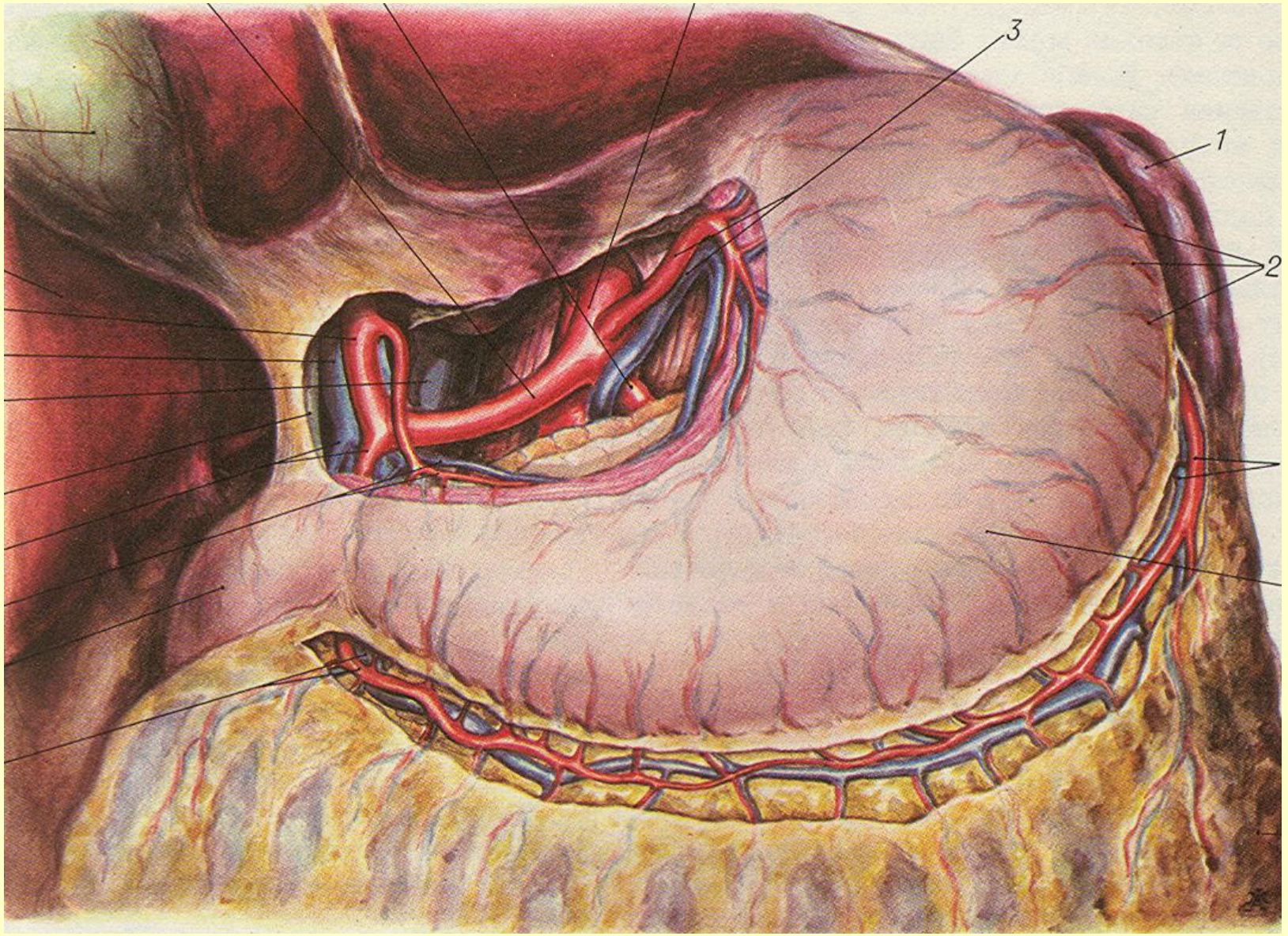
3
1
2

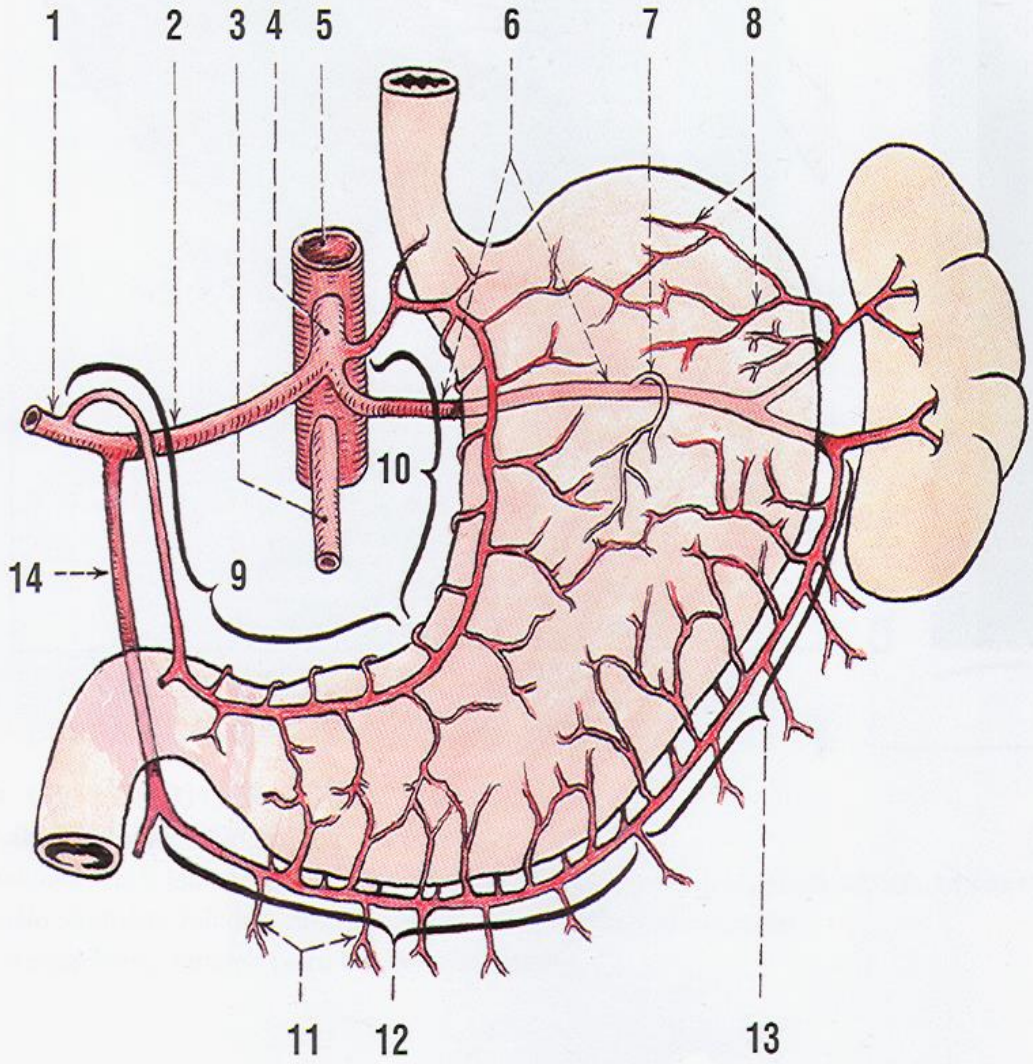

Obr. 56 A. TEPNY ŽALUDKU; schéma

1 a. hepatica propria
2 a. hepatica communis
3 a. mesenterica superior
4 truncus coeliacus
5 aorta abdominalis
6 a. splenica (a. lienalis)
7 a. gastrica posterior
8 aa. gastricae breves
9 a. gastrica dextra
10 a. gastrica sinistra
11 rr. omentales arteriae gastroomentalis (gastroep
ploicae) dextrae
12 a. gastroomentalis (gastroepiploica) dextra
13 a. gastroomentalis (gastroepiploica) sinistra
14 a. gastroduodenalis

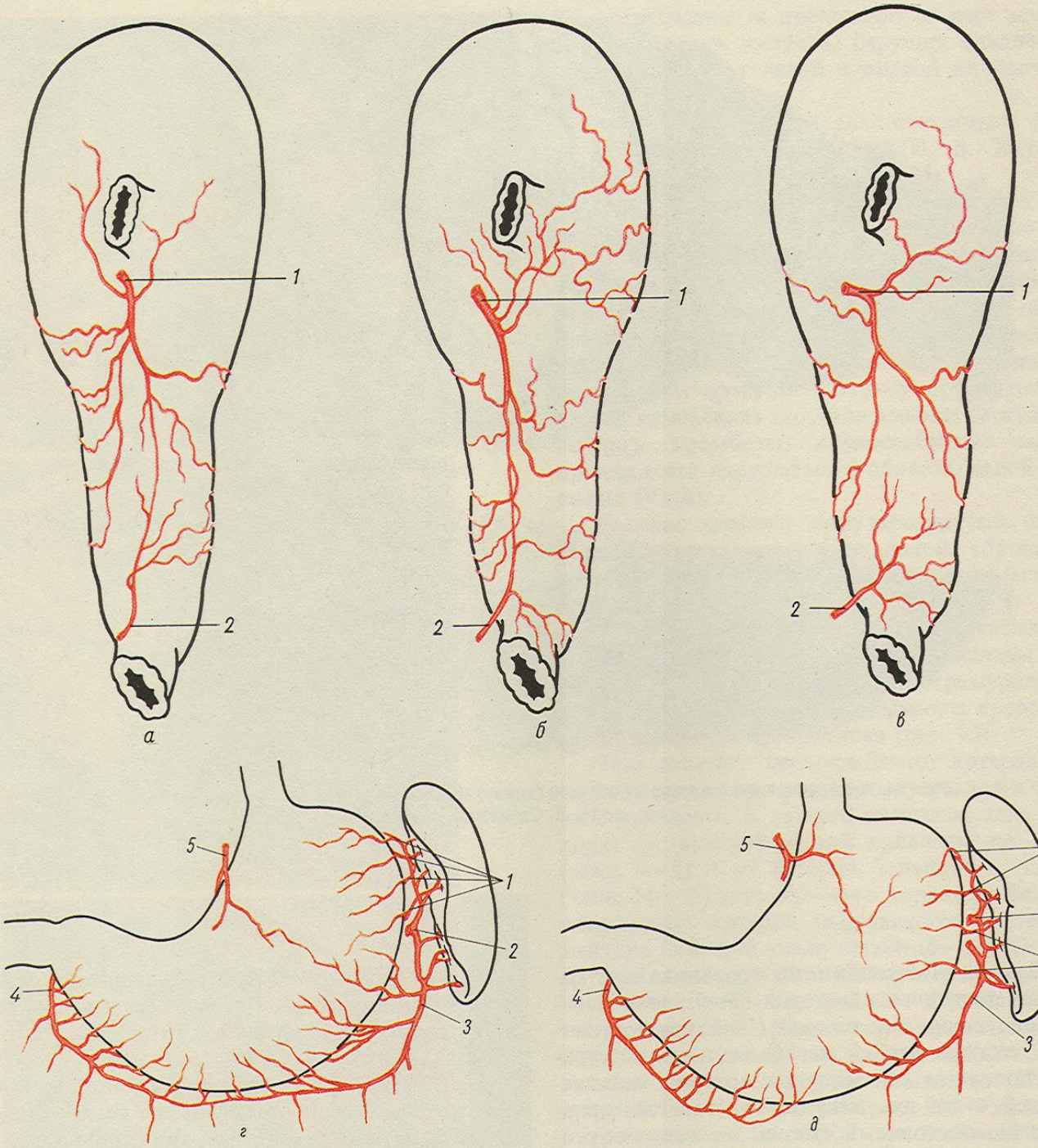
1
2
а
1
2
б
1
2
в
5
1
2
4
3
г
5
1
2
1
4
3
д

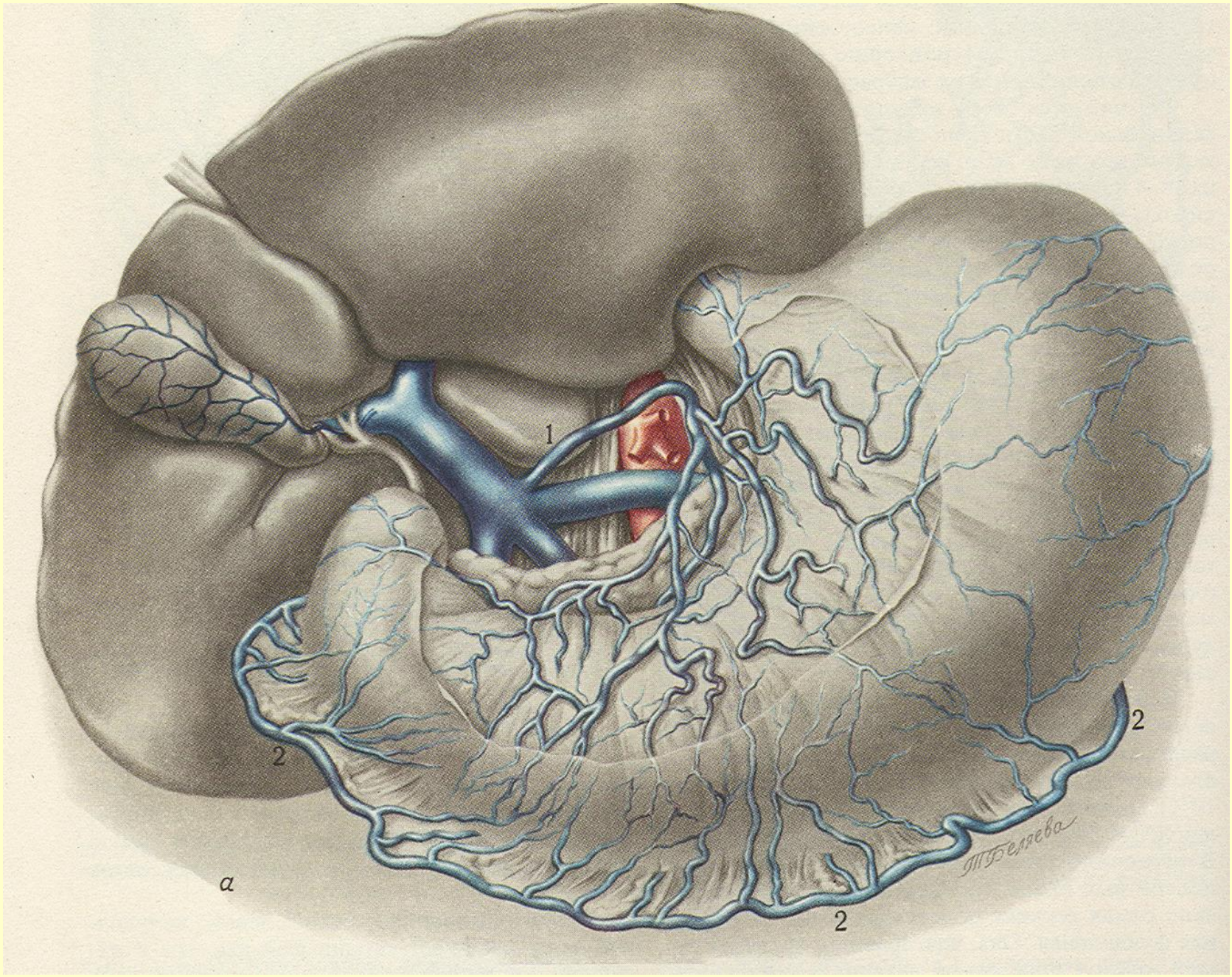
1
2
2
2
а

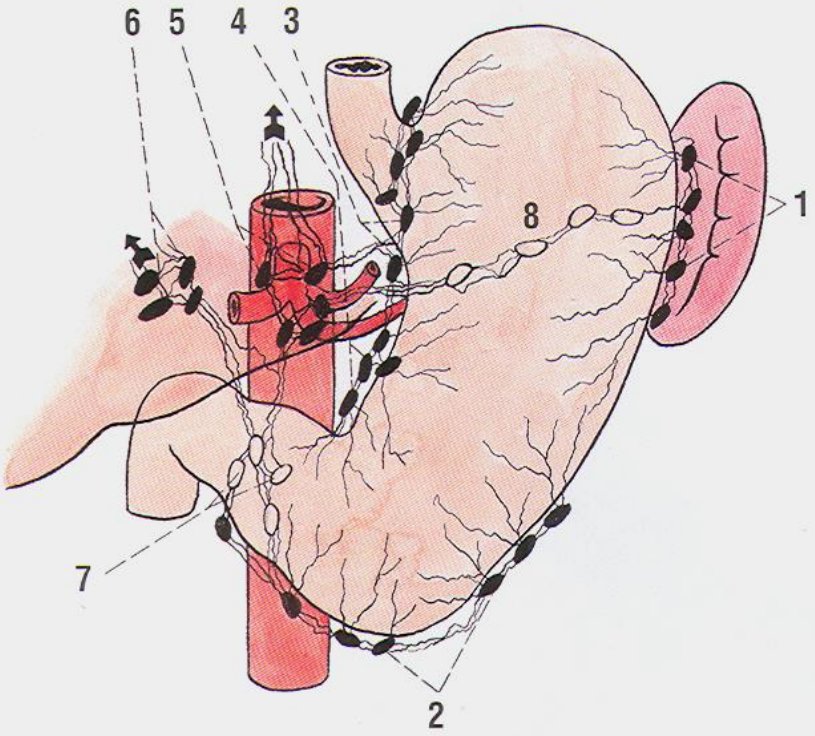

Obr. 57. MÍZNÍ CÉVY A UZLINY ŽALUDKU; schéma
1 nodi gastroomentales (gastroepiploici) sinistri
2 nodi gastroomentales (gastroepiploici) dextri
3 nodi gastrici sinistri
4 nodi gastrici dextri
5 nodi coeliaci (směr dalšího toku mízy označen šipkou)
6 nodi hepatici
7 nodi pylorici
8 nodi pancreatici superiores (pancreaticosplenici)

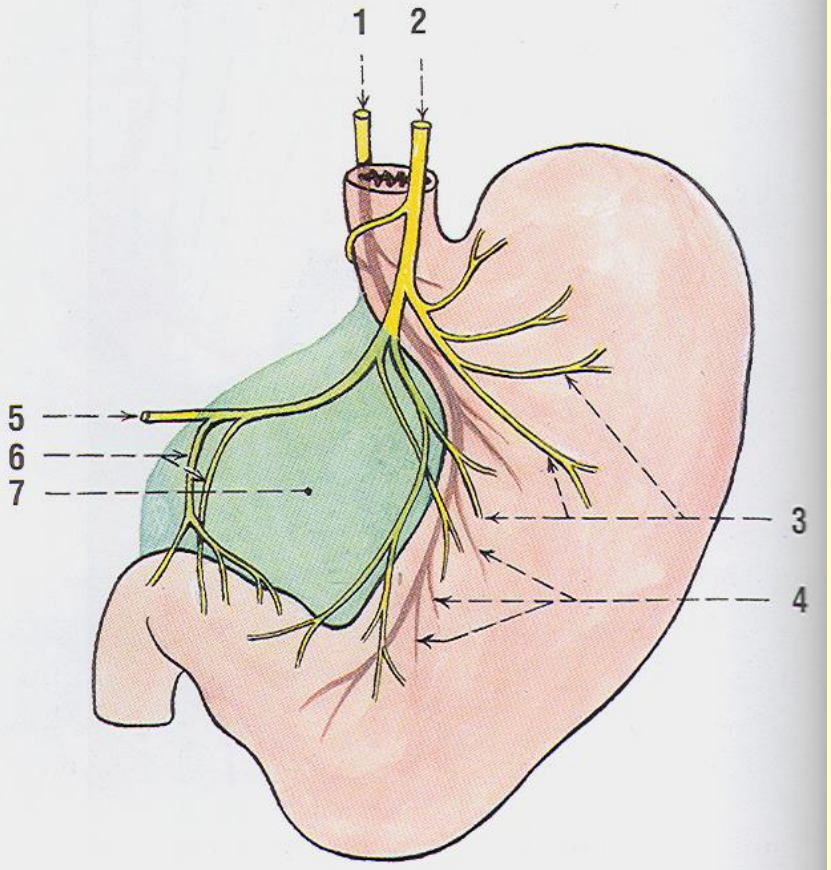

Obr. 58. PARASYMPATICKÉ NERVY ŽALUDKU; schéma
1 truncus vagalis posterior
2 truncus vagalis anterior
3 rr. gastrici anteriores
4 rr. gastrici posteriores
5 větev pro rr. hepatici
6 rr. pylorici
7 omentum minus

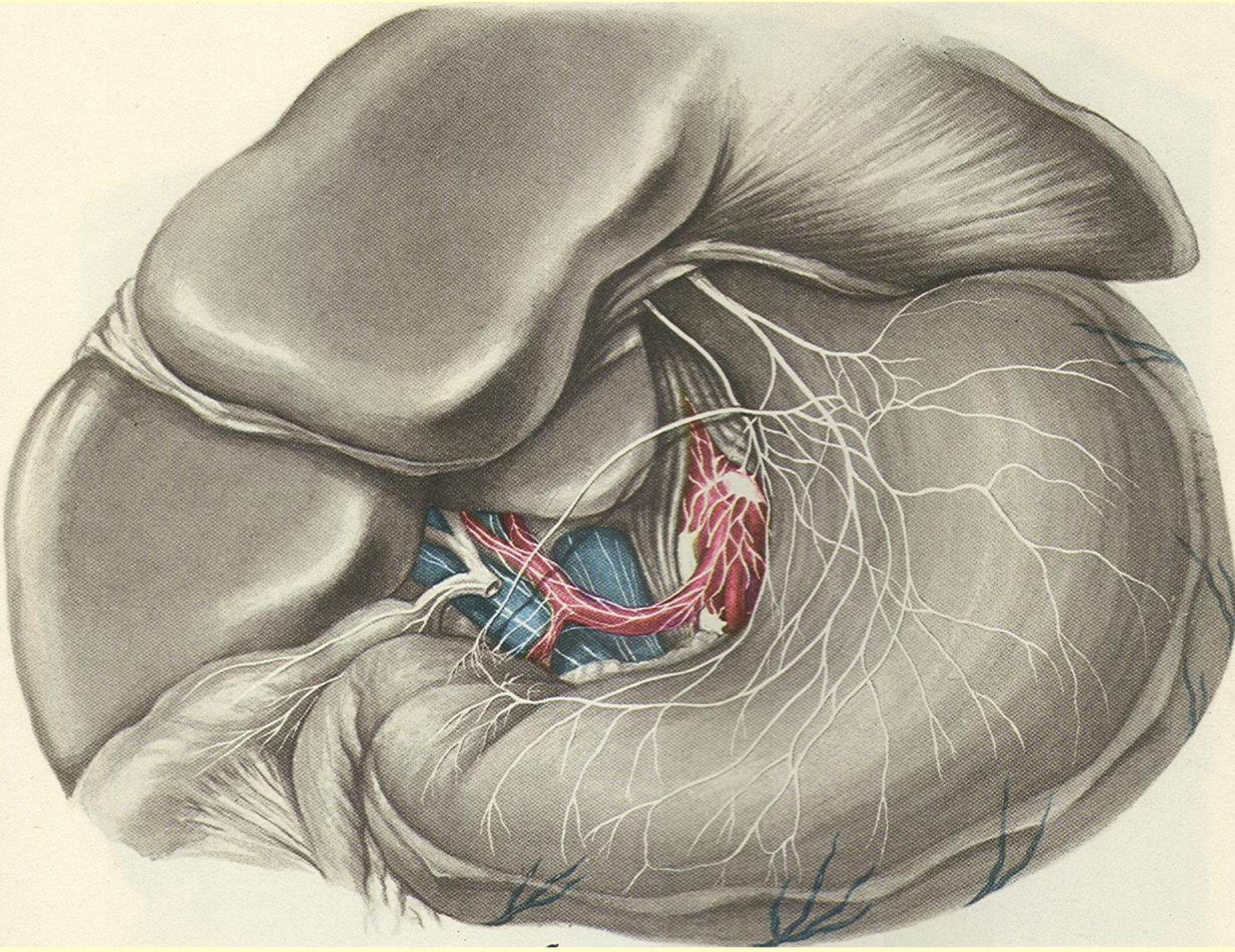

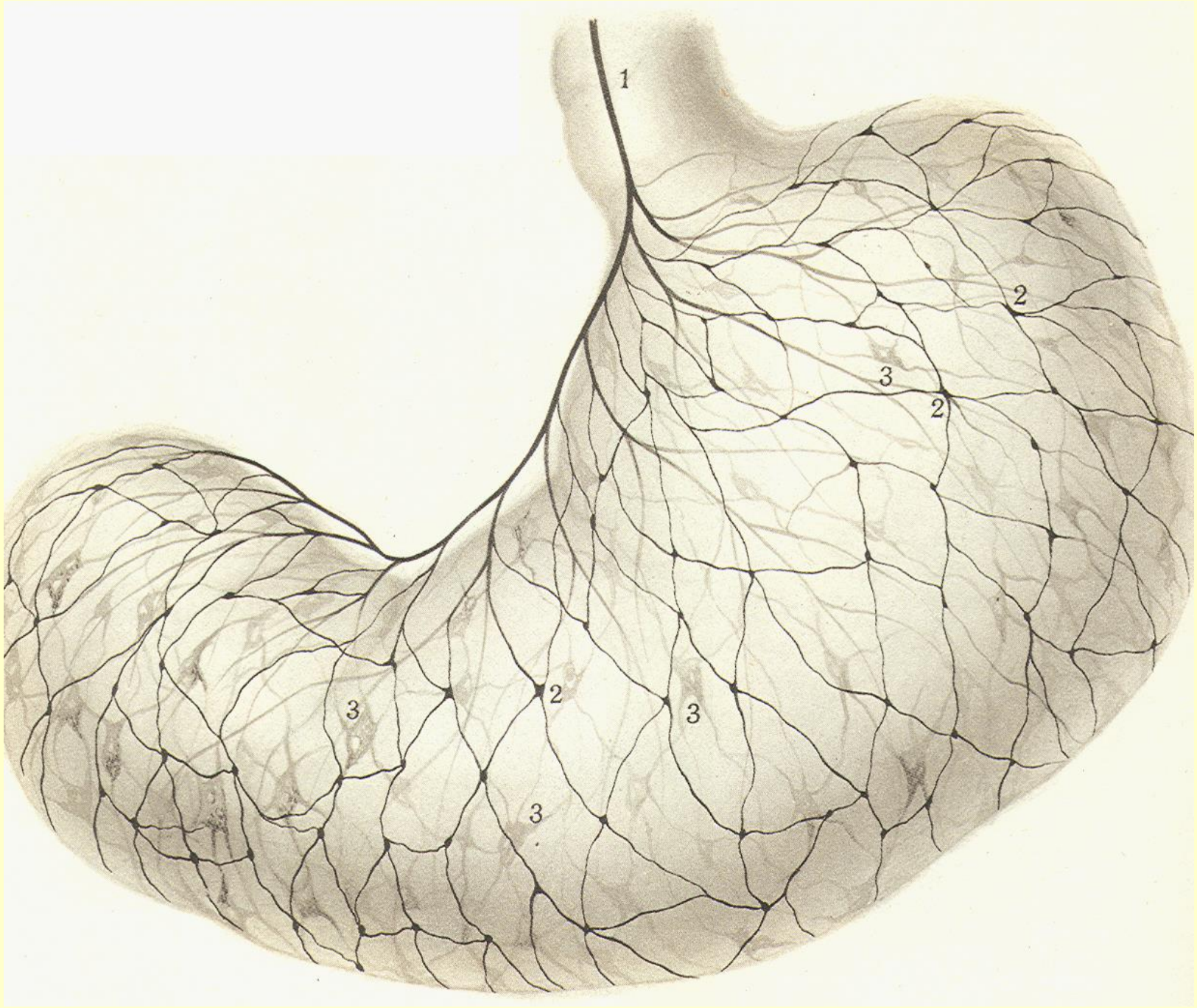
1
2
3
2
3
2
3
3

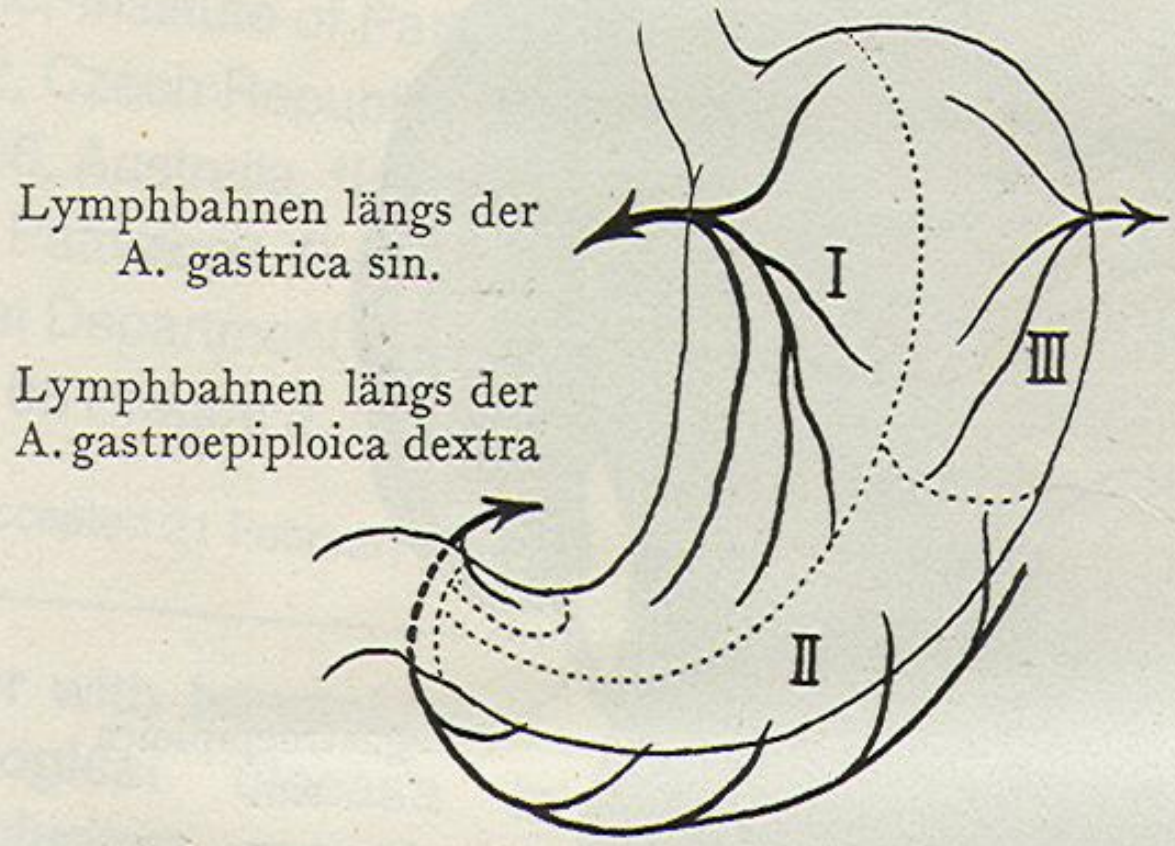

Abb. 310. Lymphgefässgebiete am Magen und Abflusswege derselben.

Schema nach Cuneo und Delamare.

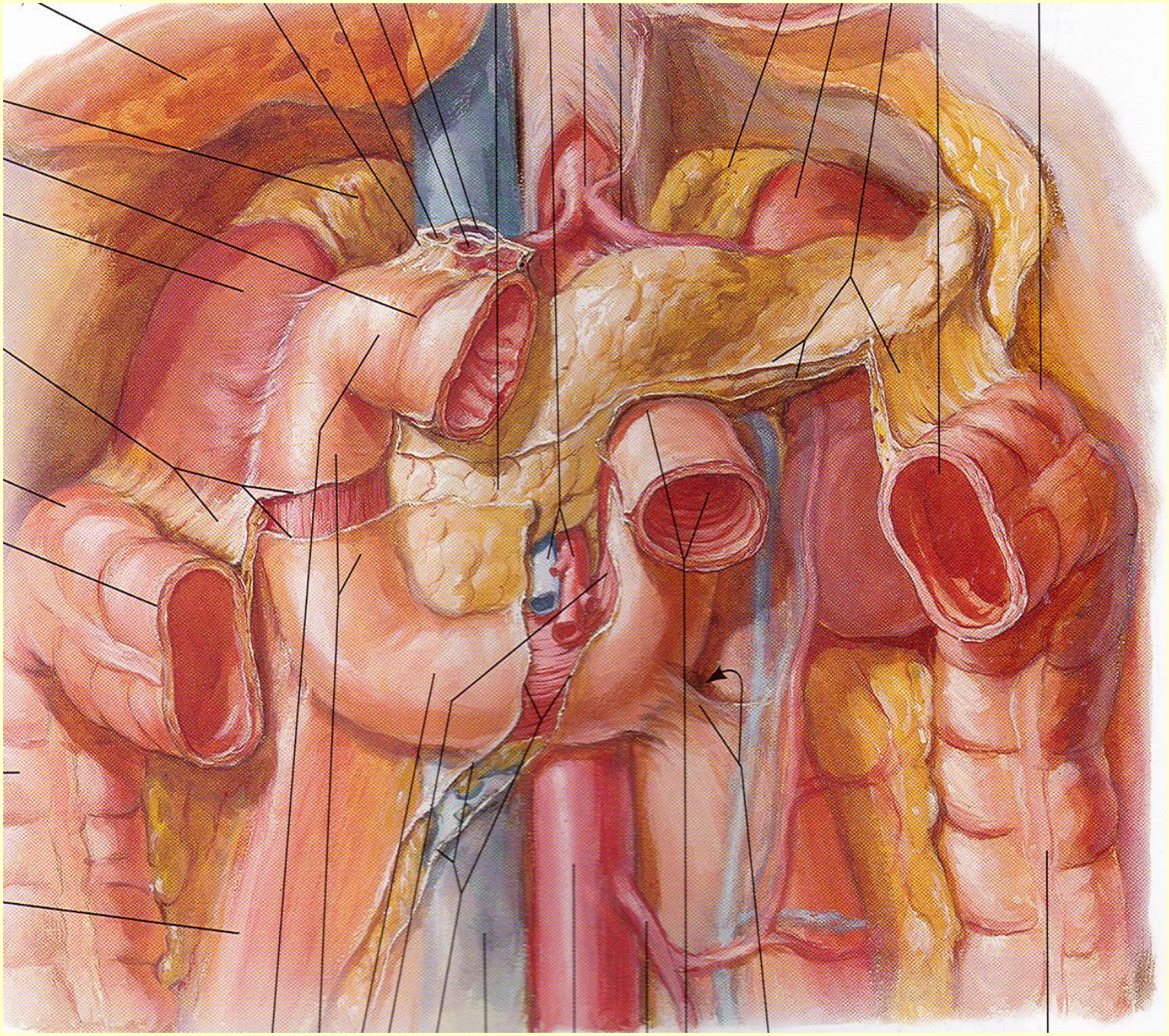

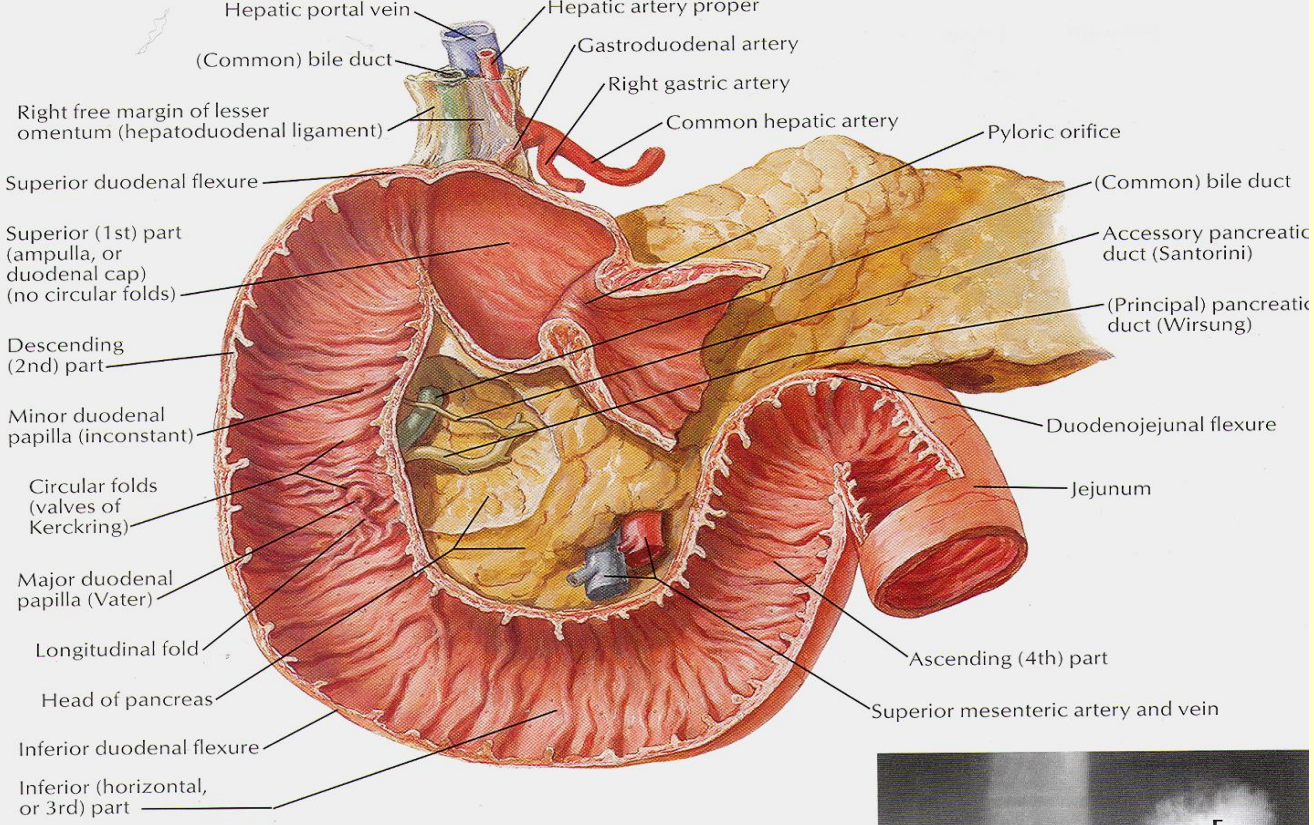

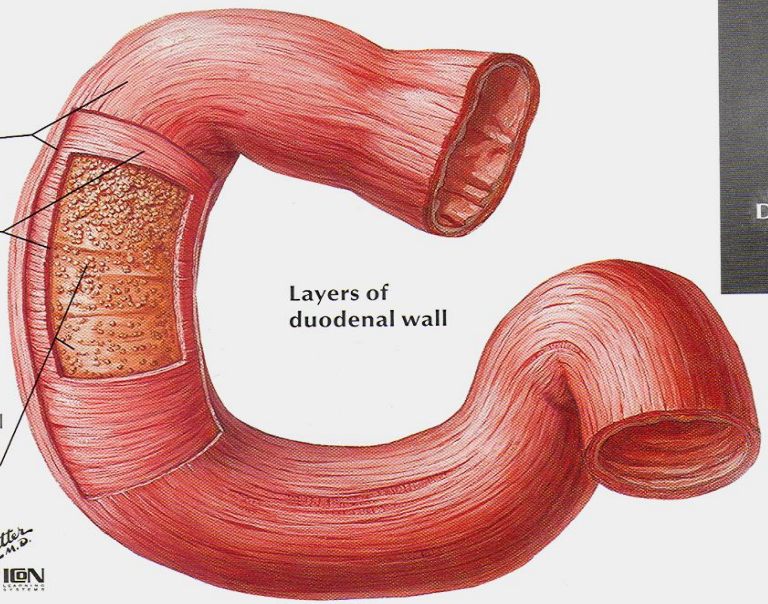

Layers of duodenal wall

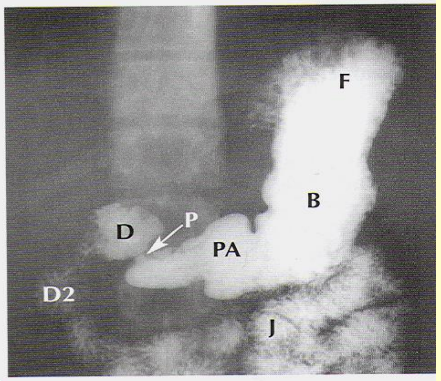

Barium radiograph of stomach, duodenum and proximal jejunum

- **B** Body of stomach
- **D** Duodenal cap
- **D2** Descending (2nd) part of duodenum
- **F** Fundus of stomach
- **J** Proximal jejunum
- **P** Pylorus
- **PA** Pyloric antrum

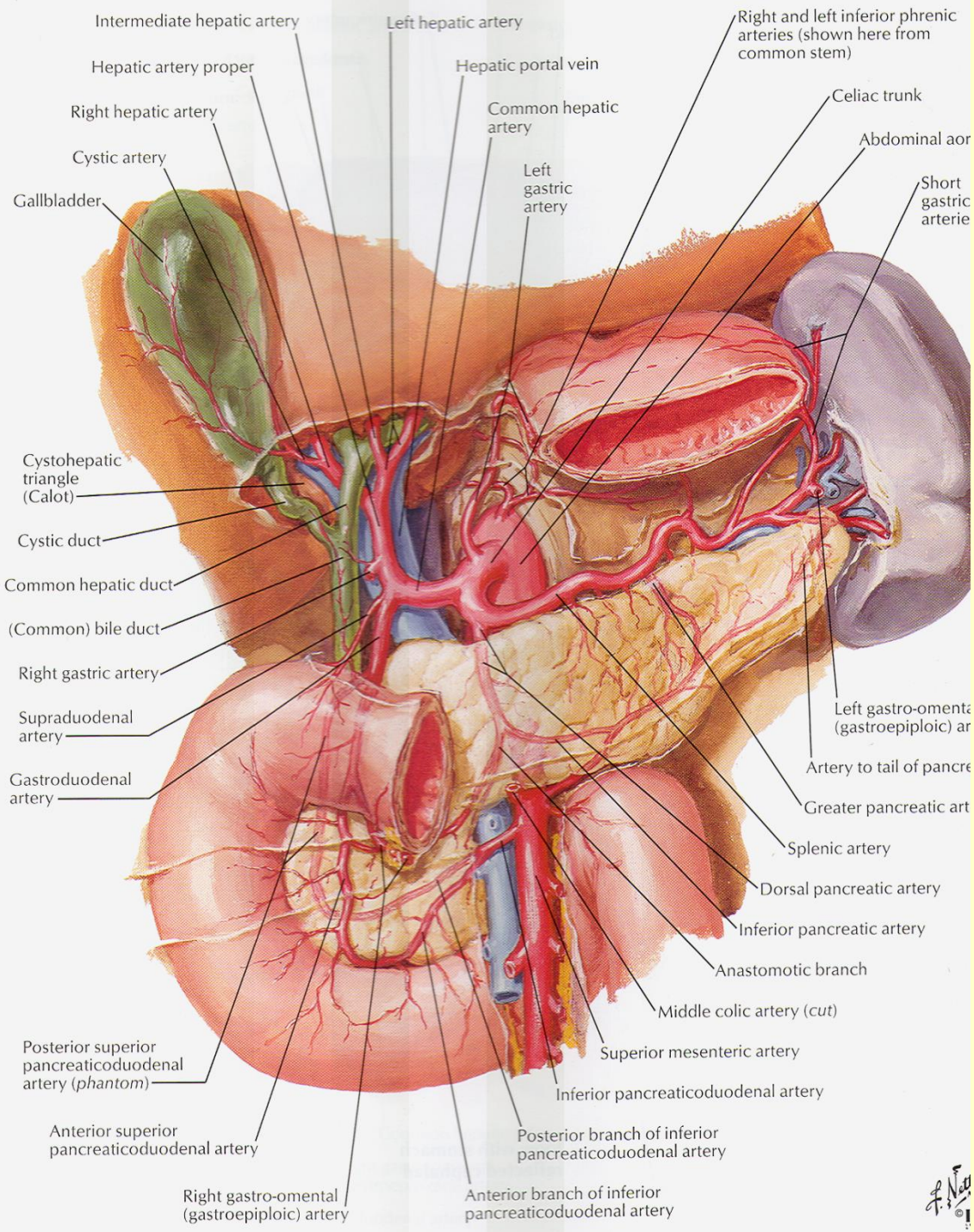
Intermediate hepatic artery
Left hepatic artery
Right and left inferior phrenic arteries (shown here from common stem)
Hepatic artery proper
Hepatic portal vein
Celiac trunk
Right hepatic artery
Common hepatic artery
Abdominal aor
Cystic artery
Left gastric artery
Short gastric arterie
Gallbladder
Cystohepatic triangle (Calot)
Cystic duct
Common hepatic duct
(Common) bile duct
Right gastric artery
Supraduodenal artery
Gastroduodenal artery
Left gastro-omenta (gastroepiploic) ar
Artery to tail of pancre
Greater pancreatic art
Splenic artery
Dorsal pancreatic artery
Inferior pancreatic artery
Anastomotic branch
Middle colic artery (cut)
Posterior superior pancreaticoduodenal artery (phantom)
Superior mesenteric artery
Inferior pancreaticoduodenal artery
Anterior superior pancreaticoduodenal artery
Posterior branch of inferior pancreaticoduodenal artery
Right gastro-omental (gastroepiploic) artery
Anterior branch of inferior pancreaticoduodenal artery

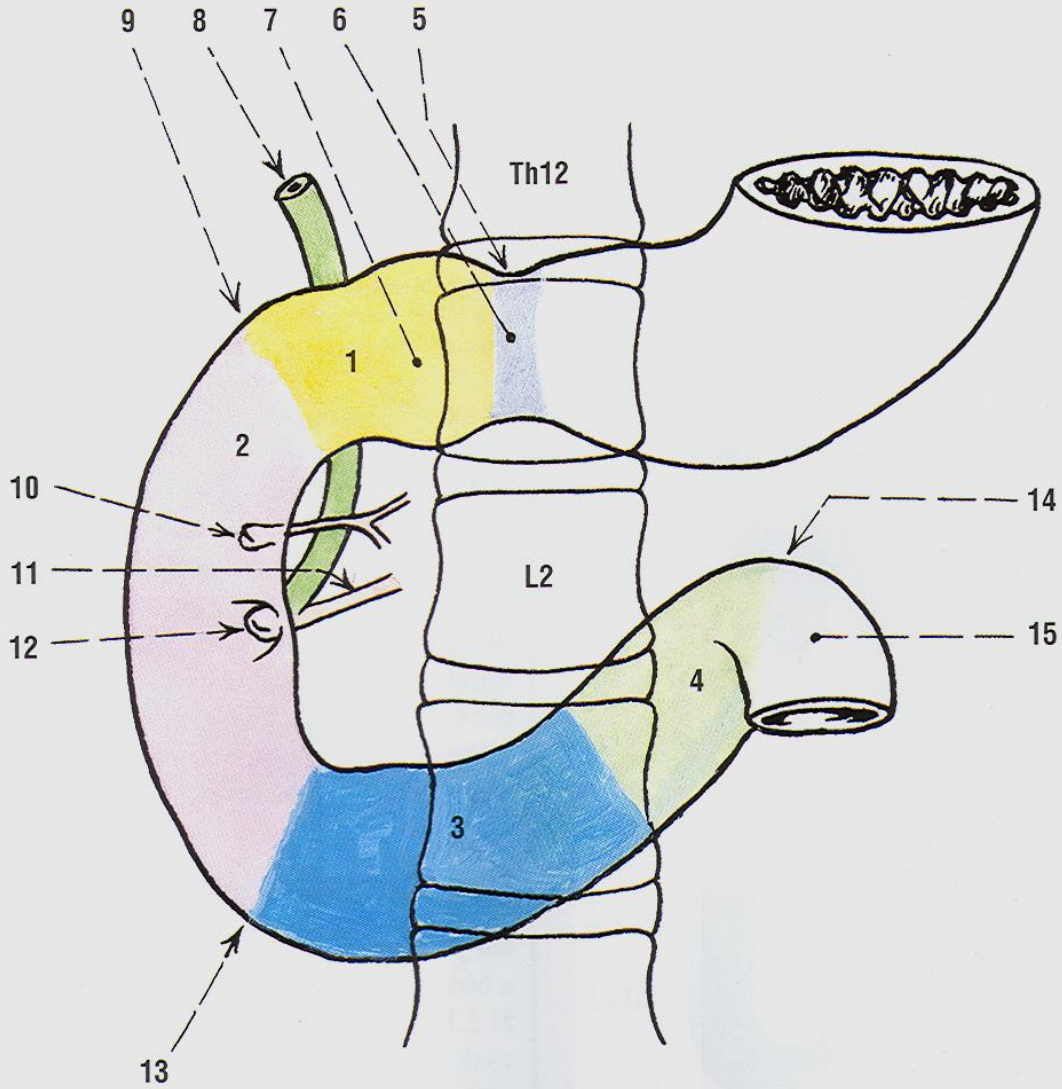

Obr. 64. ROZDĚLENÍ DUODENA PODLE PRŮBĚHU; schéma

1 pars superior
2 pars descendens
3 pars horizontalis
4 pars ascendens
5 hranice žaludku a bulbu duodena
6 pylorus
7 bulbus duodeni
8 ductus choledochus
9 flexura duodeni superior
10 papilla duodeni minor (ústí ductus pancreaticus accessorius)
11 ductus pancreaticus
12 papilla duodeni major s ústím ductus choledochus a ductus pancreaticus
13 flexura duodeni inferior
14 flexura duodenojejunalis
15 začátek jejuna

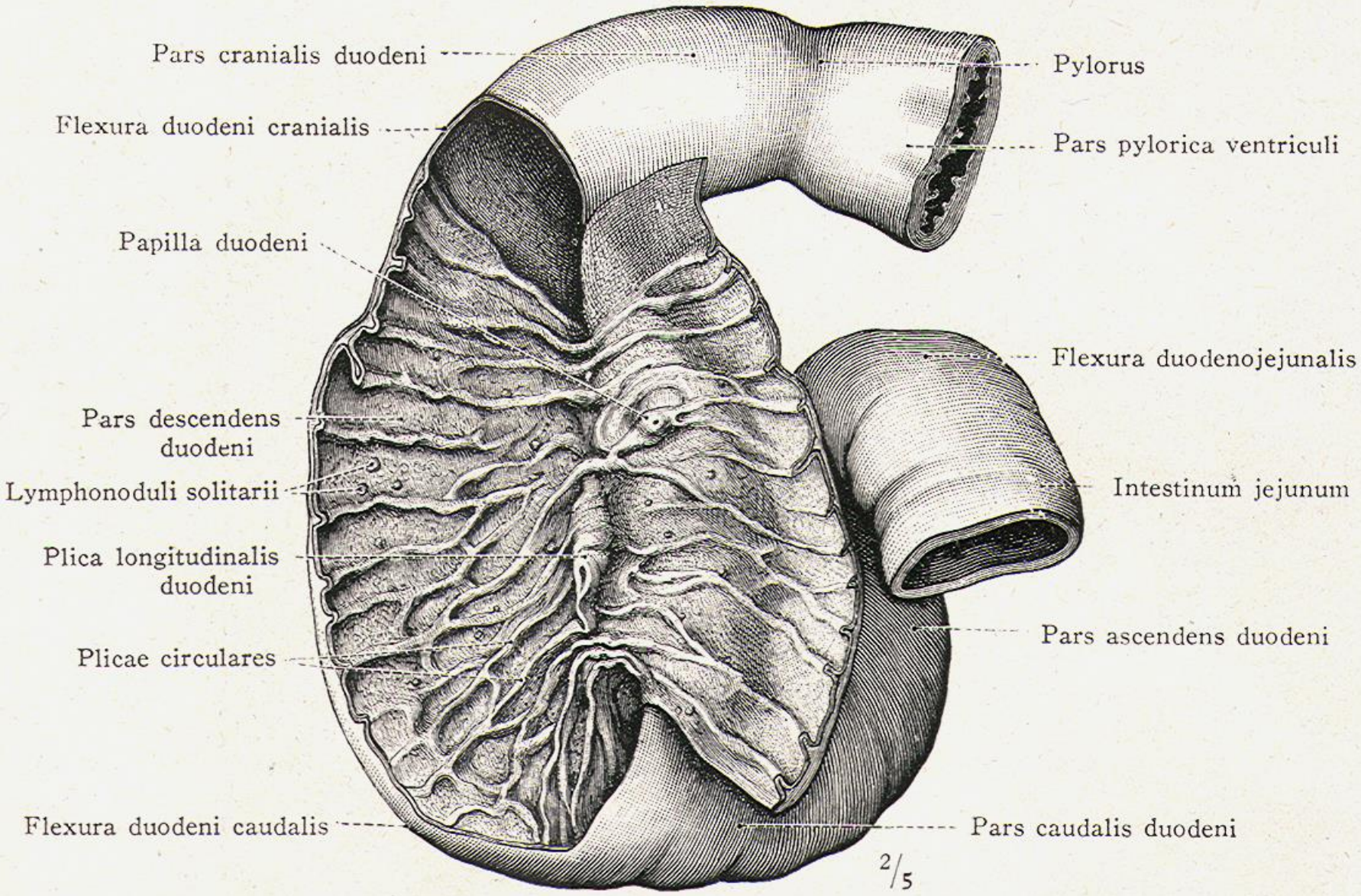
Pars cranialis duodeni
Flexura duodeni cranialis
Papilla duodeni
Pars descendens duodeni
Lymphonoduli solitarii
Plica longitudinalis duodeni
Plicae circulares
Flexura duodeni caudalis
Pylorus
Pars pylorica ventriculi
Flexura duodenojejunalis
Intestinum jejunum
Pars ascendens duodeni
Pars caudalis duodeni
2/5

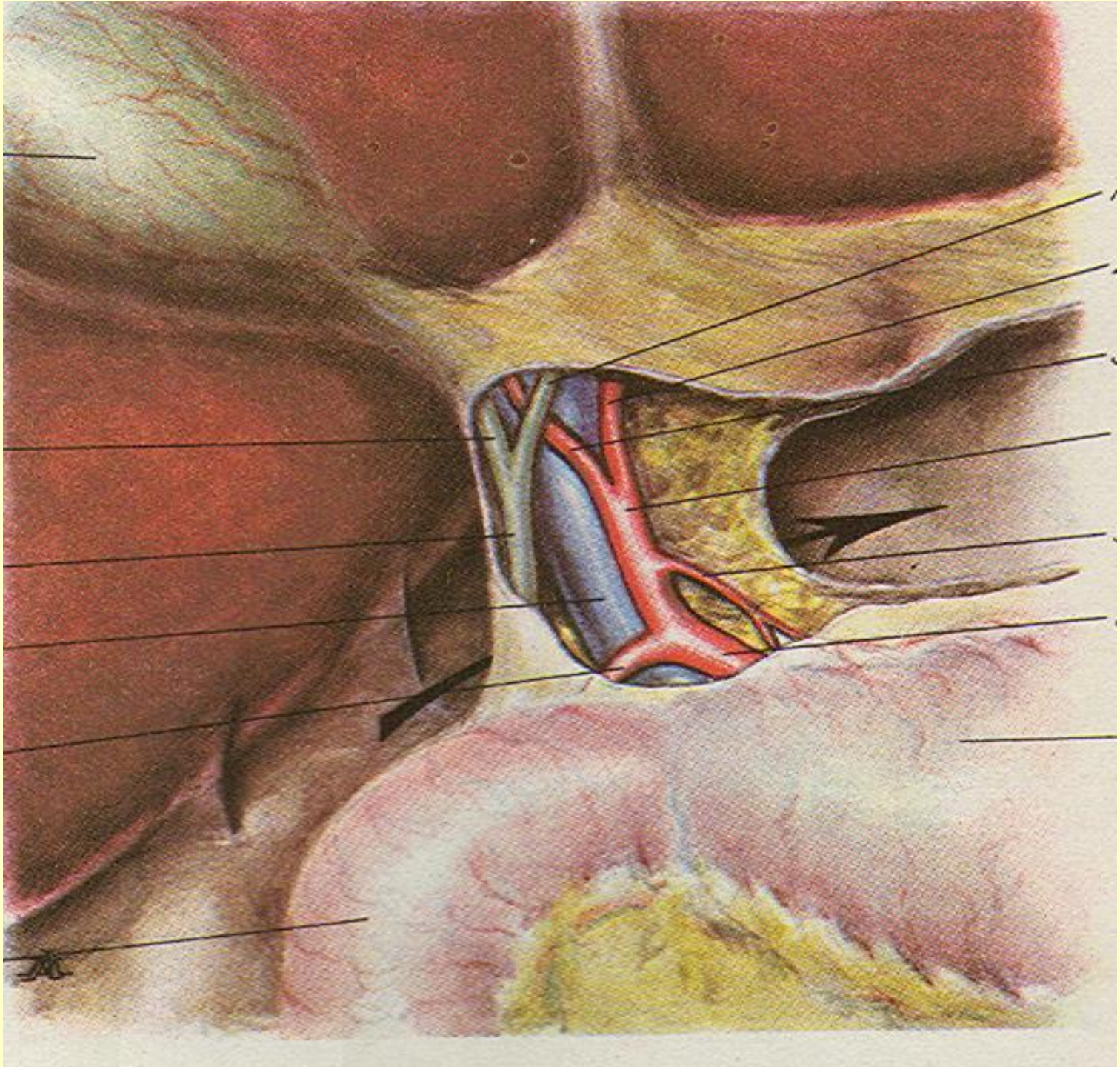

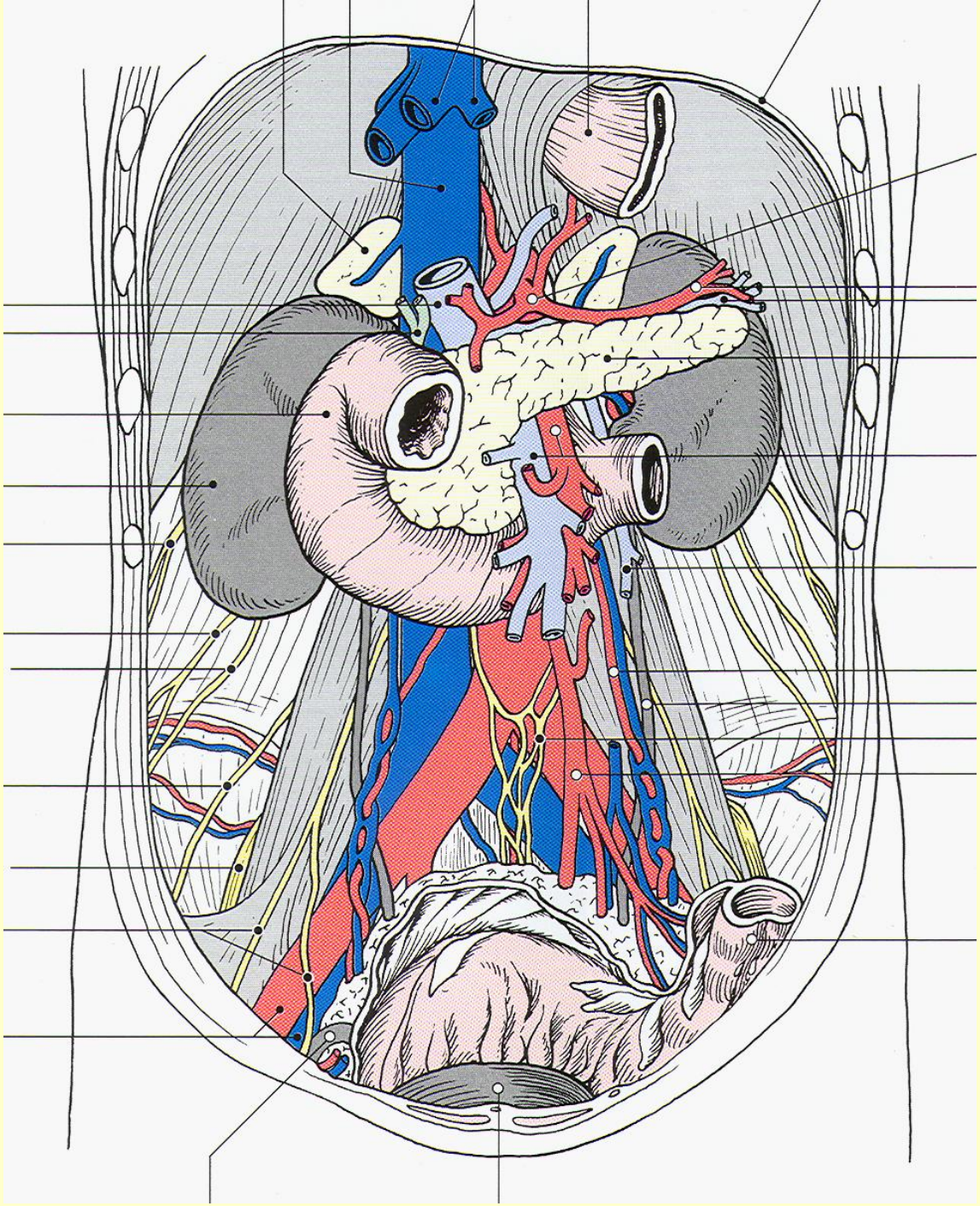

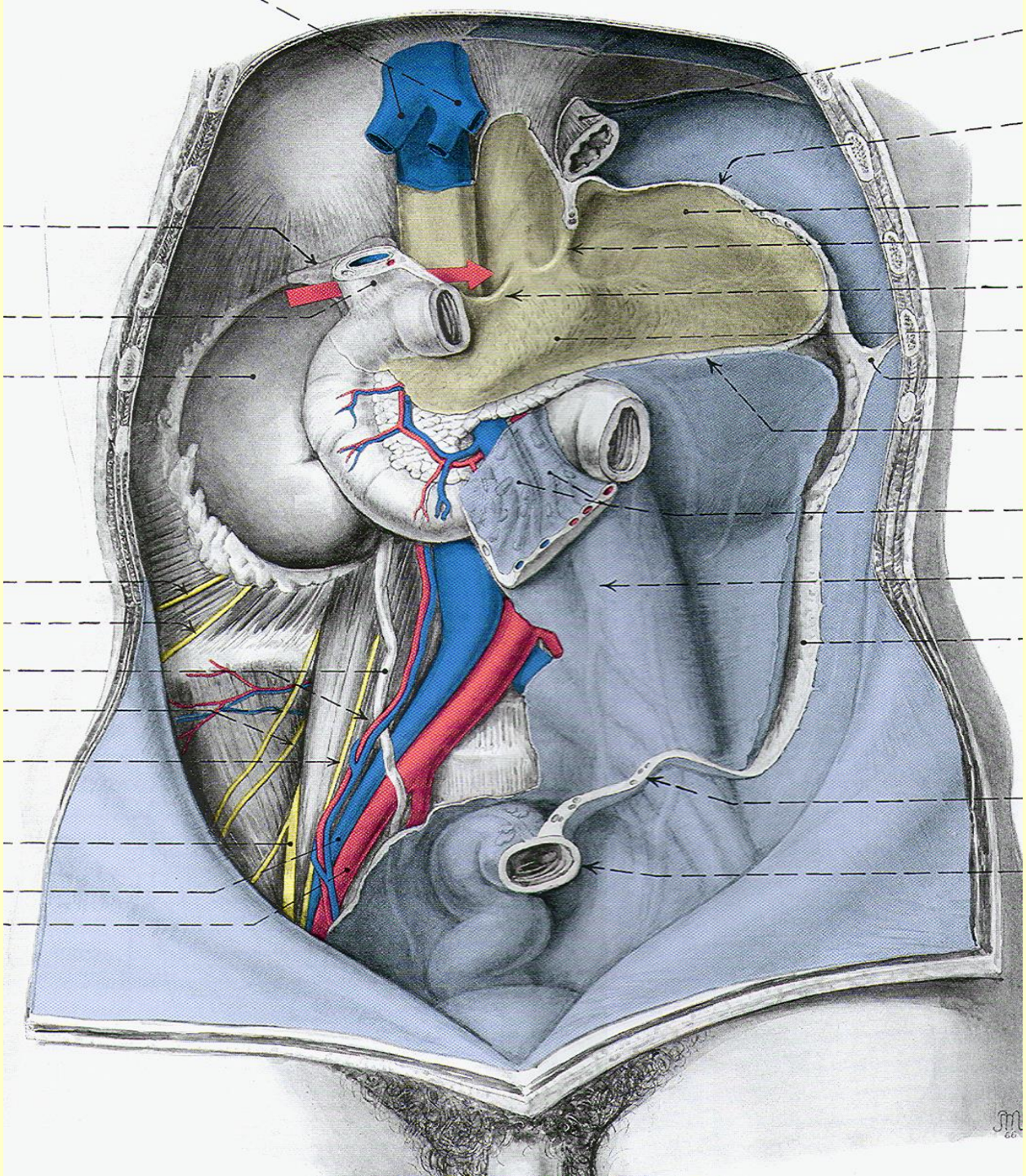

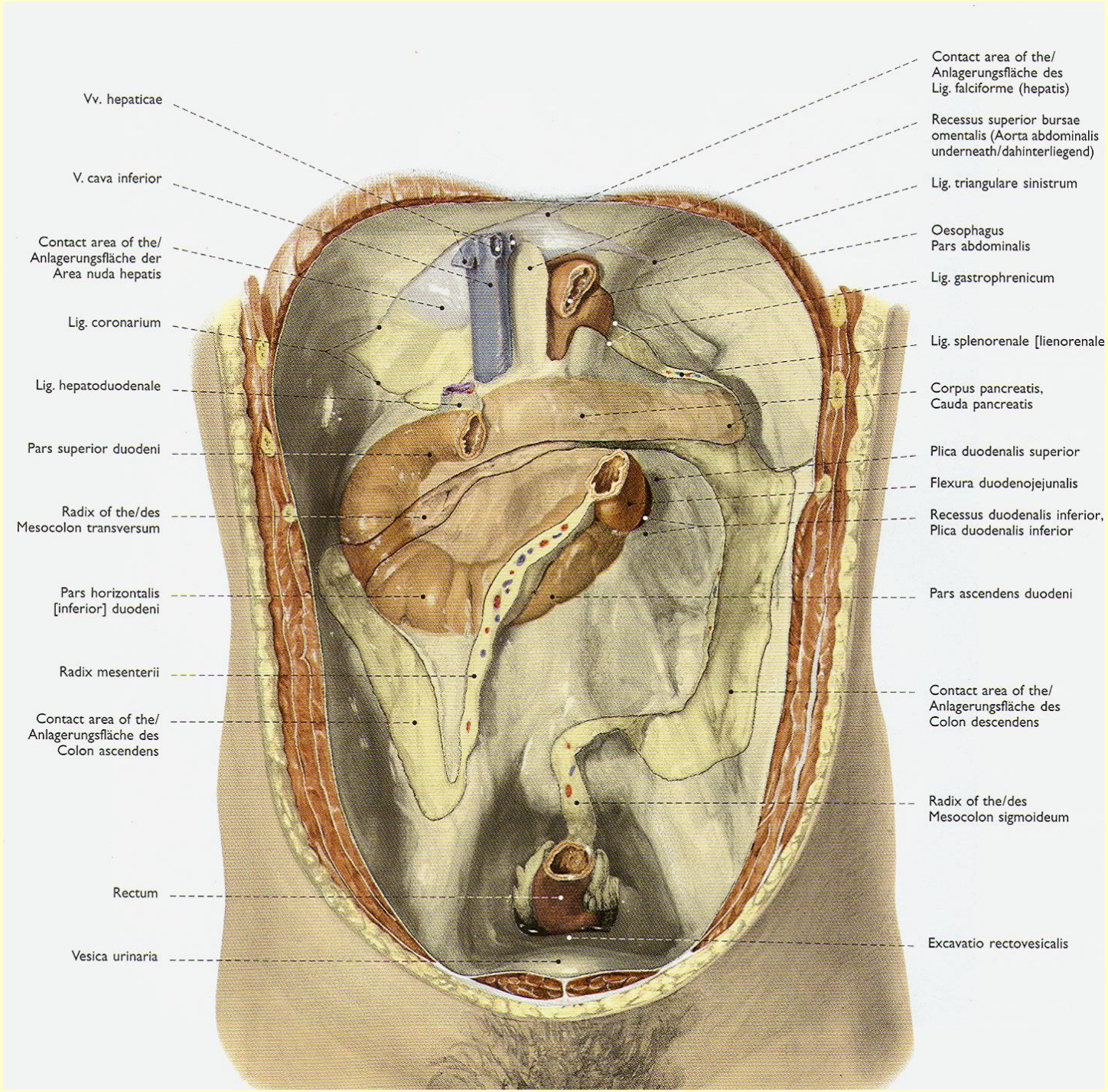
Vv. hepaticae
V. cava inferior
Contact area of the/
Anlagerungsfläche der
Area nuda hepatis
Lig. coronarium
Lig. hepatoduodenale
Pars superior duodeni
Radix of the/des
Mesocolon transversum
Pars horizontalis
[inferior] duodeni
Radix mesenterii
Contact area of the/
Anlagerungsfläche des
Colon ascendens
Rectum
Vesica urinaria
Contact area of the/
Anlagerungsfläche des
Lig. falciforme (hepatis)
Recessus superior bursae
omentalis (Aorta abdominalis
underneath/dahinterliegend)
Lig. triangulare sinistrum
Oesophagus
Pars abdominalis
Lig. gastrophrenicum
Lig. splenorenale [lienorenale
Corpus pancreatis,
Cauda pancreatis
Plica duodenalis superior
Flexura duodenojejunalis
Recessus duodenalis inferior,
Plica duodenalis inferior
Pars ascendens duodeni
Contact area of the/
Anlagerungsfläche des
Colon descendens
Radix of the/des
Mesocolon sigmoideum
Excavatio rectovesicalis

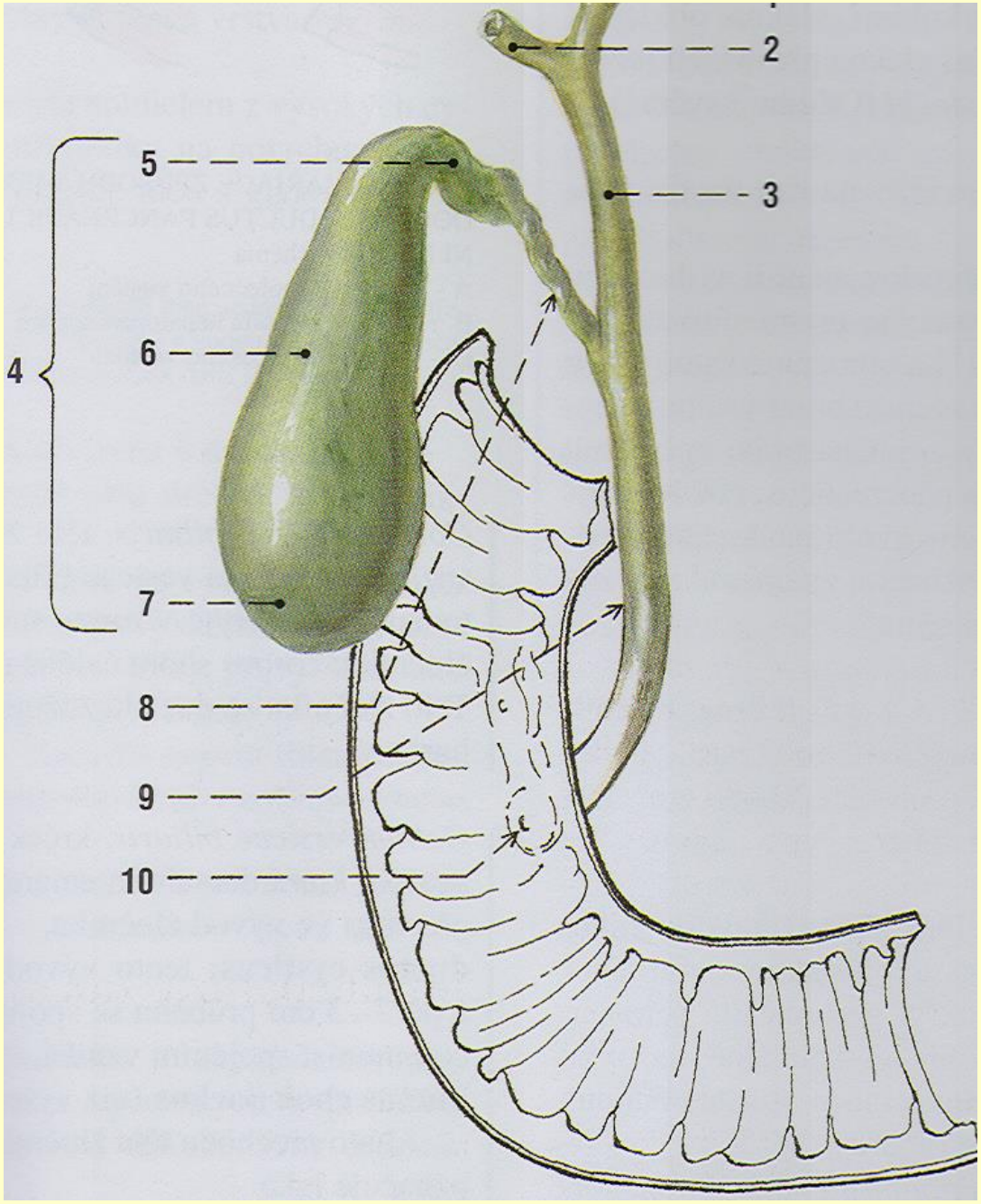
2
5
3
4
6
7
8
9
10

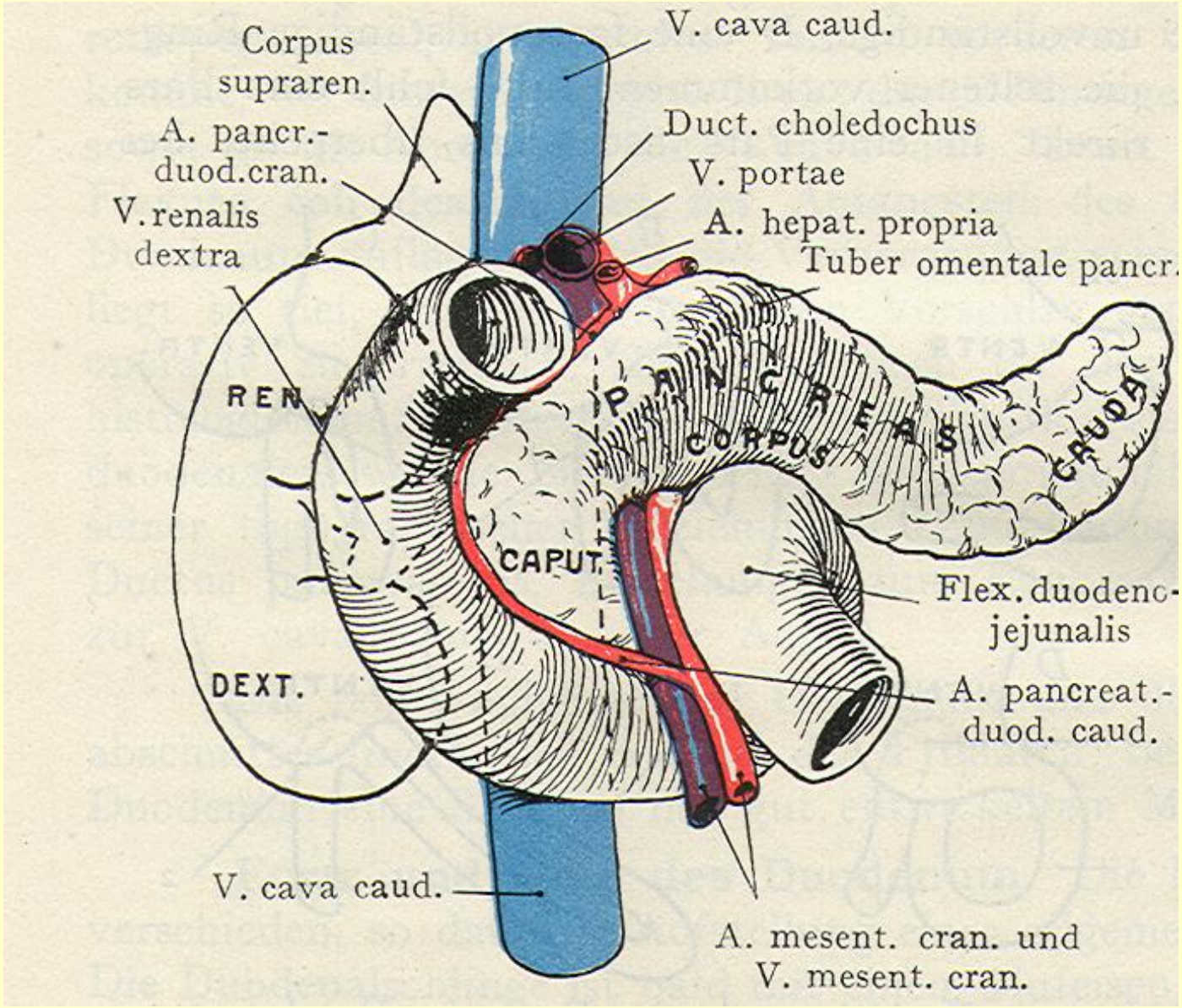
Corpus
supraren.
A. pancr.-
duod.cran.
V. renalis
dextra
V. cava caud.
Duct. choledochus
V. portae
A. hepat. propria
Tuber omentale pancr.
REN
DEXT.
PANCREAS
CORPUS
CAUDA
CAPUT
Flex. duodeno-
jejunalis
A. pancreat.-
duod. caud.
V. cava caud.
A. mesent. cran. und
V. mesent. cran.

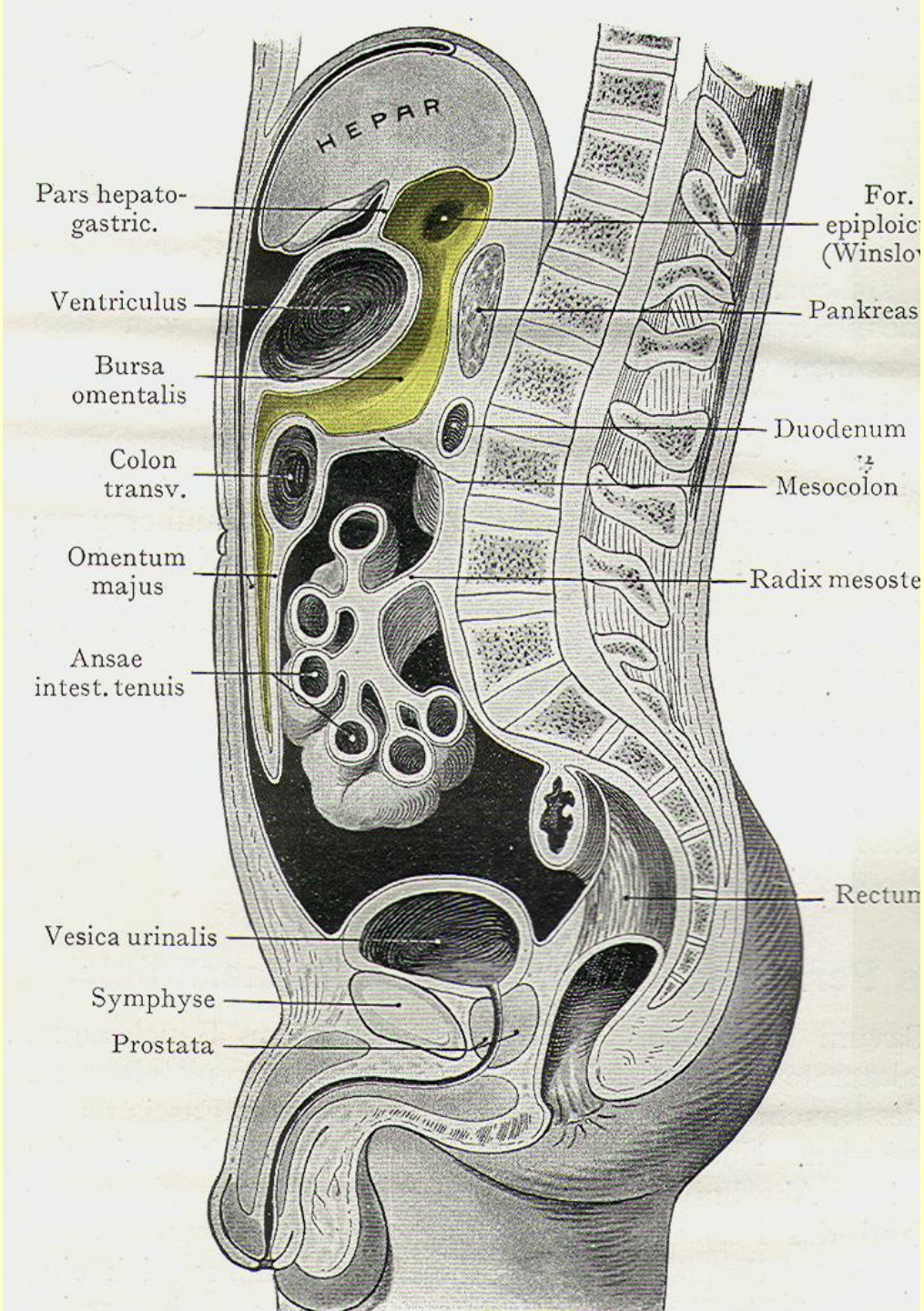
HEPAR
Pars hepato-gastric.
Ventriculus
Bursa omentalis
Colon transv.
Omentum majus
Ansae intest. tenuis
Vesica urinalis
Symphyse
Prostata
For. epiploic (Winslo
Pankreas
Duodenum
Mesocolon
Radix mesoste
Rectum

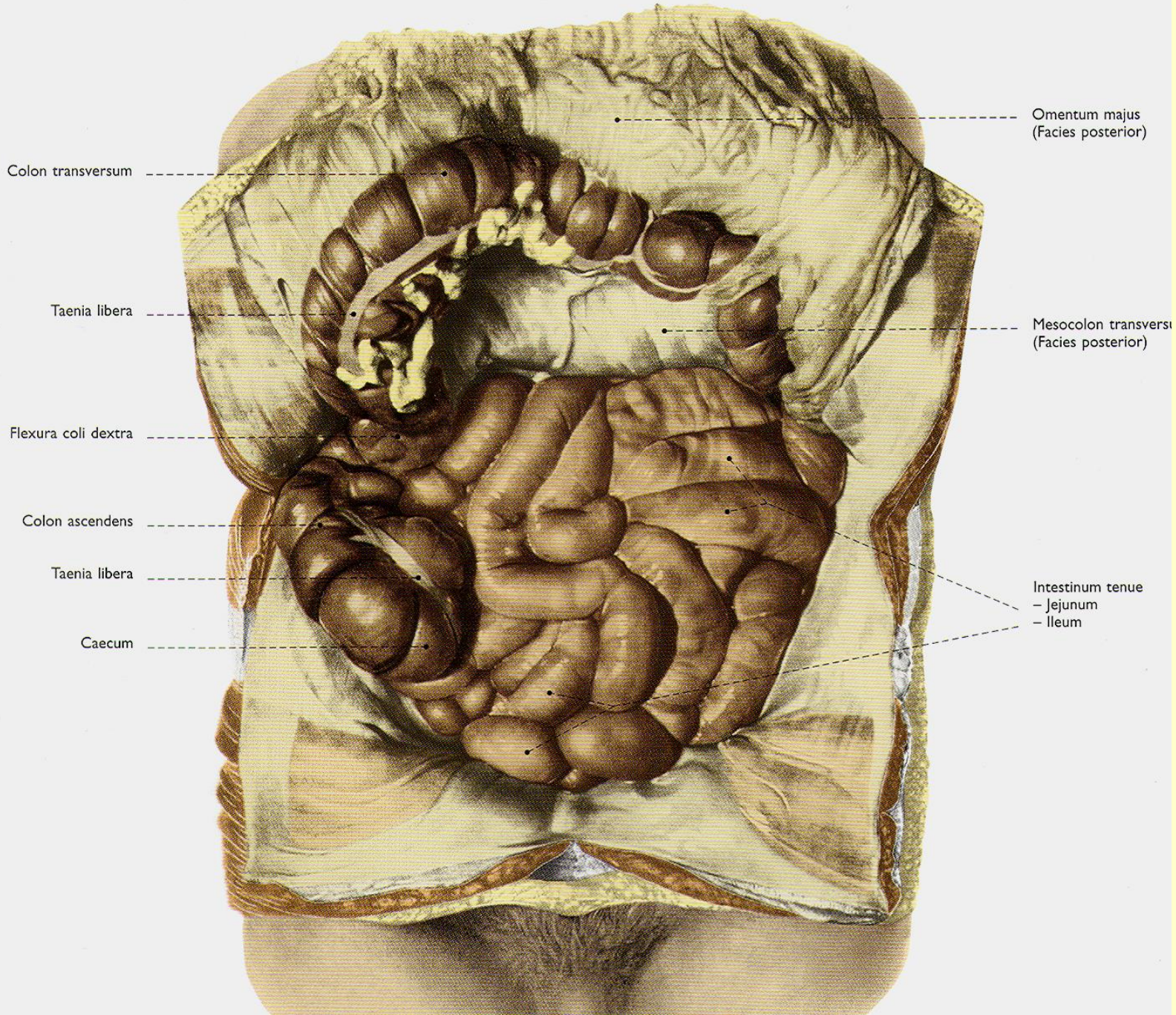
Omentum majus
(Facies posterior)
Colon transversum
Taenia libera
Mesocolon transversu
(Facies posterior)
Flexura coli dextra
Colon ascendens
Taenia libera
Intestinum tenue
– Jejunum
– Ileum
Caecum

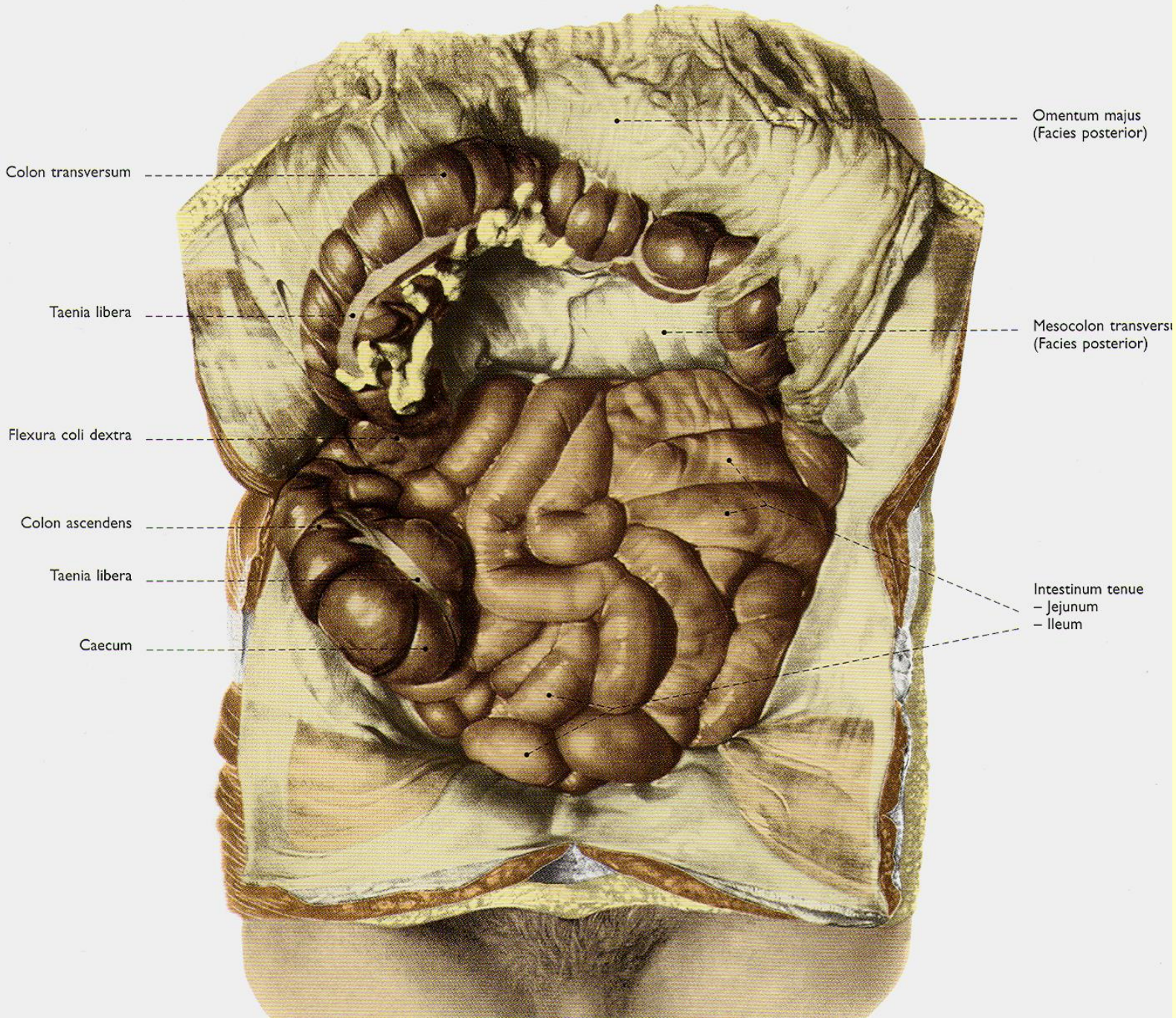
Omentum majus
(Facies posterior)
Colon transversum
Taenia libera
Mesocolon transversi
(Facies posterior)
Flexura coli dextra
Colon ascendens
Taenia libera
Intestinum tenue
– Jejunum
– Ileum
Caecum

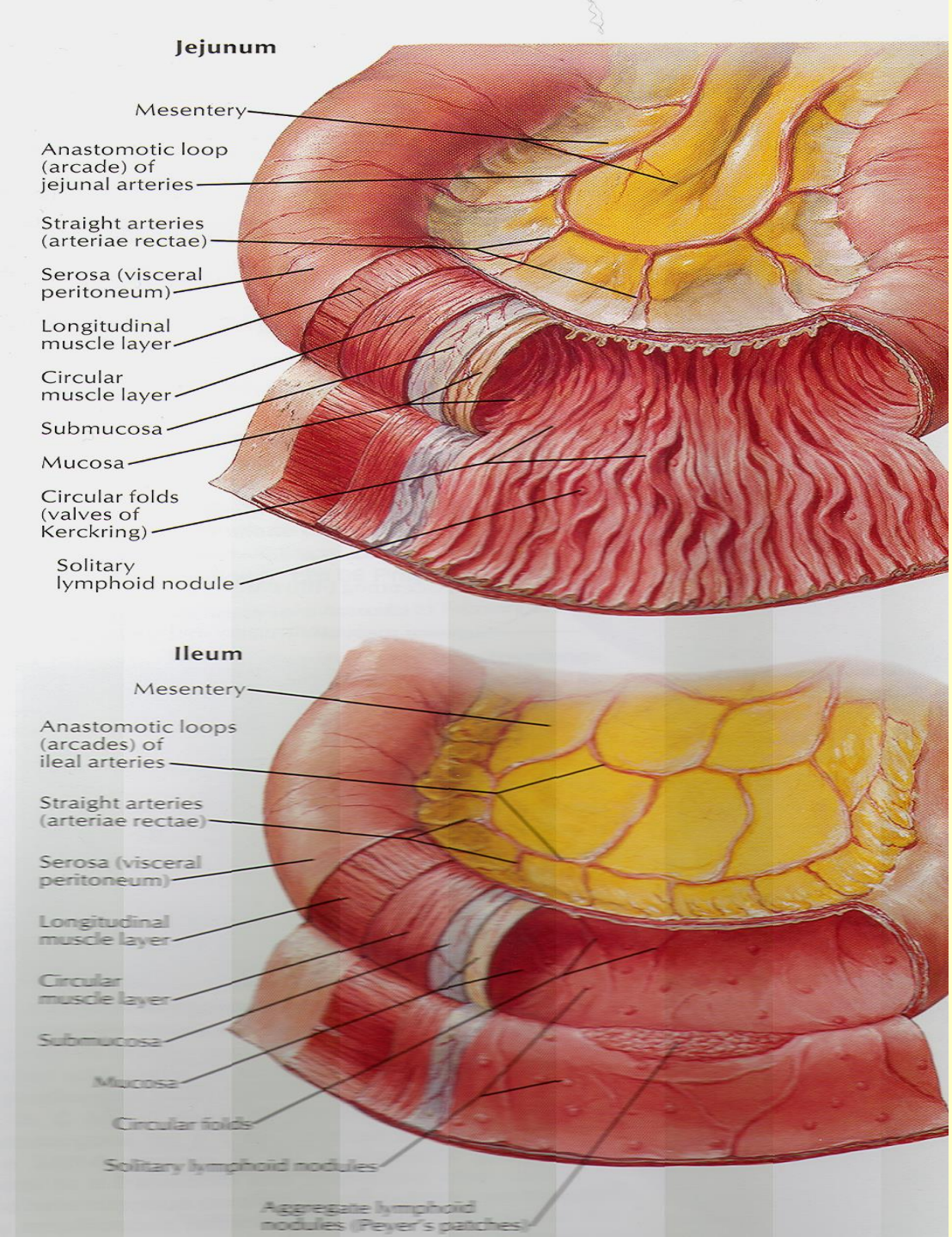
Jejunum
Mesentery
Anastomotic loop (arcade) of jejunal arteries
Straight arteries (arteriae rectae)
Serosa (visceral peritoneum)
Longitudinal muscle layer
Circular muscle layer
Submucosa
Mucosa
Circular folds (valves of Kerckring)
Solitary lymphoid nodule
Ileum
Mesentery
Anastomotic loops (arcades) of ileal arteries
Straight arteries (arteriae rectae)
Serosa (visceral peritoneum)
Longitudinal muscle layer
Circular muscle layer
Submucosa
Mucosa
Circular folds
Solitary lymphoid nodules
Aggregate lymphoid nodules (Peyer's patches)

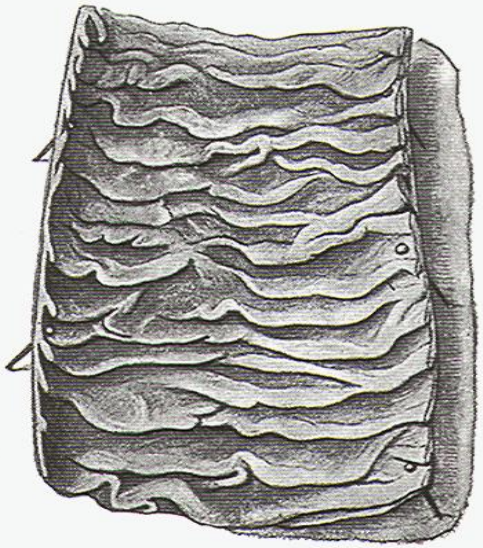

Fig. 72.2 Internal aspect of a representative sample of the proximal jejunum, showing circular folds.

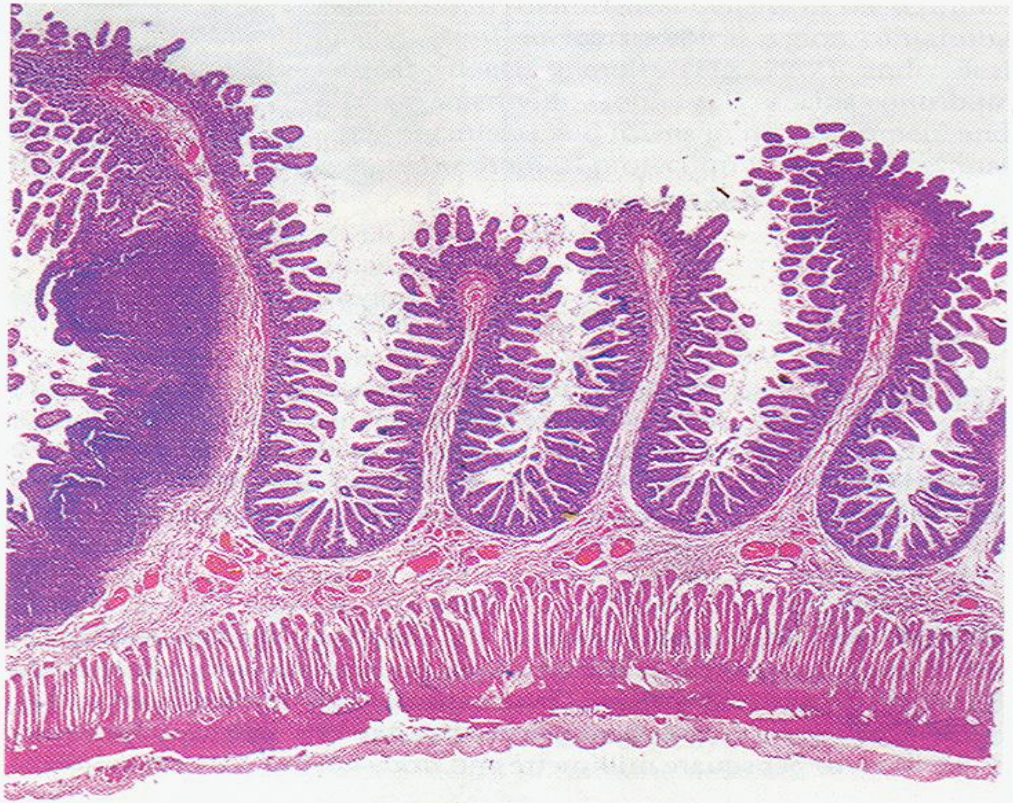

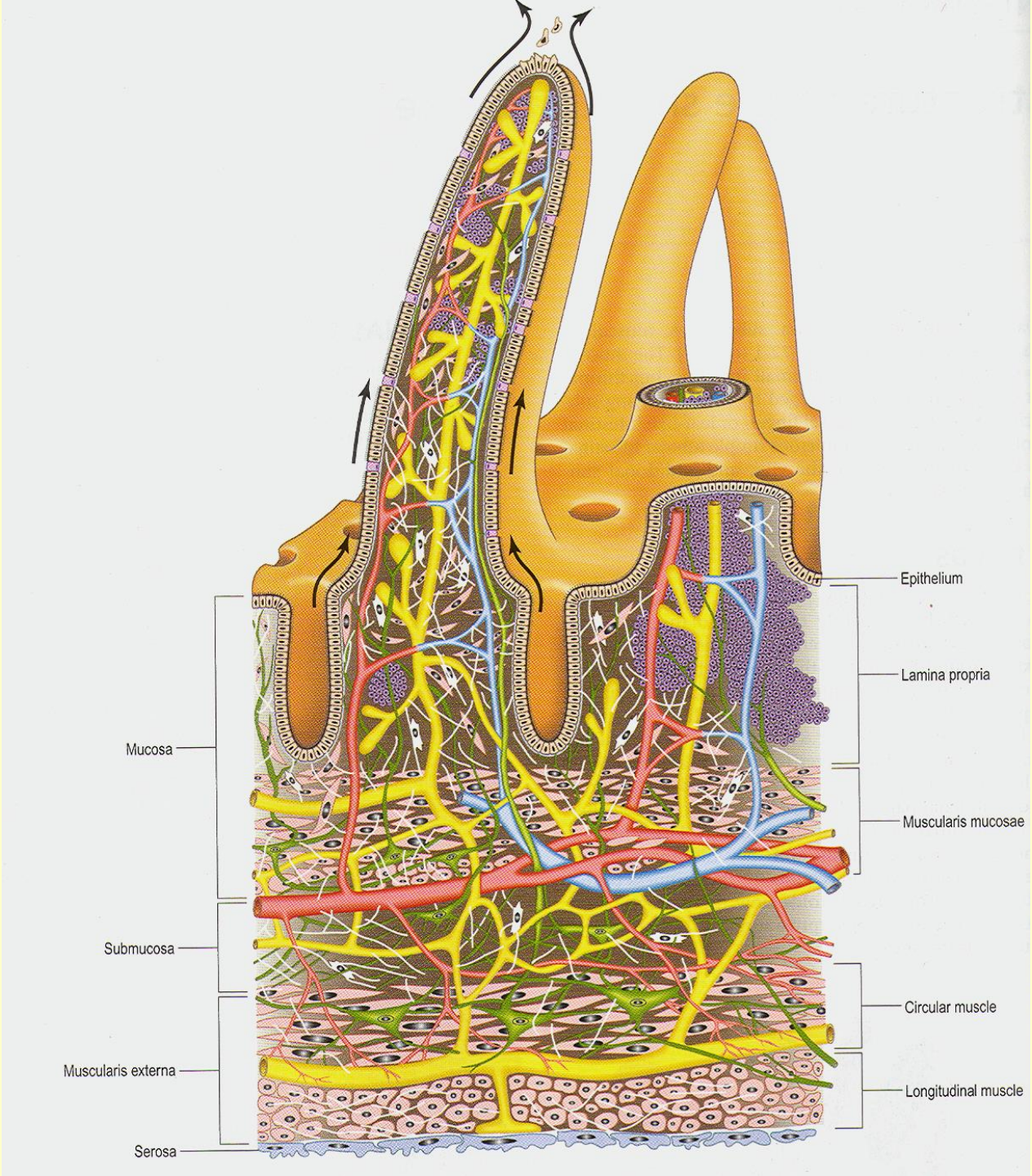
Epithelium
Lamina propria
Mucosa
Muscularis mucosae
Submucosa
Circular muscle
Muscularis externa
Longitudinal muscle
Serosa

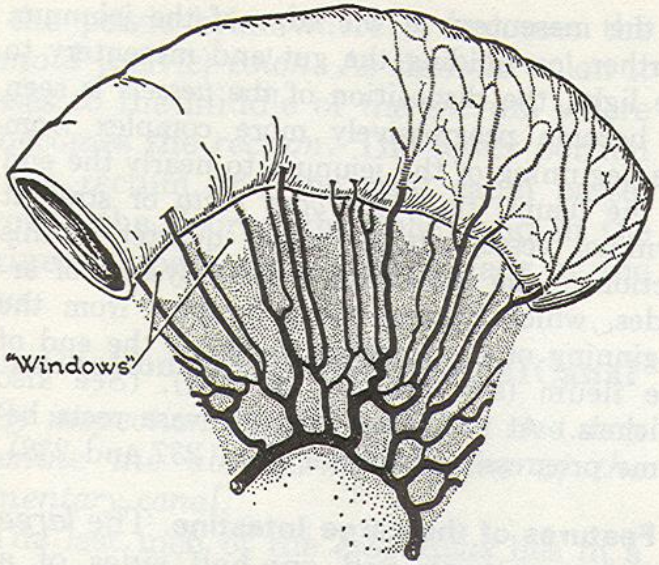

FIG. 237. The arteries of the jejunum (from an injected specimen).

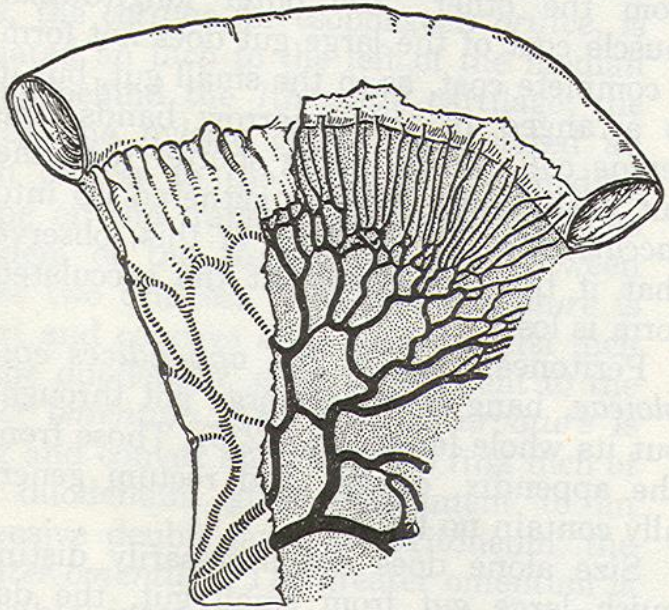

FIG. 238. The arteries of the ileum (from an injected specimen).

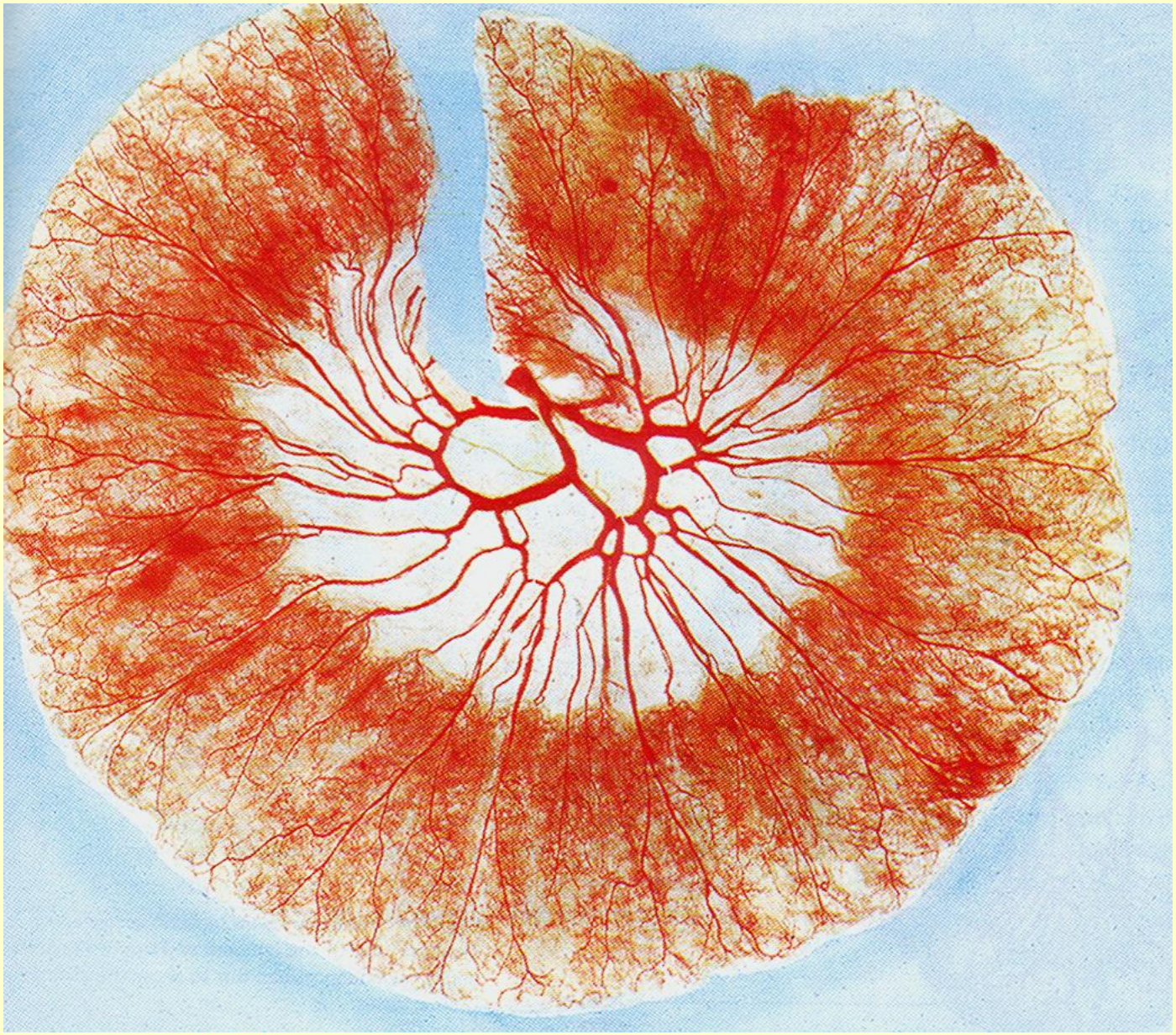

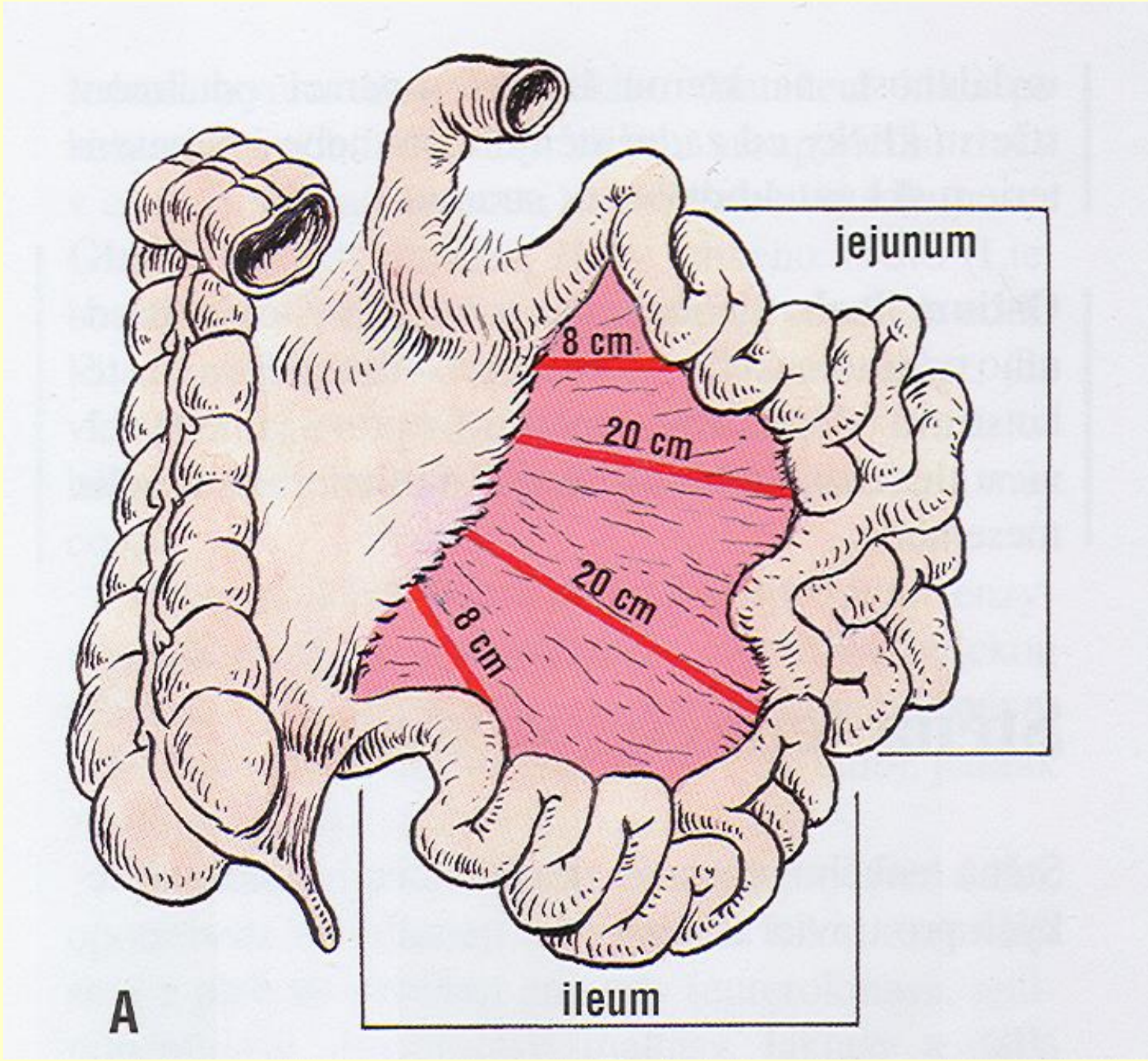
jejunum
8 cm
20 cm
20 cm
8 cm
ileum
A

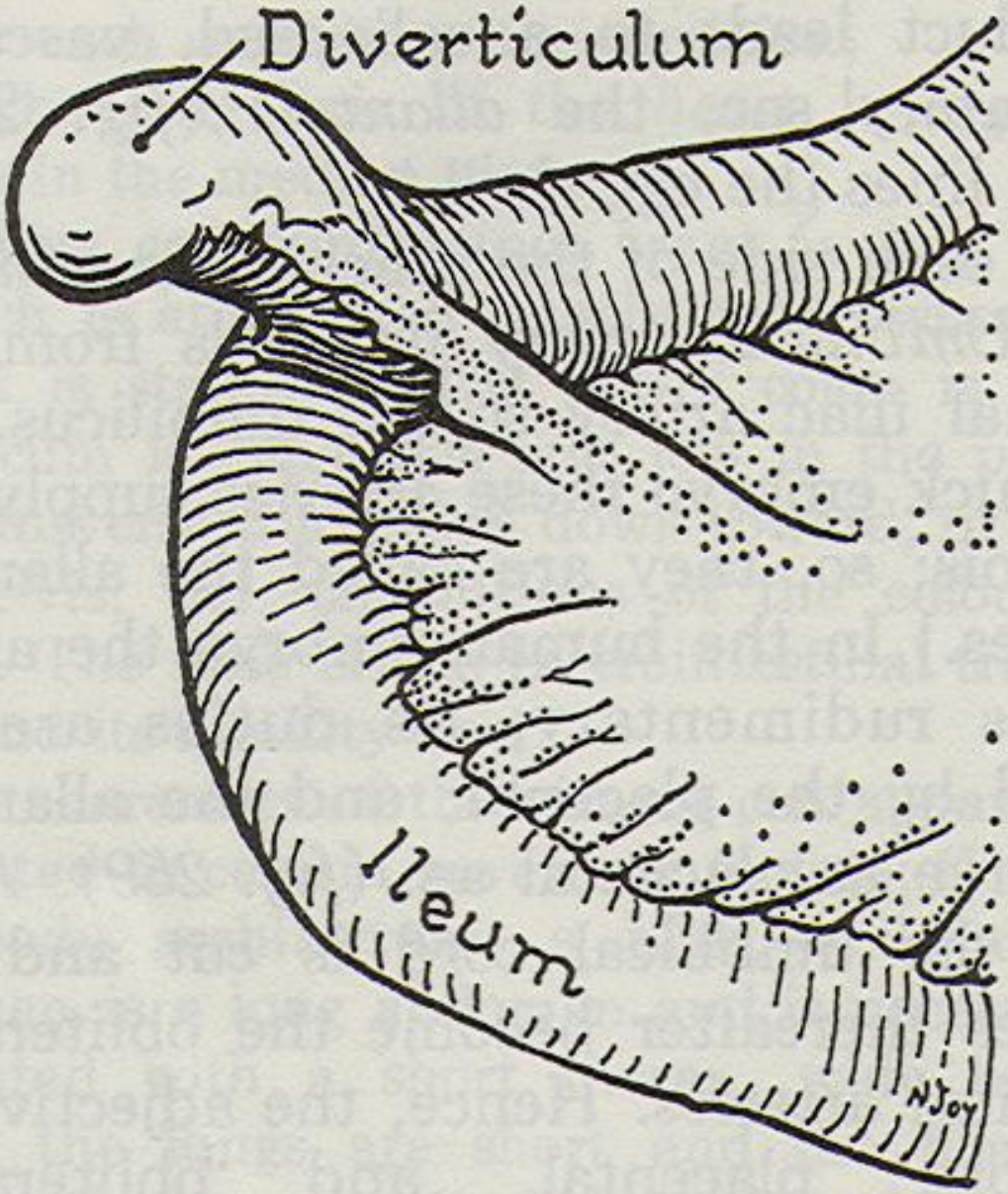

FIG. 259.1. Diverticulum ilei (of Meckel)

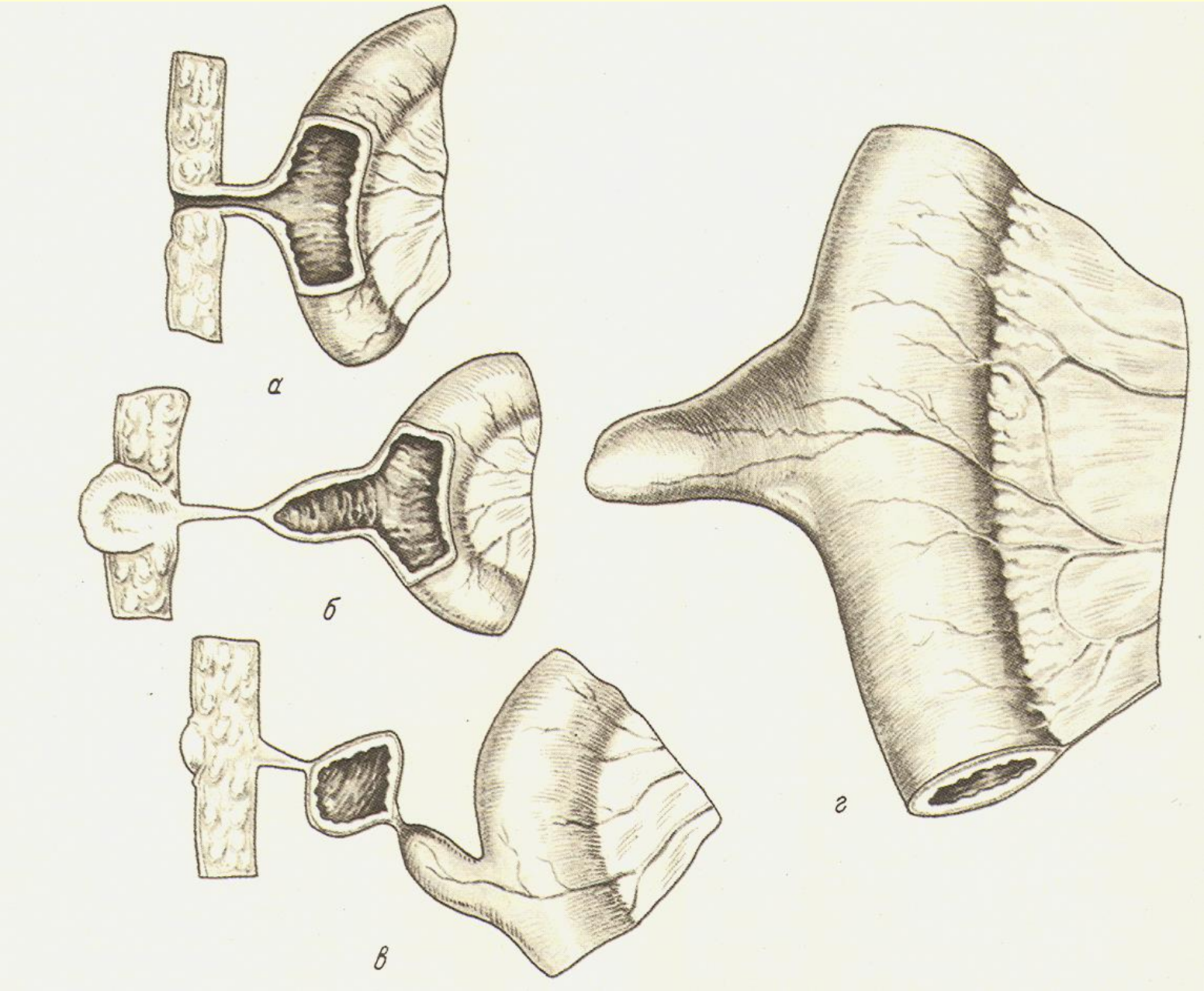
а
б
в
г

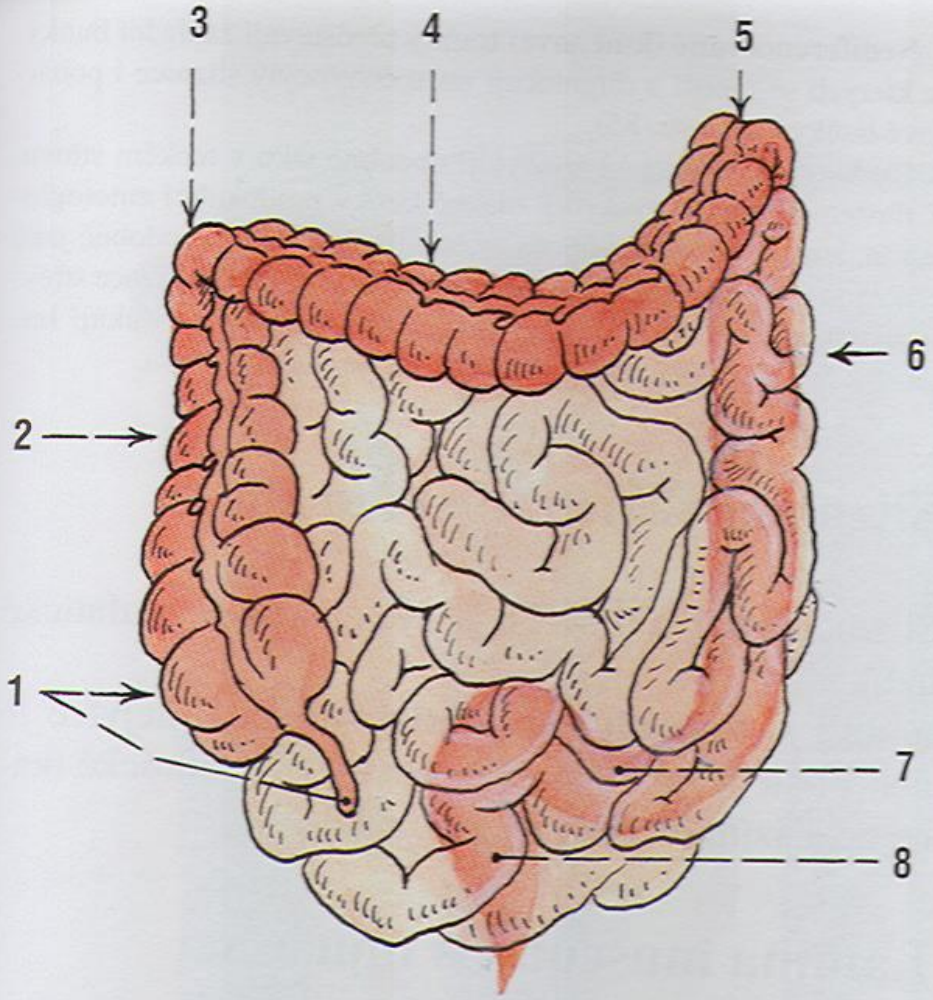

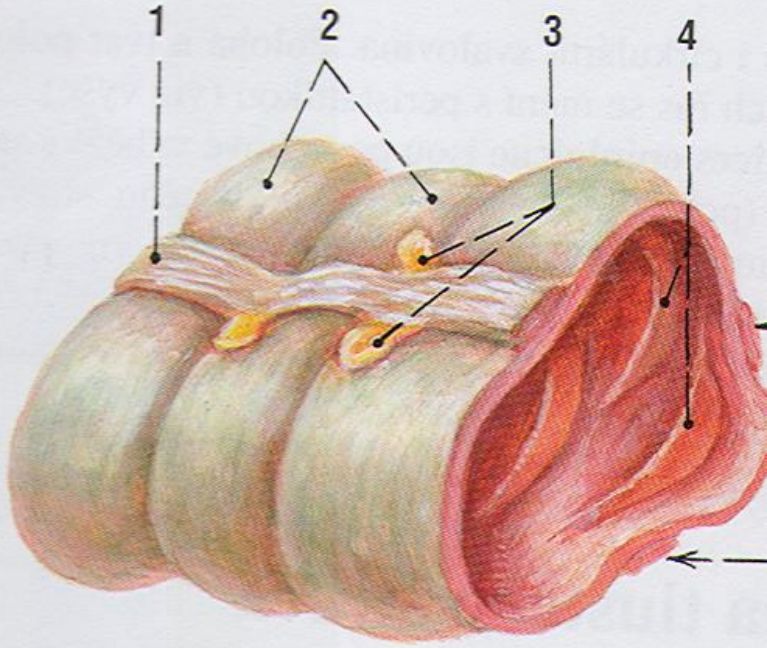

Obr. 70. CHARAKTERISTICKÉ ZNAKY TLUSTÉHO S

1 taenia (taenia omentalis)
2 haustra
3 appendices epiploicae
4 plicae semilunares
5 taenia mesocolica
6 taenia libera

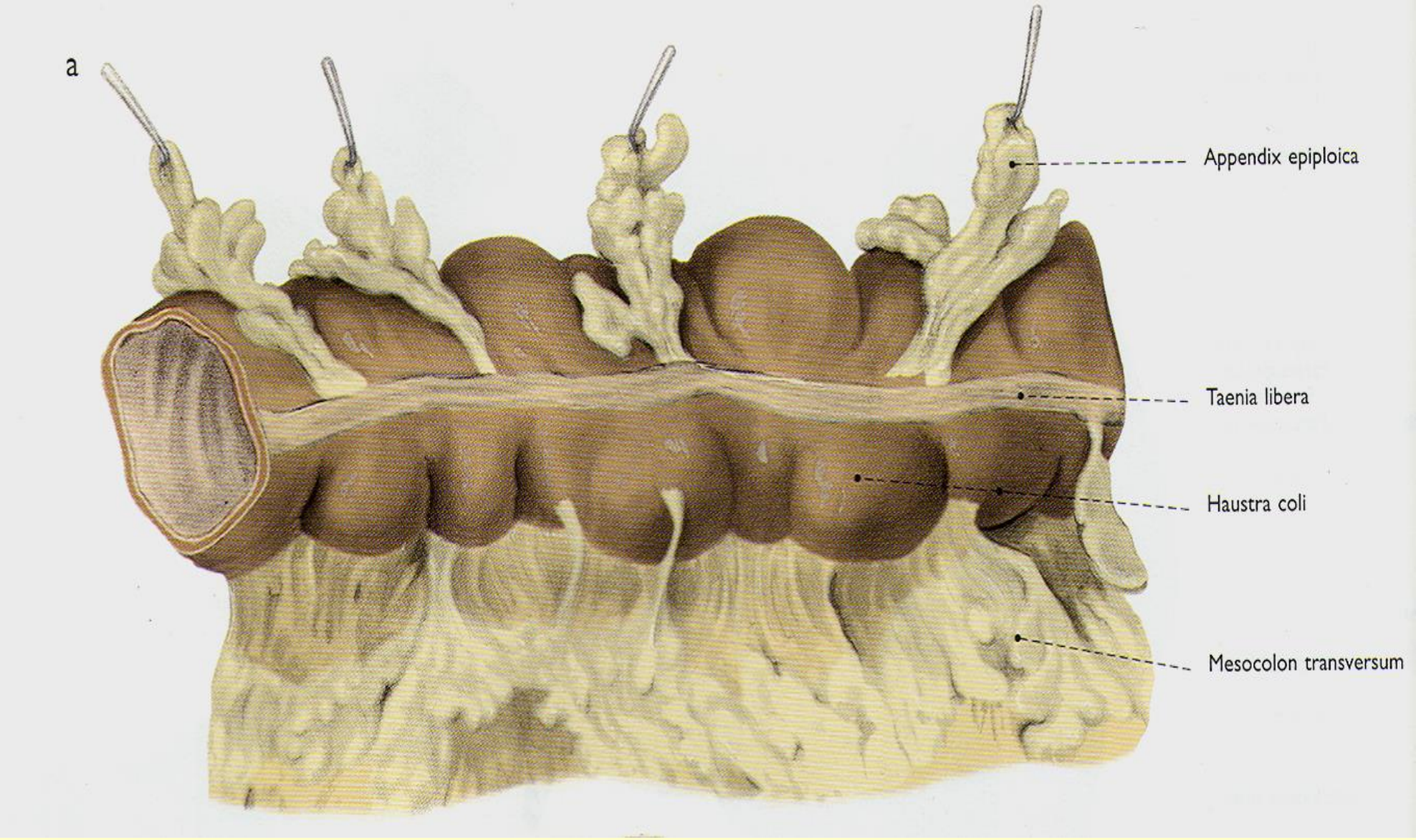
a
Appendix epiploica
Taenia libera
Haustra coli
Mesocolon transversum

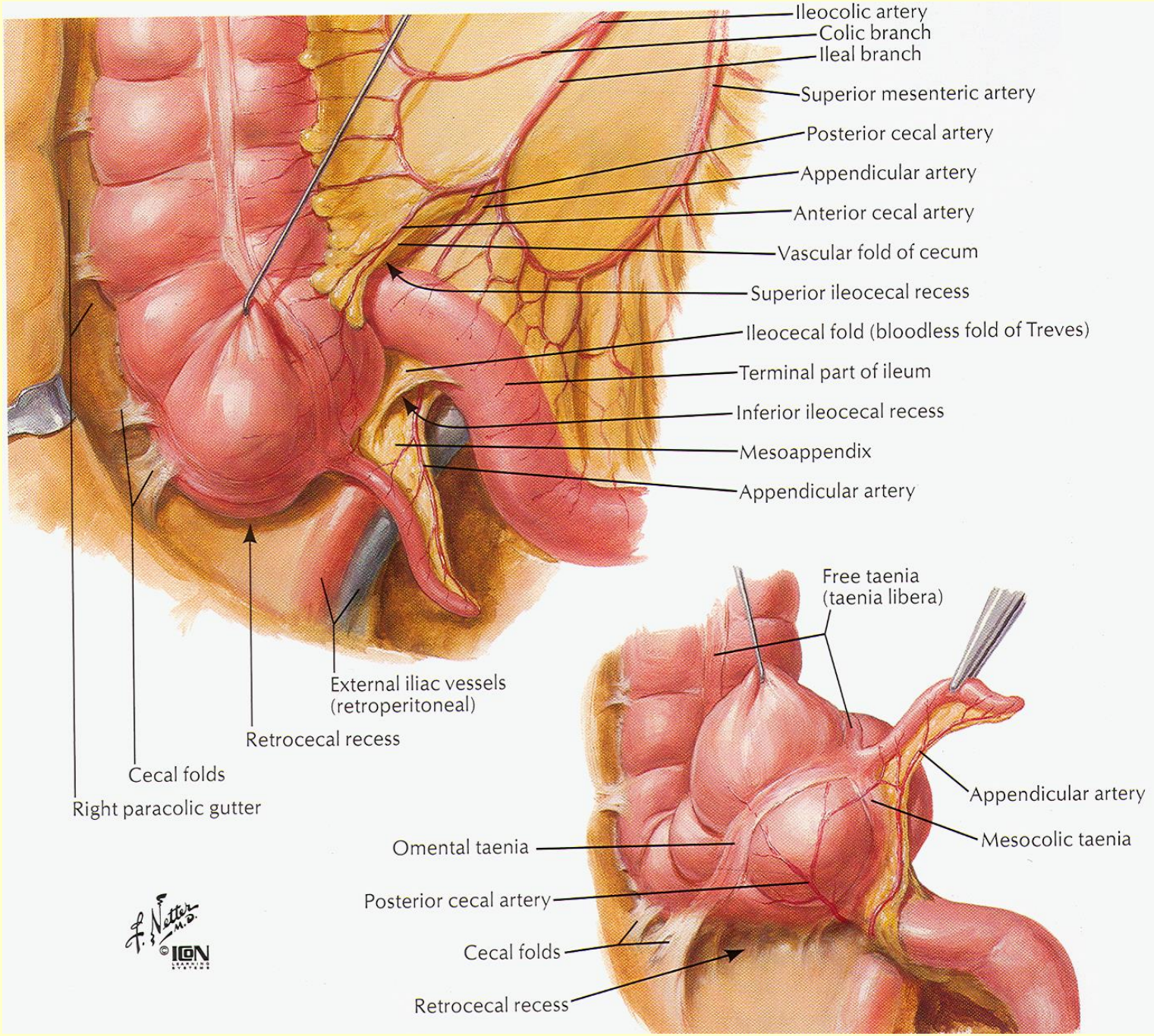
Ileocolic artery
Colic branch
Ileal branch
Superior mesenteric artery
Posterior cecal artery
Appendicular artery
Anterior cecal artery
Vascular fold of cecum
Superior ileocecal recess
Ileocecal fold (bloodless fold of Treves)
Terminal part of ileum
Inferior ileocecal recess
Mesoappendix
Appendicular artery
External iliac vessels (retroperitoneal)
Retrocecal recess
Cecal folds
Right paracolic gutter
Free taenia (taenia libera)
Appendicular artery
Mesocolic taenia
Omental taenia
Posterior cecal artery
Cecal folds
Retrocecal recess
F. Netter M.D.
©ICN

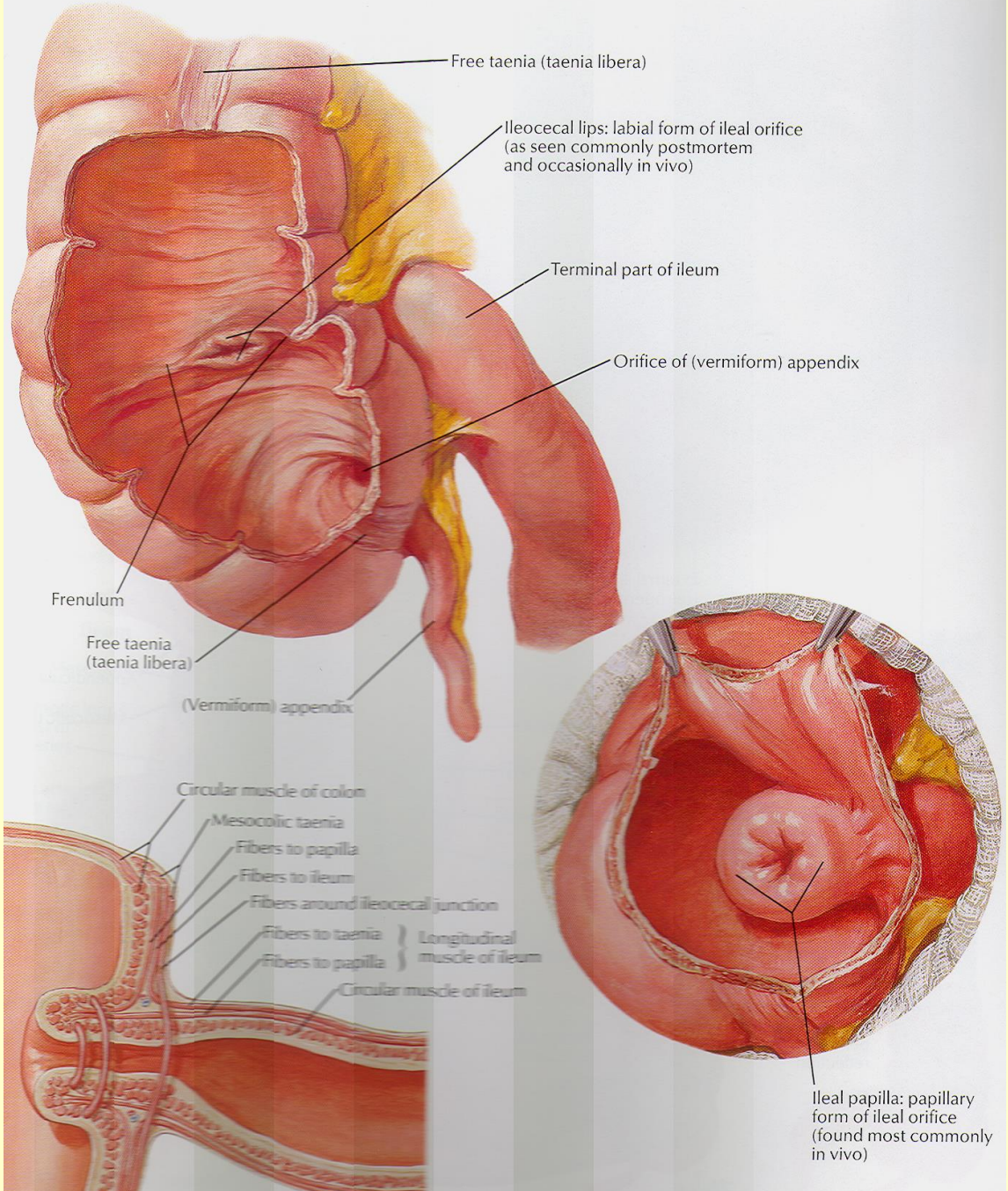

chema of muscle fibers at ileal orifice

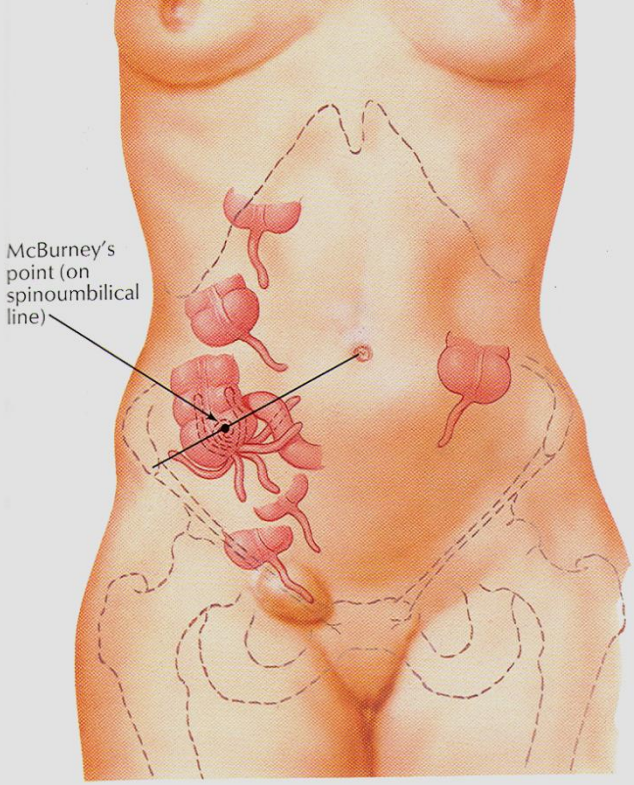

Variations in position of appendix

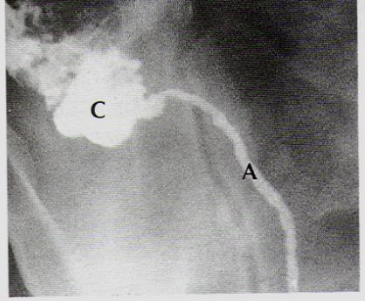

Barium radiograph of unusually long appendix (**A** Appendix; **C** Cecum)

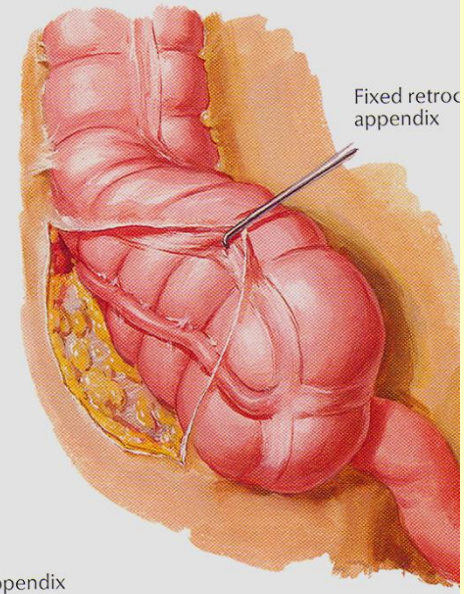

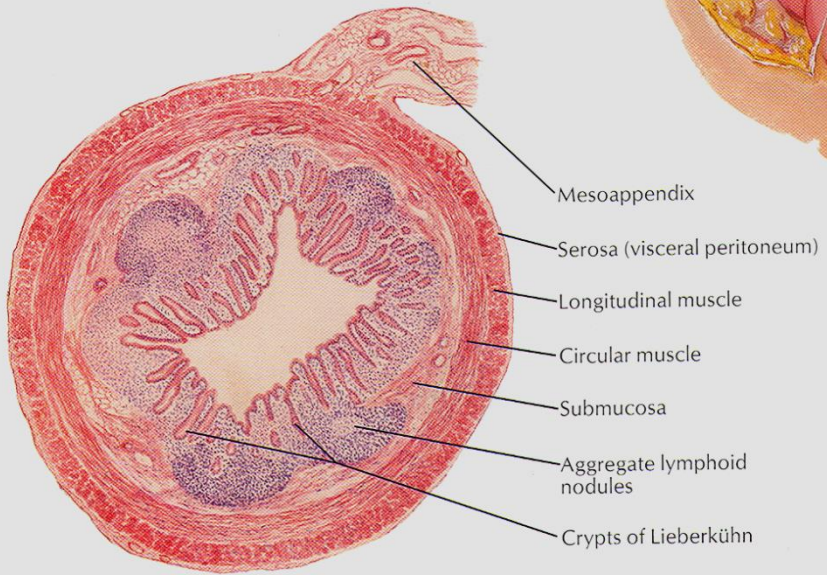

F. Netter M.D.

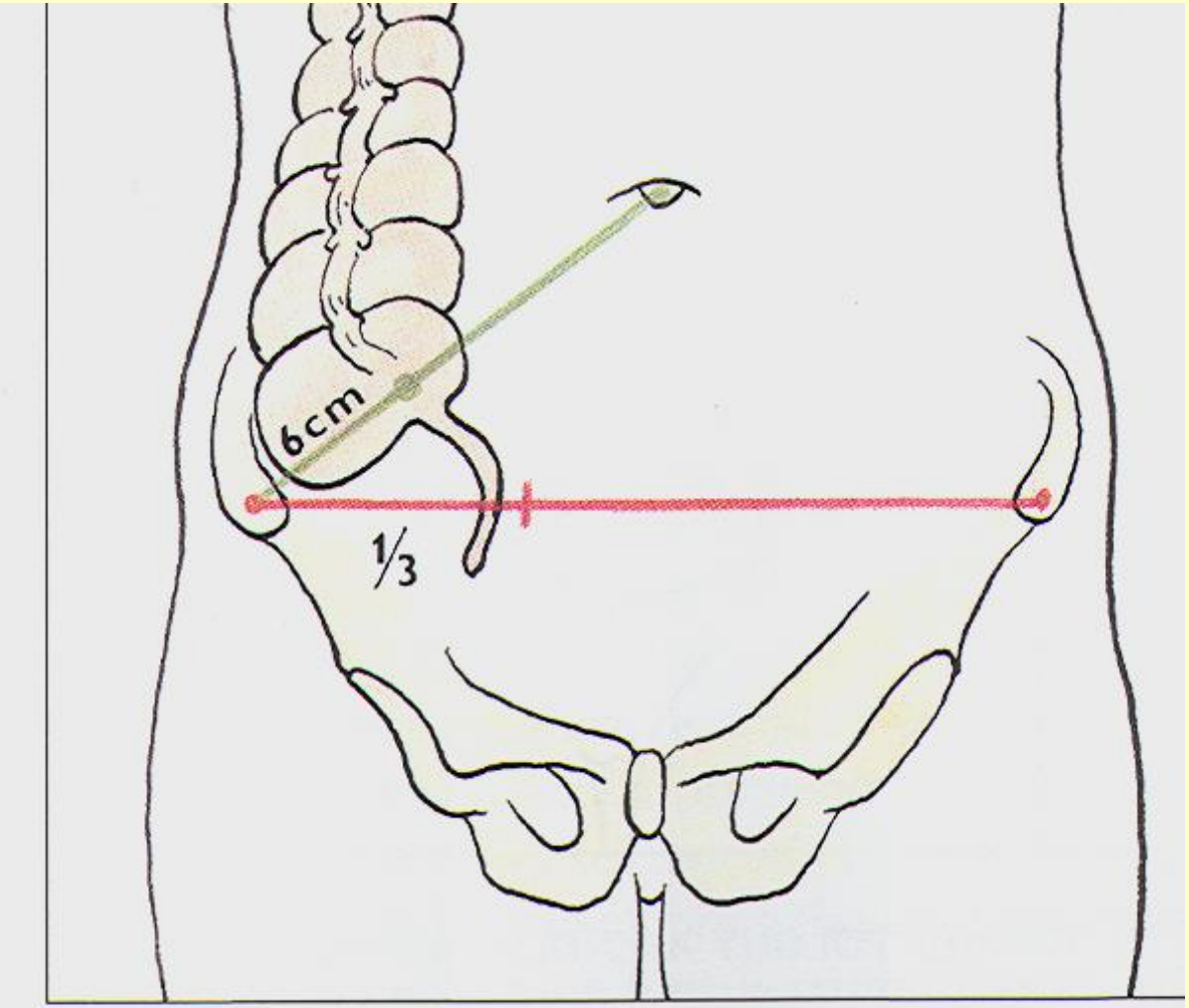

Obr. 74. BODY PRO VYHLEDÁNÍ APENDIXU; schéma
zeleně – McBurneyův bod
červeně – Lanzův bod

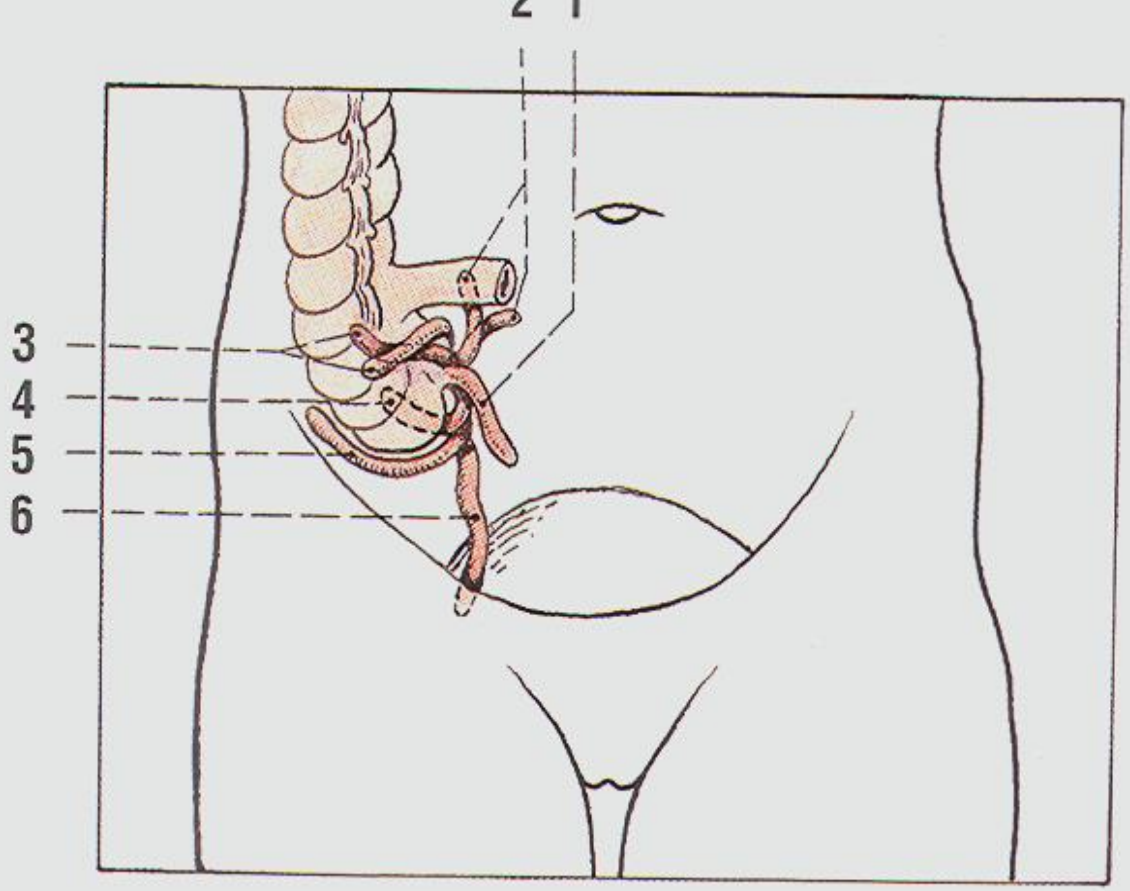

Obr. 75. TYPICKÉ POLOHY APENDIXU; schéma
1 positio subcaecalis
2 positio ileocaecalis
3 positio precaecalis
4 positio retrocaecalis
5 positio laterocaecalis
6 positio pelvina
(u ileocaekální a precaekální pozice jsou znázorněny různé možné směry konce apendixu)

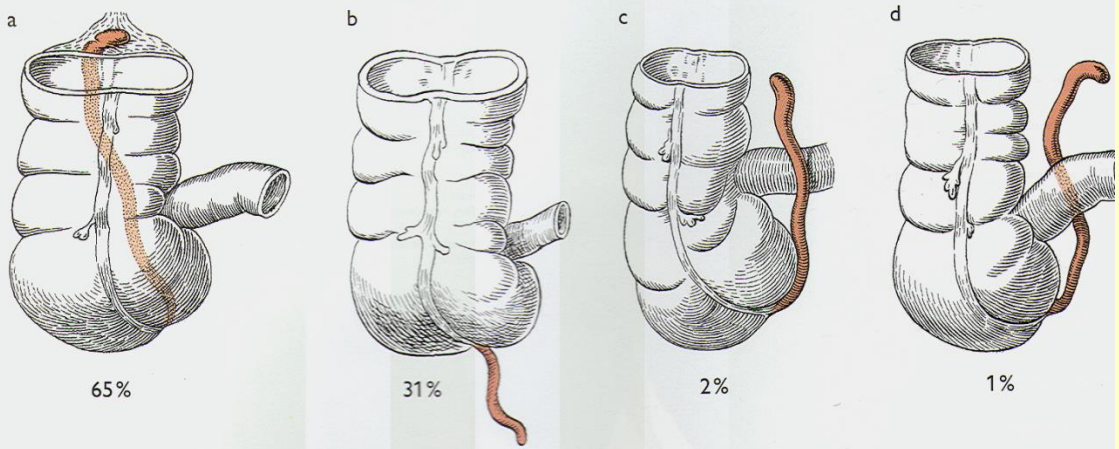

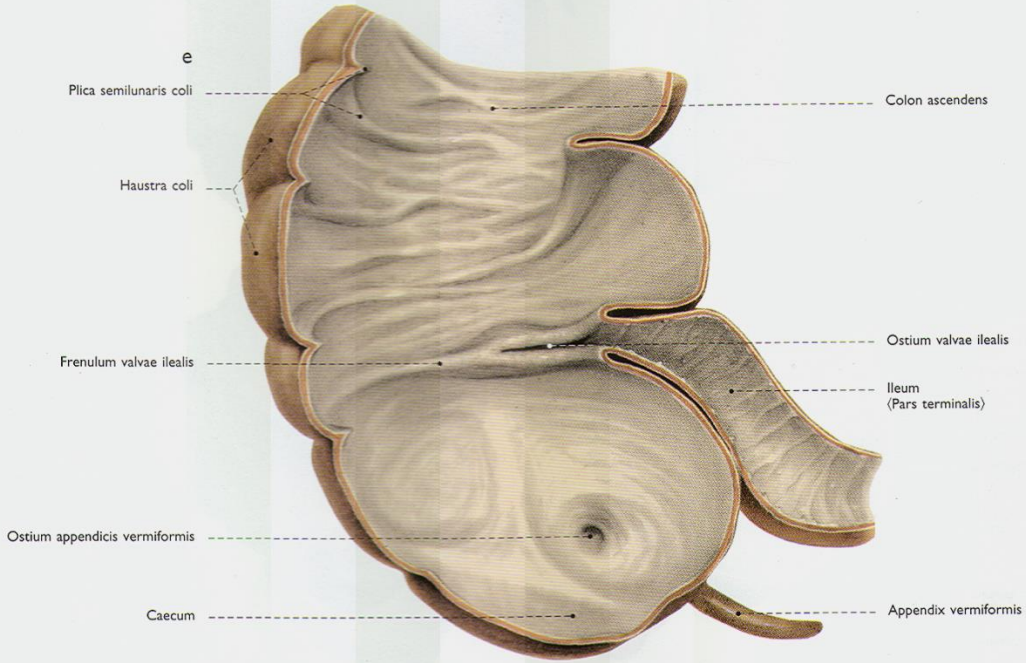

178 Caecum et Appendix vermiformis

178 Cecum and vermiform appendix

a–d Four possible positions of the vermiform appendix. The percentile numbers beneath the pictures indicate the approximate frequency.
a Retrocecal and retrocolic position
b Pendulous position into the lesser pelvis
c Position in front of the terminal part of the ileum
d Retroileal position
e Internal aspect of the dorsal wall of the cecum after removal of the ventral intestinal

178 Blinddarm und Wurmfortsatz

a–d Vier mögliche Lagen des Wurmfortsatzes. Die Prozentzahlen unter den Abbildungen geben die ungefähre Häufigkeit an.
a Retrozäkale und retrokolische Lage
b Ins kleine Becken herabhängende Lage
c Präileale Lage
d Retroileale Lage
e Innenansicht der Hinterwand des Caecum (des Blinddarms) nach Entfernung der ventralen Darmwand (80%)

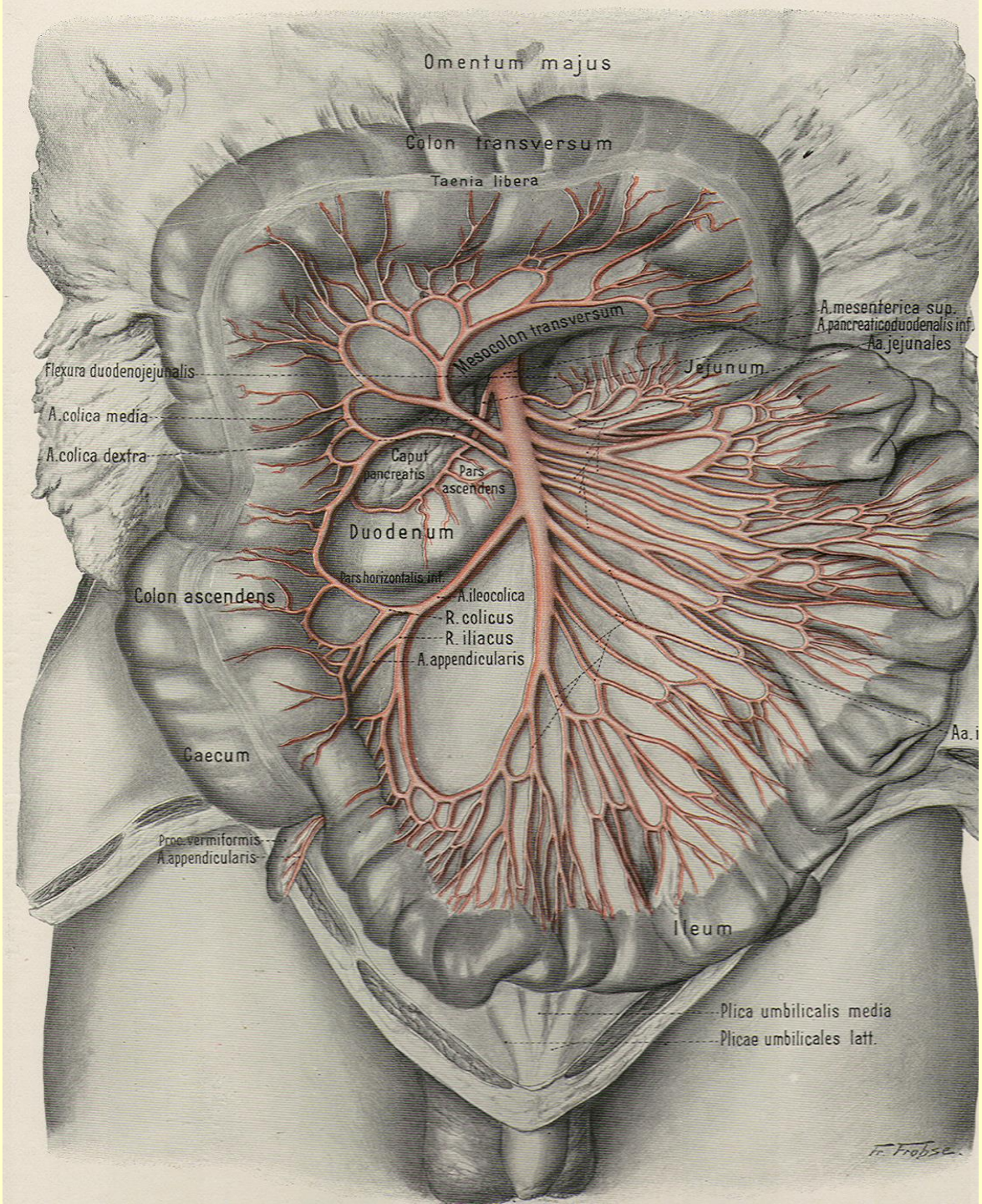
Omentum majus
Colon transversum
Taenia libera
A. mesenterica sup.
A. pancreaticoduodenalis inf.
Aa. jejunales
Mesocolon transversum
Jejunum
Flexura duodenojejunalis
A. colica media
A. colica dextra
Caput pancreatis
Pars ascendens
Duodenum
Pars horizontalis inf.
Colon ascendens
A. ileocolica
R. colicus
R. iliacus
A. appendicularis
Caecum
Proc. vermiformis
A. appendicularis
Ileum
Plica umbilicalis media
Plicae umbilicales latt.

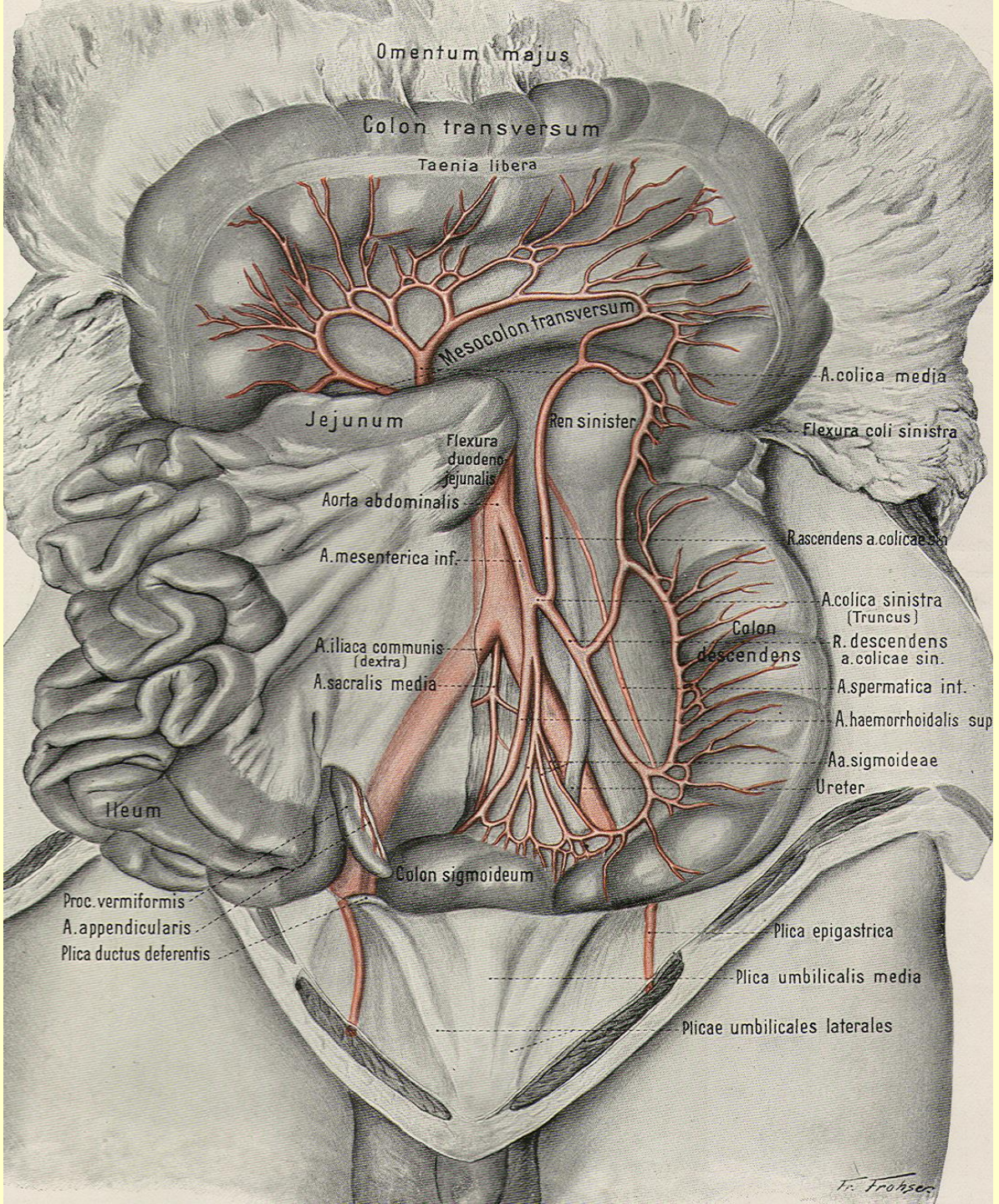
Omentum majus
Colon transversum
Taenia libera
Mesocolon transversum
A.colica media
Jejunum
Ren sinister
Flexura coli sinistra
Flexura duodeno jejunalis
Aorta abdominalis
R.ascendens a.colicae sin.
A.mesenterica inf.
A.colica sinistra (Truncus)
Colon descendens
A.iliaca communis (dextra)
R. descendens a.colicae sin.
A.sacralis media
A.spermatica int.
A.haemorrhoidalis sup.
Aa.sigmoideae
Ureter
Ileum
Colon sigmoideum
Proc.vermiformis
A.appendicularis
Plica ductus deferentis
Plica epigastrica
Plica umbilicalis media
Plicae umbilicales laterales

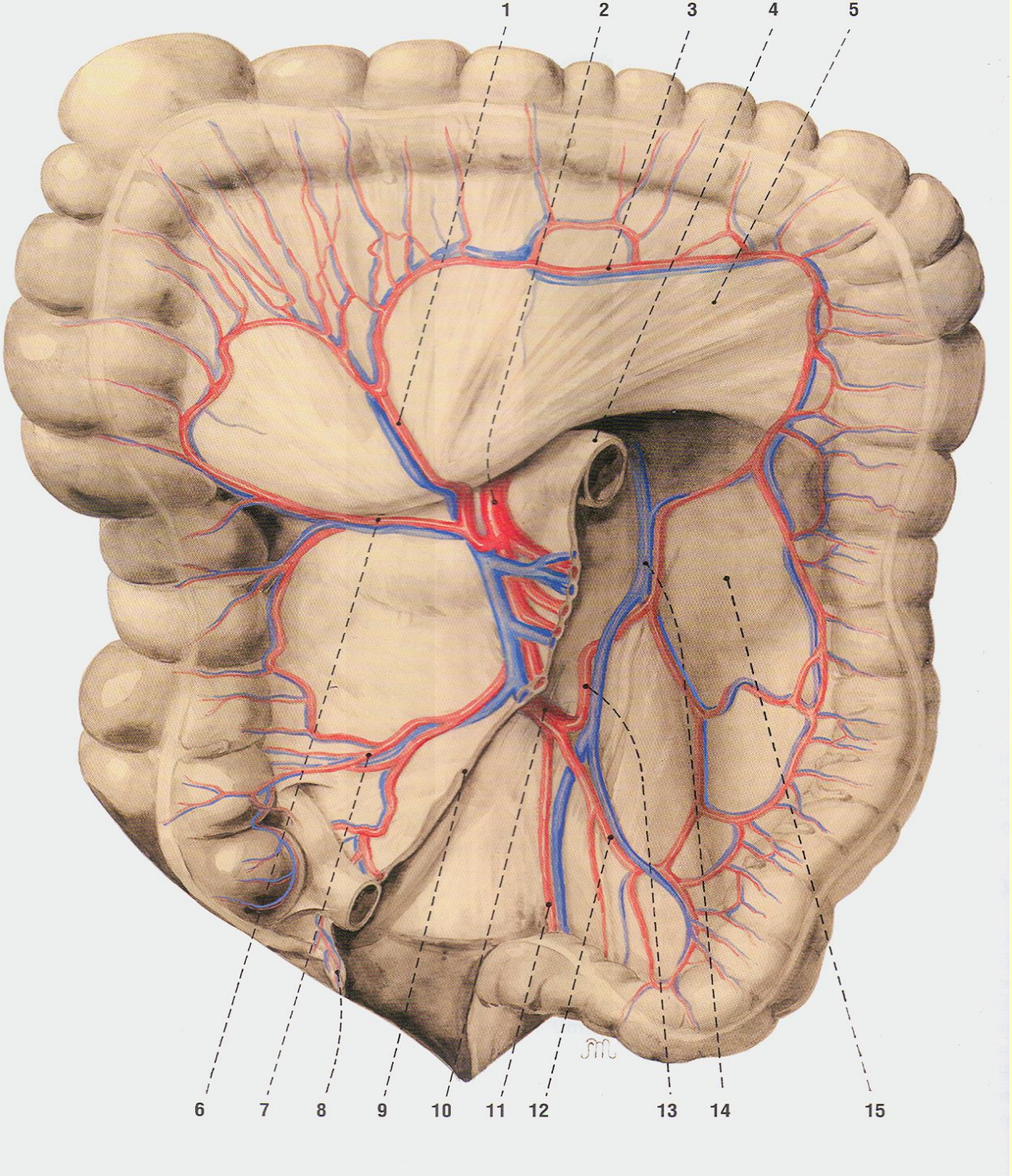
1
2
3
4
5
6
7
8
9
10
11
12
13
14
15

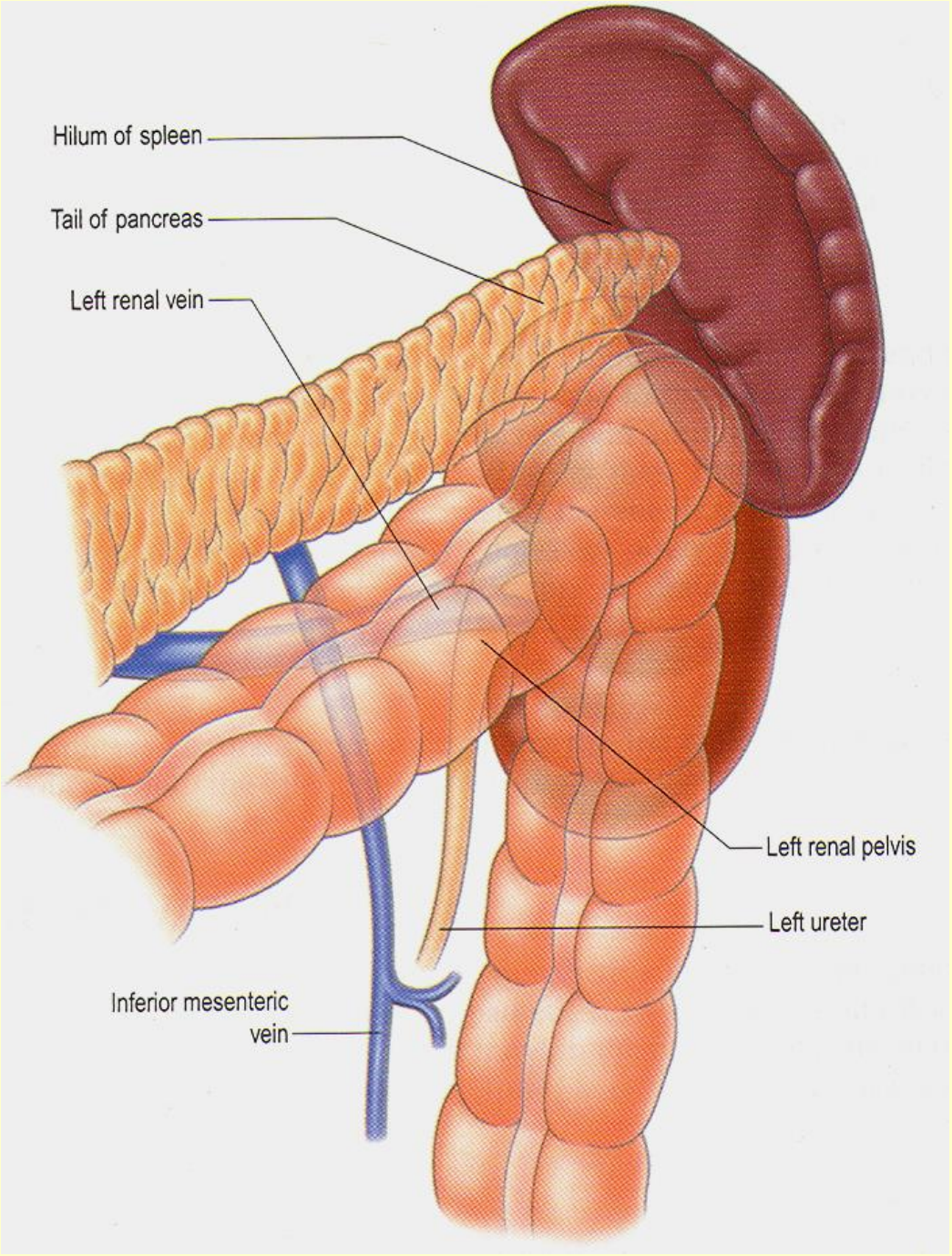
Hilum of spleen
Tail of pancreas
Left renal vein
Left renal pelvis
Left ureter
Inferior mesenteric vein

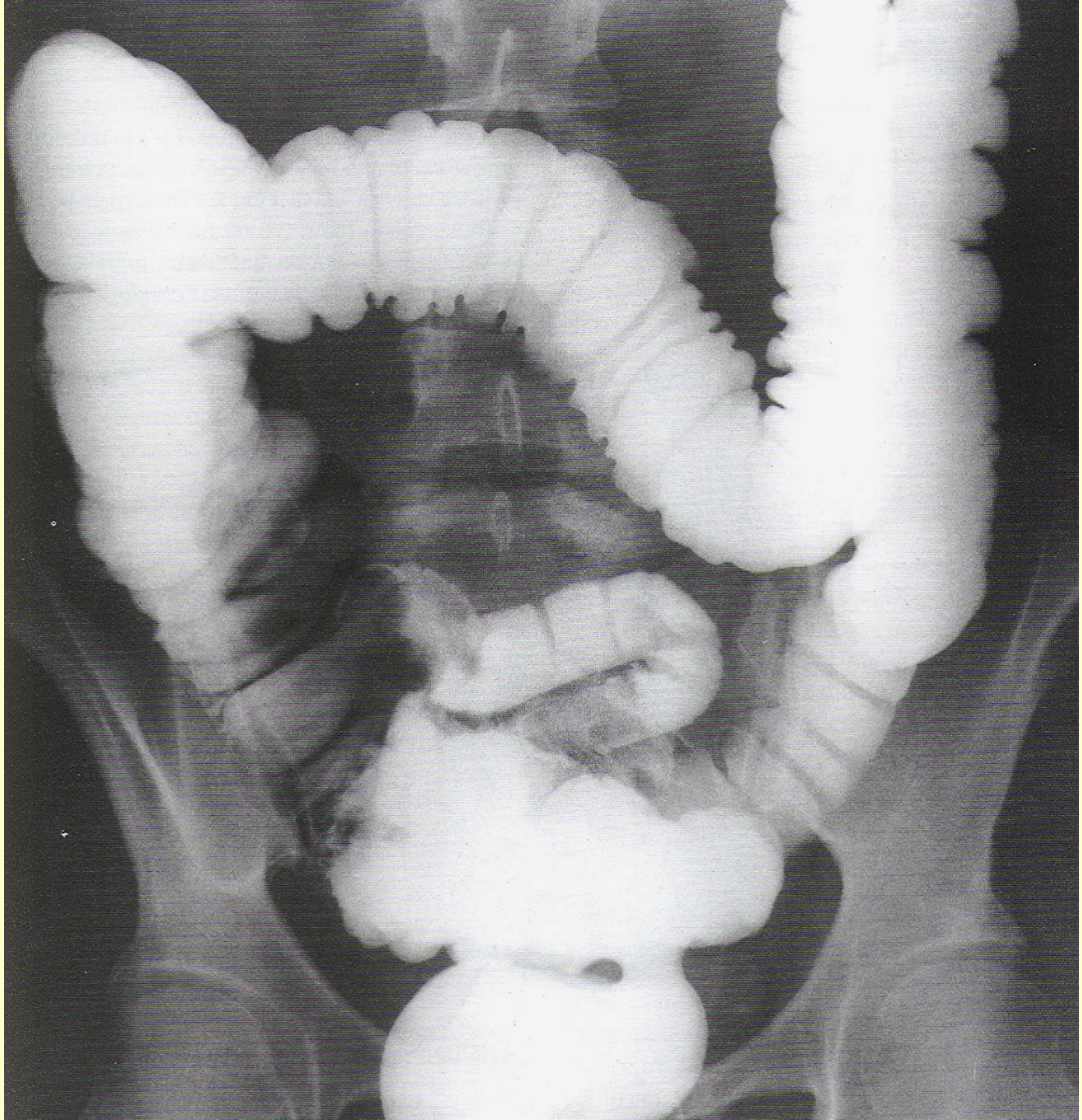

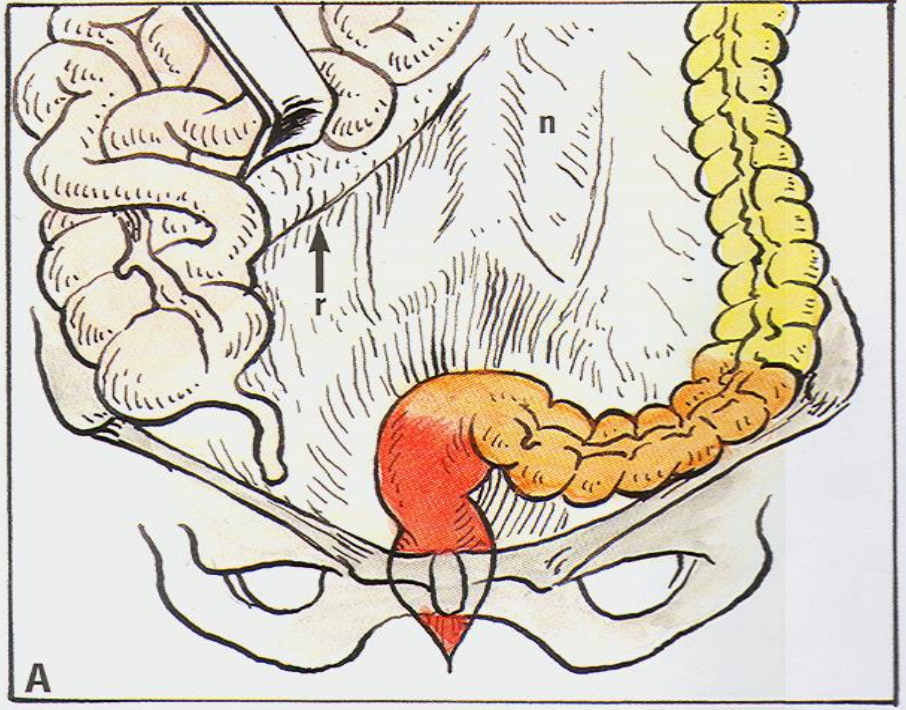
n
r
A

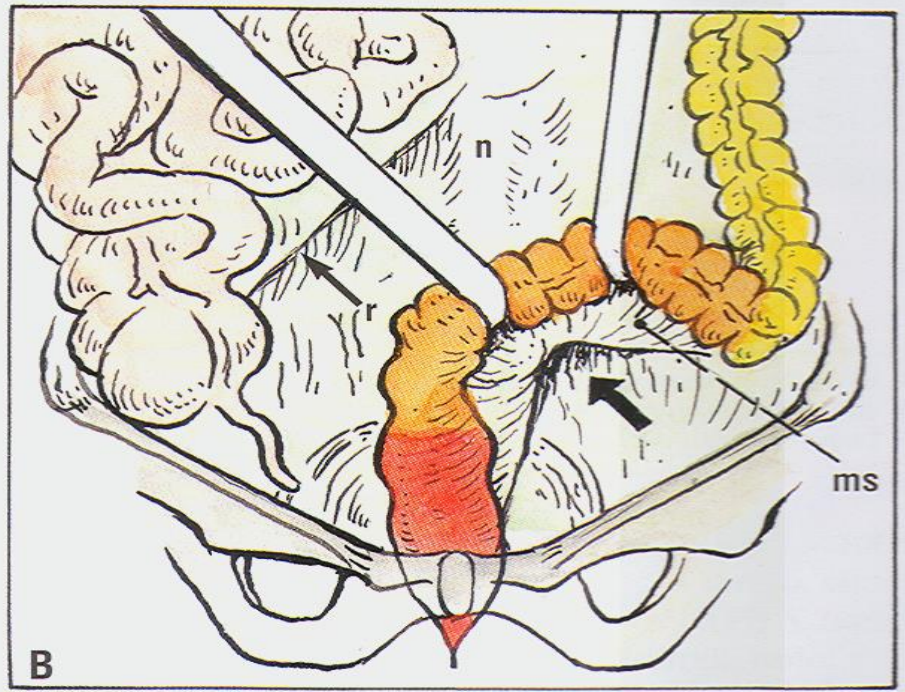
n
r
ms
B

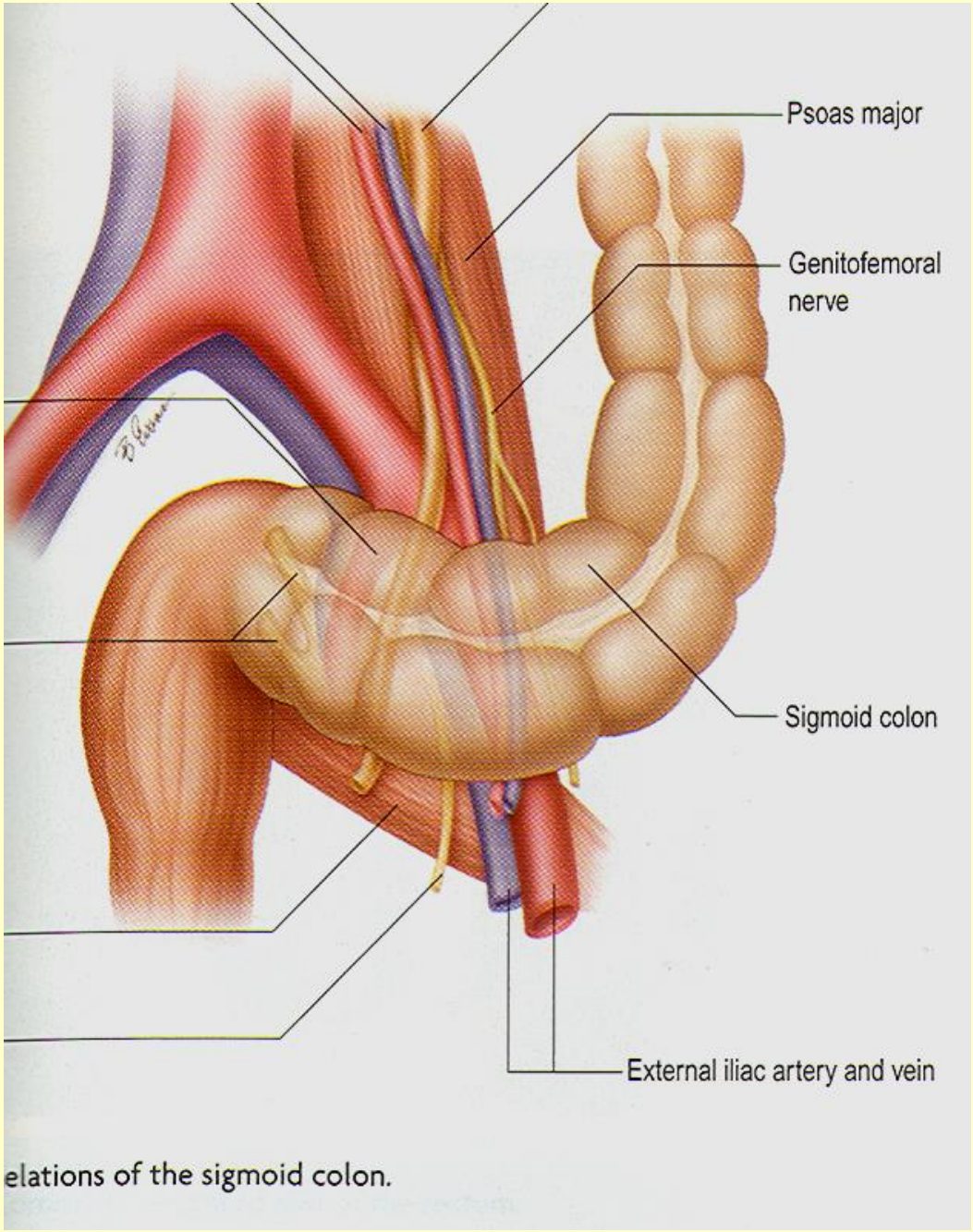

elations of the sigmoid colon.