ŽÍLY

David Kachlík

Žilní část řečiště

- nízkotlaká část
- zásobník krve (70-80 %)

- žilky (*venulae*)
- žíly malého až středního průsvitu
- velké žíly

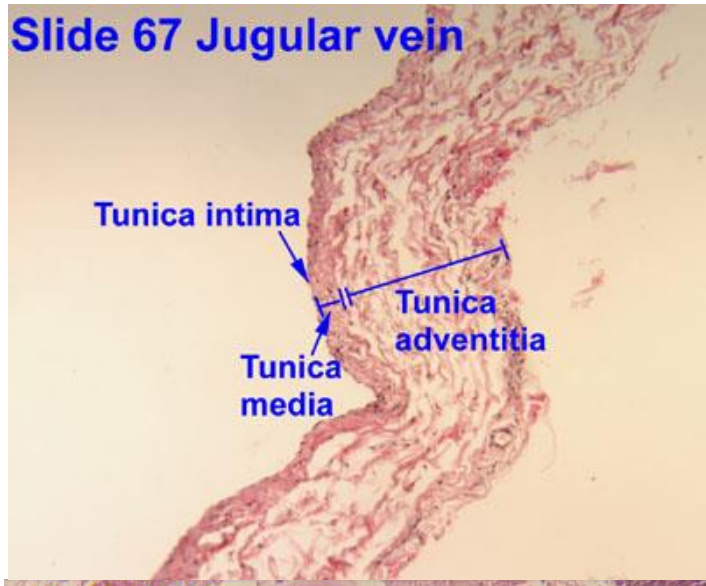

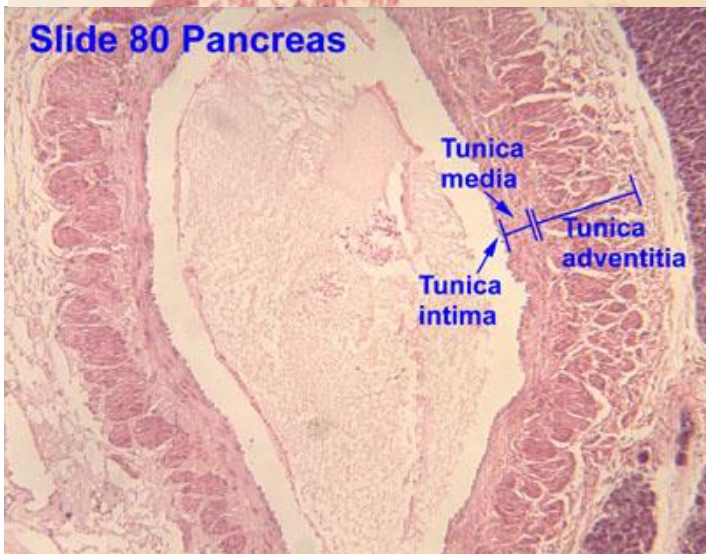

Žilky = Venuly

- průměr 0,2-1 mm

- tunica intima
- tunica media - ***tenká***
- tunica adventitia (externa) - ***tlustá***

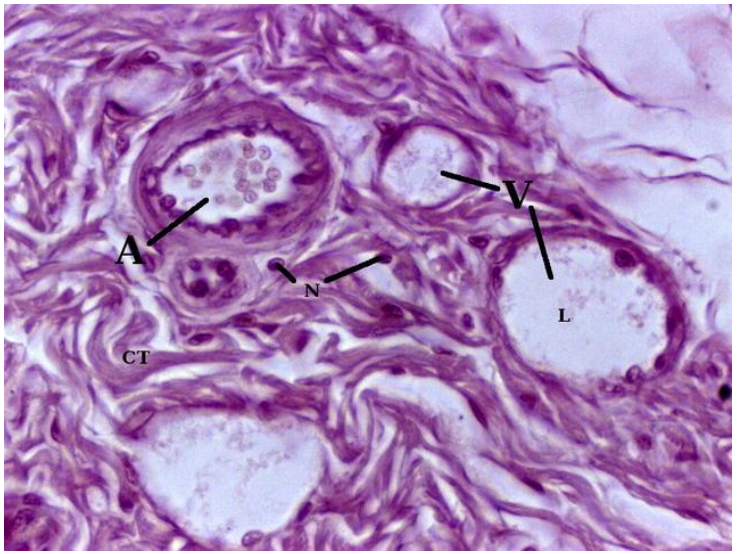

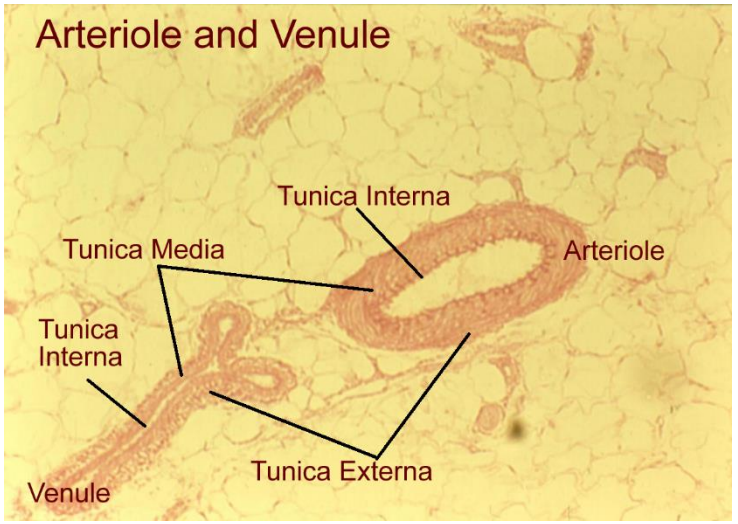

Žíly malého a středního průsvitu

- všechny tři vrstvy jsou rozlišitelné, ***tenké***
- žíly končetin obsahují chlopně
  - duplikatura tunica intima
  - proti zpětnému toku krve
  - nedomykavost → městky („křečové žíly“)

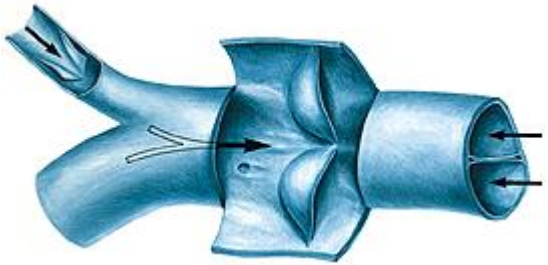

Žíly velkého průsvitu

- **tunica intima**
  - fragmentovaná lamina elastica interna
- **tunica media**
  - několik vrstev hladkých svalových buněk
  - poměrně dost vaziva
- **tunica adventitia (externa)**
  - nejlépe vyvinuta, vazivový základ
  - podélně uspořádané svazky hladkých svalových buněk
  - vasa vasorum

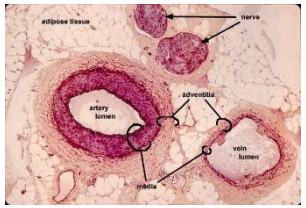

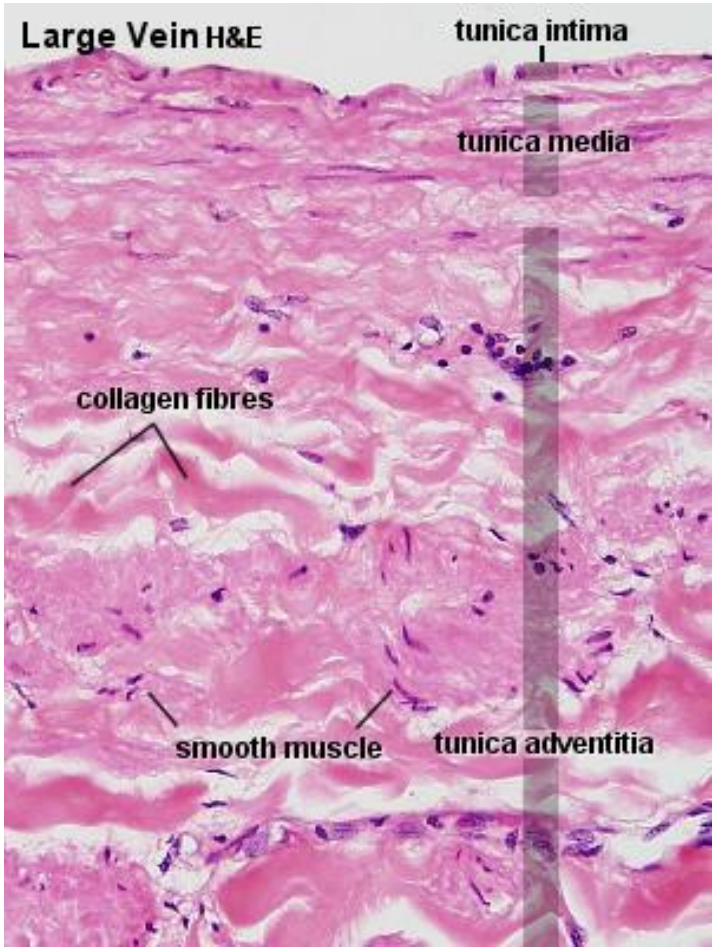

Uspořádání žil v těle

3 soustavy:

- soustava **horní duté** žíly
- soustava **dolní duté** žíly
- soustava **vrátnicové** žíly

vzájemné anastomózy:

  - porto-kavální
  - kavo-kavální

2 vrstvy: končetiny, krk

- povrchová soustava
  - bez doprovodných tepen
- hluboká soustava
- perforátory

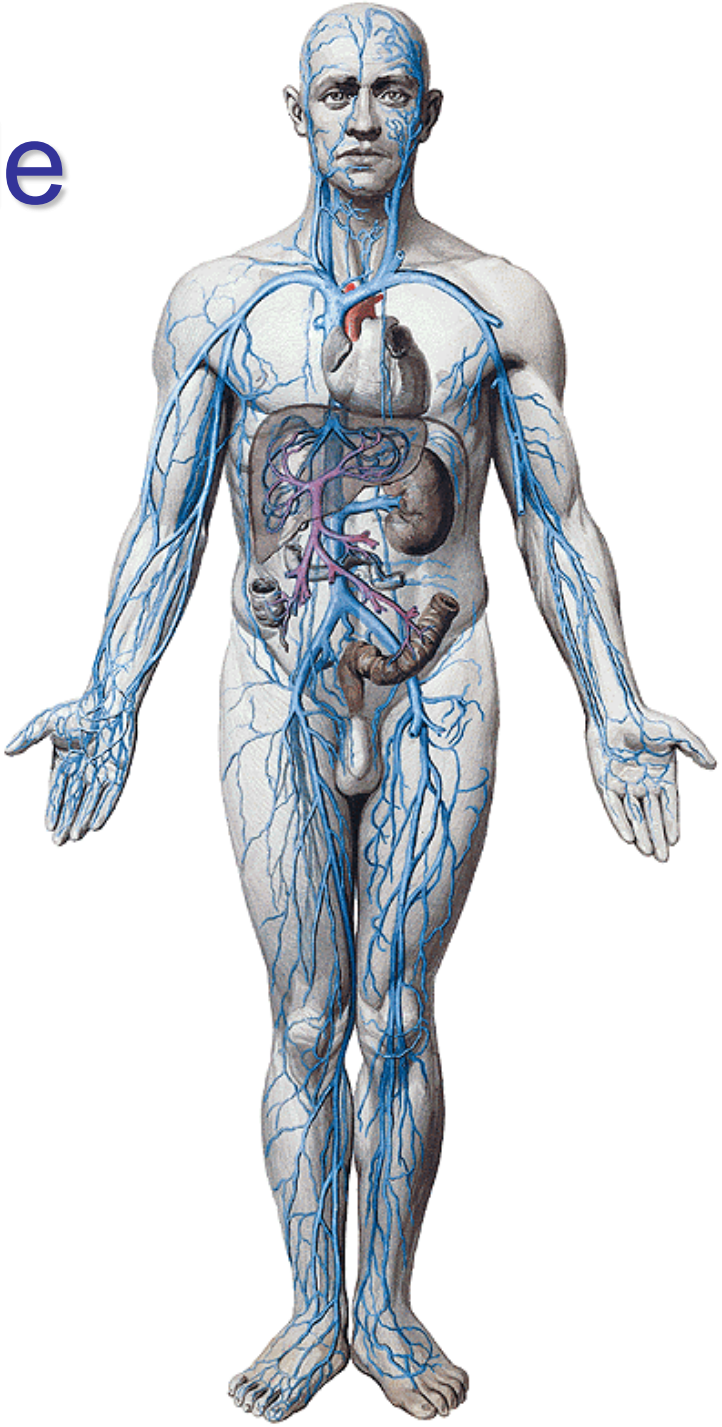

Vena cava superior

- původně dvě žíly, žádné chlopně
  - v. precardinalis dx.
  - *v. precardinalis sin.* → *v. obliqua atrii sin. Marshalli*
- vv. brachiocephalicae
  - pravá svislá (2,5 cm) x levá šikmá (6 cm)
  - v. thyroidea inf. / plexus thyroideus impar + v. laryngea inf.
  - v. vertebralis (v. vertebralis acc., ant.)
  - v. thoracica int. sin.
  - v. intercostalis suprema, intercostalis sup. sin.
- v. azygos
- v. thoracica interna dx.
- viscerální větve orgánů horního předního mezihrudí

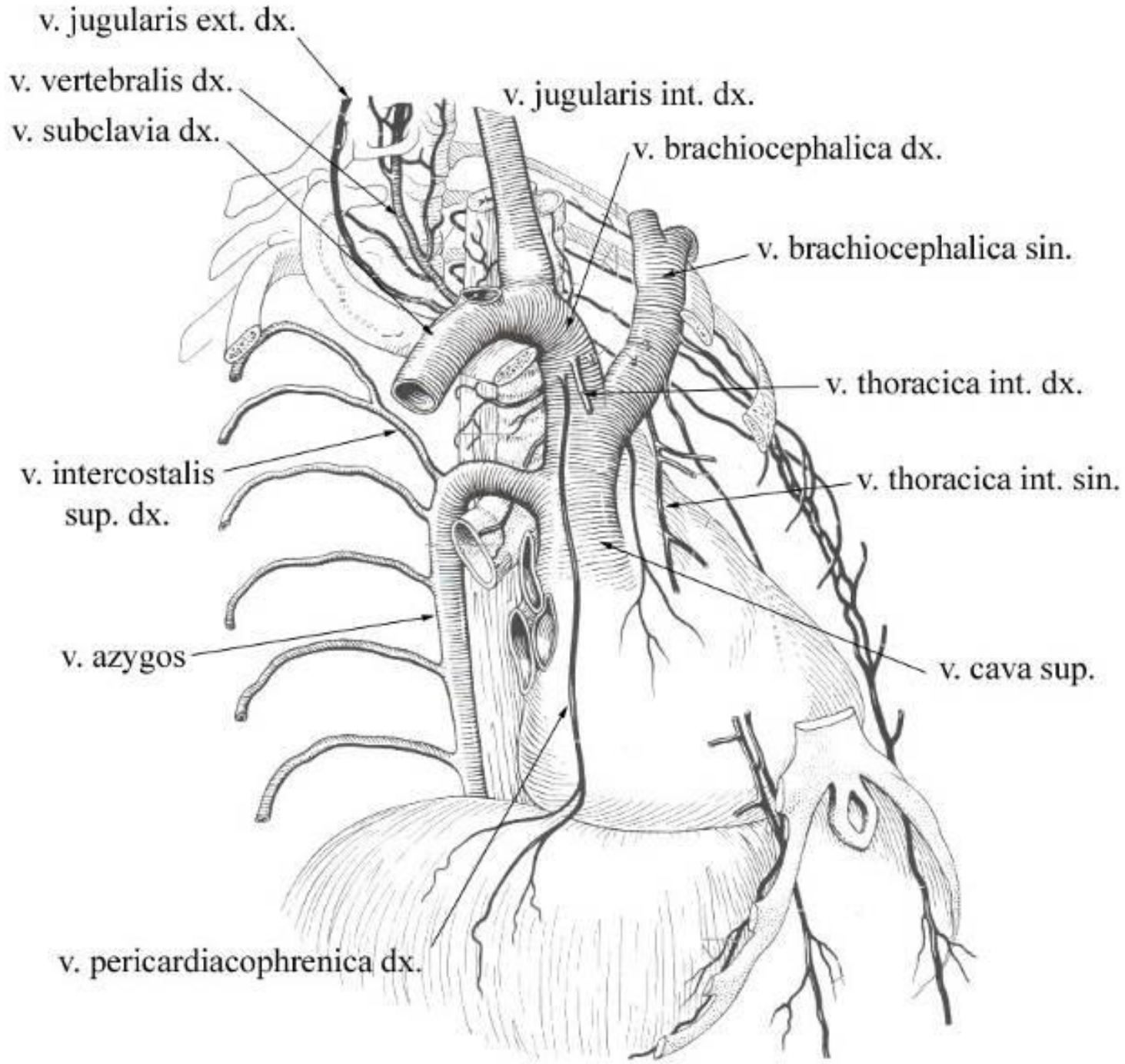
v. jugularis ext. dx.
v. vertebralis dx.
v. subclavia dx.
v. jugularis int. dx.
v. brachiocephalica dx.
v. brachiocephalica sin.
v. thoracica int. dx.
v. intercostalis sup. dx.
v. thoracica int. sin.
v. azygos
v. cava sup.
v. pericardiacophrenica dx.

Syndrom horní duté žíly

- uzávěr žíly trombem
- zúžení žíly nádorem

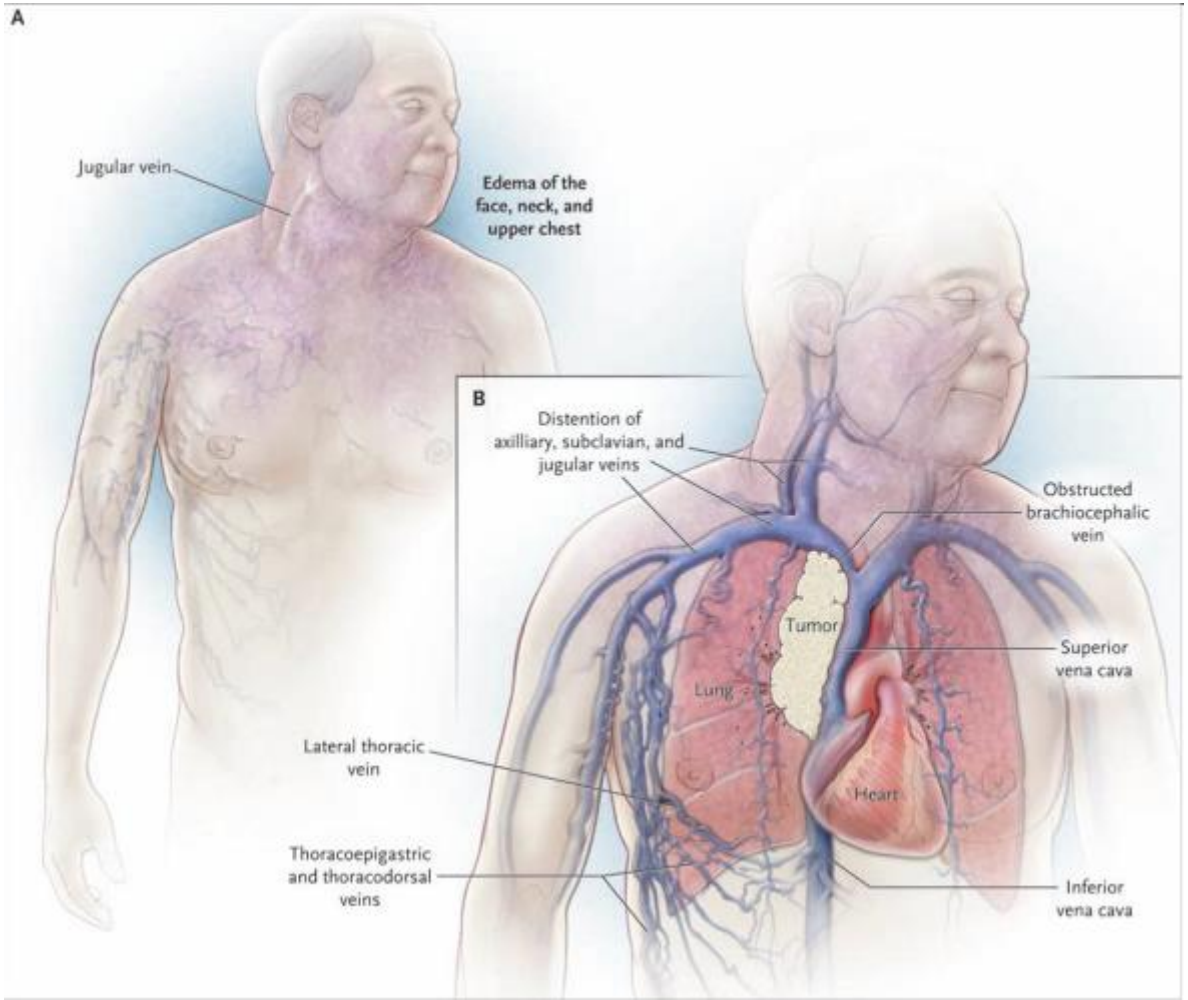

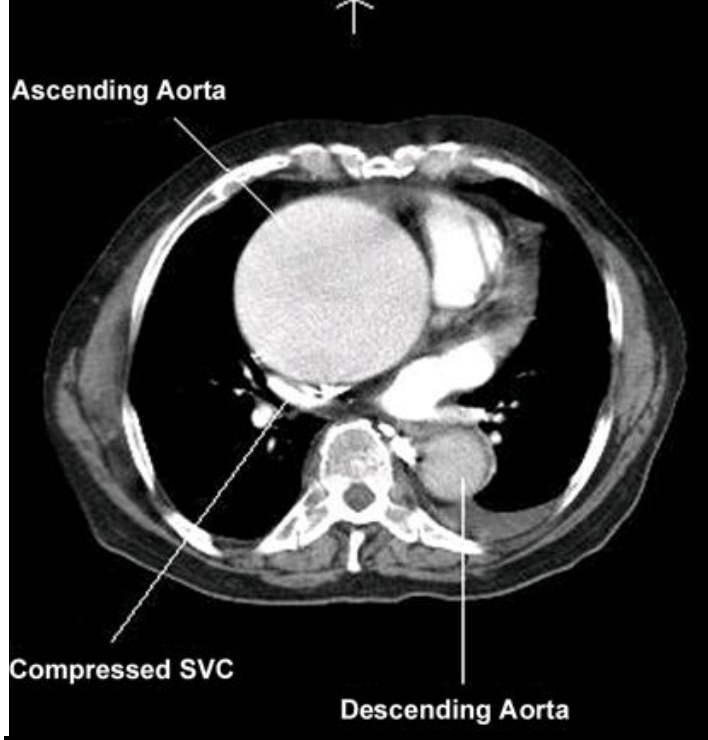

ANGULUS VENOSUS PIROGOVI

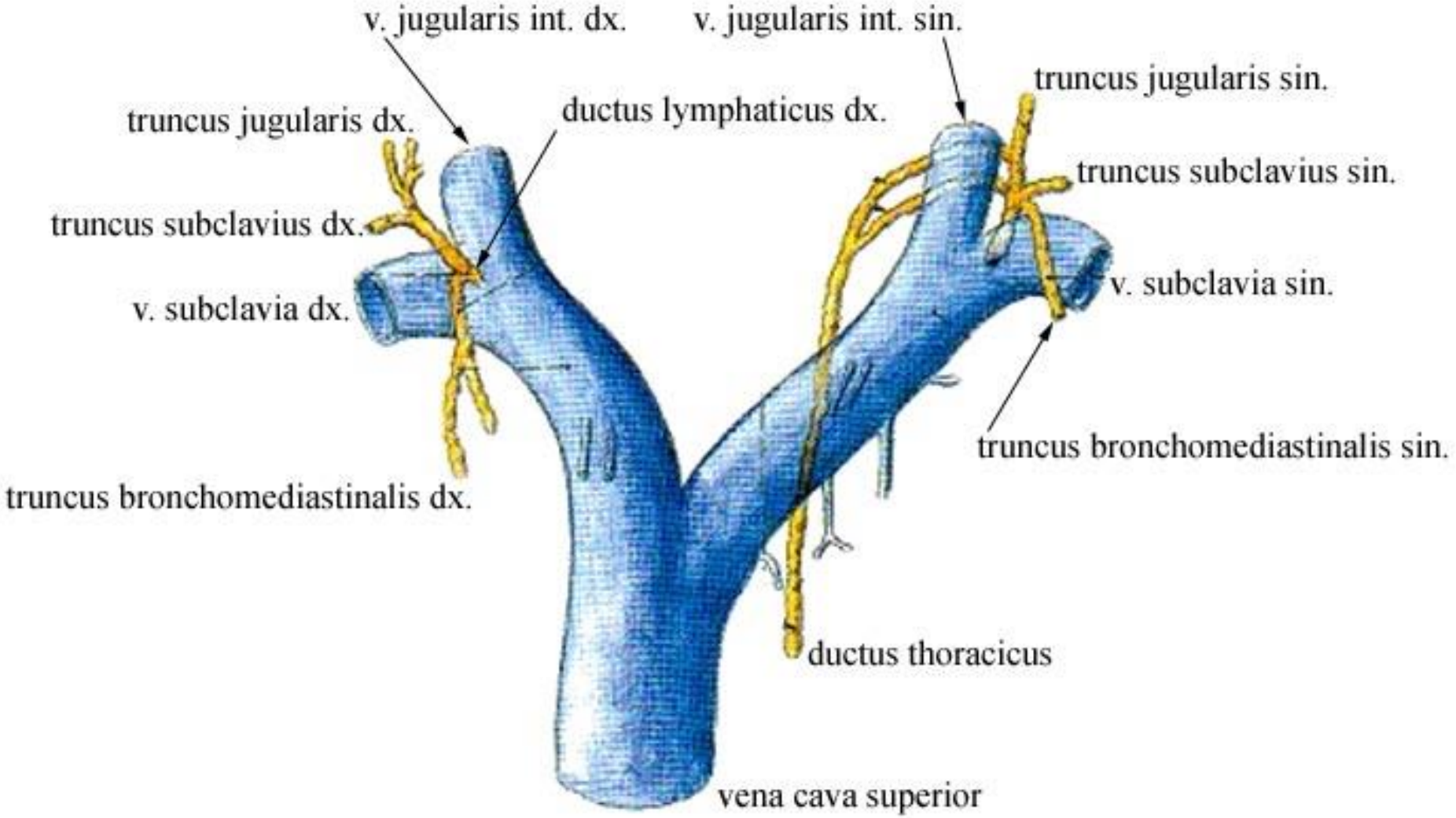

Vena jugularis interna

- bulbus superior – začátek
- bulbus inferior – konec
  - do angulus venosus
- vagina carotica
  - součást lamina pretrachealis fasciae cervicalis
- angulus venosus *Pirogovi*
  - *sinister*: ductus thoracicus
  - *dexter*: ductus lymphaticus dexter

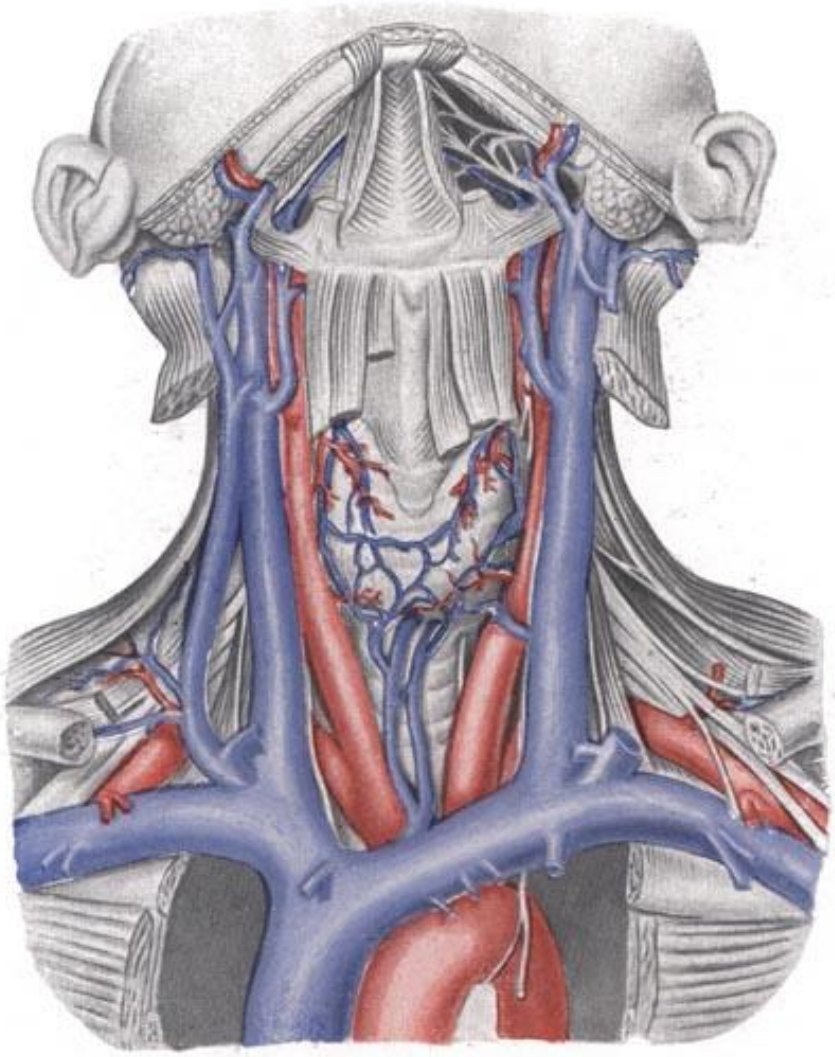

Vena jugularis interna - začátek

- sinus sigmoideus +
- sinus petrosus inferior

➔ **bulbus superior venae jugularis internae**

foramen jugulare

dorzolaterální část

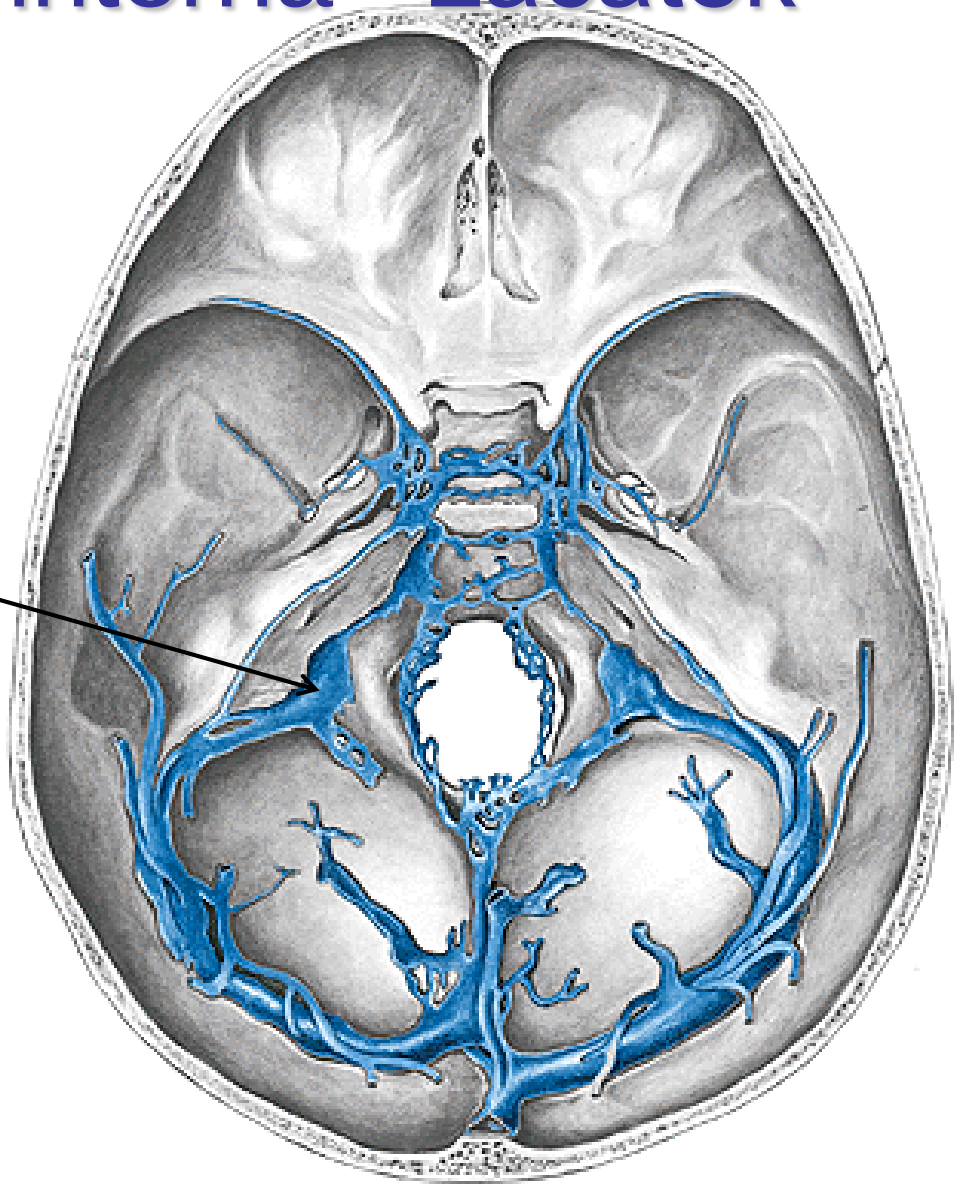

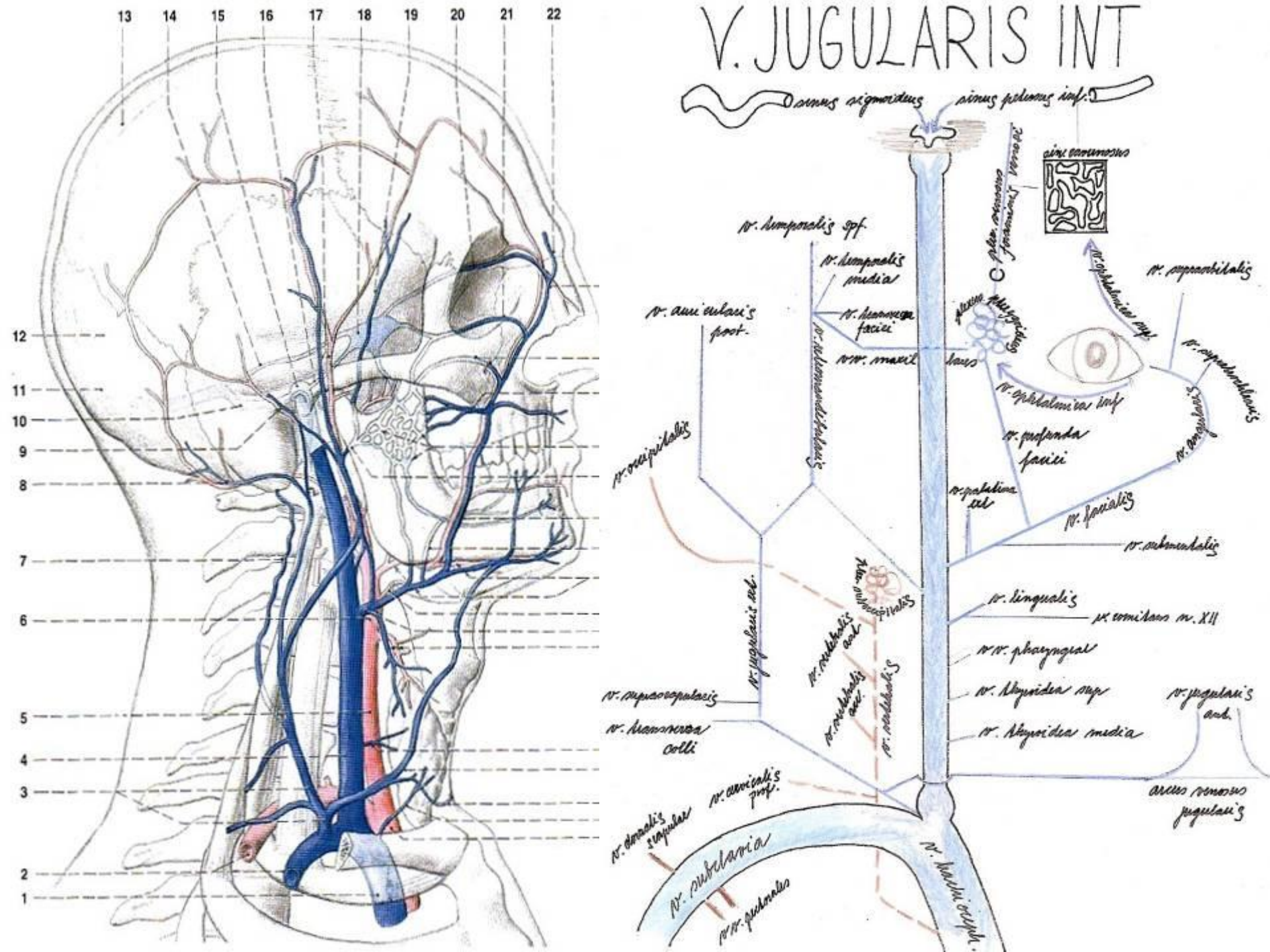
V. JUGULARIS INT
sinus sigmoideus
sinus petrosus inf.
sinus cavernosus
v. temporalis spf.
v. temporalis media
v. auricularis post.
v. transversa faciei
v.v. maxillares
v. ophtalmica sup.
v. ophtalmica inf.
v. profunda faciei
v. supraorbitalis
v. occipitalis
v. palatina ext.
v. facialis
v. submentalis
v. lingualis
v. comitans n. XII
v.v. pharyngeae
v. thyroidea sup.
v. thyroidea media
v. jugularis ant.
v. suprascapularis
v. transversa colli
v. cervicalis prof.
v. dorsalis scapulae
v. subclavia
v.v. pectorales
arcus venosus jugularis
v. jugularis ext.
v. vertebralis ant.
v. vertebralis acc.
v. vertebralis
v. retromandibularis
v. ophtalmica sup.
v. angularis
v. supratrochlearis
v. subcapitalis
13
14
15
16
17
18
19
20
21
22
12
11
10
9
8
7
6
5
4
3
2
1

Vena jugularis interna – přehled přítoků

nitrolebeční přítoky

- splavy (*sinus durae matris*)
- mozkové (*vv. cerebri*)
- plenové (*vv. meningeae*)
- píchatkové (*vv. diploicae*)
- bludišťové (*vv. labyrinthi*)
- výtokové (*vv. emissariae*)
- oční (*vv. ophthalmicae)*

mimolebeční přítoky

– obličejové
  - v. retromandibularis
  - v. facialis
  - v. lingualis

– povrchové krční
  - v. jugularis ext.
  - v. jugularis ant.

– hluboké krční
  - vv. pharyngeae
  - vv. thyroideae

Vena jugularis interna + externa

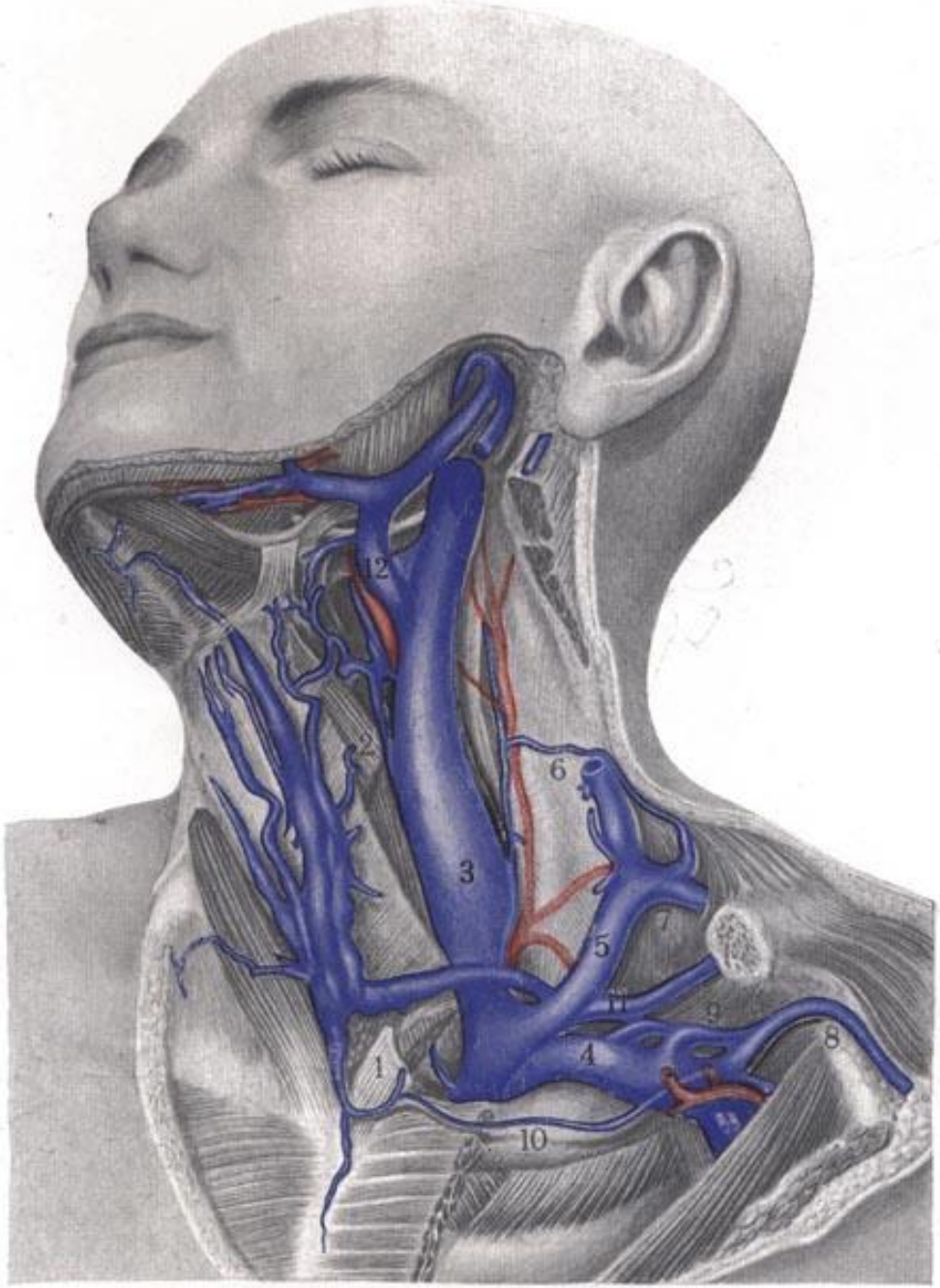

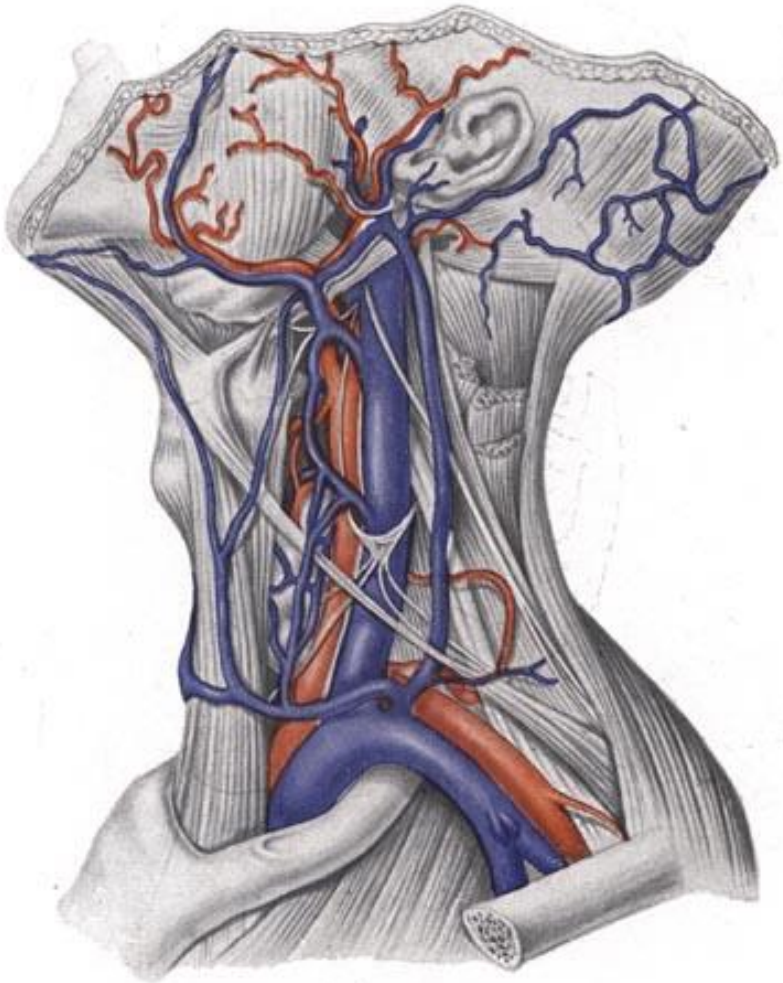

Skupiny přítoků vnitřní hrdelní žíly 1.

- **sinus durae matris**

!!! *stěnu tvoří tvrdá plena* ***!!!***

confluens sinuum

(= *torcular Herophili)*

chordae *Willisi*

<u>nepárové:</u>

s. sagittalis sup. (1)

s. sagittalis inf. (2)

s. rectus (3)

s. occipitalis (6)

plexus basilaris (8)

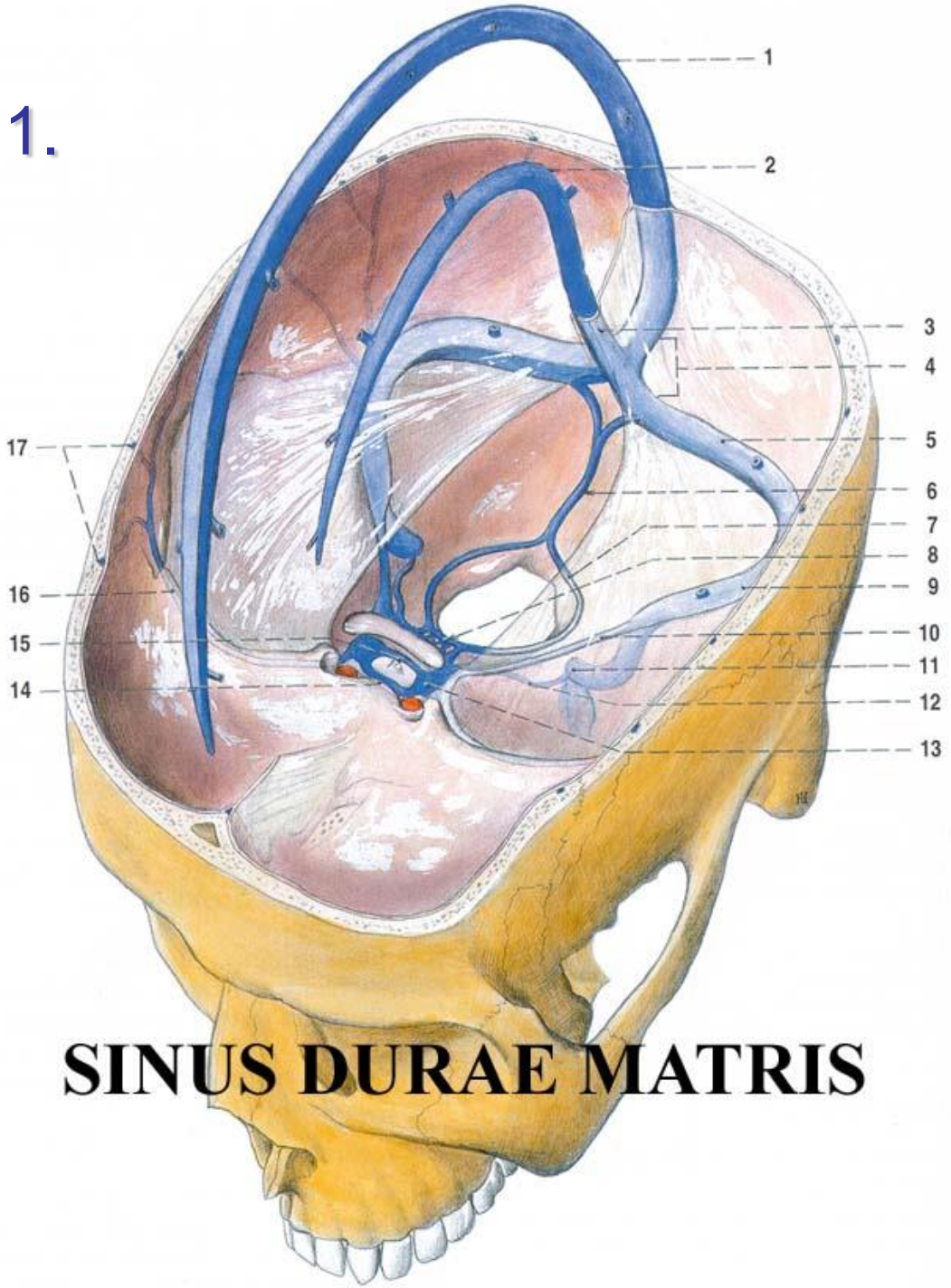

Sinus durae matris

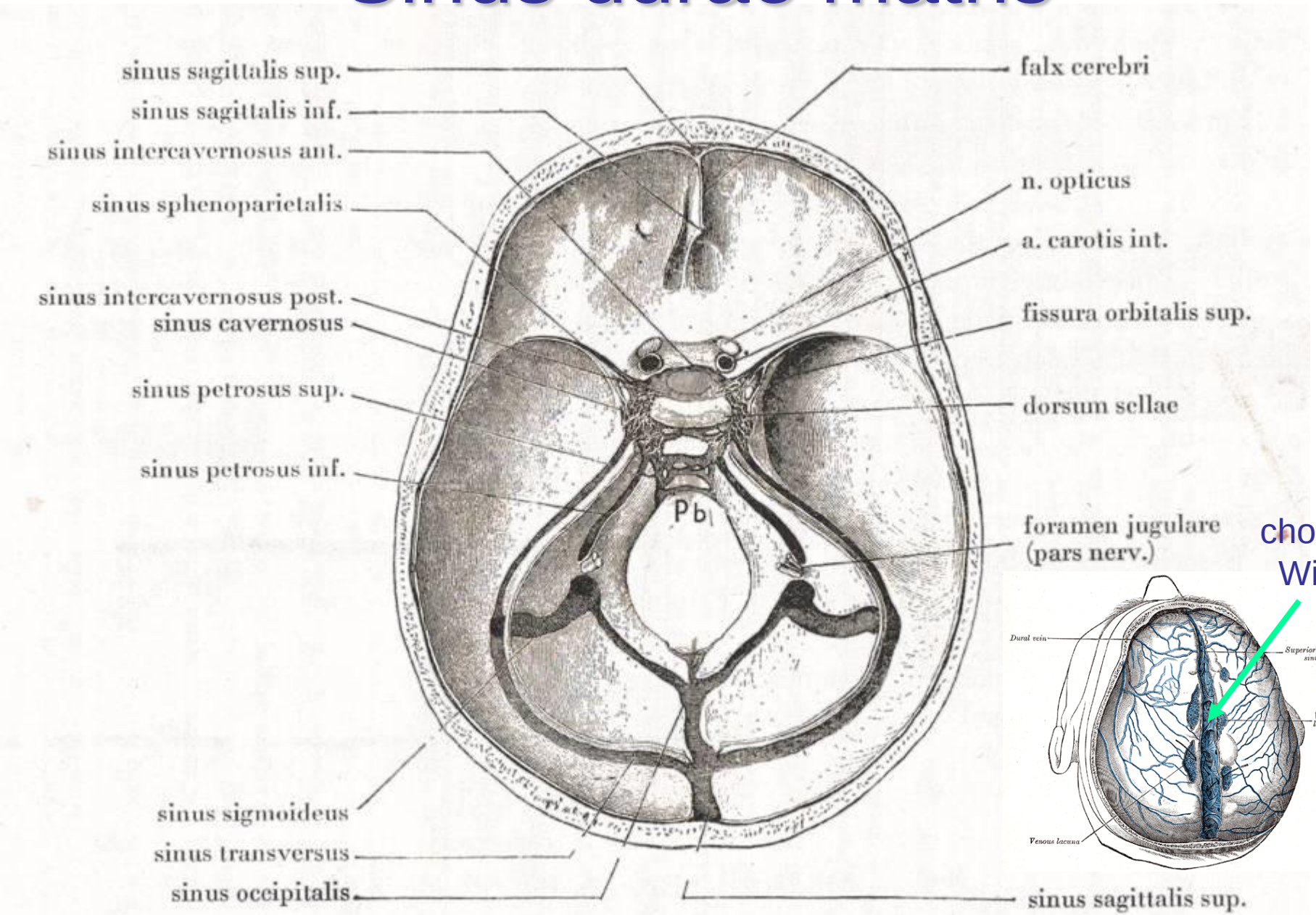

chordae Willisi

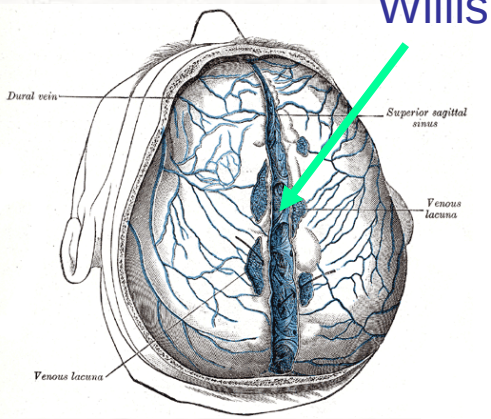

Skupiny přítoků vnitřní hrdelní žíly 2.

<u>párové:</u>

- **s. transversus** (5)
- **s. sigmoideus** (11)
- **s. petrosus sup.**(10)
- **s. petrosus inf.** (12)
- **s. marginalis** (7)
- **s. cavernosus** (13)
- **s. intercavernosus ant.** (14)
- **s. intercavernosus post.** (15)
- **s. sphenoparietalis** (16)
- **s. petrosquamosus**

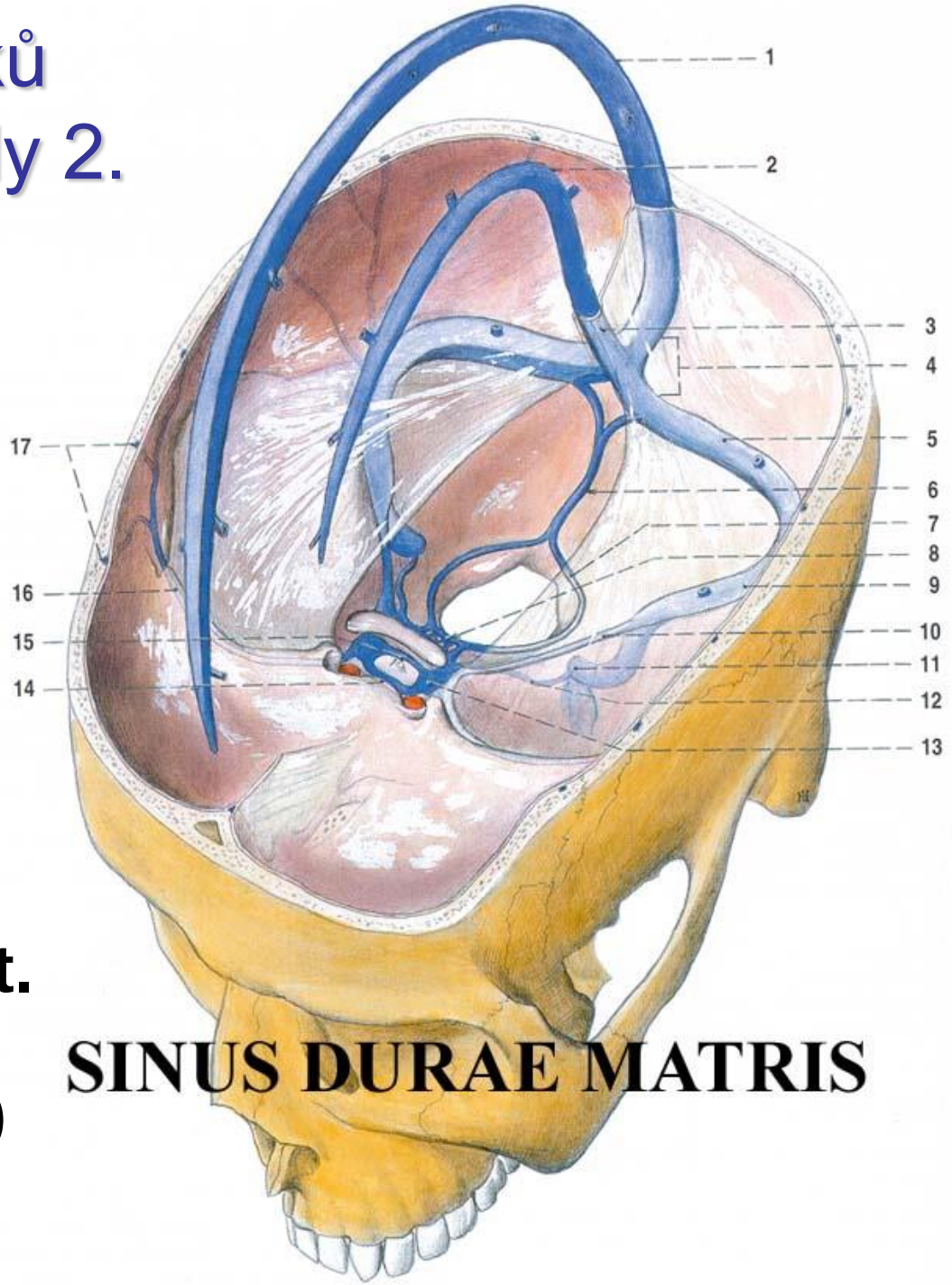

Sinus cavernosus

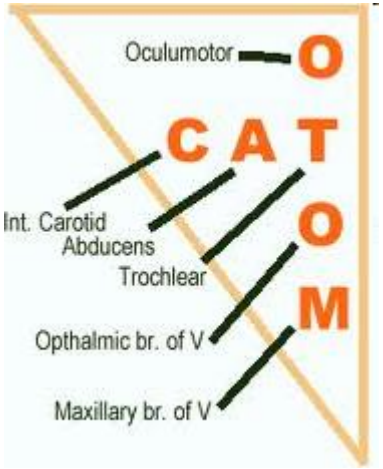

- po stranách tureckého sedla
- dutinky (mnoho chordae Willisi)

mediálně:

- a. carotis int.
- n. VI.

laterálně:

- n. III
- n. IV
- n. V1
- n. V2

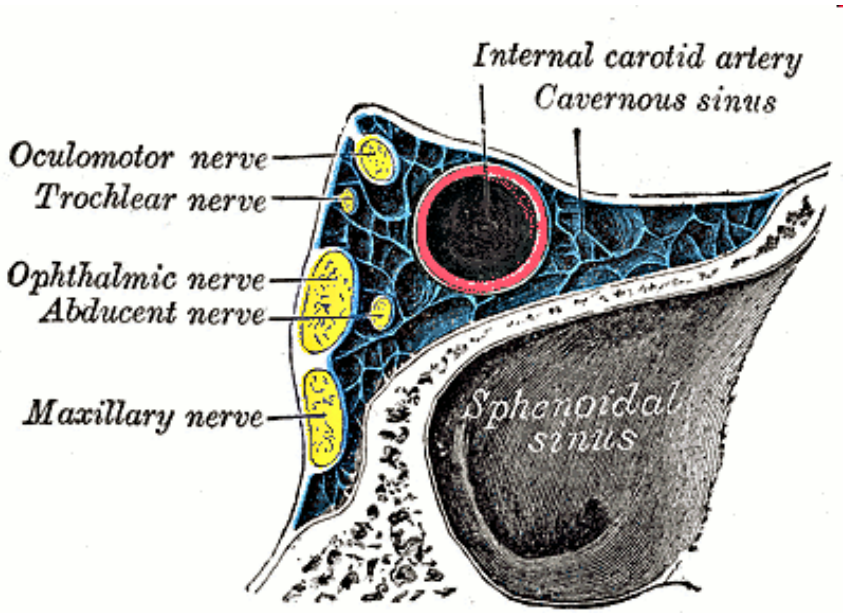

trombóza, šíření infekce přes očnici

Sinus cavernosus

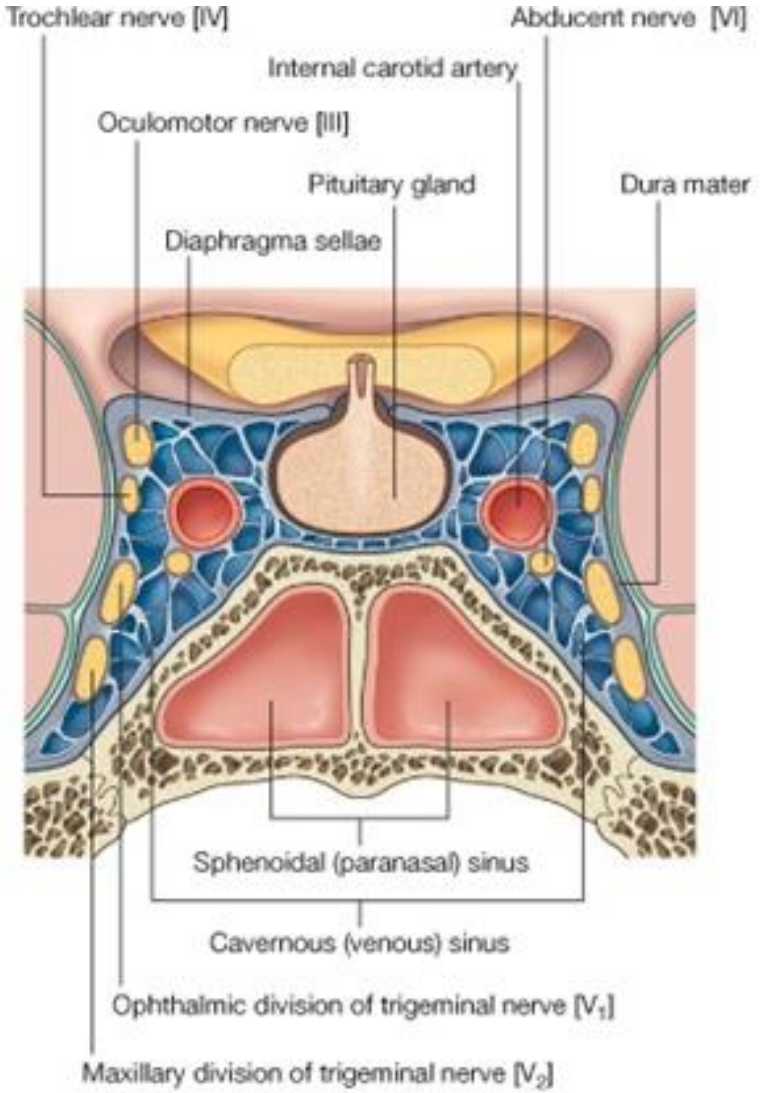

© Elsevier. Drake et al: Gray's Anatomy for Students - www.studentco

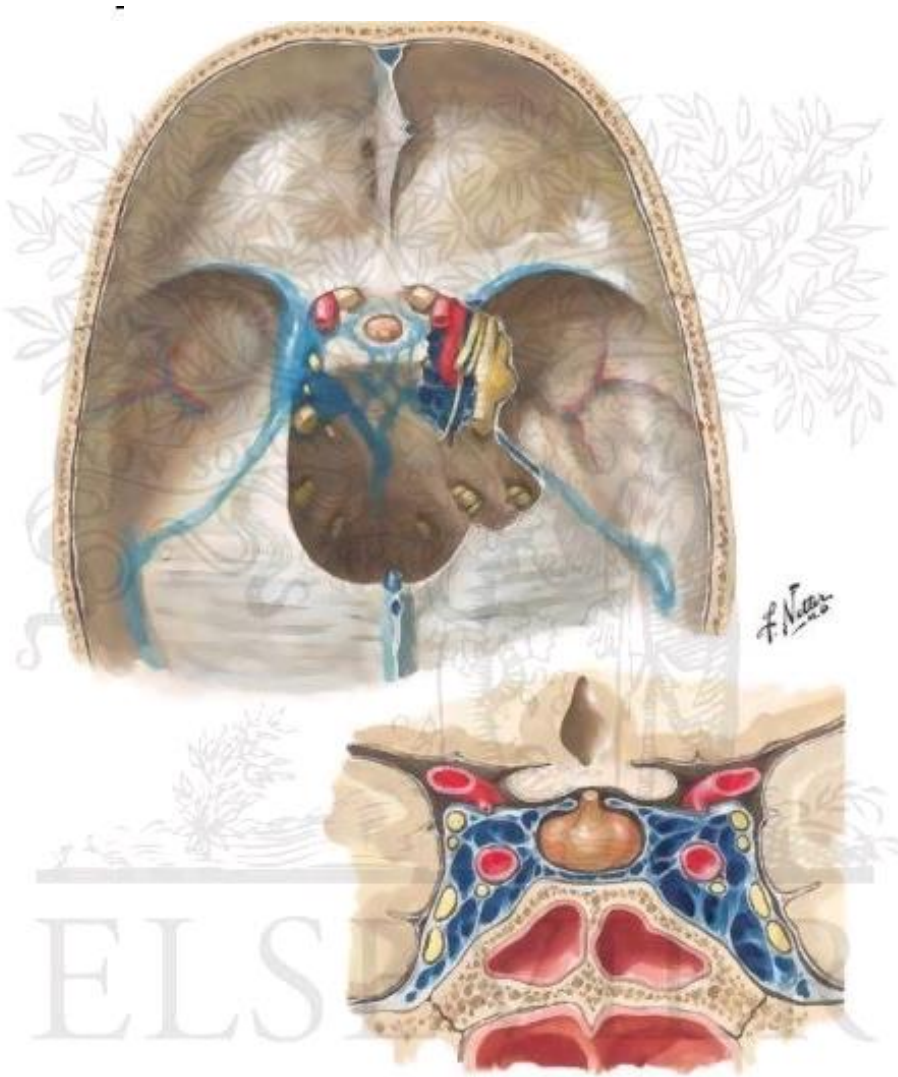

© ELSEVIER, INC. – NETTERIMAGES.COM

Sinus cavernosus spojení a odtok krve

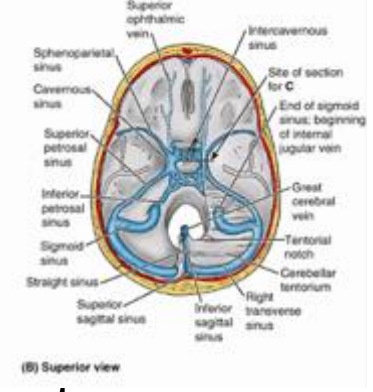

- vv. temporales profundae → v. diploica temp. ant. → sinus sphenoparietalis → SC
- SC → sinus petrosus sup. → sinus transversus
- SC → sinus petrosus inf. → bulbus VJI
- SC → plexus basilaris → sinus marginales → plexus venosus suboccipialis → vv. vertebrales
- SC → plexus venosus caroticus int. → VJI
- **SC → plexus venosus foraminis ovalis → plexus pterygoideus** → v. maxillaris → v. retromandibularis
- **SC → v. ophthalmica sup**. → v. angularis → v. facialis
- SC → v. ophthalmica inf. → plexus pterygoideus
- *šíření infekce opačným směrem*

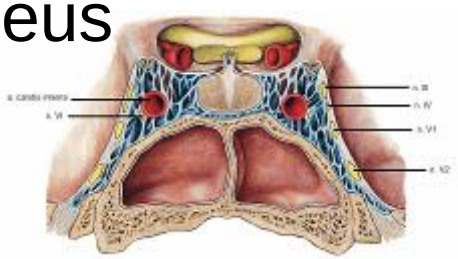

Trombóza (tromboflebitída) sinus cavernosus „trigonum mortis“

Skupiny přítoků vnitřní hrdelní žíly 3.

- **vv. cerebri**:
  - povrchové (do splavů)
    - subdurální krvácení
  - hluboké (do vena cerebri magna *Galeni)*
- **vv. meningeae**
  - odpovídají tepnám
- **vv. diploicae**
  - 4 skupiny
  - nemají žilní stěnu
- **vv. labyrinthi**
  - odpovídají tepnám
- **vv. emissariae**
  - spojky nitrolebečních a mimolebečních žil

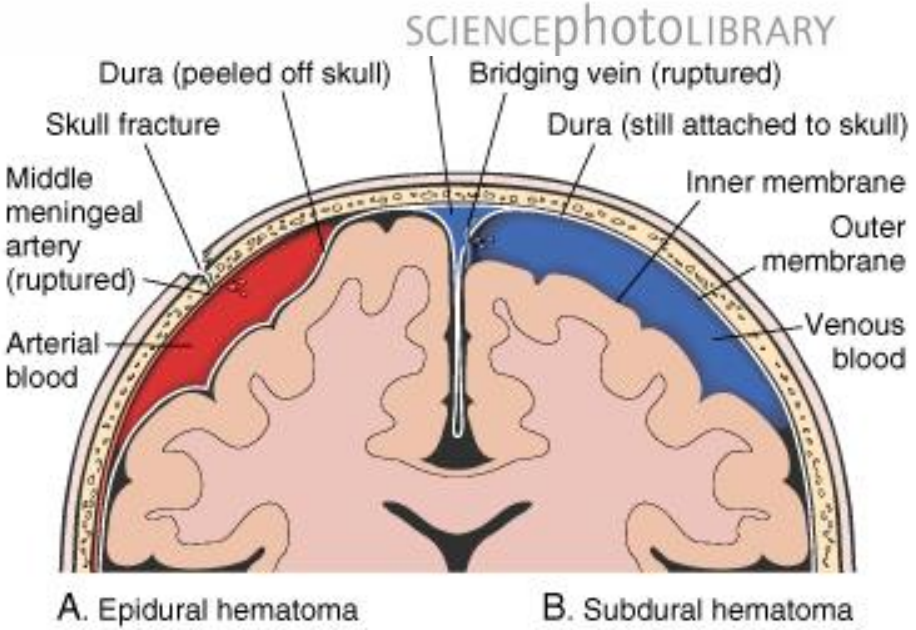

© Elsevier Ltd. Kumar et al: Basic Pathology 7E www.studentconsult.com

Venae cerebri

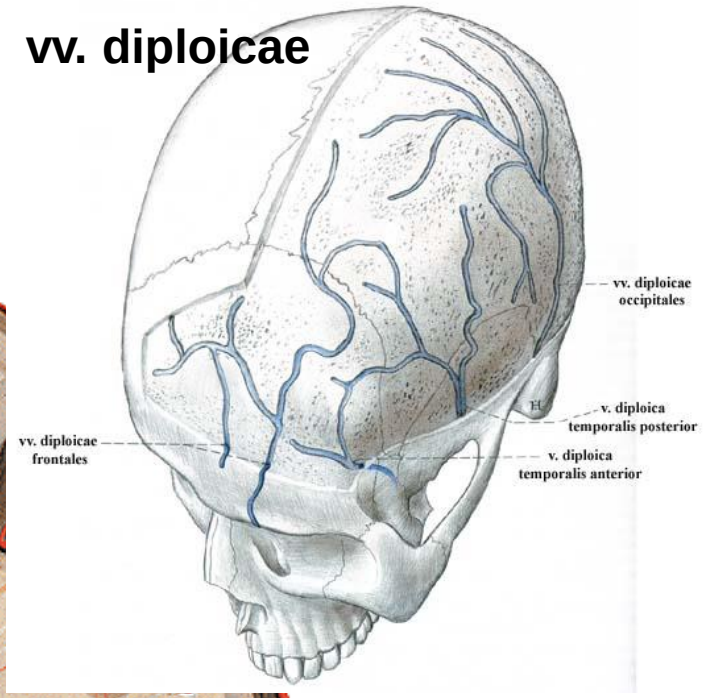

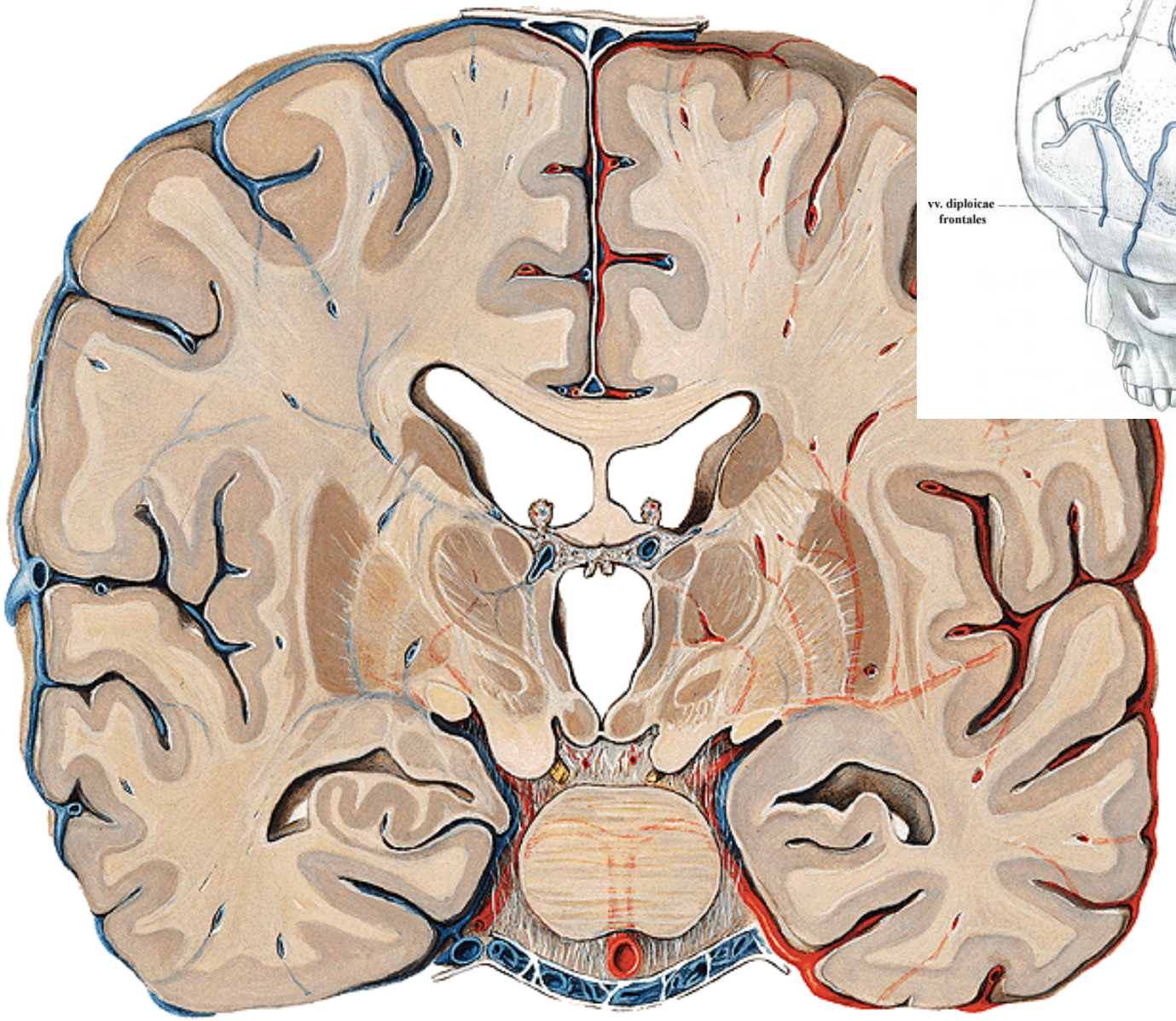

Skupiny přítoků vnitřní hrdelní žíly 4. - **vv. emissariae**

- v. emissaria (výtoková žíla)
  - parietalis
  - mastoidea
  - condylari
  - occipitalis
  - (foraminis venosi Vesalii)
  - (foraminis caeci) 1 %
- plexus venosus
  - canalis n. hypoglossi
  - foraminis ovalis
  - caroticus internus
- další
  - vv. ophthalmicae

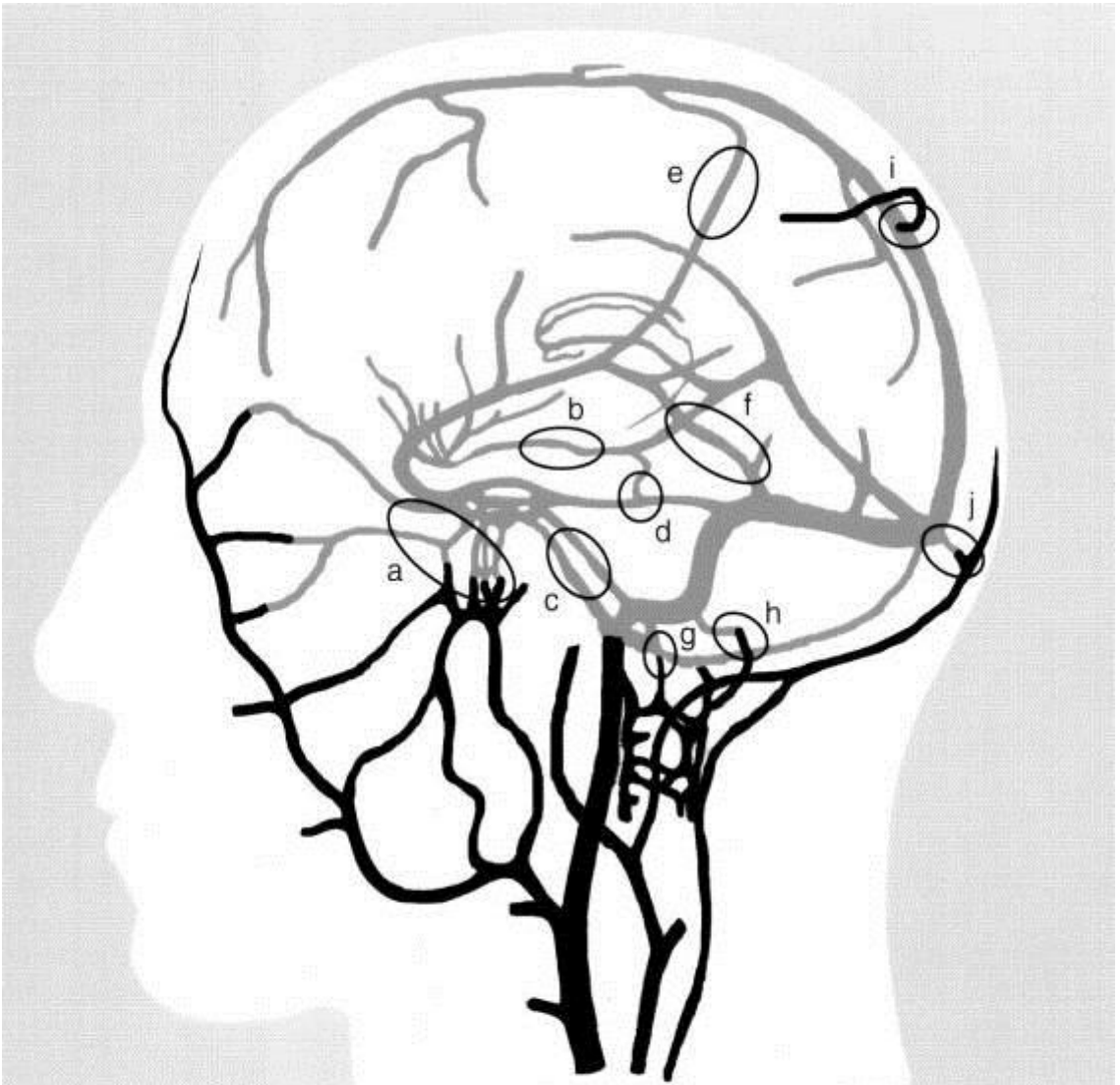

Venous collateral circulation. Shown are:
pterygoid plexus (a), deep middle cerebral vein (b),inferior petrosal sinus and basilar plexus (c),
superior petrosal sinus (d), anastomotic vein of Trolard (e), anastomotic vein of Labbé (f),
condyloid emissary vein (g), mastoid emissary vein (h), parietal emissary vein (i), and occipital emissary vein (j).

Vv. emissariae

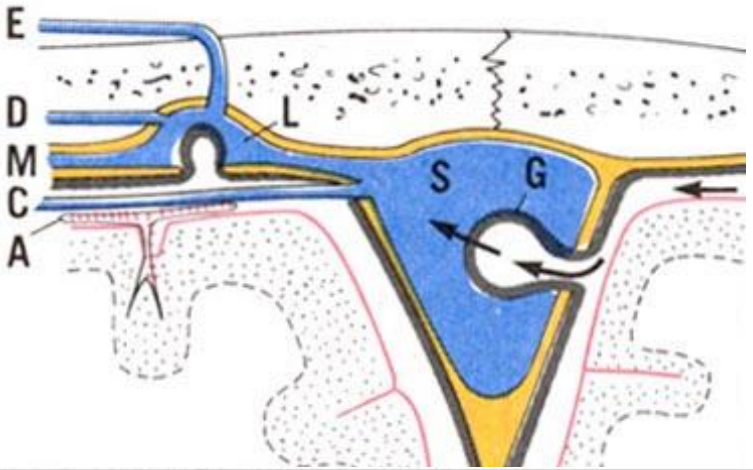

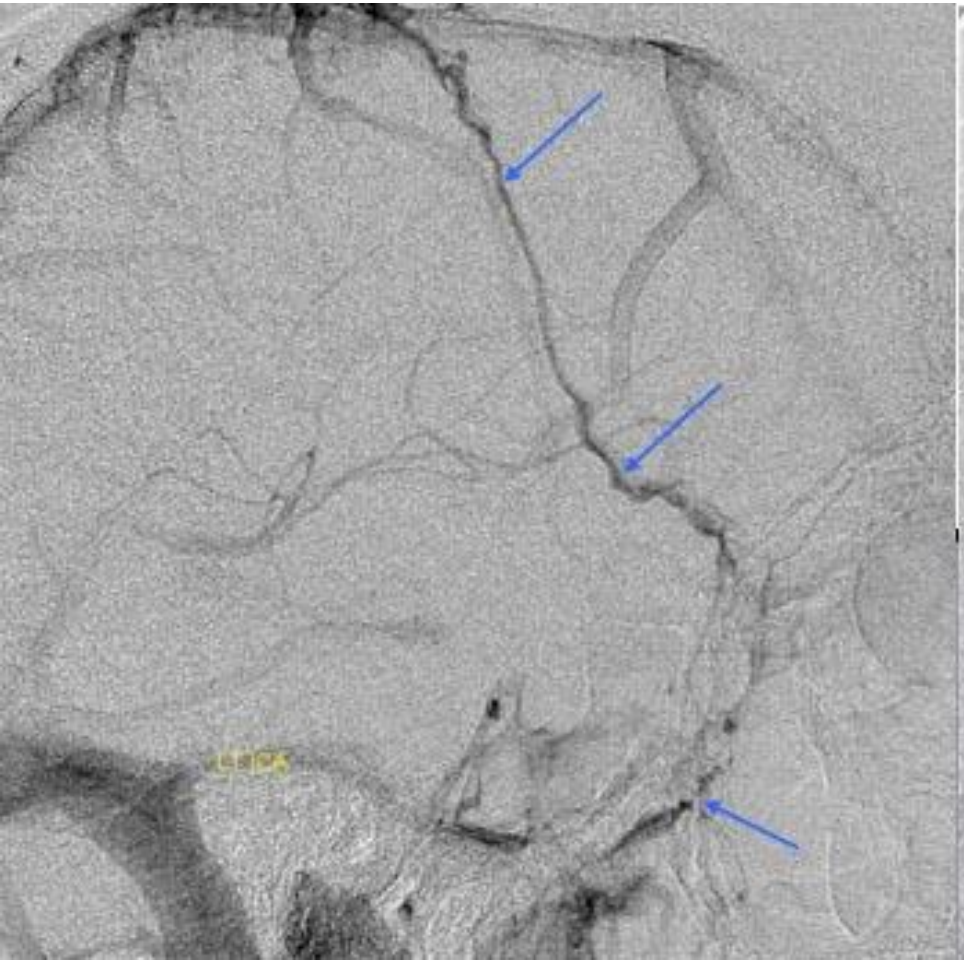

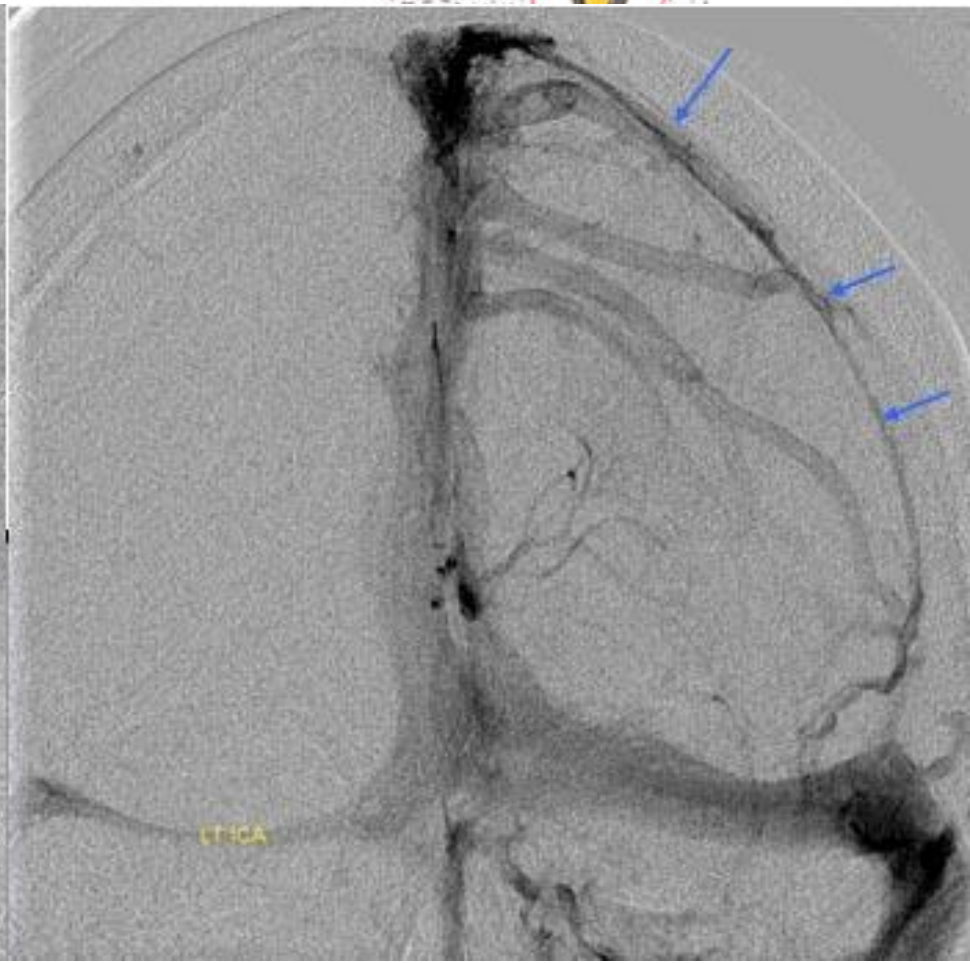

Skupiny přítoků vnitřní hrdelní žíly 5.

- vv. ophthalmicae
  - superior
  - inferior
- v. retromandibularis
  - plexus pterygoideus
- v. facialis
  - v. profunda faciei
- v. lingualis
  - v. comitans n. hypoglossi
- vv. pharyngeae: plexus venosus pharyngeus
- vv. thyroideae: sup. + media *Kocheri*

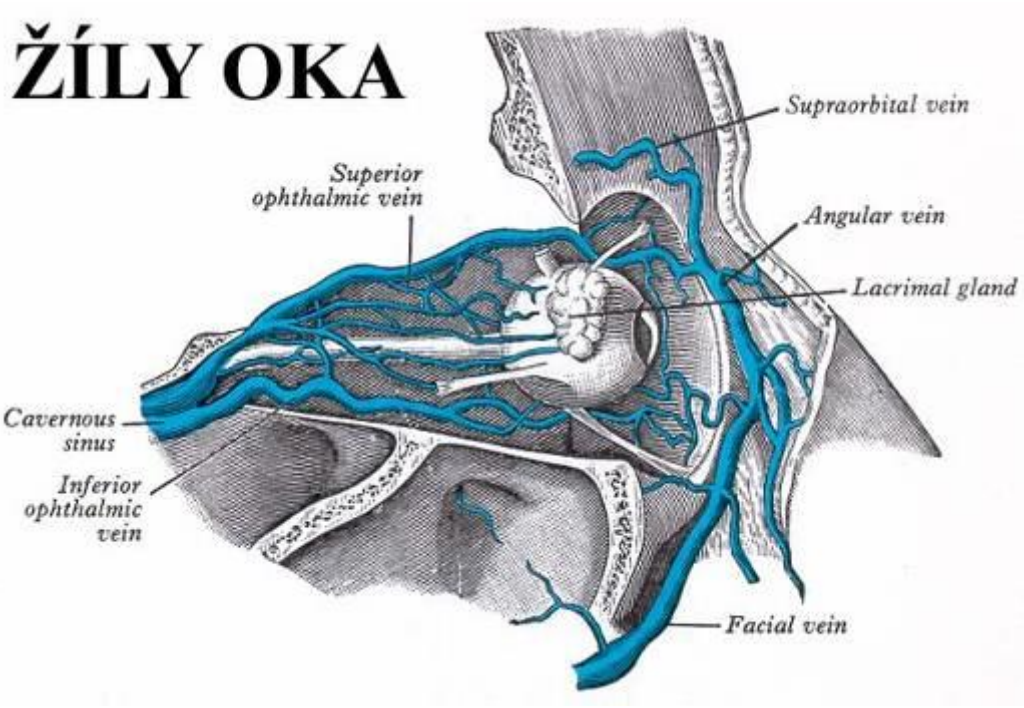

Povrchové žíly hlavy

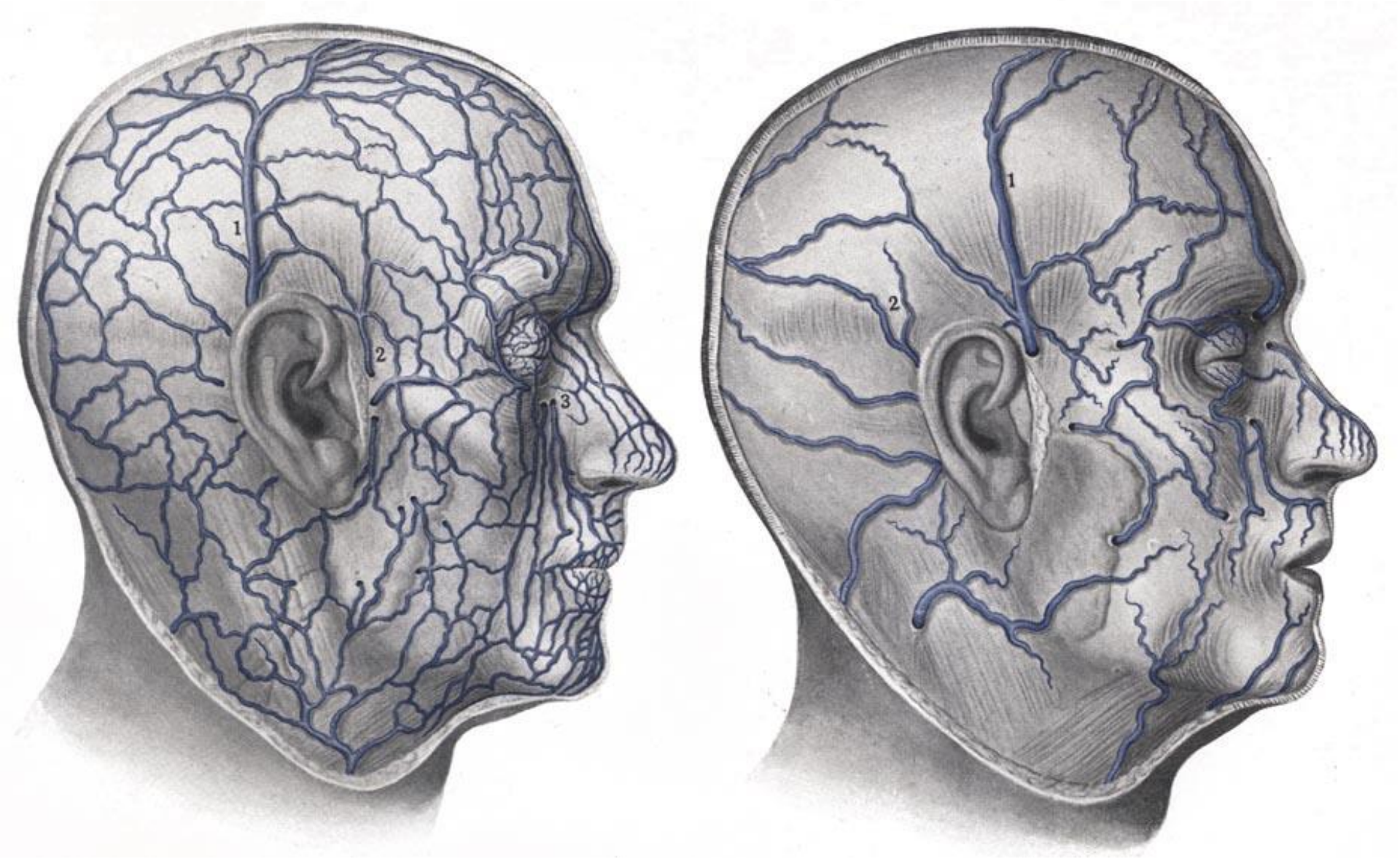

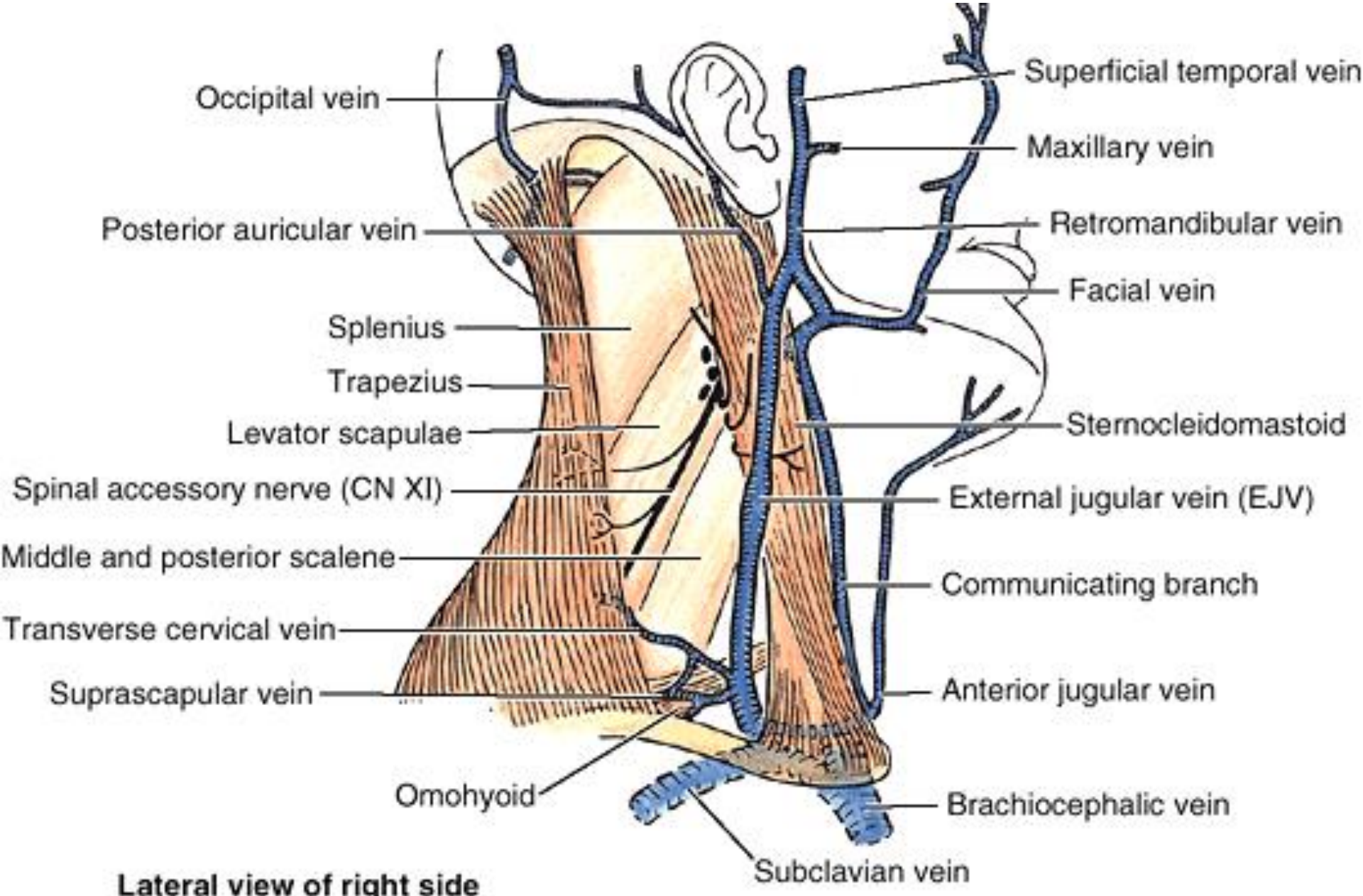

Lateral view of right side

Skupiny přítoků vnitřní hrdelní žíly 6.

povrchové žíly krku

mezi platysmatem a lamina superficialis fasciae cervicalis

- v. jugularis externa
  - v. auricularis post.
  - zadní větvení v. retromandibularis
  - konec: angulus venosus
- v. jugularis anterior
  - soutok povrchových podčelistních žil
  - arcus venosus jugularis (*!tracheotomia inferior!*)
  - konec: v. jugularis ext.

měnlivé vyústění do oblasti angulus venosus !

ŽÍLY HLAVY

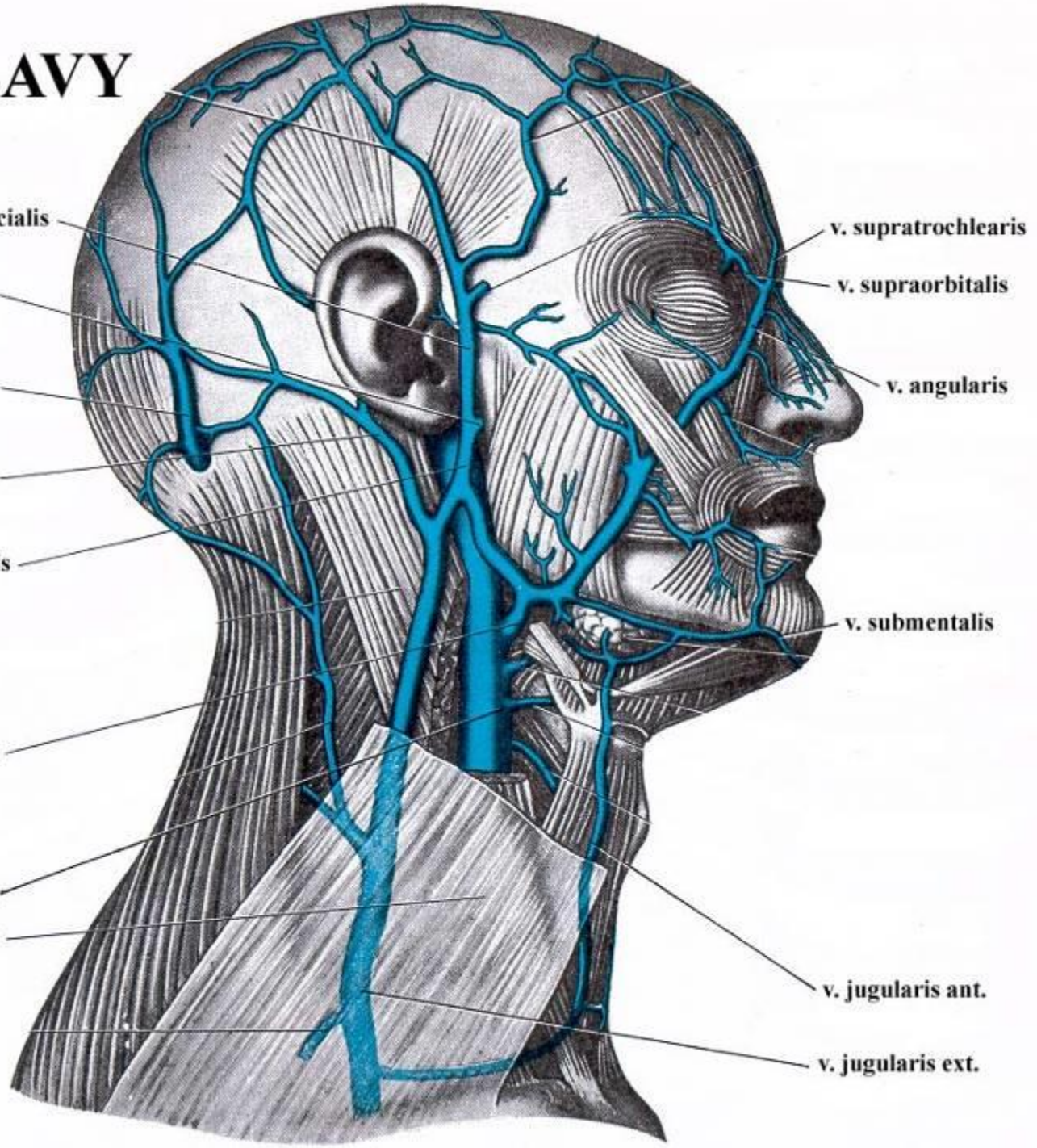
v. temporalis superficialis
v. maxillaris
v. occipitalis
v. auricularis post.
v. retromandibularis
v. facialis
v. jugularis int.
m. platysma
v. supratrochlearis
v. supraorbitalis
v. angularis
v. submentalis
v. jugularis ant.
v. jugularis ext.

Hluboké žíly obličeje

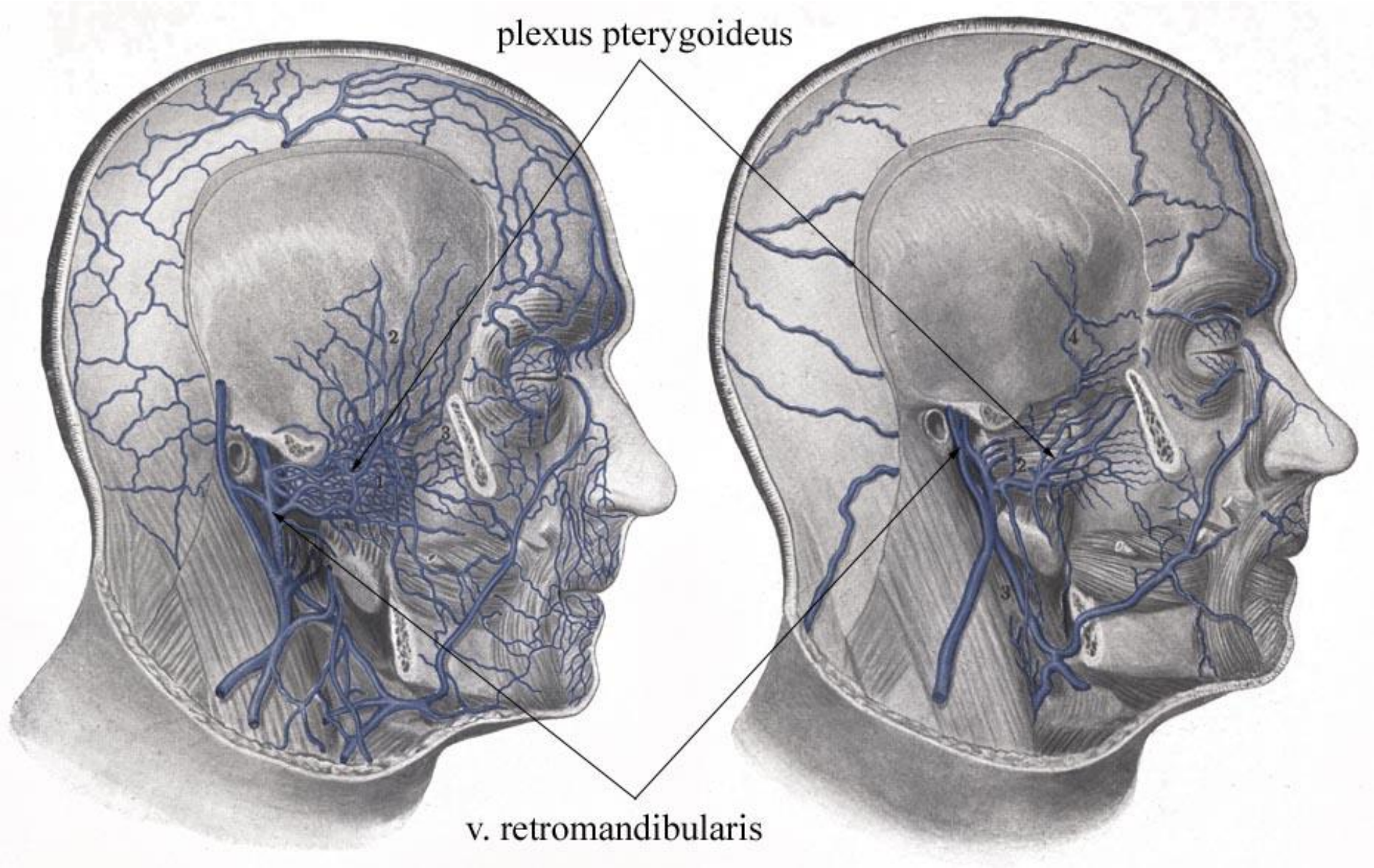

ŽÍLY HLOUBKY OBLIČEJE

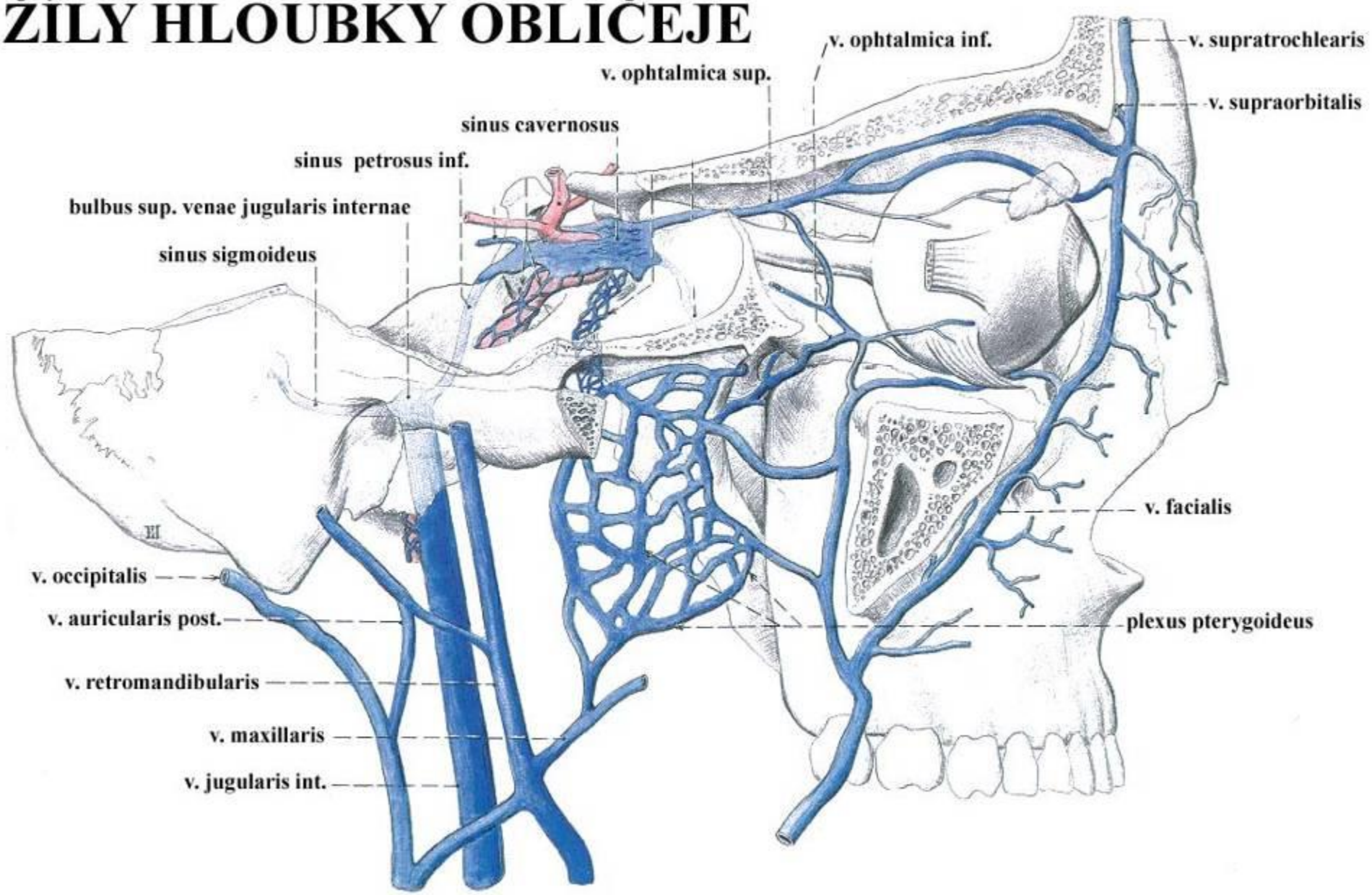

Cesty šíření infekce žílami hlavy

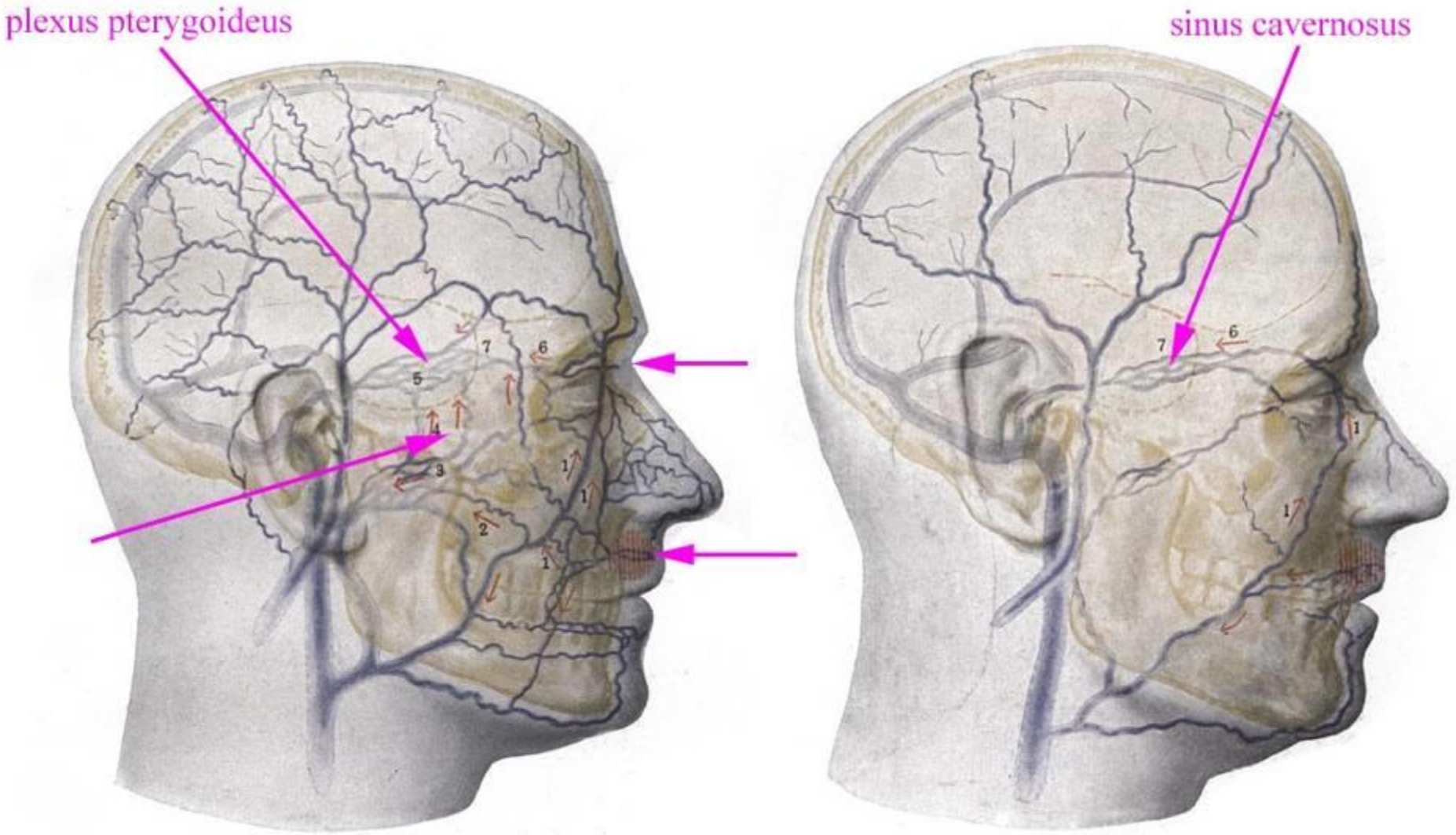

Riziko vzduchové embólie do krčních žil

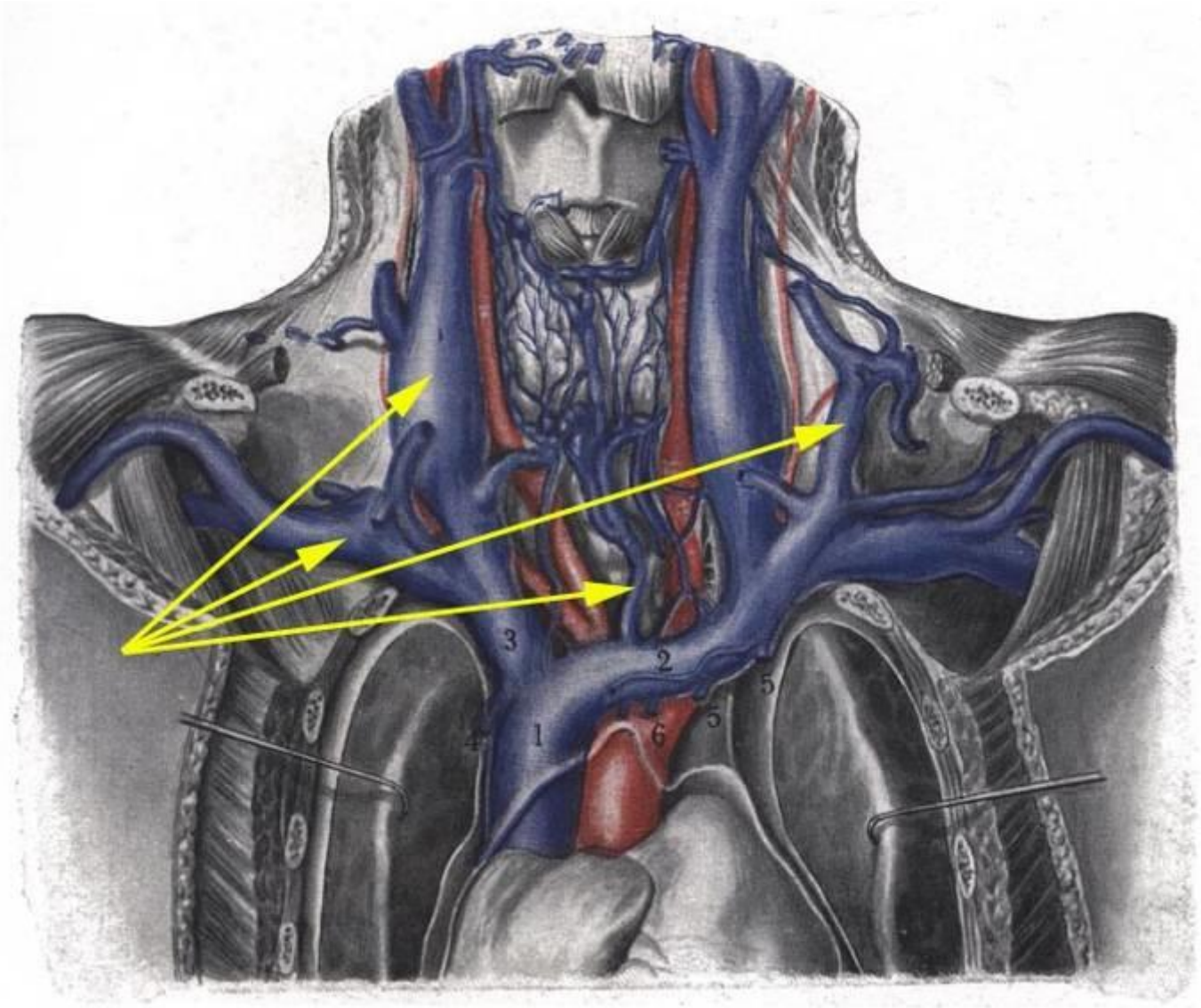

Centrální žilní katetrizace

- **v. jugularis int.**
- **v. subclavia** – infraklavikulárně *(méně supraklavikulárně)*
- v. femoralis (urgentní vstup)
- v. axillaris, v. mediana cubiti, v. jugularis ext.
- v. umbilicalis (novorozenci)
- <u>komplikace</u>: infekce, pneumothorax, hemothorax, poranění plexus brachialis, vzduchová embólie

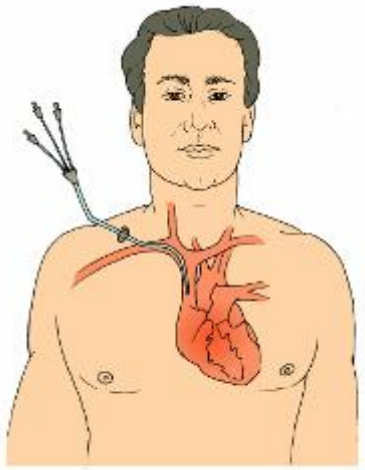

Figure 46-10 Placement of triple-lumen nontunneled percutaneous central venous catheter.

Copyright © 2005 Lippincott Williams & Wilkins. Instructor's Resource CD-ROM to Accompany Fundamentals of Nursing: The Art and Science of Nursing Care, 5th

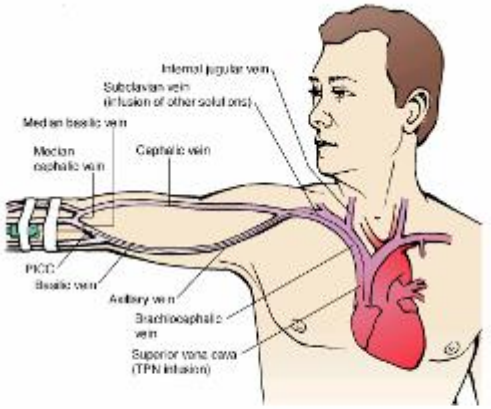

Figure 46-9 Placement of peripherally inserted central catheter (PICC).

Copyright © 2005 Lippincott Williams & Wilkins. Instructor's Resource CD-ROM to Accompany Fundamentals of Nursing: The Art and Science of Nursing Care

Centrální žilní katetrizace

- **dlouhodobý žilní vstup**
- nekolabují při šoku
- sledování centrálního žilního tlaku
- velké objemové náhrady
- aplikace parenterální výživy
- podávání katecholaminů, podávání látek dráždících žilní stěnu (cytostatika, glukóza), vysokoosmolárních roztoků
- dialýza

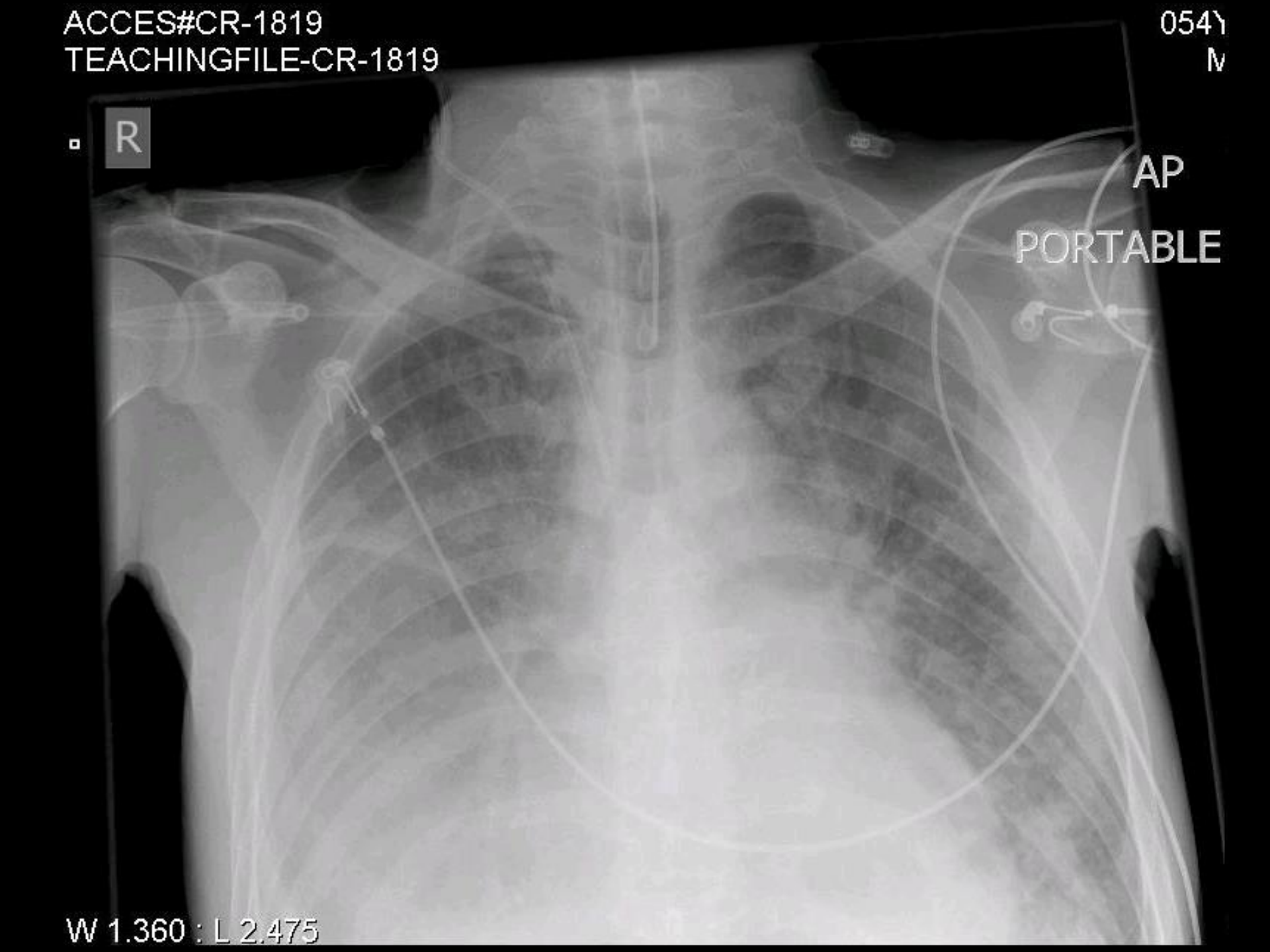
ACCES#CR-1819
TEACHINGFILE-CR-1819
R
AP
PORTABLE
W 1.360 : L 2.475

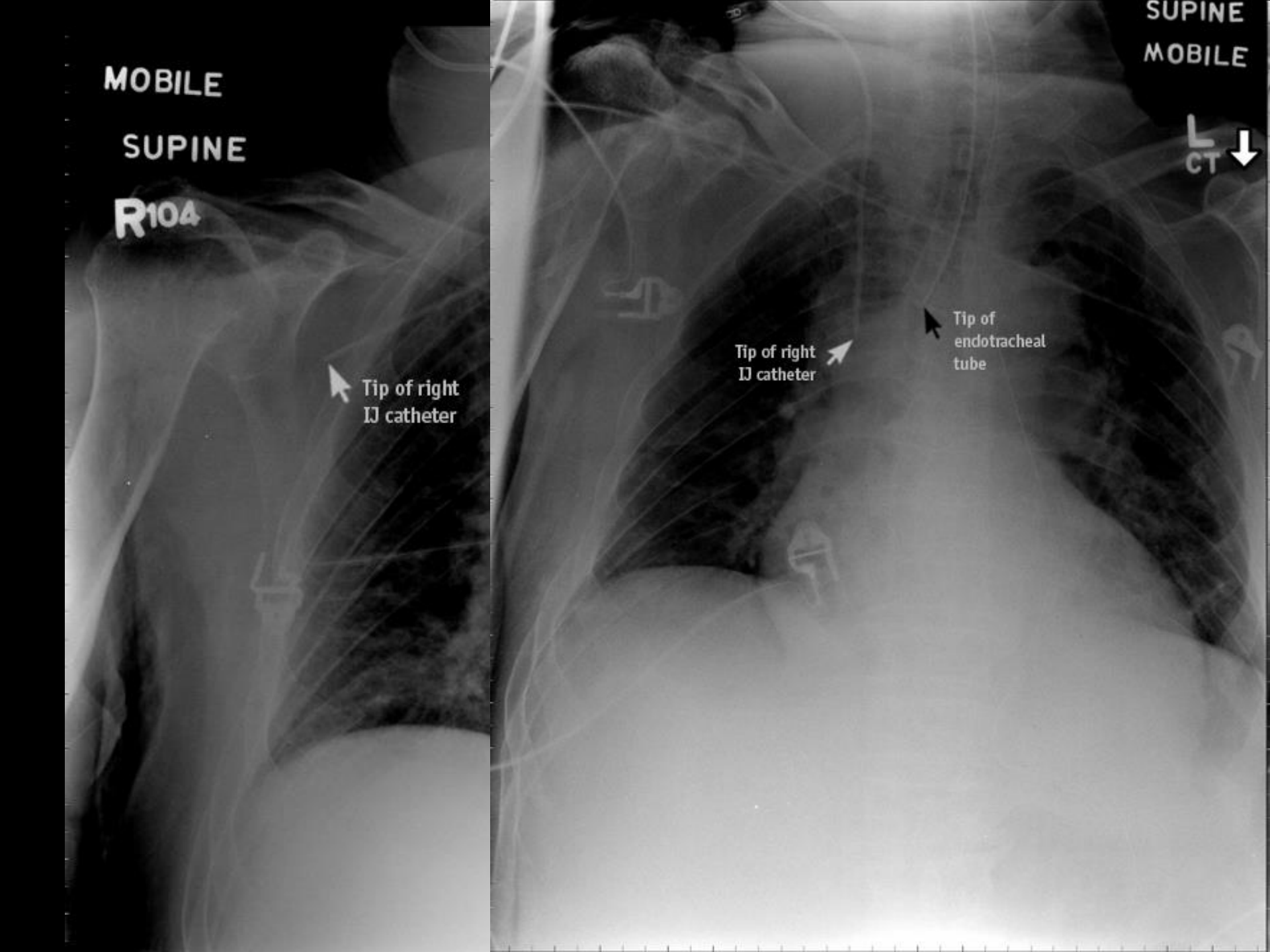
MOBILE
SUPINE
R104
Tip of right
IJ catheter
SUPINE
MOBILE
L
CT
Tip of right
IJ catheter
Tip of
endotracheal
tube

A-V píštěl

- iatrogenní
- dialýza
- radiocefalická
- (ulnarocefalická, brachiocefalická, brachiobazilická)
- (DK: tibiosafenózní)
- radiocefalická se štěpem
- tunelizovaná centrální

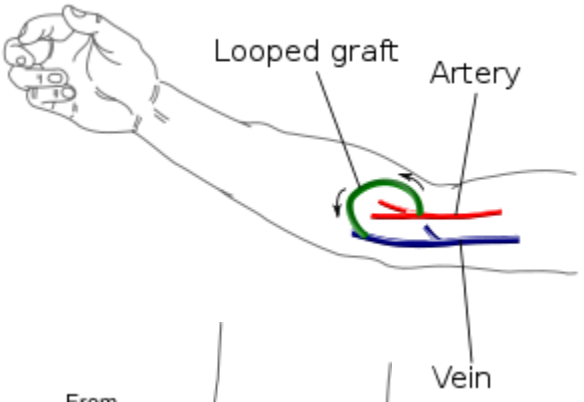

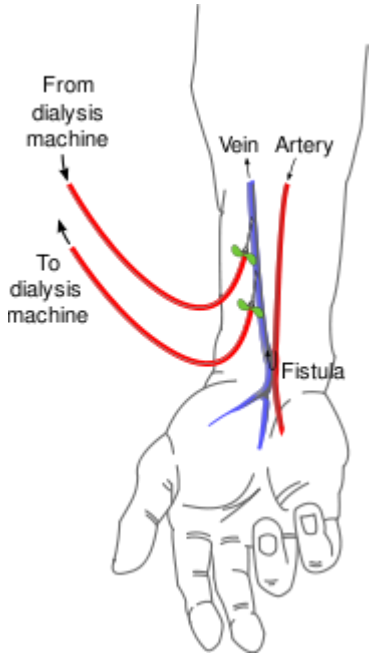

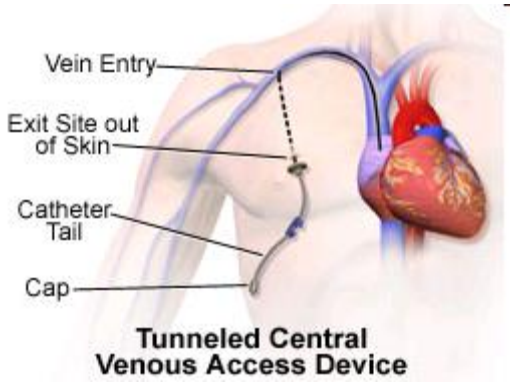

Radiocefalická A-V píštěl

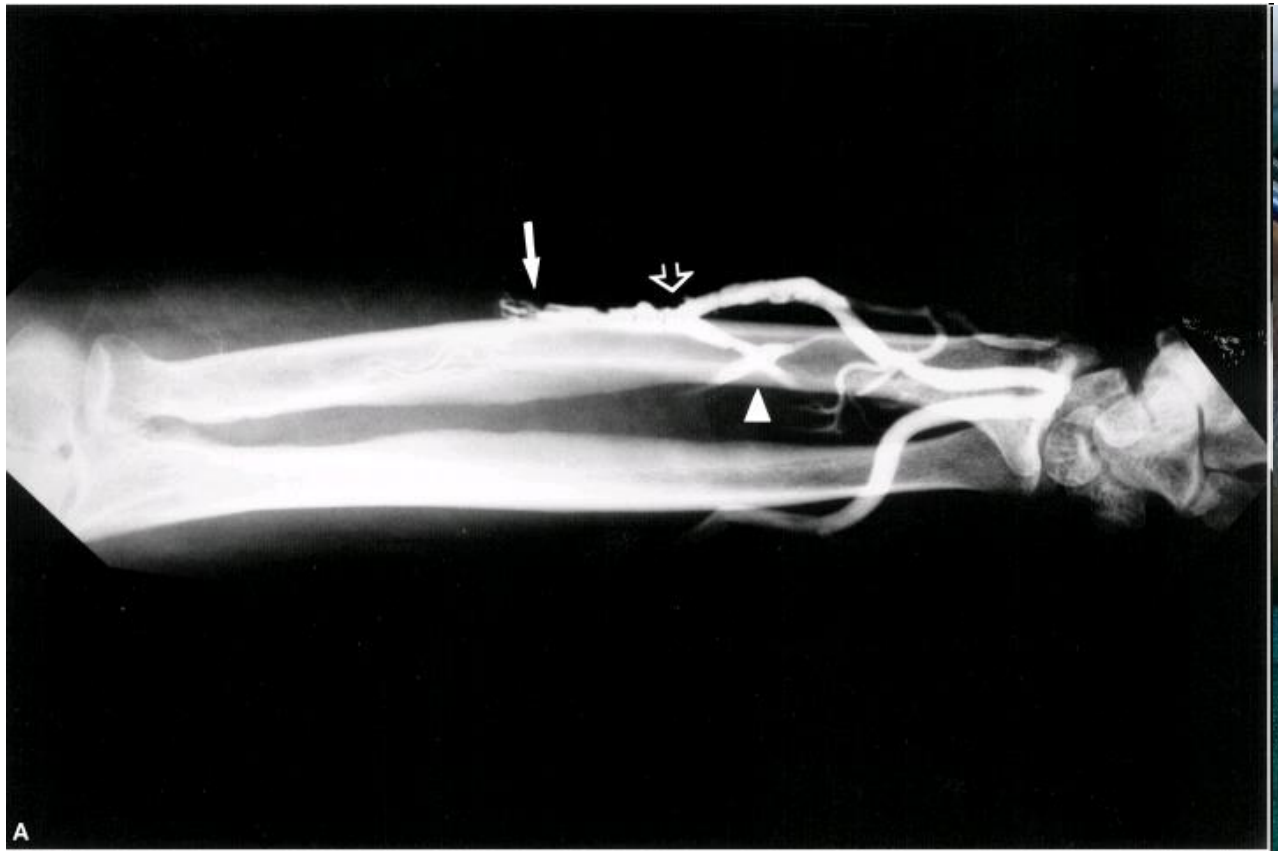

Radiocefalická A-V píštěl

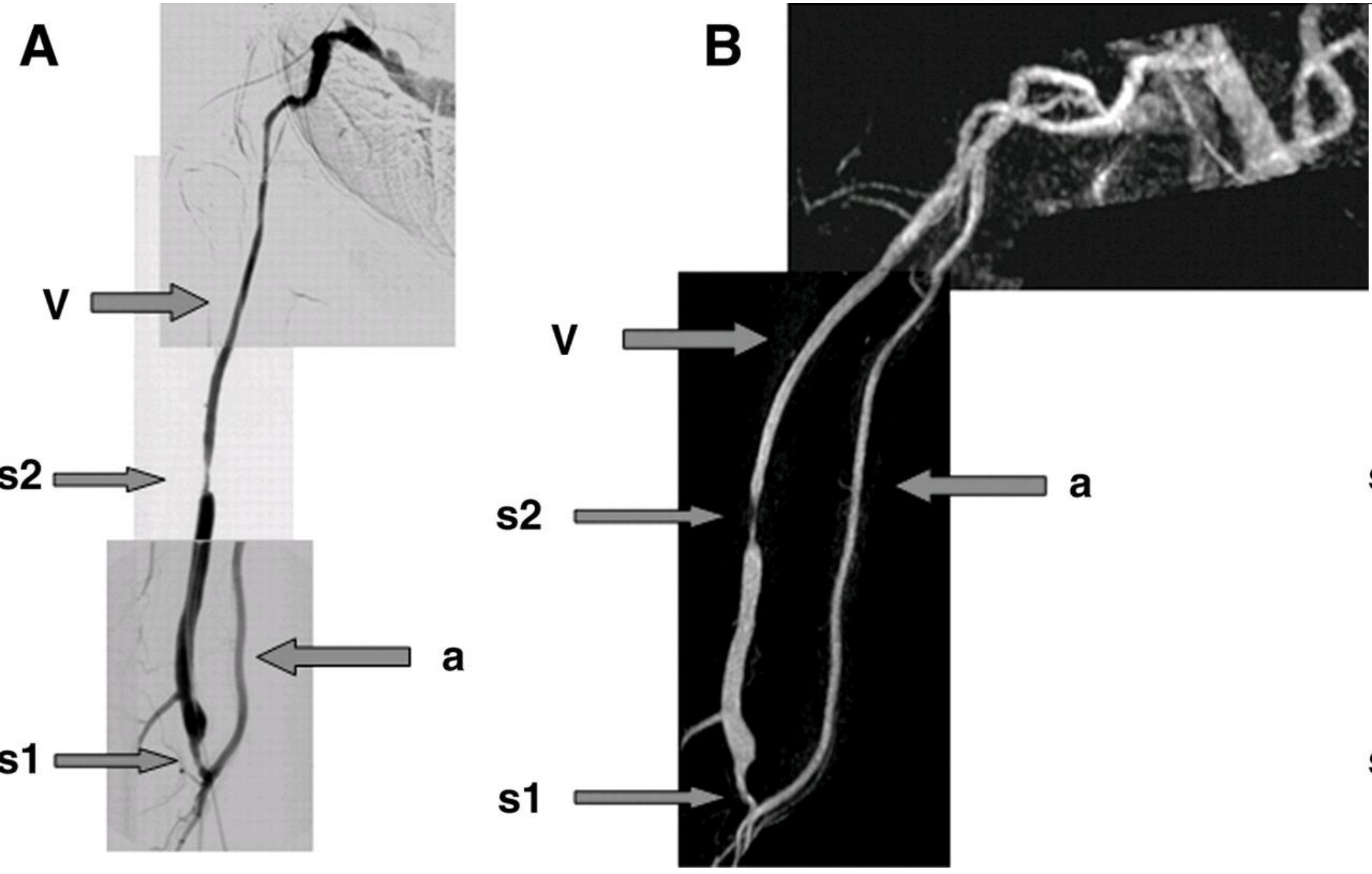

Žíly HK

- povrchová soustava
- <u>hluboká soustava</u>
  - doprovázejí tepny
  - zdvojené až do úrovně axily
  - četné spojky kolem tepny
  - četné chlopně
- v. subclavia
  - – malé přítoky

Povrchové žíly HK

- v. axillaris
  - – v. cephalica
  - – vv. thoracoepigastricae
  - – vv. costoaxillares
- v. brachialis (zdvojená)
  - – v. basilica

v. mediana cubiti + antebrachii
rete venosum dorsale manus
rete carpi dorsale
vv. intercapitulares

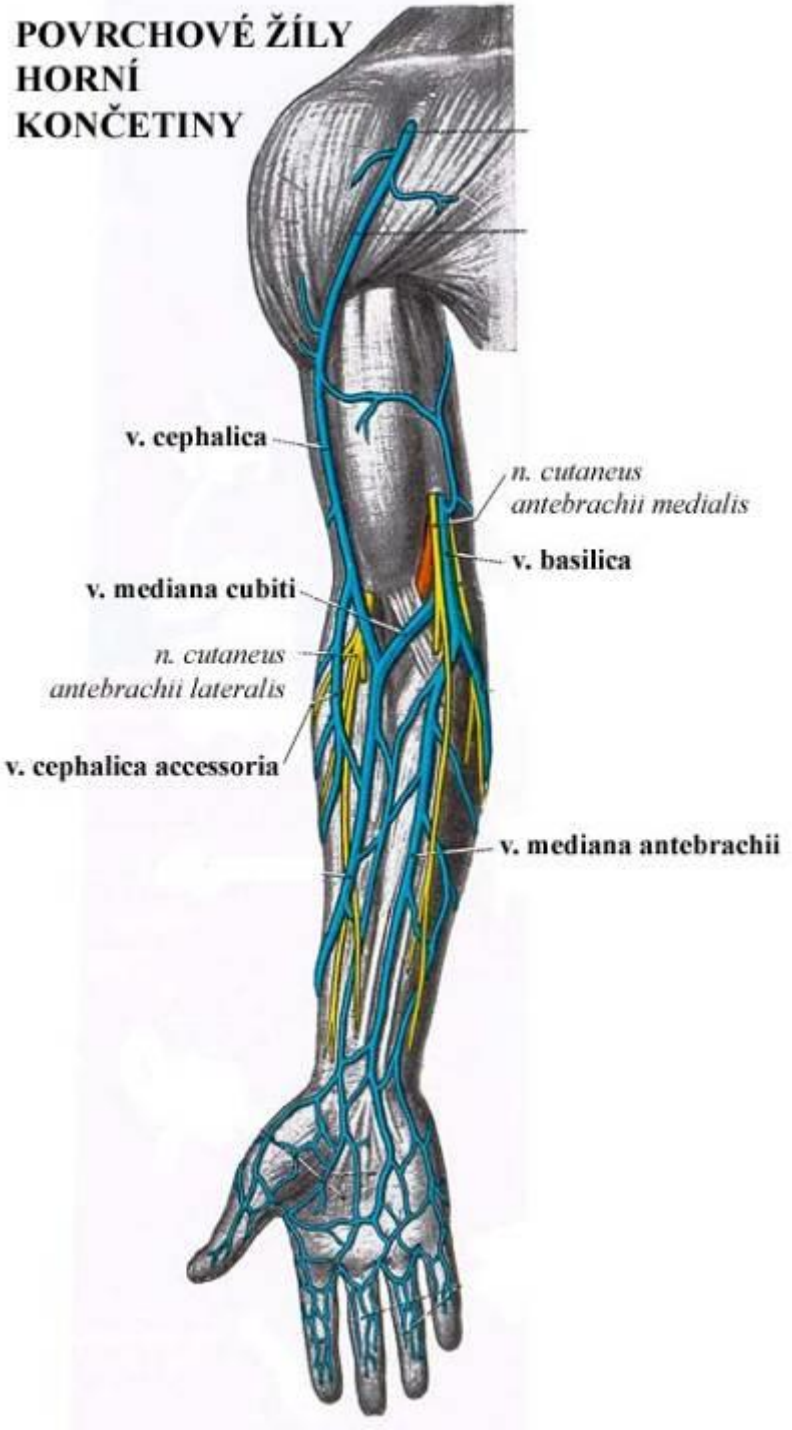

VARIACE NAPOJENÍ POVRCHOVÝCH ŽIL V LOKETNÍ JAMCE

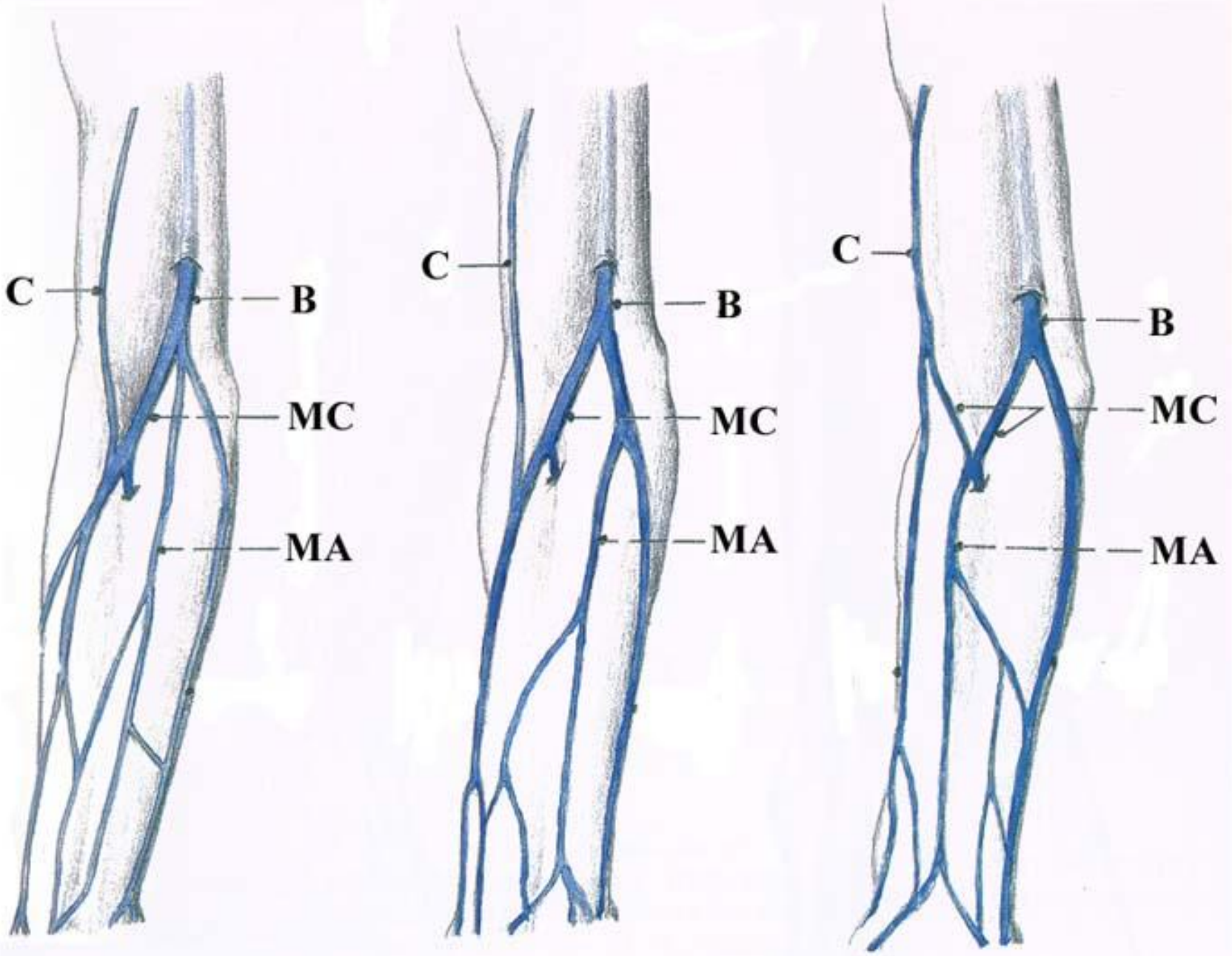

Povrchová soustava žil HK

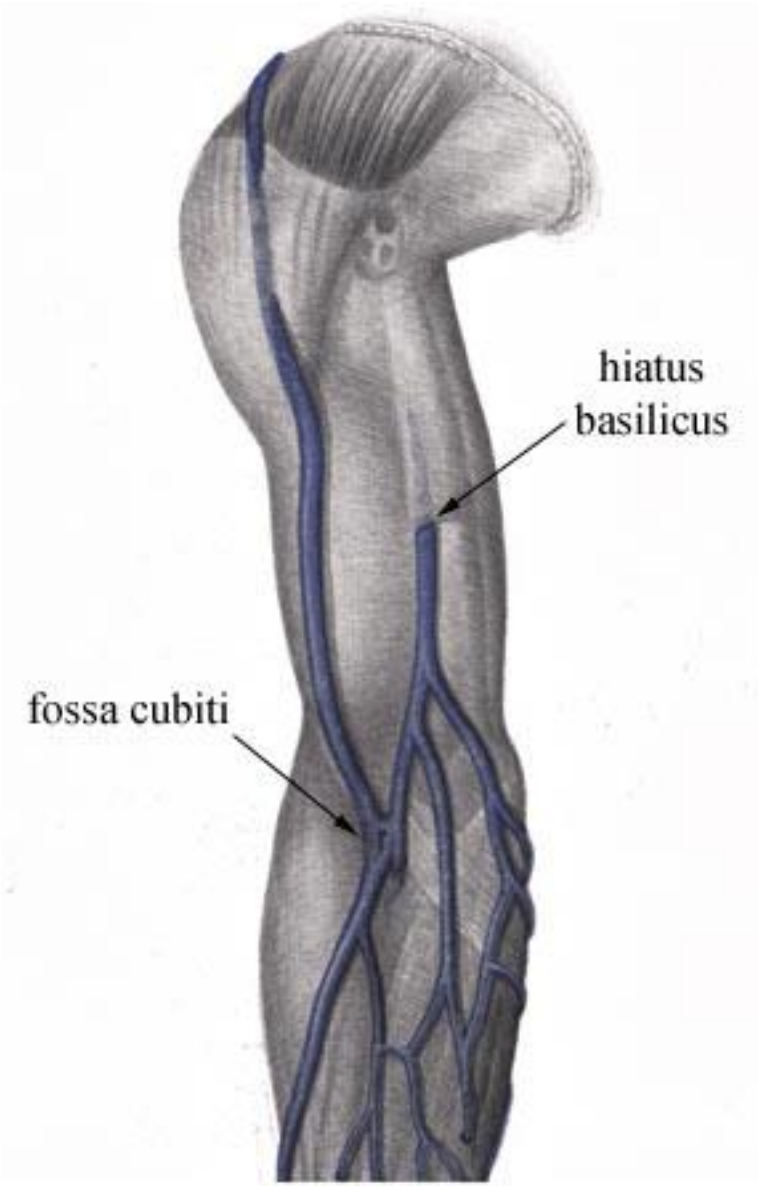

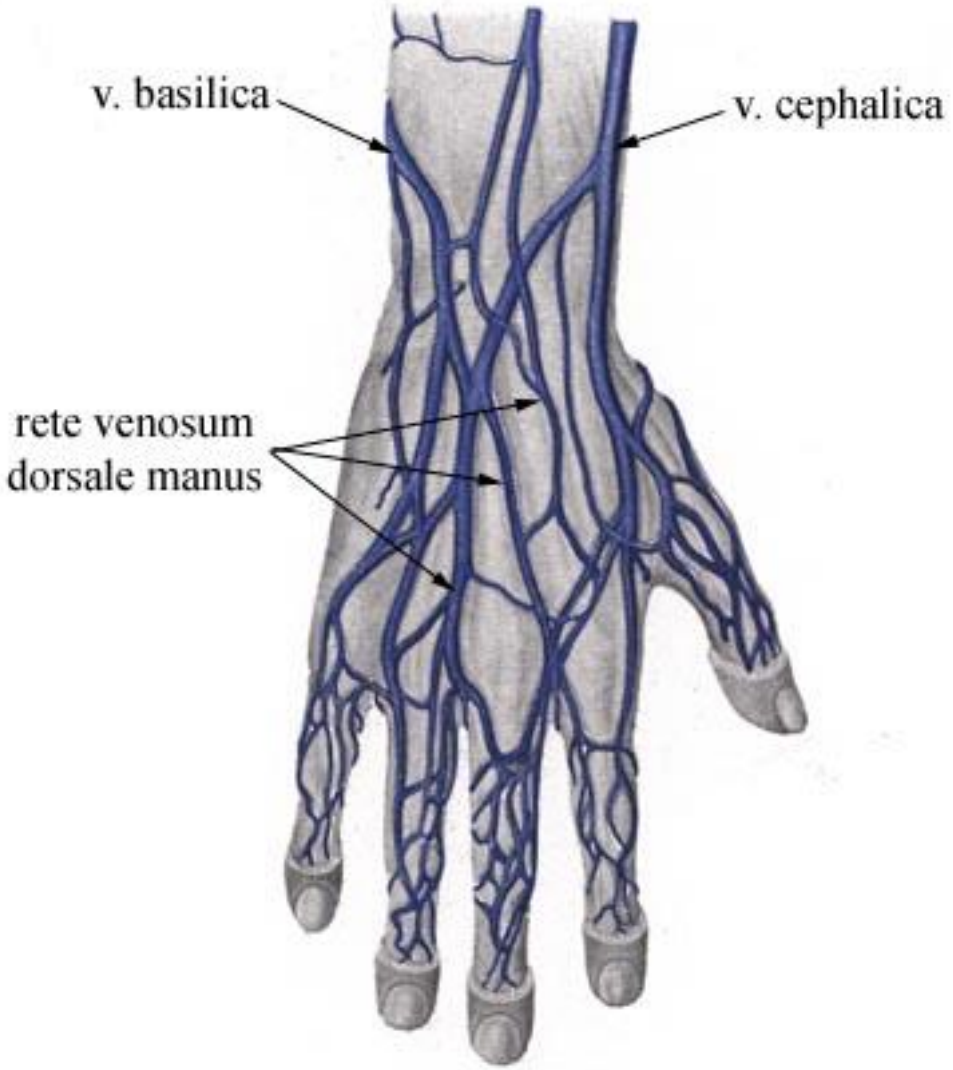

Soustava vena azygos

<u>v. azygos + hemiazygos</u>

(*lichá a pololichá žíla*)

- doprovázejí aorta thoracica
- žádné chlopně
- zadní dolní a horní mediastinum
- <u>začátek</u>: v. lumbalis ascendens + v. subcostalis
- <u>průchod bránicí</u>: skrz pars lumbalis nebo hiatus aorticus
- <u>konec</u>: v. hemiazygos ústí do v. azygos v úrovni T7-9
- v. azygos ústí do VCS
  - arcus v. azygos

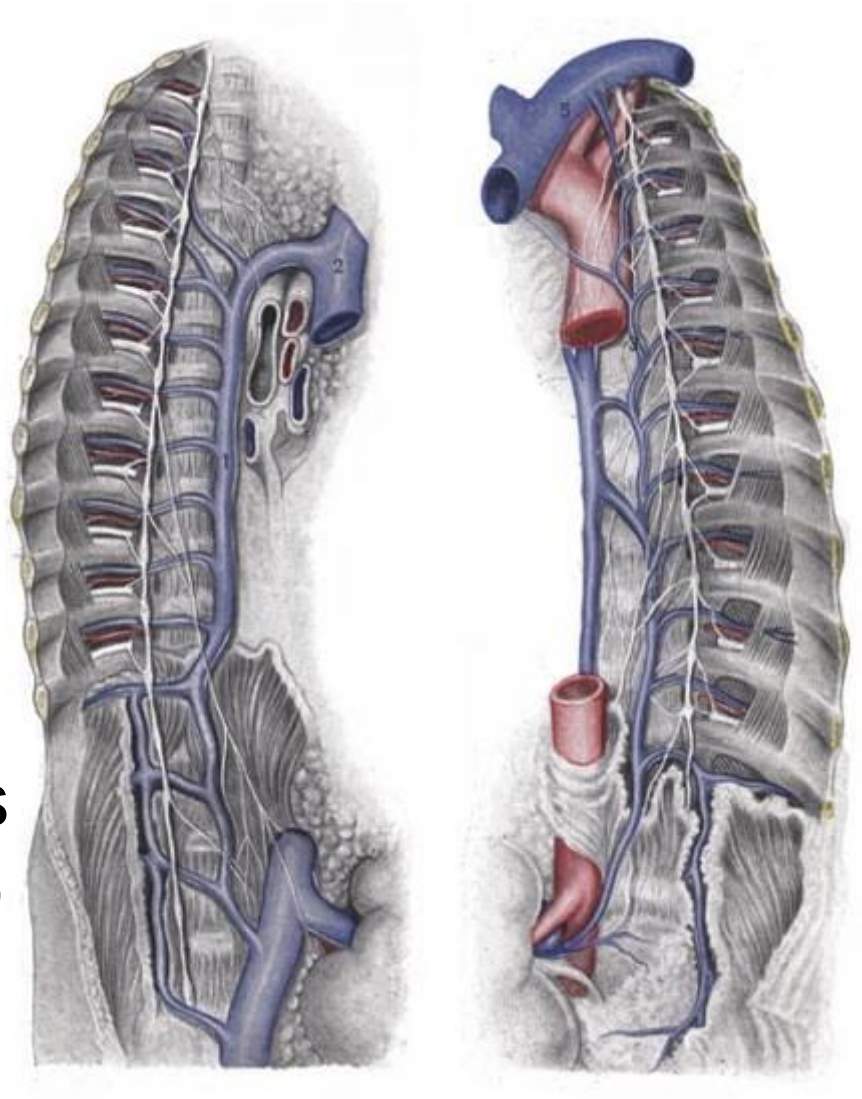

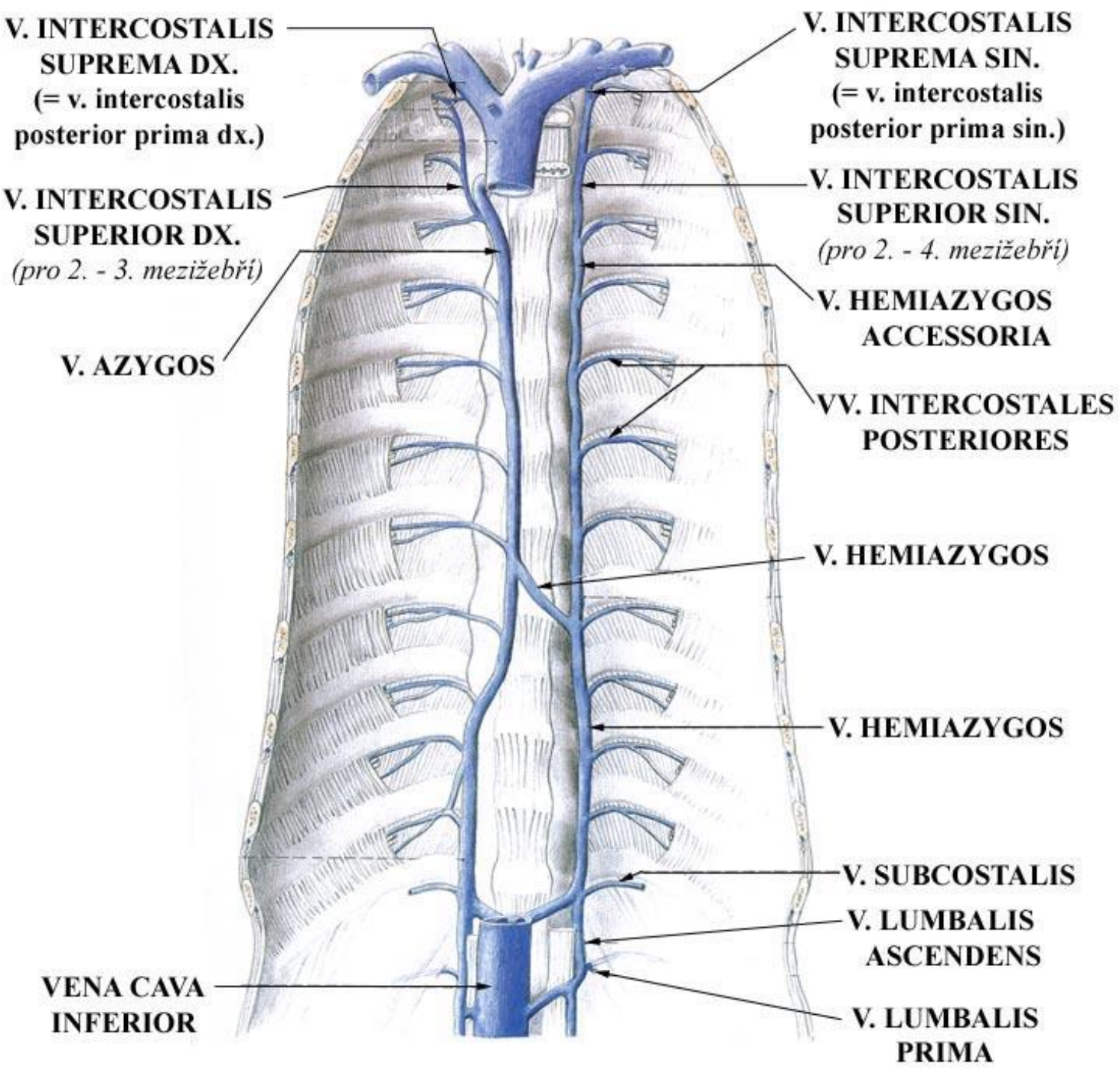
V. INTERCOSTALIS SUPREMA DX. (= v. intercostalis posterior prima dx.)
V. INTERCOSTALIS SUPERIOR DX. (pro 2. - 3. mezižebří)
V. AZYGOS
V. INTERCOSTALIS SUPREMA SIN. (= v. intercostalis posterior prima sin.)
V. INTERCOSTALIS SUPERIOR SIN. (pro 2. - 4. mezižebří)
V. HEMIAZYGOS ACCESSORIA
VV. INTERCOSTALES POSTERIORES
V. HEMIAZYGOS
V. HEMIAZYGOS
V. SUBCOSTALIS
V. LUMBALIS ASCENDENS
V. LUMBALIS PRIMA
VENA CAVA INFERIOR

Soustava vena azygos - přítoky

- parietální:
  - vv. intercostales posteriores
  - v. intercostales sup. dx.
  - v. hemiazygos accessoria
  - vv. phrenicae sup.
- viscerální:
  - vv. oesophageales, bronchiales, mediastinales

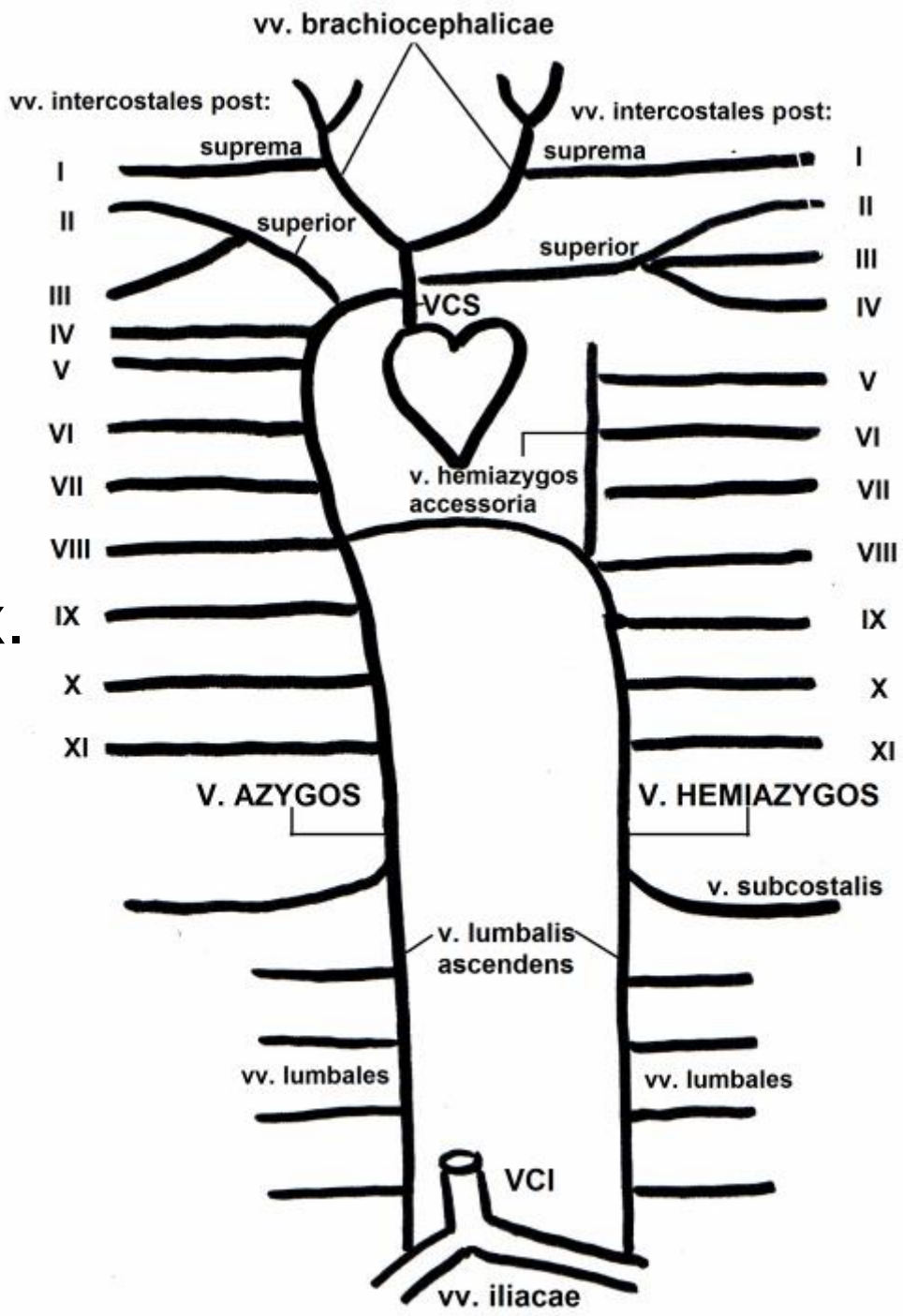

Páteřní žíly

- <u>plexus venosi vertebrales</u>
  - externi (ant. + post.)
  - interni (ant. + post.)
  - vv. basivertebrales
  - vv. medullae spinalis

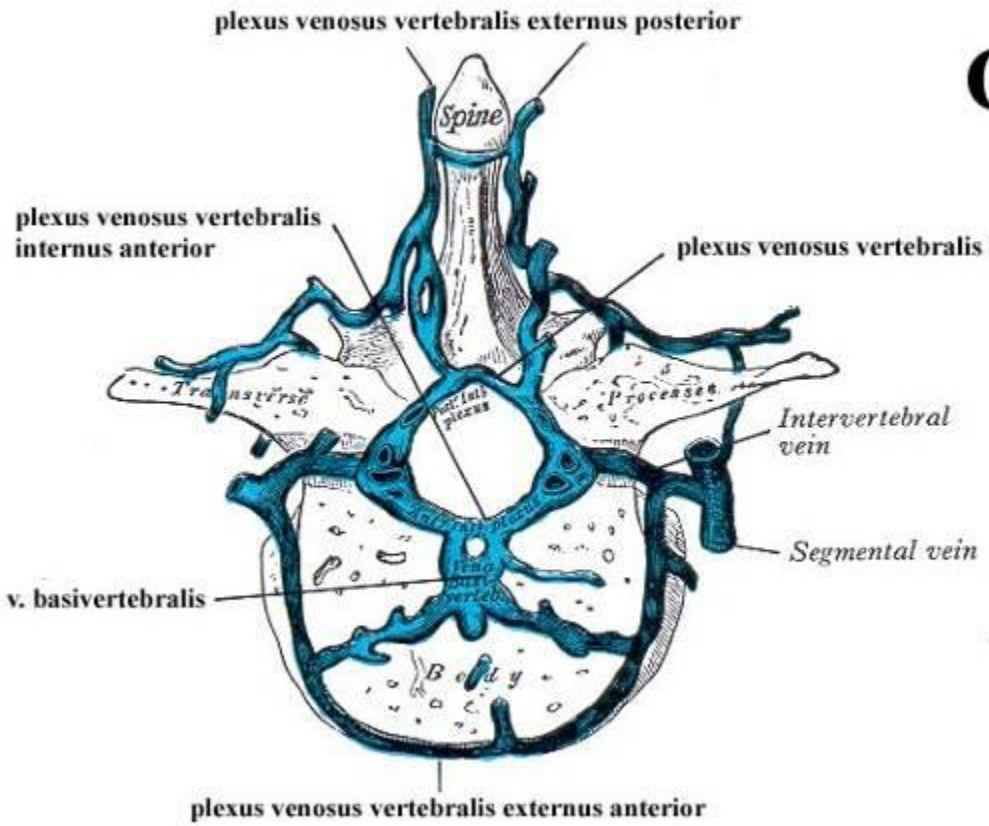

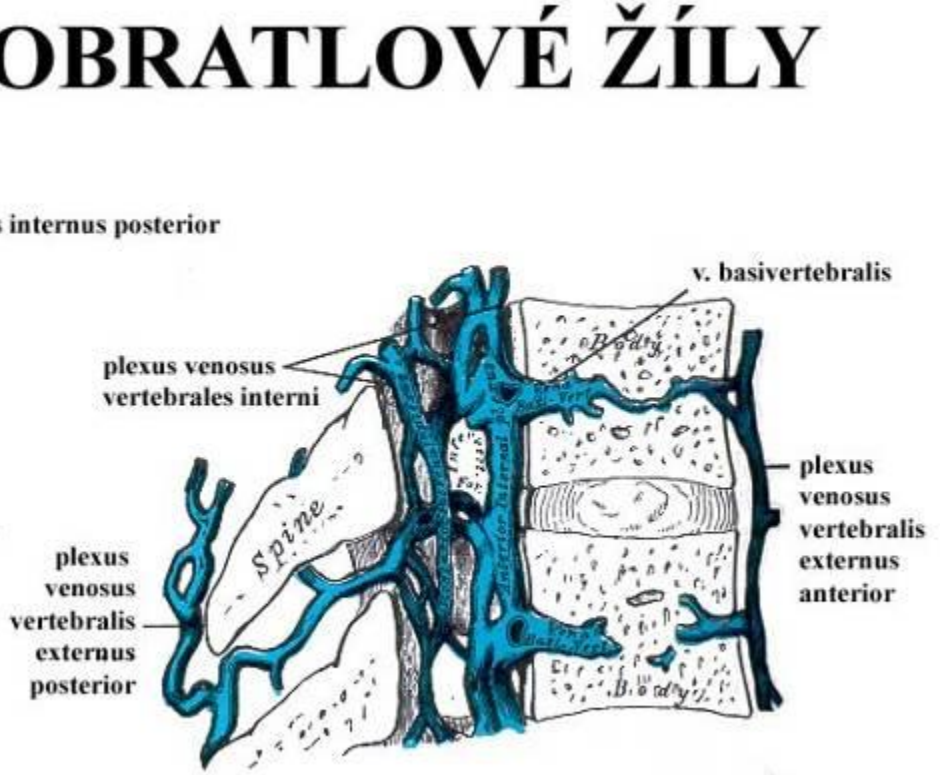

Páteřní žíly

- epidurální prostor (vnitřní pleteně)
- mají svoji stěnu na rozdíl od splavů
- nemají chlopně → kavo-kavální anastomóza
- spojení s plexus basilaris v lebce (emisarium)
- ústí do:
  - v. vertebralis
  - v. cervicalis prof.
  - vv. intercostales post.
  - a. azygos/hemiazygos
  - vv. lumbales
  - vv. sacrales laterales
- *Batsonův plexus*
- *šíření metastáz a infekce*
  (z plic, konečníku, mléčné žlázy, prostaty)

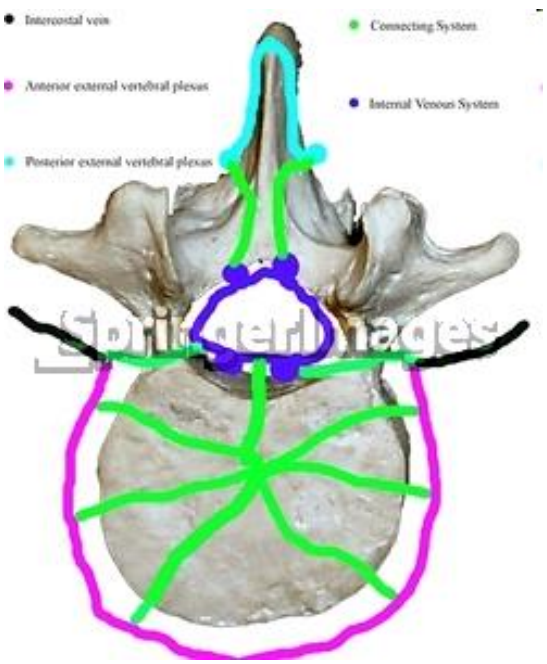

Cesty šíření vzduchové embólie při poraněních žil páteře kanálu

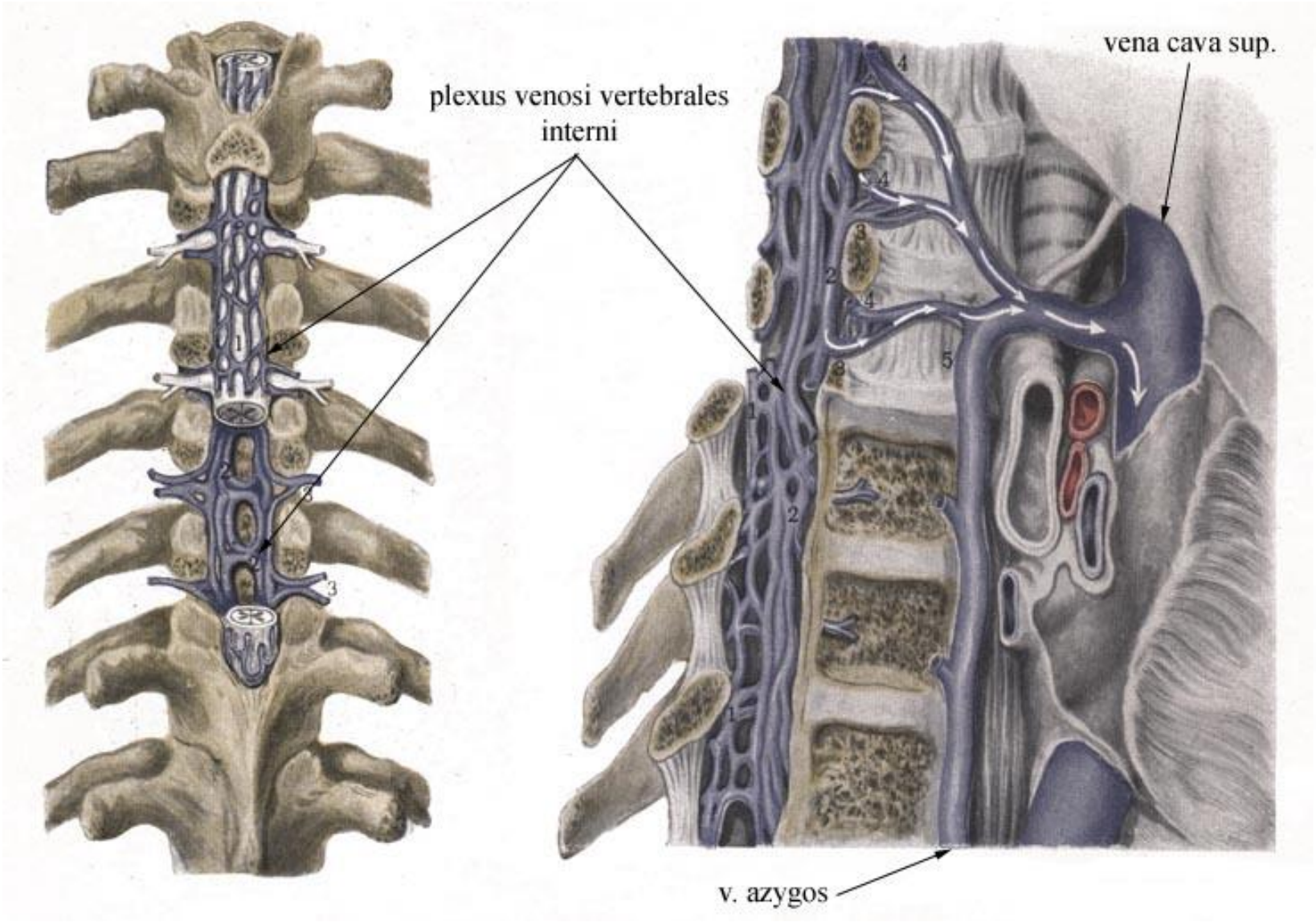

Vena cava inferior

- začátek: soutok vv. iliacae communes (L4)
- vpravo od aorta abdominalis, retroperitoneum
- žádné chlopně, vzácně část zdvojená
- sulcus venae cavae hepatis
- foramen venae cavae diaphragmatis
- u jater 2 cm, na konci 3,5 cm široká
- konec: atrium dextrum (T8)

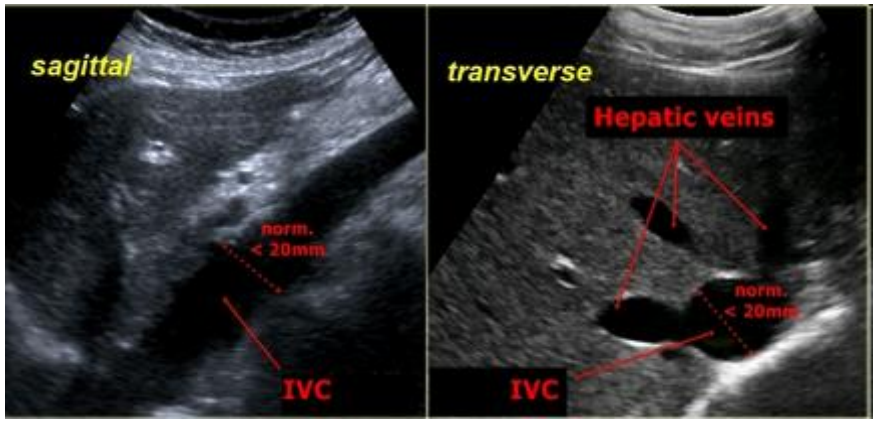

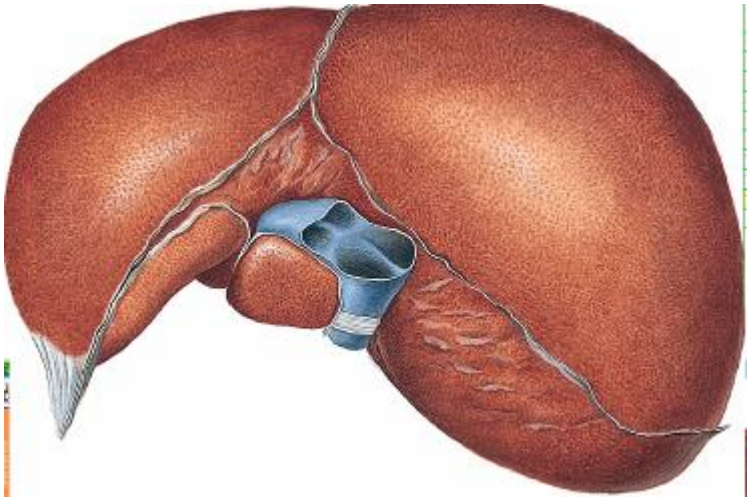

Vena cava inferior

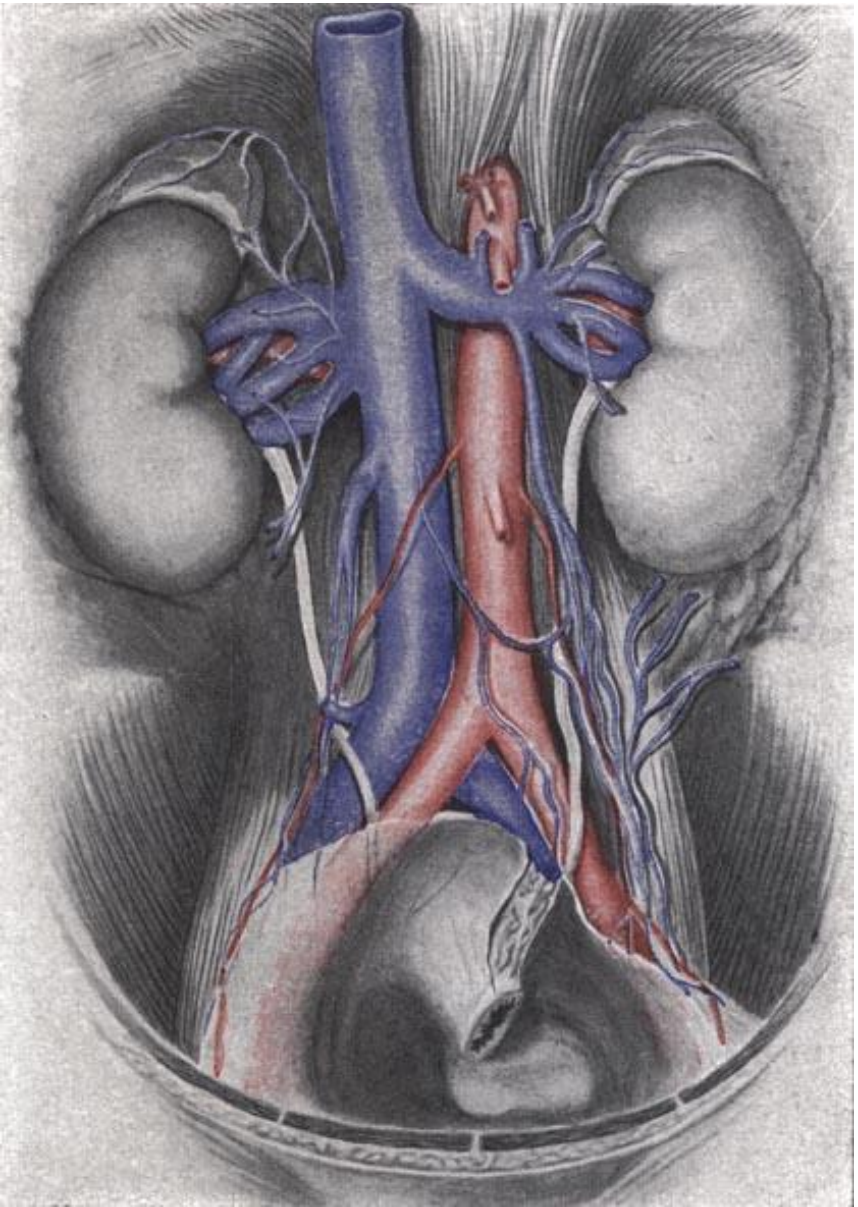

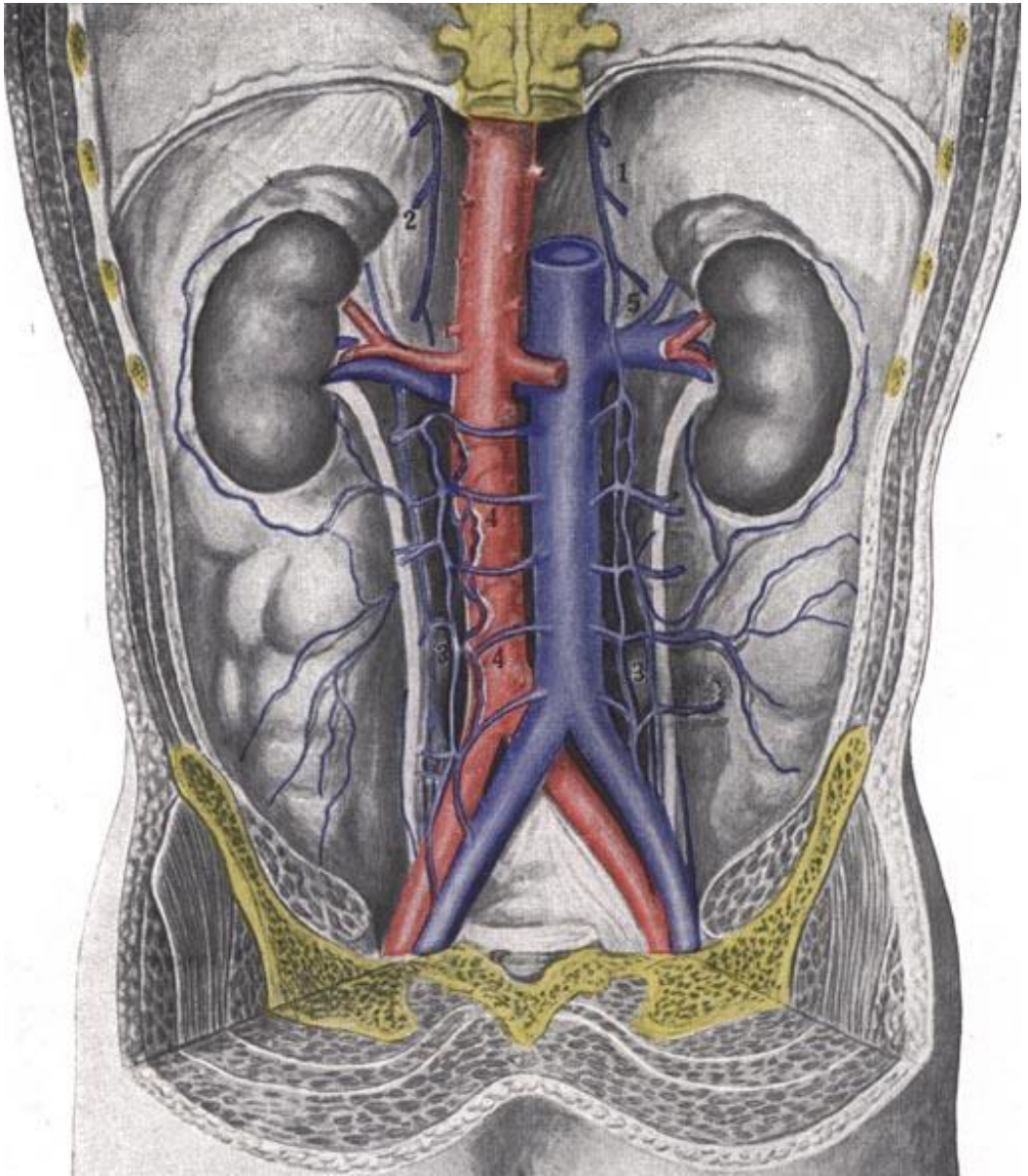

Vena cava inferior - přítoky

- variace přítoků
- parietální:
  - vv. iliacae communes, vv. lumbales I-IV (*propojeny přes v. lumbalis ascendens)*, vv. phrenicae inf., v. sacralis mediana
- viscerální:
  - vv. renales
  - v. testicularis ♂ / ovarica dx. ♀ (začíná jako plexus pampiniformis)
  - v. suprarenalis dx.
  - vv. hepaticae dextra, intermedia, sinistra (ductus venosus *Aranzii*)

Variabilita vyústění viscerálních přítoků VCI

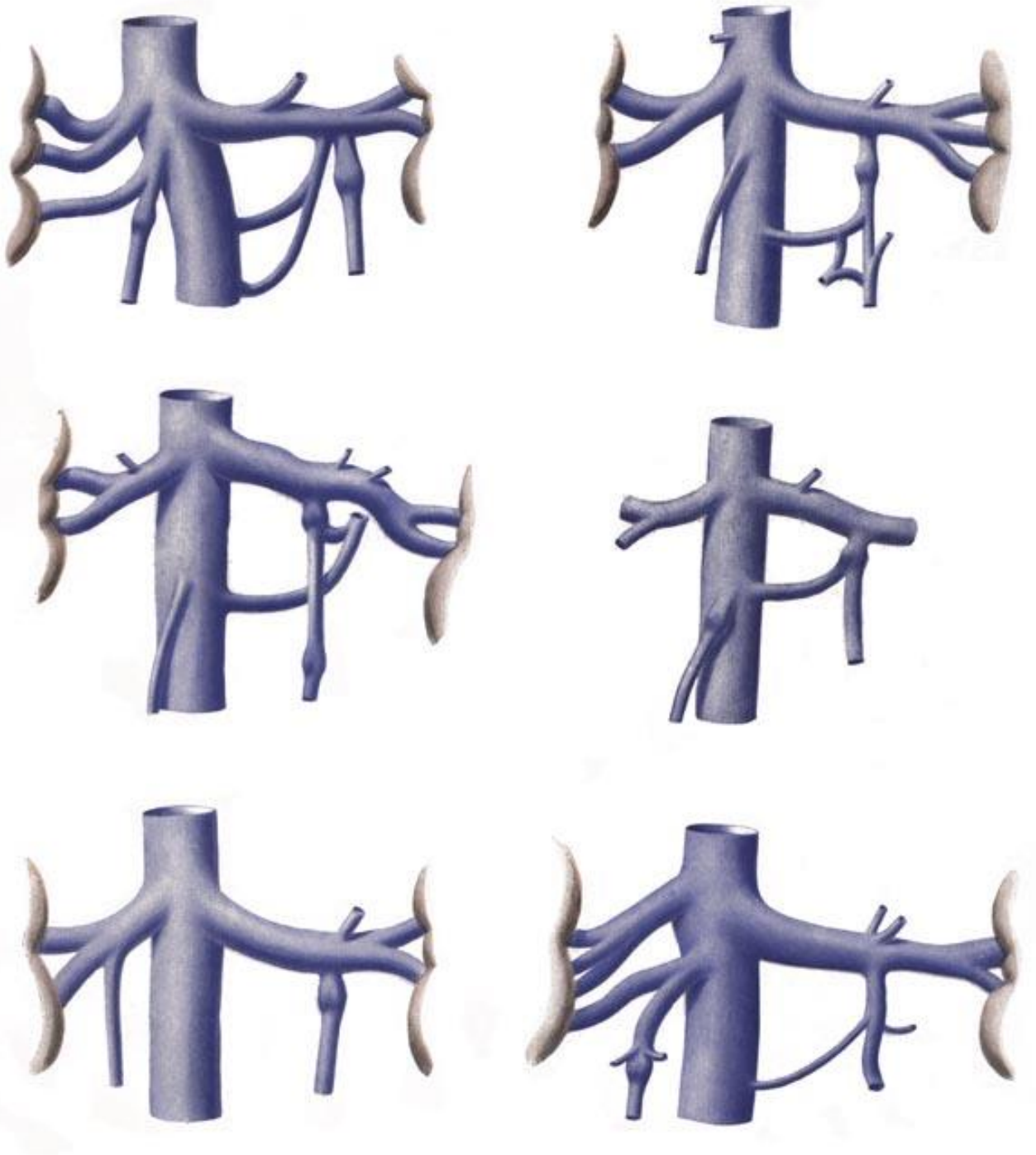

VCI - klinika

- komprese
  - aneuryzma aorty
  - těhotná děloha
  - břišní nádory
- trombóza

- prevence fatální plicní embólie - Greenfieldův filter
  - u žilní tromboembolické choroby při kontraindikaci antikoagulační léčby

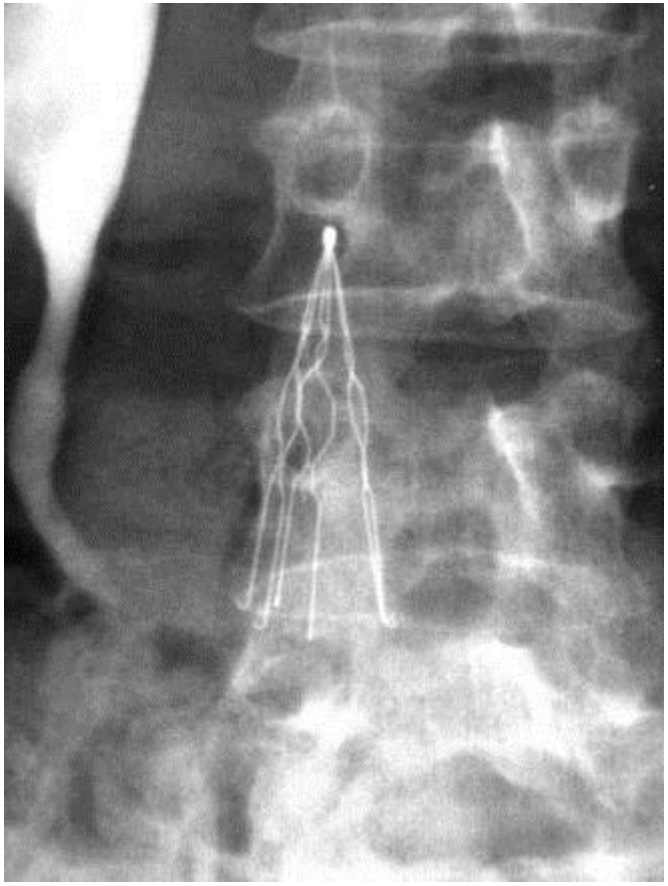

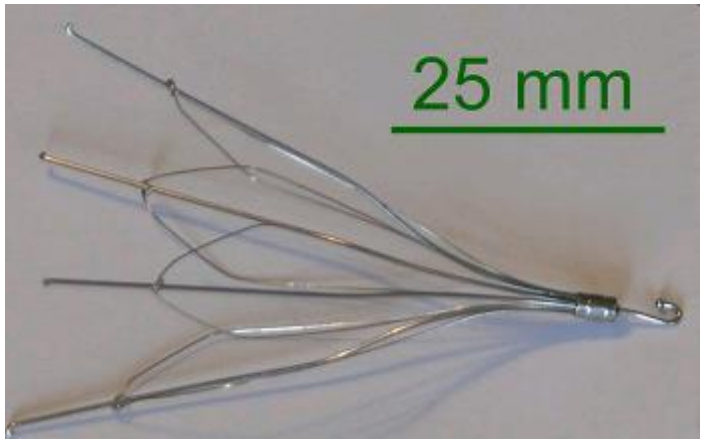

Vena iliaca communis

- průběh odpovídá tepnám
- přítoky:
  - v. lumbalis ascendens
  - v. sacralis mediana do VICsin.
- Mayův-Thurnerův syndrom
  - komprese VICsin. tepnou (AICdx.)
  - následná trombóza
  - léčba: stent

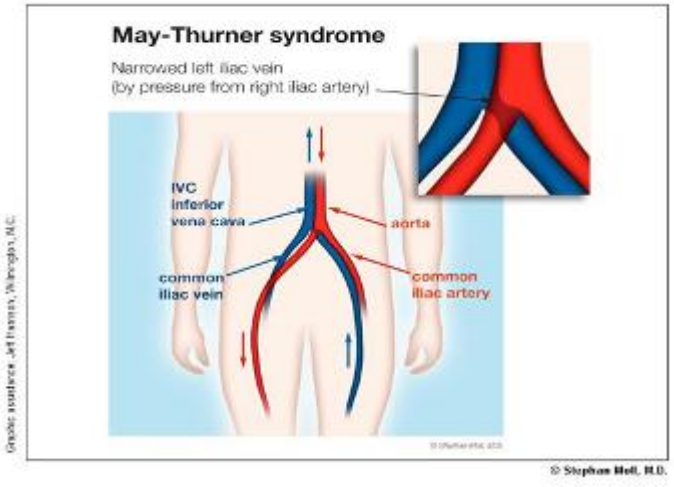

Léčba Mayova-Thurnerova syndromu



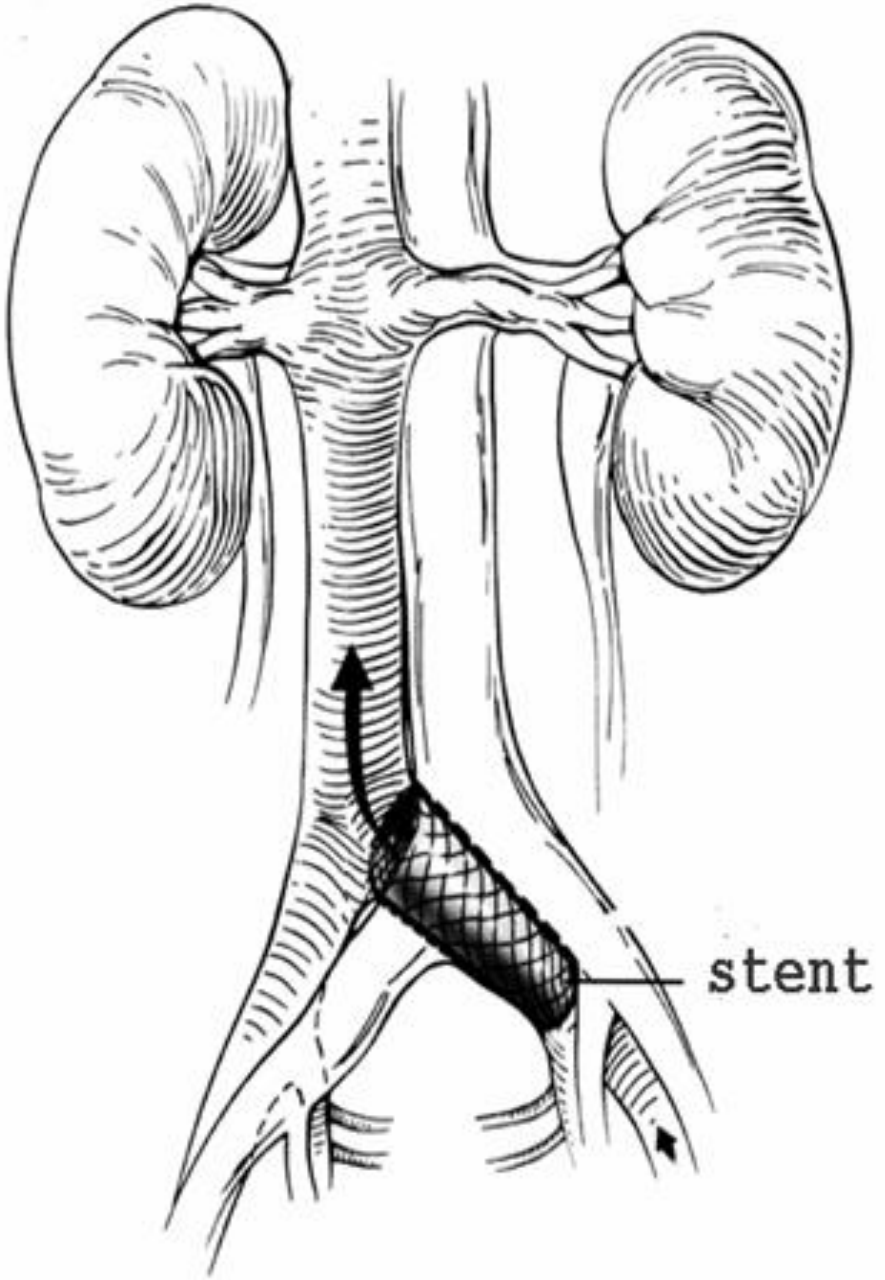

Vena iliaca externa

- větve odpovídají tepnám
- žilní corona mortis přítomná v 75 %
- chlopně přítomné do 20 %
  - obvykle nefunkční

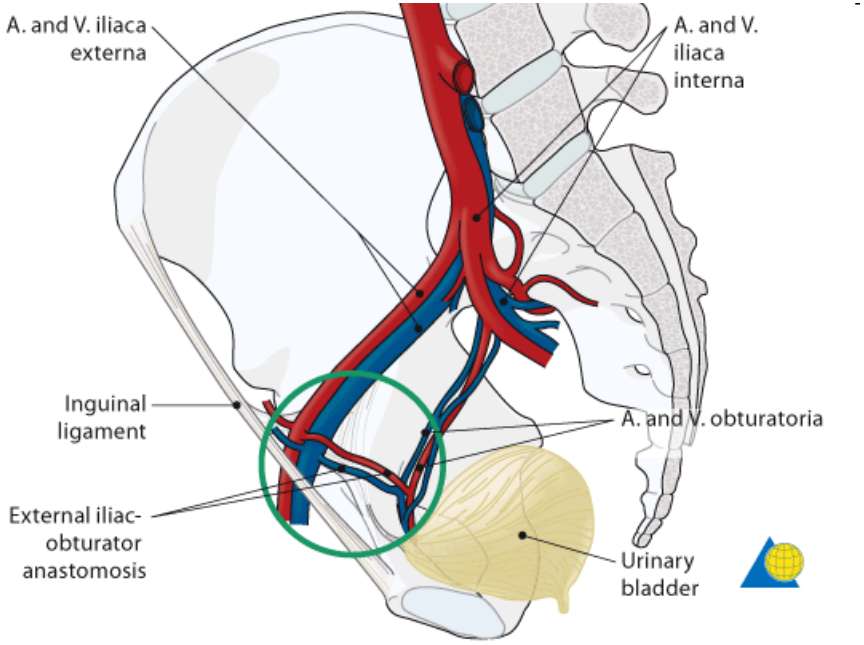

Vena iliaca interna – žíly pánve

- *parietální*: odpovídají tepnám
- *viscerální*: pleteně
  - plexus venosus pudendus (*Santorini*)
    - ve spatium retropubicum (*Retzii*)
  - p.v. vesicalis + prostaticus
  - p.v. uterinus + vaginalis (uterovaginalis)
  - p.v. rectalis
    - p.v. rectalis externus (v tunica adventitia)
    - p.v. rectalis internus = p. haemorrhoidalis (v tunica submucosa)
  - p.v. sacralis (spojky s vv. sacrales lat. + mediana)

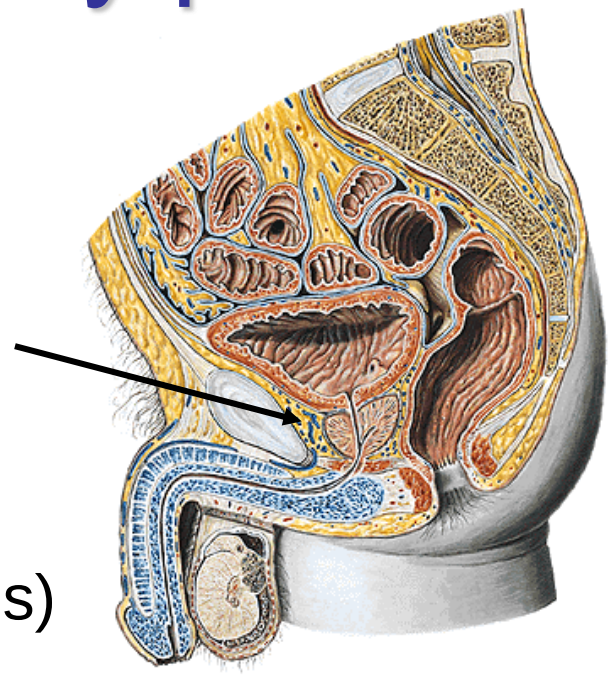

Žíly pánve

- v. lig. teretis uteri ♀
- vv. lig. lati uteri ♀

- vv. suprapubicae
- v. ischiadica

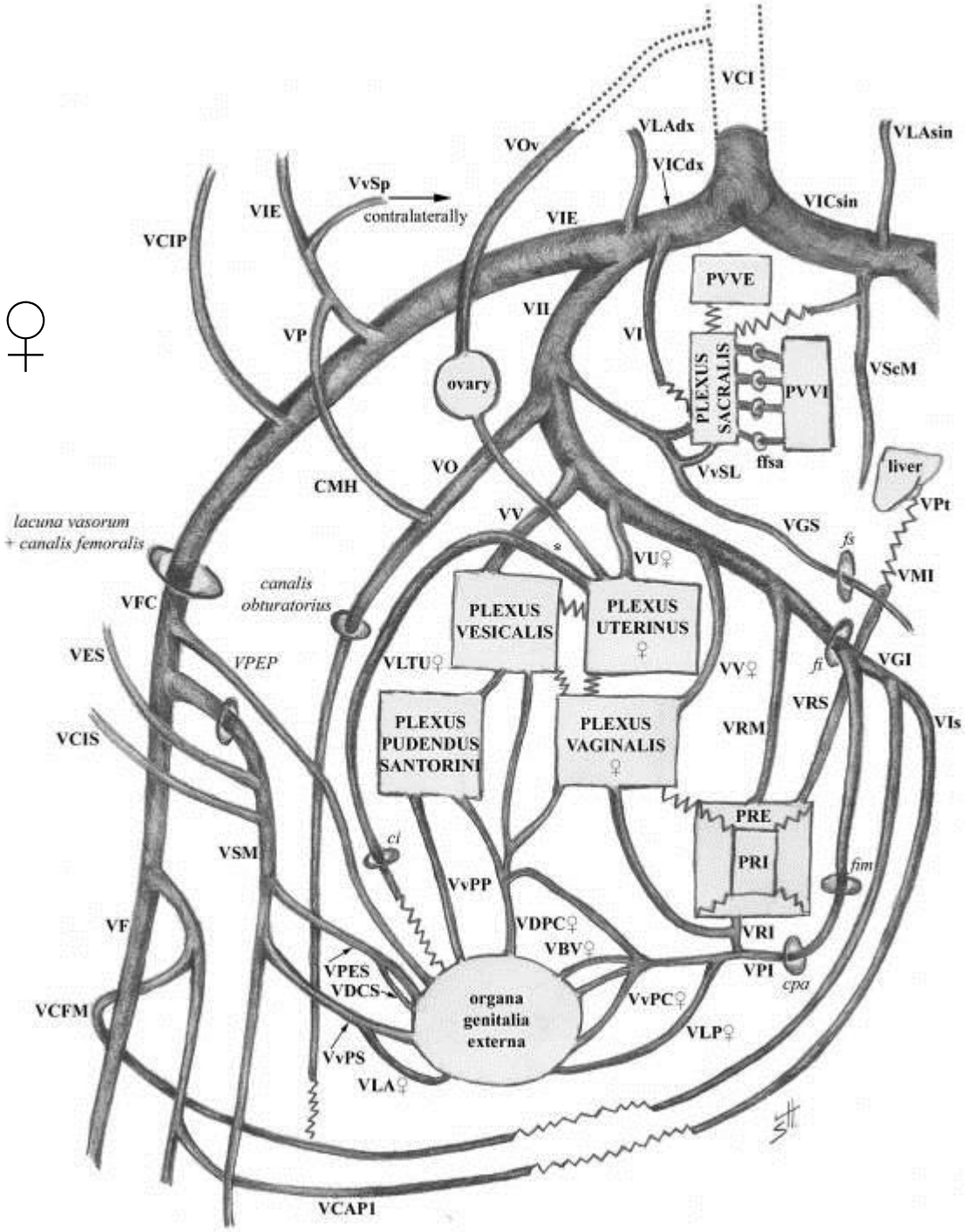

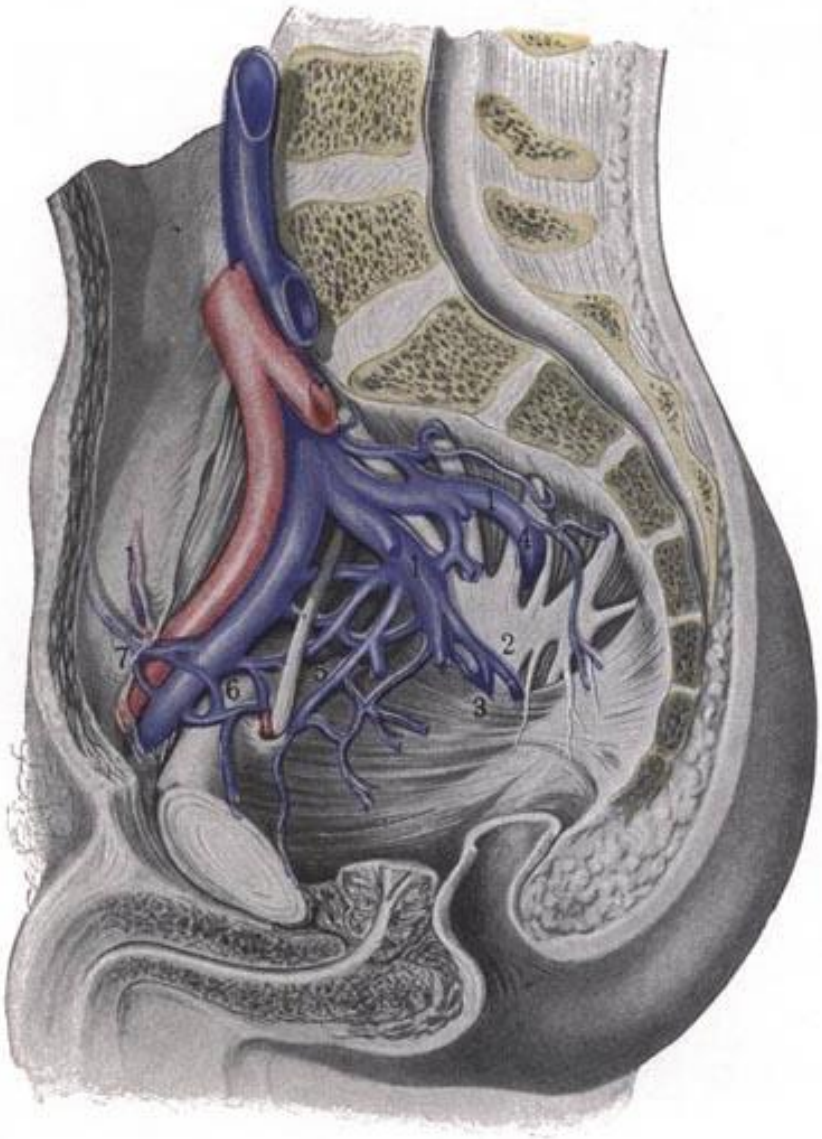
1
2
3
4
5
6
7

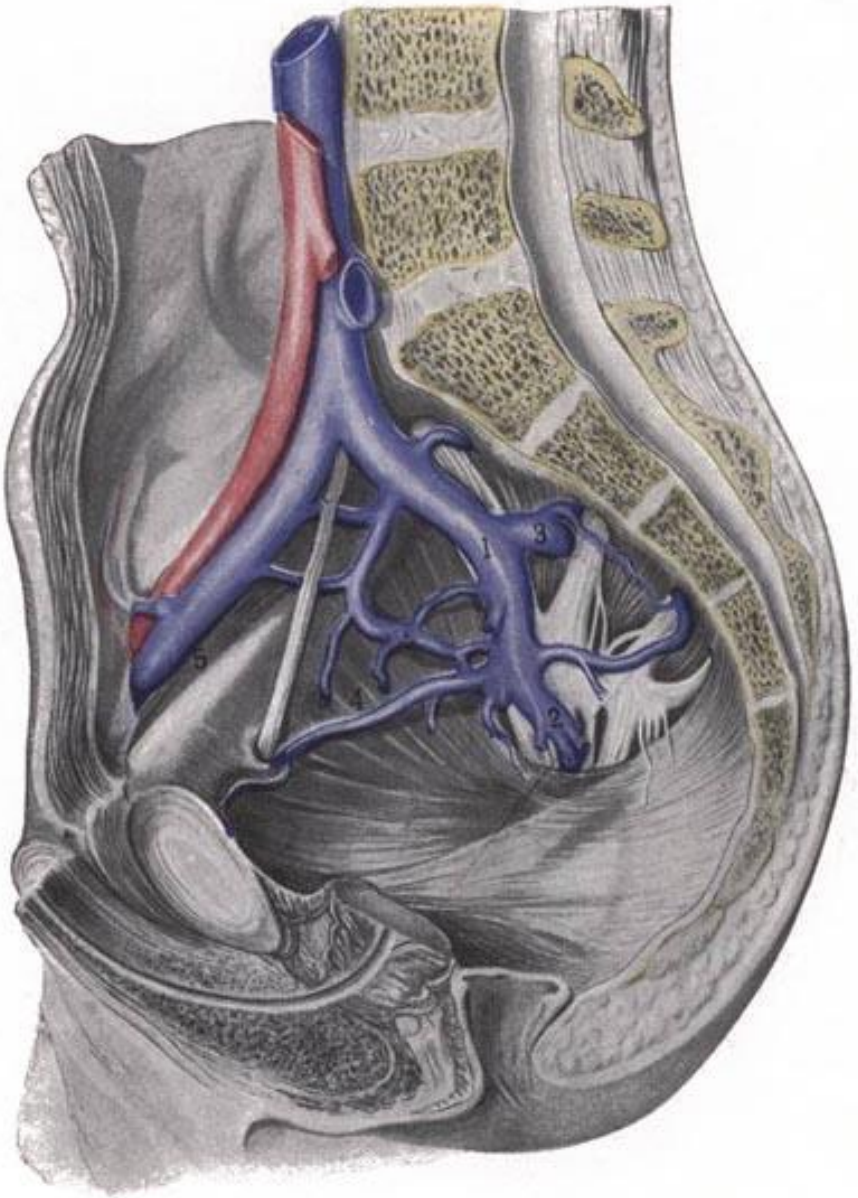
1
2
3
4
5

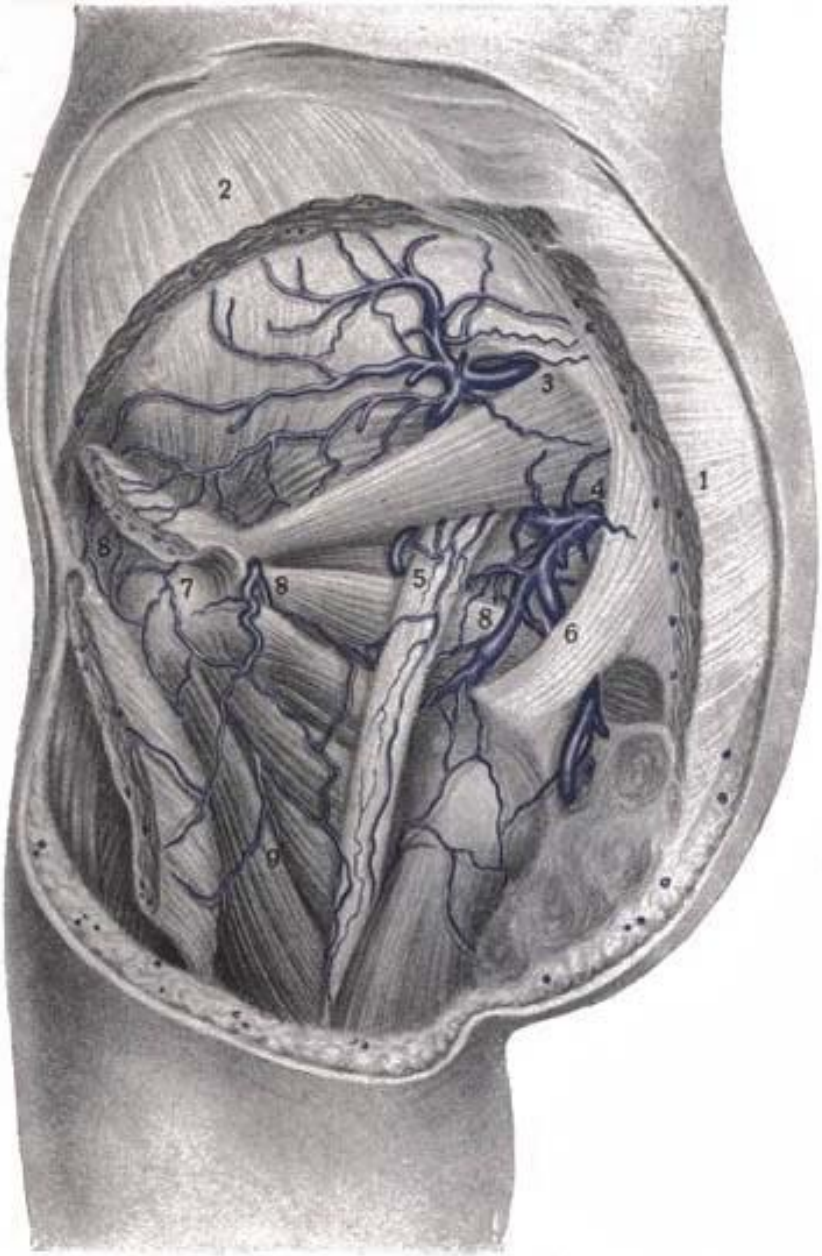
2
3
1
4
8
5
7
8
8
6
9

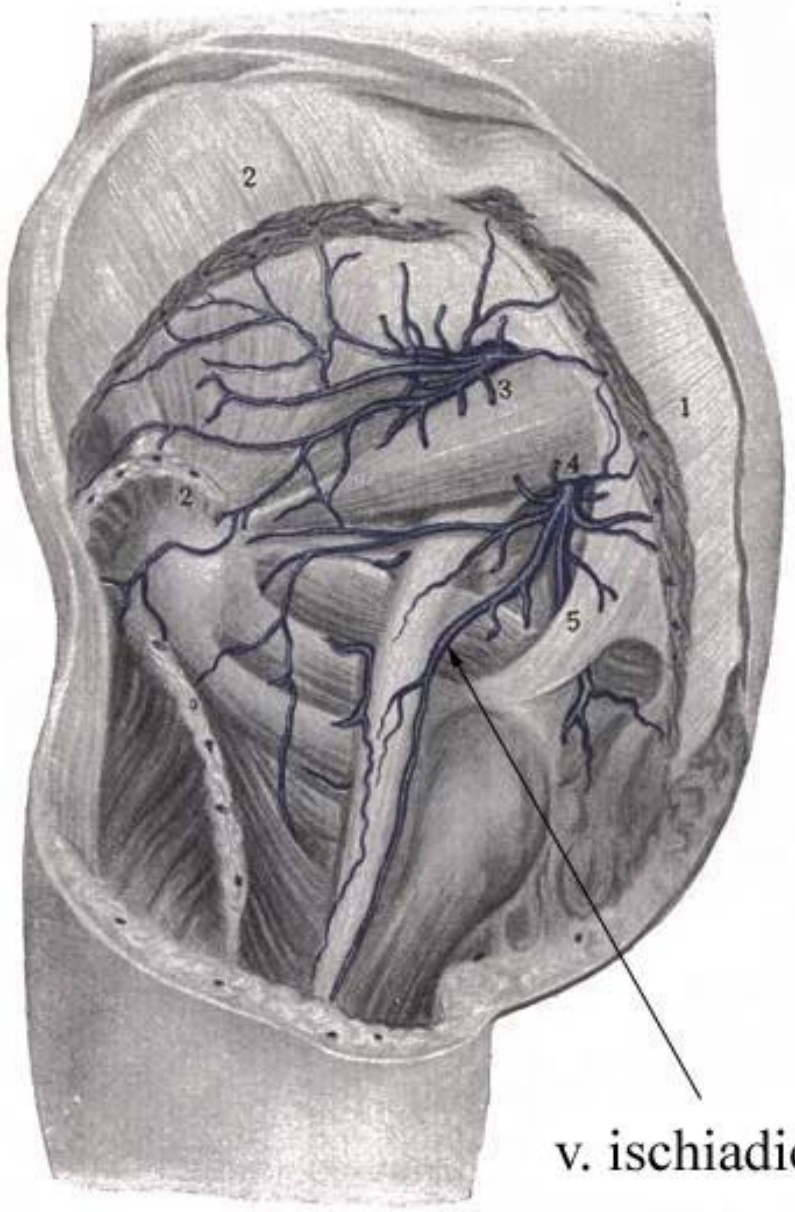
2
3
1
4
2
5
v. ischiadica

Směr odtoku žilní krve z pánve

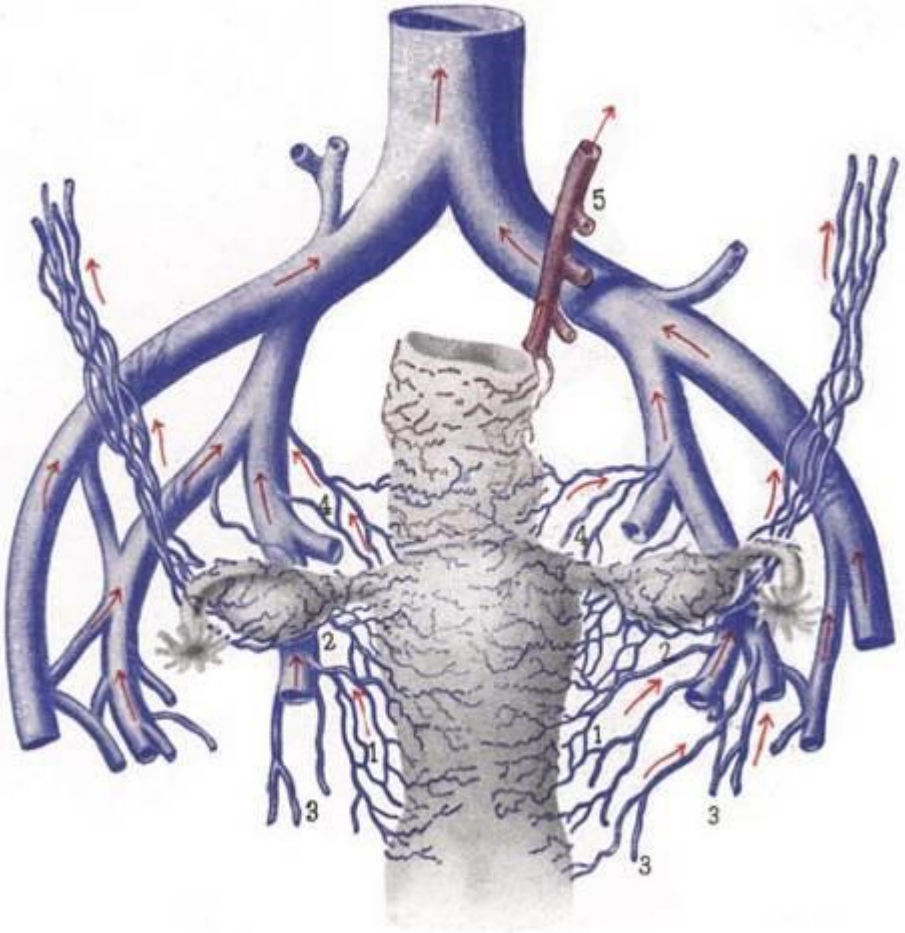

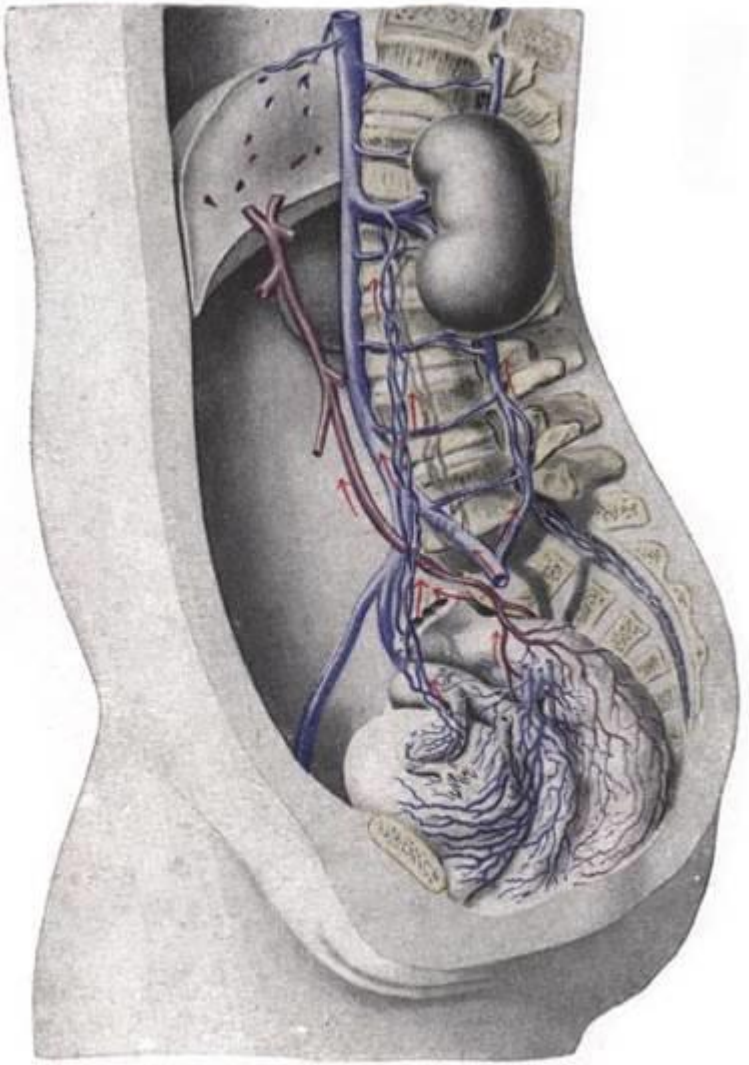

Žíly pánve - klinika

- zlomeniny pánve → silné krvácení
- obleněný průtok → trombóza → embólie
- vychytání vápenatých solí v trombech → flebolity (viditelné na rtg)
- pánevní varixy – komunikace s žílami DK
- v. iliaca int. a její přítoky málo pohyblivé → při operacích snadno krvácejí a špatně se podvazují

Místa spojení žil pánve a žil DK

- canalis inguinalis
- canalis obturatorius
- foramen infrapiriforme
- perineum
- *změny toku krve při varixech*

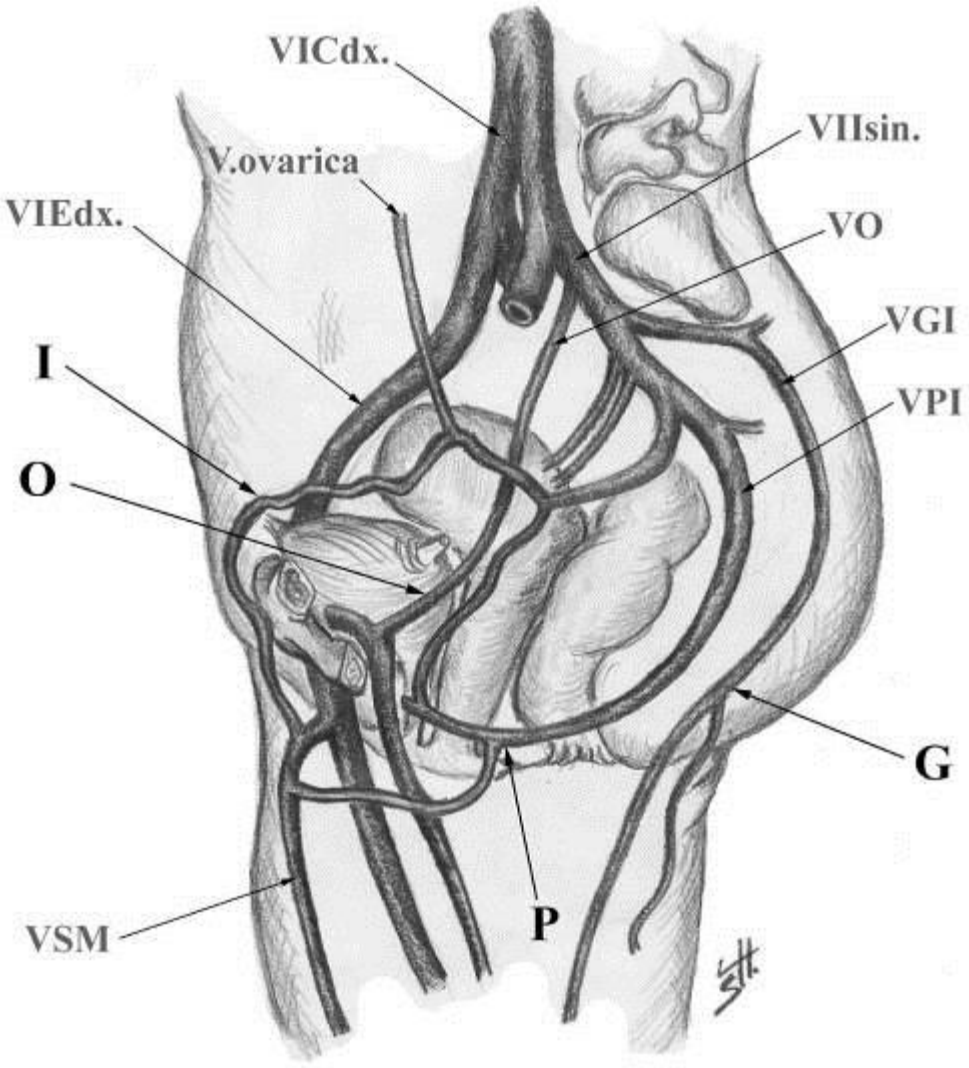

Vena portae = Vrátnicová žíla

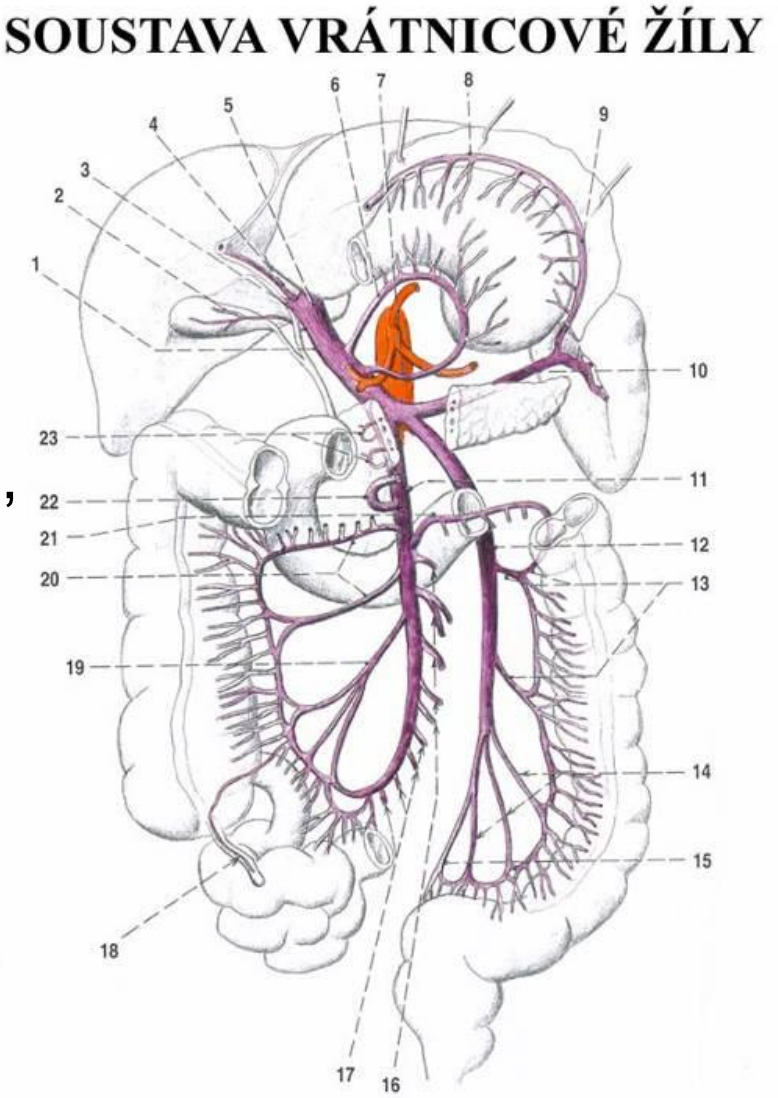

<u>sbírá krev z nepárových břišních orgánů</u>

nemá chlopně

<u>začátek</u>: soutok v. splenica + v. mesenterica sup.

- v. mesenterica inf. ústí v 50 % do VS, v 40 % do VMS a v 10 % do soutoku
- v. prepylorica (*Mayo)*
- vv. gastricae dx. + sin.
- v. cystica
- vv. paraumbilicales (*Sappey*)

<u>konec</u>: v porta hepatis se větví na r. dx. + sin. a dále do jaterních segmentů

portokavální anastomózy: 7 hlavních

Vena portae

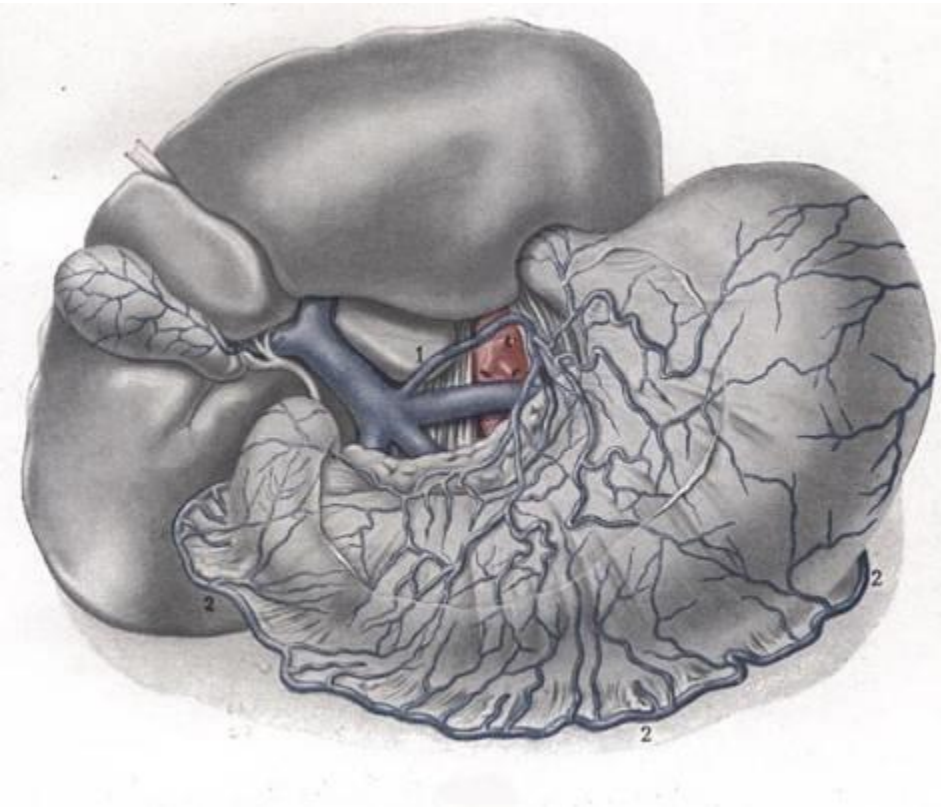

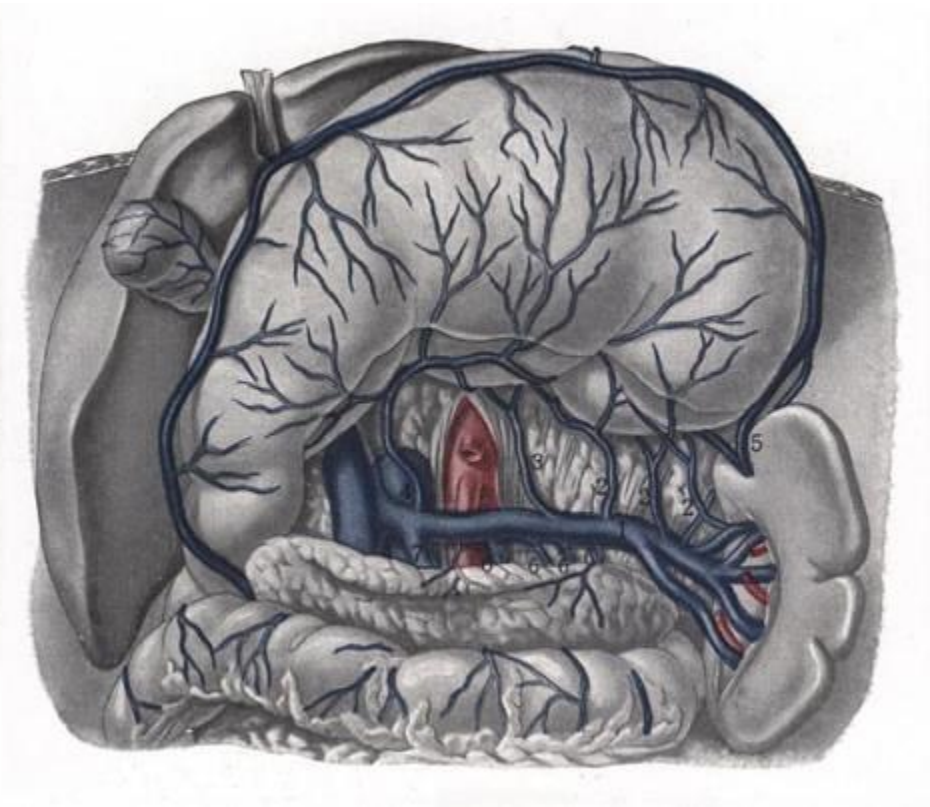

Portokaválální anastomózy

- vv. gastricae – vv. oesophageales (*jícnové varixy) – v tunica submucosa*
- vv. gastricae – vv. paraoesophageales – v *tunica adventitia*
- plexus venosus rectalis
- vv. *paraumbilicales – podkožní žíly kolem pupku (caput Medusae) a dále:*
  - *v. epigastrica sup. + inf.*
  - *v. epigastrica superficialis + vv. thoracoepigastricae*
- vv. paraumbilicales – plexus venosus vesicalis (*Burowovy žíly*)
- subkapsulární žíly jater – žíly bránice
- spojky v retroperitoneu (*Retziovy spojky)*
- rekanalizovaný ductus venosus

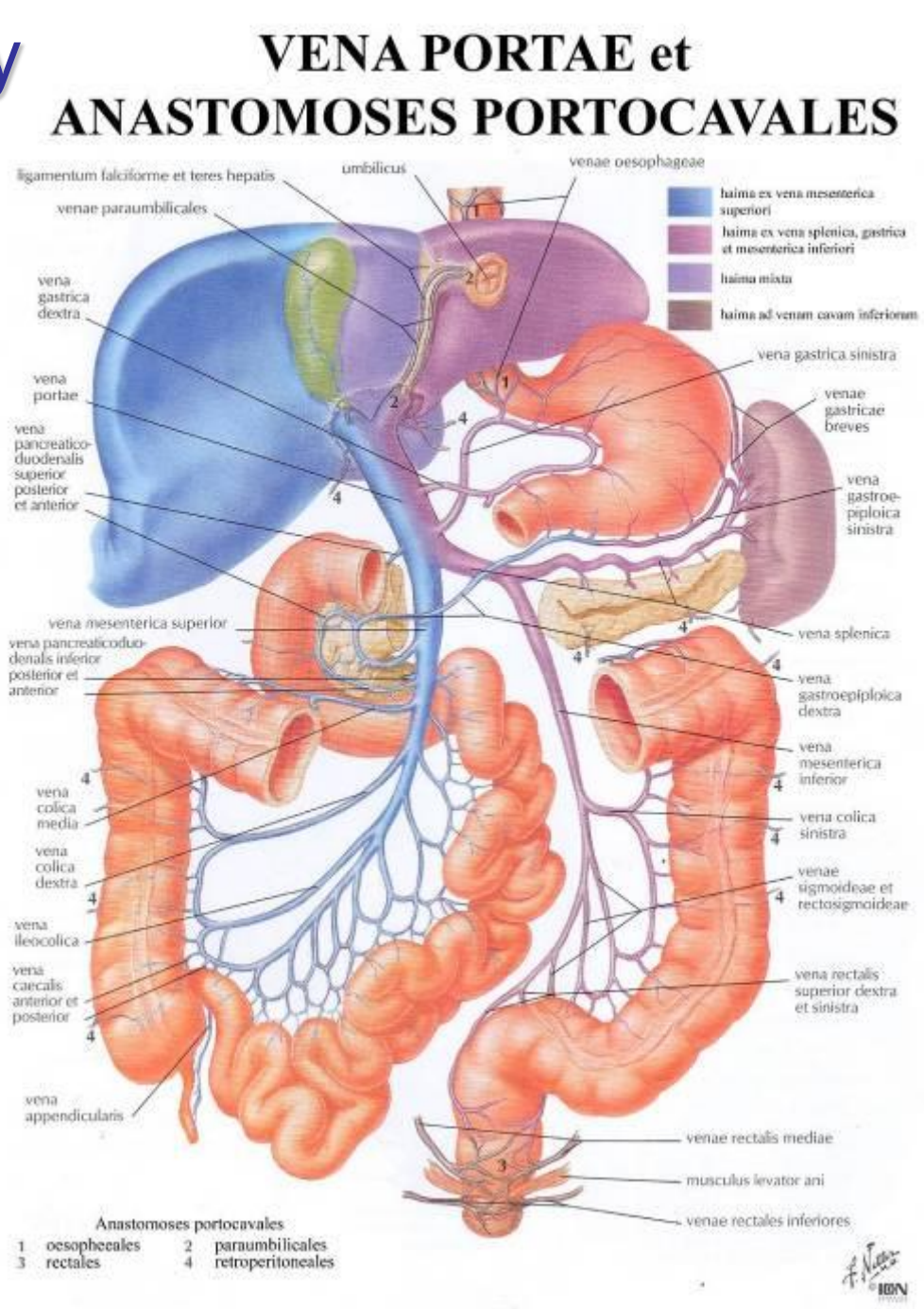

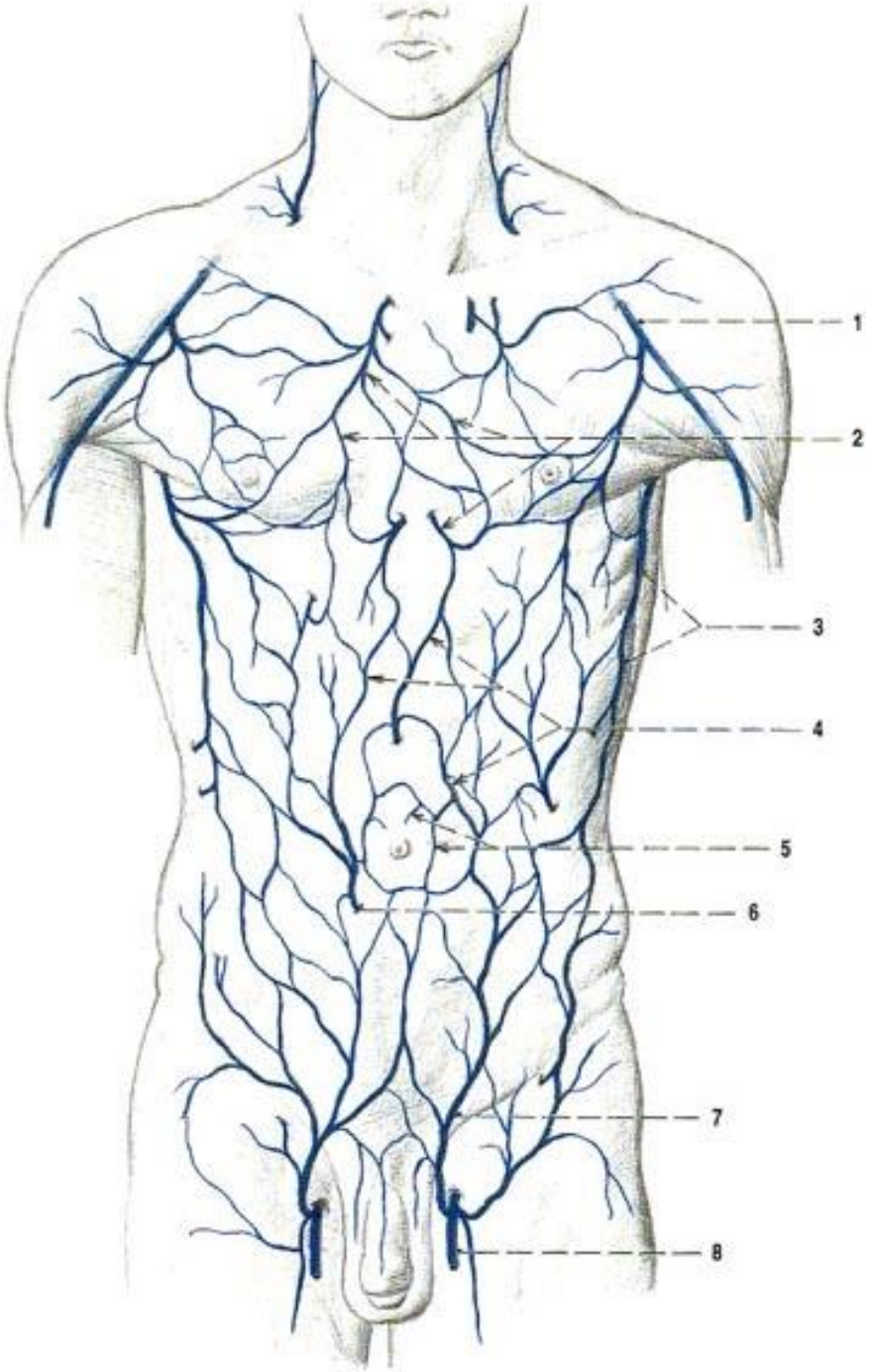
1
2
3
4
5
6
7
8

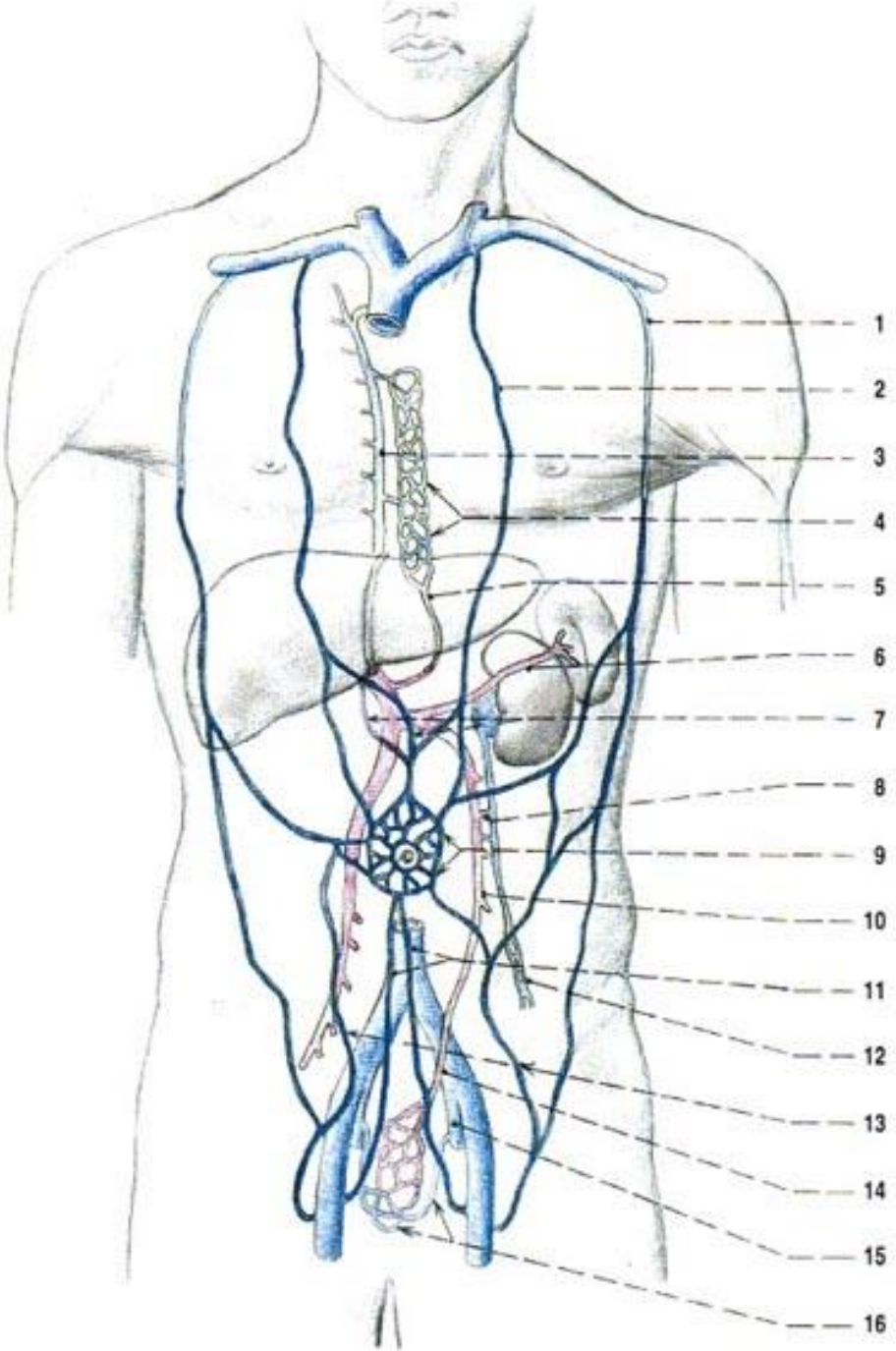
1
2
3
4
5
6
7
8
9
10
11
12
13
14
15
16

Jícnové varixy

úmrtnost: 30-50 % při záchvatu

- trojcestná dvojbalónková sonda (*Sengstakenova-Blackmoreova*)
- endoskopická sklerotizace, ligace (při číslech 3,7,11)

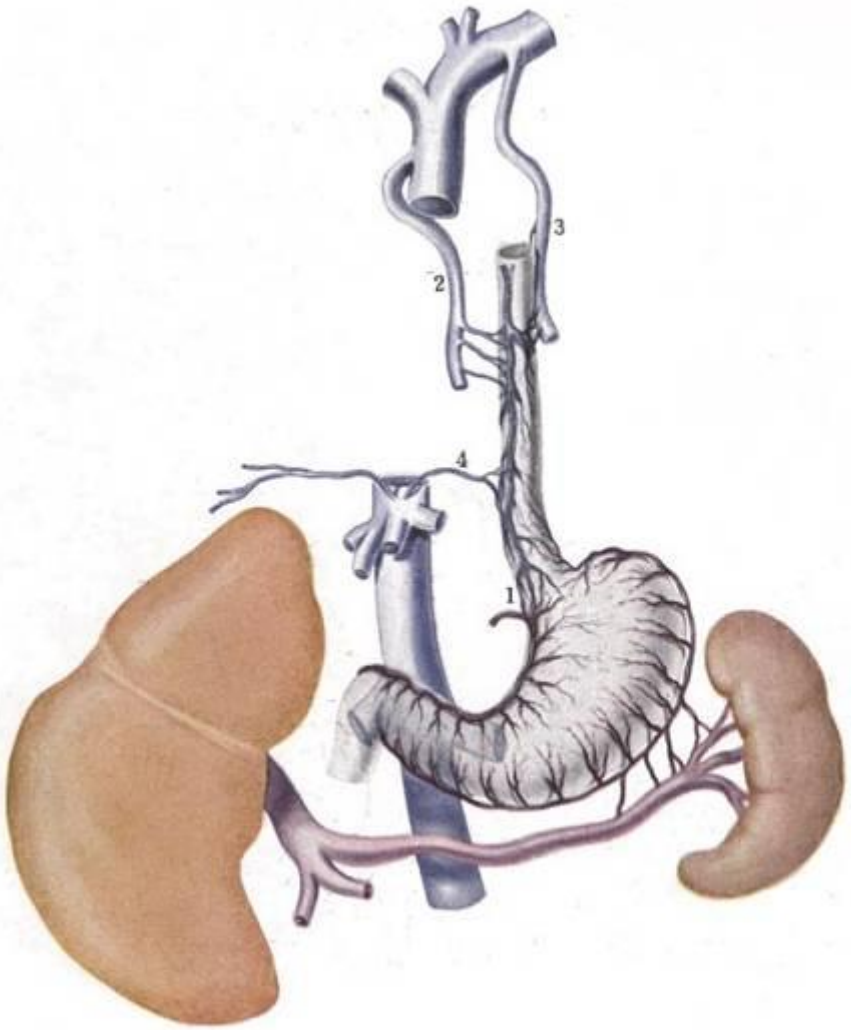

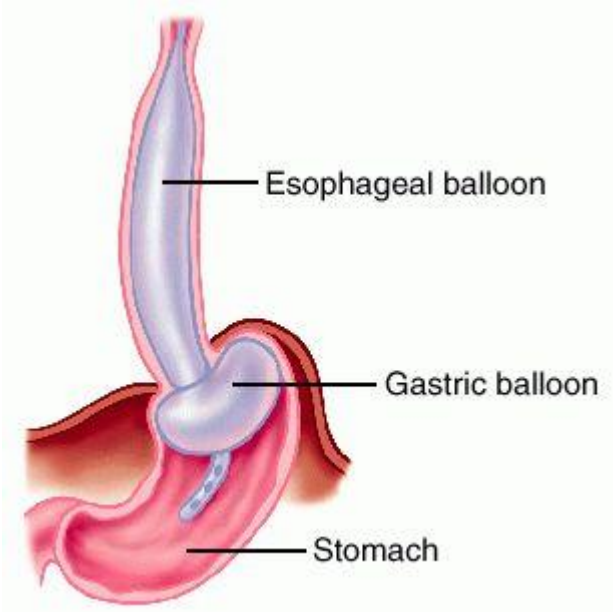

Konečníkové žíly

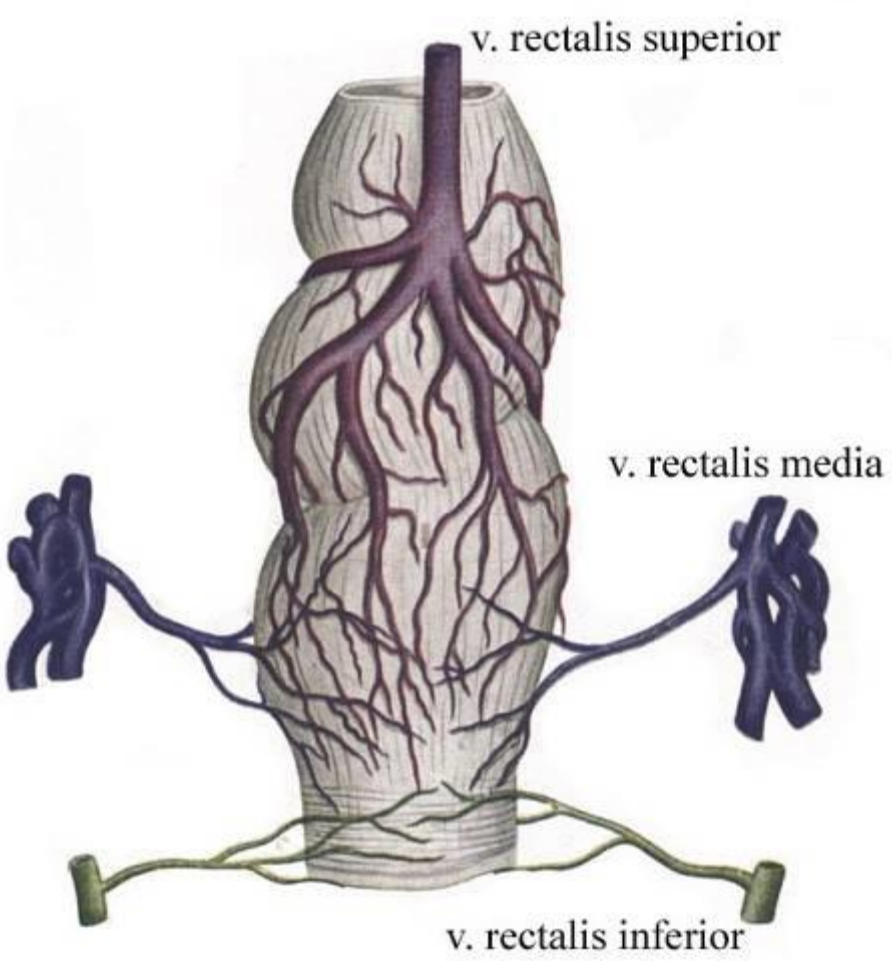

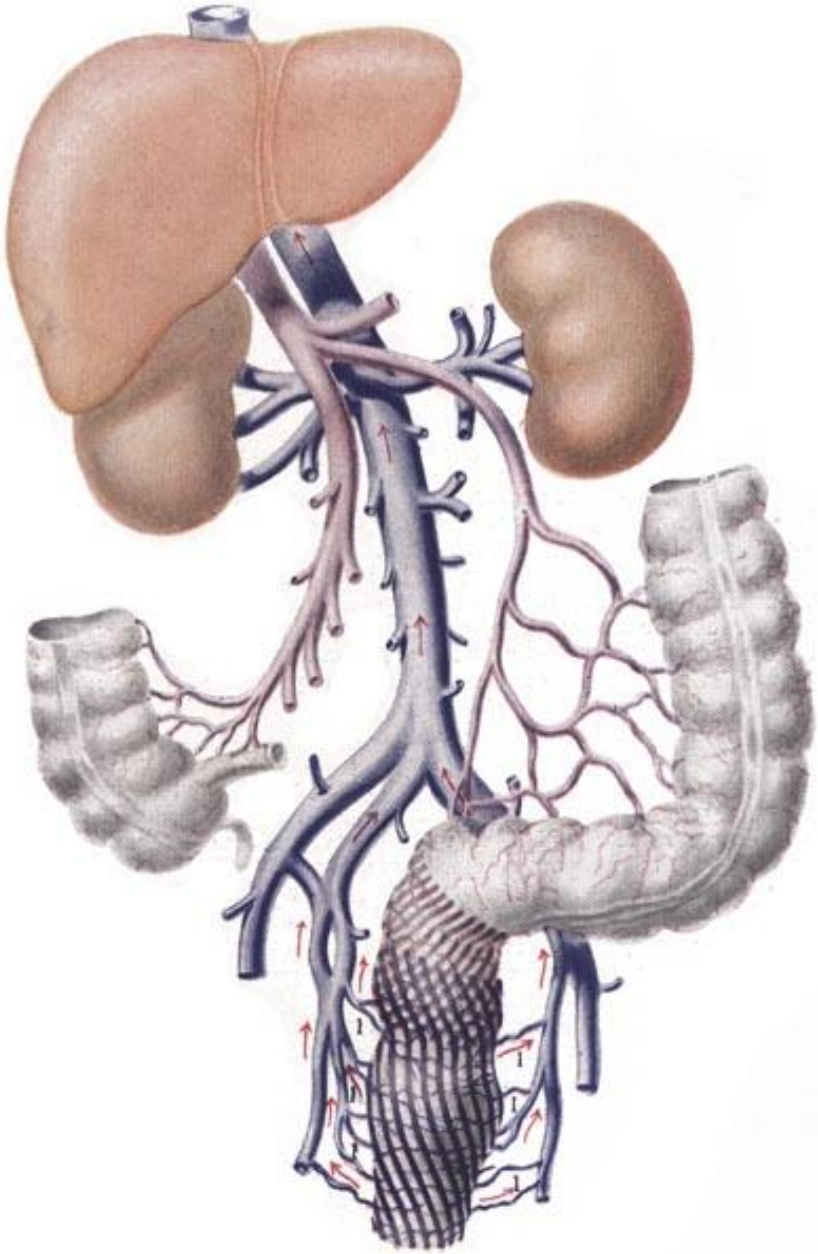
1
1
1
1
1

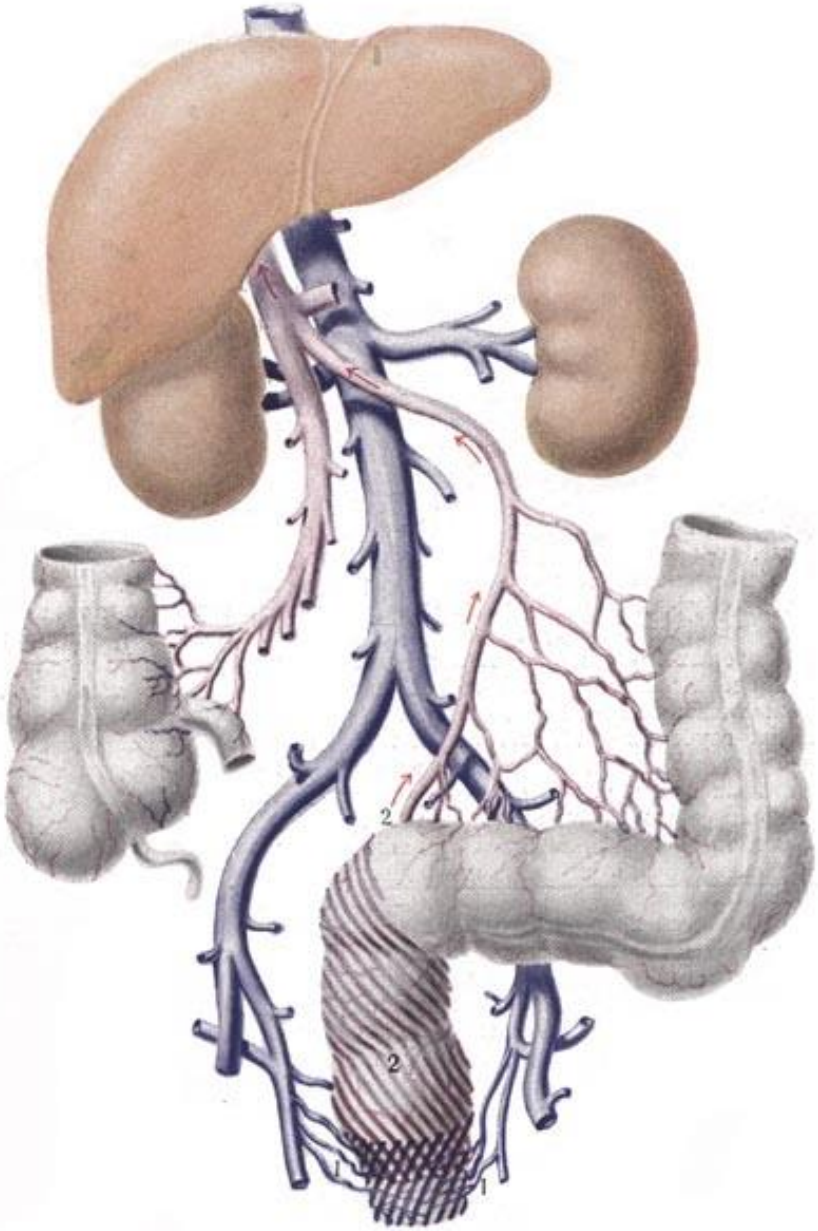
2
2
1
1

Portokaválnální anastomózy - klinika

- portální hypertenze (prehepatální – trombóza; hepatální – cirhóza; posthepatální – trombóza)
- kolaterální řečiště
- jícnové varixy – krvácení
- caput *Medusae* – vzácné (děti pupek, dospělí boky)
- hemoroidy
- ascites
- splenomegalie
- jaterní encefalopatie (amoniak v CNS)

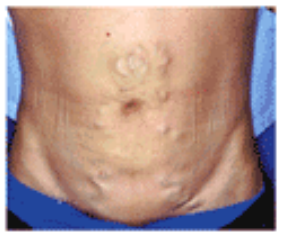

Portokaválnní anastomózy léčba portální hyperteze

- TIPS (transjugulární intrahepatální portosystémová spojka)

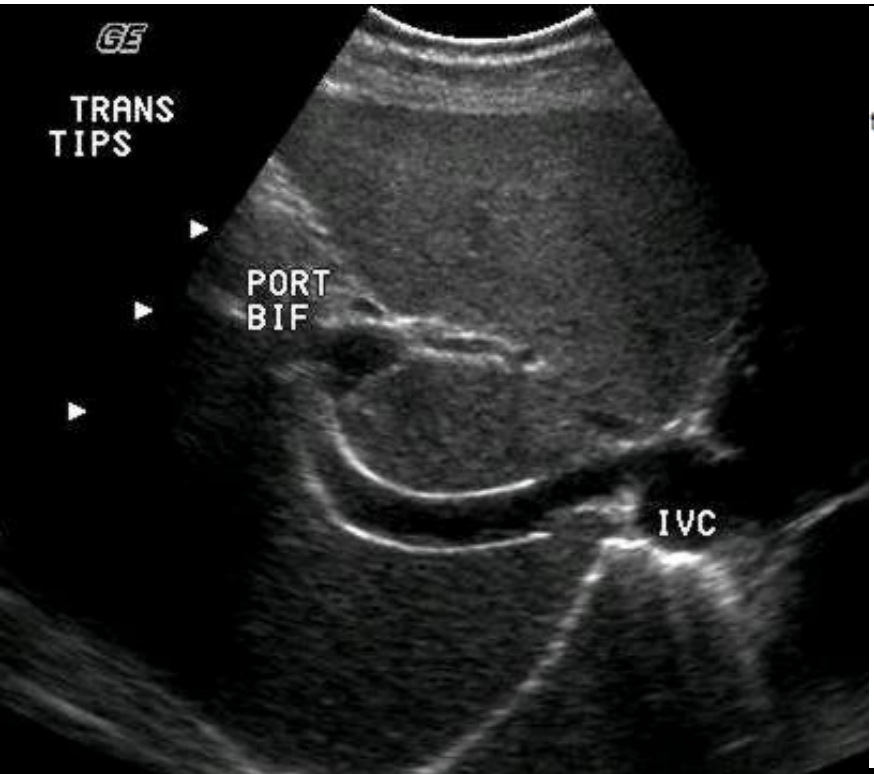

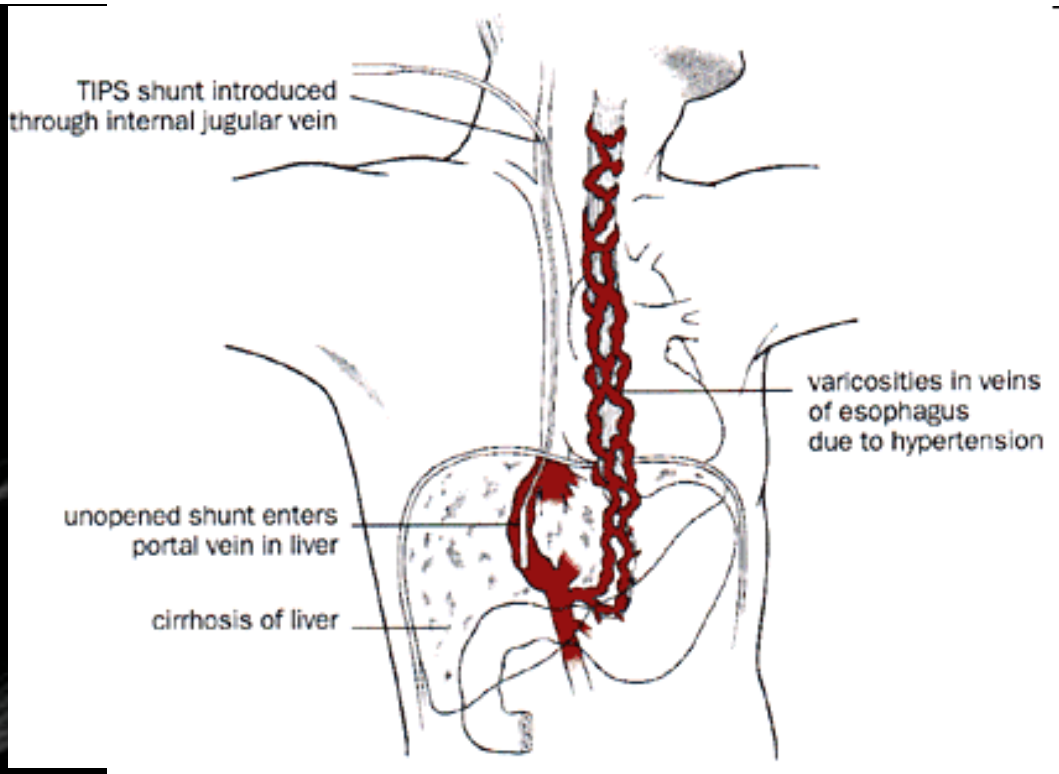

Kavokaválální anastomózy

VCI		VCS
• vv. lumbales	–	v. azygos + hemiazygos
• v. epigastrica inf.	–	v. epigastrica sup.
• v. epigastrica spf.	–	vv. thoracoepigastricae

- plexus venosi vertebrales (*Batson*)

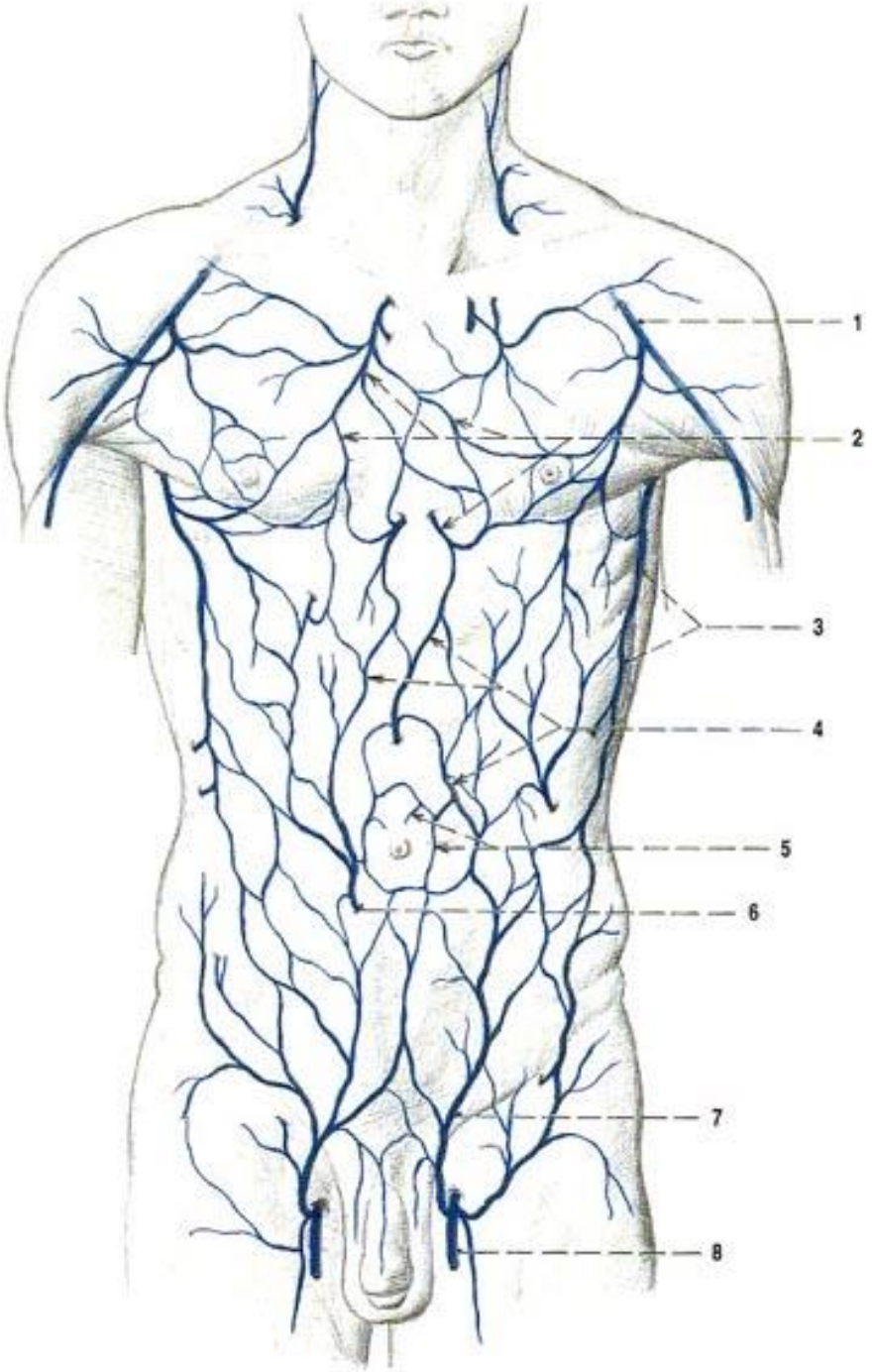
1
2
3
4
5
6
7
8

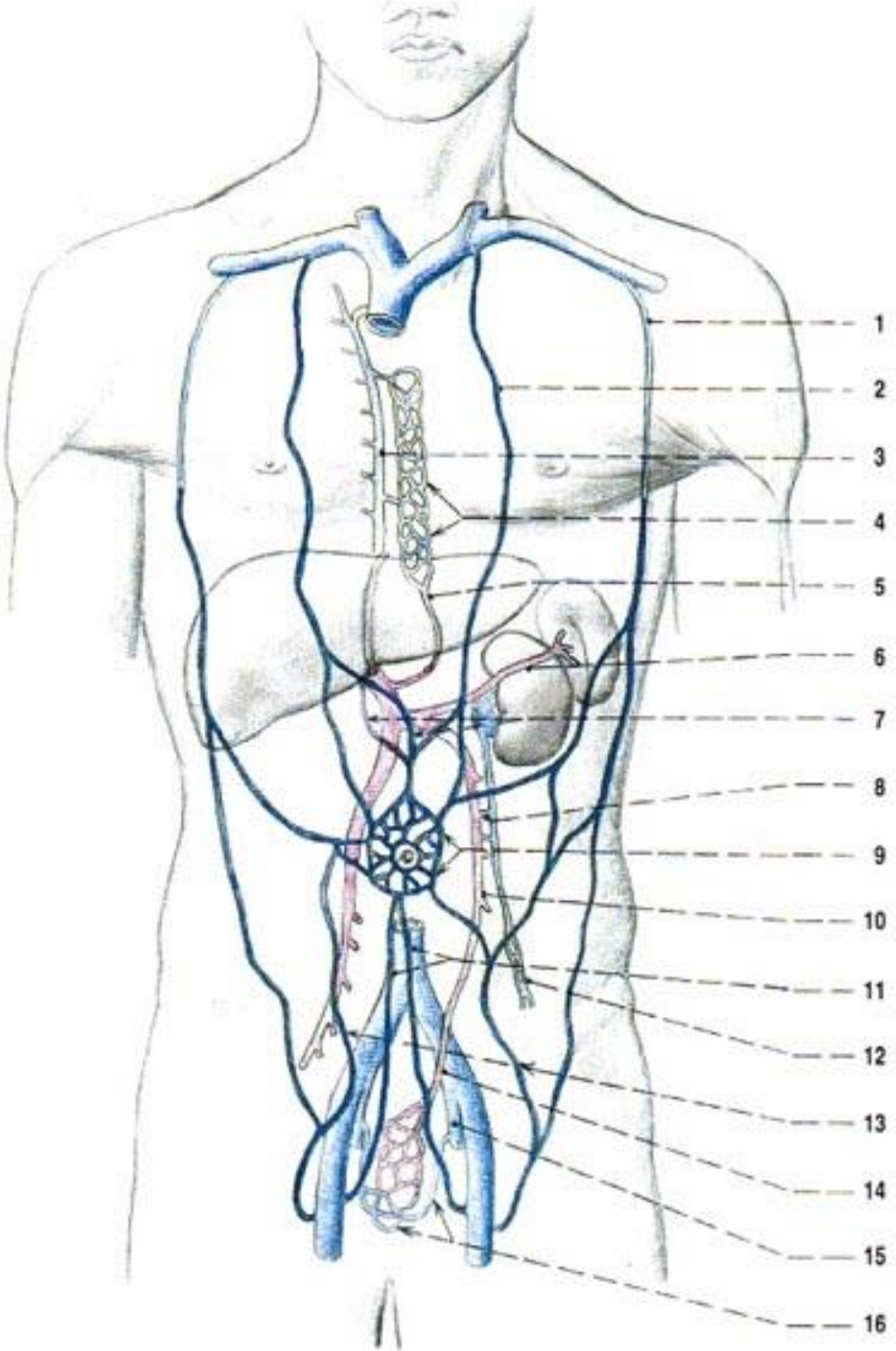
1
2
3
4
5
6
7
8
9
10
11
12
13
14
15
16

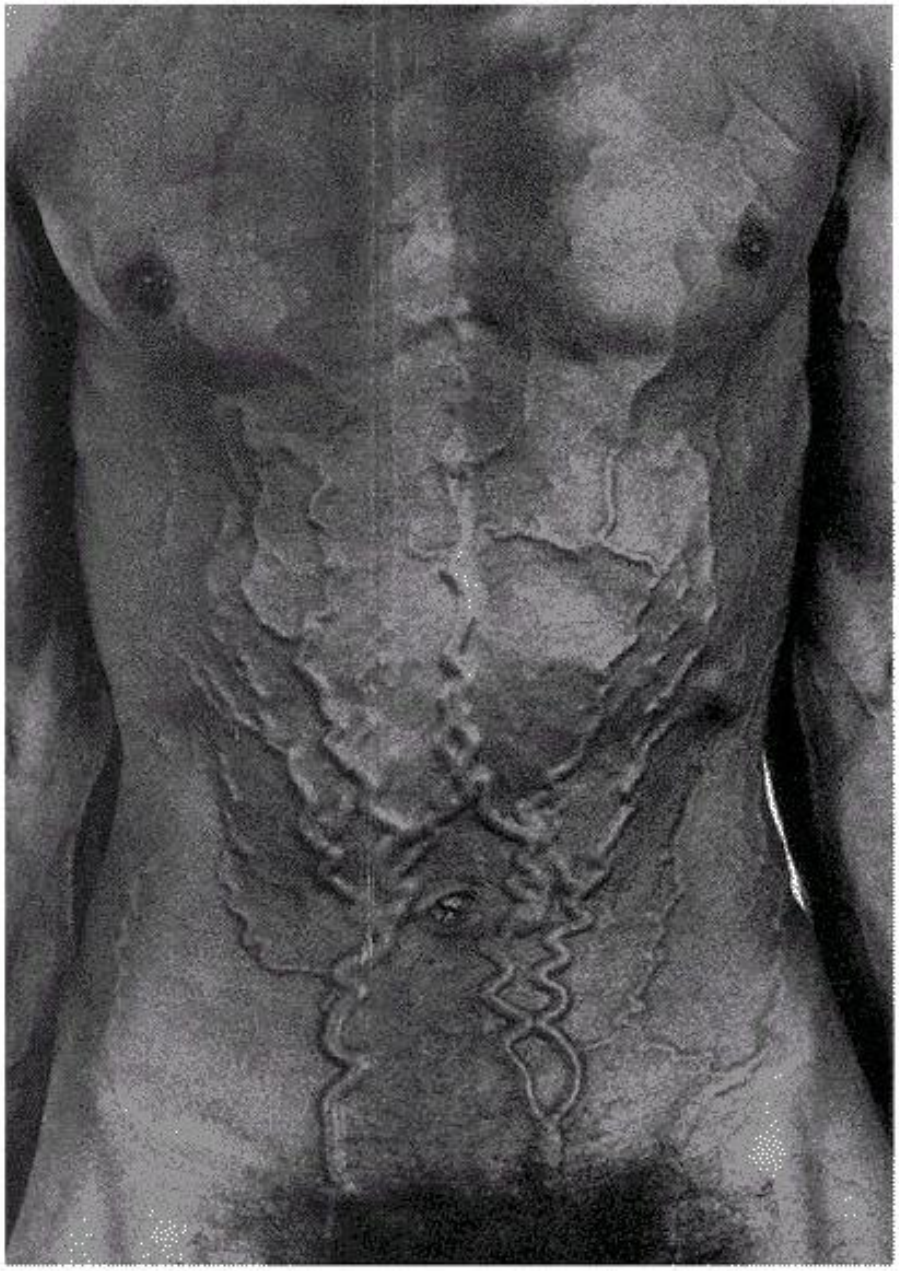

Žíly DK

- povrchová soustava
  - compartimentum saphenum
- hluboká soustava
  - doprovázejí tepny
  - zdvojené až do úrovně fossa poplitea
  - četné spojky kolem tepny
  - četné chlopně
- systema venosum laterale (*Albanesei*)

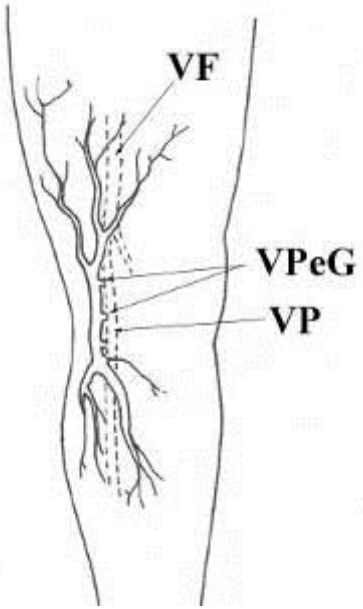

Hluboké žíly DK

- vena femoralis communis
- venae comitantes arteriarum perforantium
- plexus venosus genicularis
- venae soleales + venae gastrocnemii
- vena ischiadica
  - vzácná
  - často spojena s Klippelovým-Trenaunayovým-Weberovým syndromem
    - žíly s městky, kožní hemangiomy a hypertrofie měkkých tkání a kostí)

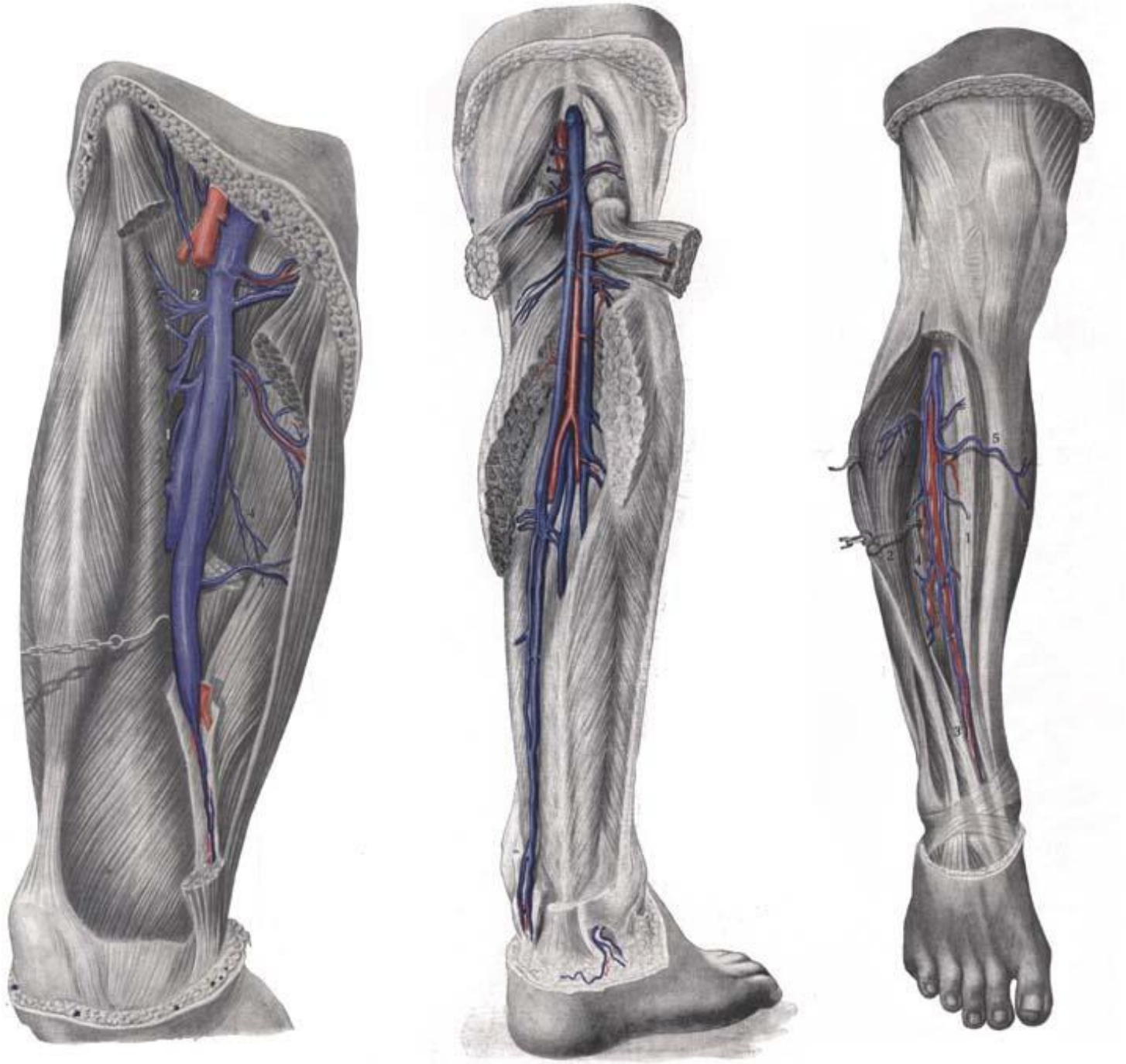
2
5
1
2
4
3

Vena saphena magna

- confluens venosus subinguinalis
- valvula terminalis + preterminalis
- v.s.m. accessoria
  - ant., post., superficialis
- v. circumflexa femoris ant., post.
- běží s n. saphenus
- *sonografie: „egyptské / Kleopatřino oko“*

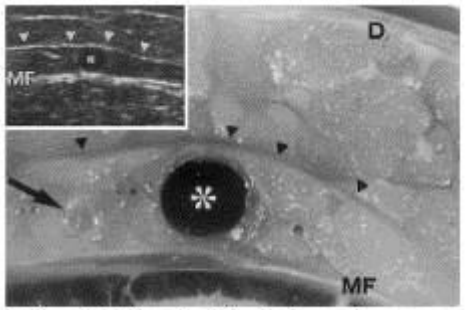

D - dermis, MF - svalová fascie, * - v. saphena magna

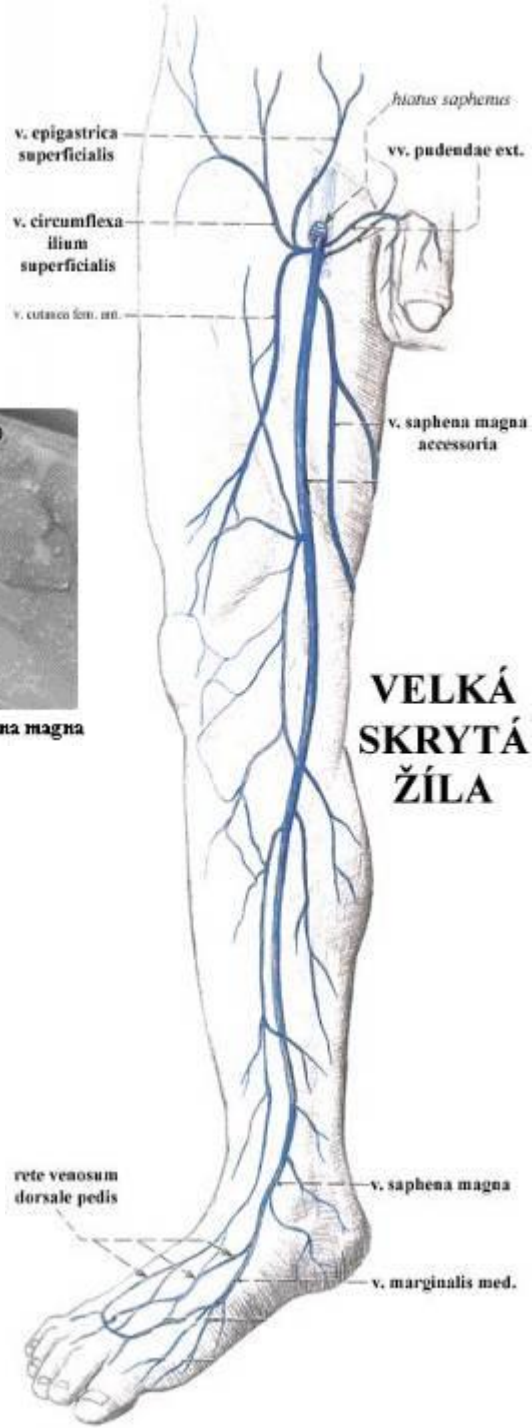

Vena saphena magna – ultrazvuk

- „egyptské / Kleopatřino oko“

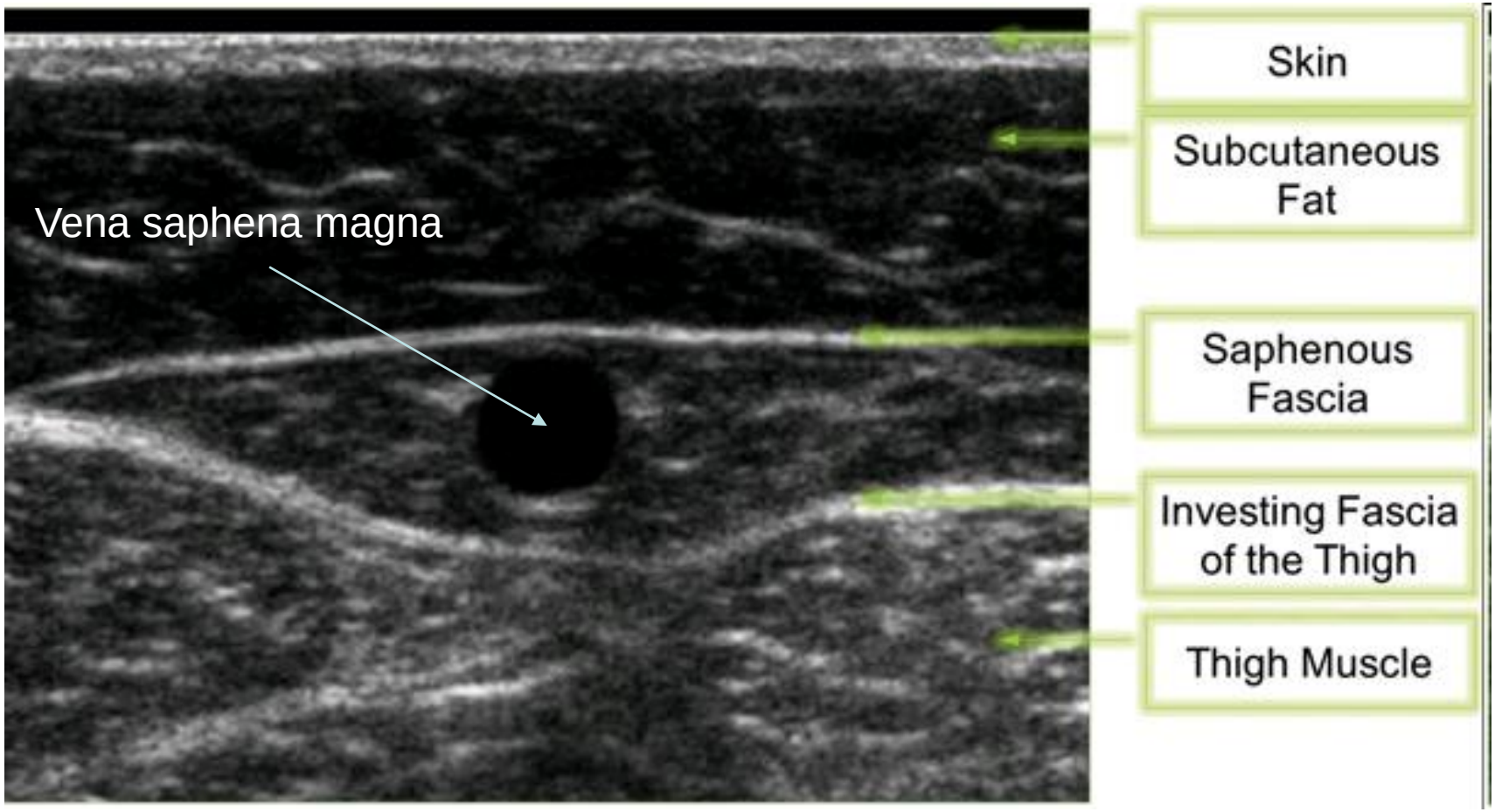

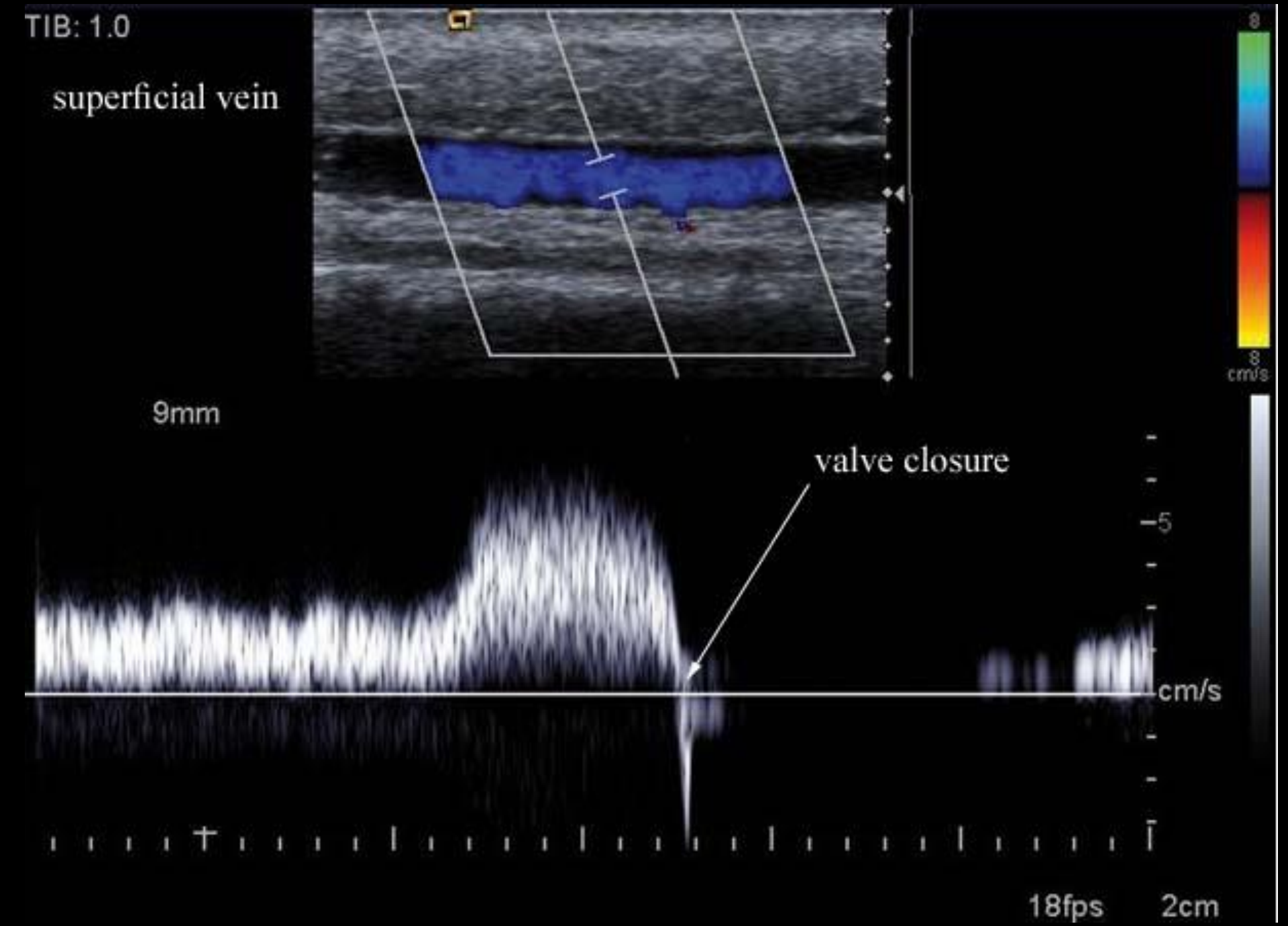
TIB: 1.0
superficial vein
8
8
cm/s
9mm
valve closure
5
cm/s
18fps
2cm

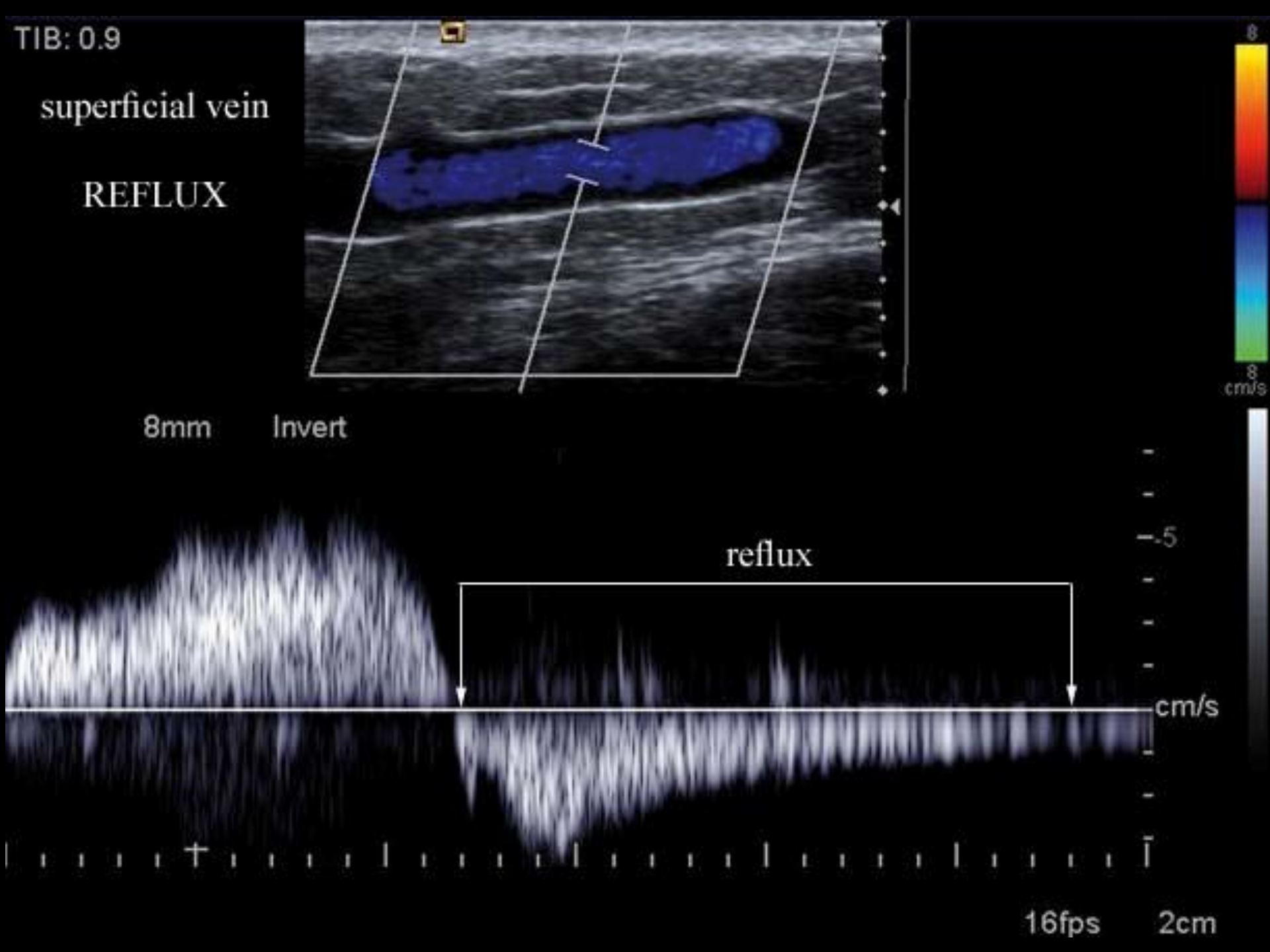
TIB: 0.9
superficial vein
REFLUX
8
8
cm/s
8mm
Invert
reflux
-5
cm/s
16fps
2cm

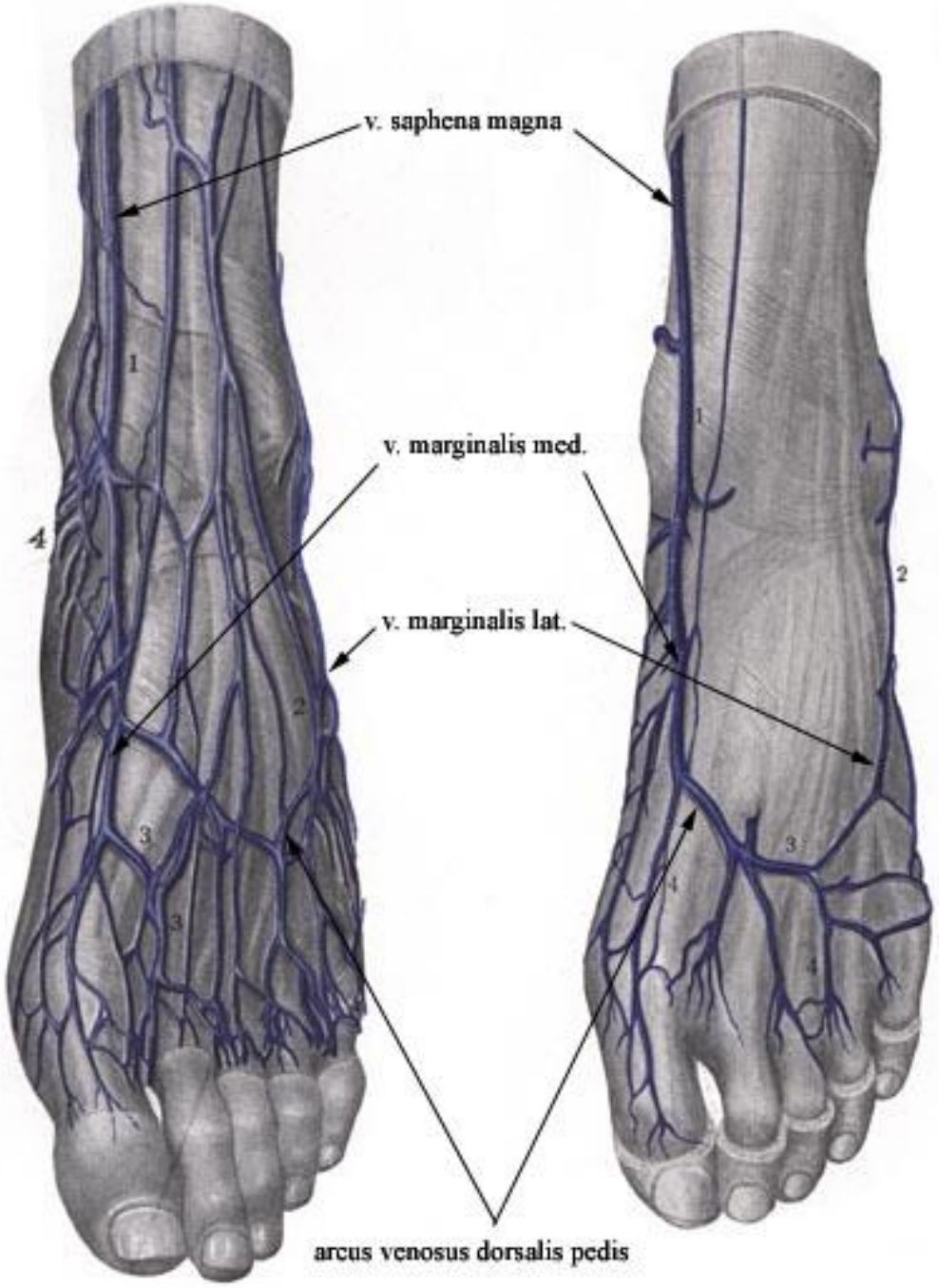
v. saphena magna
v. marginalis med.
v. marginalis lat.
arcus venosus dorsalis pedis

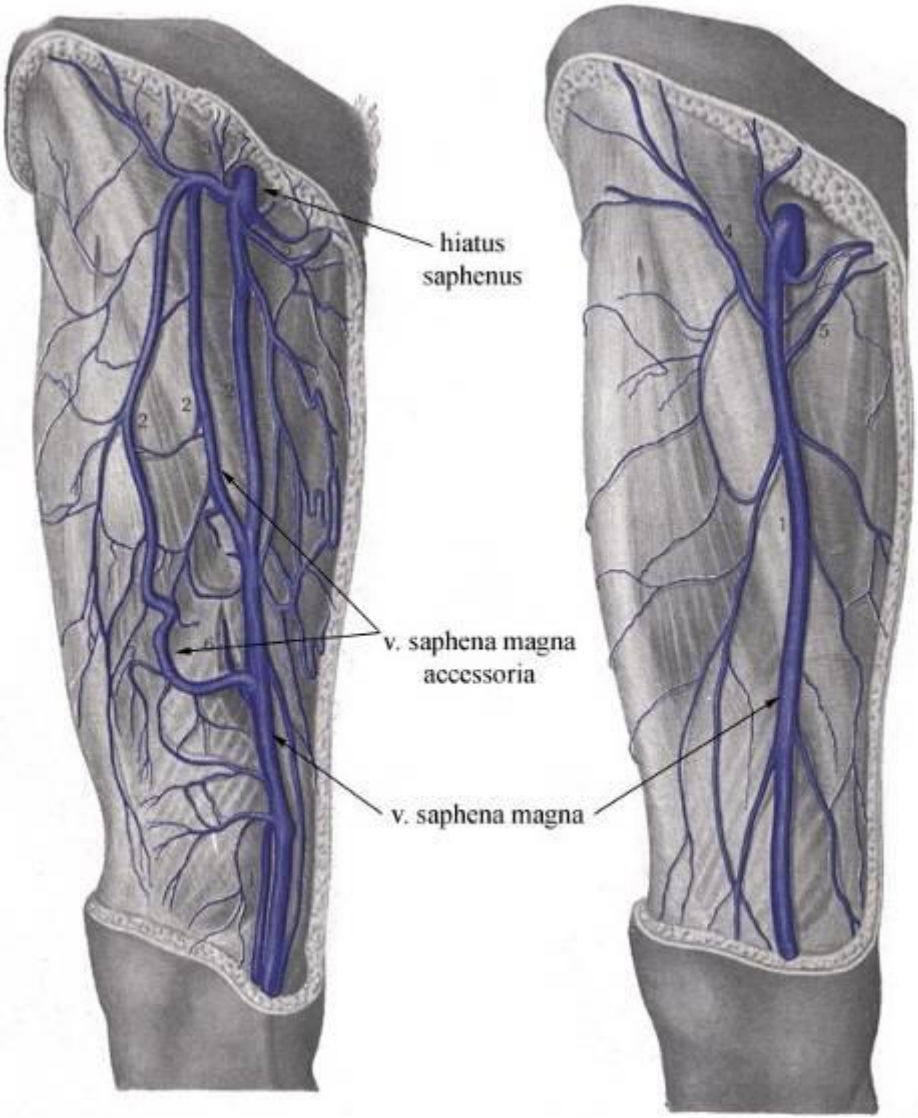

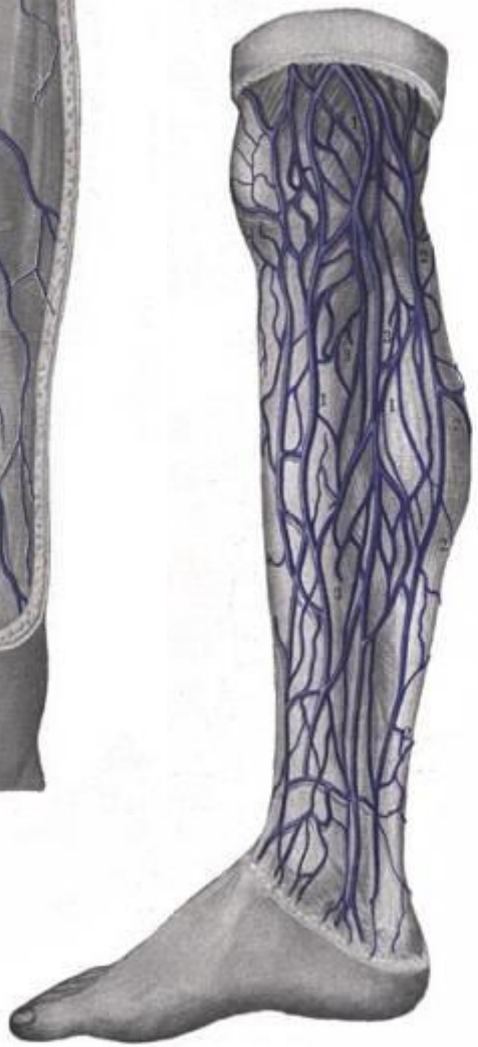

Vena
saphena
magna

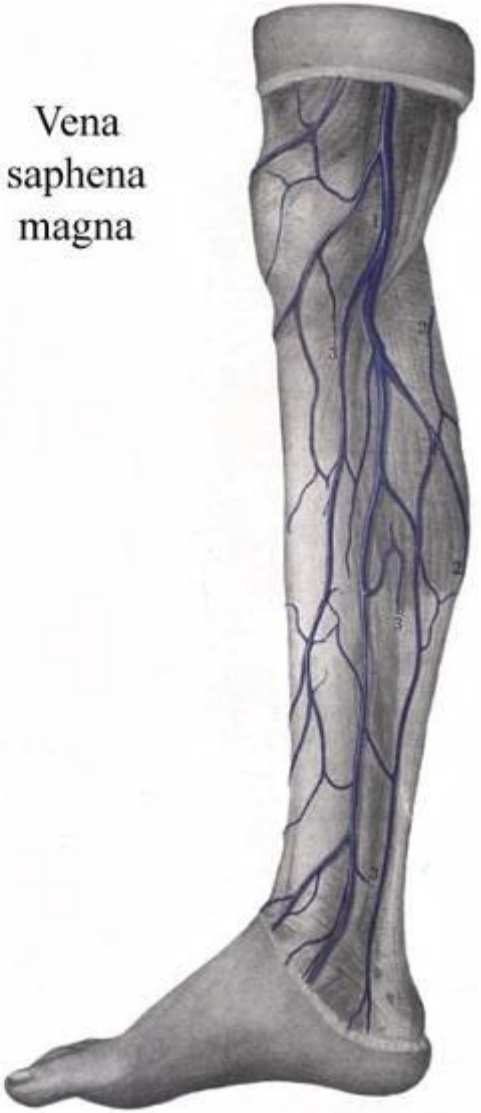

Confluens venosus subinguinalis

klinicky „Crosse“

= terminální úsek VSM ohraničený chlopněmi

- v. epigastrica superficialis
- v. circumflexa ilium superficialis
- v. pudenda externa superficialis
- v. saphena magna accessoria anterior et posterior

- *krosektomie*

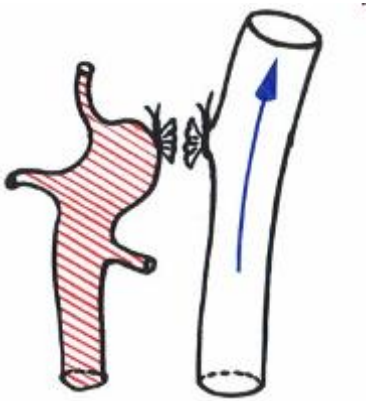

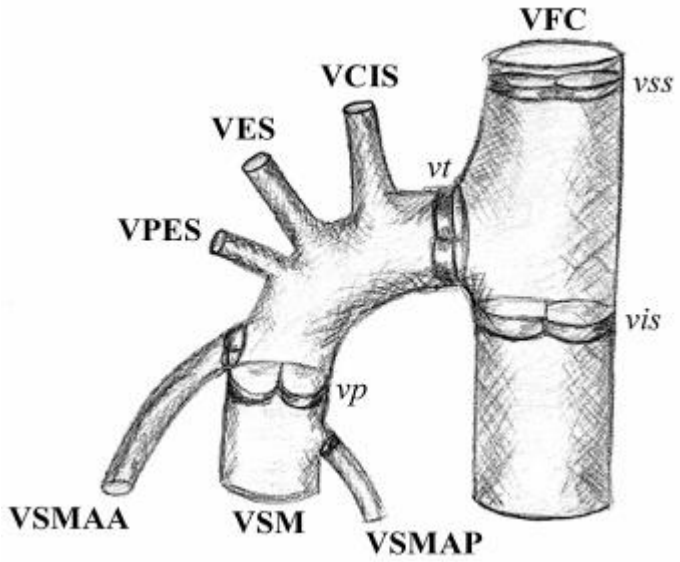

Topografie VSM

- compartimentum saphenum
- hiatus saphenus
- trigonum femorale

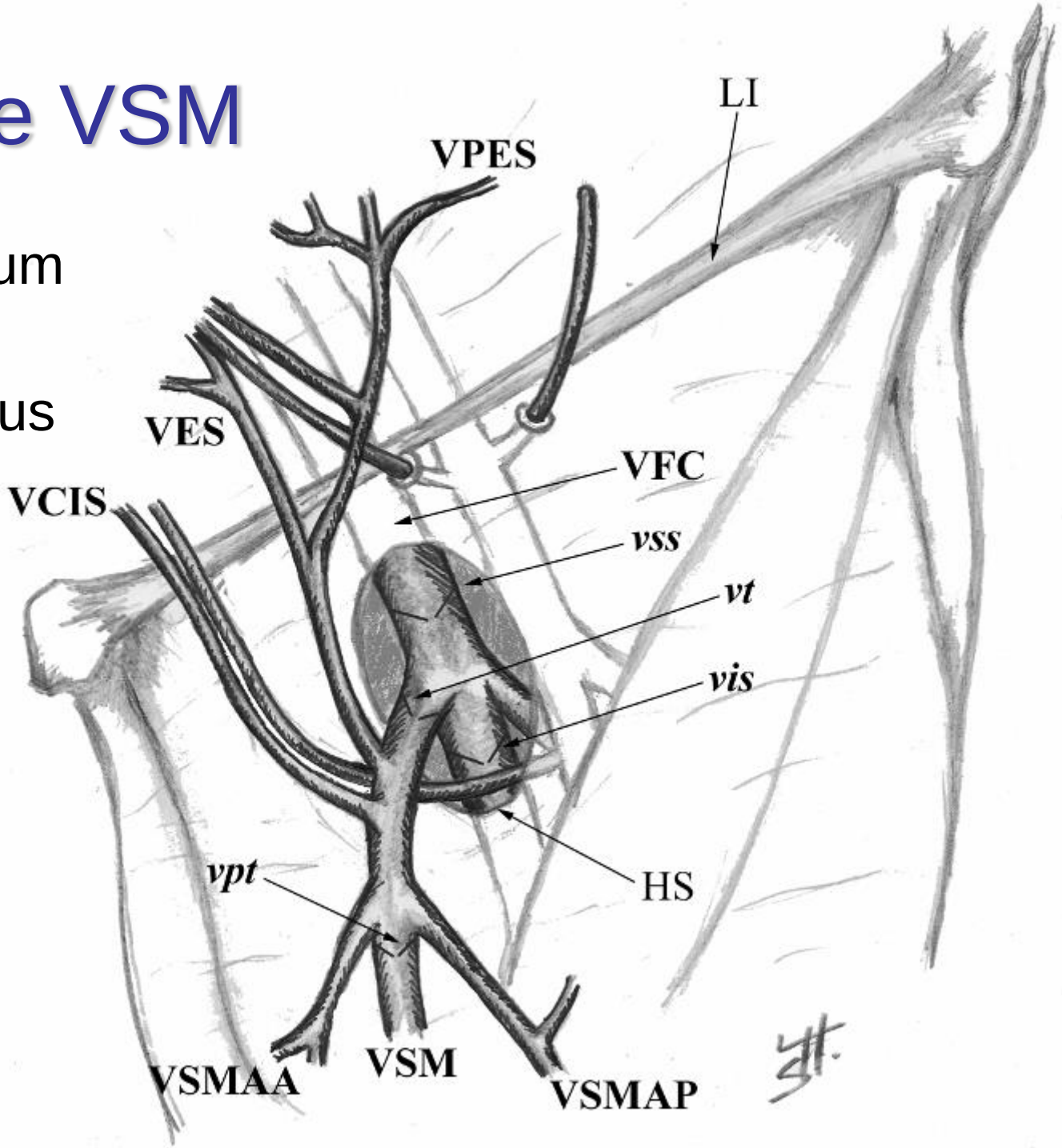

Vena saphena parva

- valvula terminalis + preterminalis
- v.s.p. accessoria superficialis
- extensio cranialis venae saphenae parvae (dříve „v. femoropoplitea)
- běží s n. suralis

venae intersaphenae

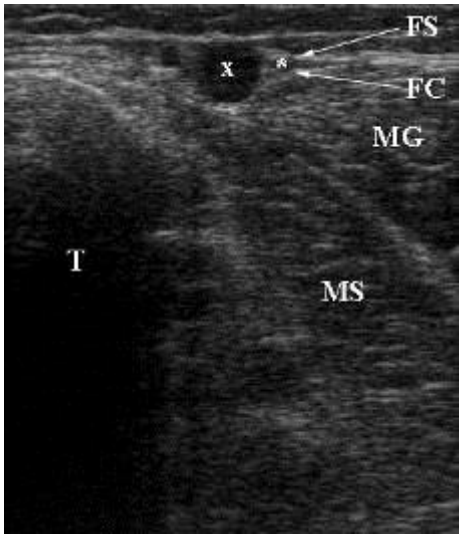

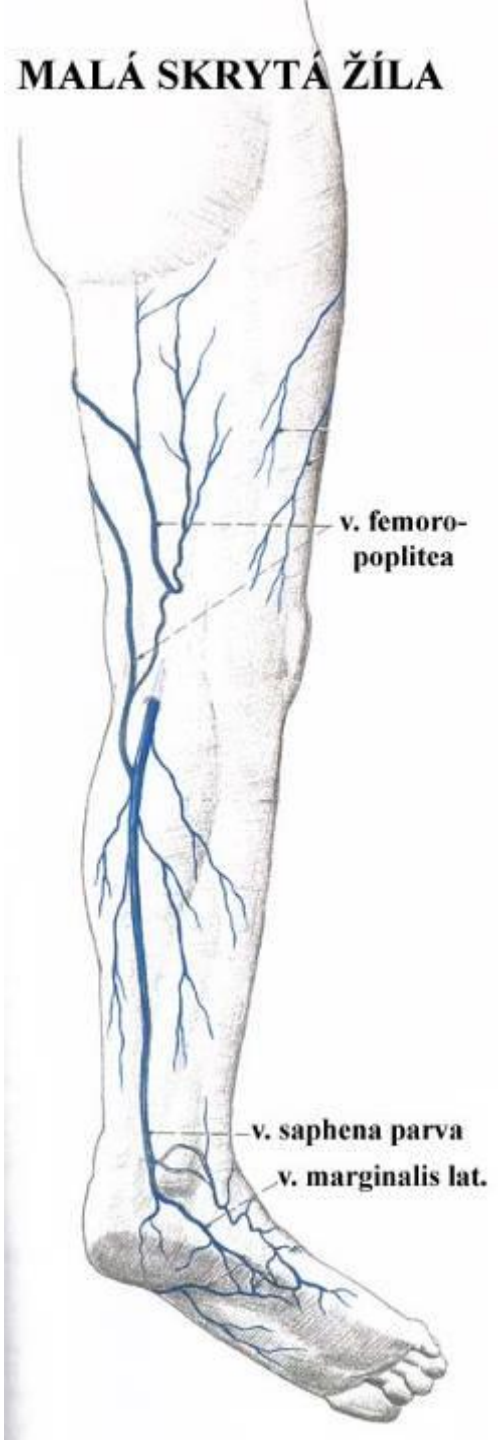

vena saphena parva

Venae perforantes
Transfasciální spojky = perforátory

- poprvé namaloval Leonardo da Vinci
- propojují hlubokou (80 % krve) a povrchovou soustavu
- obsahují chlopně
- při nedostatečnosti chlopní → varixy
- 6 skupin podle polohy

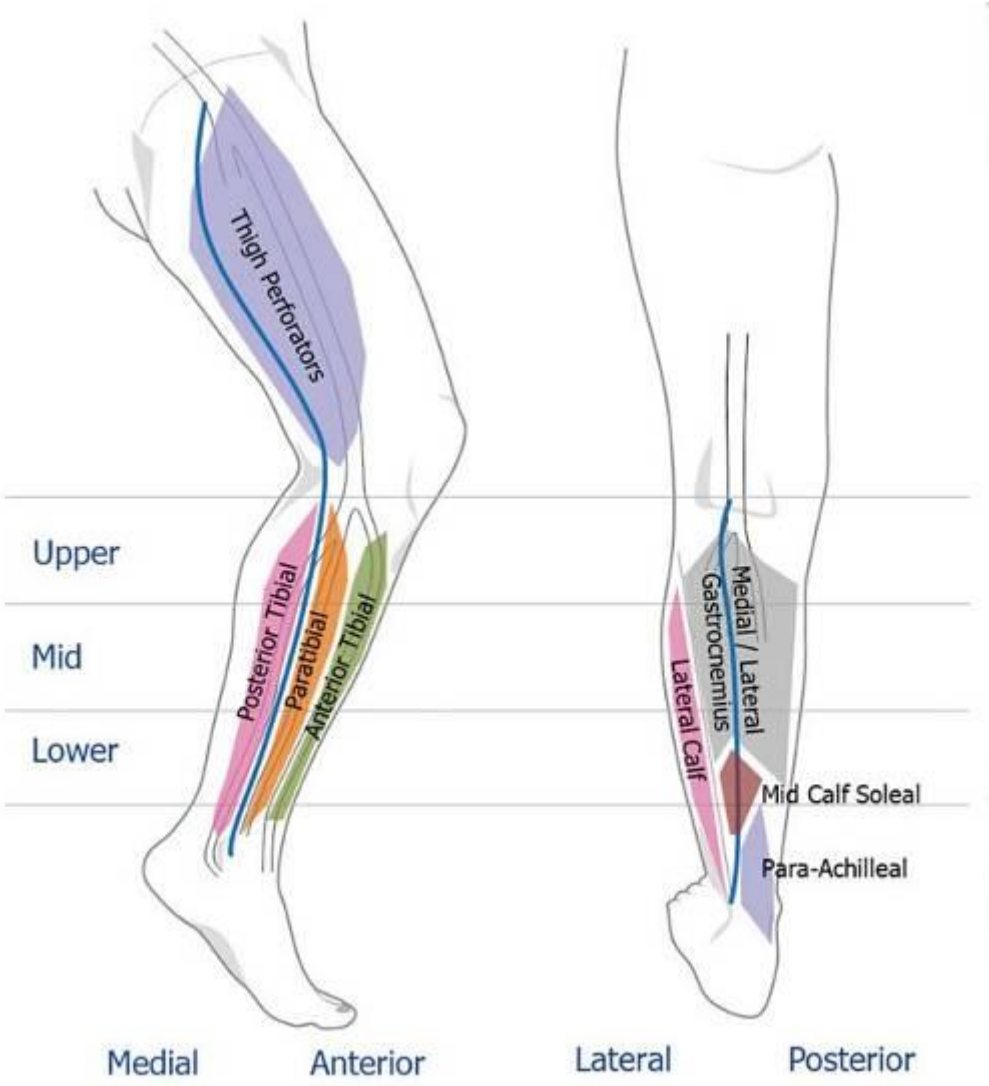

Venae perforantes
Transfasciální spojky = perforátory

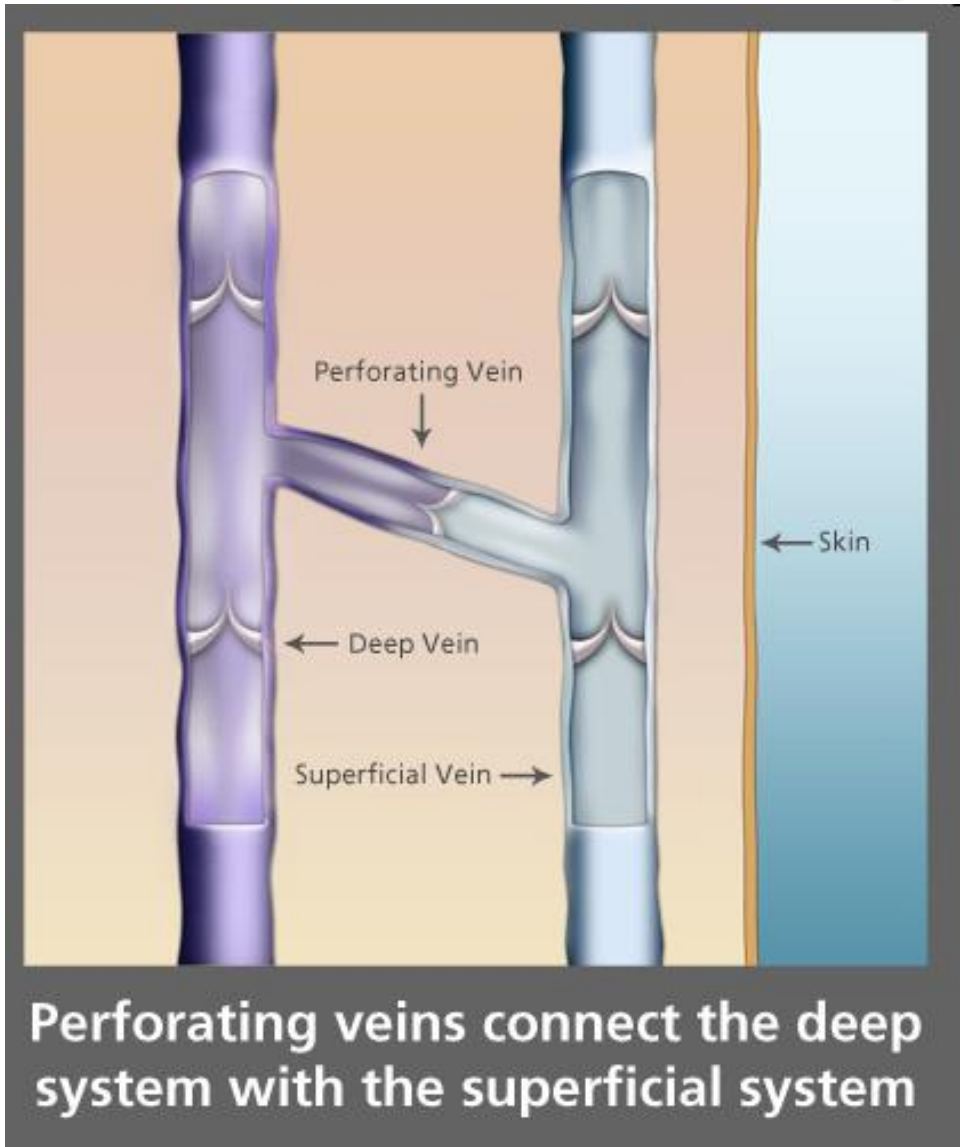

Perforating veins connect the deep system with the superficial system

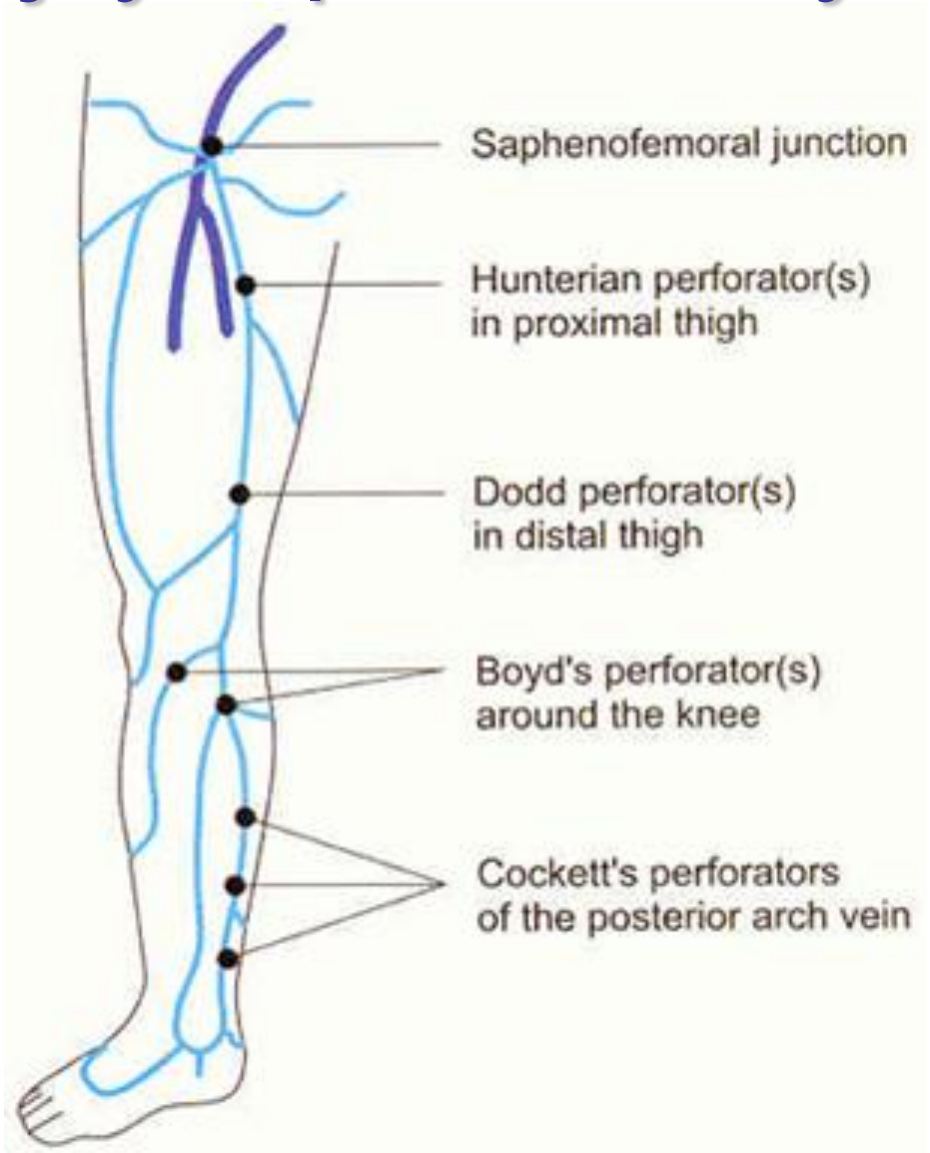

Venae perforantes

- jednoduché, zdvojené nebo vícečetné
- provázené malou tepnou a kožním nervem (Staubesandova triáda)
- 6 skupin: noha, hlezno, bérec, koleno, stehno, hýždě
- eponyma: Cockett, Boyd, Dodd
- <u>př.:</u> *venae perforantes cruris posteriores tibiales = Cockettovy perforátory*
  - propojují v.s.m. accessoria posterior venae tibiales posteriores
  - 18.5, 13.5 a 7 cm proximálně od chodidla

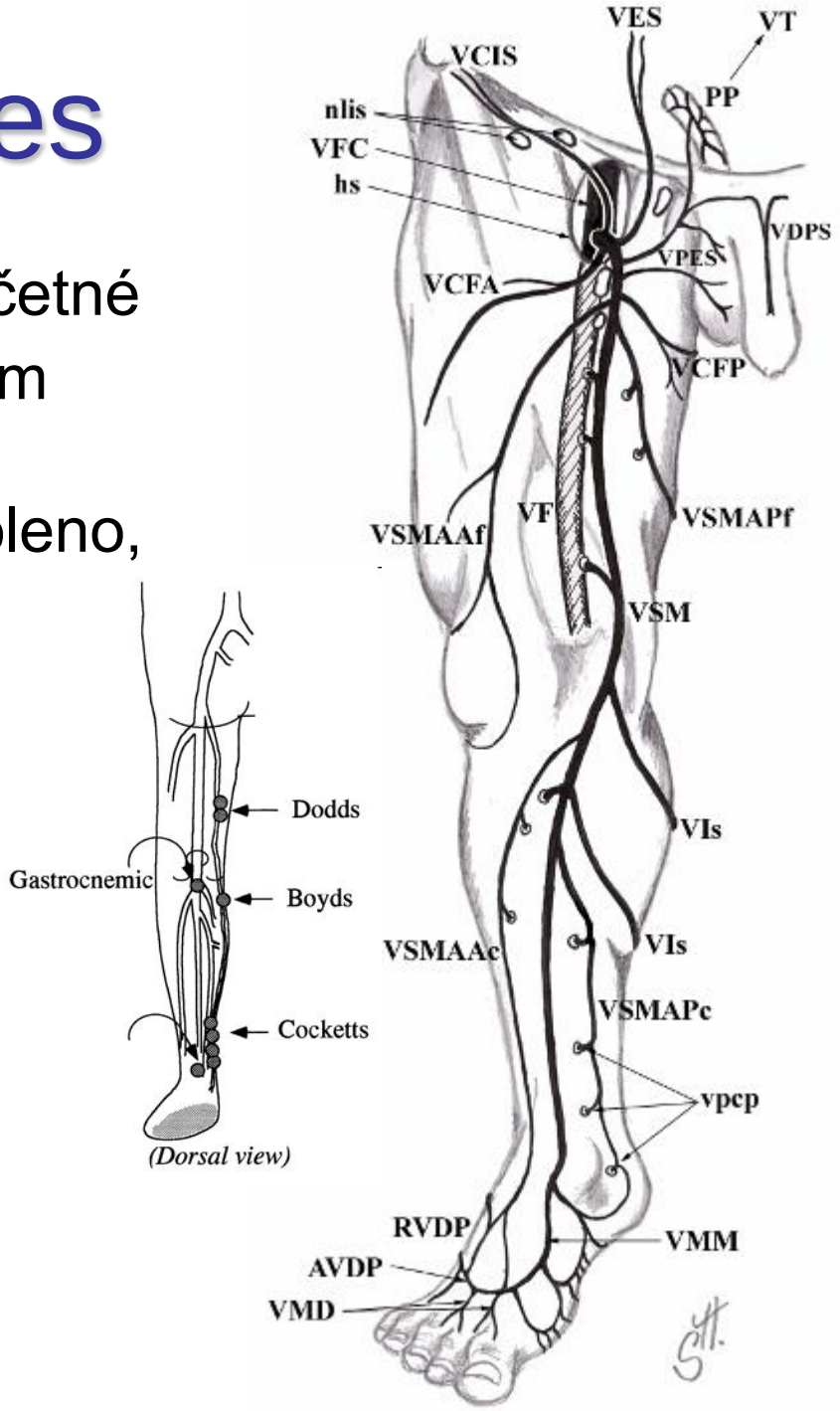

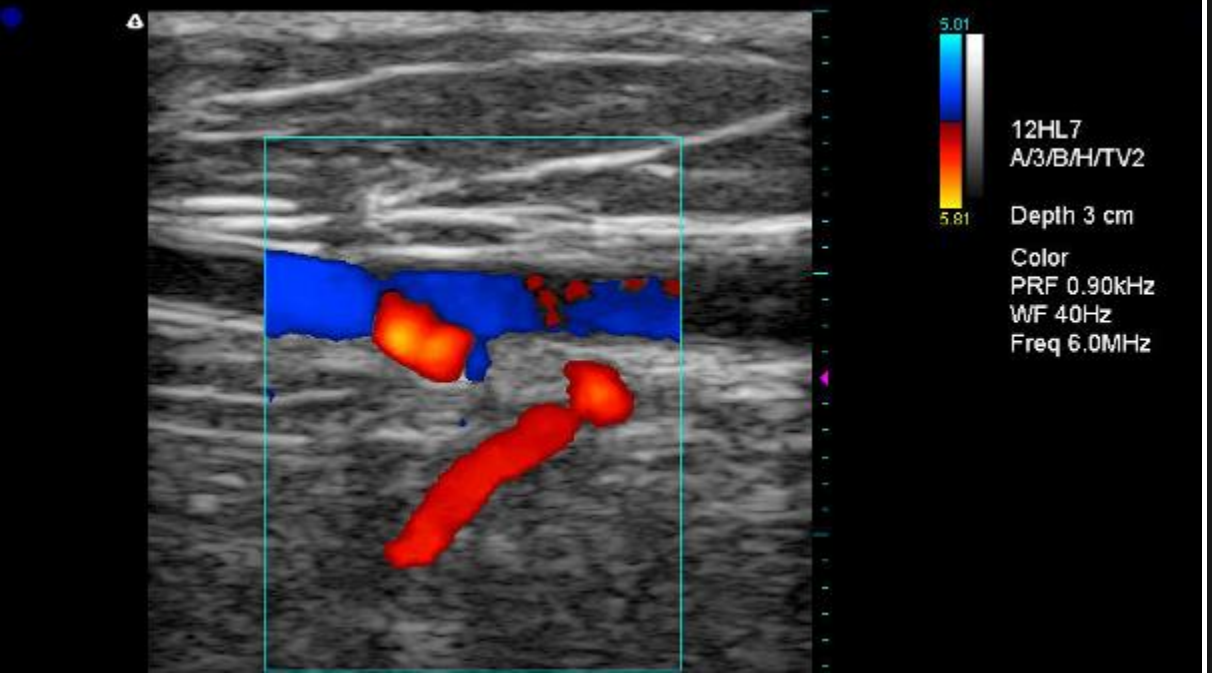

4-mm tibiální perforátor

ID:
L38
VEN
26-10-2010
08:53:39
FR: 8
10/ 37
PERFORANTE
F:9.0 MHz
G:76 dB
CG:55 %
6.0
2.0kHz
DR:45 dB
SM: 4
VF: 2
CF: 2
MENU PAGE CD-1
1:
2:
3:
4:
5:
6:

Žíly DK – 3D-fleboCT

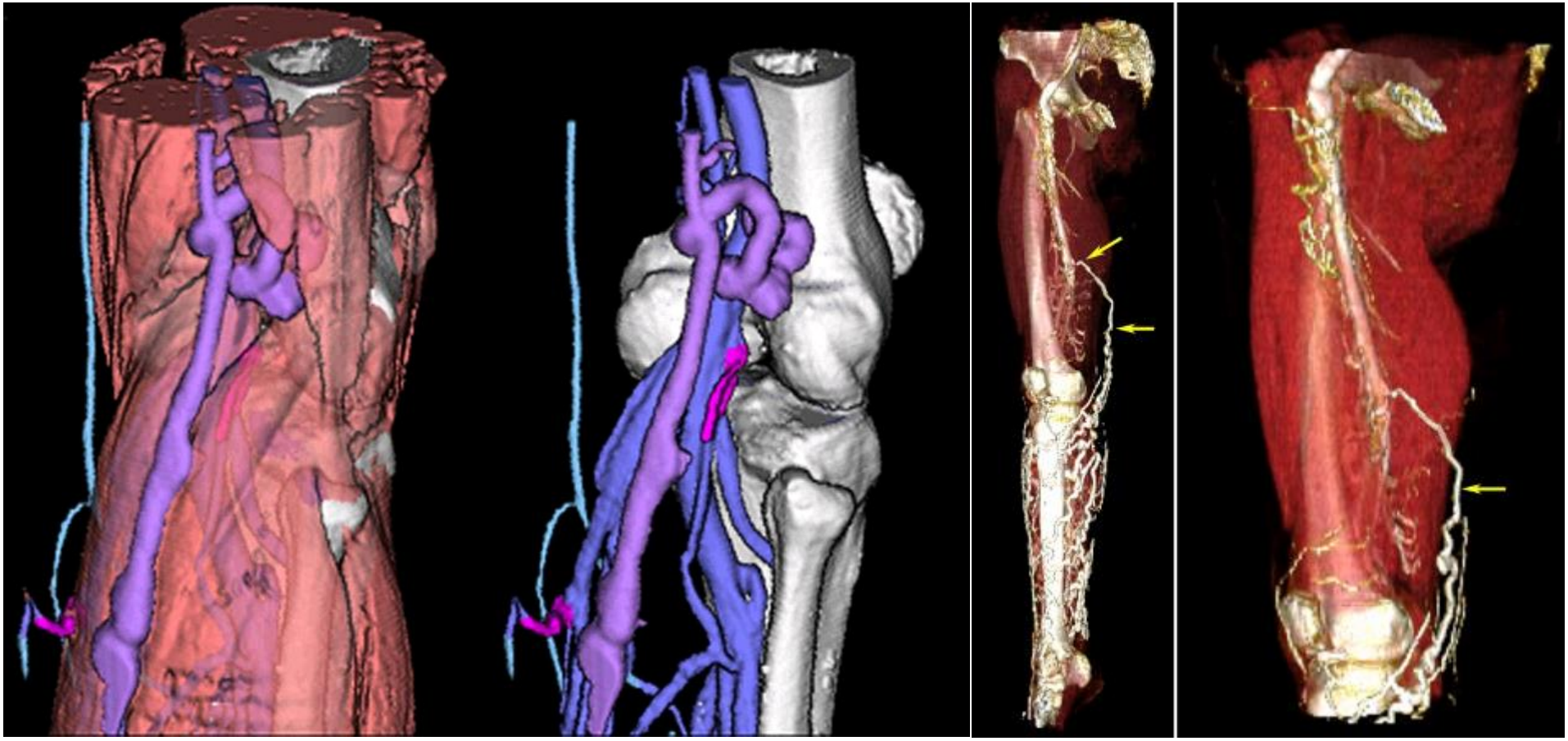

Varixy VSP

Dodd

V. axialis – vývojová céva

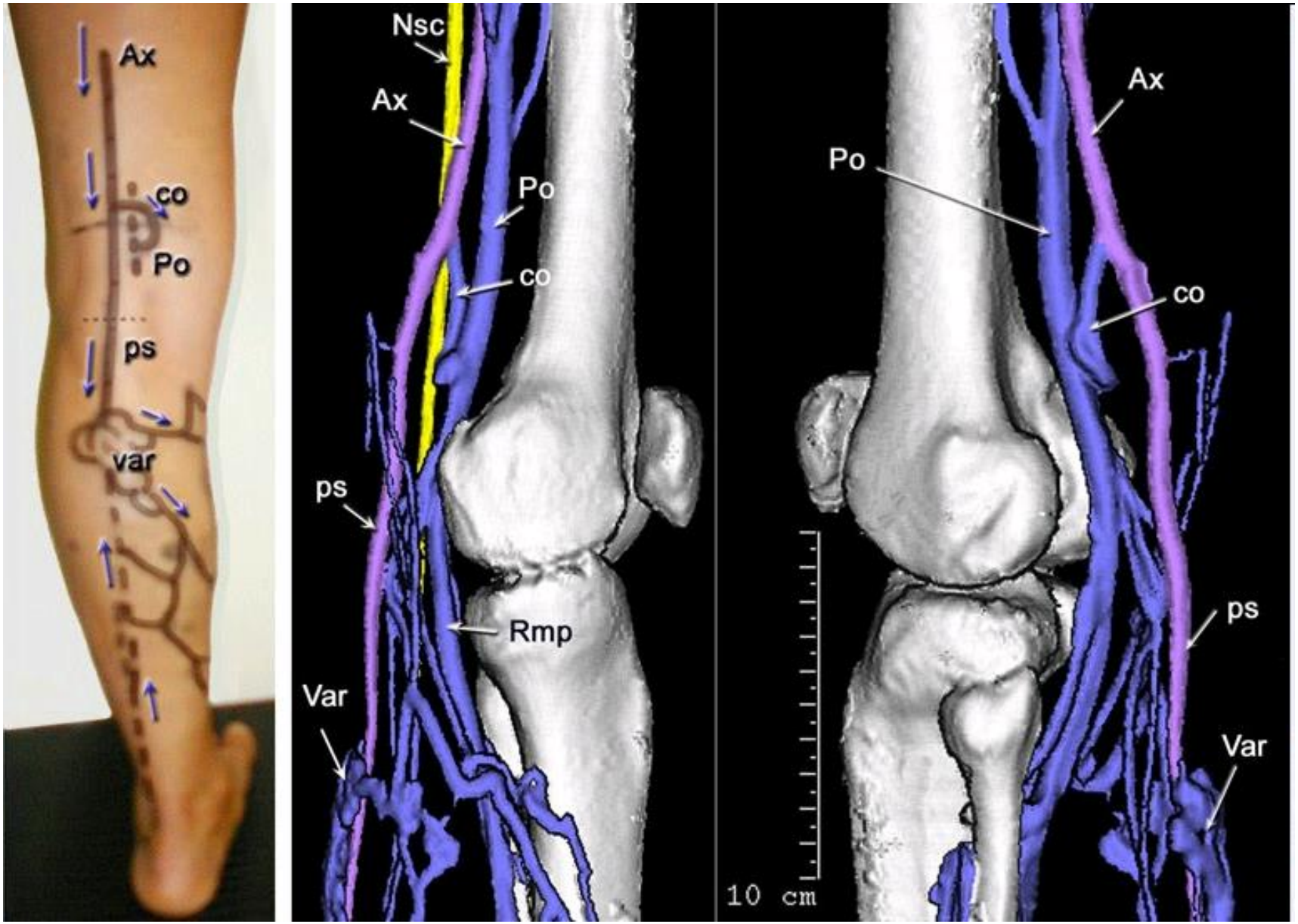

Varixy

- změna toku krve → žilní hypertenze → ischémie

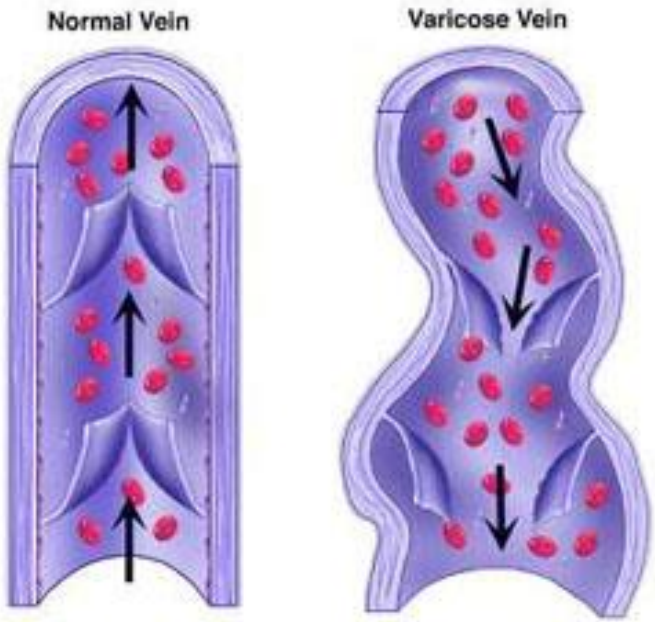

Copyright © 2003 Society of Interventional Radiology

Žíly DK - klinika

- chronická žilní insuficience
- povrchová tromboflebitída
- hluboká žilní trombóza – trombembolické nemoc
- varixy (*varices*) = městky; „křečové žíly“
  - primární (porucha kolagenu), sekundární
  - léčba: flebektomie (stripping) + krosektomie, miniinvazivní operace (CHIVA – La **C**ure **H**émodynamique de l'**I**nsuffisance **V**eineuse en **A**mbulatoire), endovenózní laser (EVLT), sklerotizace, radiofrekvenční endoluminální ablace
- bércové vředy
- plicní embólie