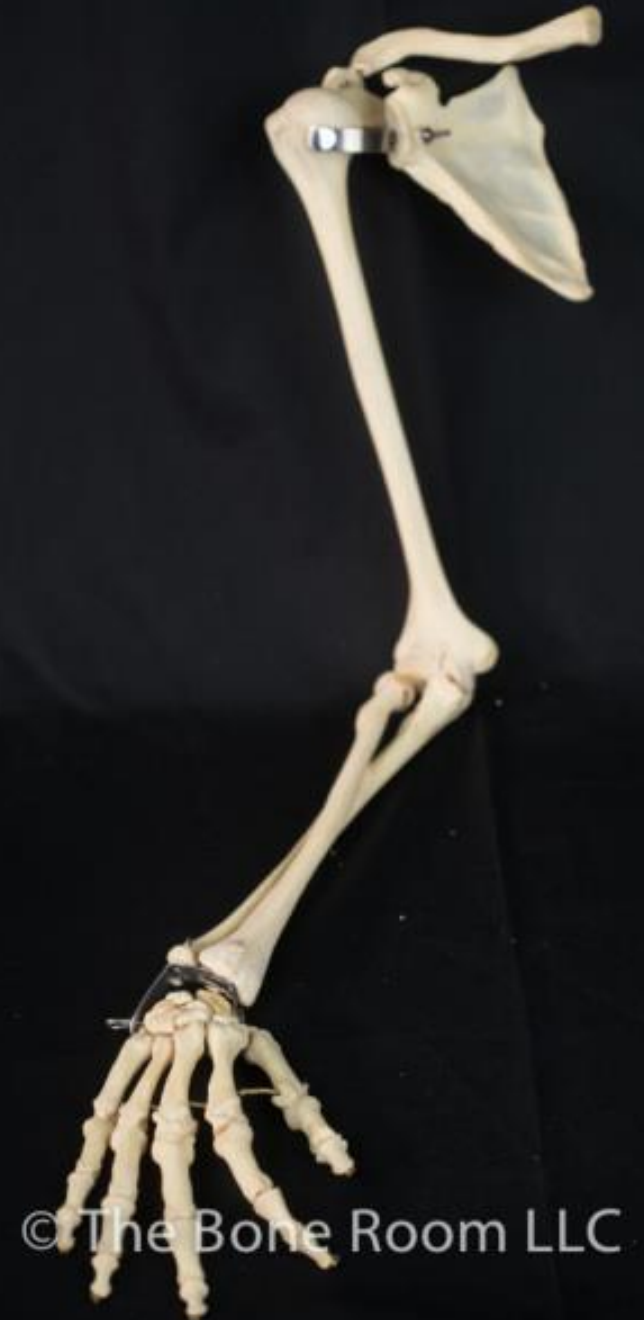


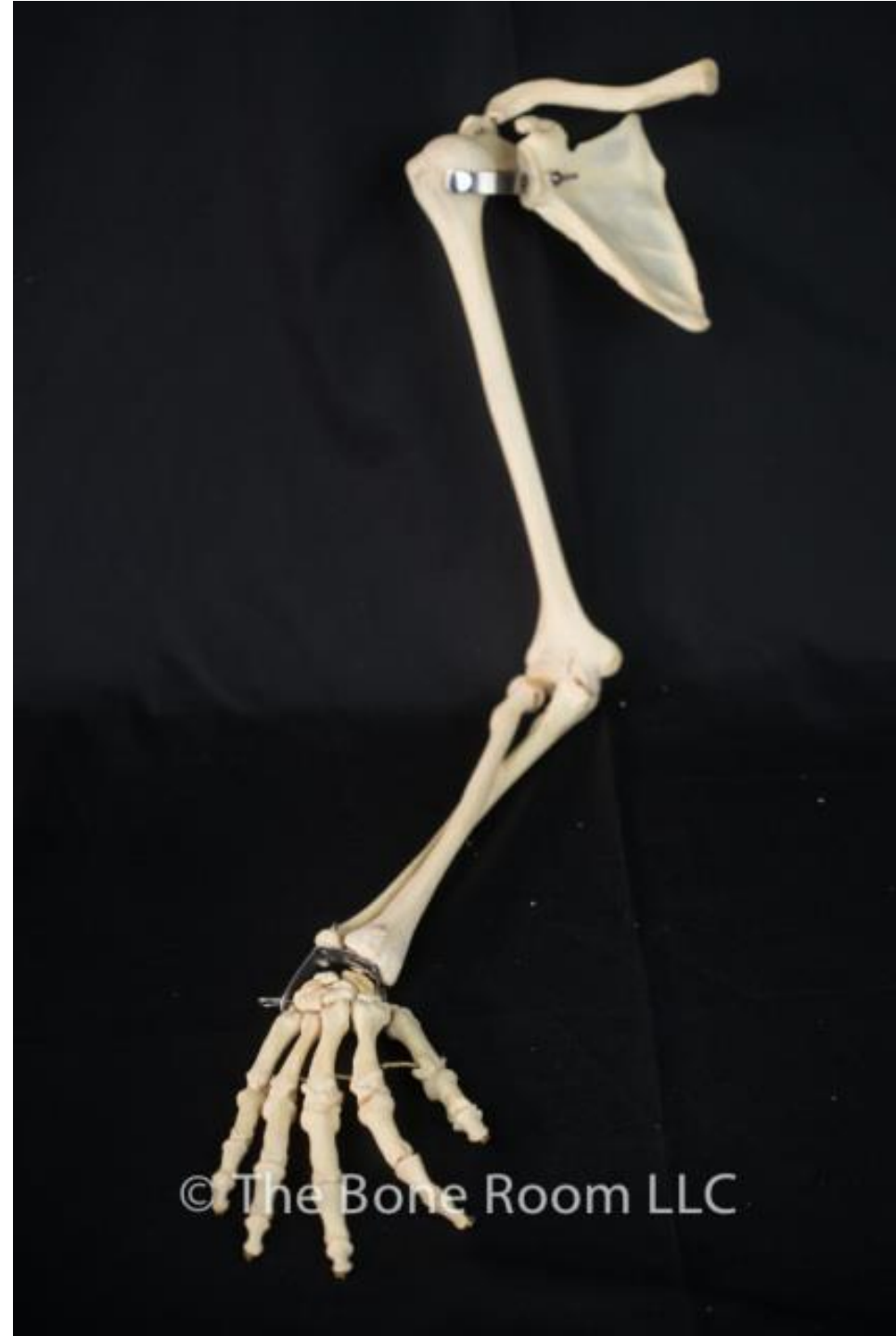
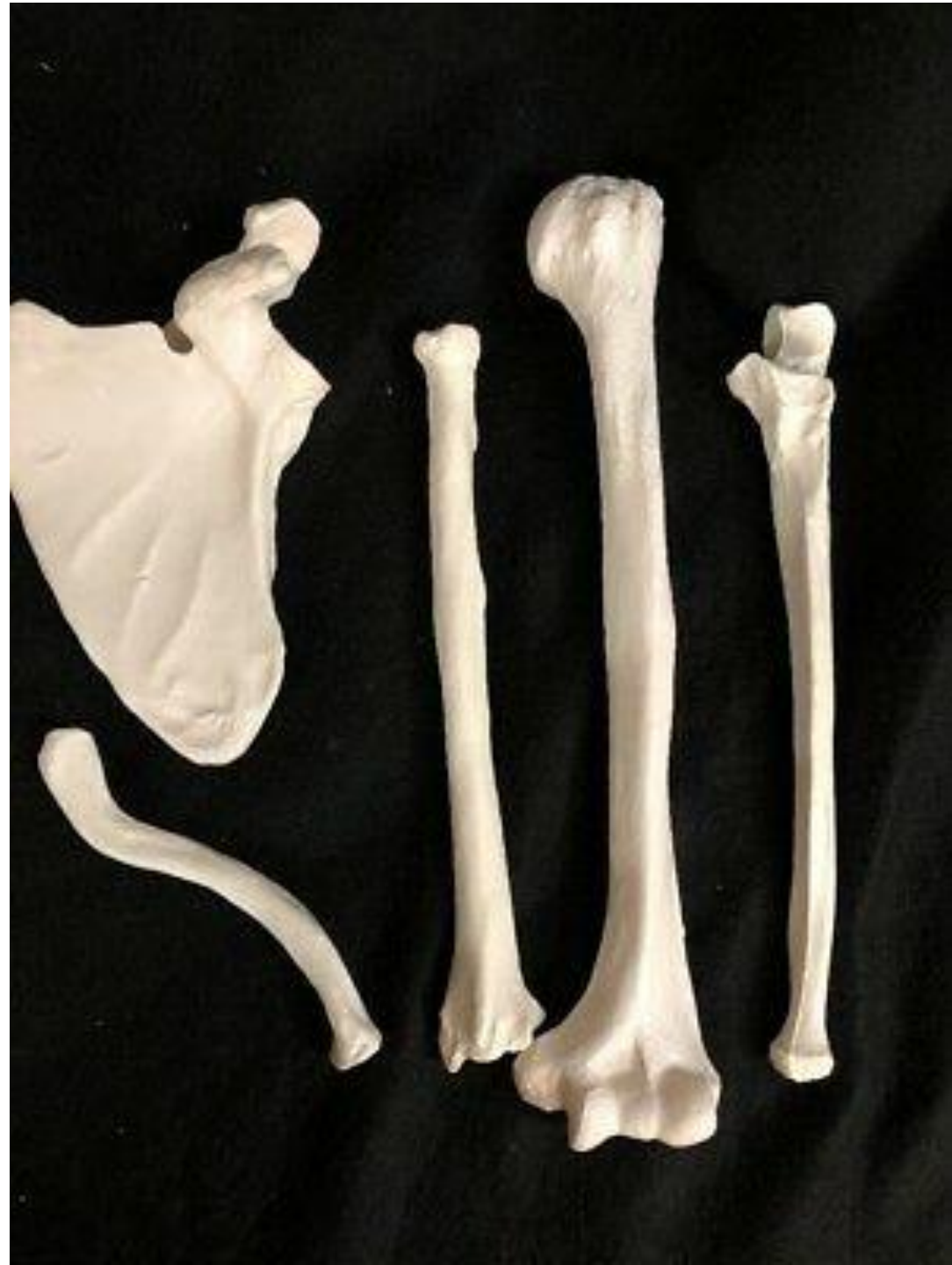**Department of Anatomy**  
Second Faculty of Medicine  
Charles University

# **BONES OF THE UPPER & LOWER LIMBS**

MUDr. Azzat Al-Redouan





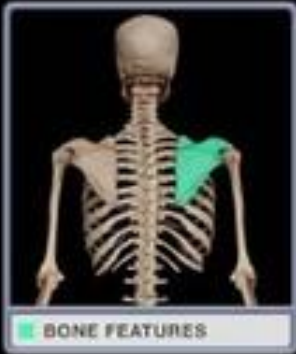© The Bone Room LLC



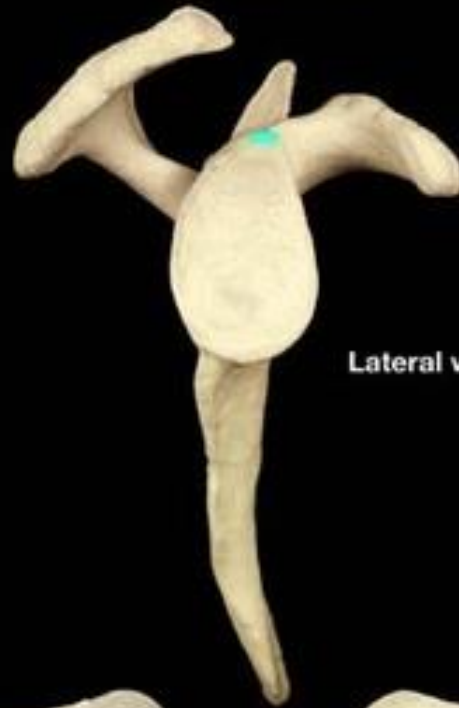(a)



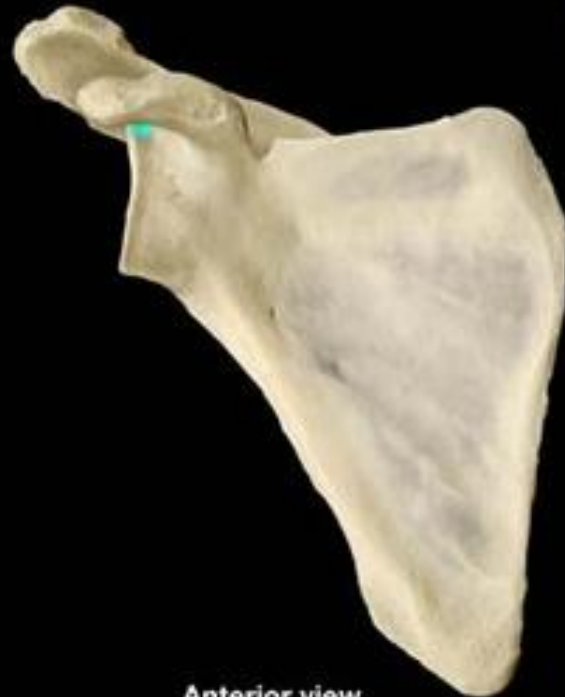(a)



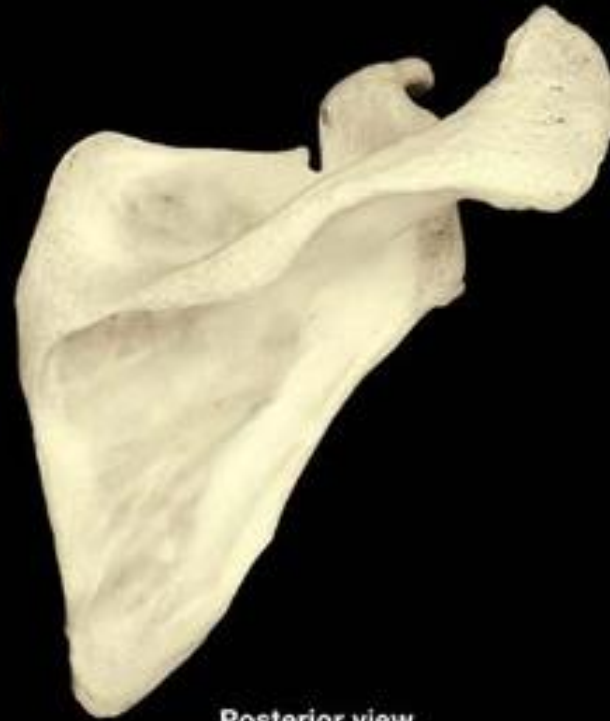# Scapula



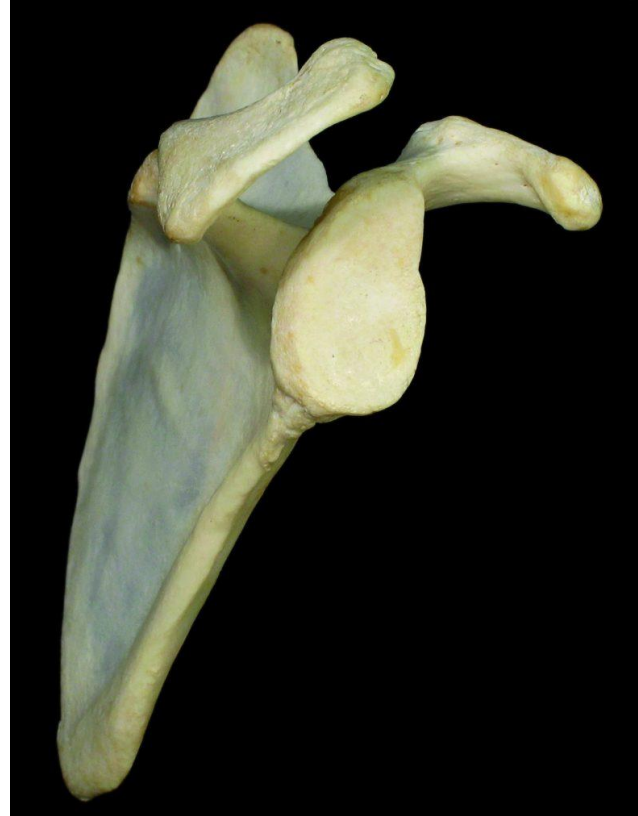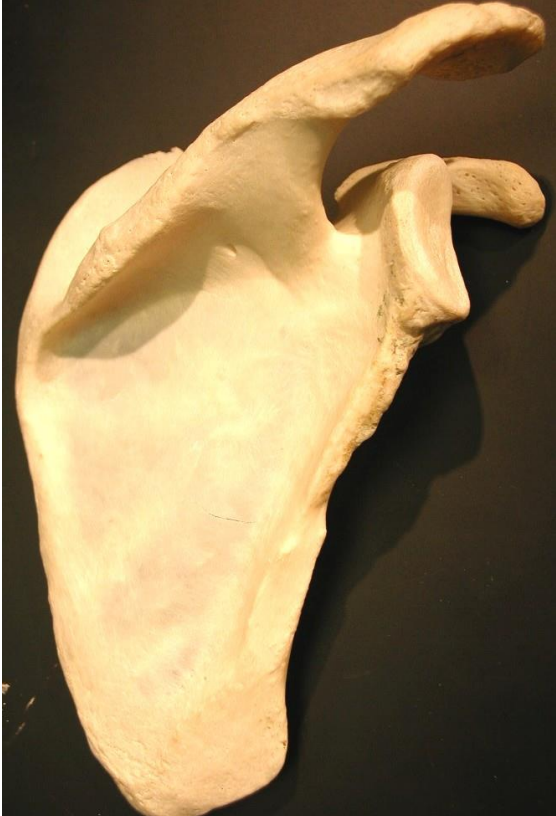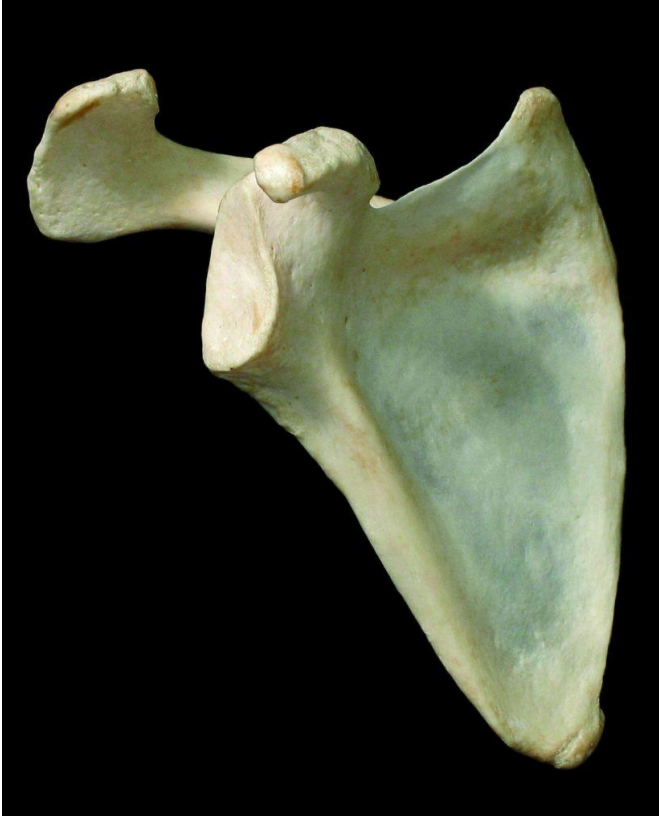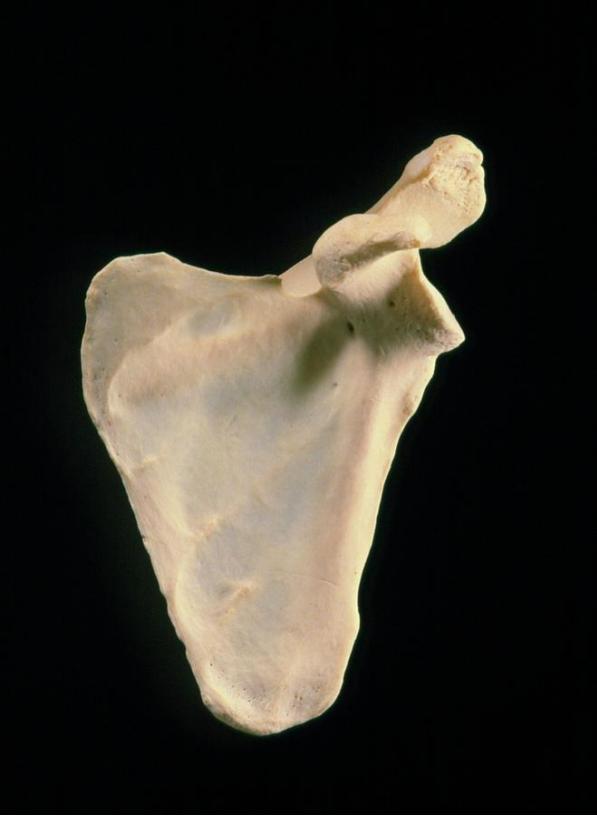Lateral view

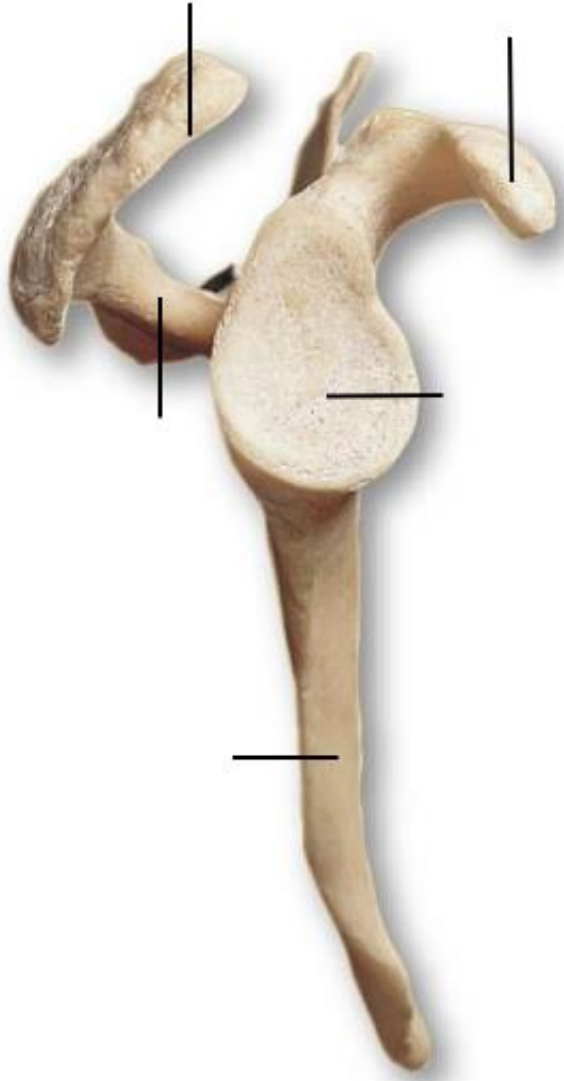


Anterior view

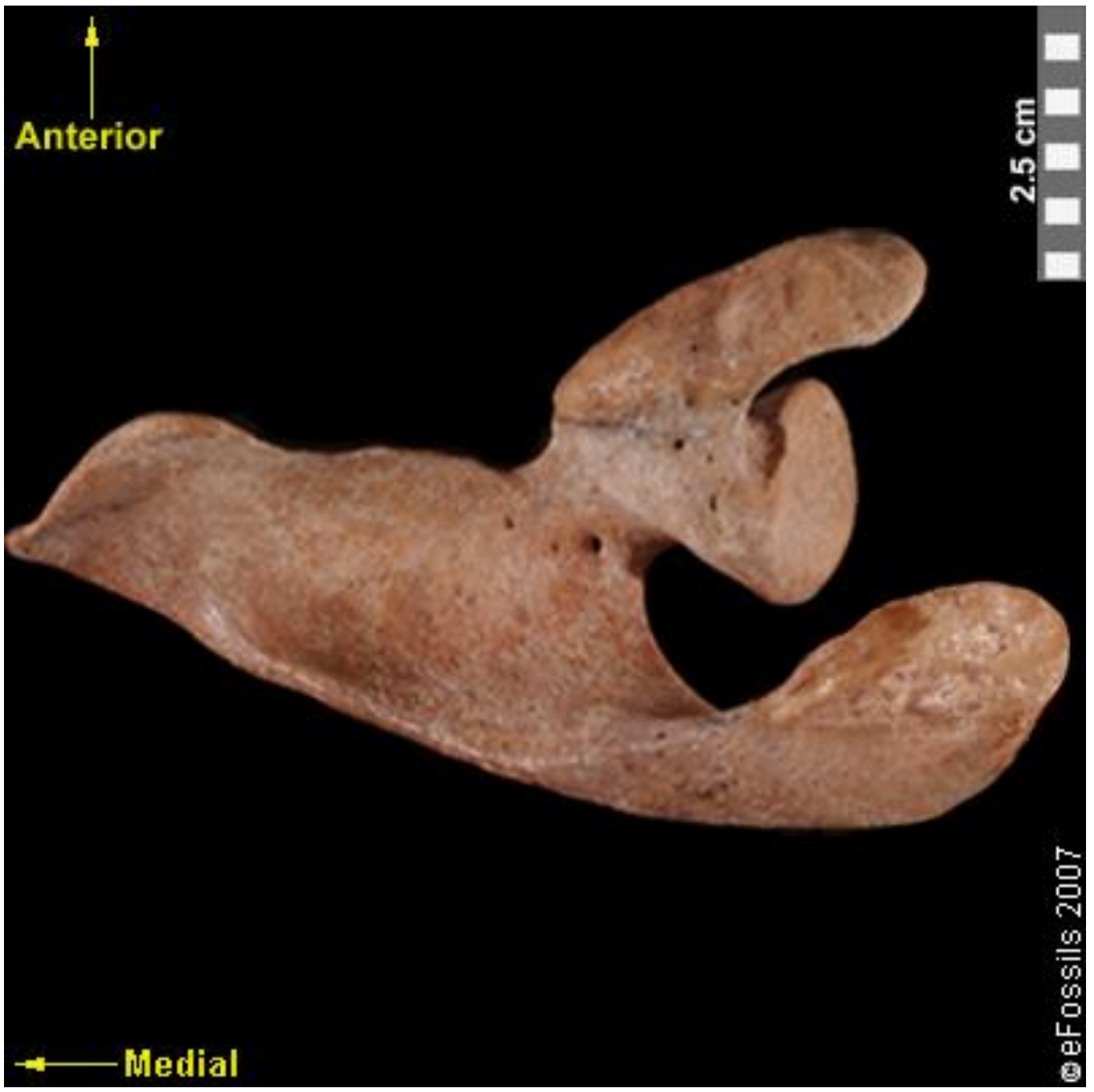

Posterior view



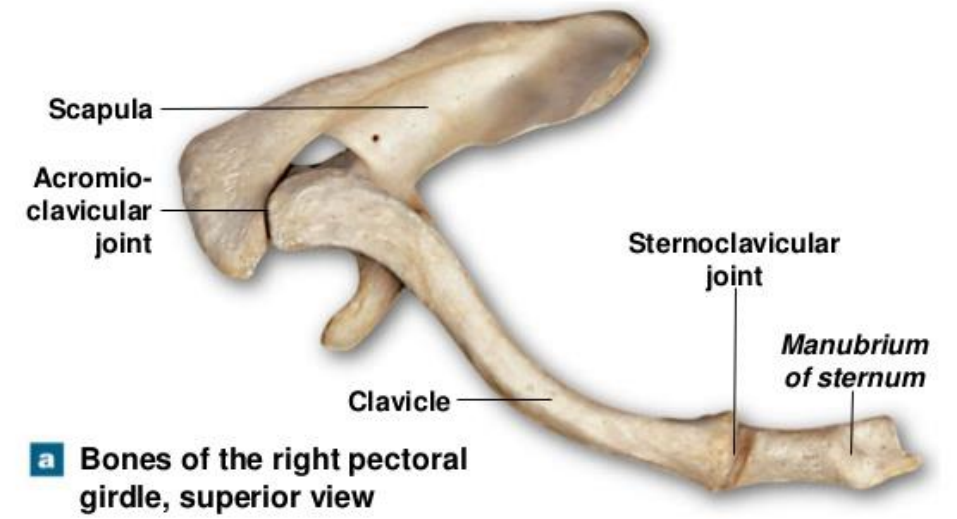


**b Lateral view**

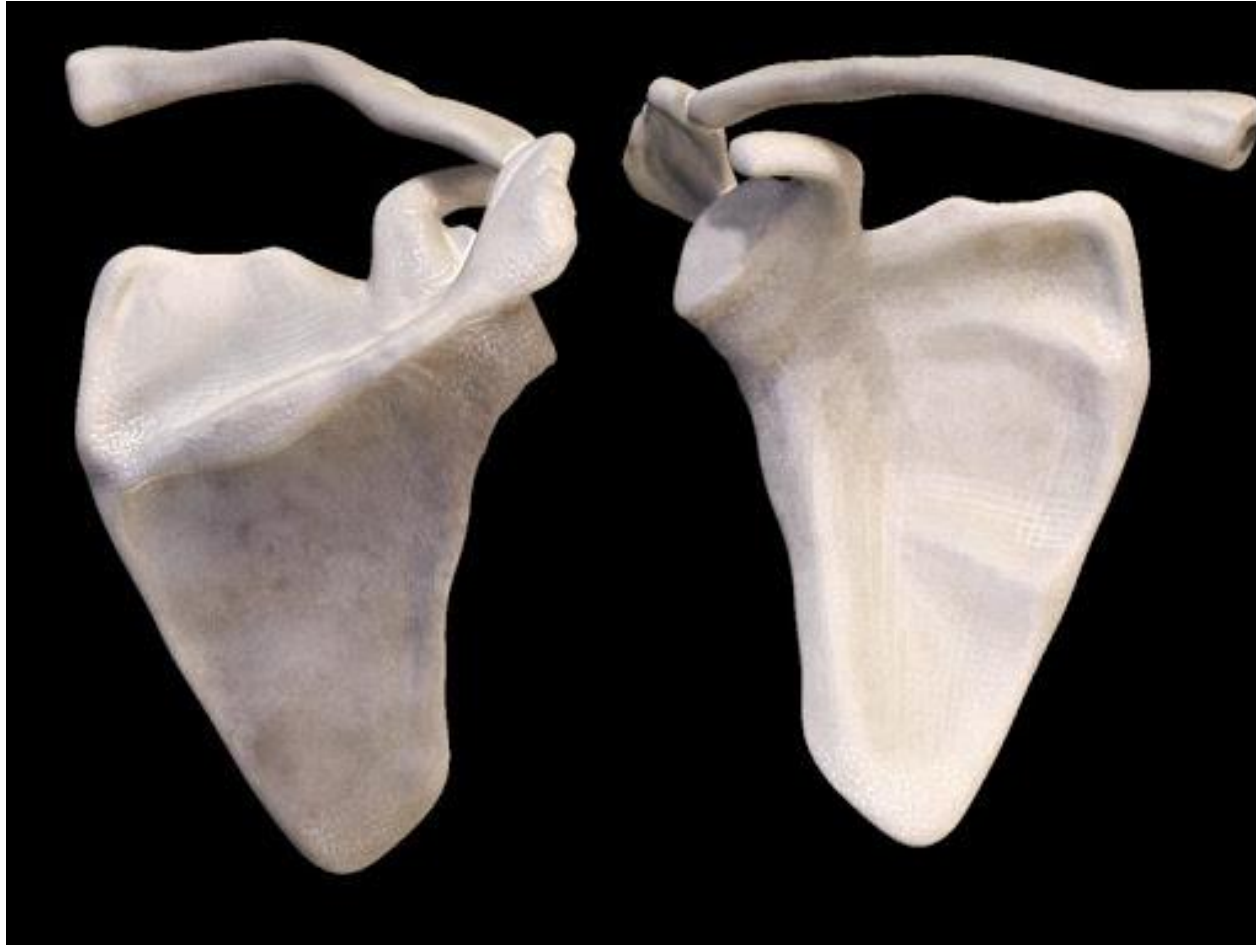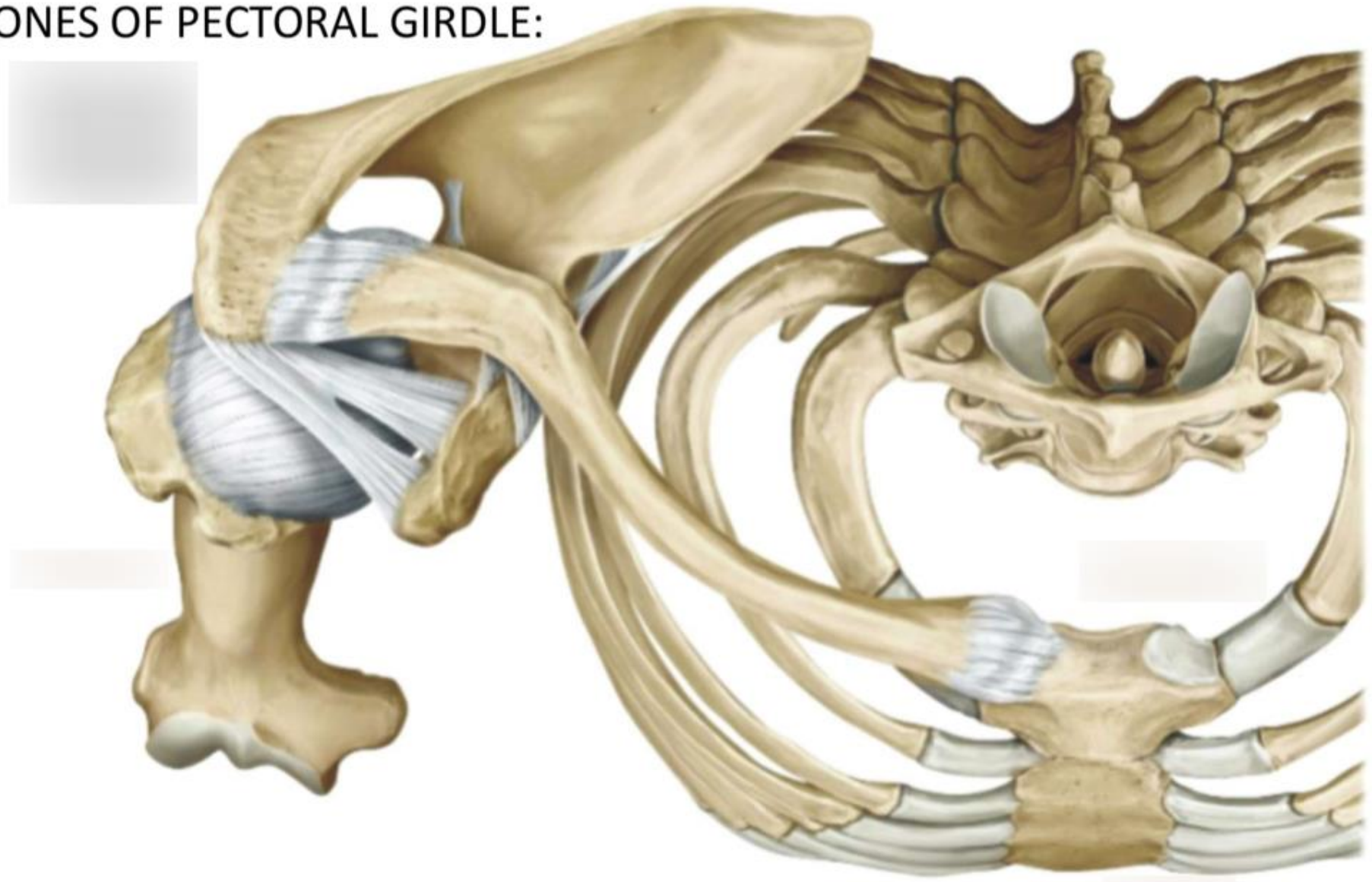




Figure 7.4a Mobility of the Pectoral Girdle

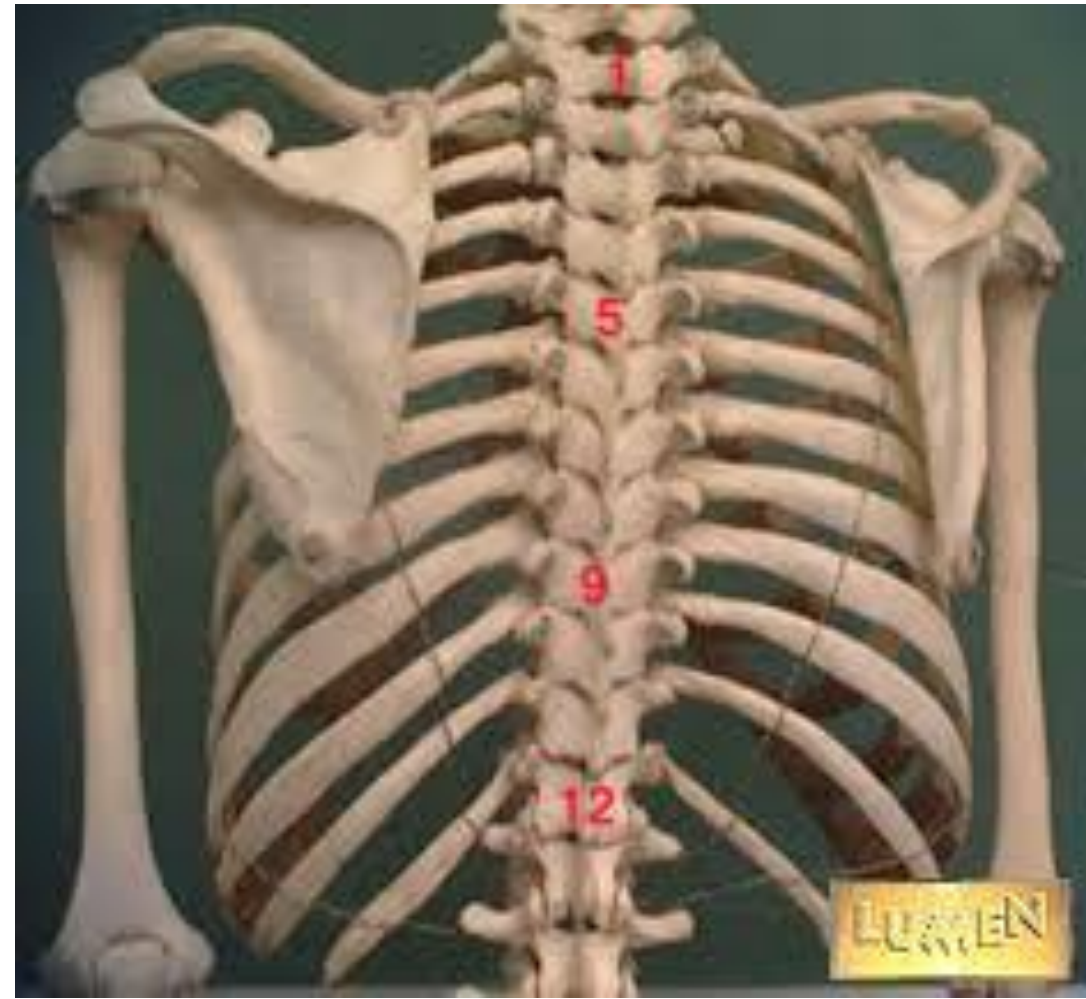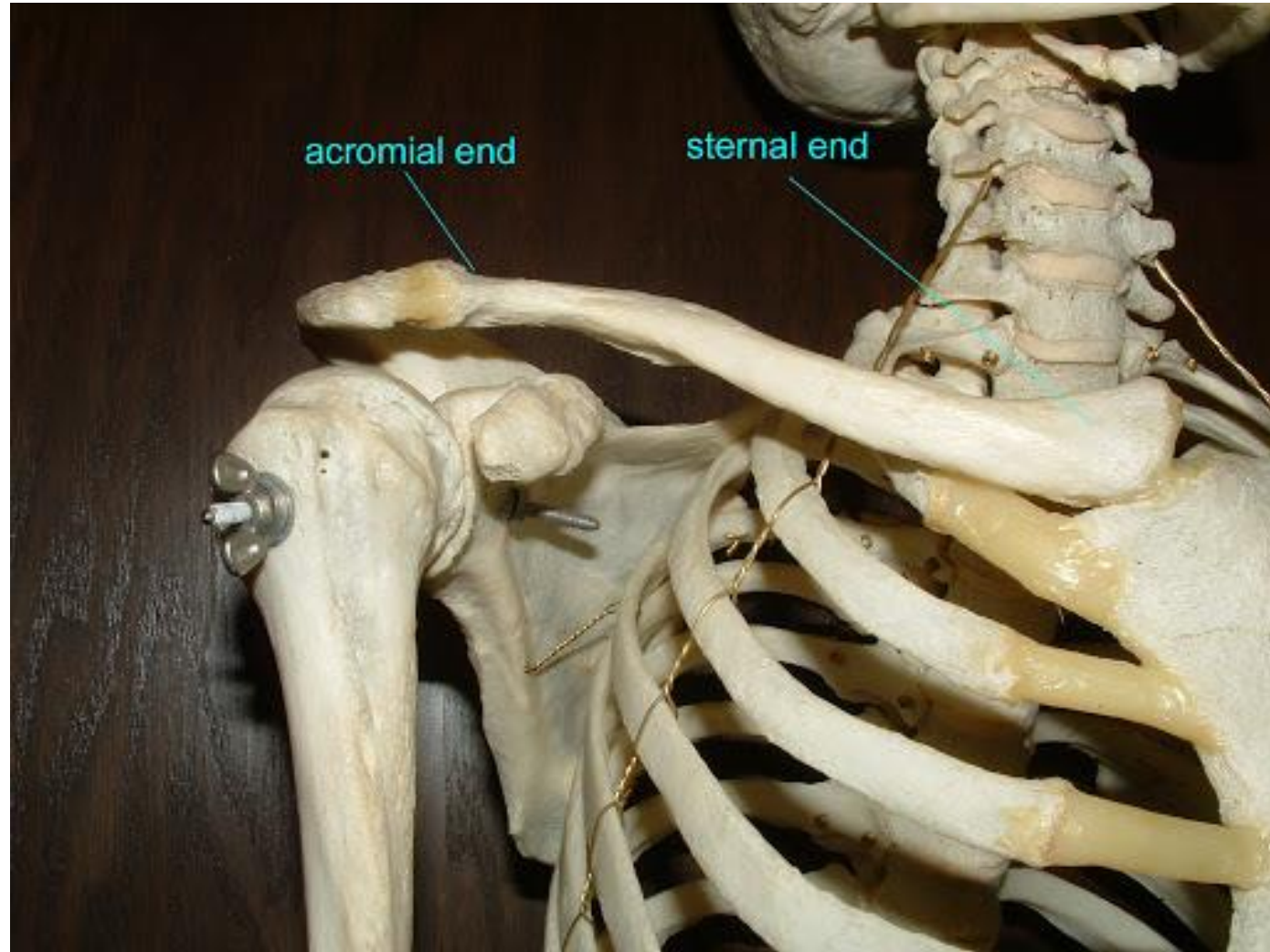


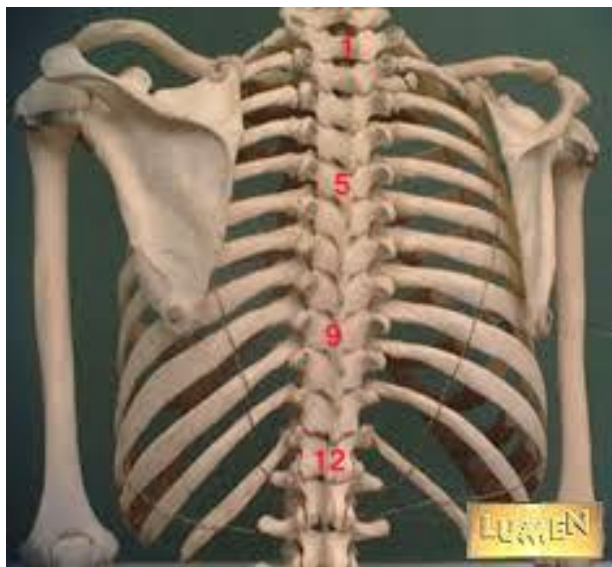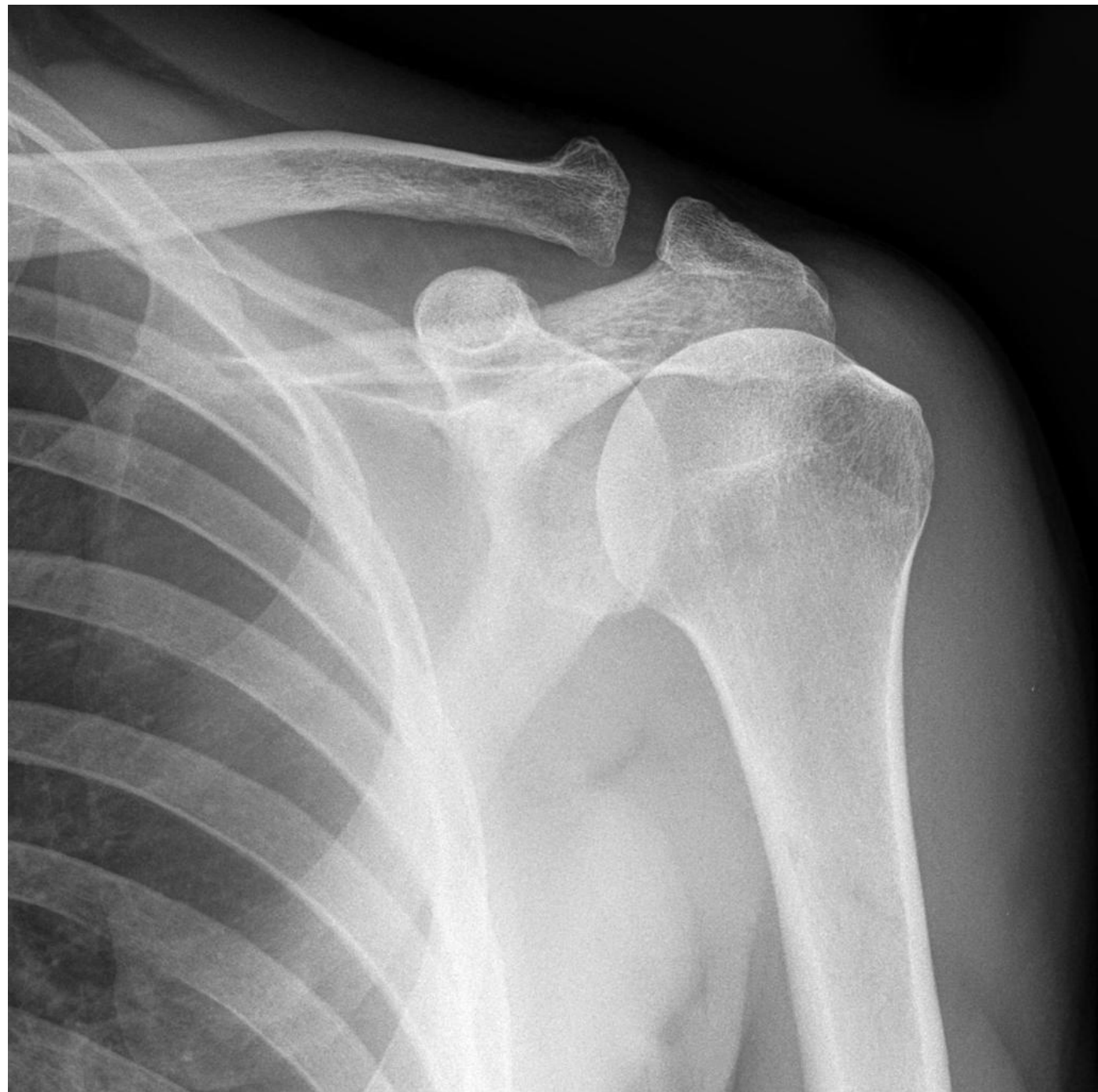
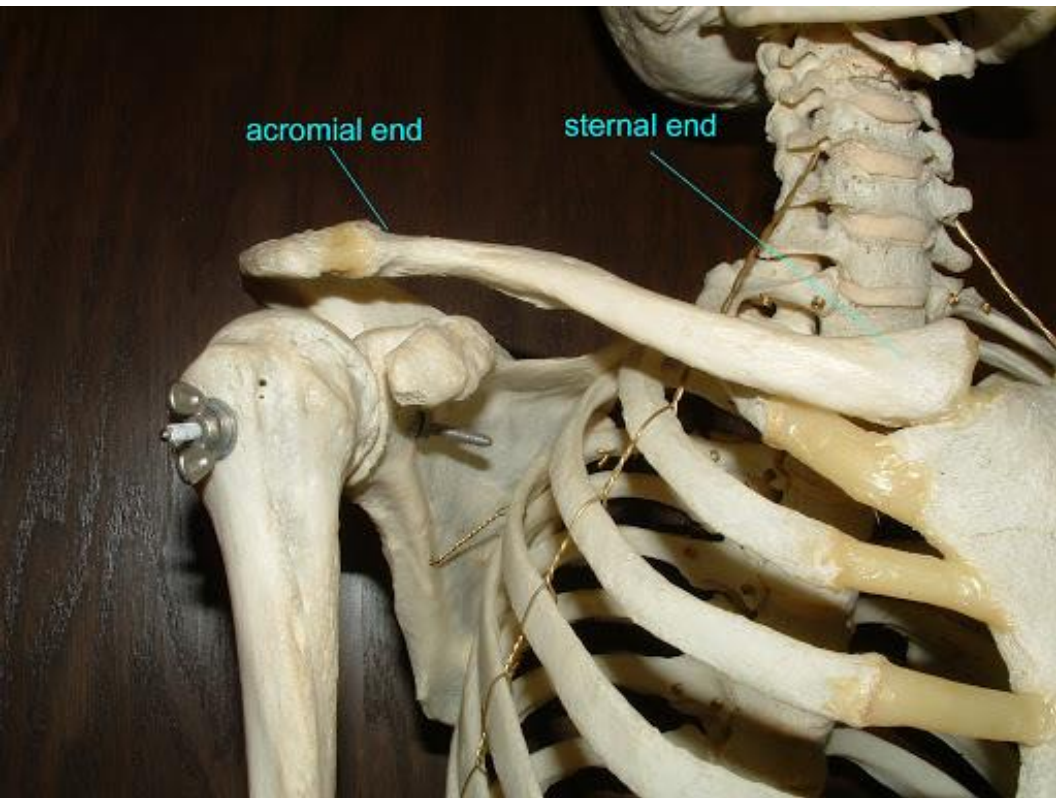
BONES OF PECTORAL GIRDLE:

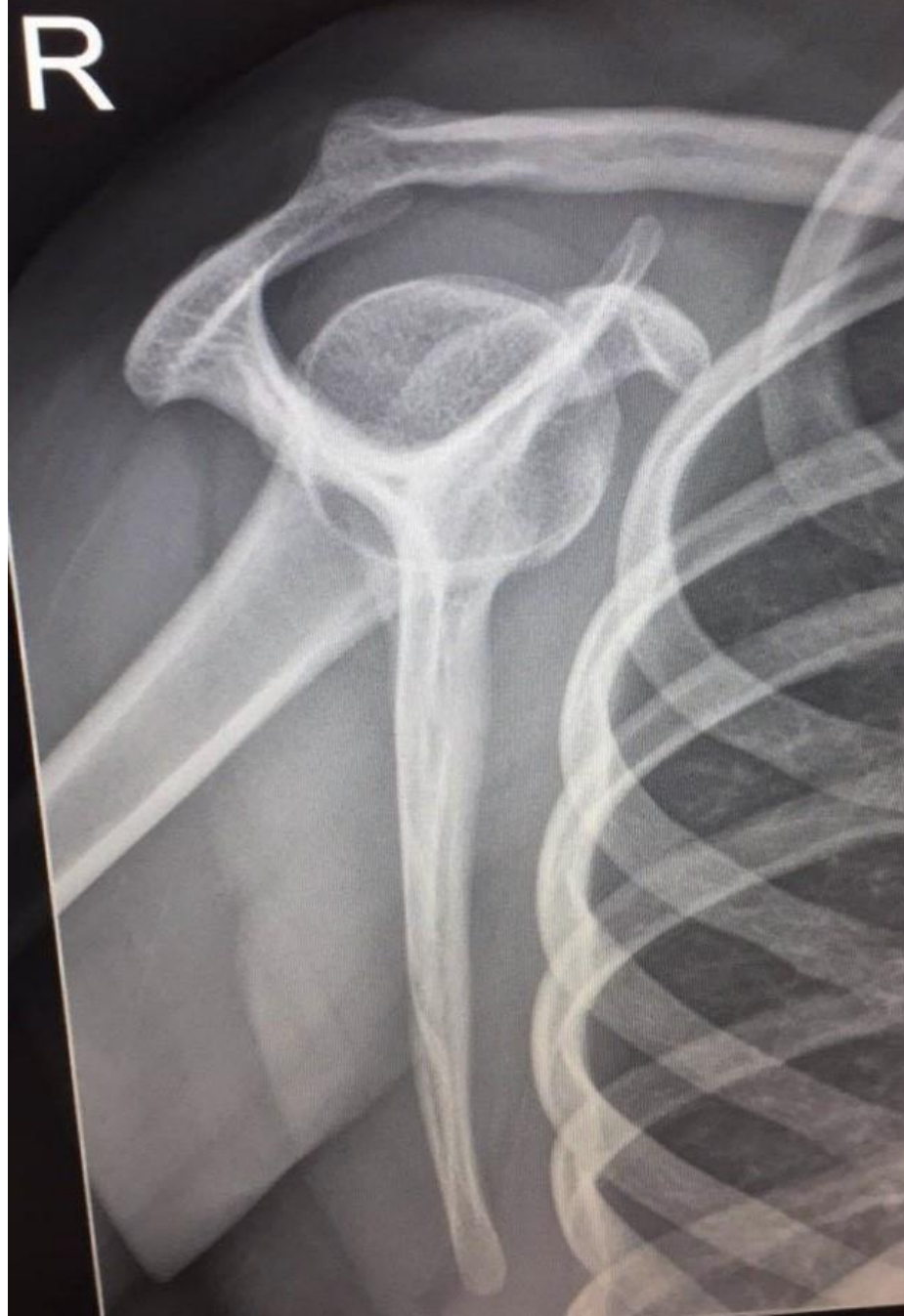
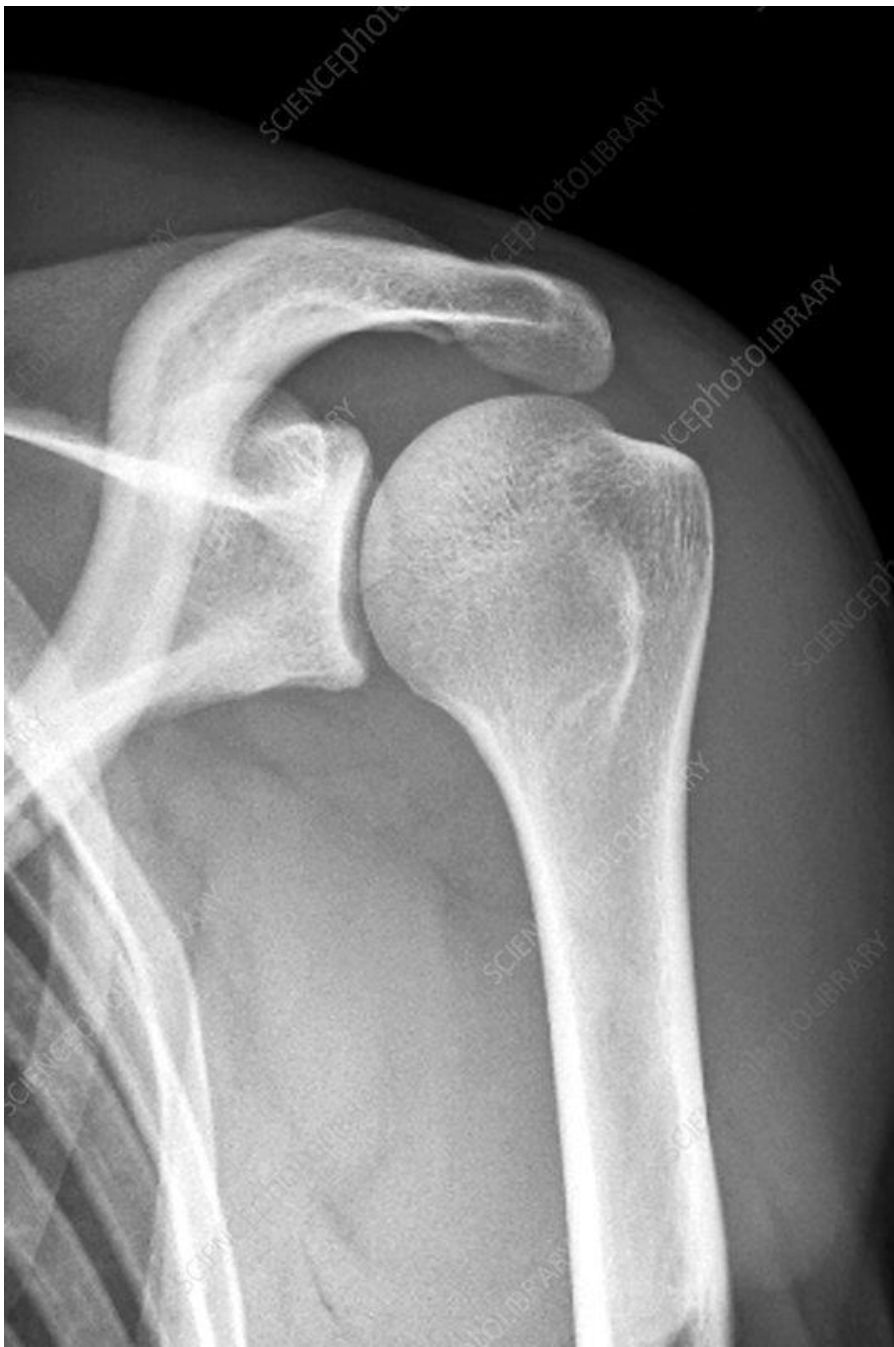
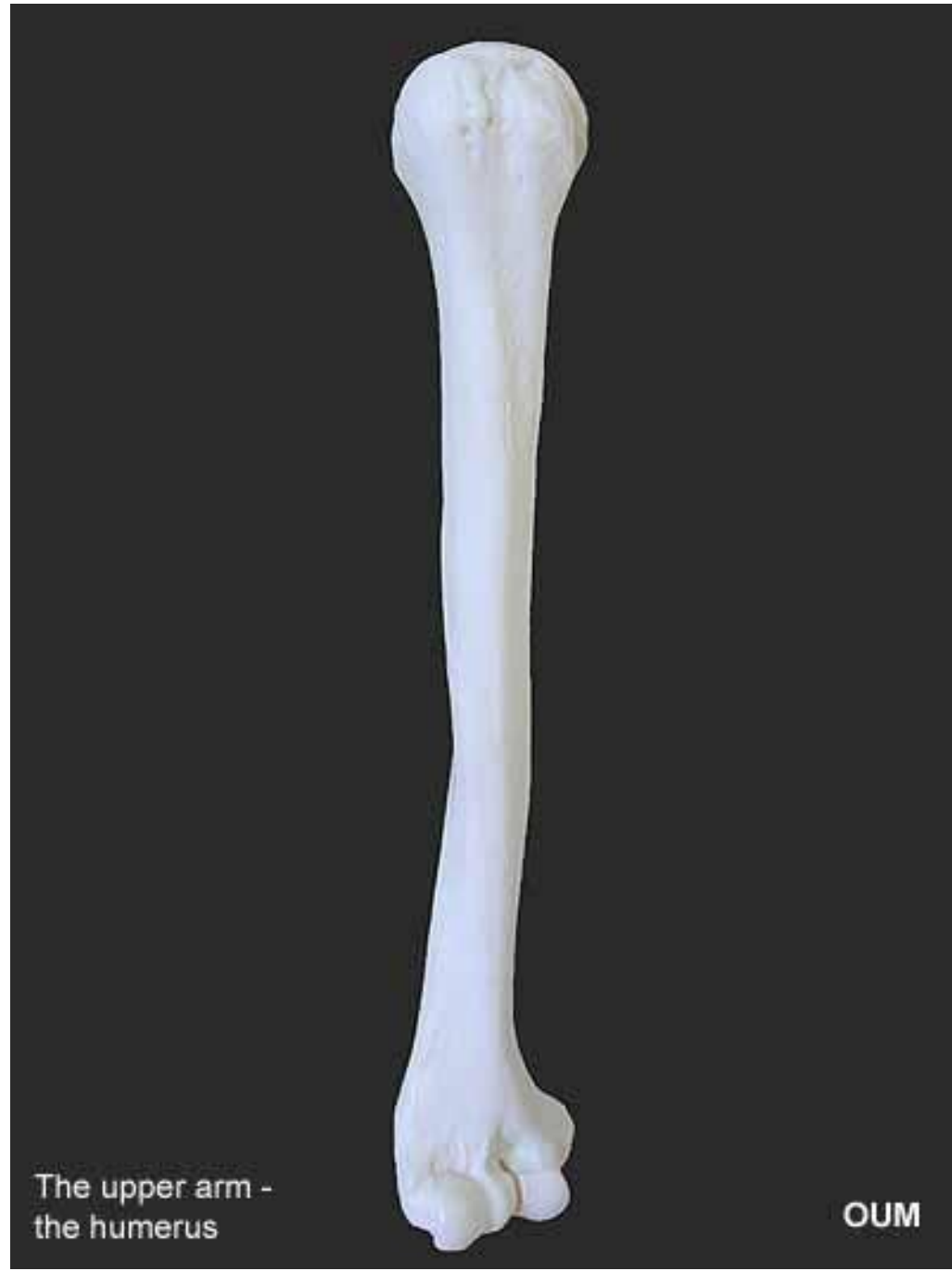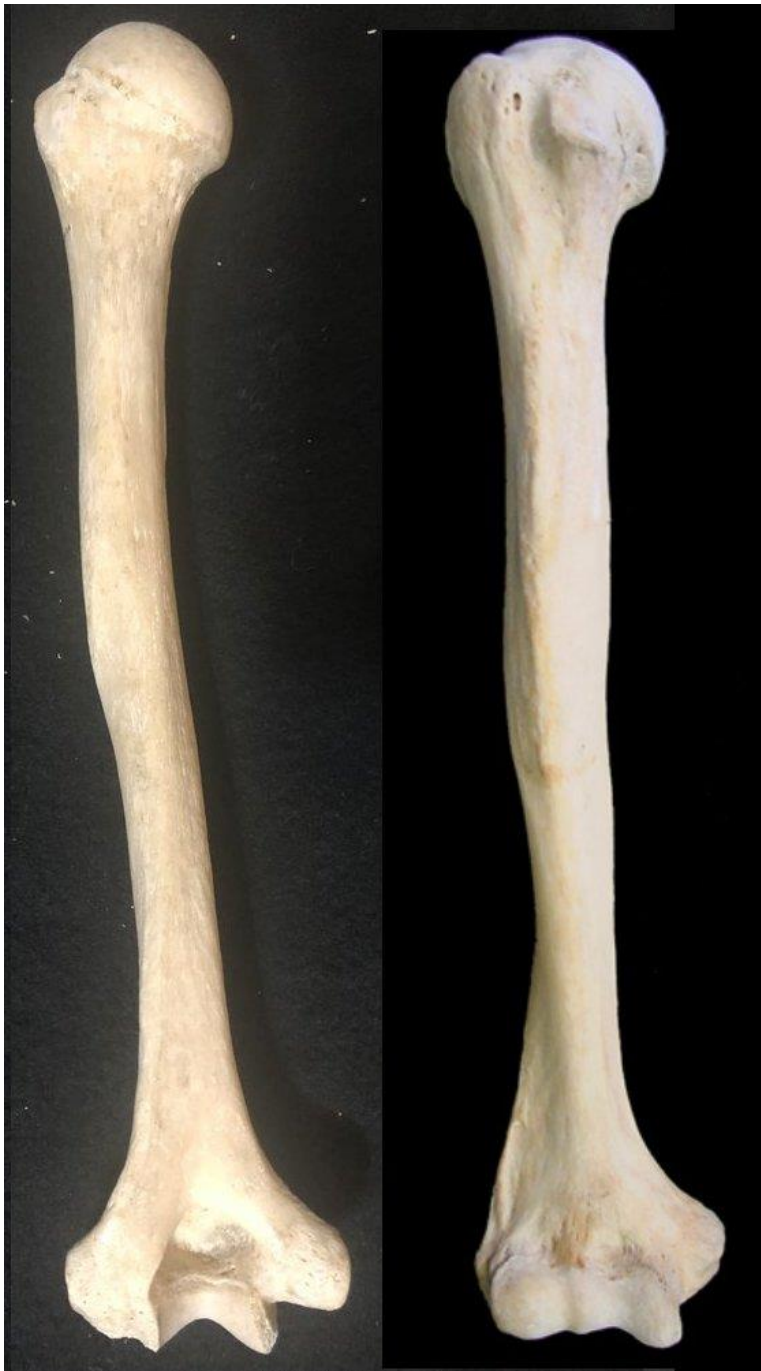Superior View

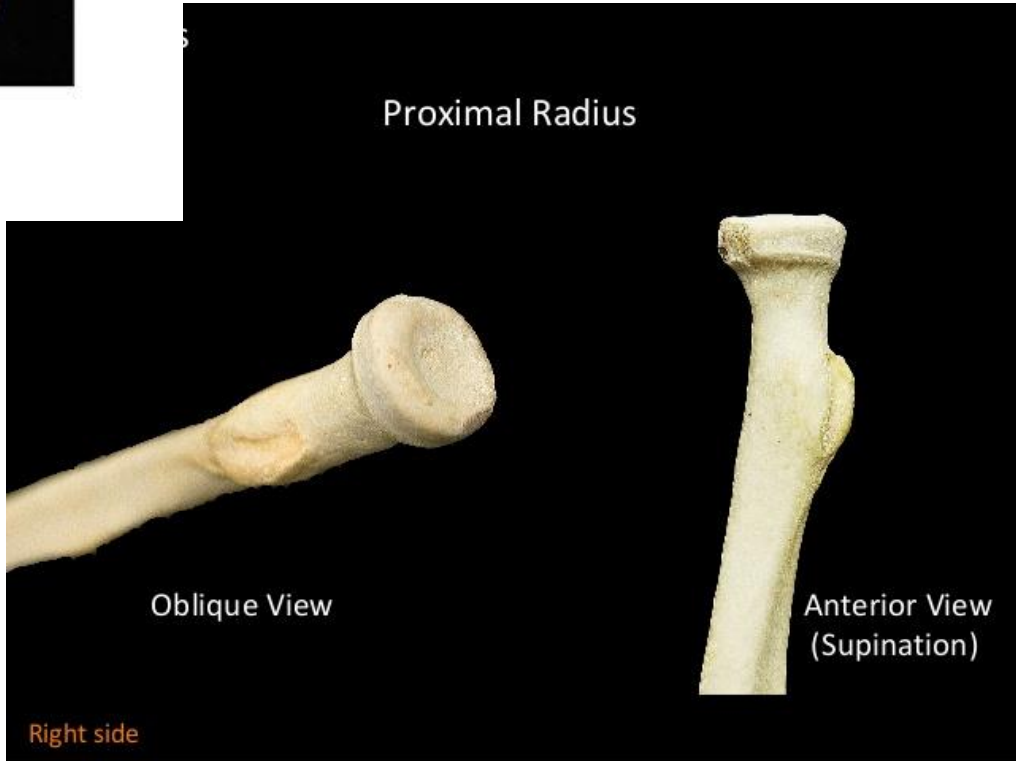
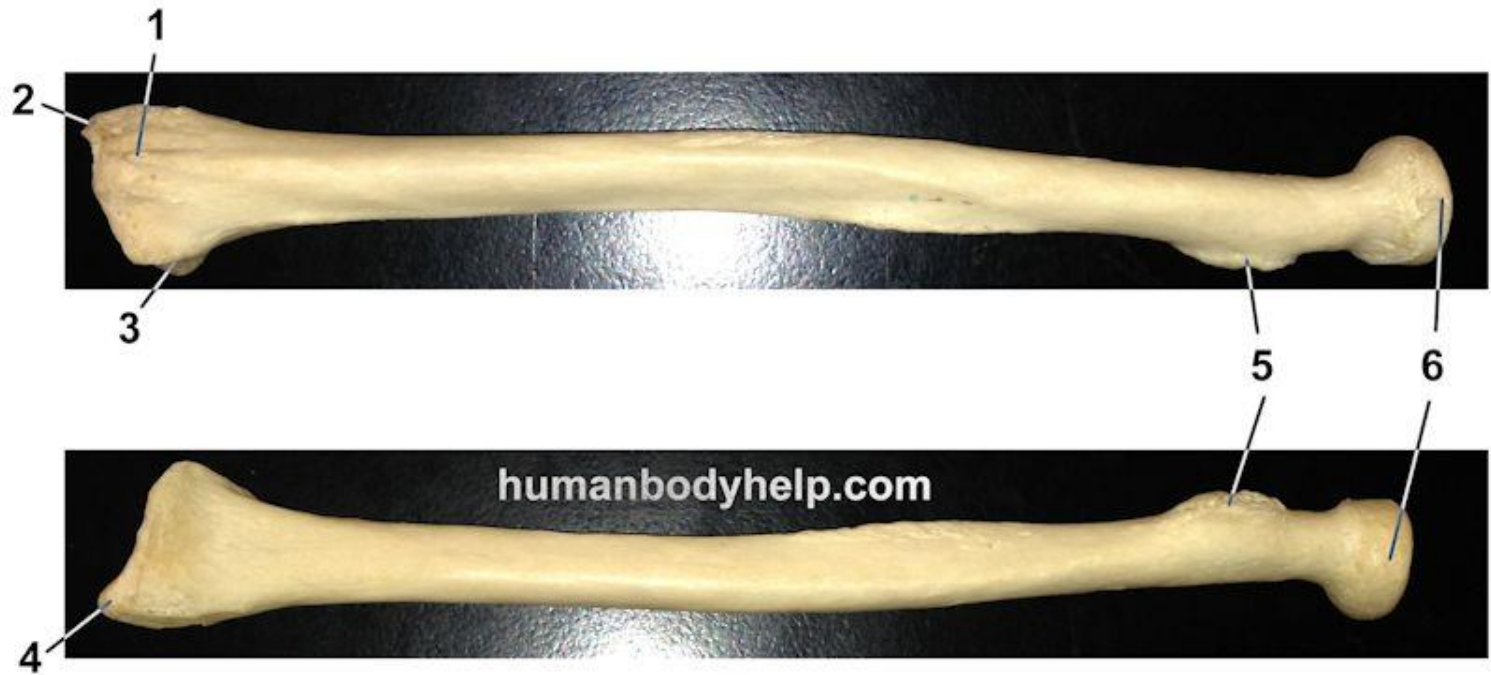



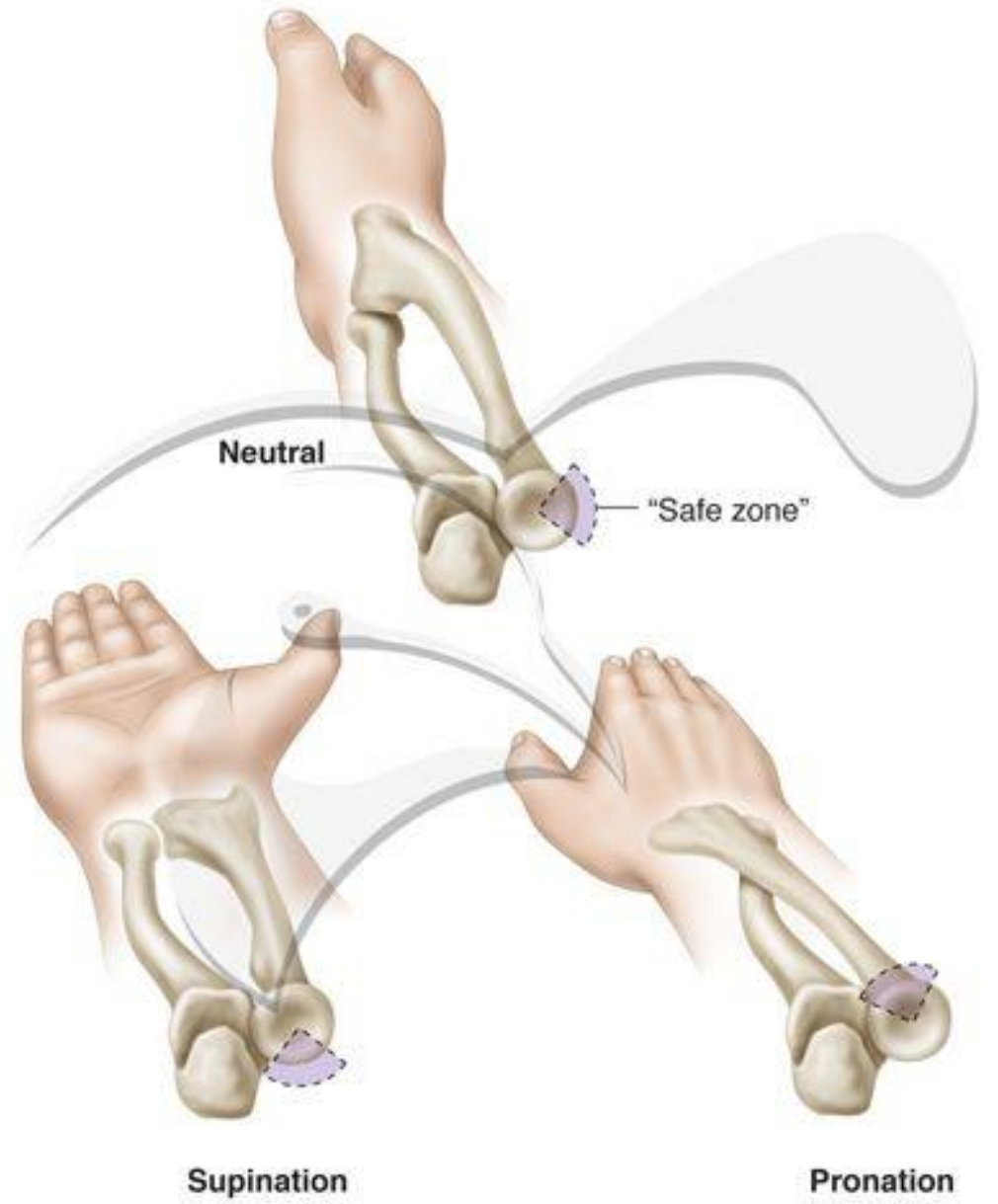

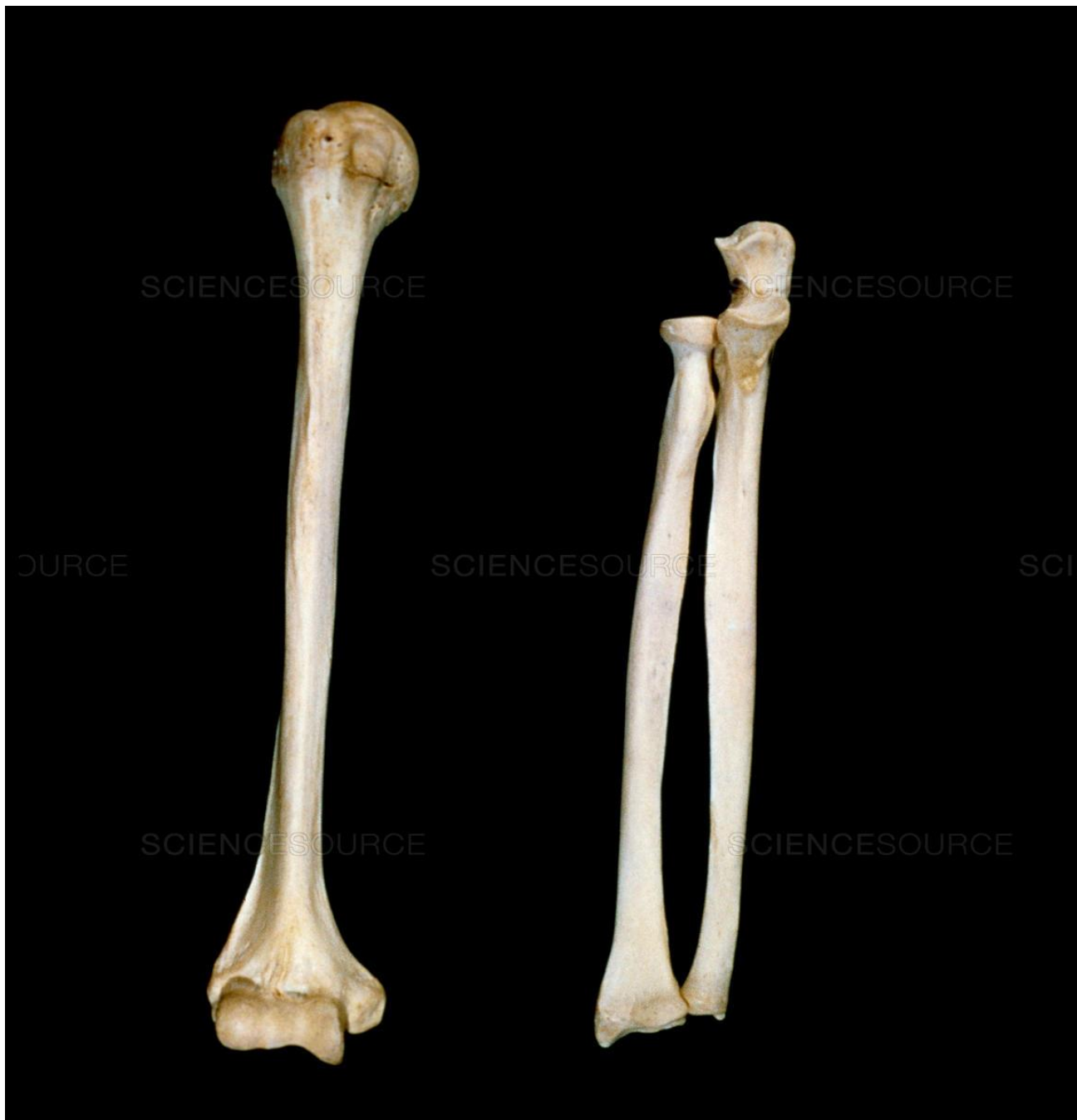


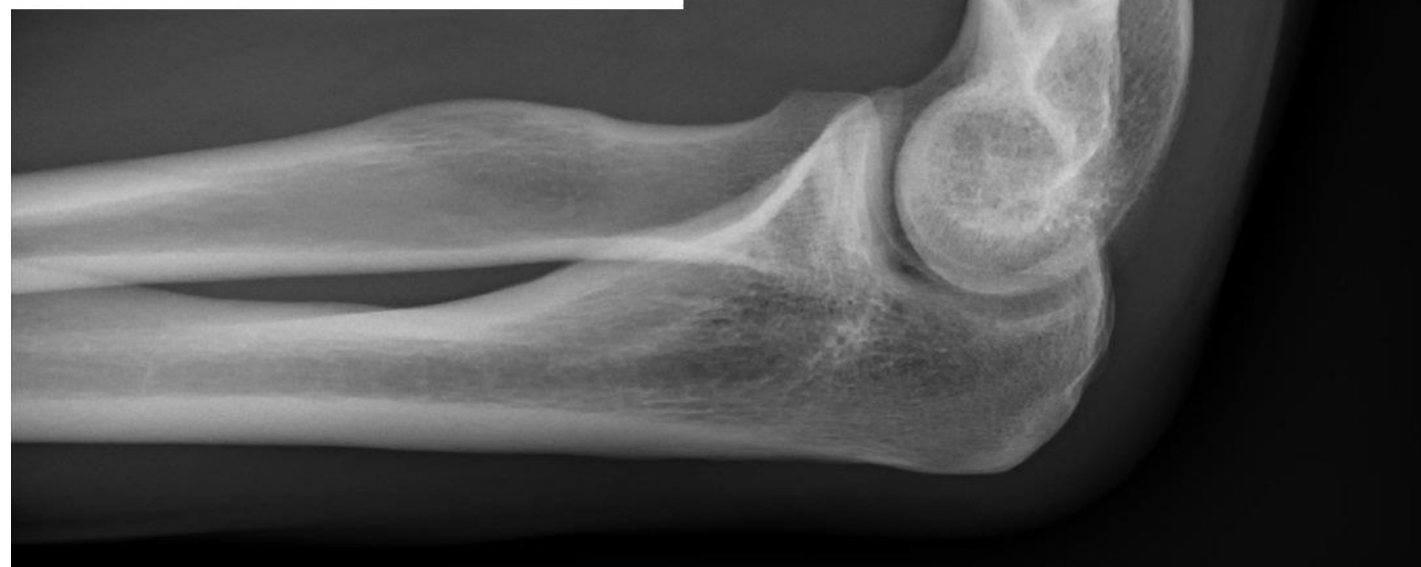
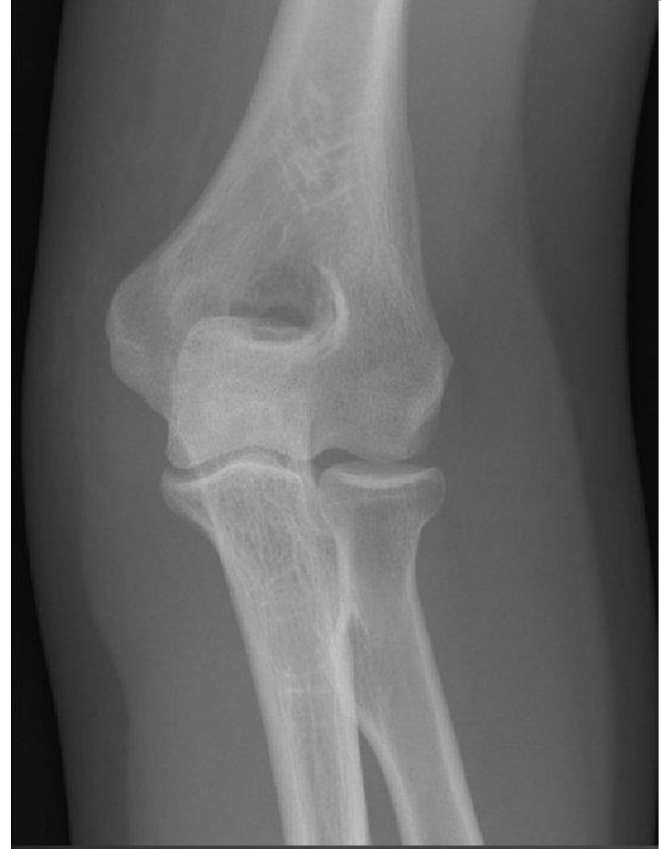
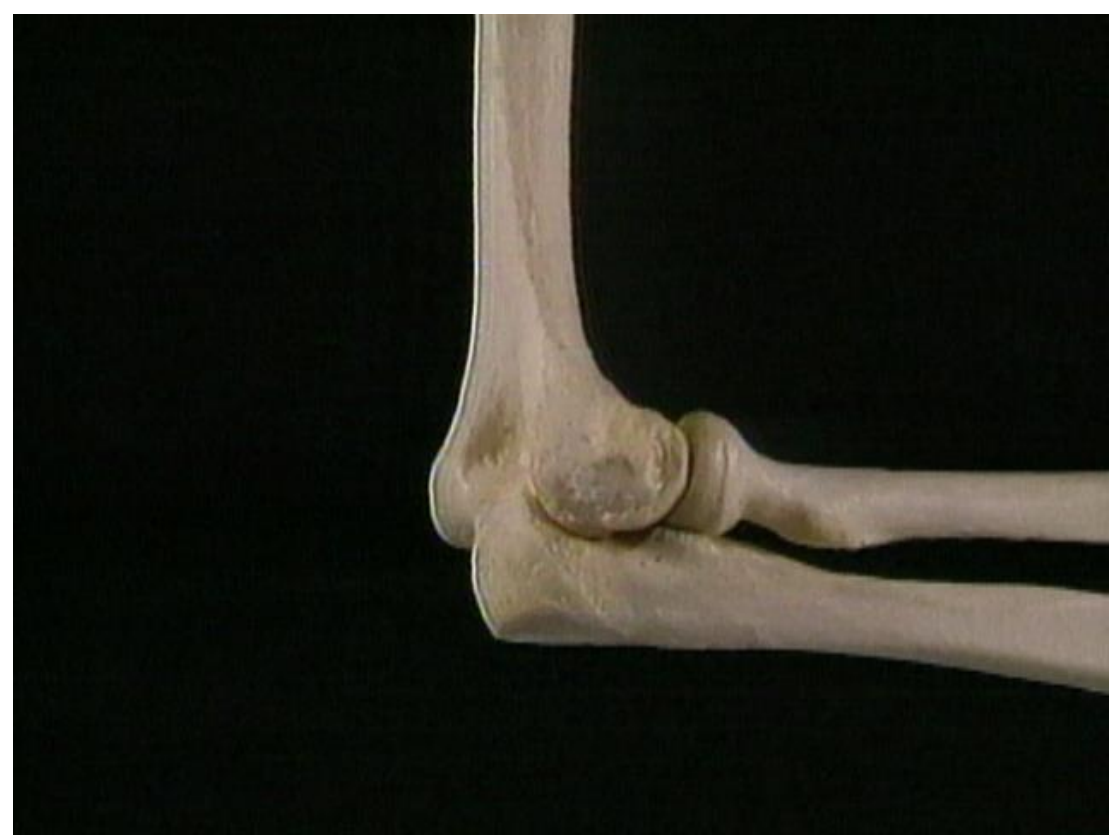



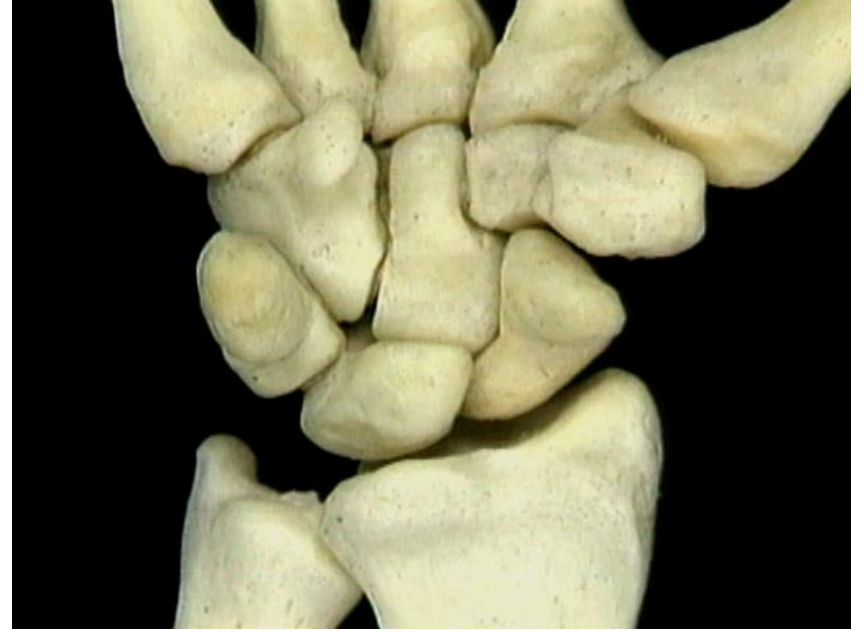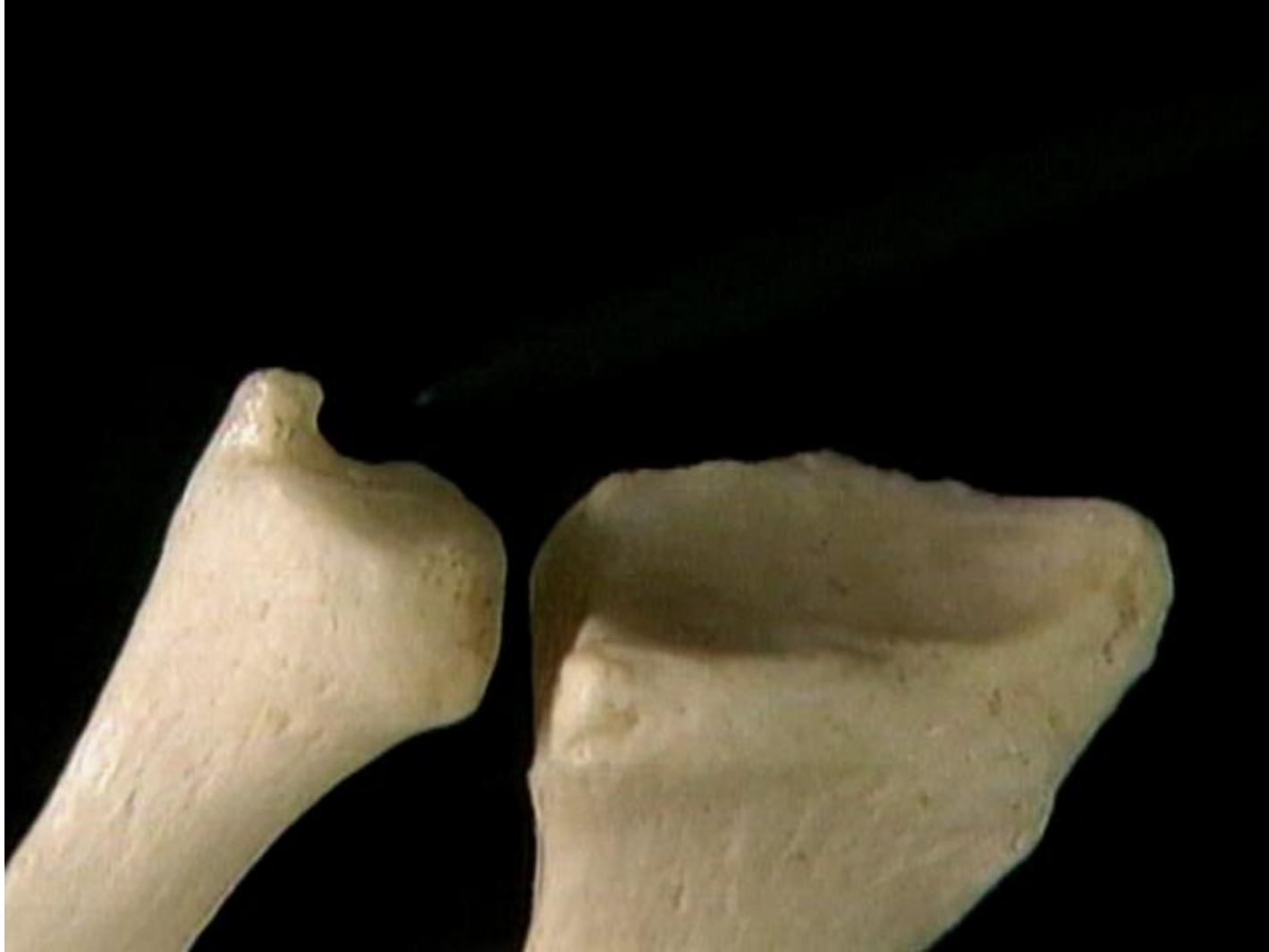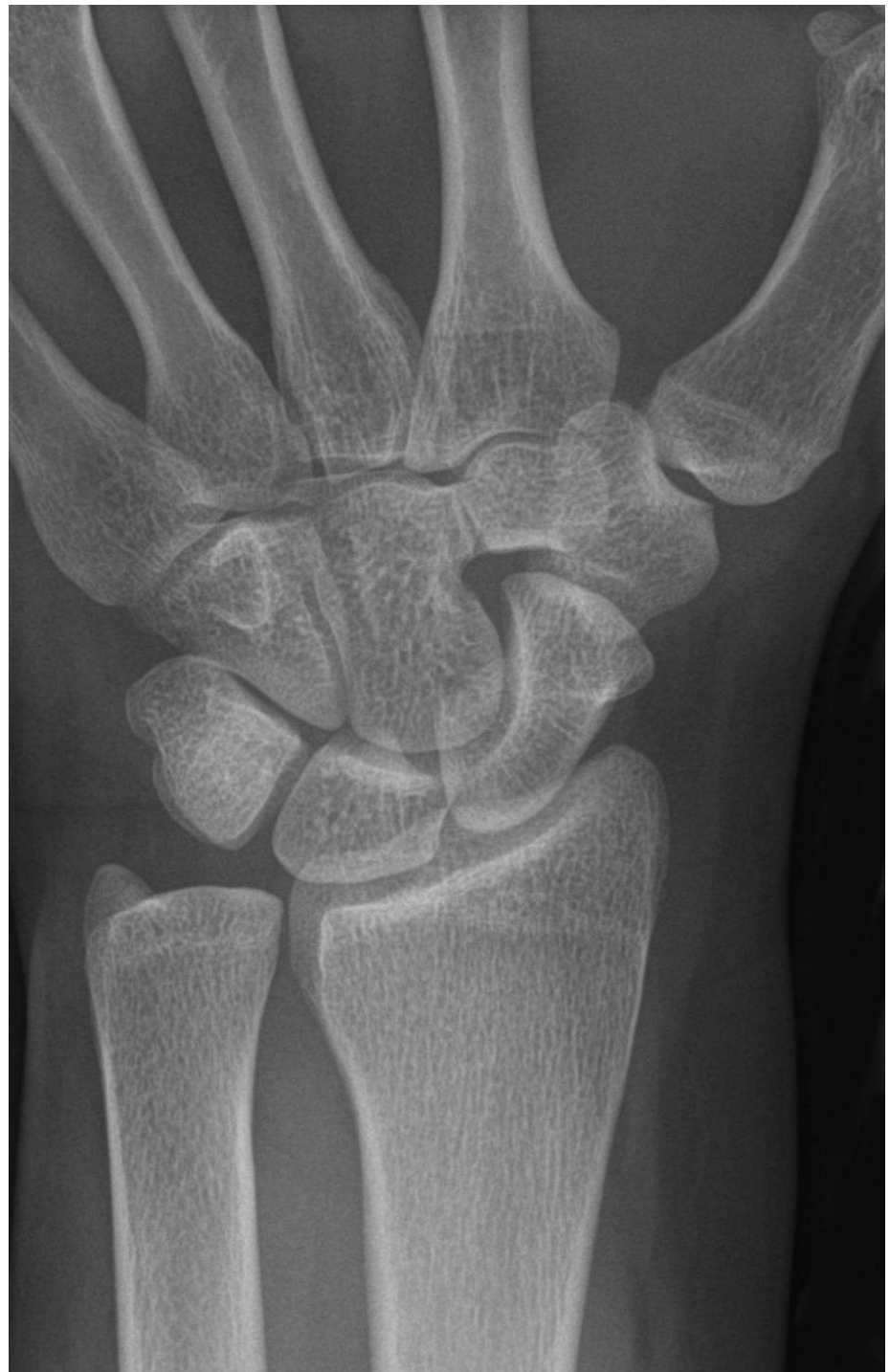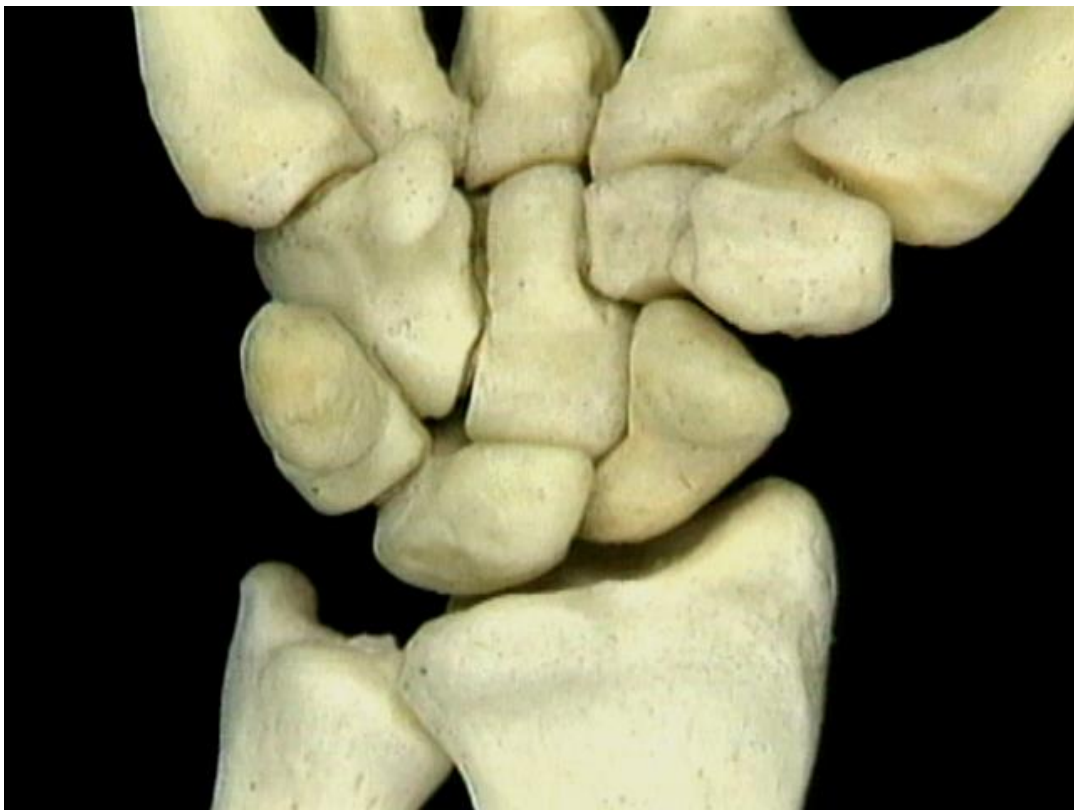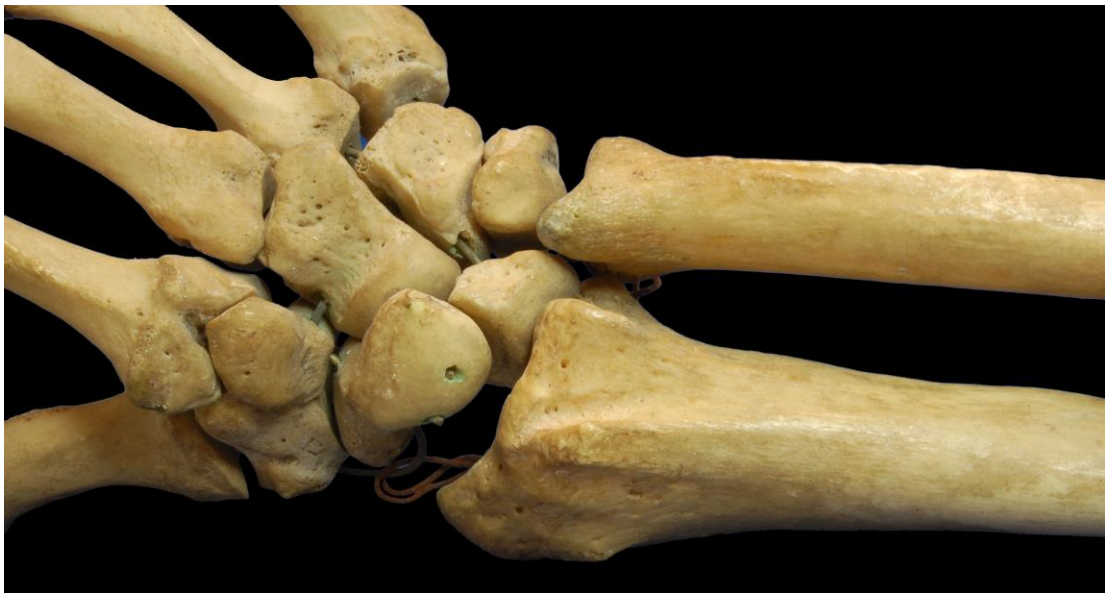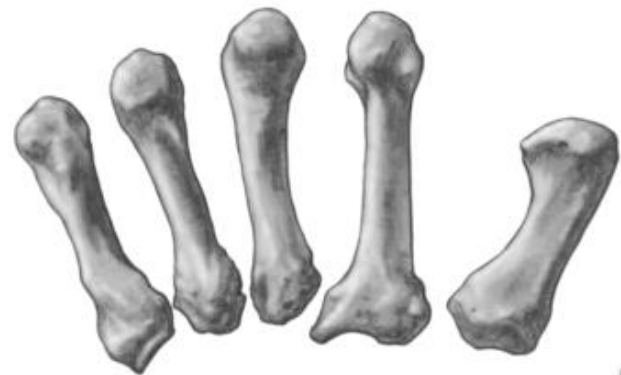












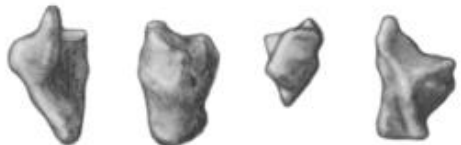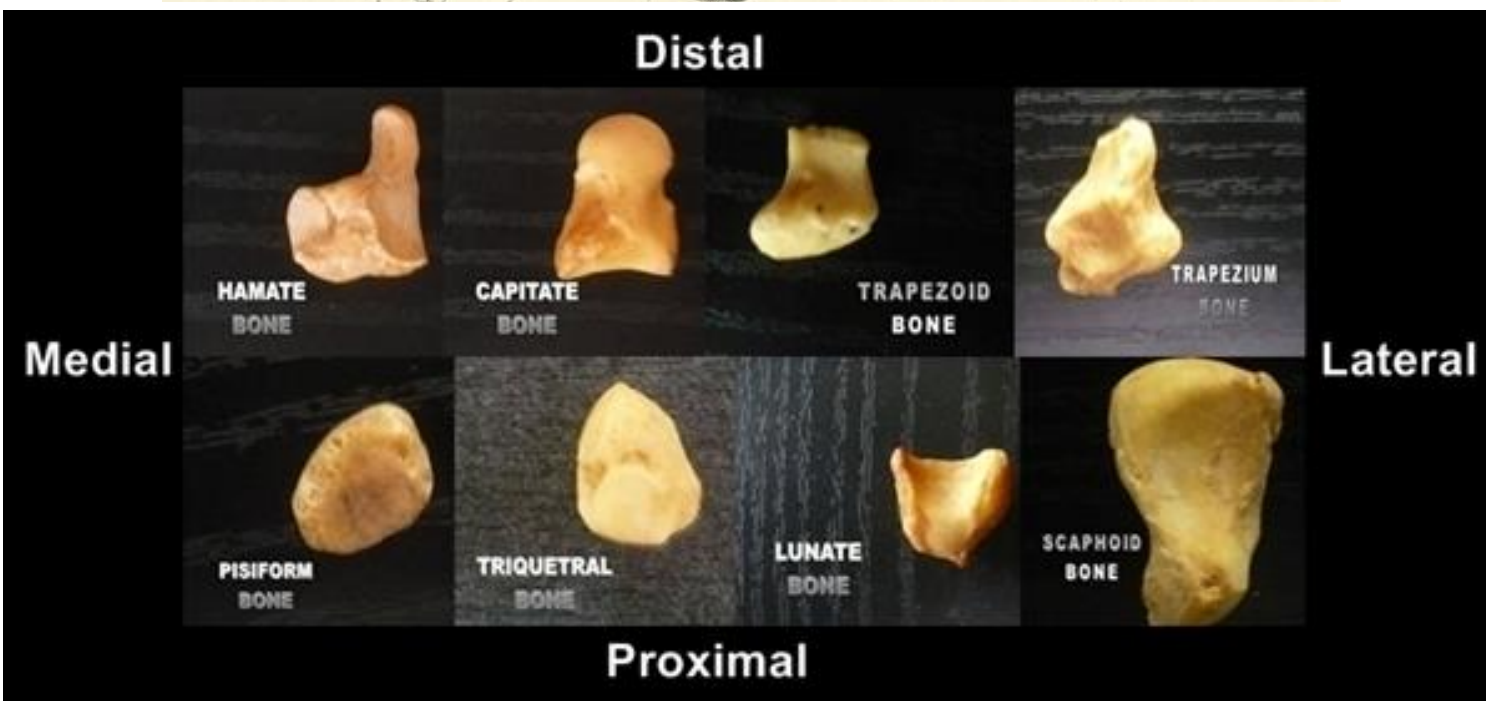
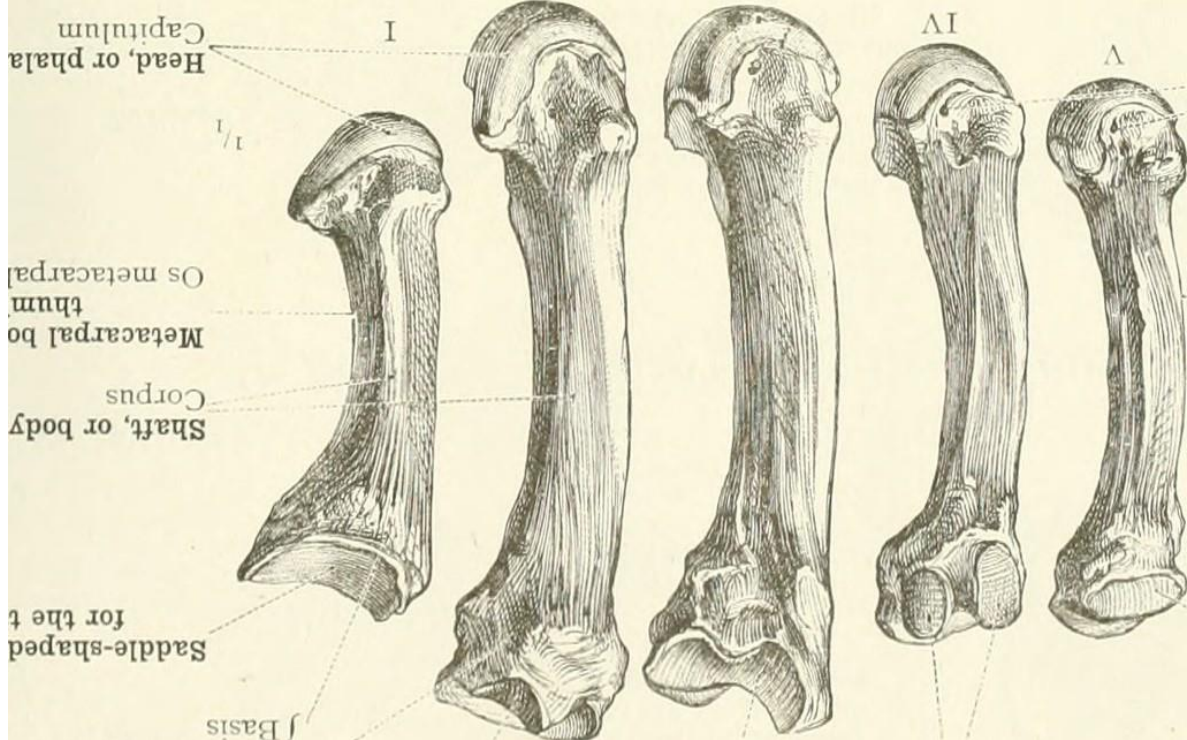
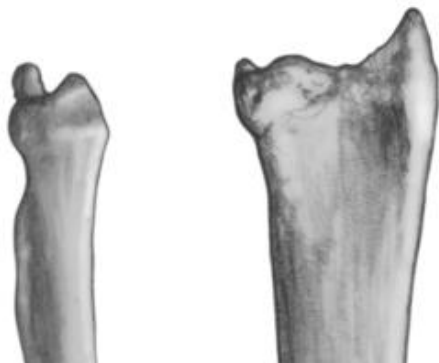
**CARPOMETACARPAL JOINTS**

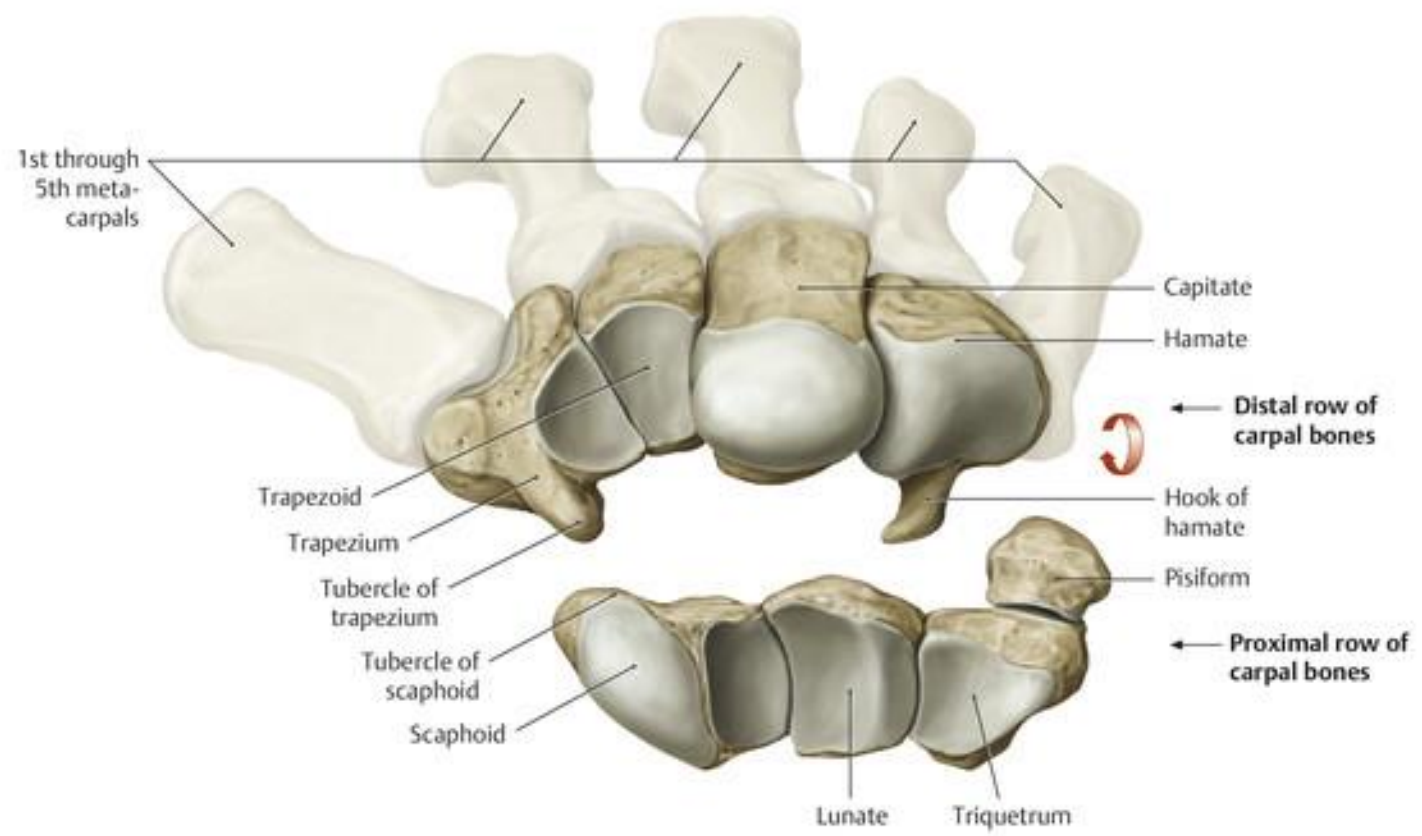
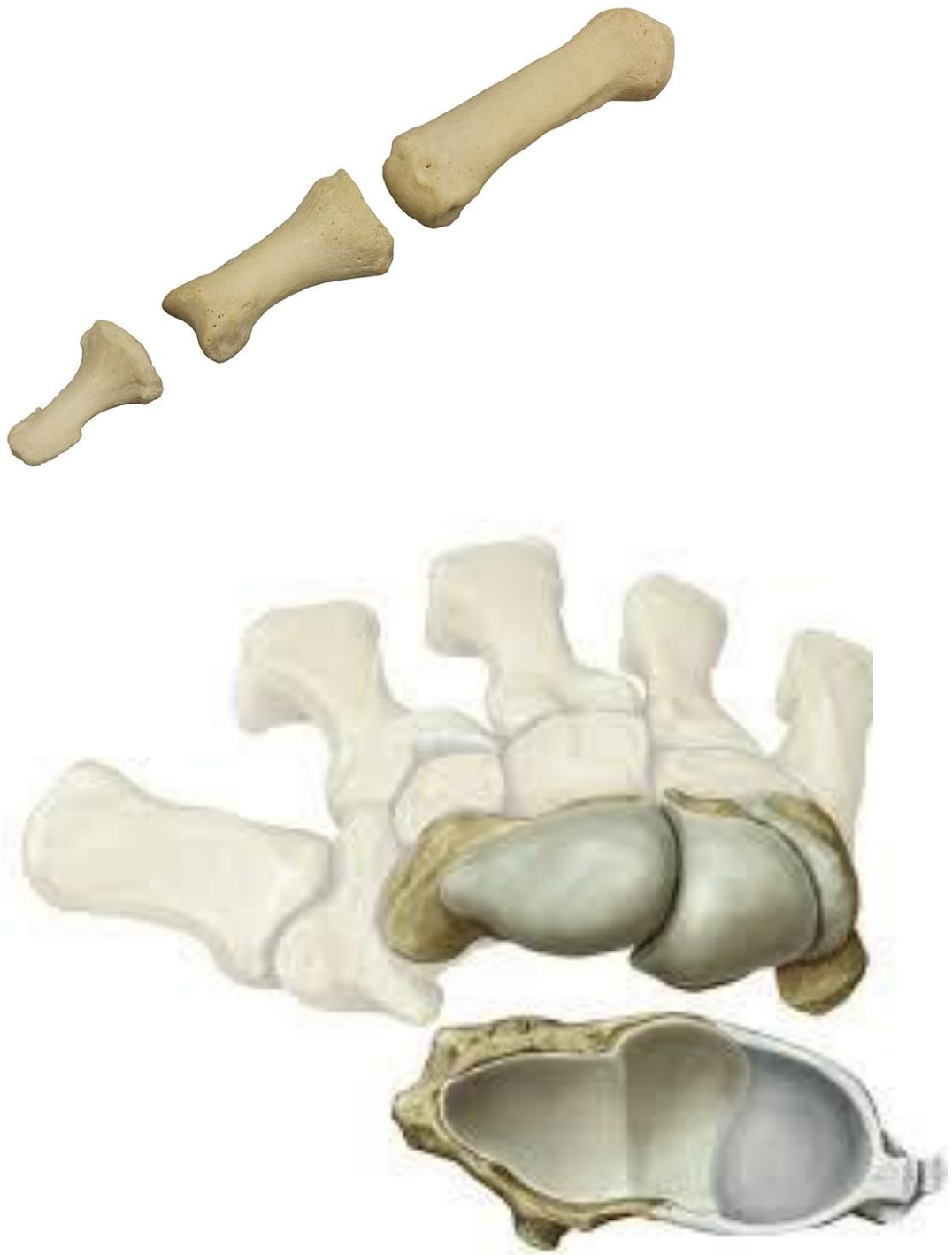

**MIDCARPAL JOINTS**

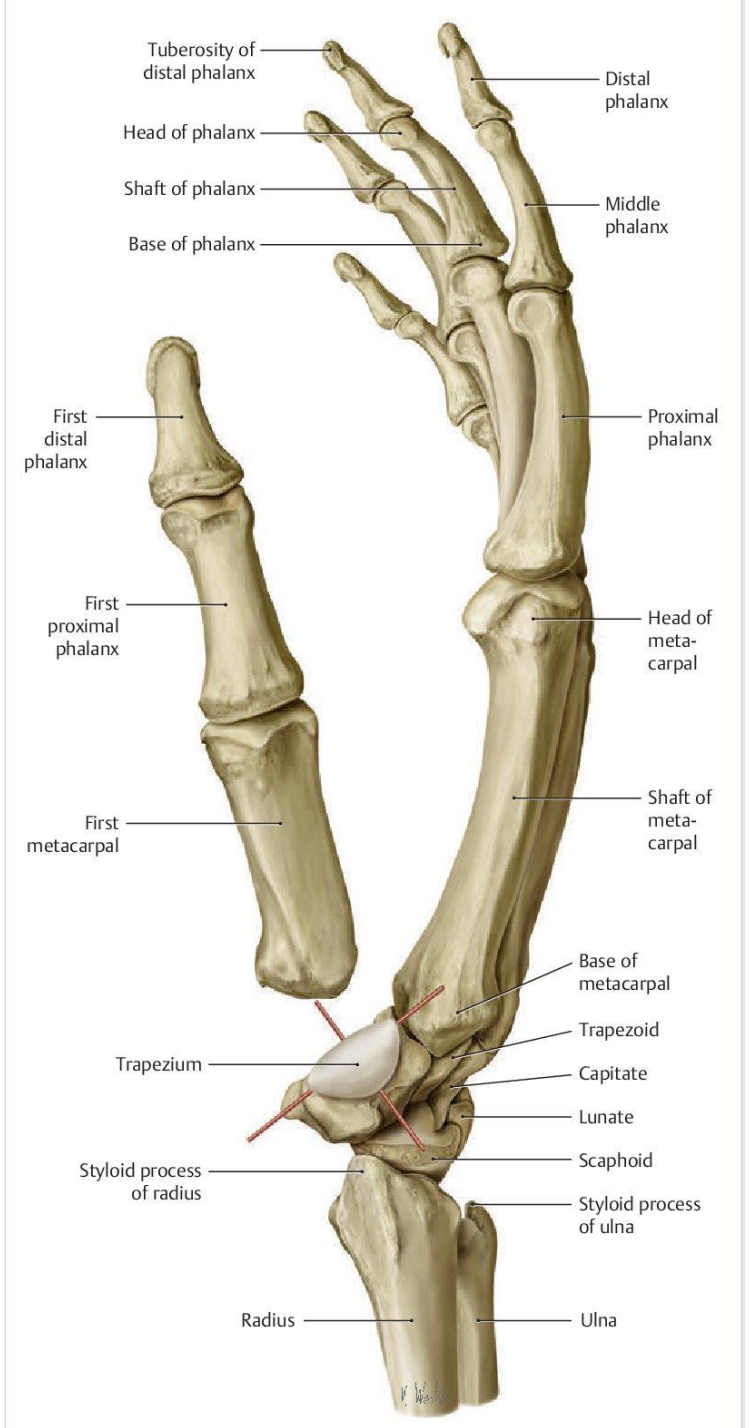
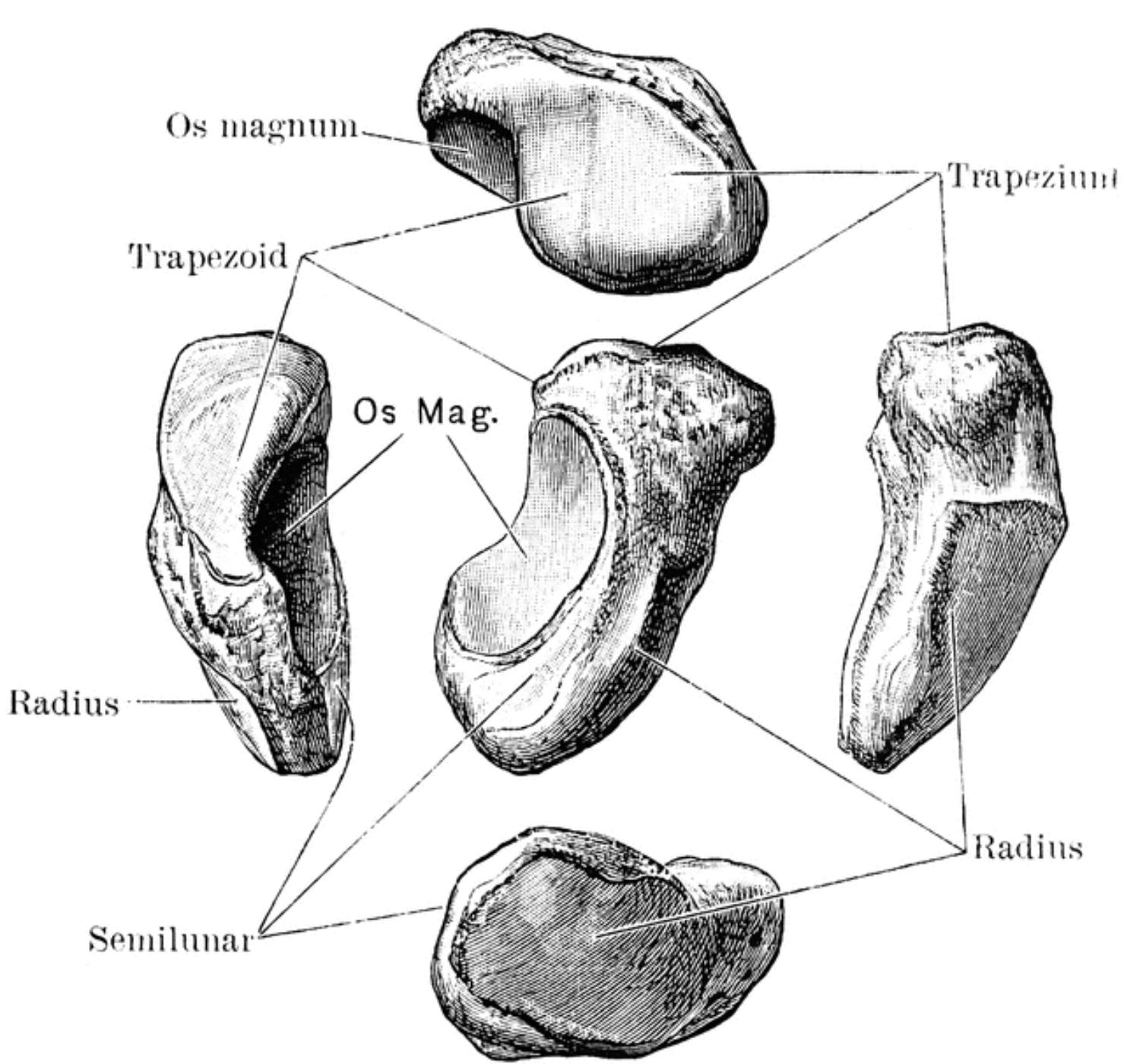


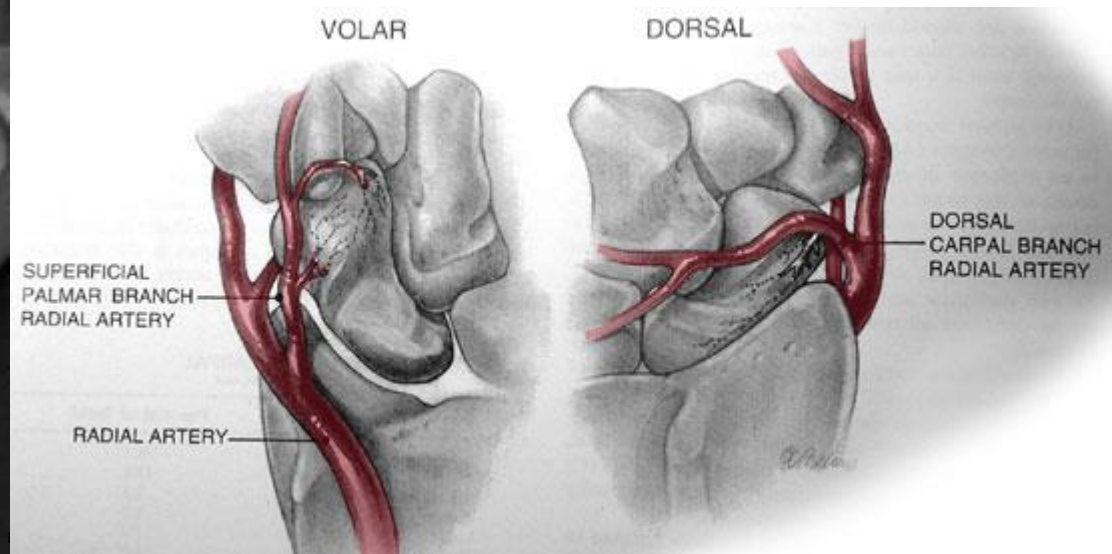
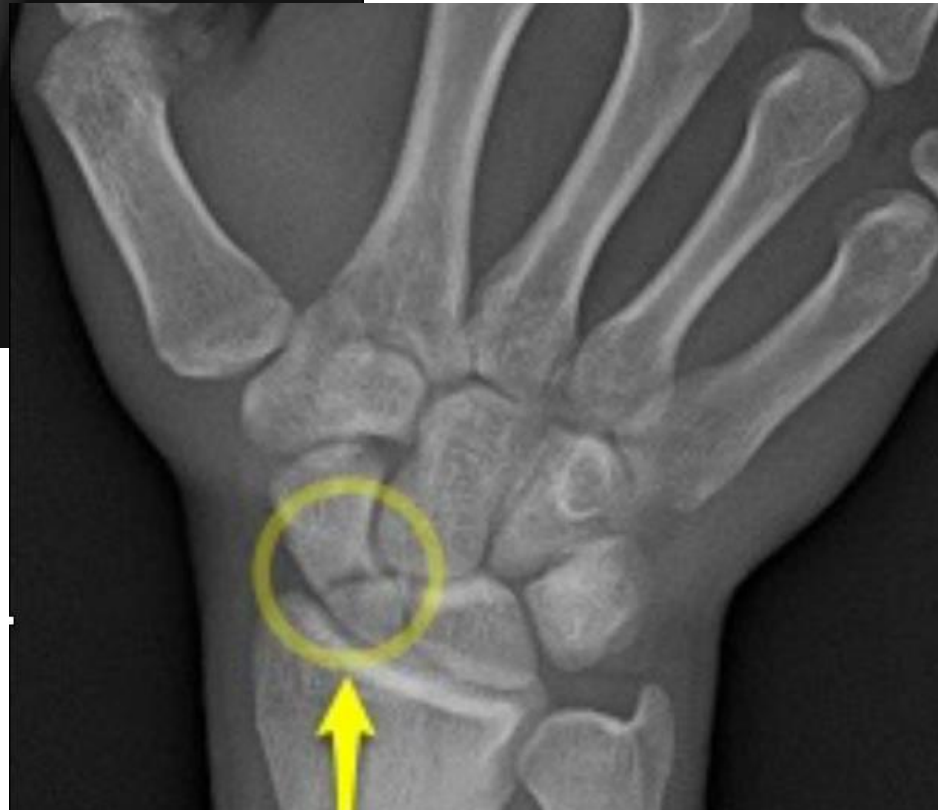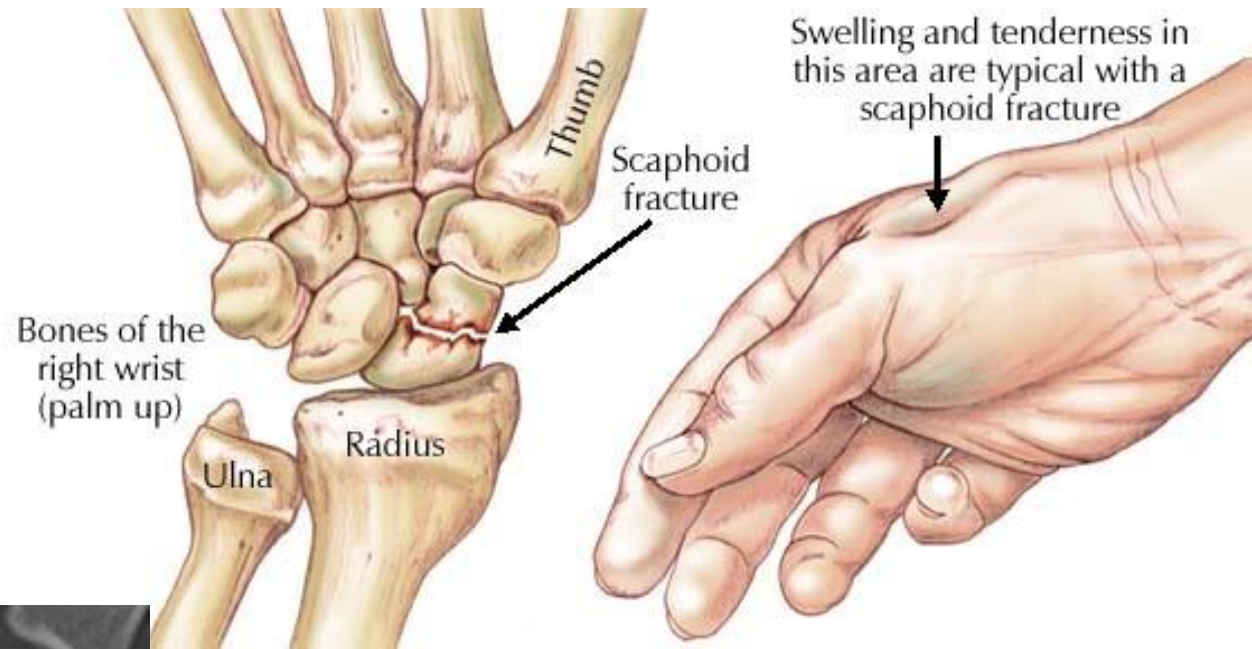
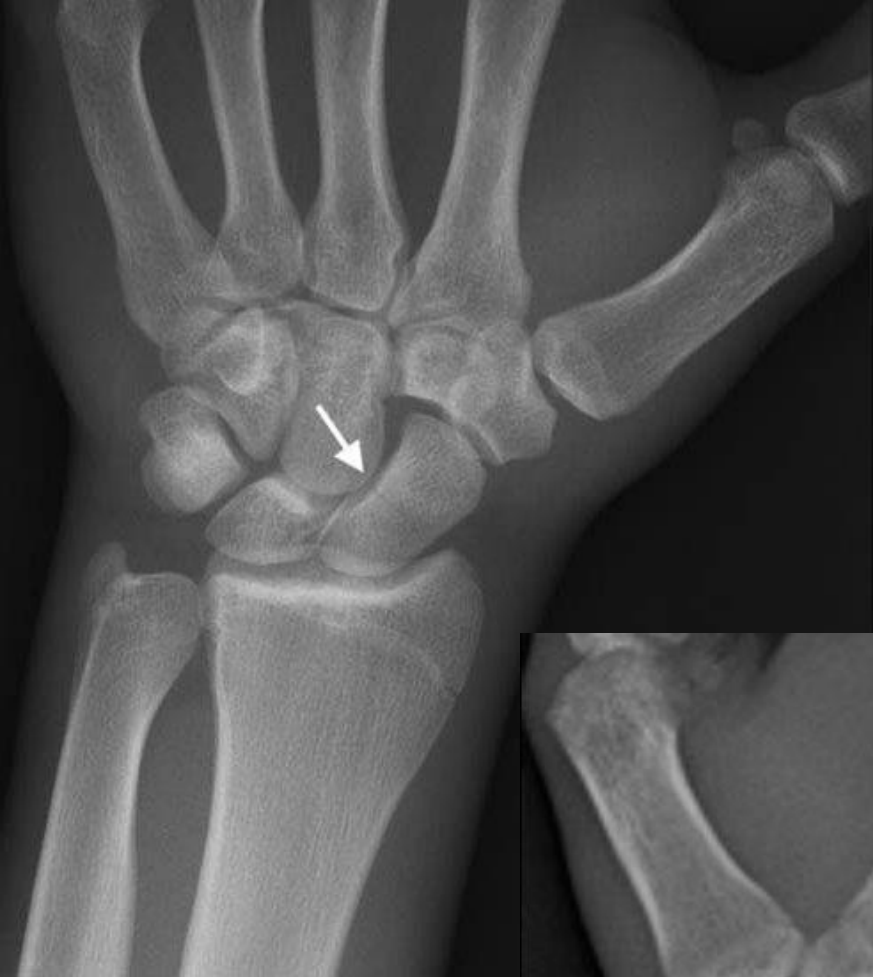**RADIOCARPAL JOINTS**

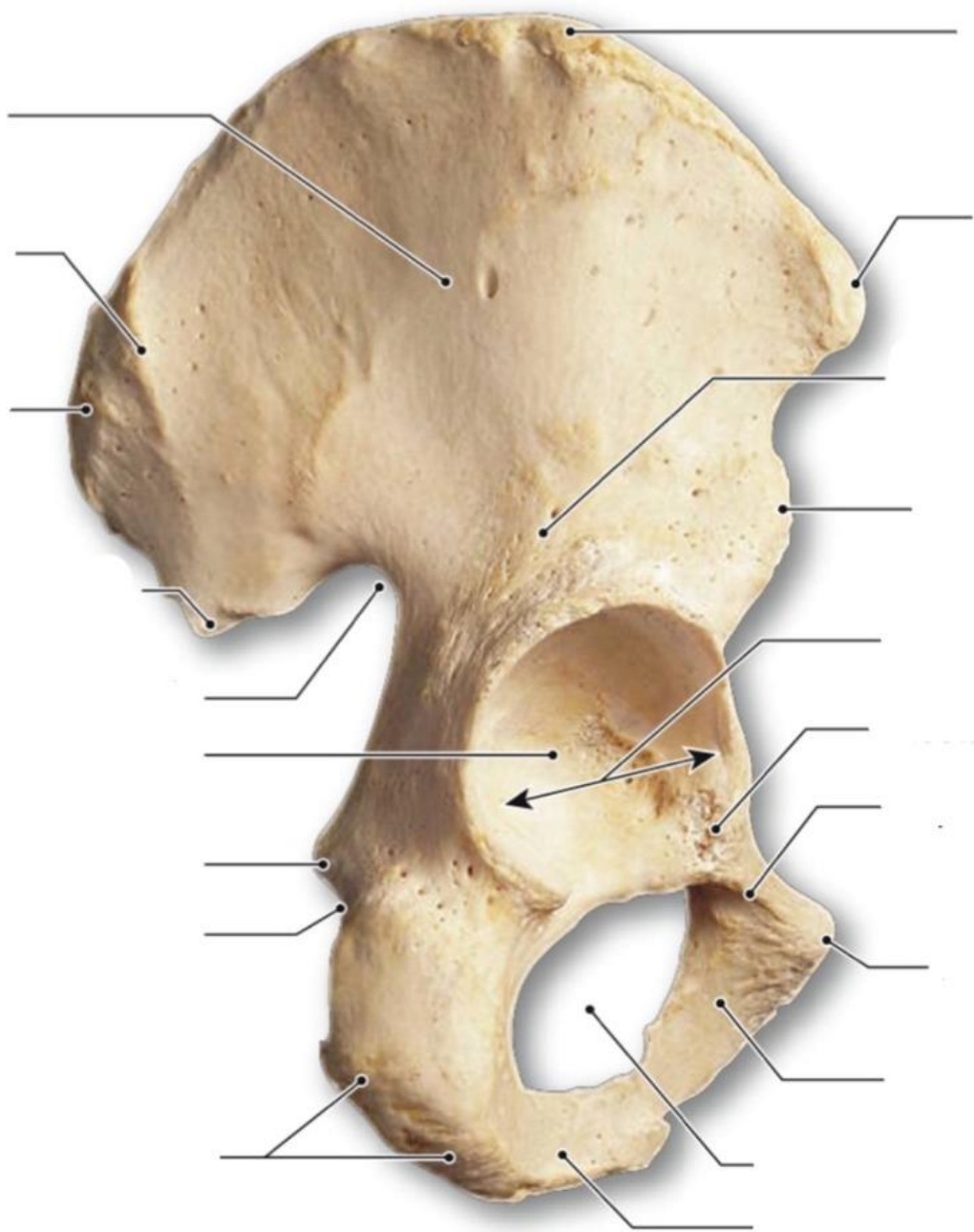




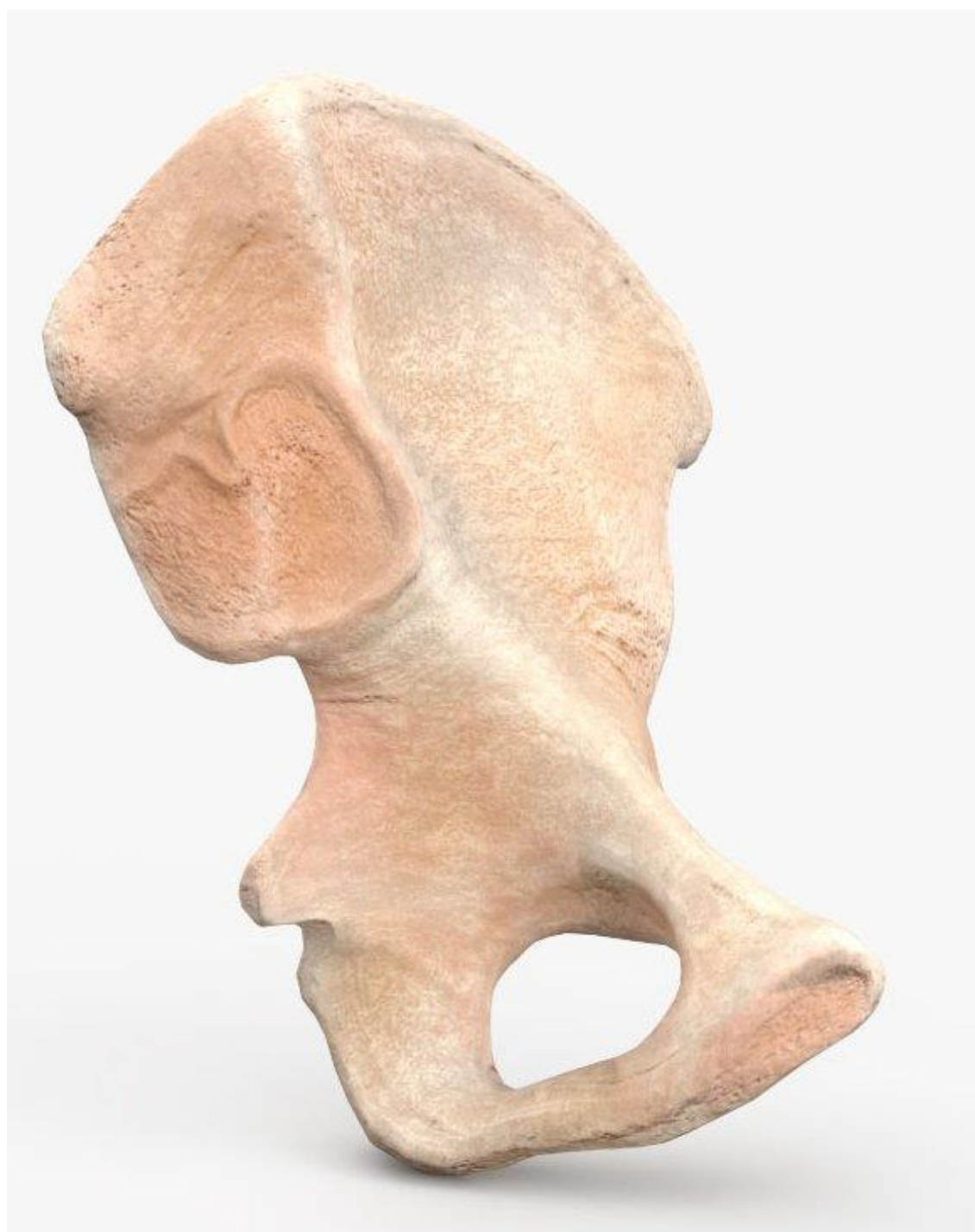




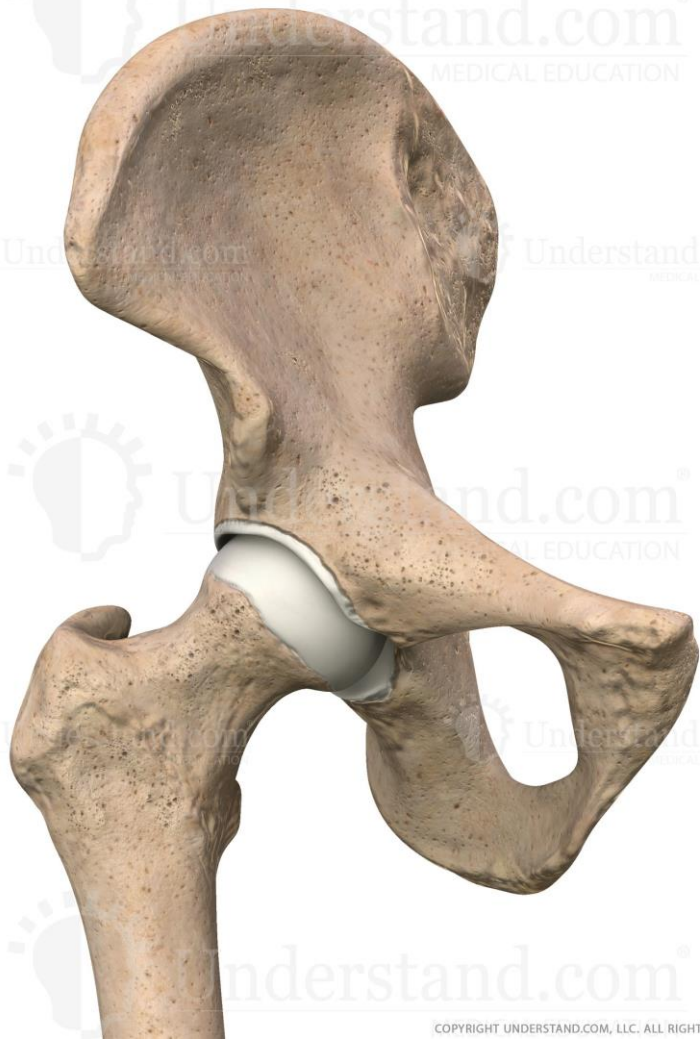


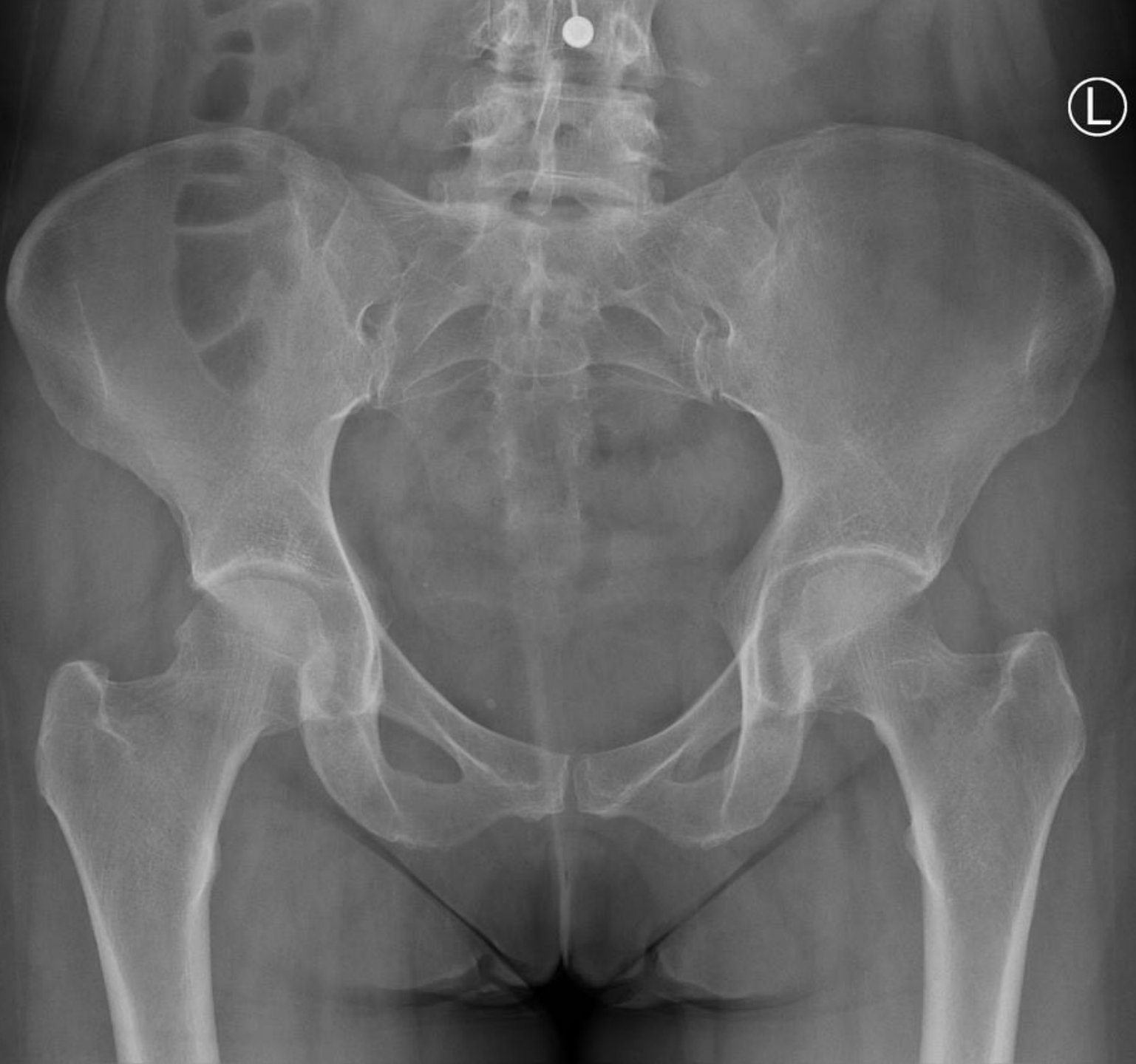
**a** Right hip bone, lateral view

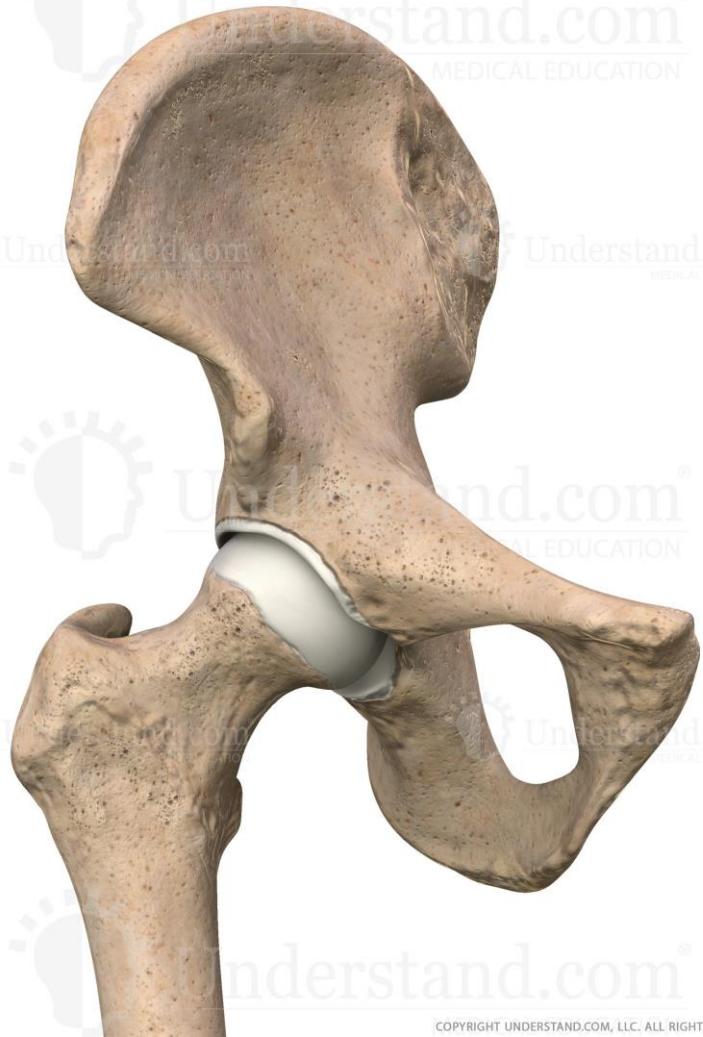





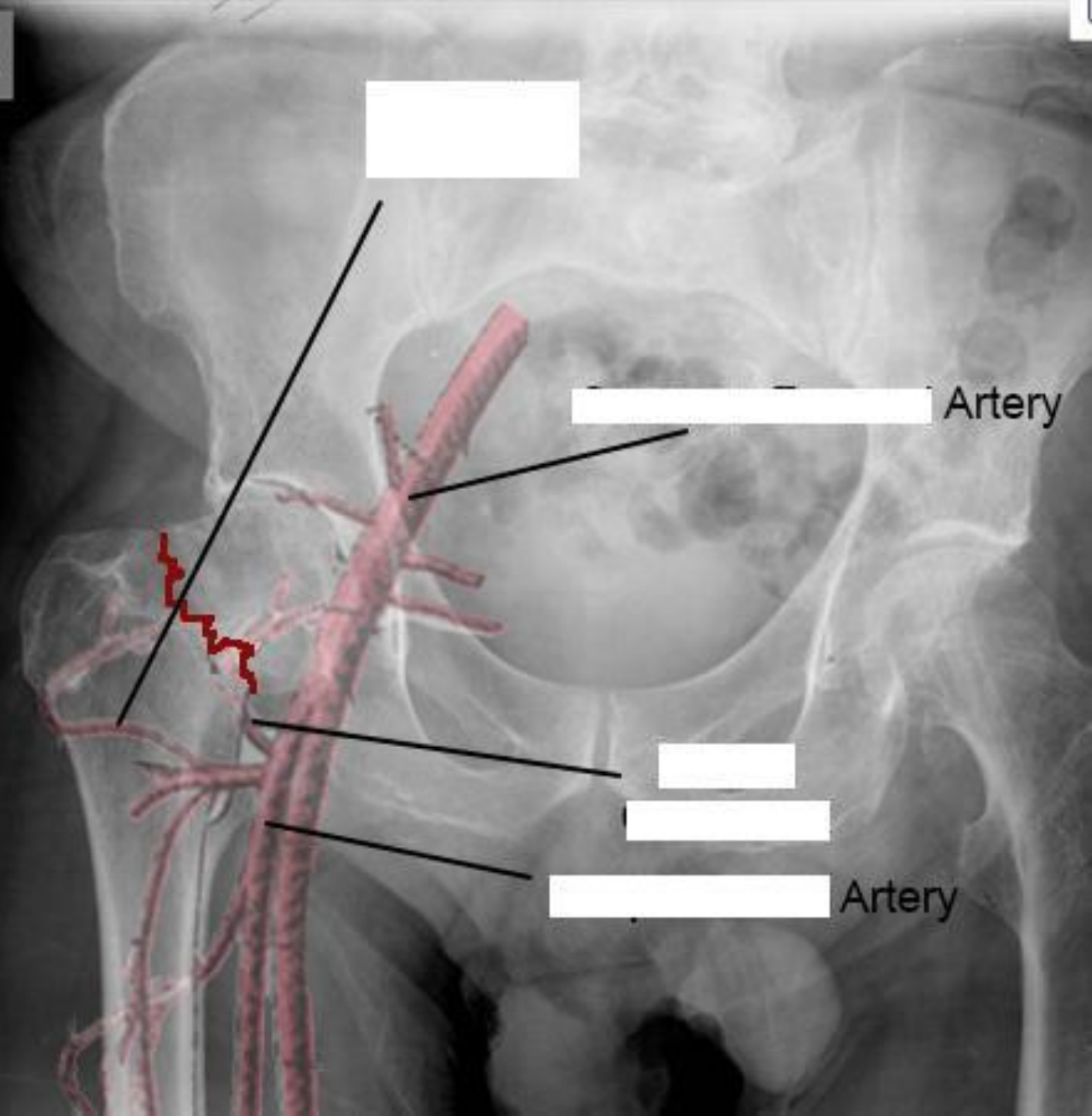
COPYRIGHT UNDERSTAND.COM, LLC. ALL RIGHTS RESERVED



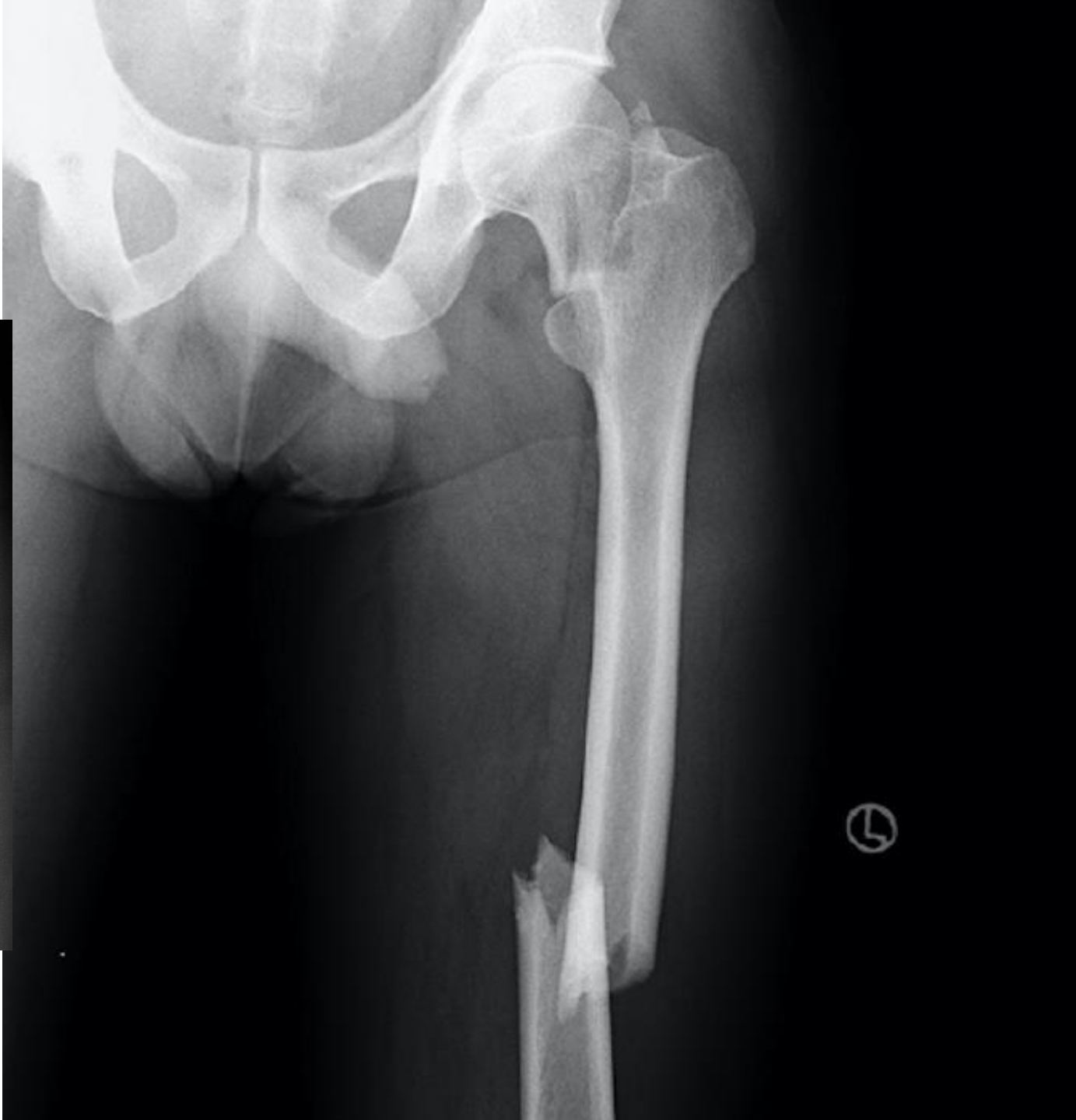
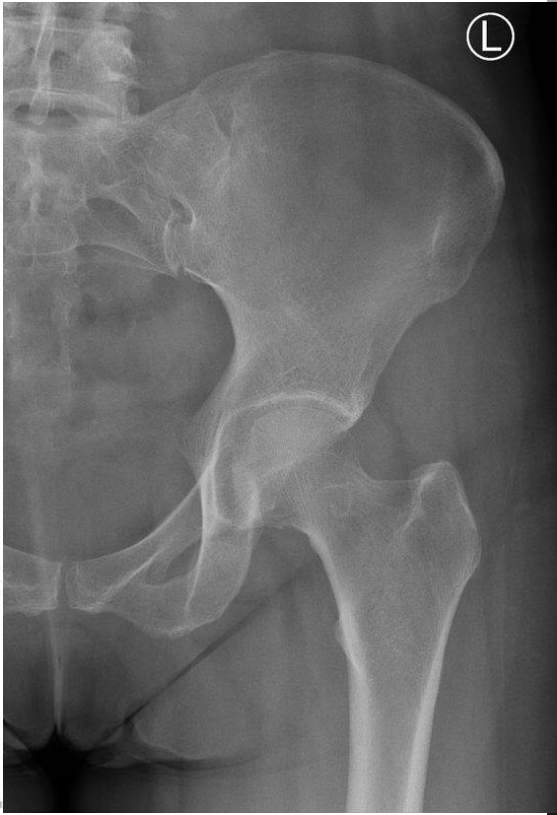
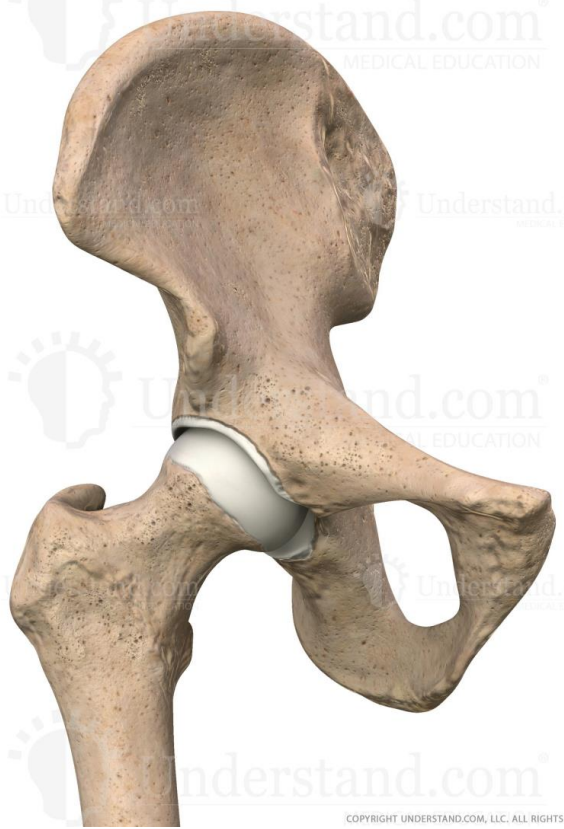COPYRIGHT UNDERSTAND.COM, LLC. ALL RIGHTS RESERVED

R

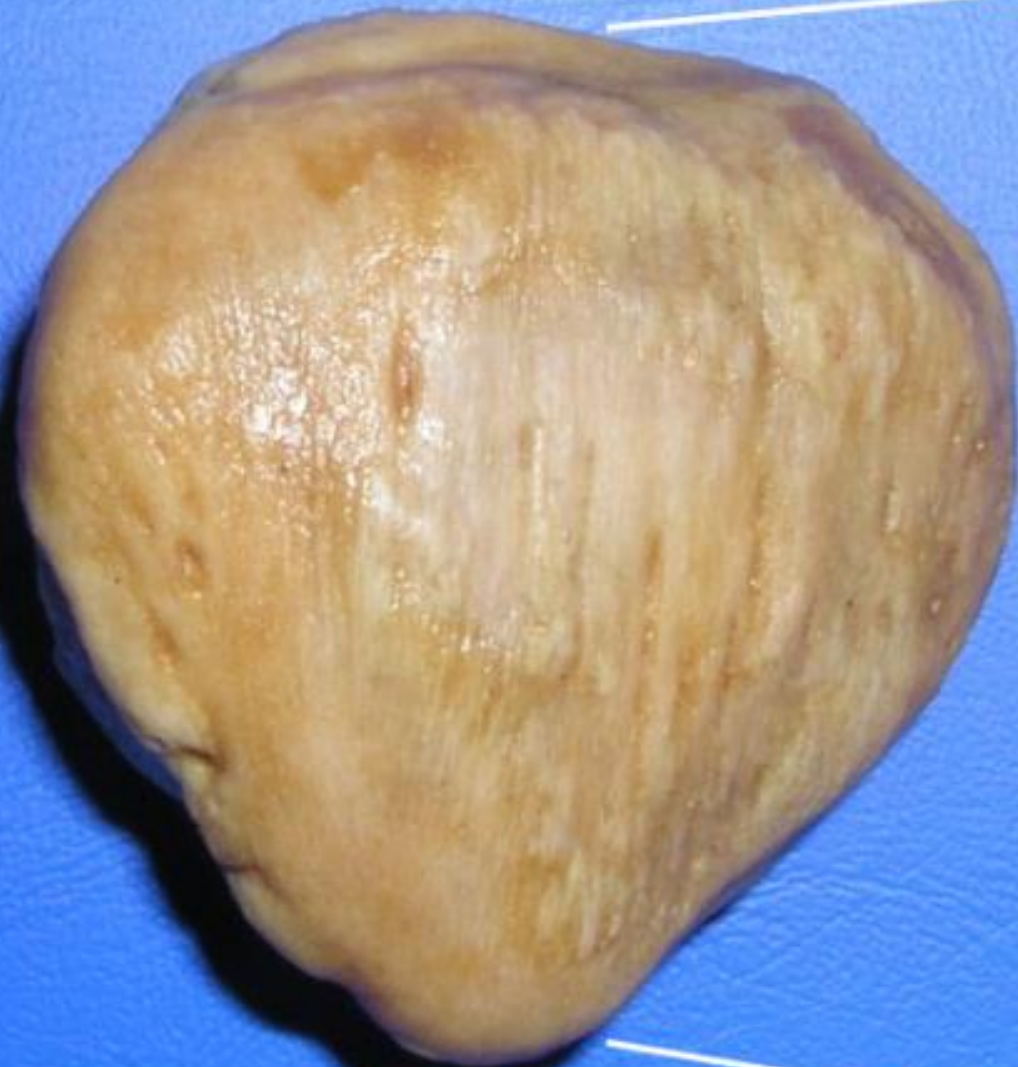





# Patella

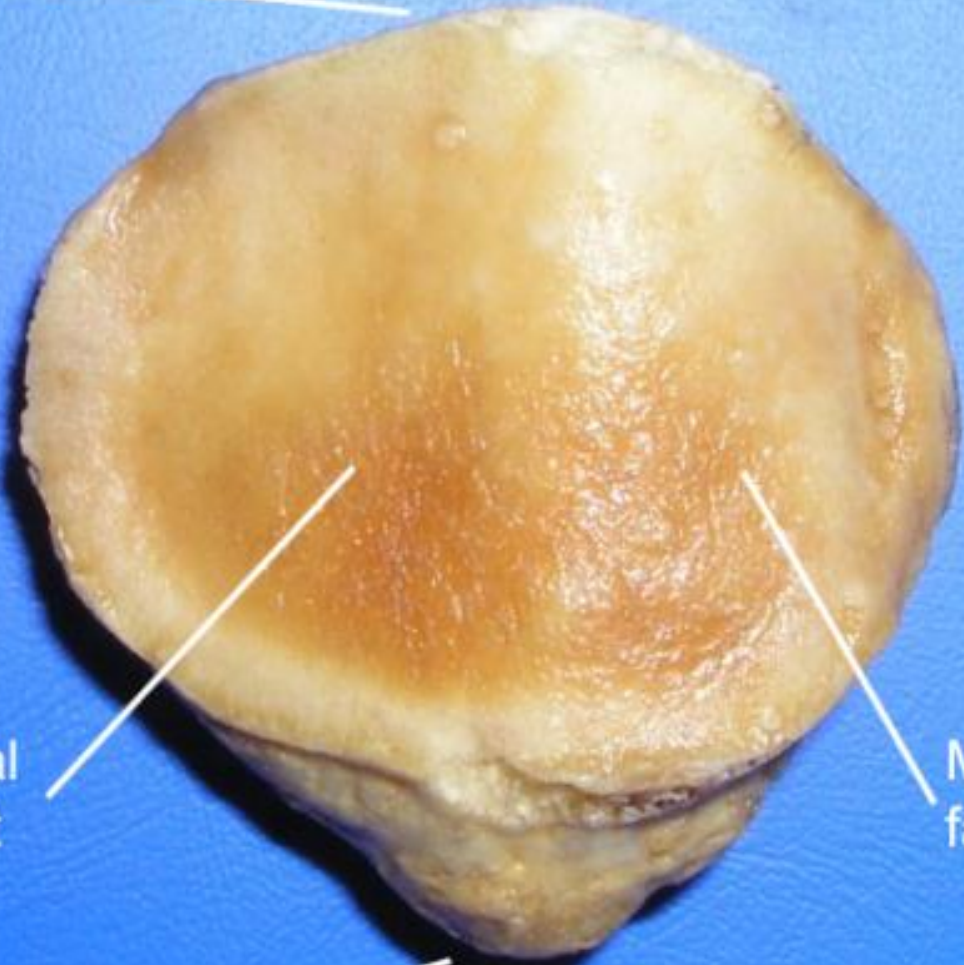
Base



Anterior

Apex

Lateral  
faucet

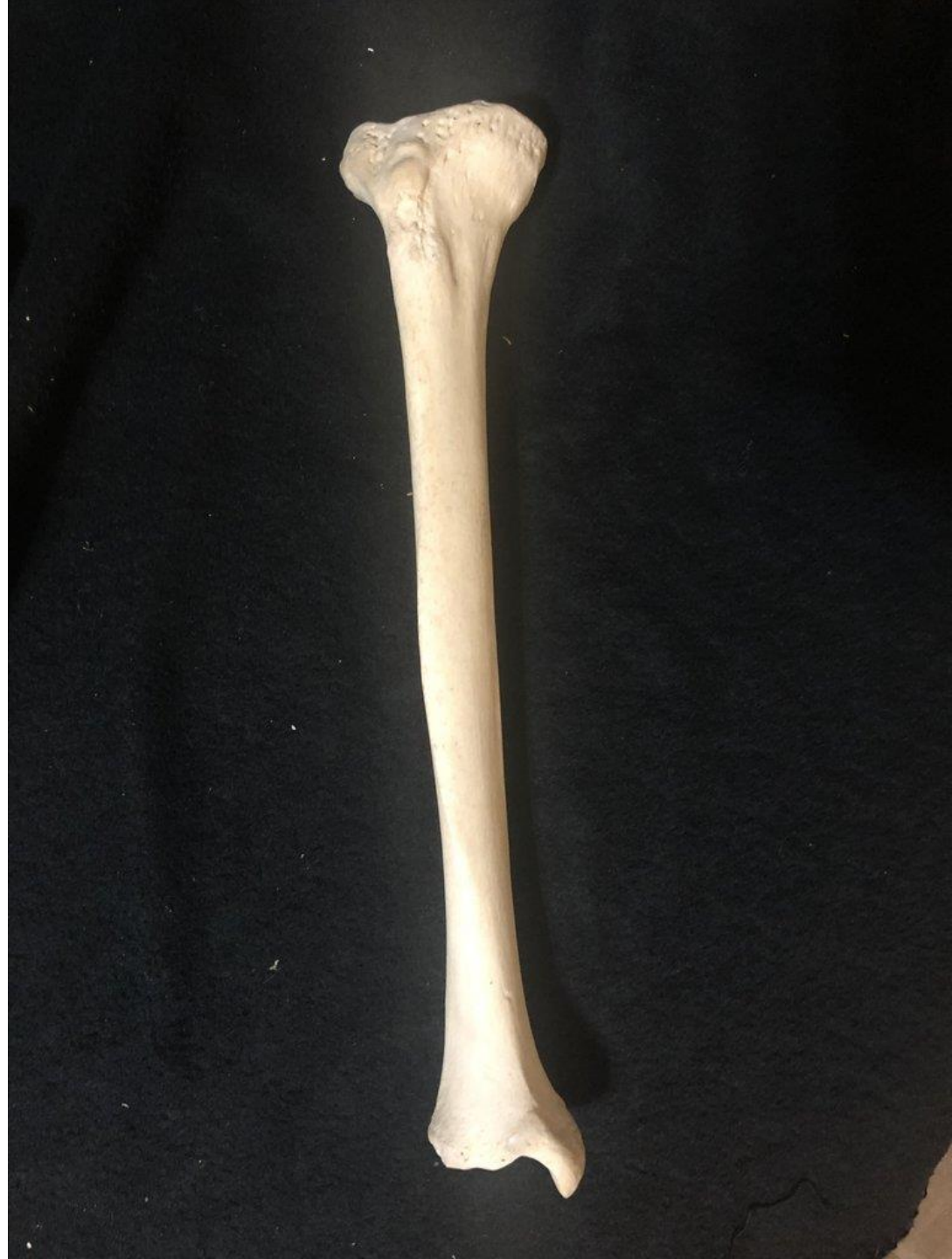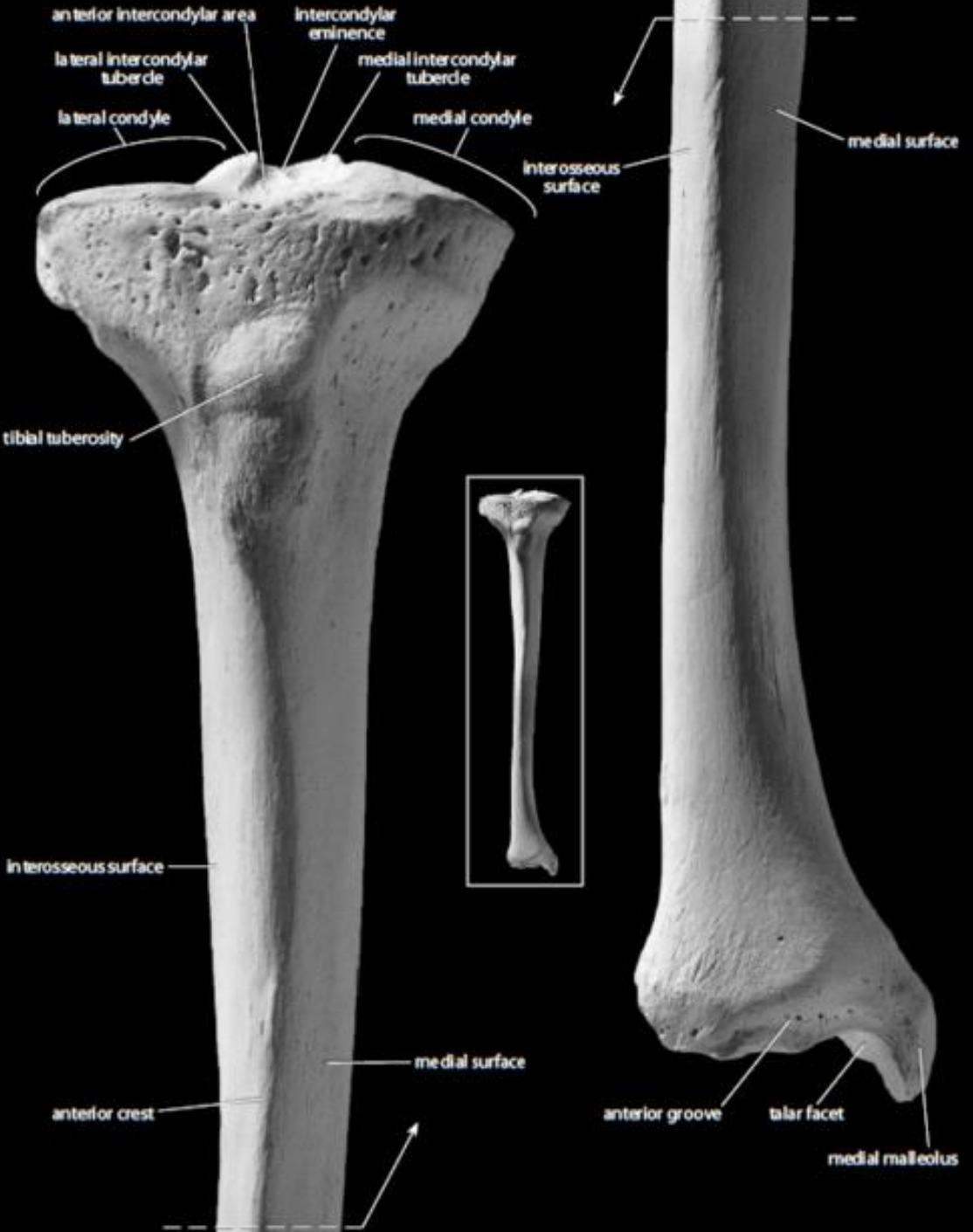



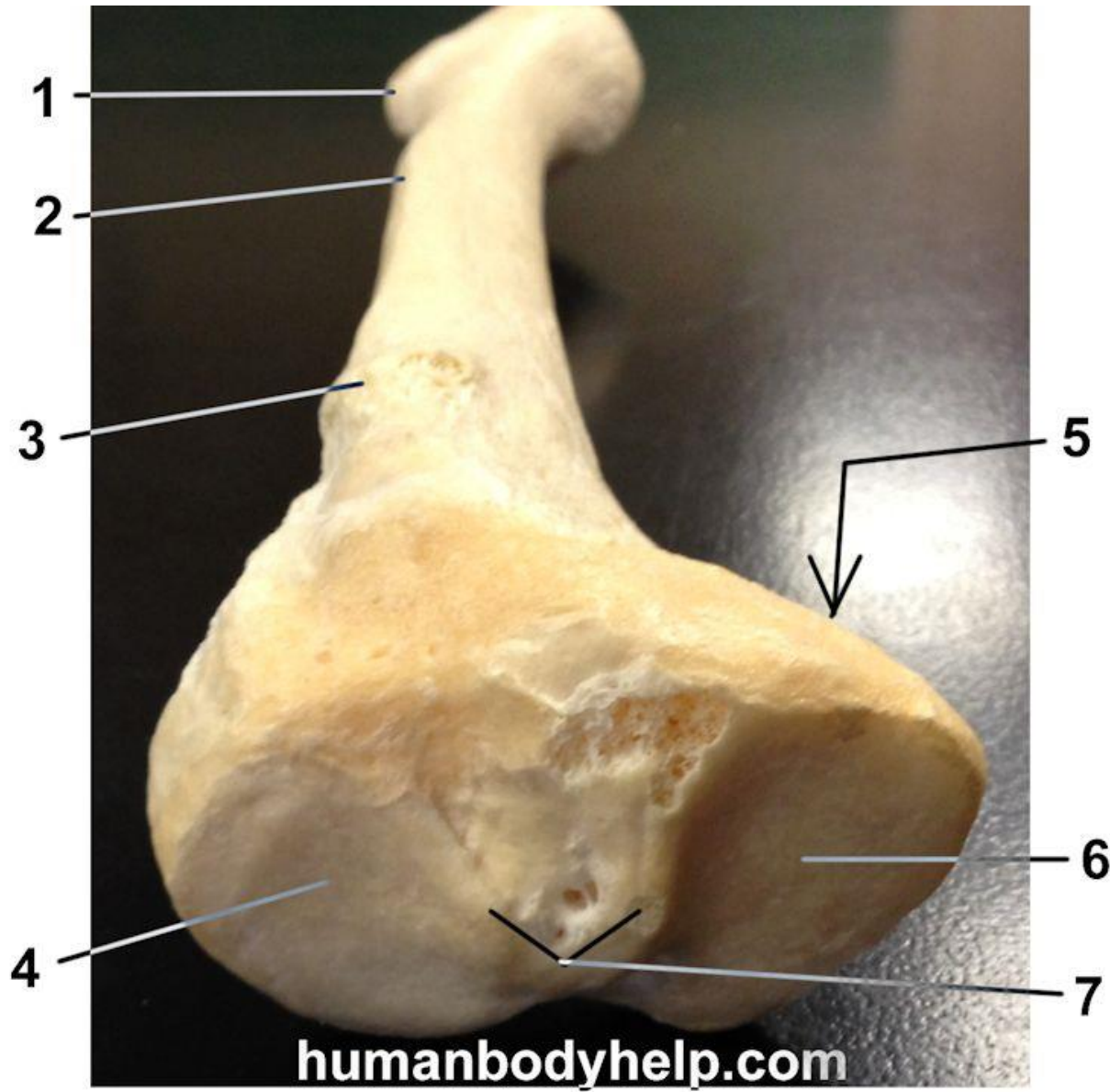
Medial  
faucet

Posterior

PALPATE YOUR PATELLA

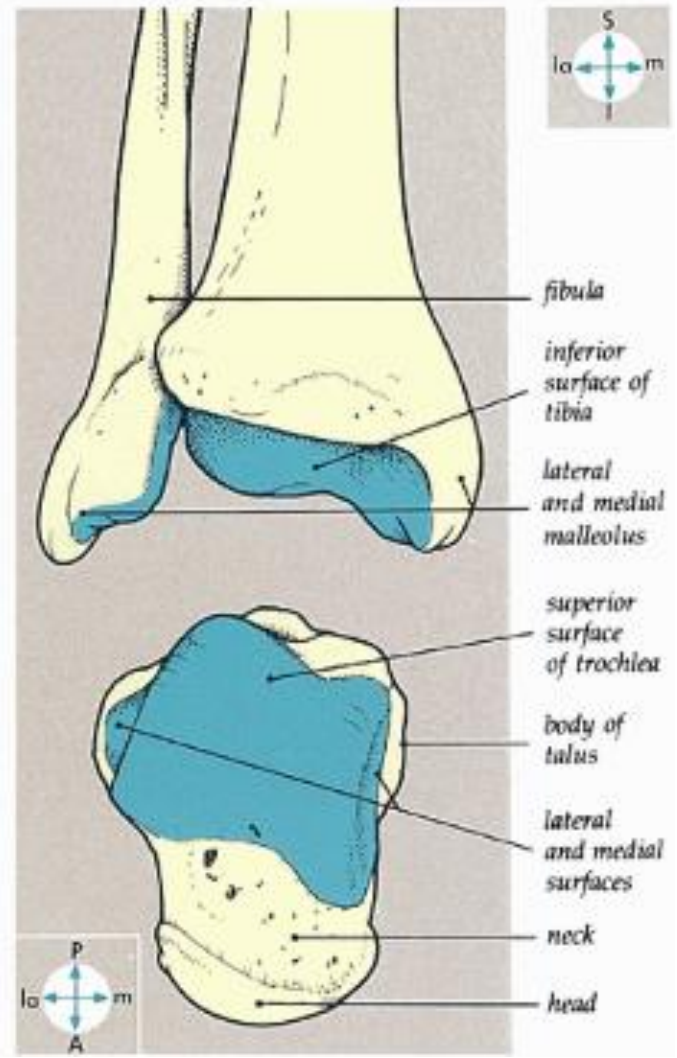
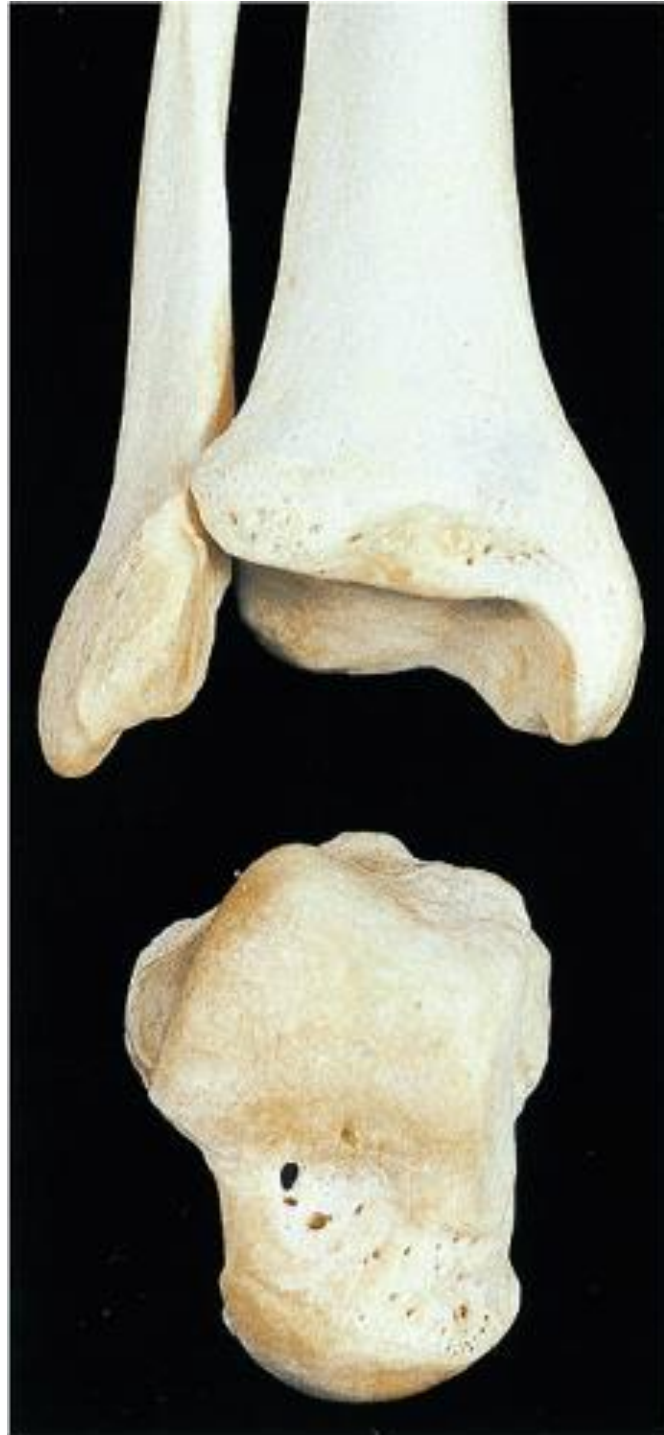
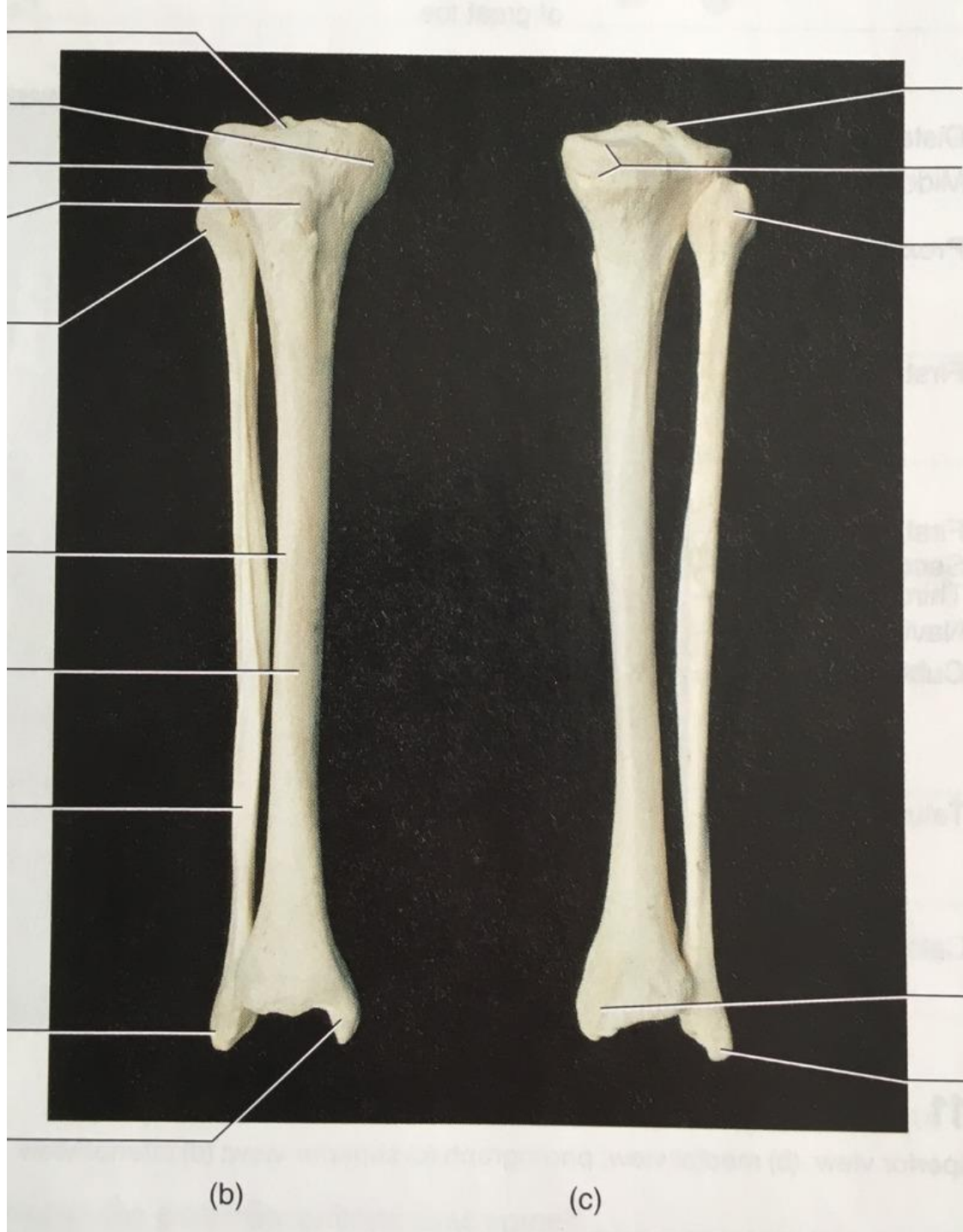


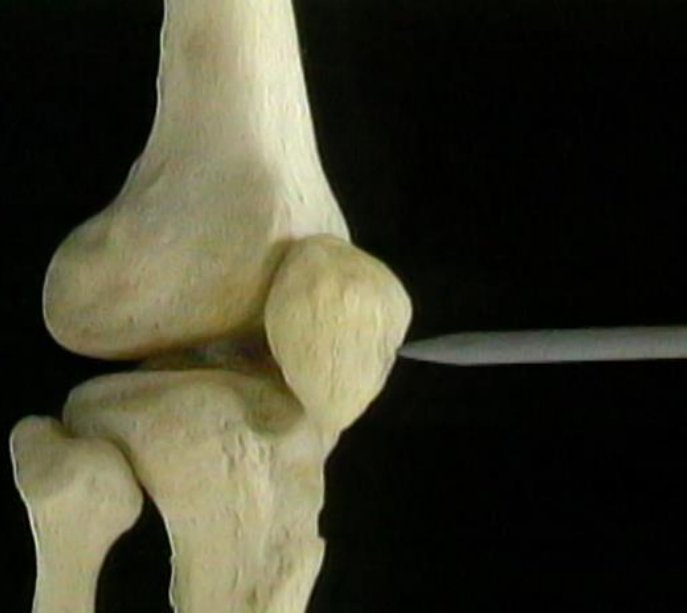
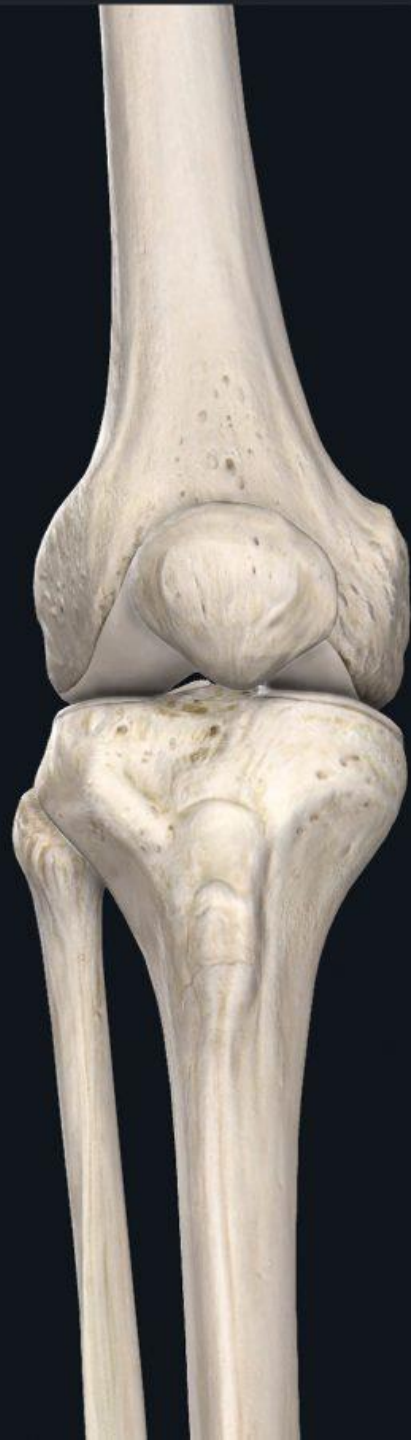
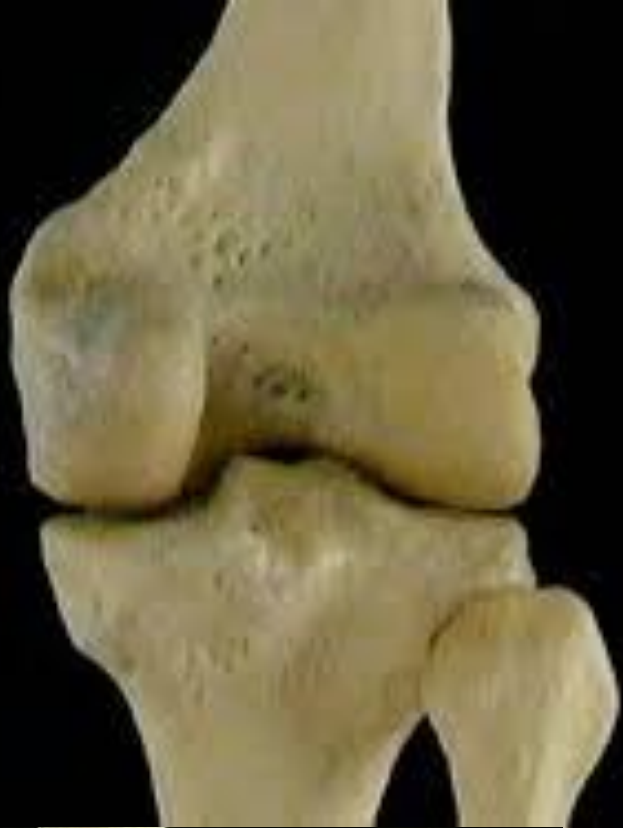
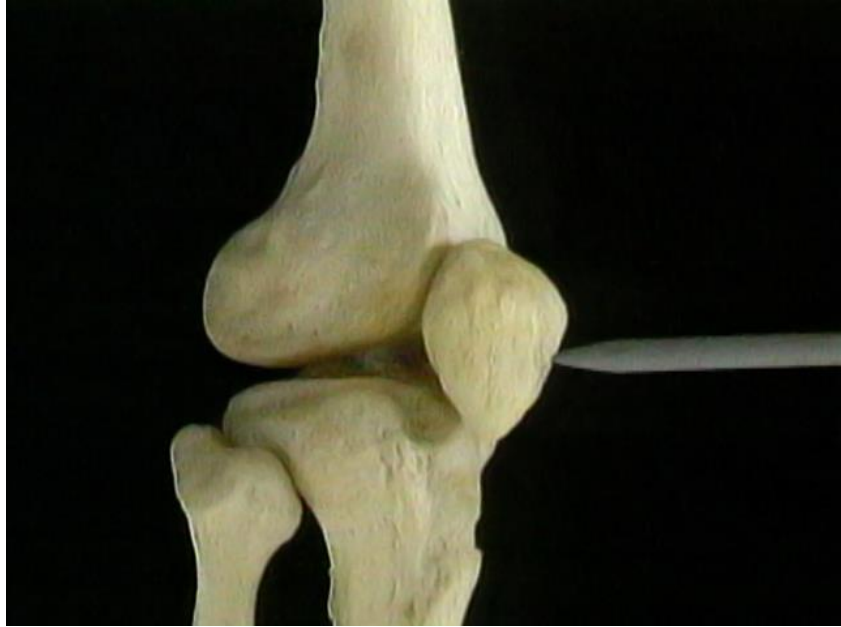






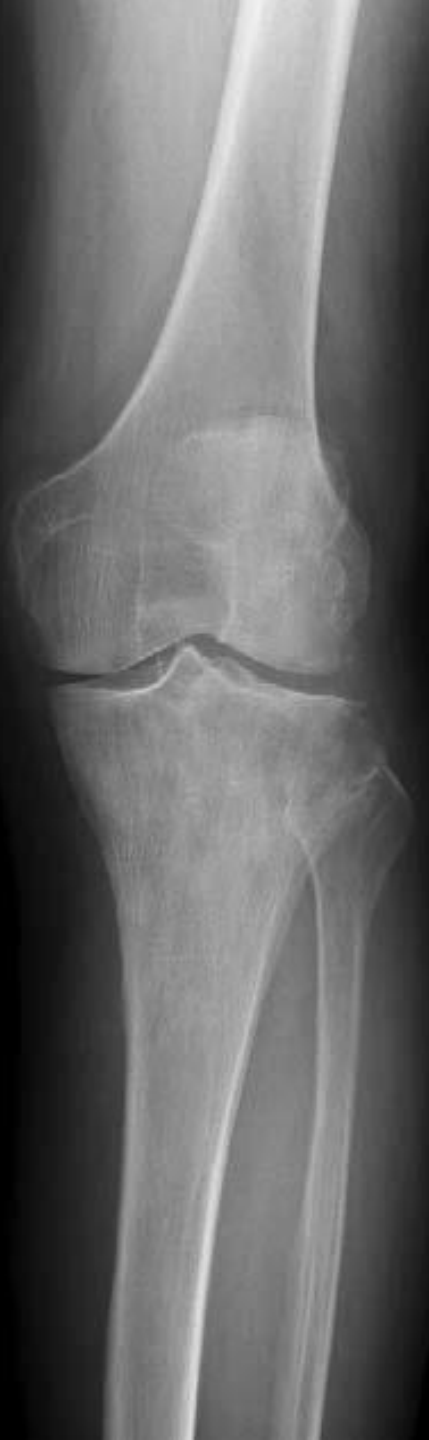




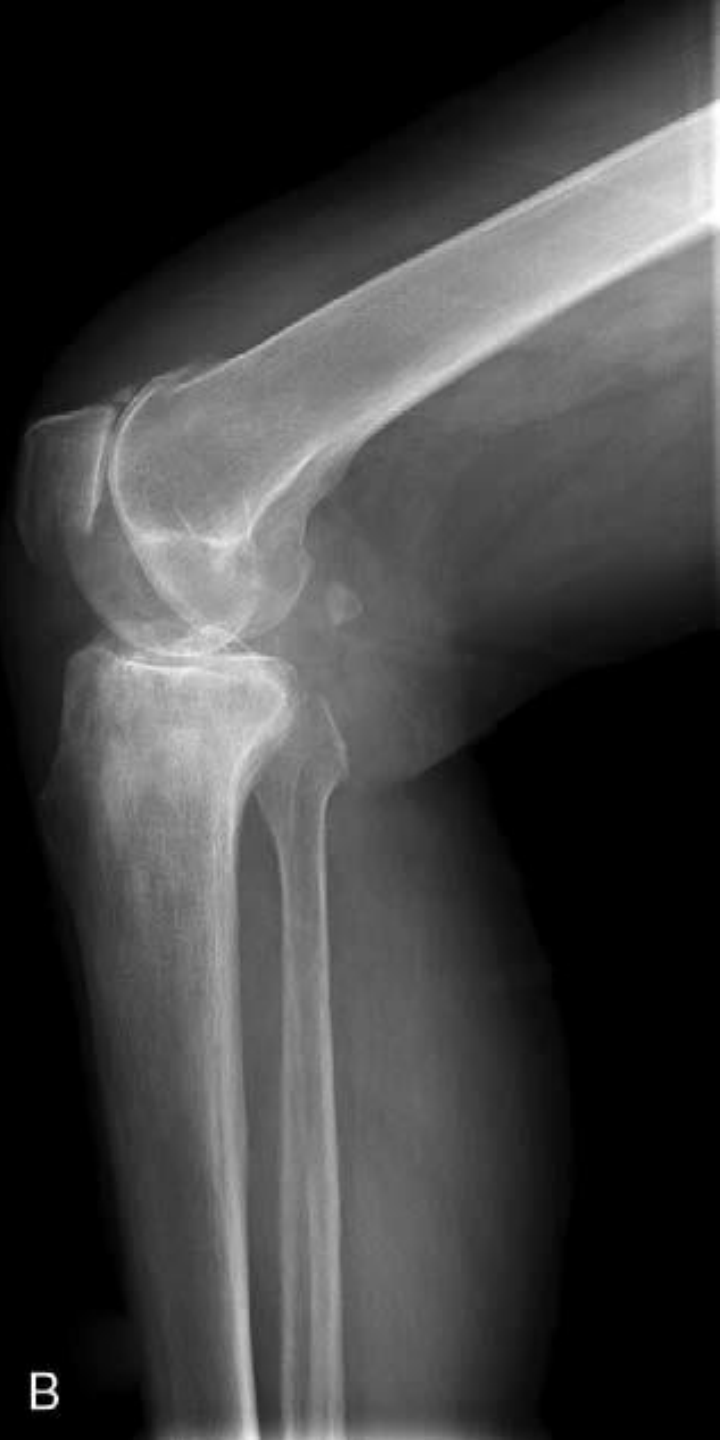
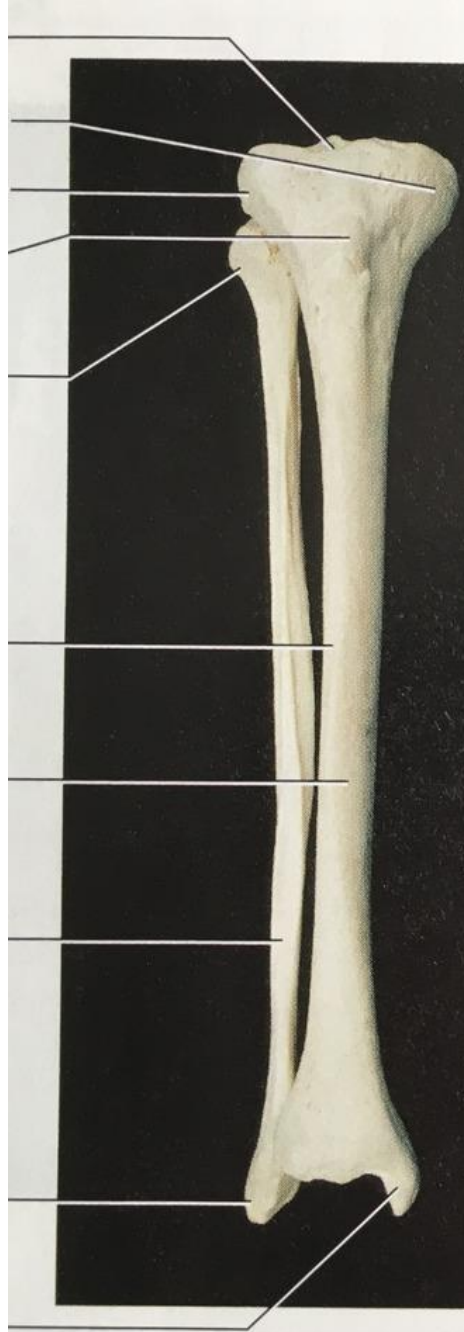A

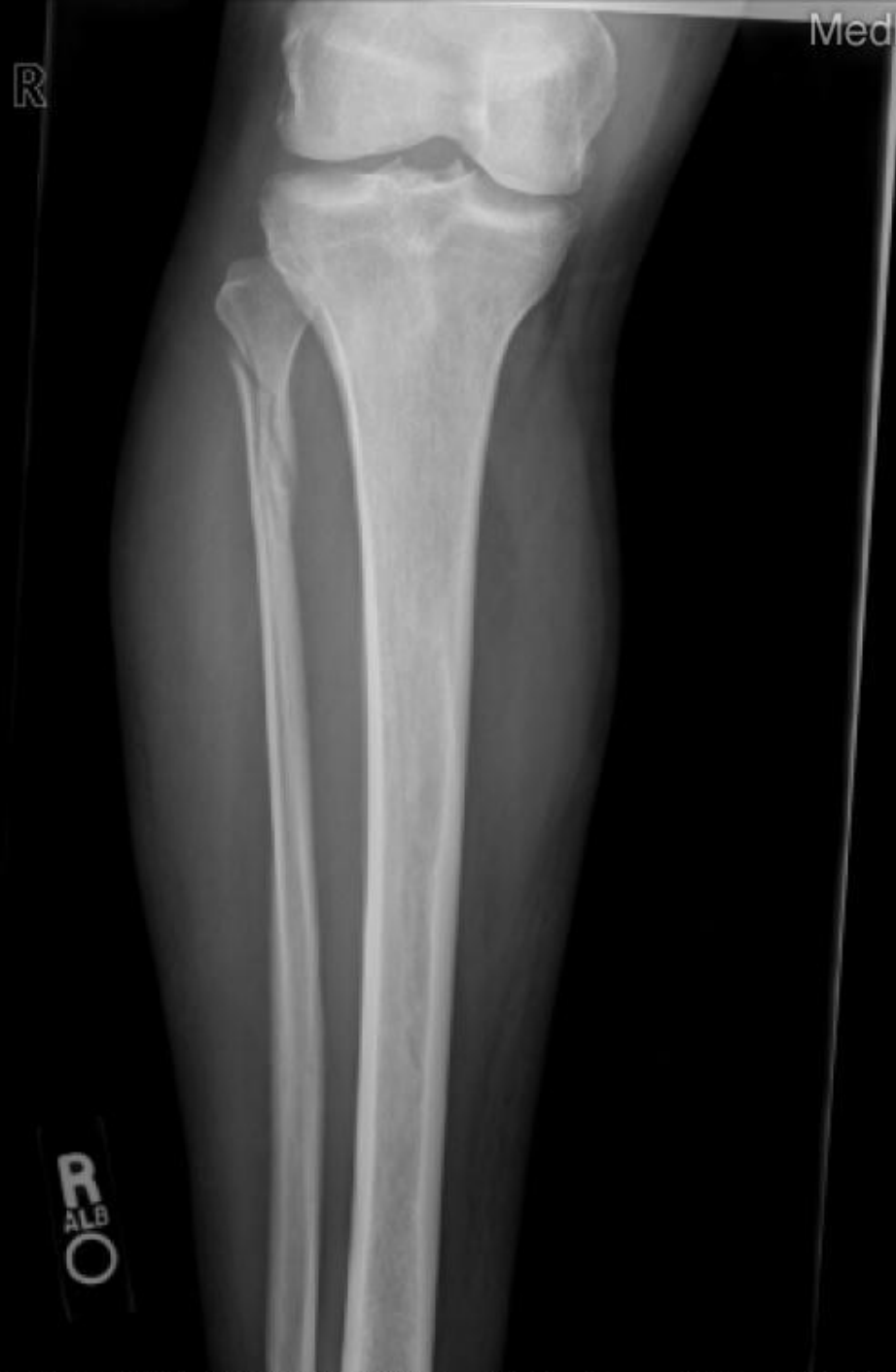

B

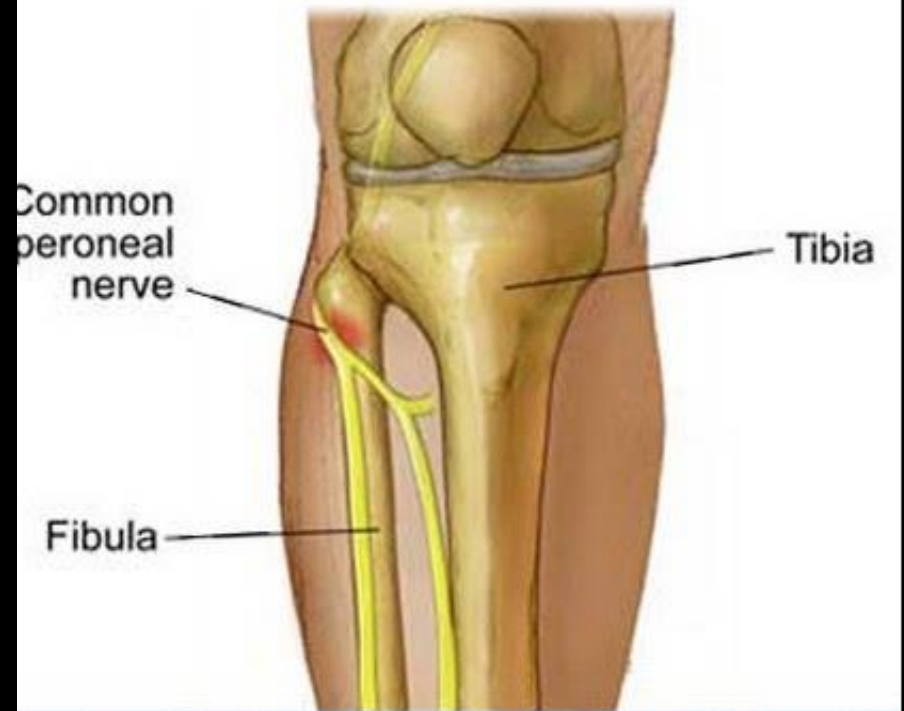



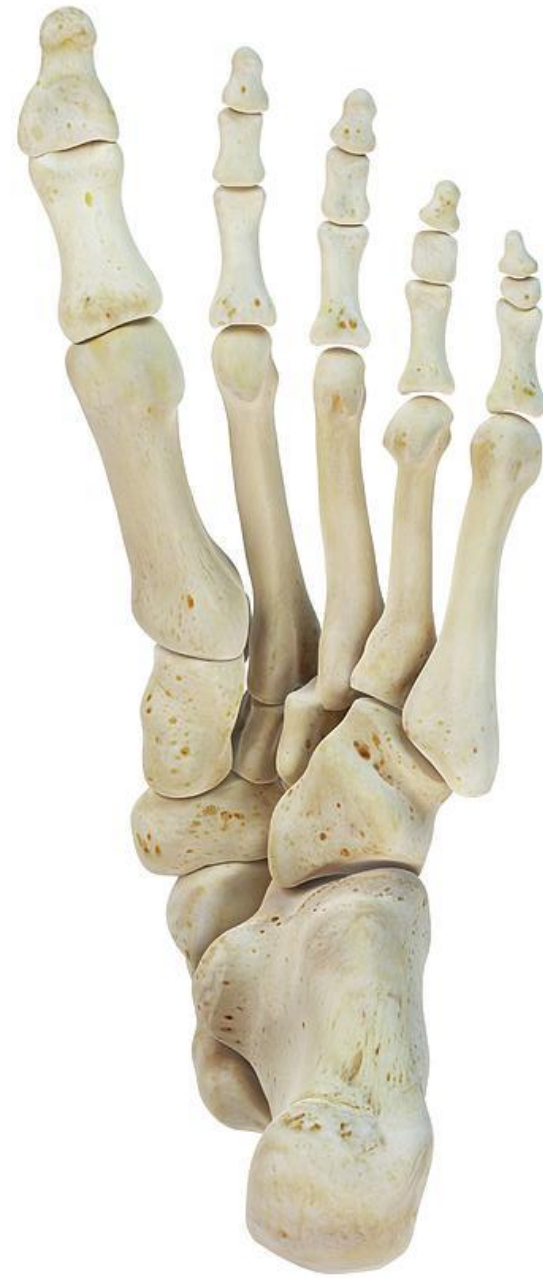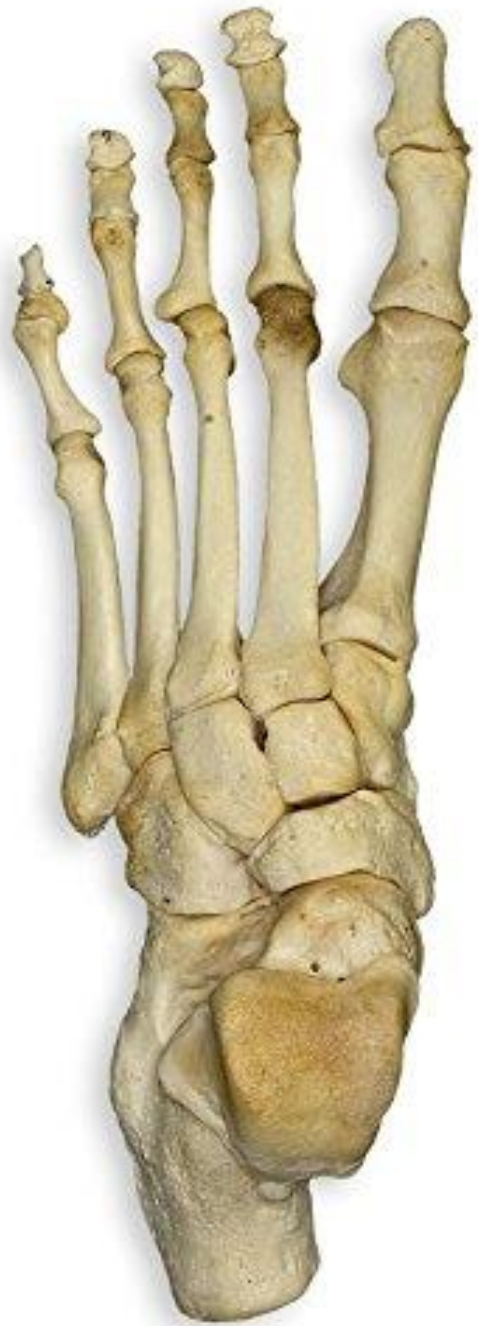(b)



MedPix®



© Mayo Foundation for Medical Education and Research. All rights reserved.



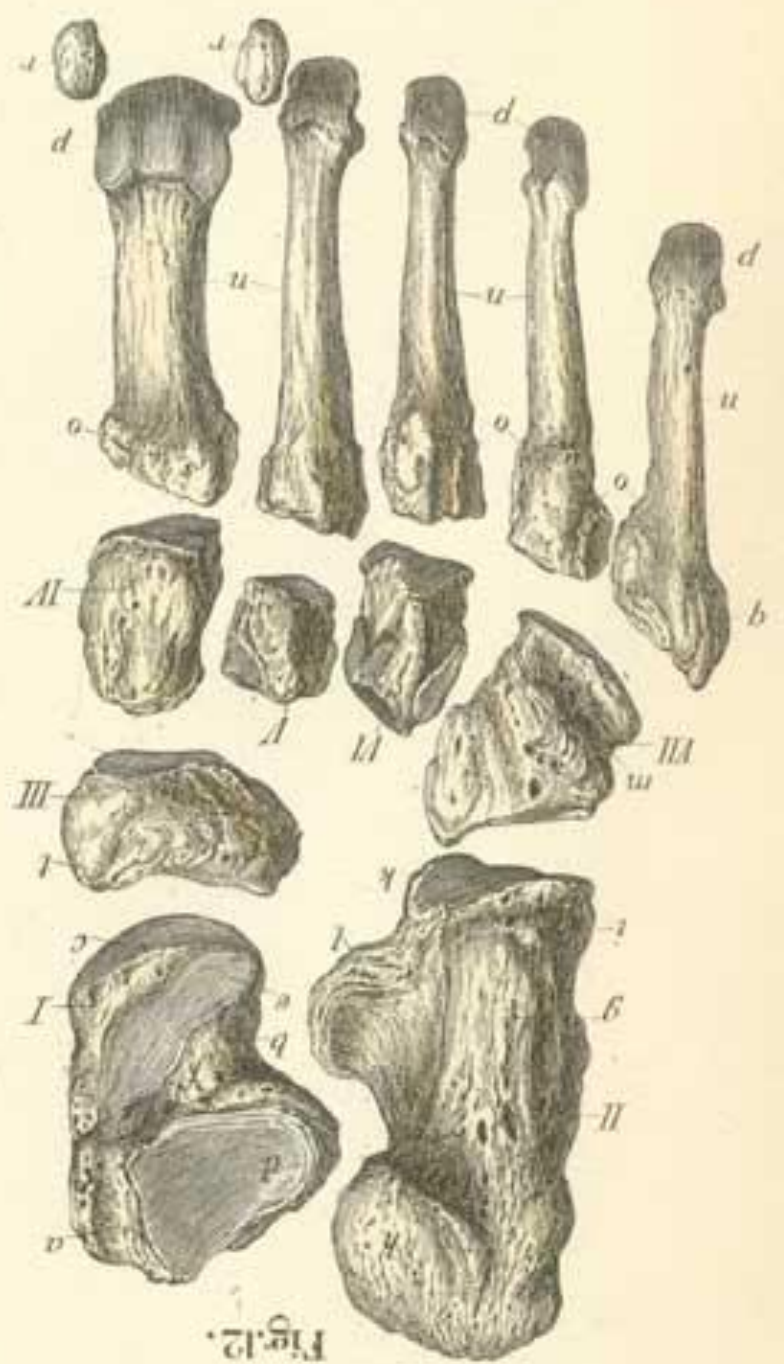
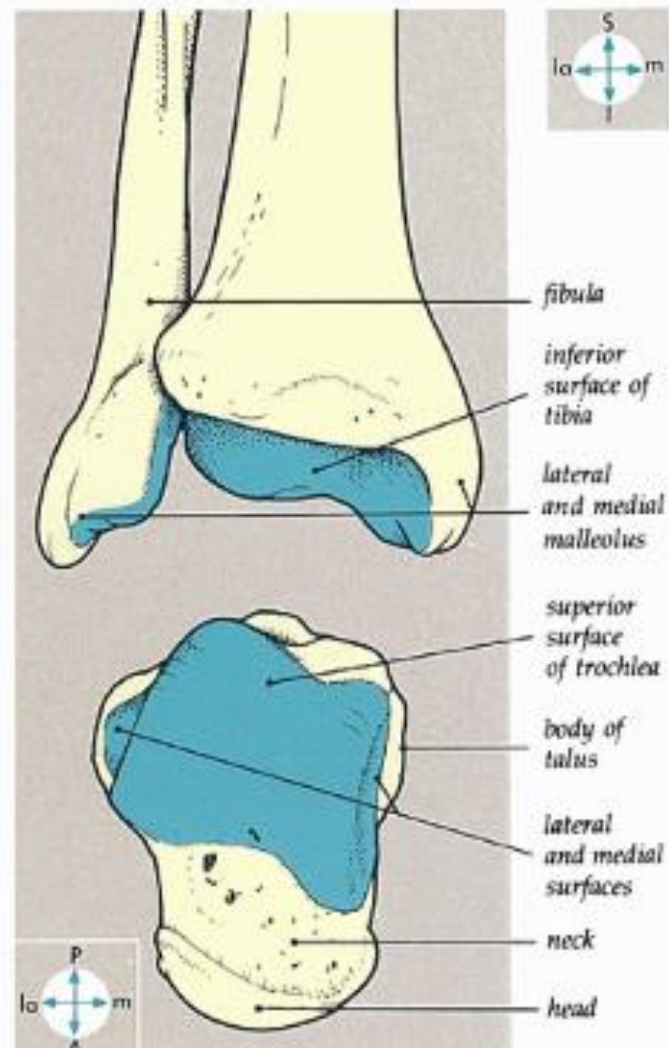
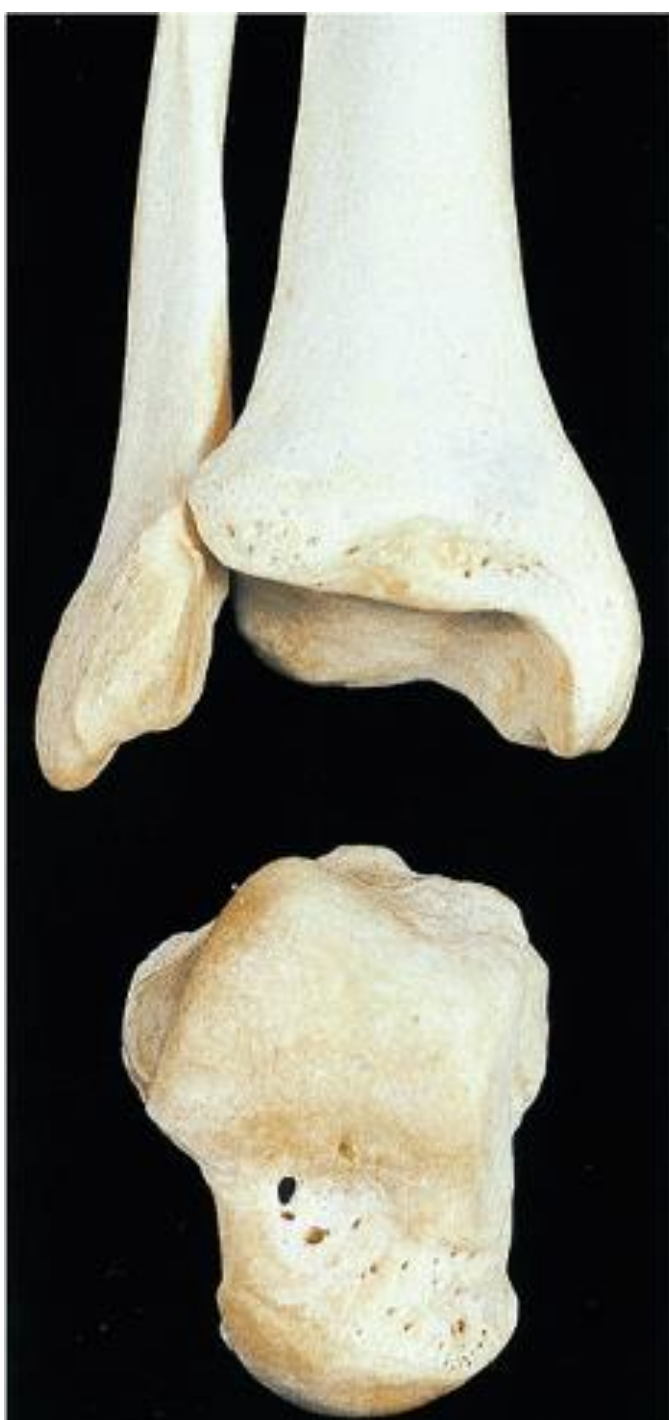


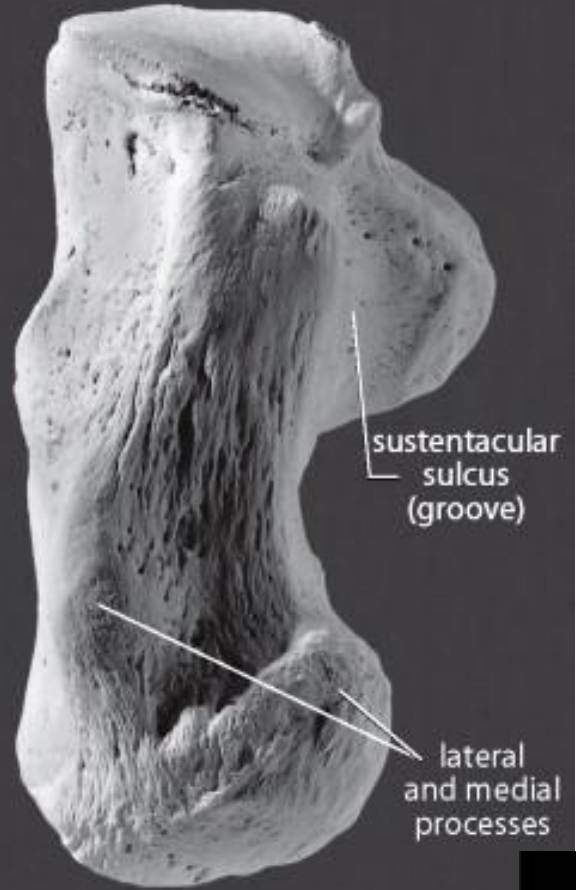
Fig. 12.





calcaneal  
tuber

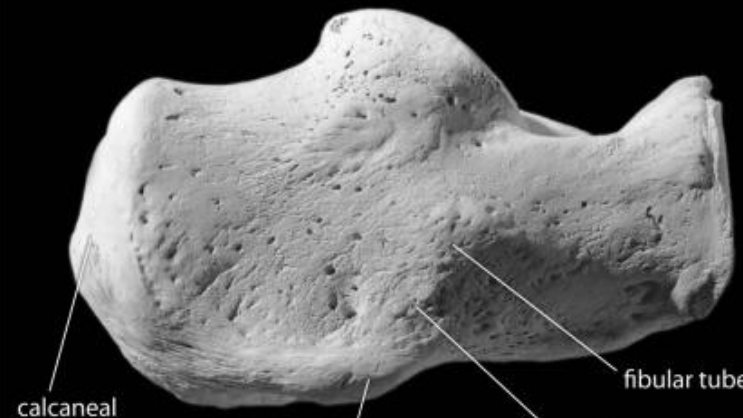
DORSAL (SUPERIOR)



sustentacular  
sulcus  
(groove)

lateral  
and medial  
processes

PLANTAR (INFERIOR)

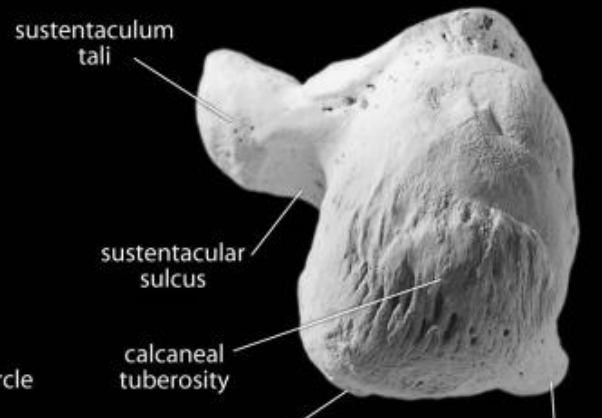


calcaneal  
tuberosity

lateral process of the  
calcaneal tuberosity

groove for  
*fibularis longus*

fibular tubercle



sustentaculum  
tali

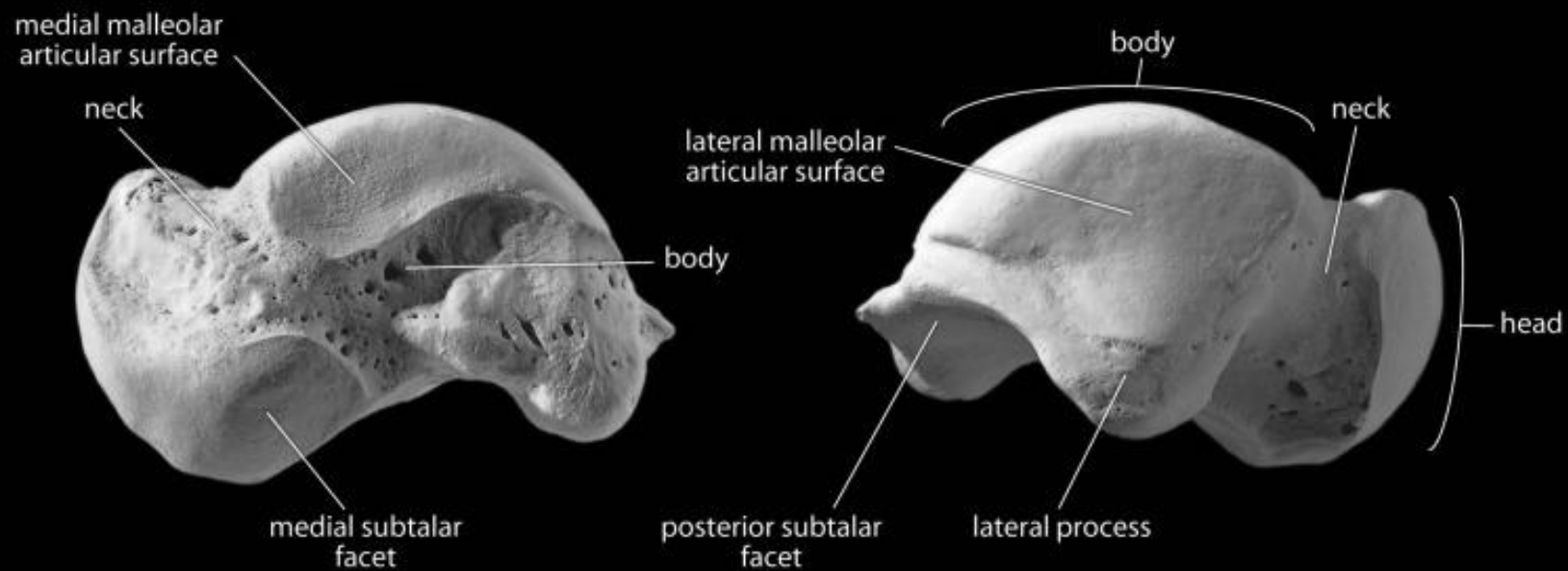
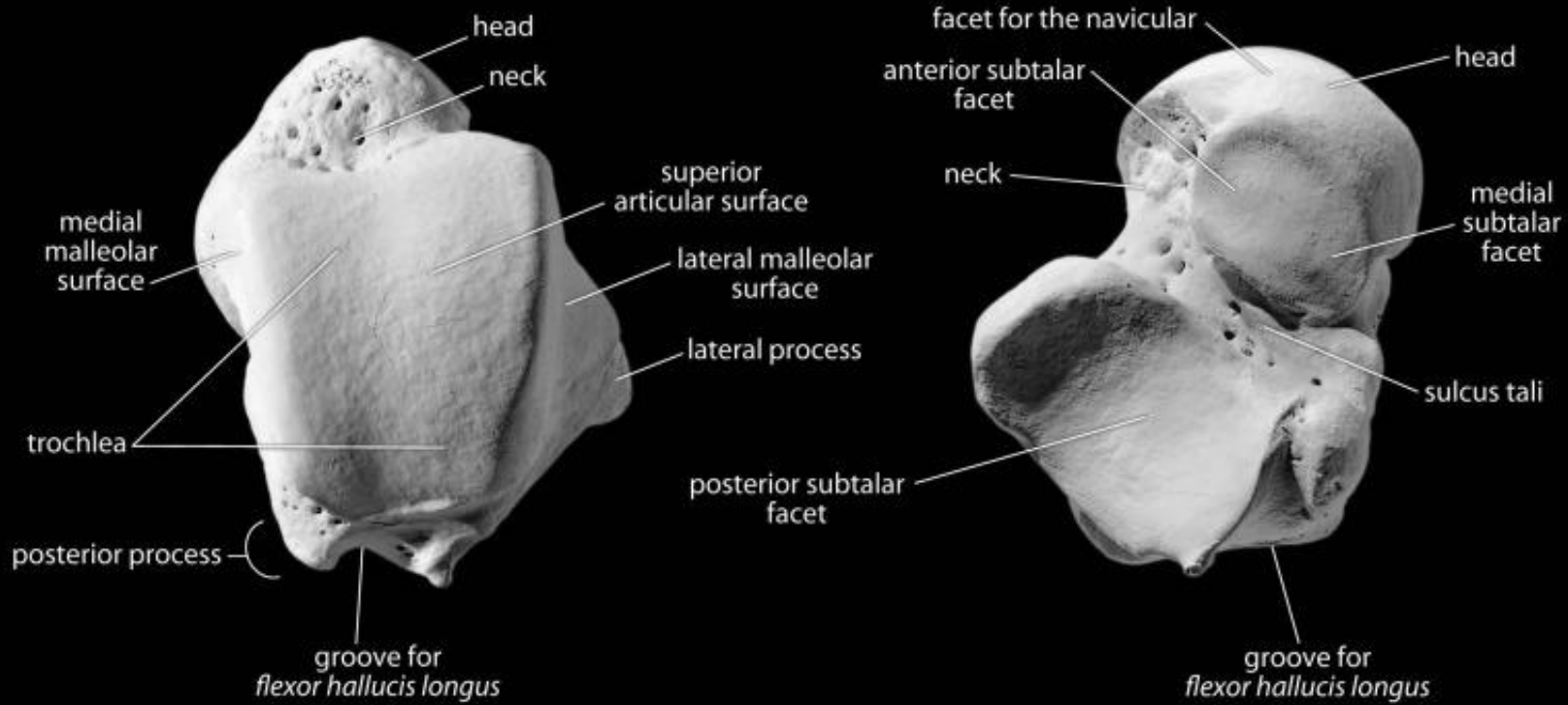
sustentacular  
sulcus

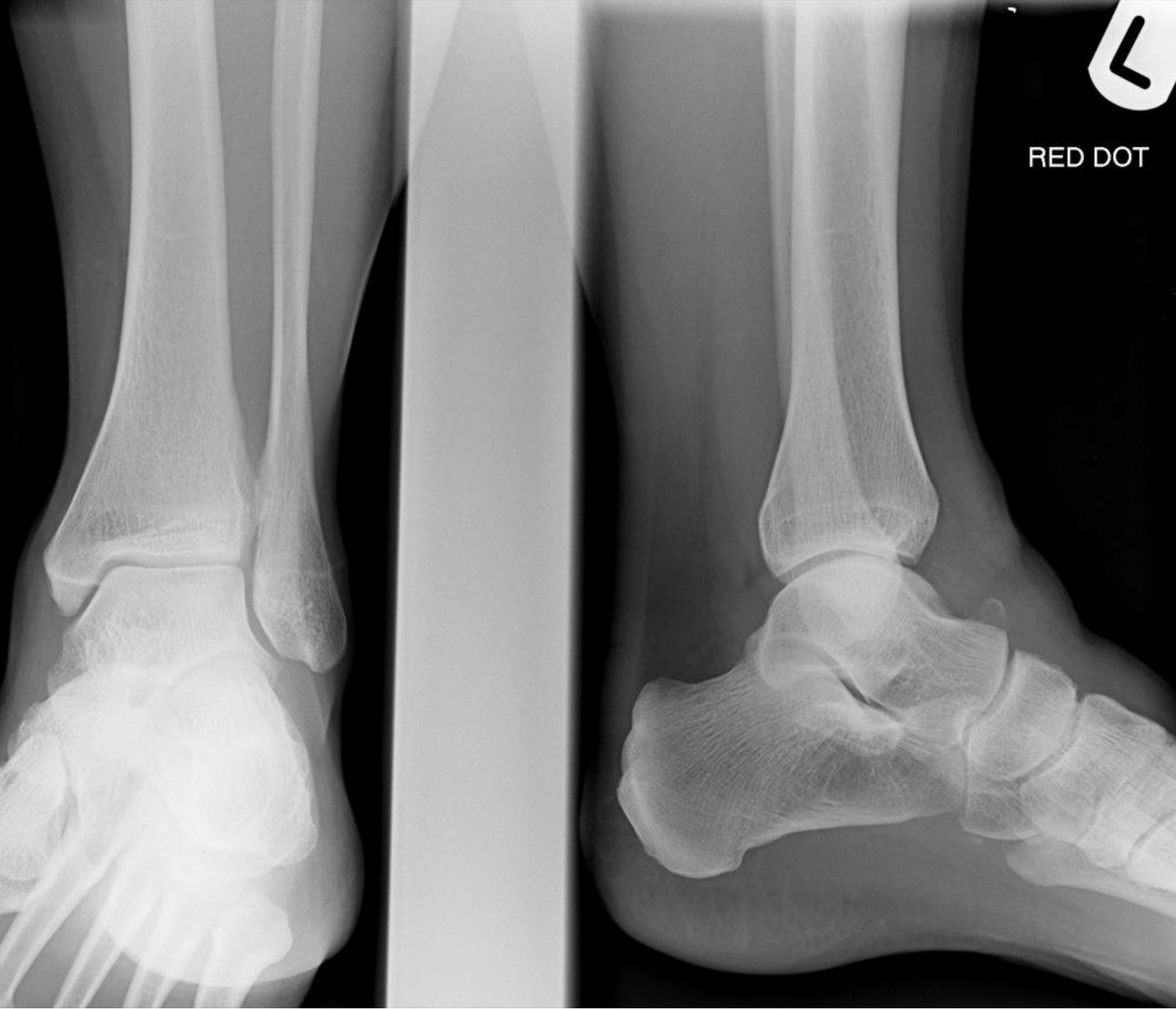calcaneal  
tuberosity

medial process of the  
calcaneal tuberosity


lateral process of the  
calcaneal tuberosity

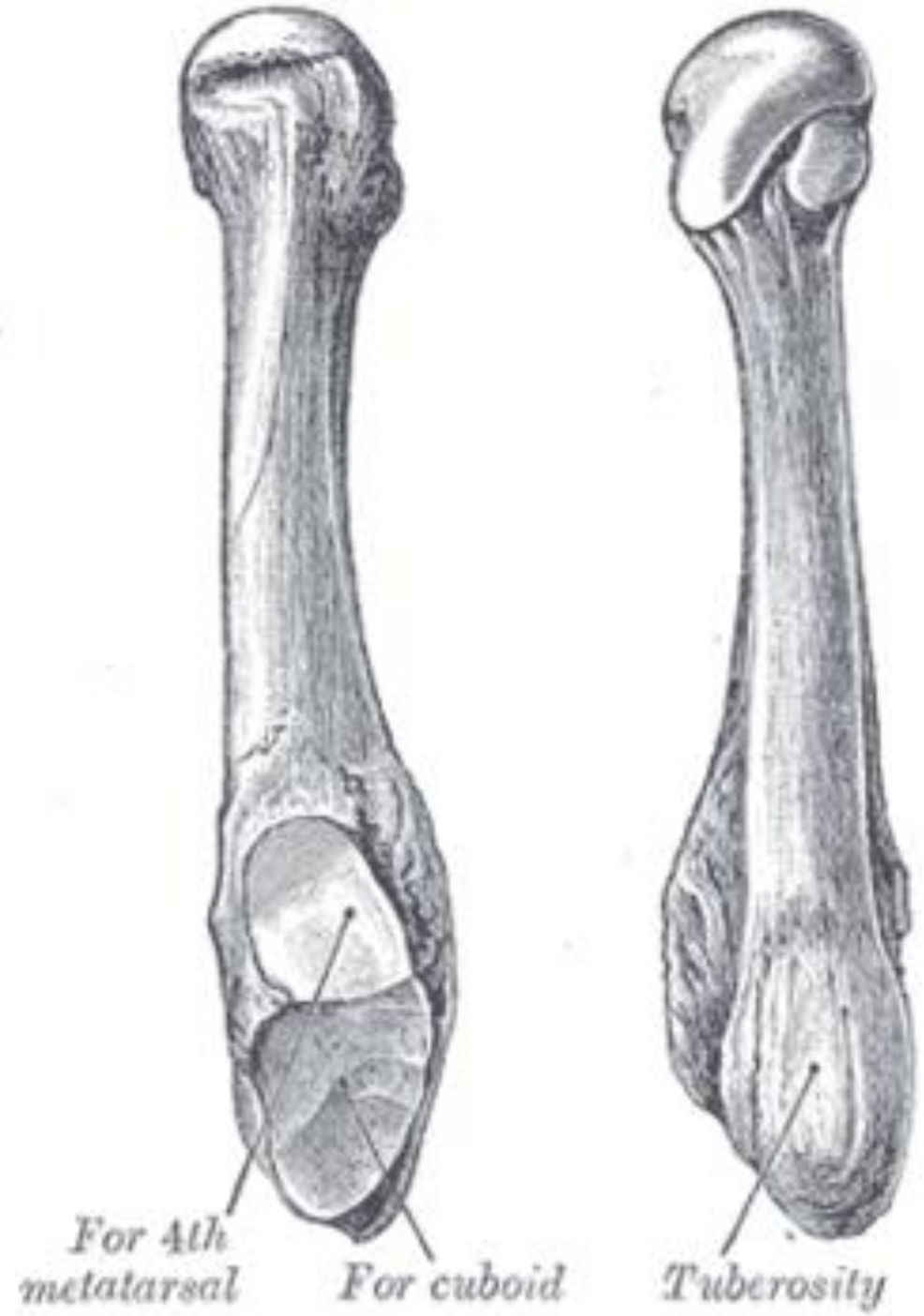
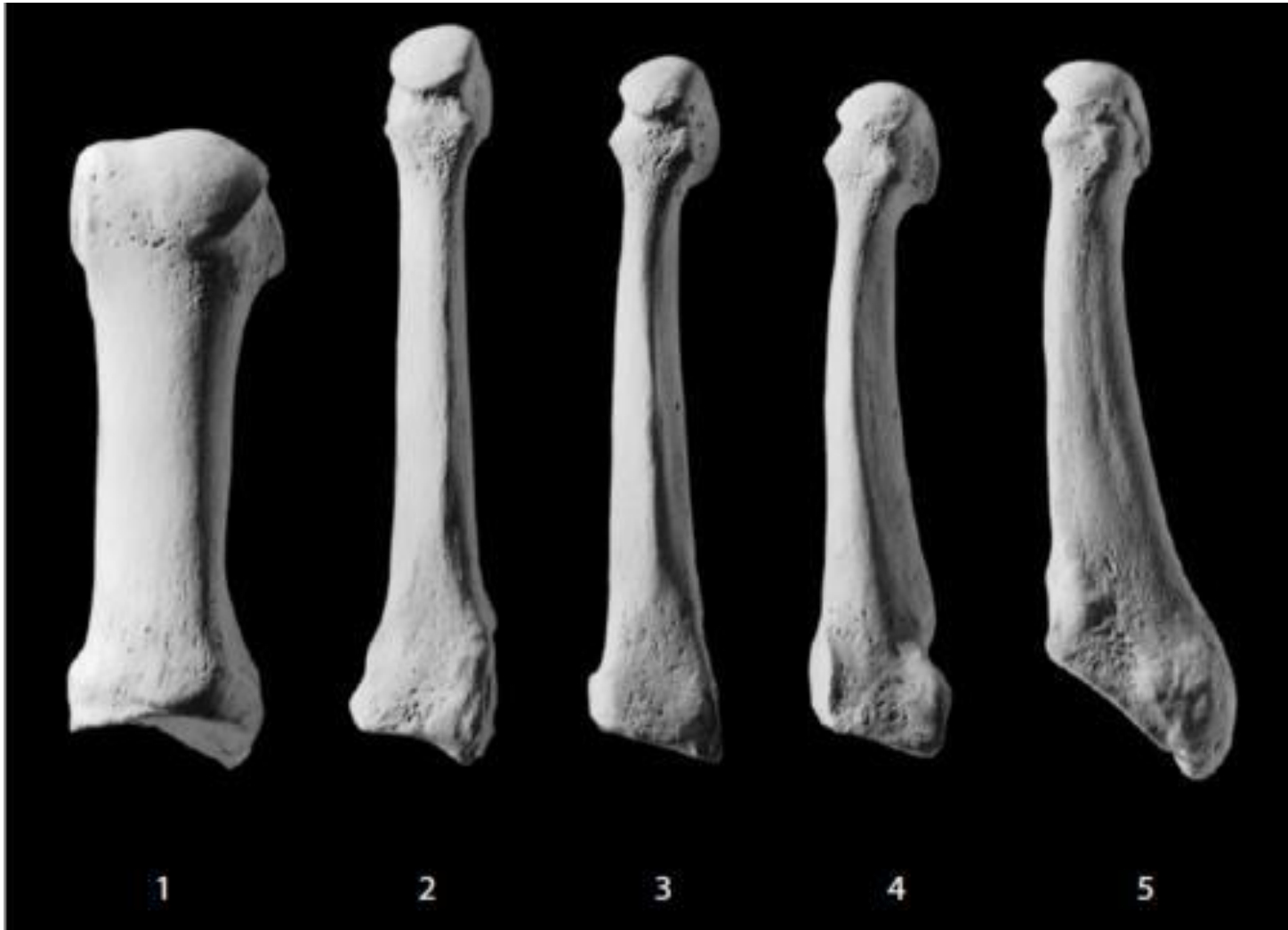




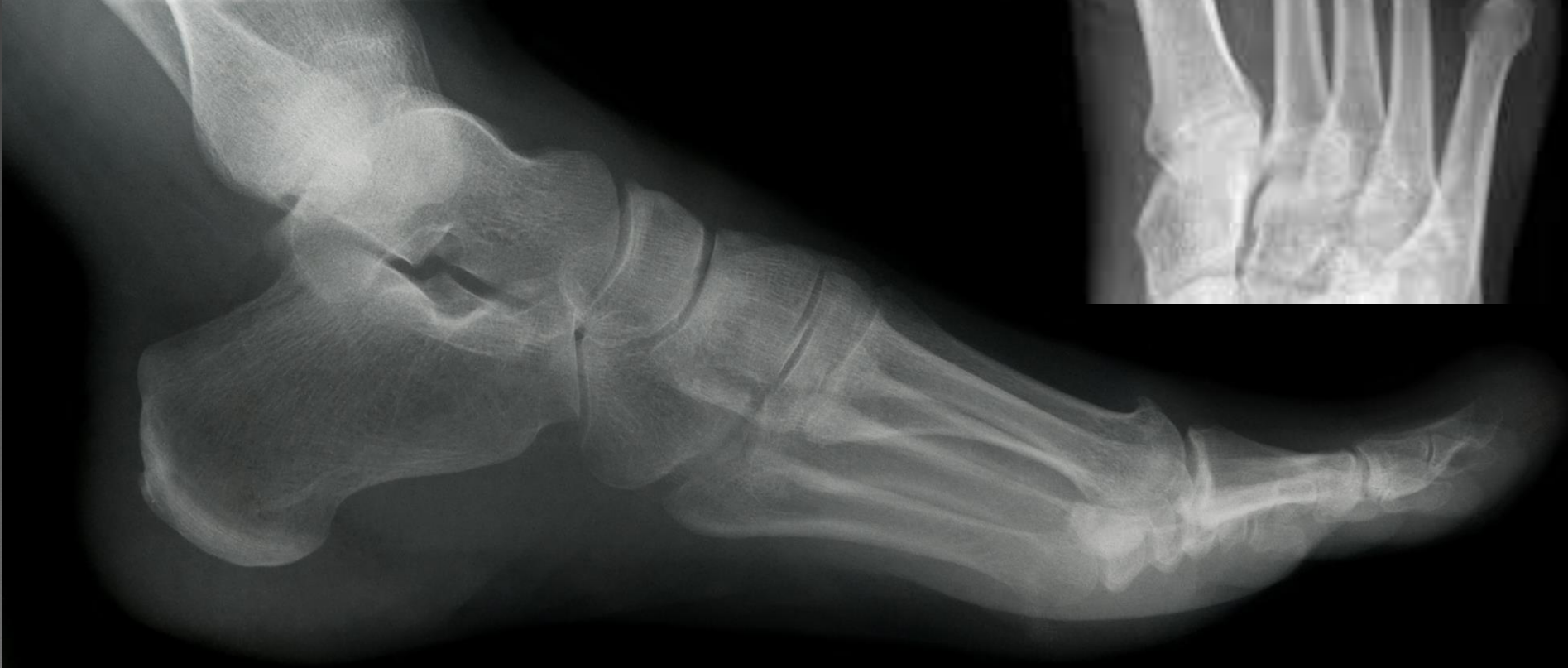
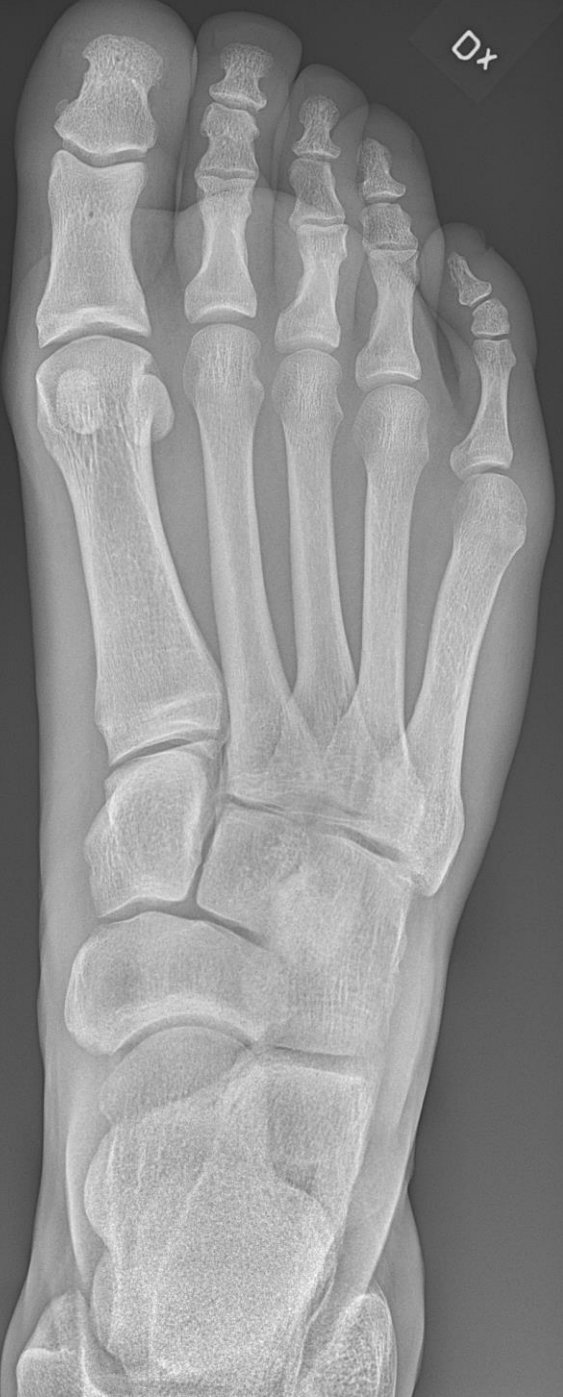RED DOT

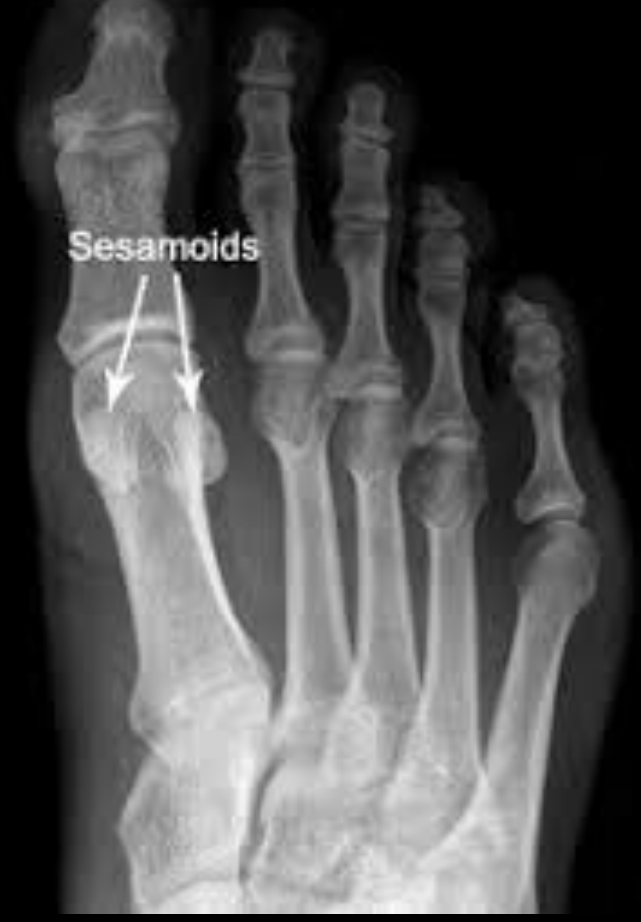


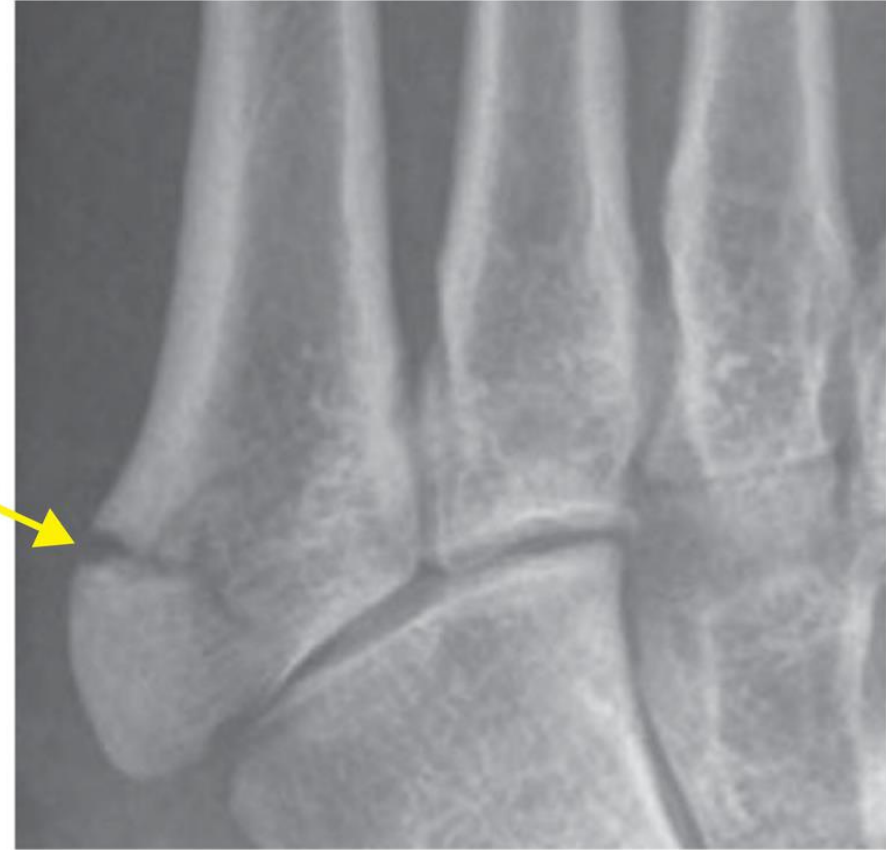
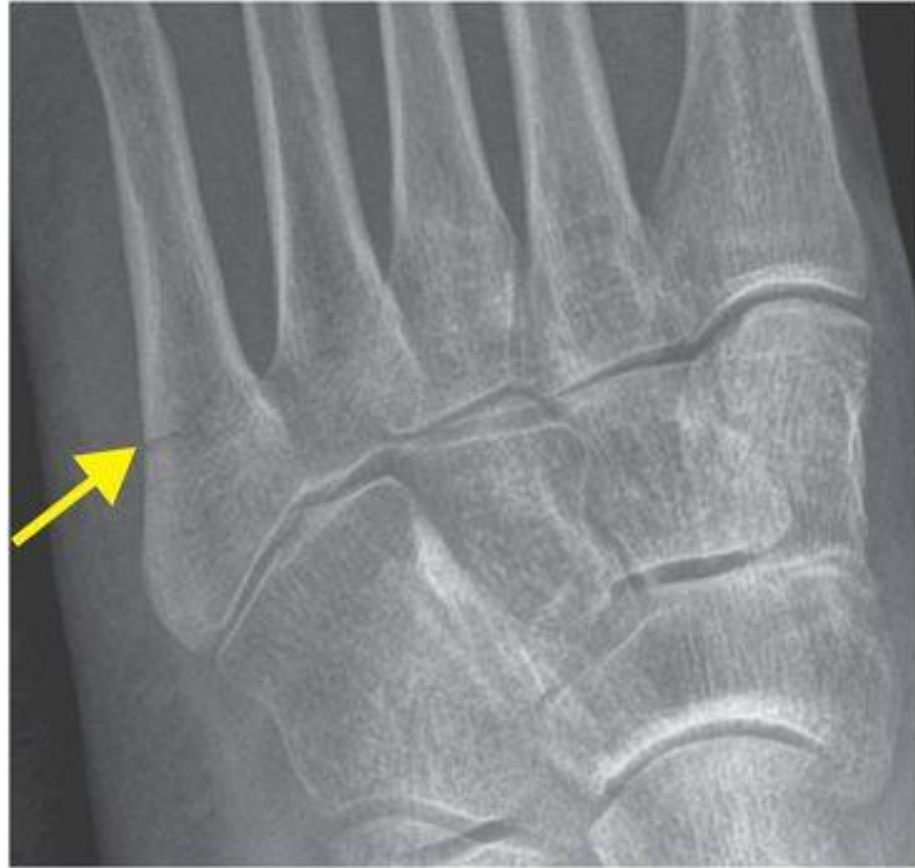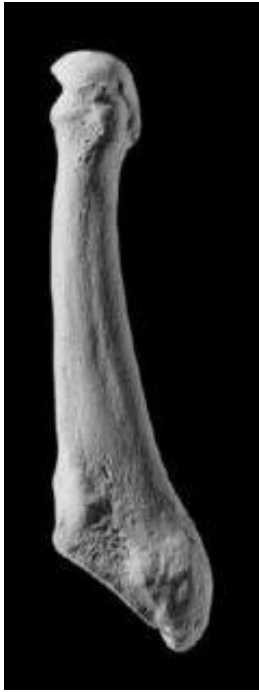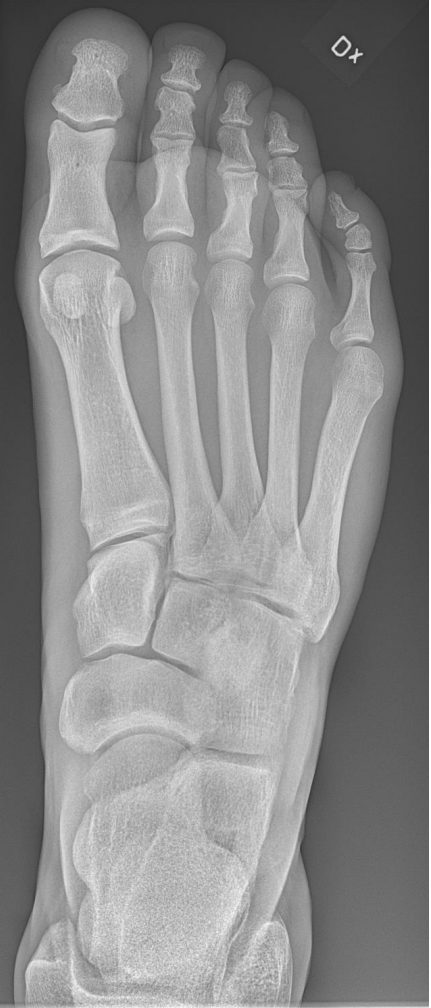Dx



Sesamoids





What is it???

