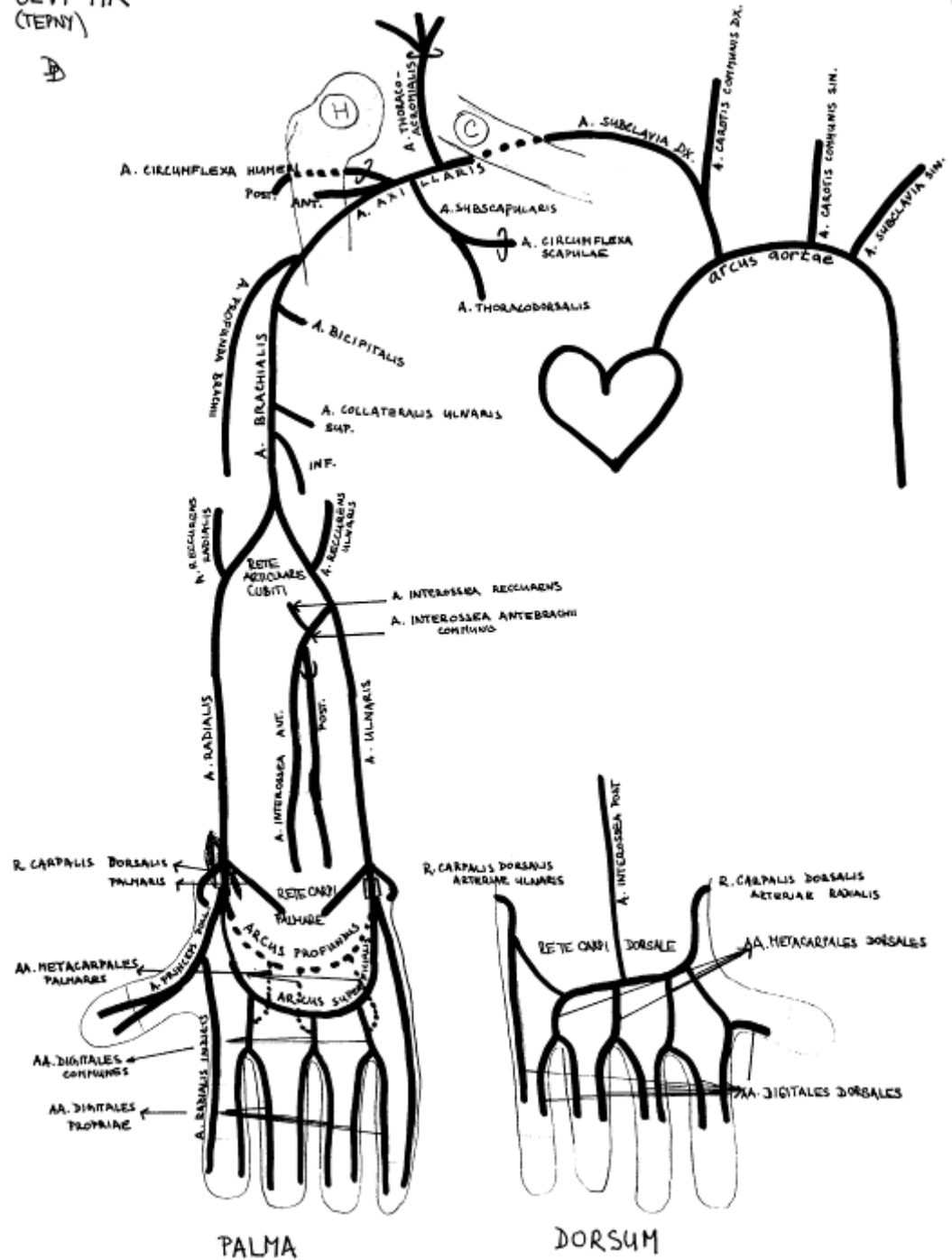


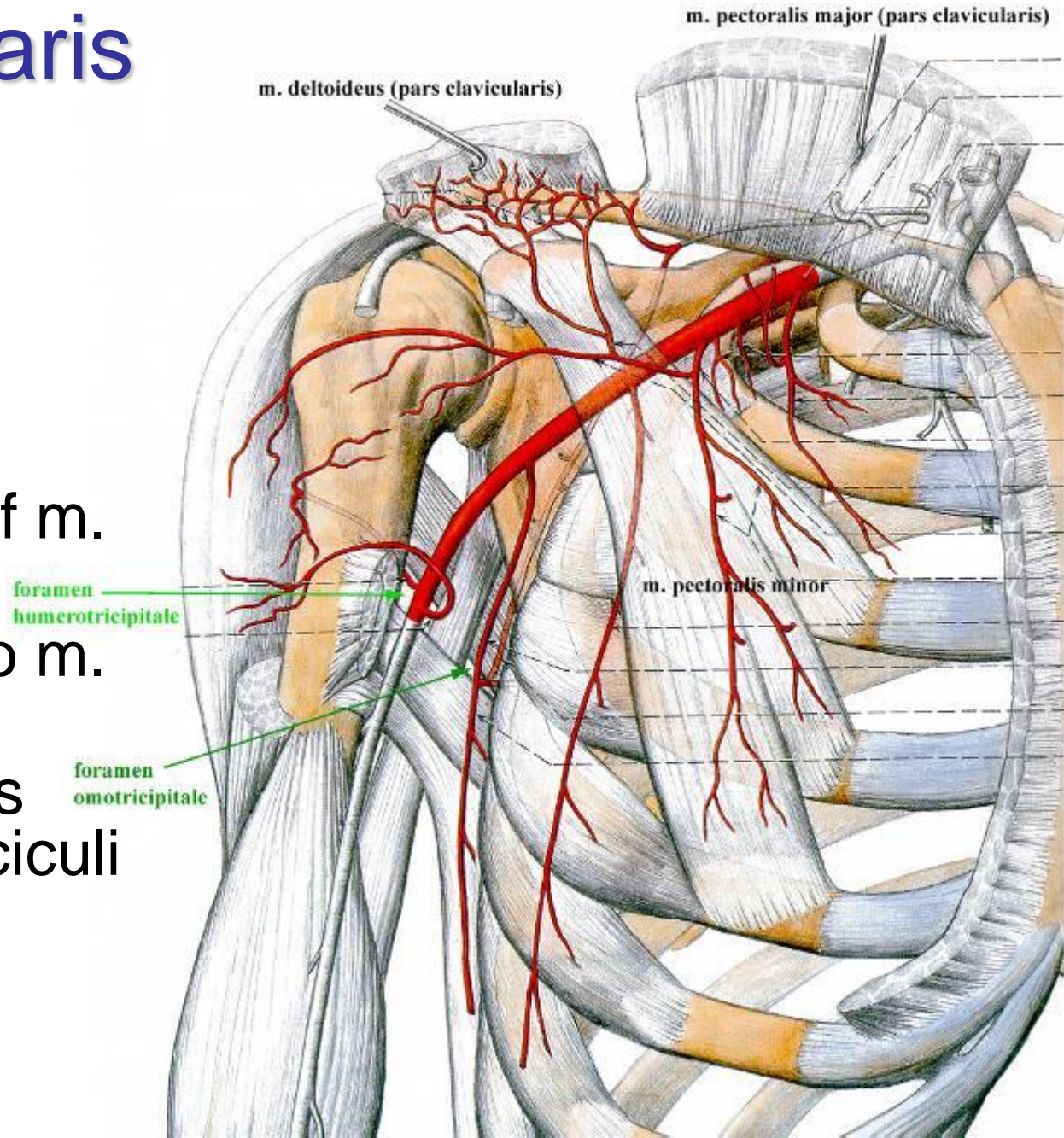
CEVY HK  
(TEPNY)

# Arteries of upper limbs



## Arteria axillaris

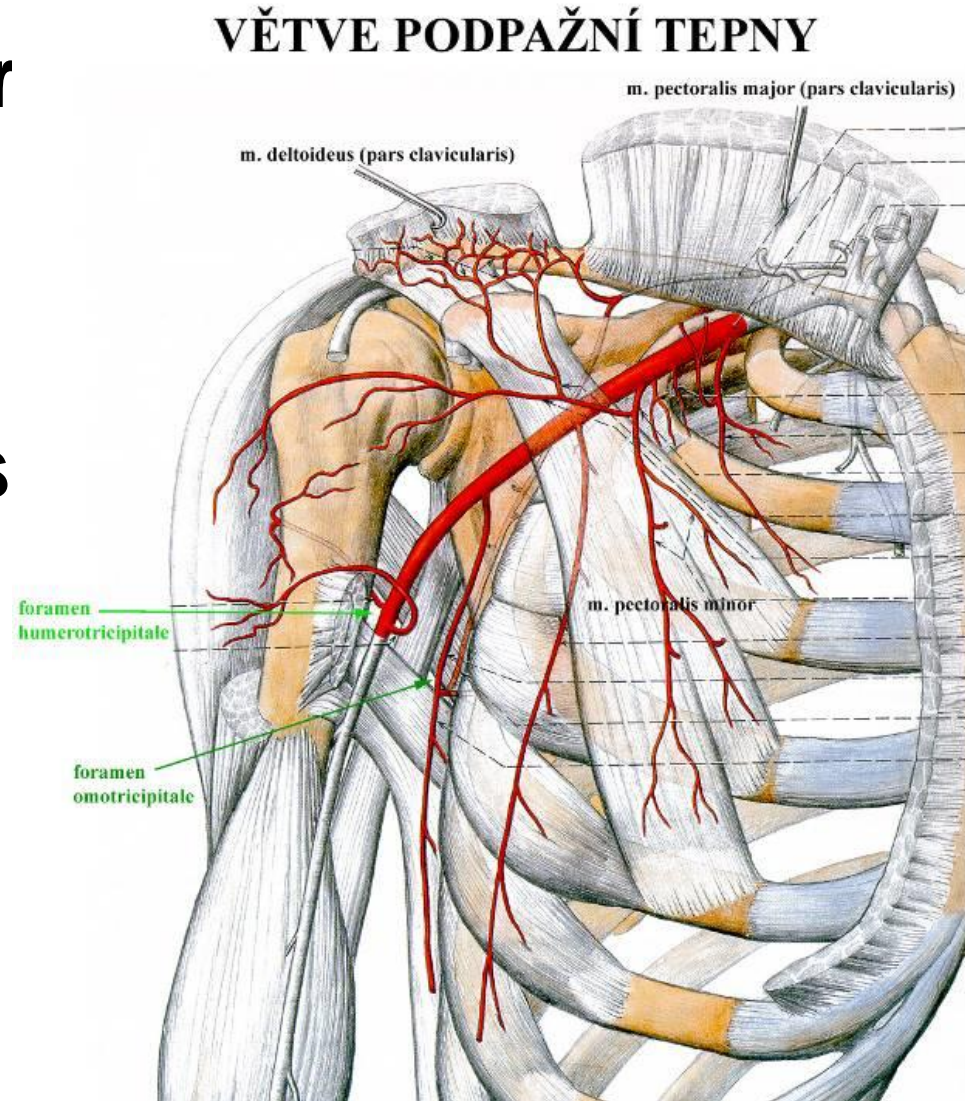
- origin: from a. subclavia to clavícula
- end: collum chirurgicum = inferior margin of m. pectoralis major
- 3 parts related to m. pectoralis minor
- division of plexus brachialis in fasciculi
- bifurcation of n. medianus



# Arteria axillaris – branches from 1st part

## pars suprapectoralis:

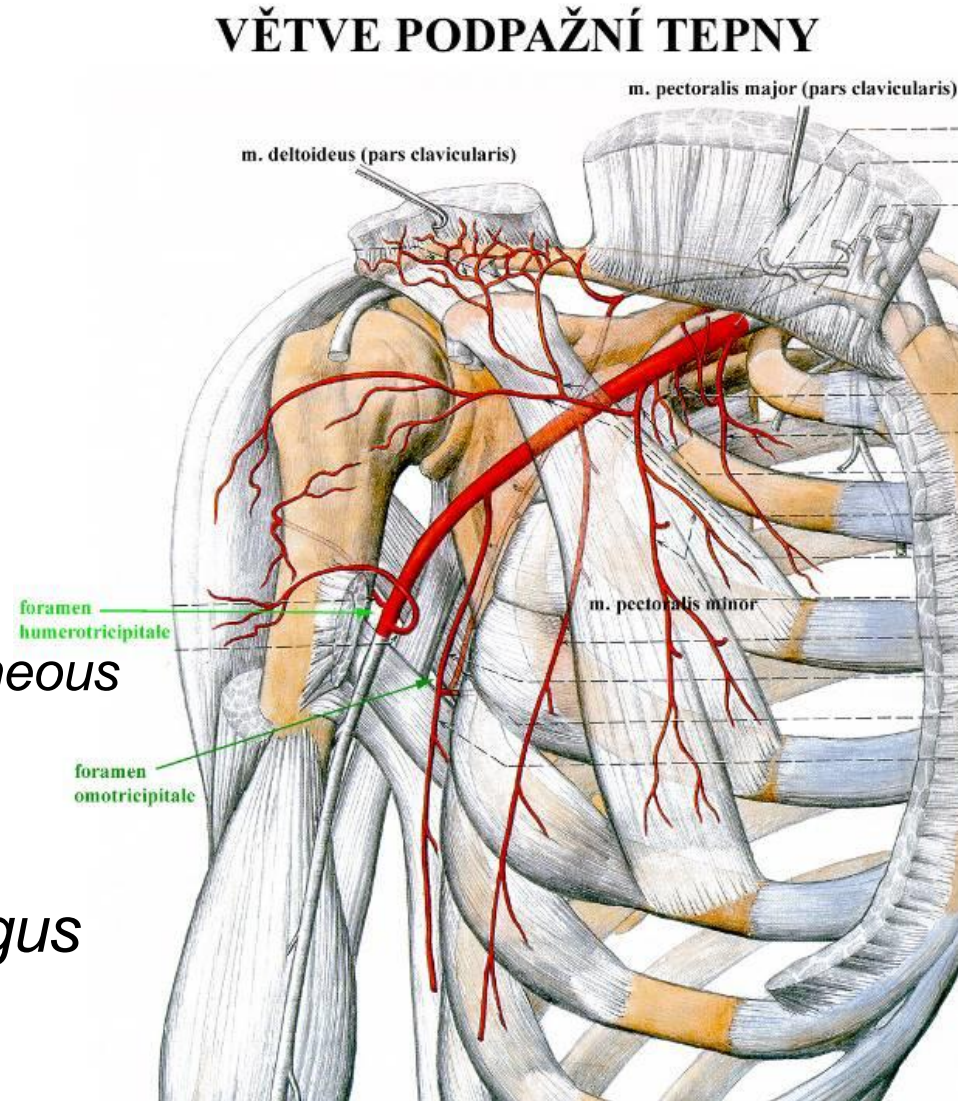
- **a. thoracica superior**
  - *variable caliber*
  - *for upper intercostal spaces*
- **a. thoracoacromialis**
  - rr. pectorales
  - r. acromialis
  - r. deltoideus
  - r. clavicularis
- **rr. subscapulares**  
(*for m. subscapularis*)



# Arteria axillaris – branches from 2nd part

## pars retropectoralis:

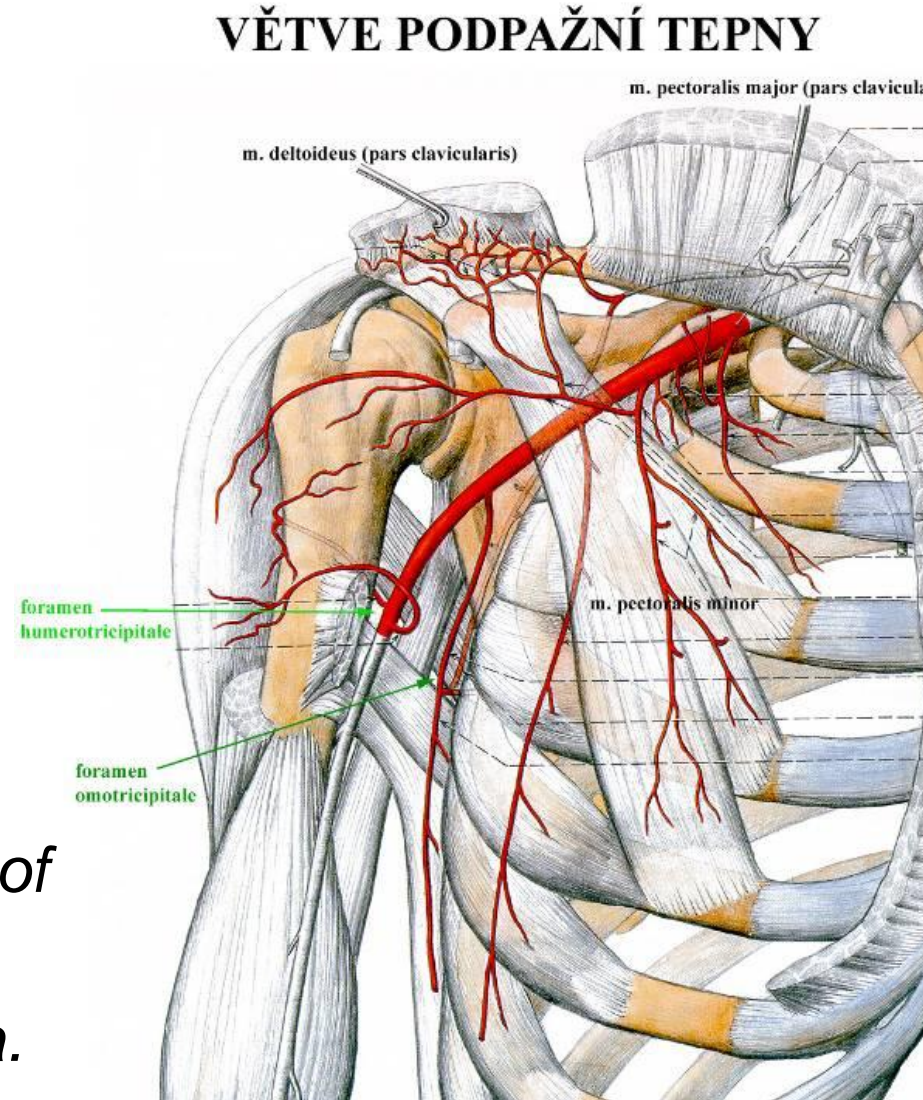
- **a. subscapularis** – *short and thick*
  - a. circumflexa scapulae
    - *foramen omotricipitale*
  - a. thoracodorsalis
    - *runs with n. thoracodorsalis*
    - *muscular and musculo-cutaneous flap of m. latissimus dorsi*
- **a. thoracica lateralis**
  - *runs with n. thoracicus longus in periphery*
  - for m. serratus anterior



# Arteria axillaris – branches from 3rd part

## pars infrapectoralis:

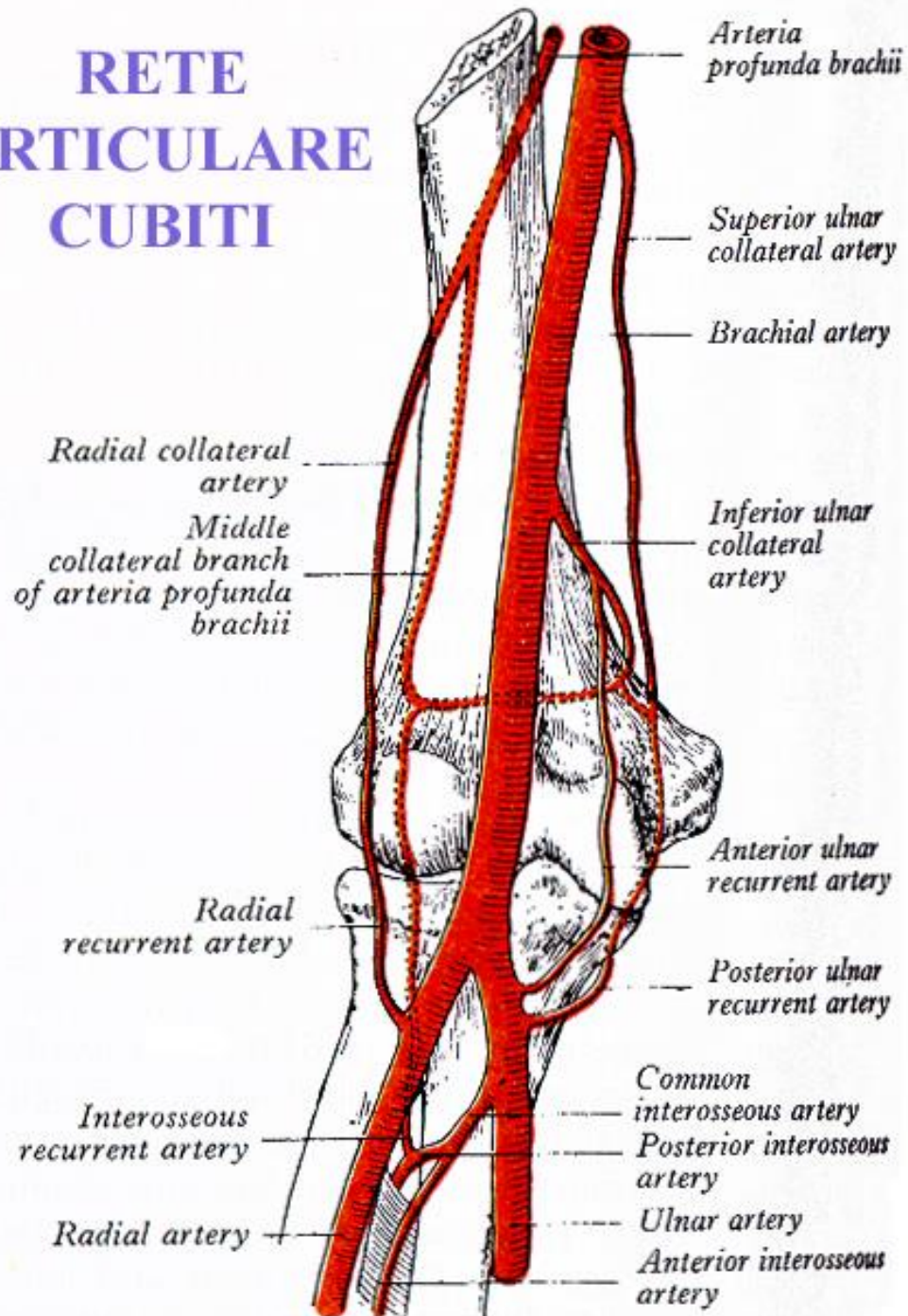
- **a. circumflexa humeri ant.** – *thin*
- **a. circumflexa humeri post.**
  - *around collum chirurgicum humeri*
  - *foramen humerotricipitale*
  - *danger of injury in fractures of collum chirurgicum humeri*
  - *in 10% common trunk with a. profunda brachii*



# Arteria brachialis

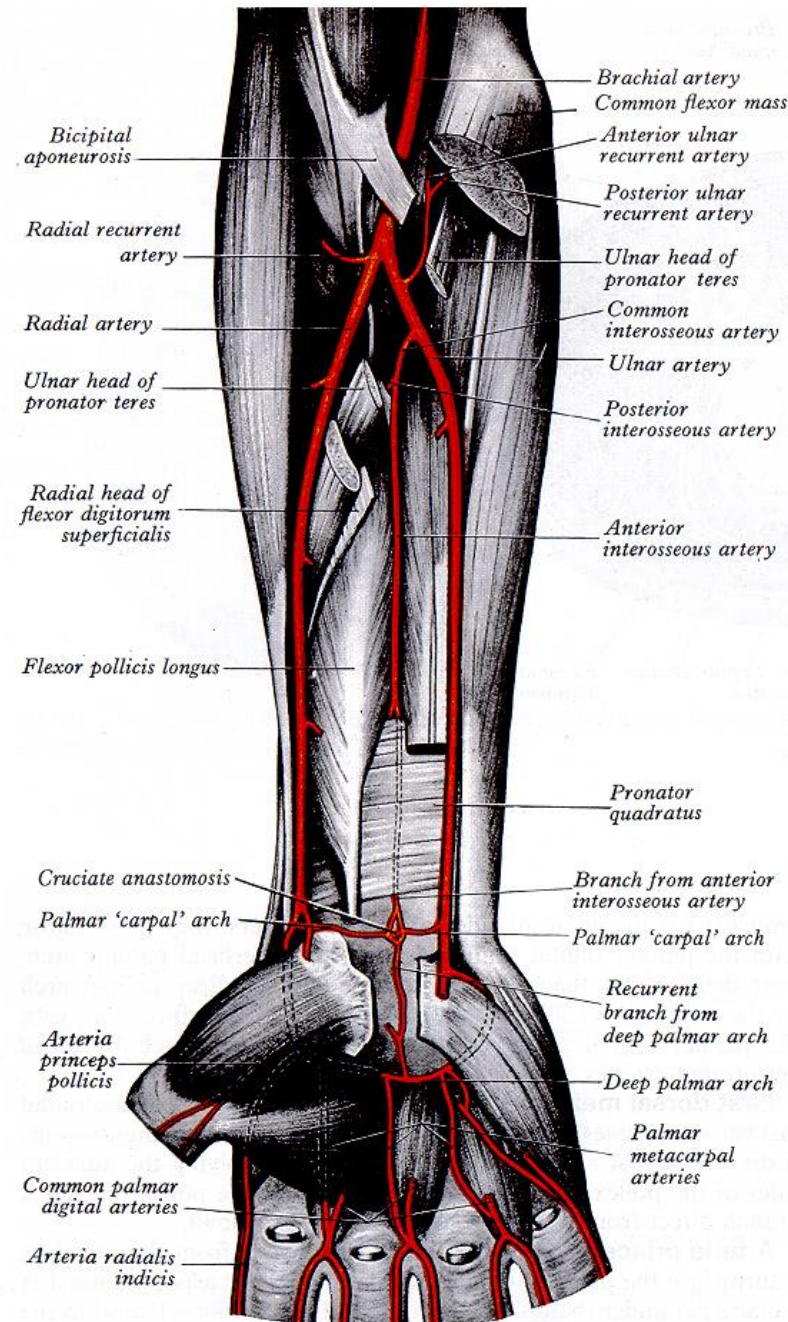
- collateral circulation
- rete articulare cubiti
- septum intermusculare mediale brachii
- blood pressure measurement (proximal to fossa cubitalis)
- catheterization site (proximal to fossa cubitalis)
- variation: a. brachioradialis superficialis (3-14%)

## RETE ARTICULARE CUBITI

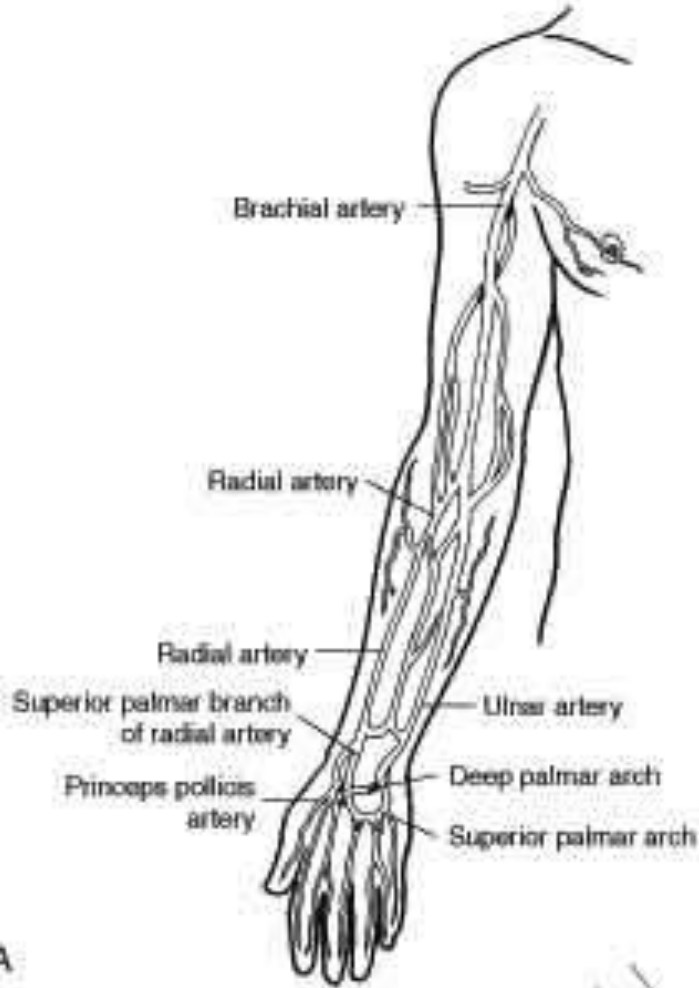


## Arteria radialis

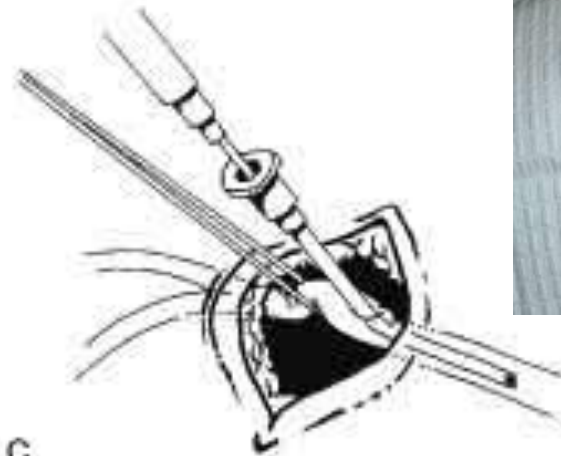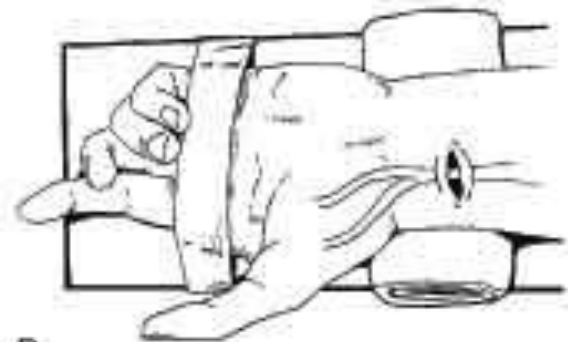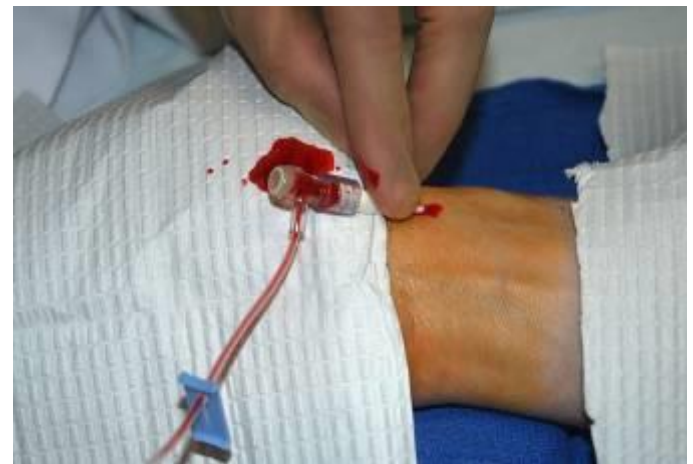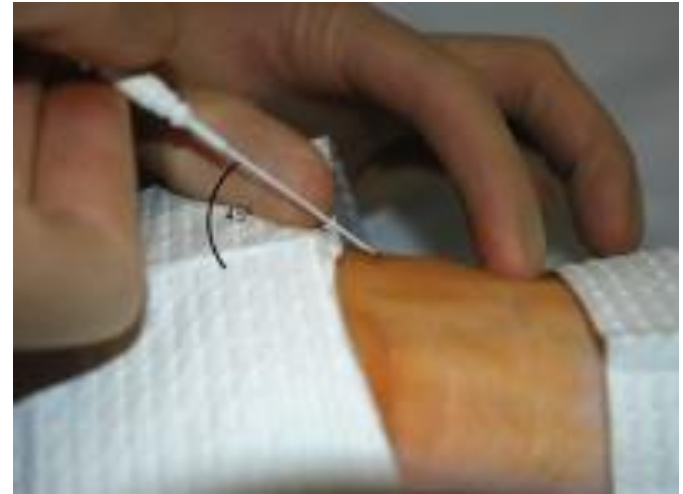- fossa cubitalis
- foveola radialis
- Guiot's space
- pulse measurement (proximal to carpus)
- catheterization site (proximal to carpus)
- measurement of pH, pO<sub>2</sub>, pCO<sub>2</sub> = *Astrup*
- high clinical relevance of variations (22%)
- ↓ *atherosclerosis*,
- ↑ *mediocalcinosis*



# Radial catheterization



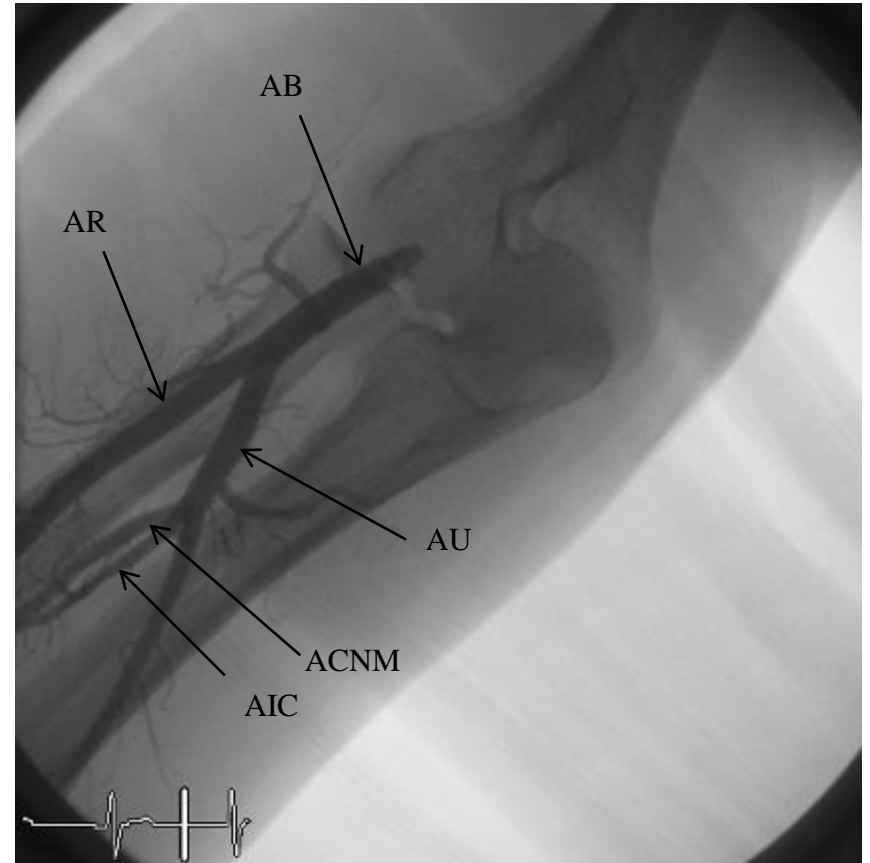
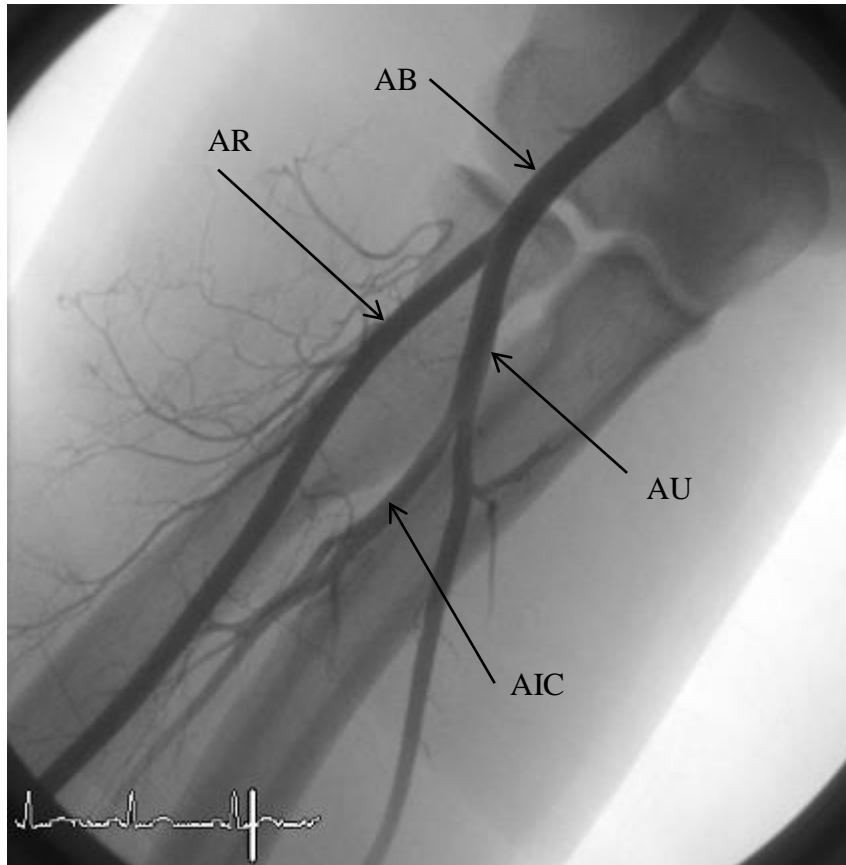
A



C

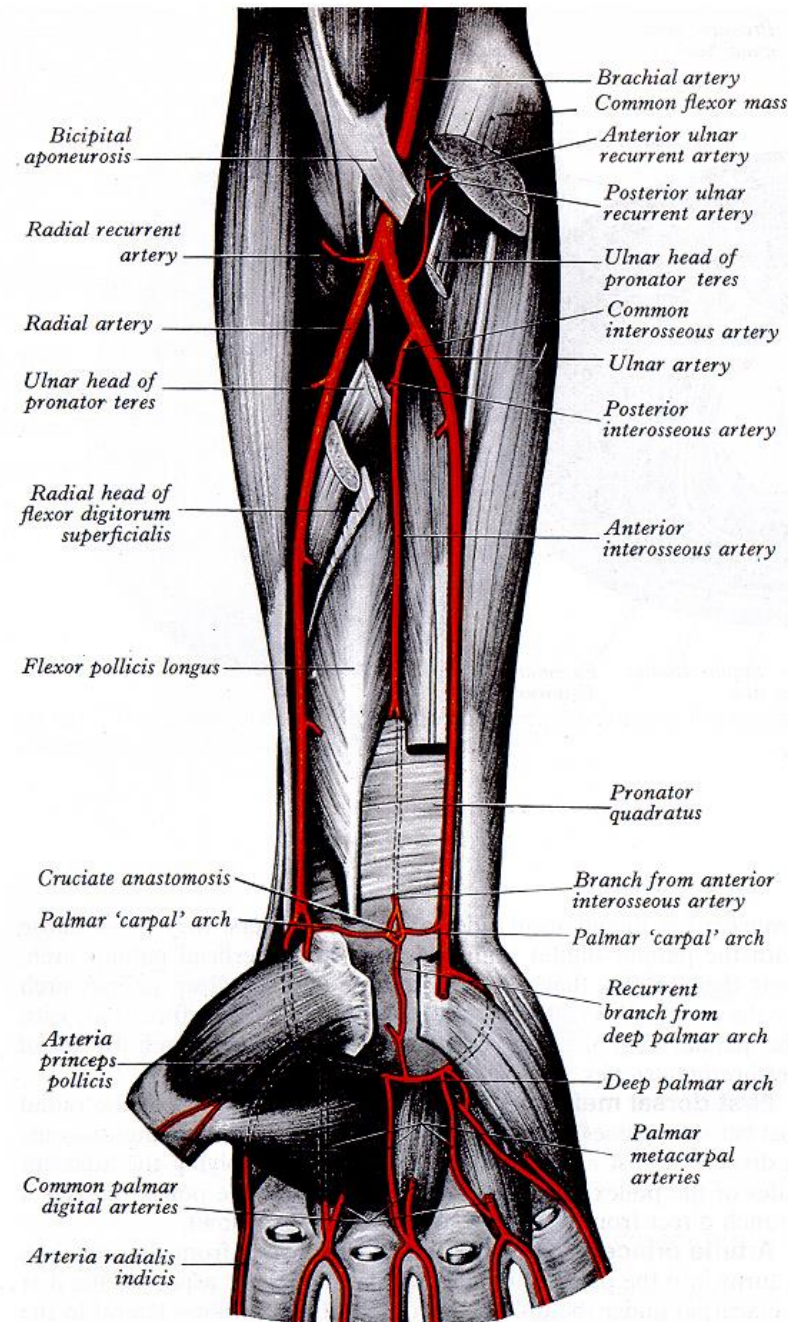


# Angiography of forearm arteries - norm



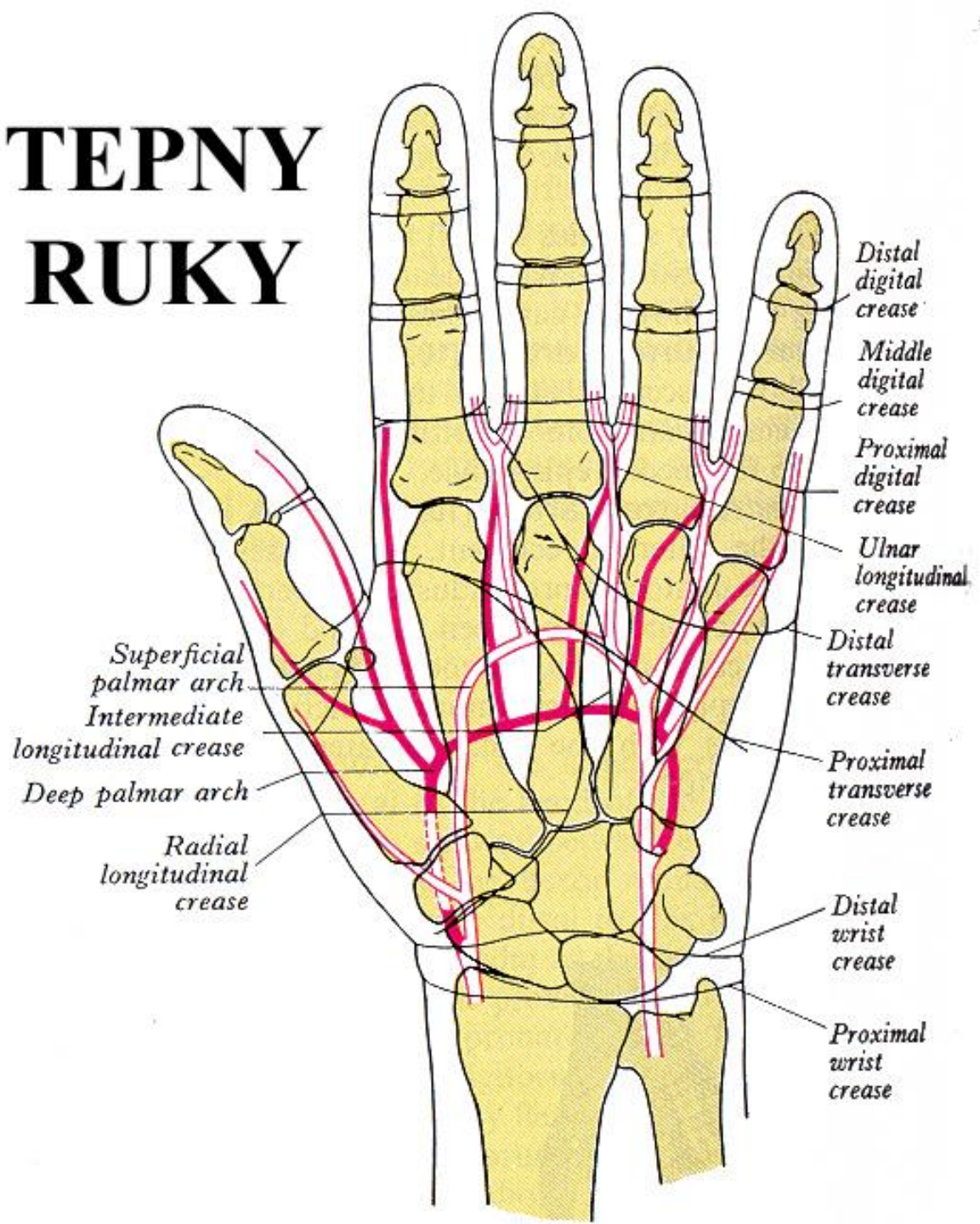
## Arteria ulnaris

- fossa cubitalis
- canalis ulnaris Guyoni
- runs with n. ulnaris
- catheterization site (proximal to carpus)
- low clinical relevance of variations (3%)
- ↓ *atherosclerosis*
- ↑ *mediocalcinosis*

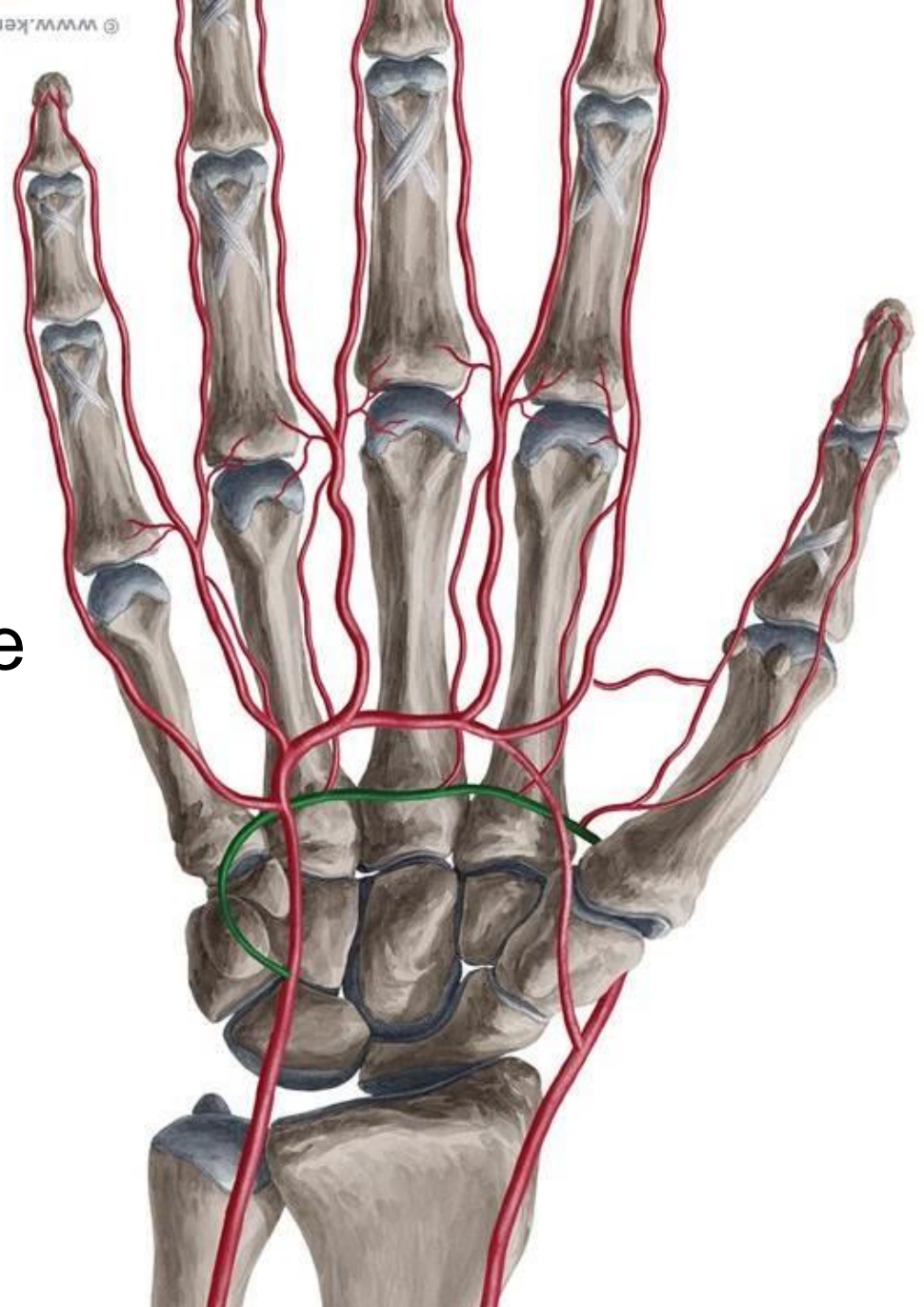


# TEPNY RUKY

- arcus palmaris superficialis
- arcus palmaris profundus
- rete carpi dorsale



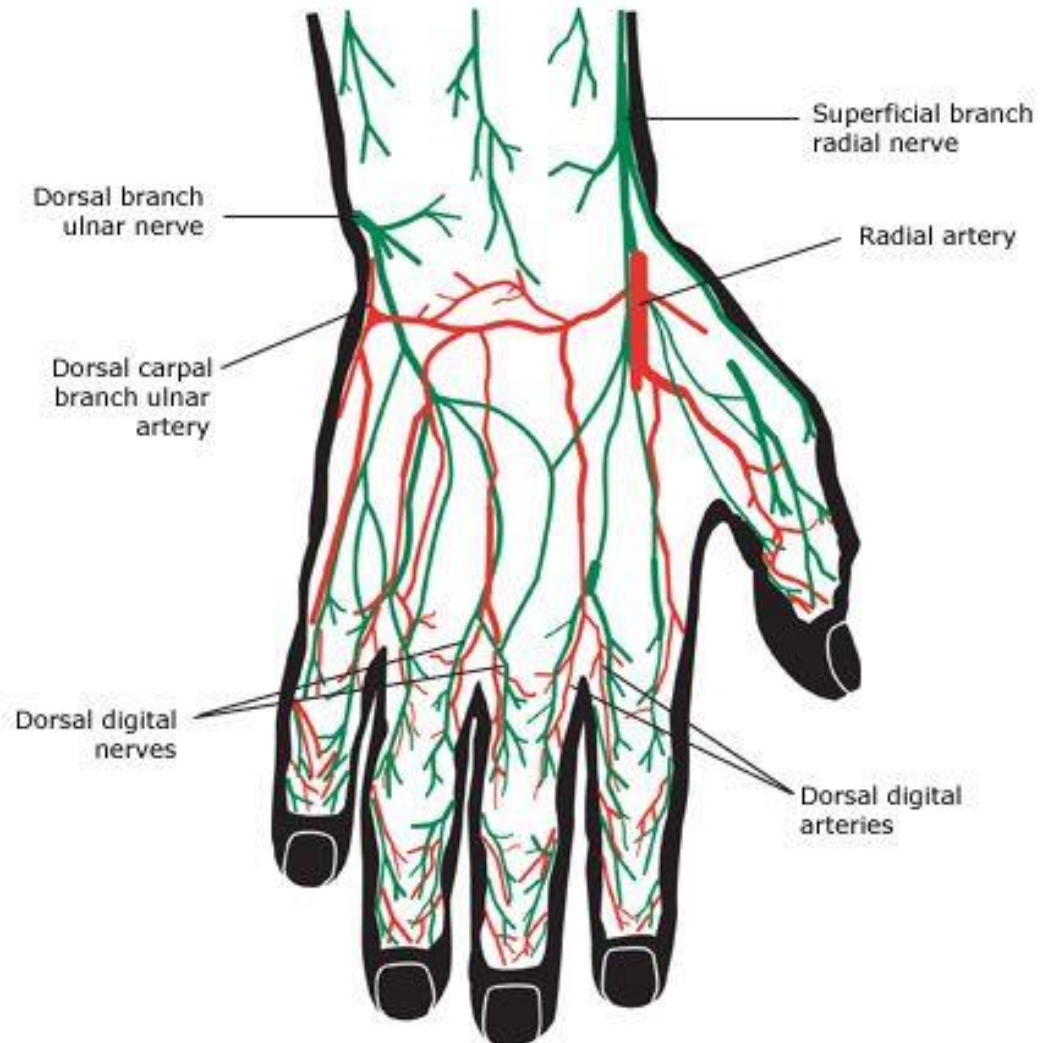
# Palm



- arcus palmaris **superficialis** → aa. **digitales palmares communes** → propriae
- arcus palmaris **profundus** → aa. **metacarpales palmares** → merge distally with aa. **digitales palmares communes**

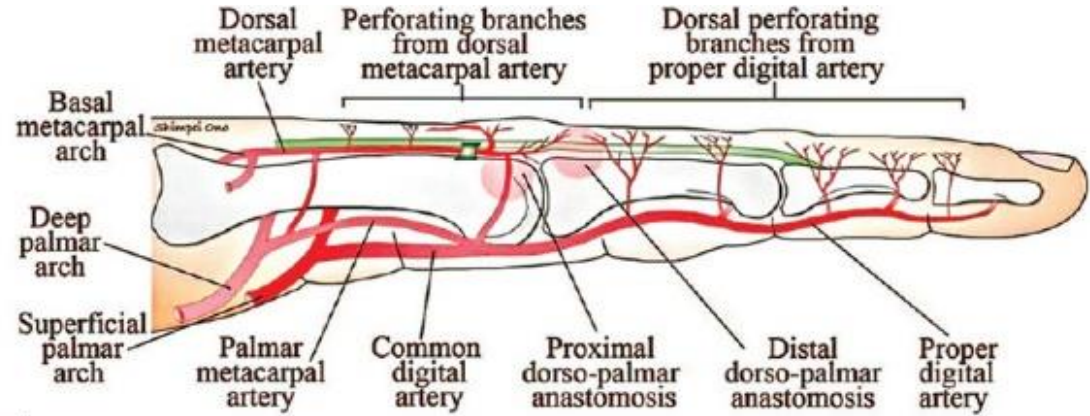
# Rete carpi dorsale

- a. radialis →  
r. carpalis dorsalis  
dorsalis
- a. radialis →  
r. carpalis dorsalis  
dorsalis
- **aa. metacarpales dorsales** → aa. digitales dorsales  
– to half of phalanx proximalis only

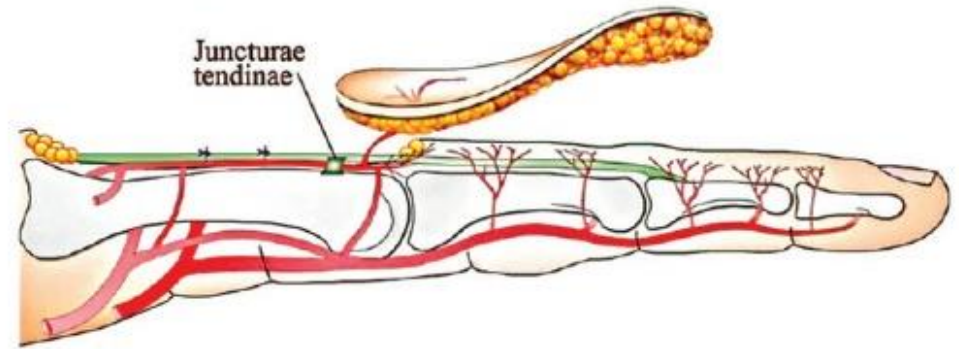


# Arteriae digitales

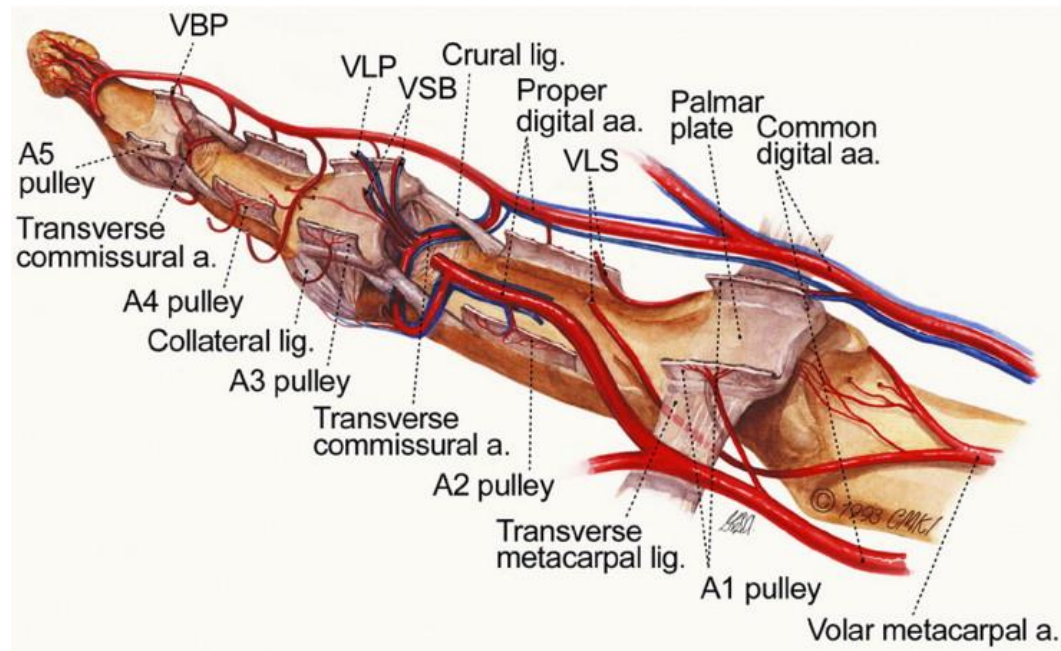
- a. digitalis palmaris propria radialis + ulnaris
- a. digitalis dorsalis
  - to half of phalanx proximalis only

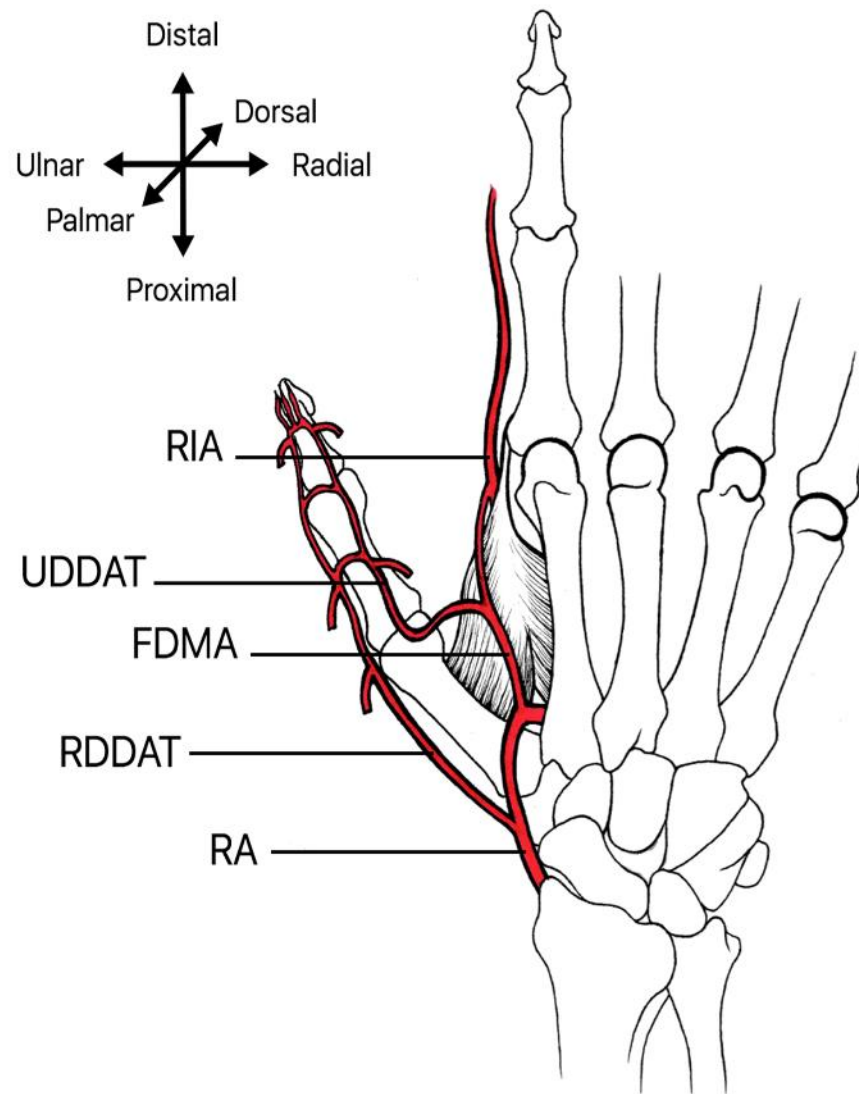
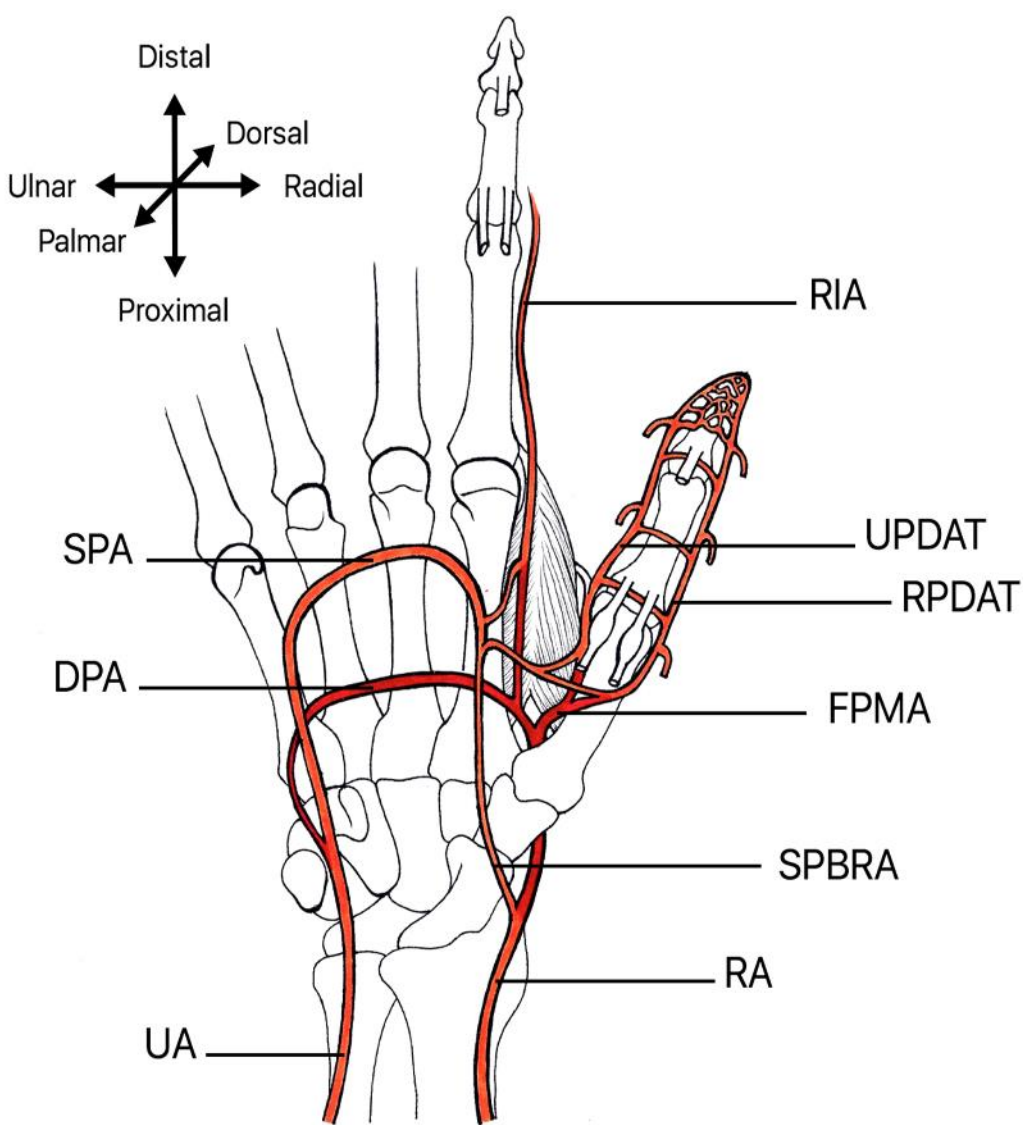


a



b





DPA – deep palmar arch, FDMA – first dorsal metacarpal artery, FPMA – first palmar metacarpal artery, RPDAT – radiopalmar digital artery of the thumb, UPDAT – ulnopalmar digital artery of the thumb, RA – radial artery, RIA – radialis indicis artery, RDDAT – radiodorsal digital artery of the thumb SPA – superficial palmar arch, SPBRA – superficial palmar branch of radial artery, UA – ulnar artery, UDDAT – ulnodorsal digital artery of the thumb

# Aorta

- aorta ascendens
- arcus aortae
- aorta descendens
  - pars thoracica
  - pars abdominalis

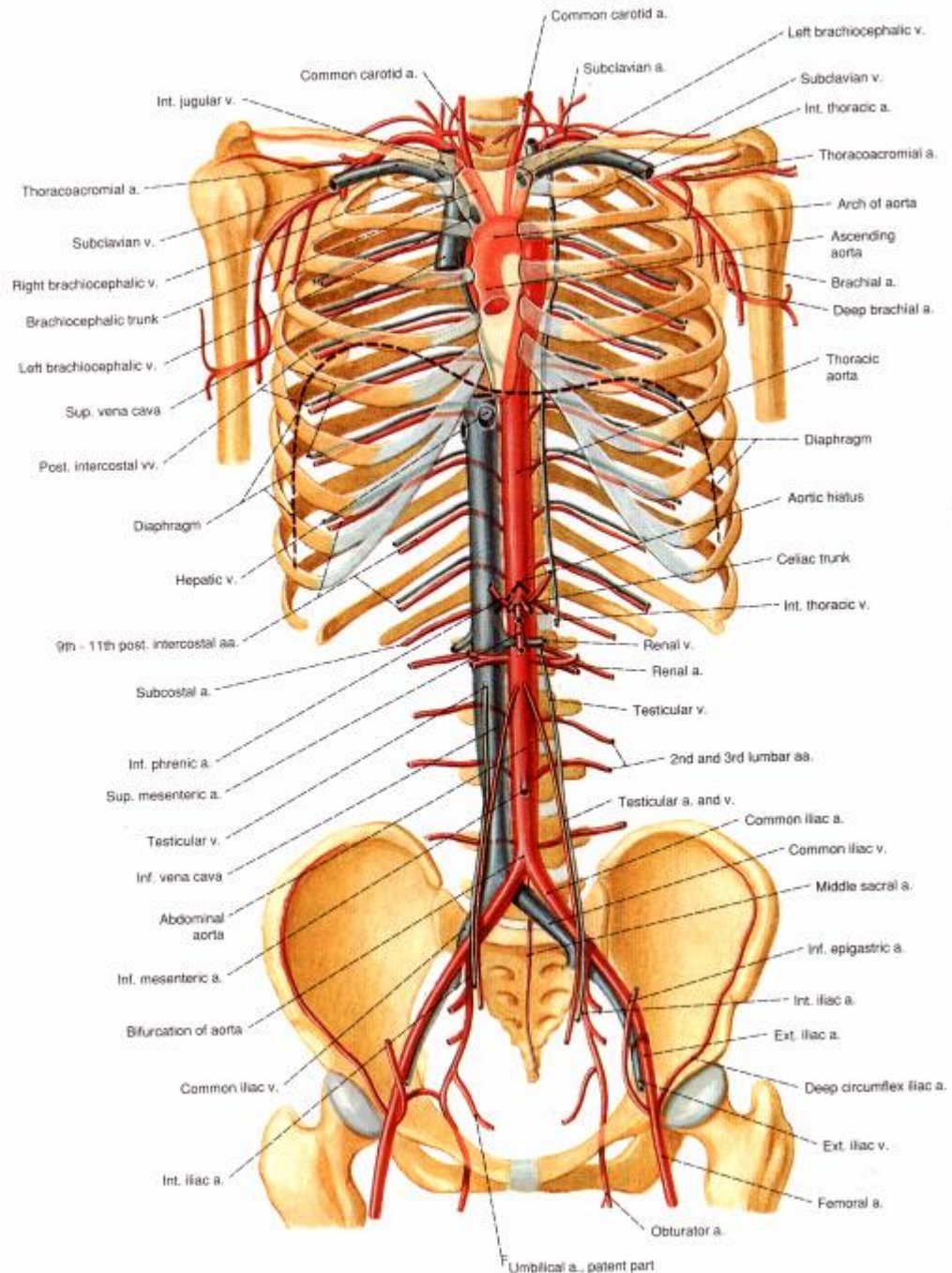
*atherosclerosis*

*aneurysms*

*replacement*

*cystic medionecrosis*

*Takayashu's arteritis  
(granulomatous)*





# Aorta thoracica

parietal branches: *paired*

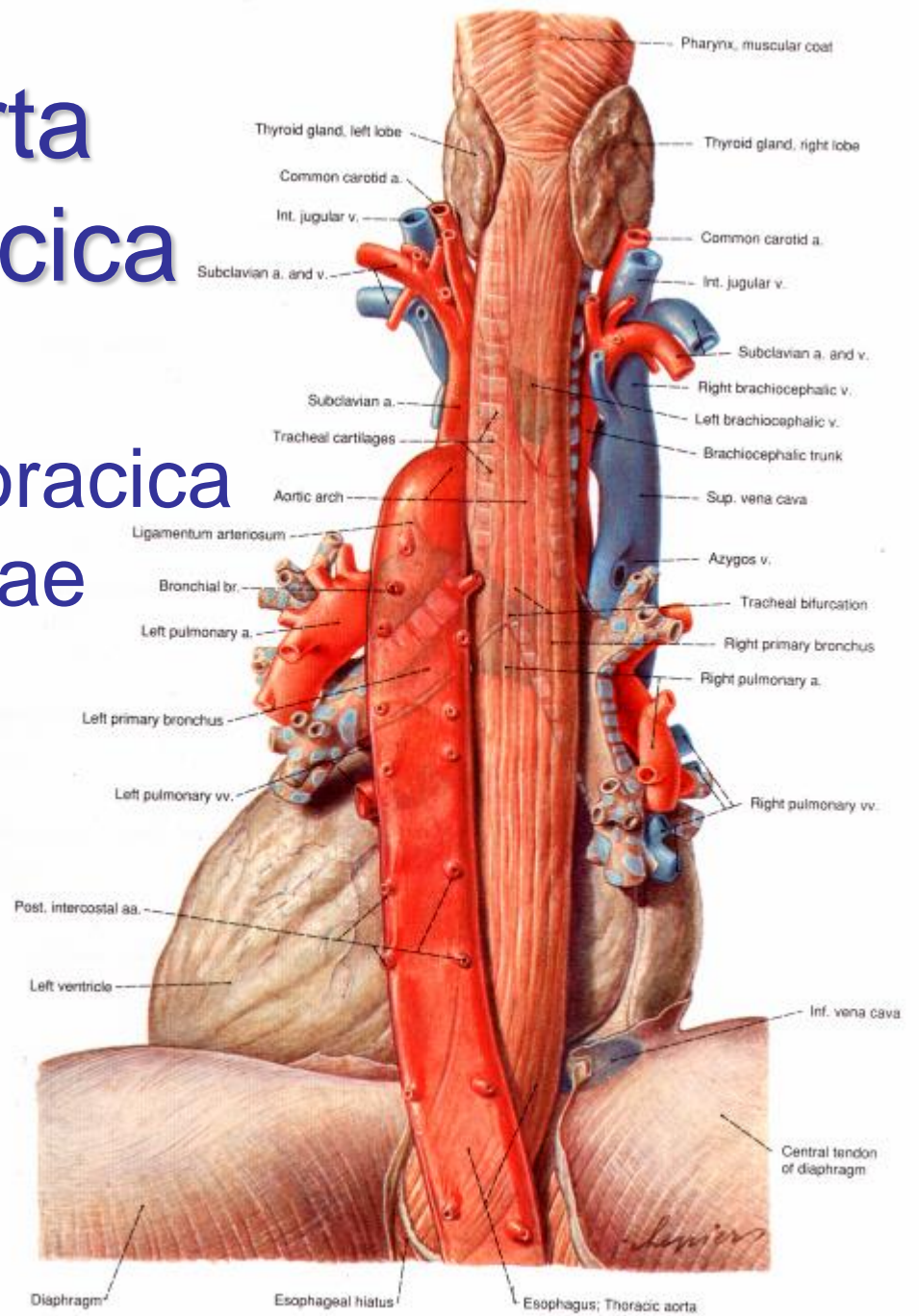
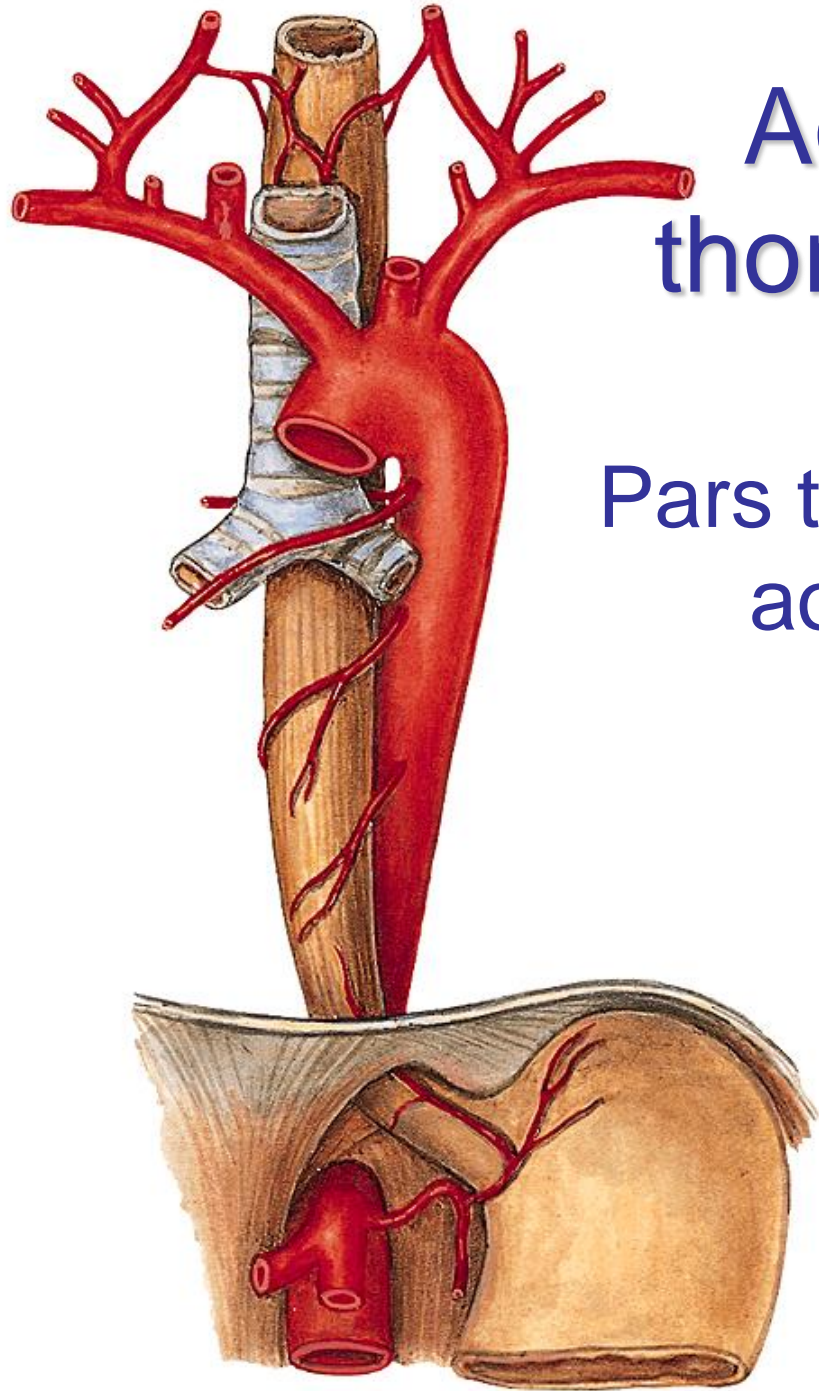
- aa. intercostales posteriores (3-11)
- a. subcostalis
- a. phrenica superior (*rudimentary*)

visceral branches: *larger number of small branches*

- rr. bronchiales
  - 1 right – most often from a. intercostalis tertia
  - 2 left directly from aorta thoracica
- rr. oesophagei
- rr. pericardiaci
- rr. mediastinales

# Aorta thoracica

## Pars thoracica aortae



# Aorta thoracica – topography

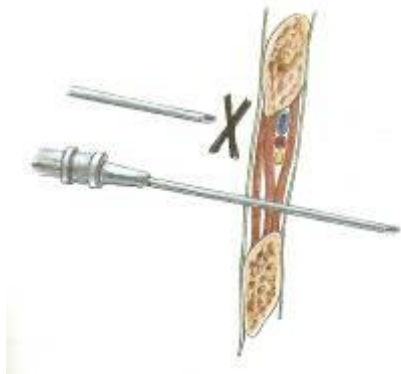
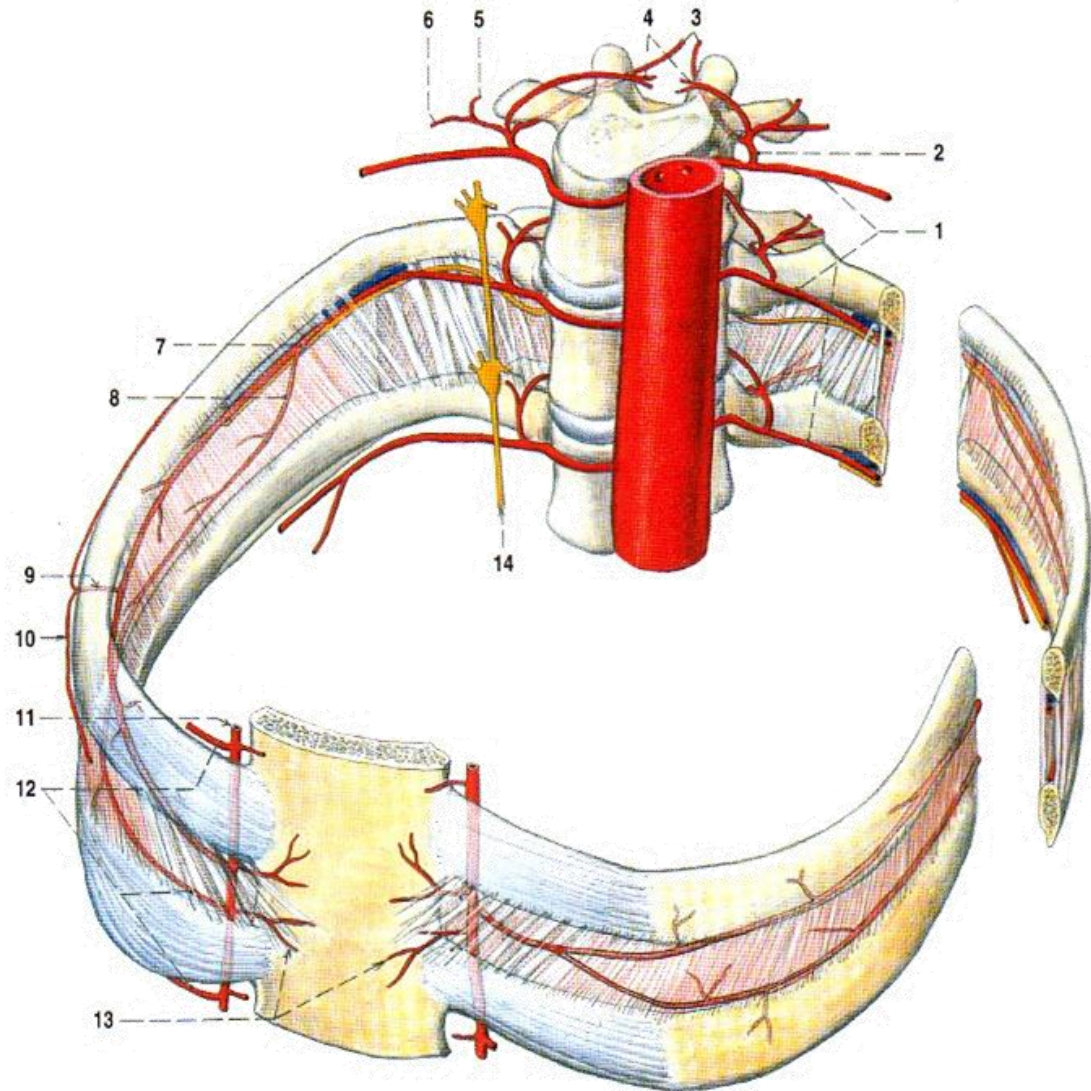
- mediastinum inferius posterius
- hiatus aorticus diaphragmatis
  - lig. arcuatum medianum (aortic arcade) -  
*compression*

## relations:

- oesophagus: right to aorta → dorsally
- ductus thoracicus: right to aorta
- v. azygos: right to aorta
- v. hemiazygos: left to aorta → dorsally

# Intercostal spaces supply *aa. intercostales posteriores*

- r. dorsalis
  - r. cutaneii
  - rr. spinales
- r. collateralis
- r. cutaneus lat.
  - rr. mammarii lat.

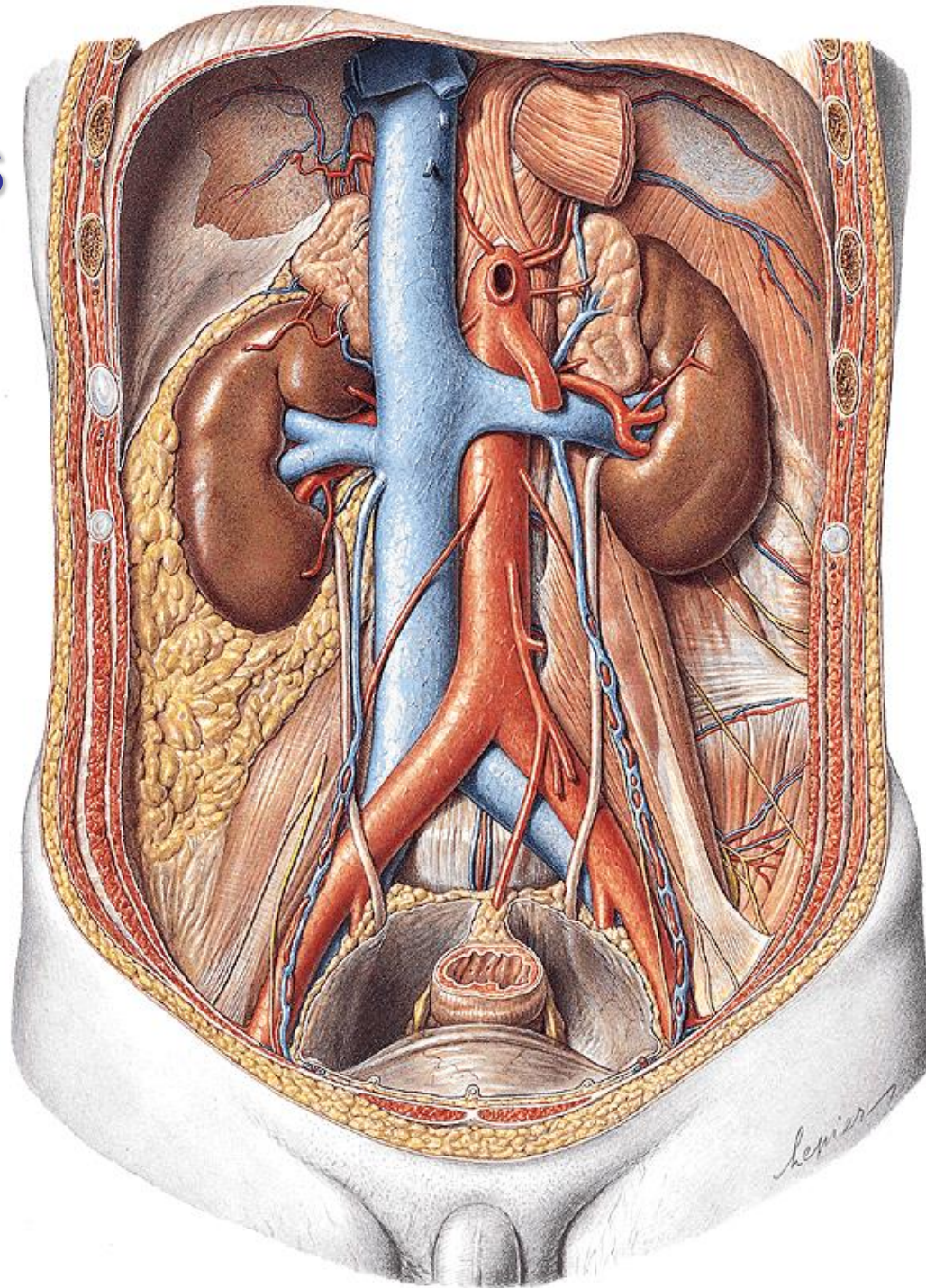


# Aorta abdominalis

origin: hiatus  
oesophageus  
diaphragmatis

end: bifurcatio aortae L4

- retroperitoneum,  
slightly left to vertebral  
column
- v. cava inferior +  
ductus thoracicus right  
to aorta abdominalis



# Aorta abdominalis

parietal branches: *paired*

- a. phrenica inf.
- aa. lumbales (4)
- rr. retroperitoneales (6-7)

visceral branches: *paired*

- a. suprarenalis media
- a. renalis
- a. renalis accessoria (30%)
- a. testicularis♂ / ovarica♀

# AORTA ABDOMINALIS

a. suprarenalis sup.

a. suprarenalis media

a. suprarenalis inf.

a. renalis

a. ovarica /  
testicularis

a. phrenica inf.

truncus coeliacus

a. mesenterica sup.

a. mesenterica inf.

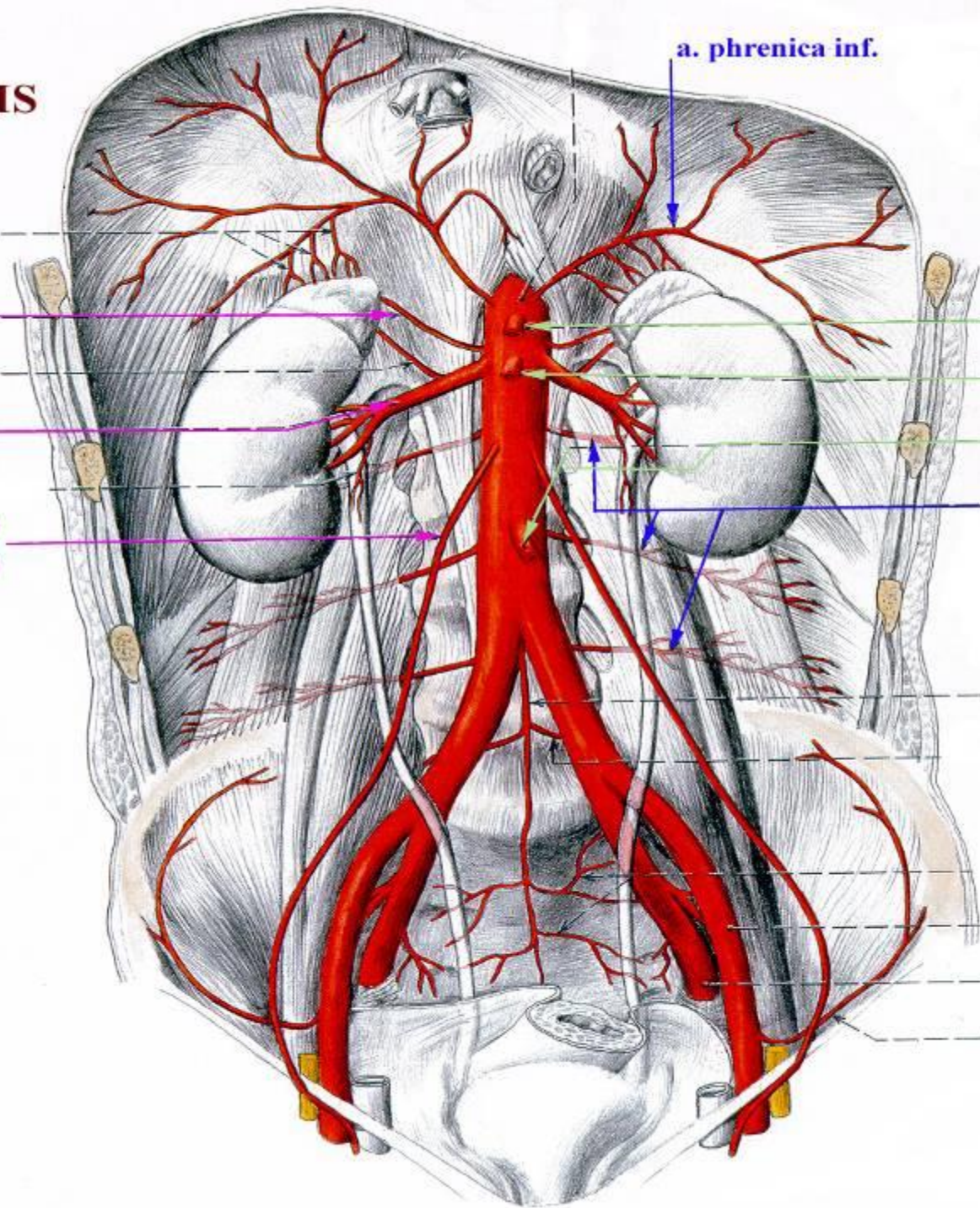
aa. lumbales

a. sacralis media

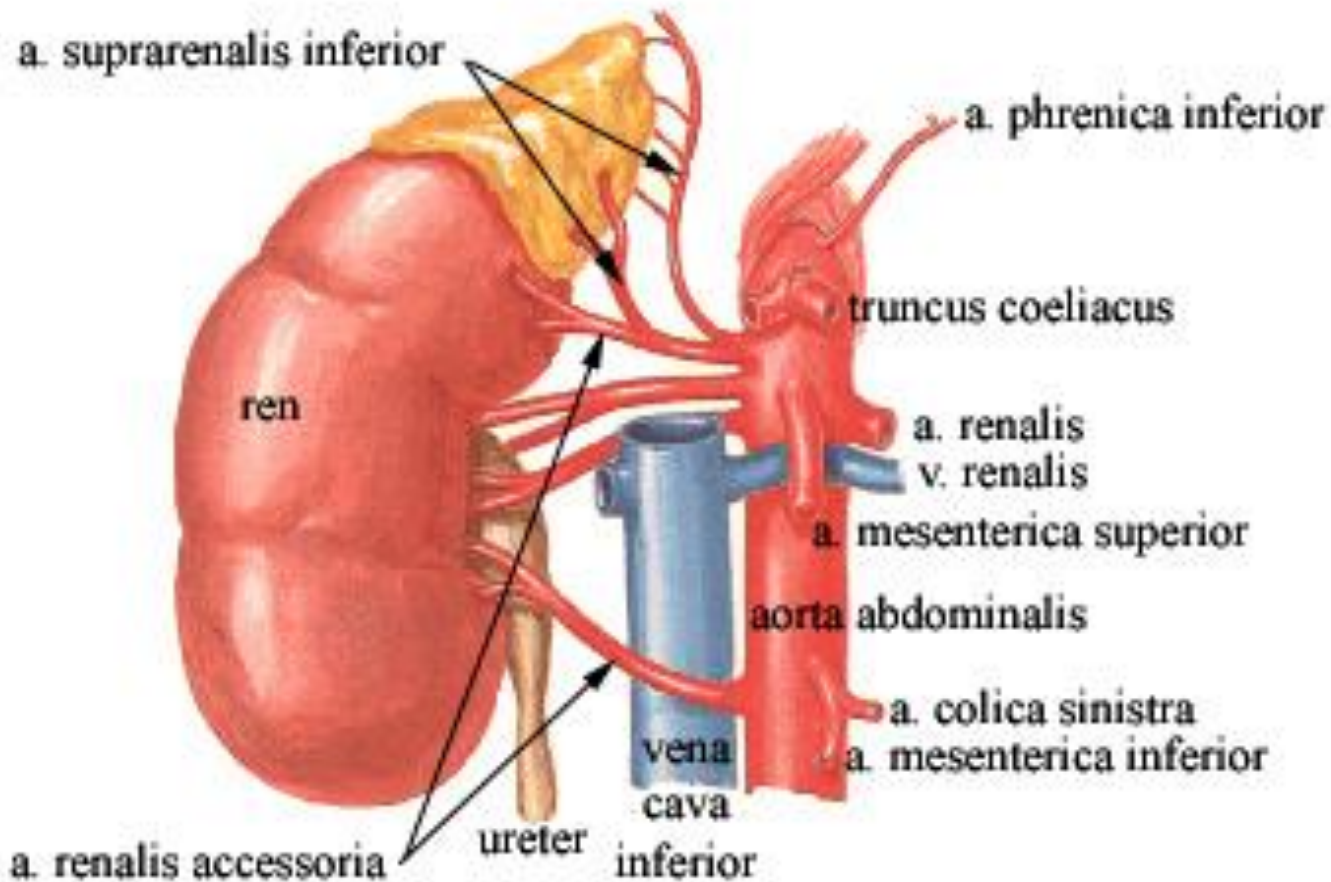
a. iliaca interna

a. iliaca externa

a. circumflexa  
ilium profunda



# ARTERIA RENALIS ACCESSORIA



- enters upper pole (less), hilum or inferior pole (more) of kidney
- incidence 30%



# Aorta abdominalis

terminal branches: *paired*

- a. iliaca communis

terminal branches : *unpaired*

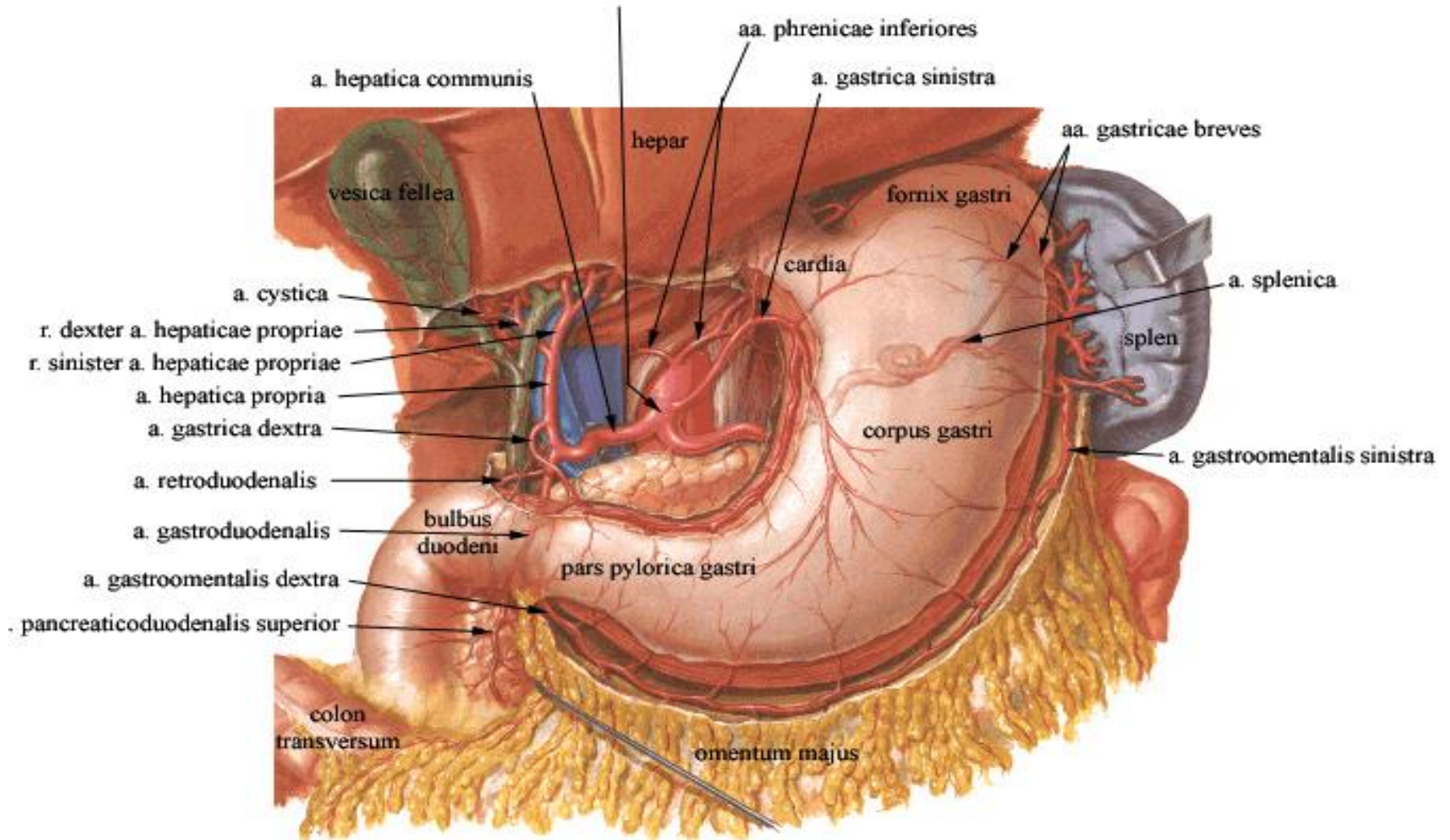
- a. sacralis mediana

visceral branches : *unpaired*

- truncus coeliacus
- a. mesenterica superior
- a. mesenterica inferior



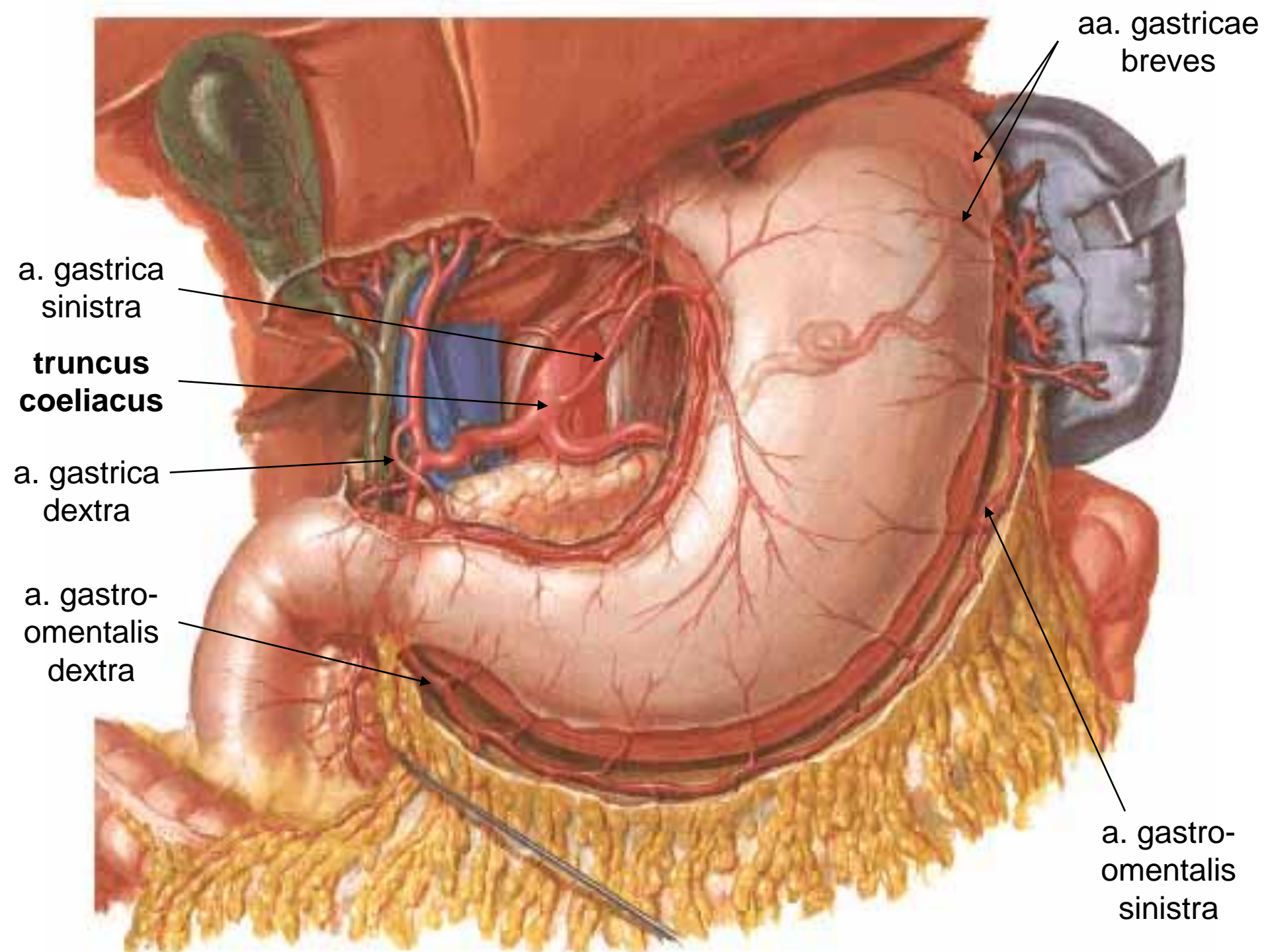
# TRUNCUS COELIACUS



# Stomach – arterial supply

aorta abdominalis (level T12) → **truncus coeliacus**

- → aa. gastrica sin.
- → a. hepatica communis
  - a. hepatica propria → **a. gastrica dx.**
  - a. gastroduodenalis → **a. gastromentalis dx.**
- → a. splenica
  - **a. gastromentalis sin.**
  - **aa. gastricae breves** (fundus)
  - a. gastrica posterior (*variable*)



aa. gastricae  
breves

a. gastrica  
sinistra

**truncus  
coeliacus**

a. gastrica  
dextra

a. gastro-  
omentalis  
dextra

a. gastro-  
omentalis  
sinistra

# Duodenum – arterial supply

- **truncus coeliacus** → a. hepatica communis  
→ a. gastroduodenalis → a.  
pancreaticoduodenalis sup. post. + sup.  
ant. + aa. retroduodenales
- **a. mesenterica superior** → a.  
pancreaticoduodenalis inf. → ramus ant. +  
r. post.

a. gastroduodenalis

a. pancreaticoduodenalis  
sup.

a. pancreaticoduodenalis  
sup. ant.

a. pancreaticoduodenalis  
sup. post.

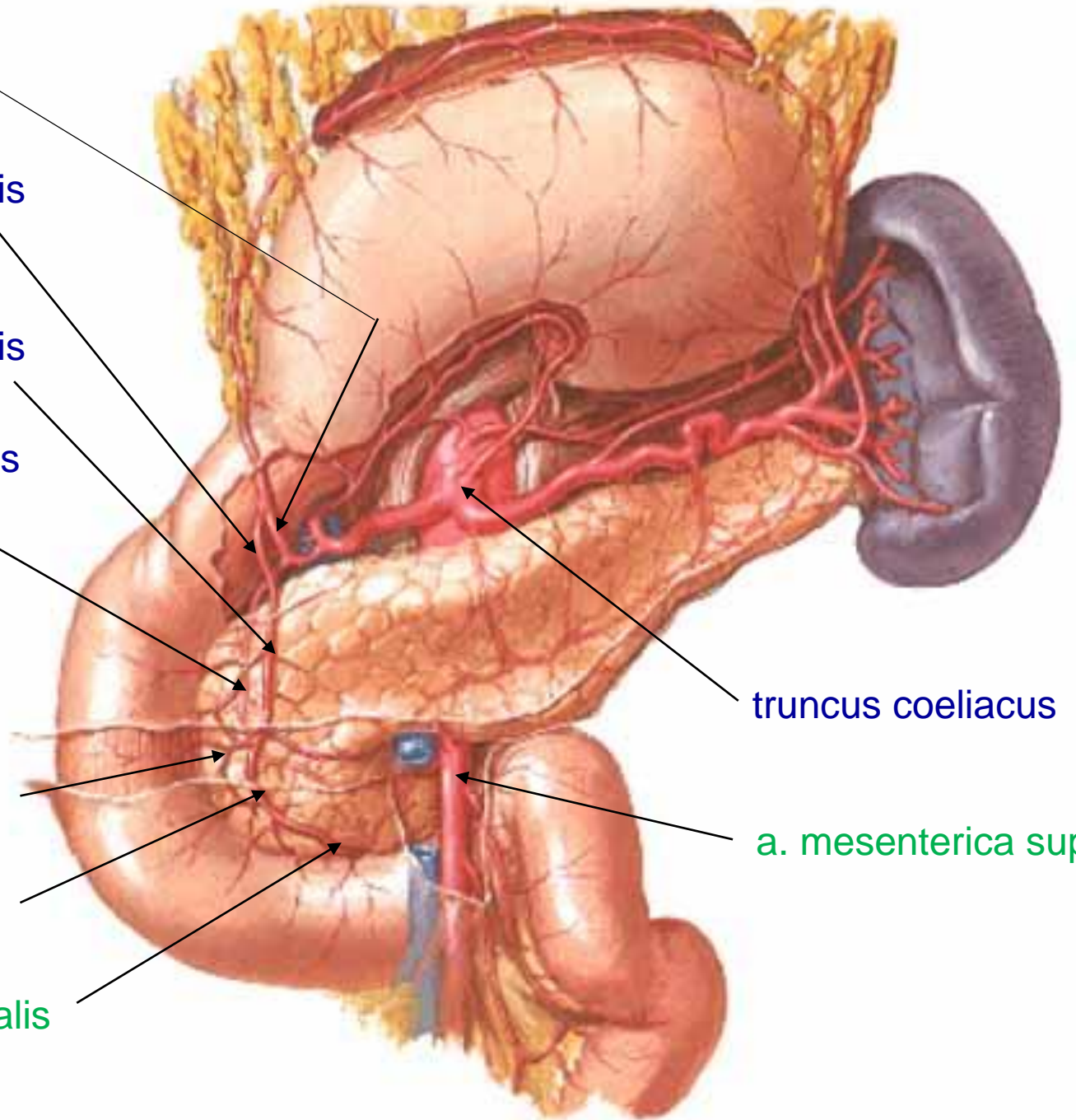
truncus coeliacus

a. mesenterica sup.

a. pancreaticoduodenalis  
inf. post.

a. pancreaticoduodenalis  
inf. ant.

a. pancreaticoduodenalis  
inf.



# Jejunum + ileum

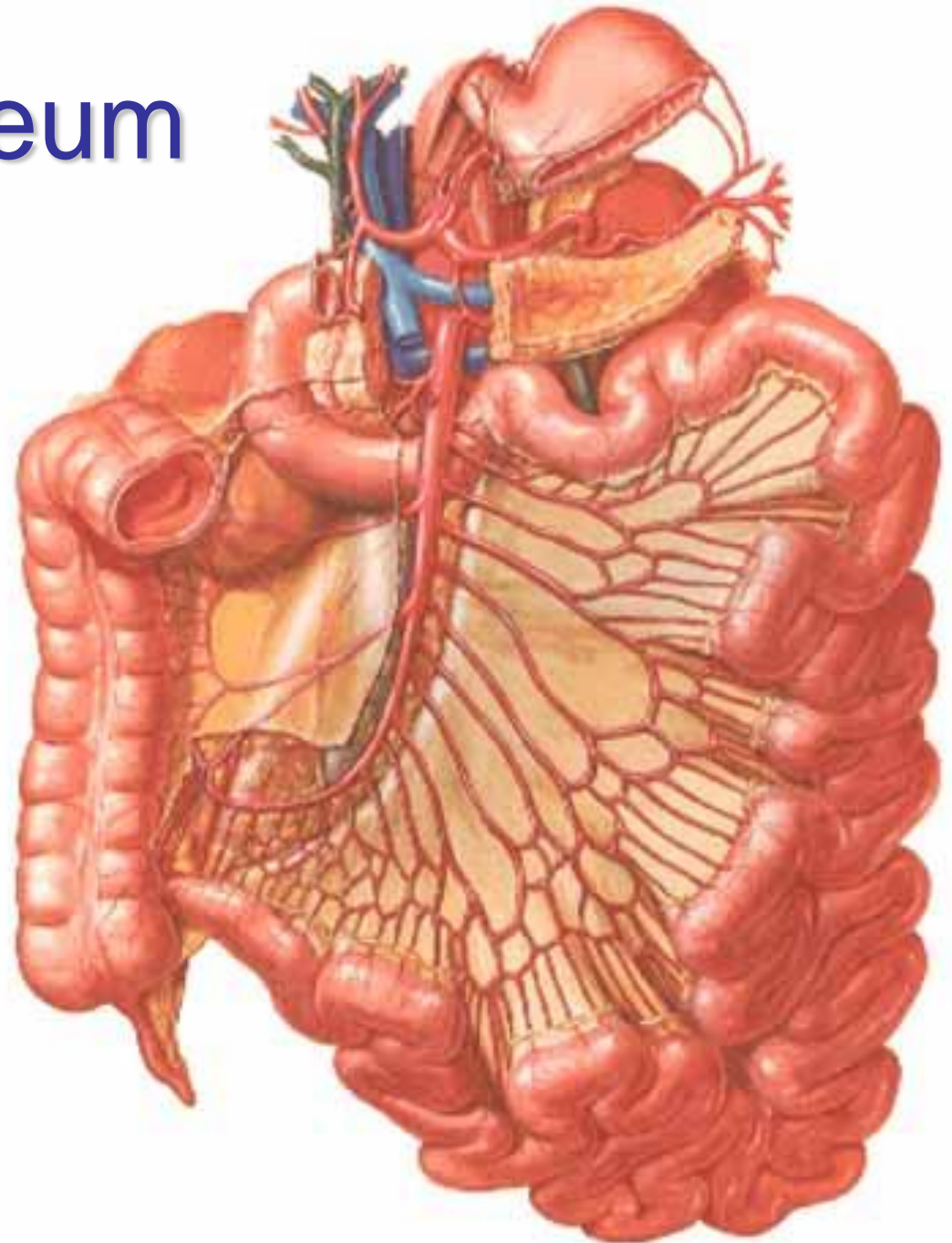
a. mesenterica sup.

- aa. jejunales
- aa. ileales
- a. ileocolica

arcades

*parallel Dwight's  
artery*

→ arteriolar rectae →  
intramural  
plexuses

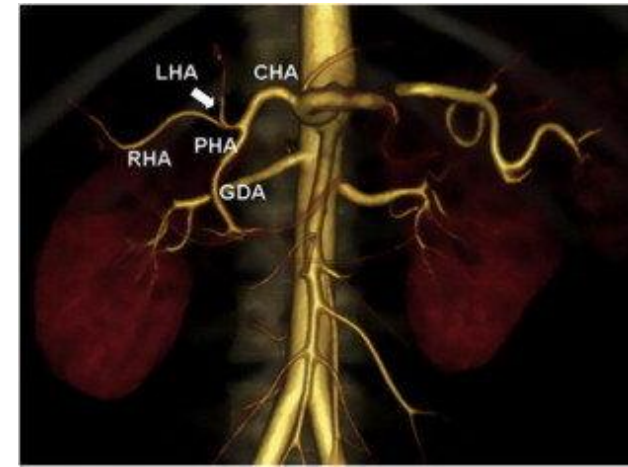




# Liver and gallbladder

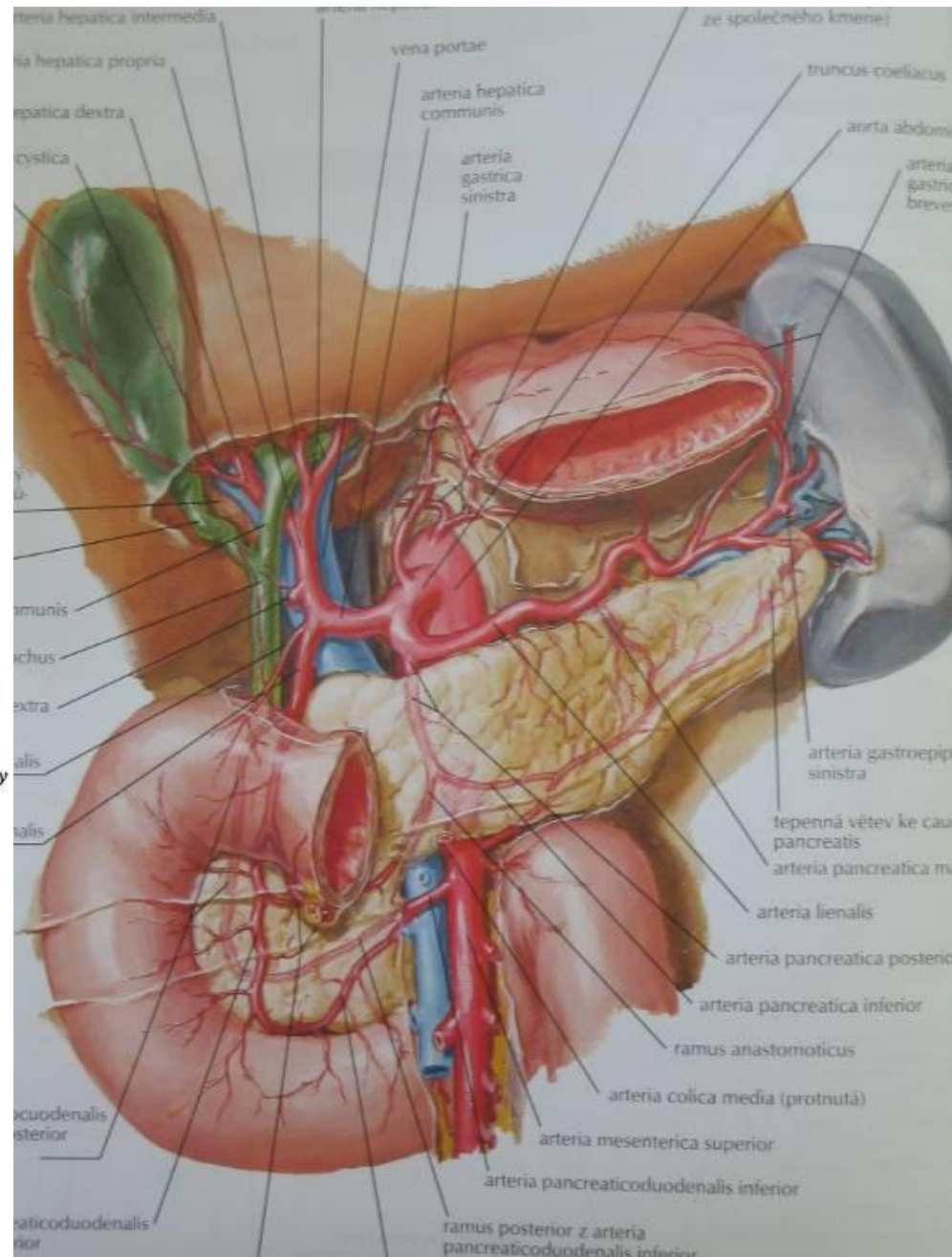
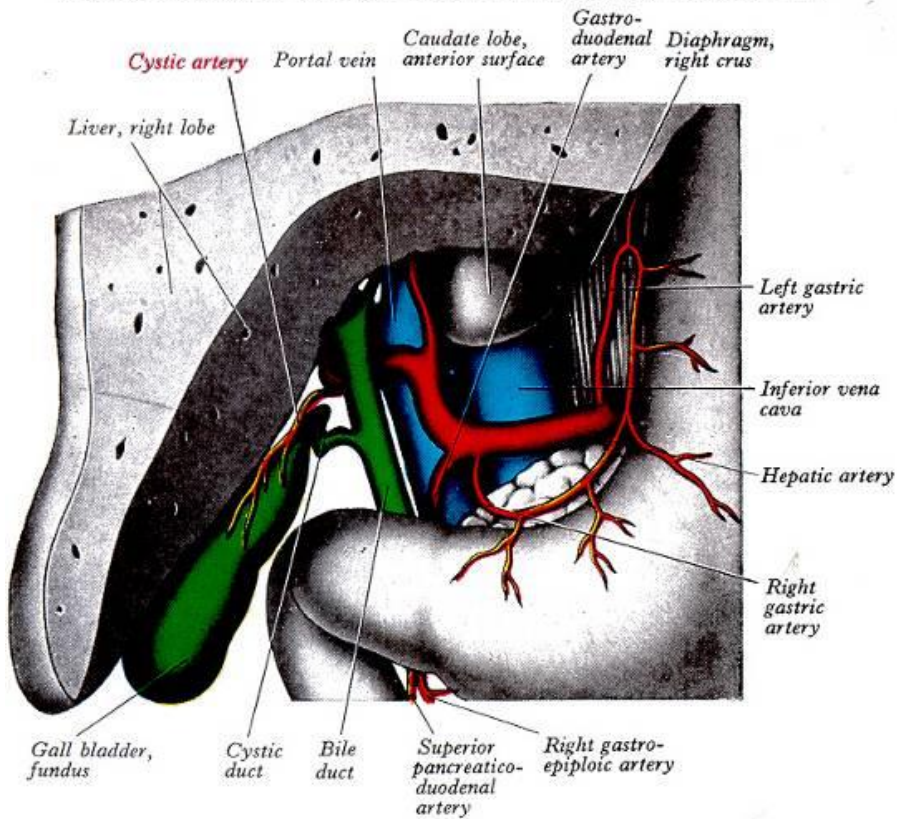
**truncus coeliacus** → a. hepatica communis  
→ a. hepatica propria (+ a. hepatica  
accessoria) → r. dx.+ sin. → aa.  
interlobulares → sinusoids

- nutritive circulation supplies 25% of blood
- r. dexter → a. cystica (*trigonum Caloti*)
- r. hepaticus accessorius
  - branch of AMS or AGS
- a. hepatica aberrans (2 %)
  - branch of AMS



# Liver and gallbladder

## TRIGONUM CYSTOHEPATICUM CALOTI

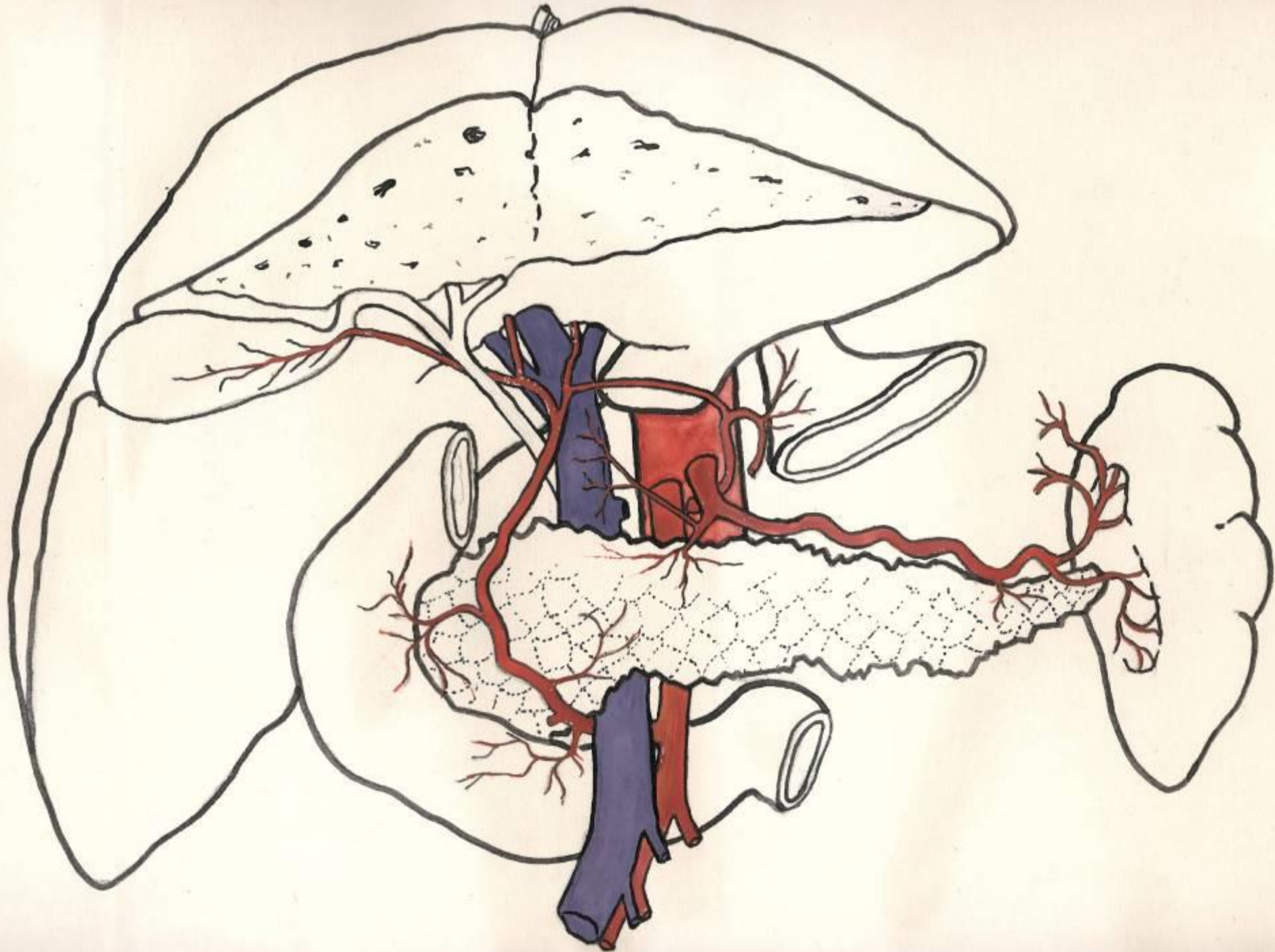


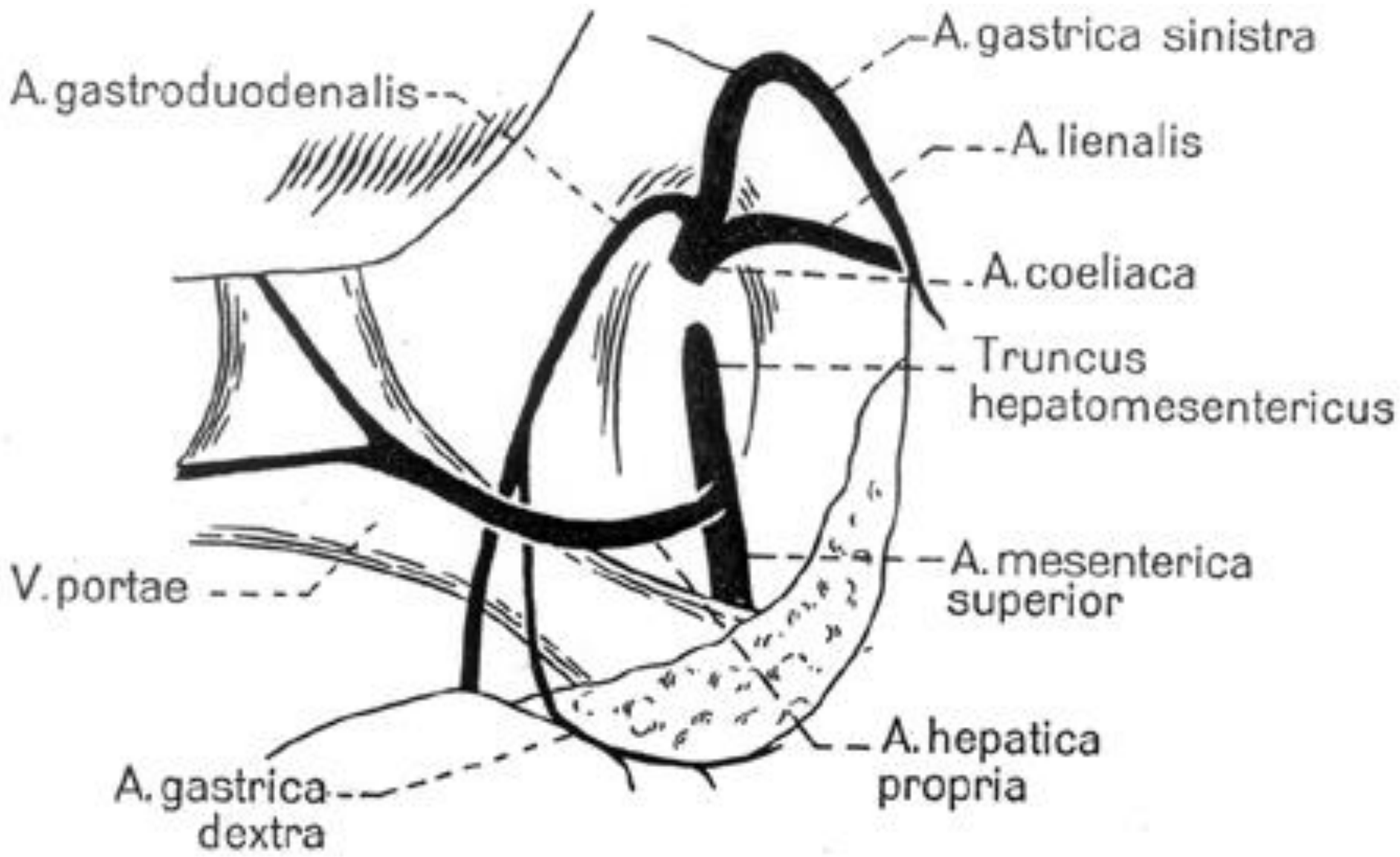
# Arteria hepatica – variations

- normal anatomy – 75%

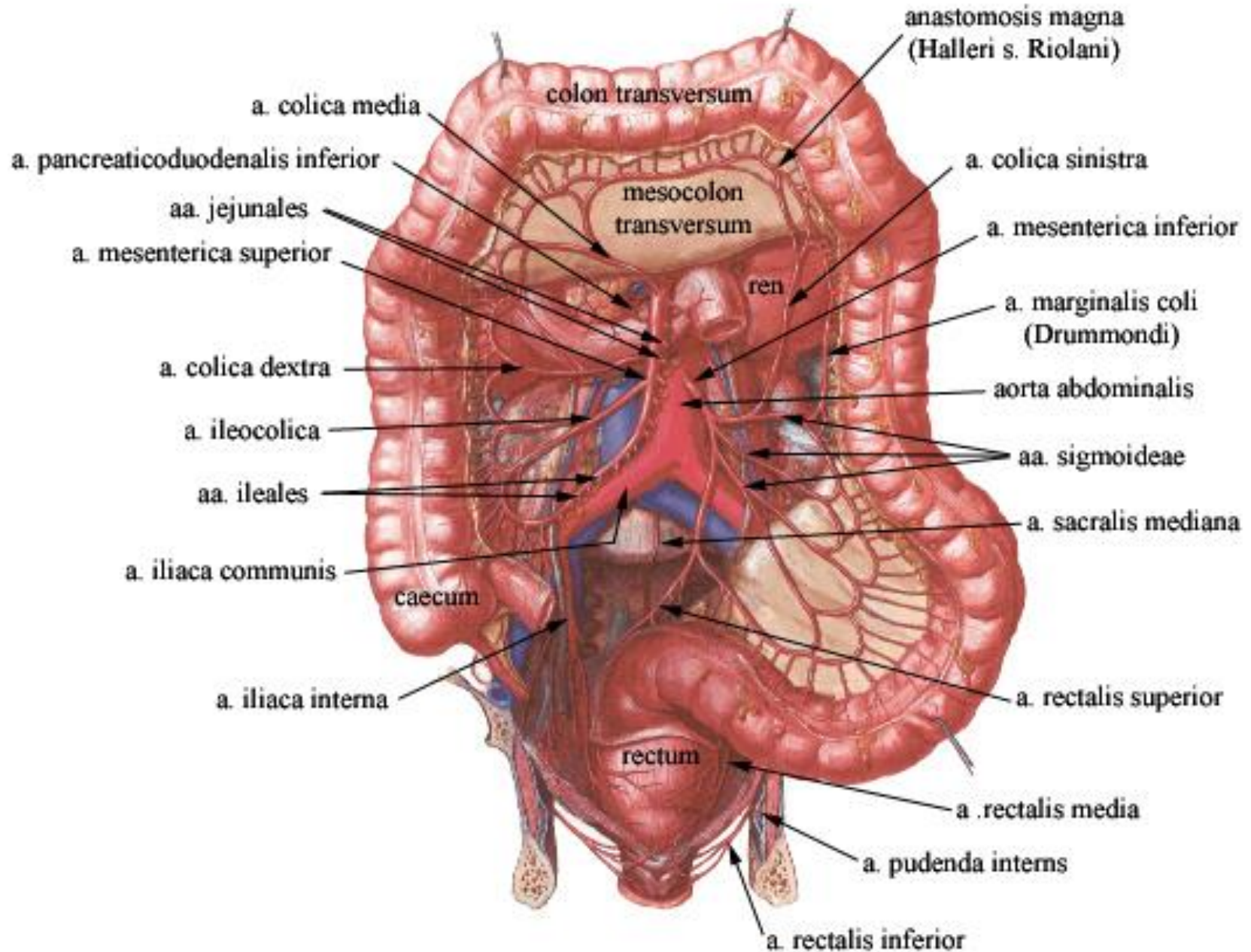
## accessory x aberrant (replaced artery)

- r. dx. accessorius / aberrans from AMS – 10%
- r. sin. accessorius / aberrans from AGS – 10%
- separate r. dx+sin. aberrans from AGS – 2%
- whole AHC aberrans from AMS – 2%
- whole AHC directly from TC – 1%



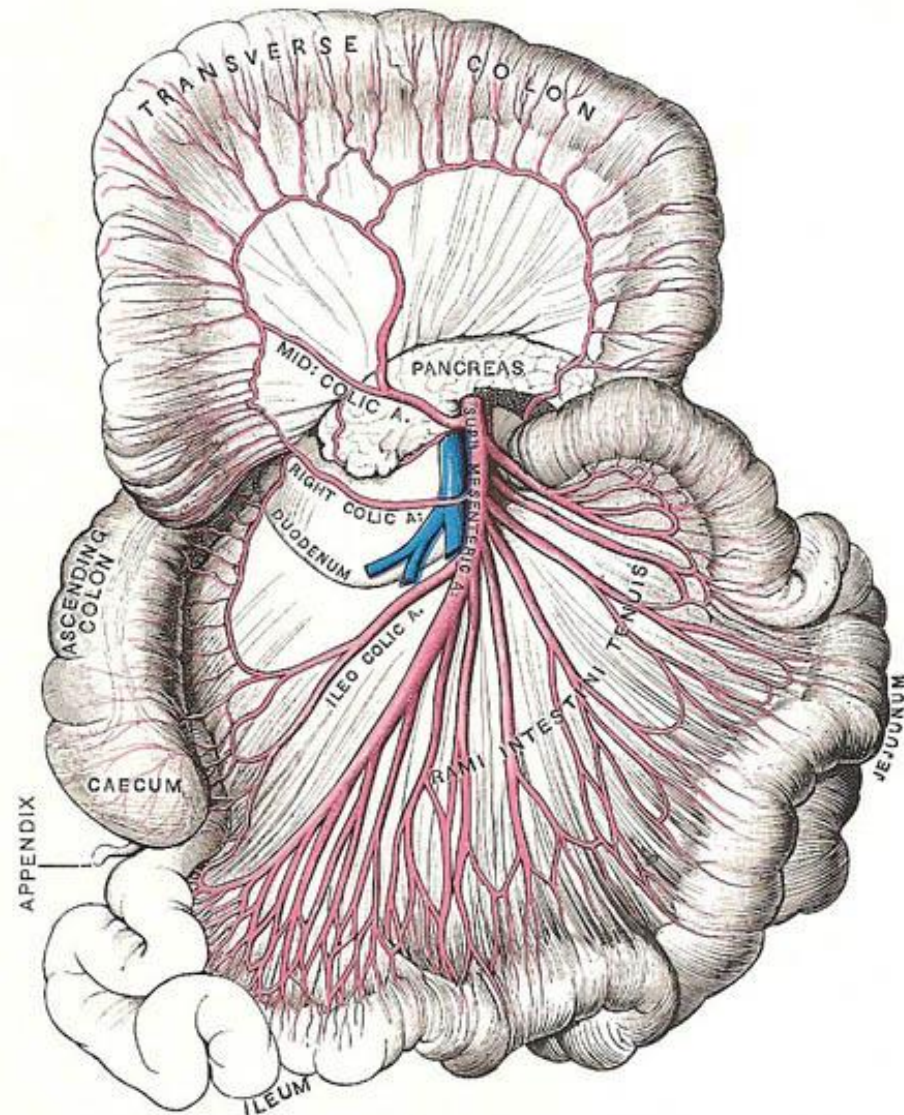


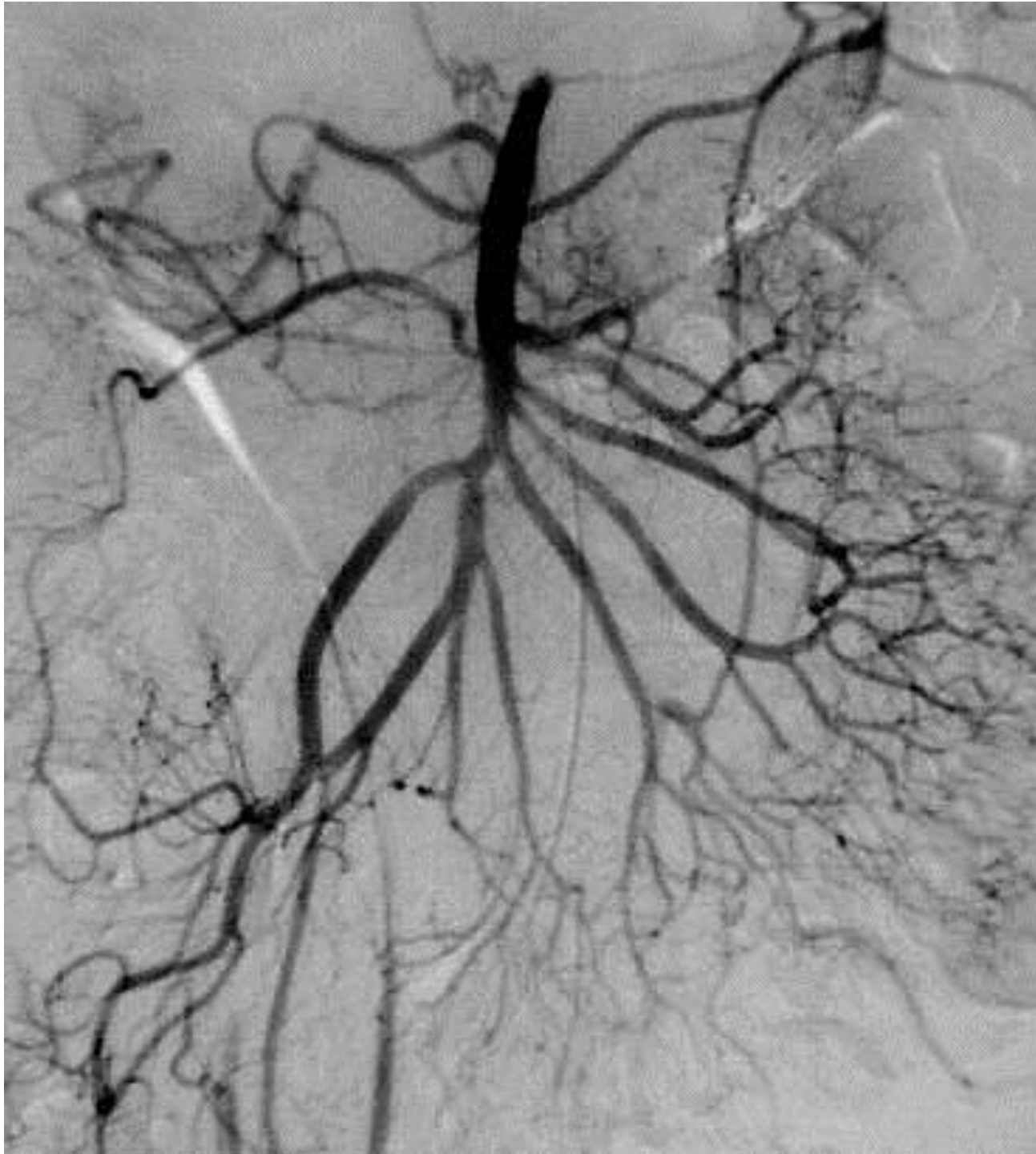# ARTERIAE MESENTERICAE



# Arteria mesenterica superior

- L1, 1 cm below TC  
ventrally: collum pancreatis  
dorsally: aorta, v. renalis sin., processus uncinatus, pars inferior duodeni, oral part of jejunum
- *abdominal angina*
- *syndrome of AMS = compression of pars inferior duodeni*
- *occlusion of AMS → 80% mortality*

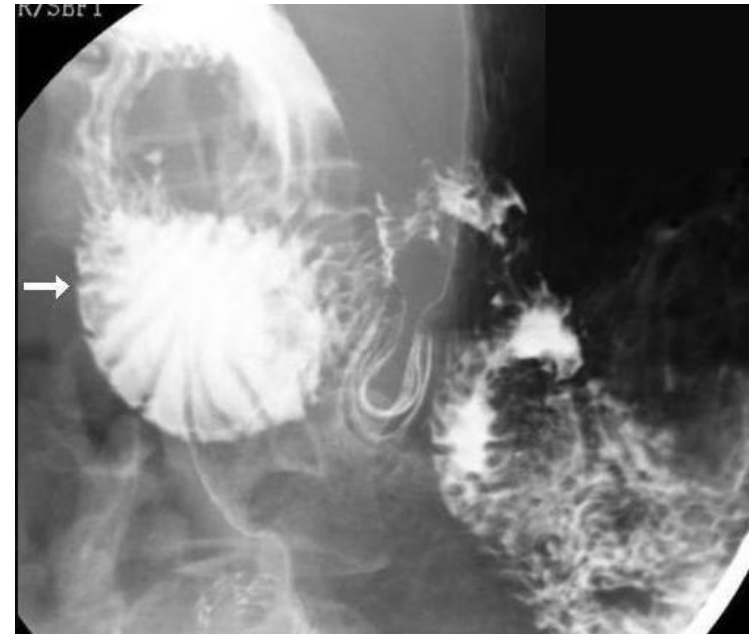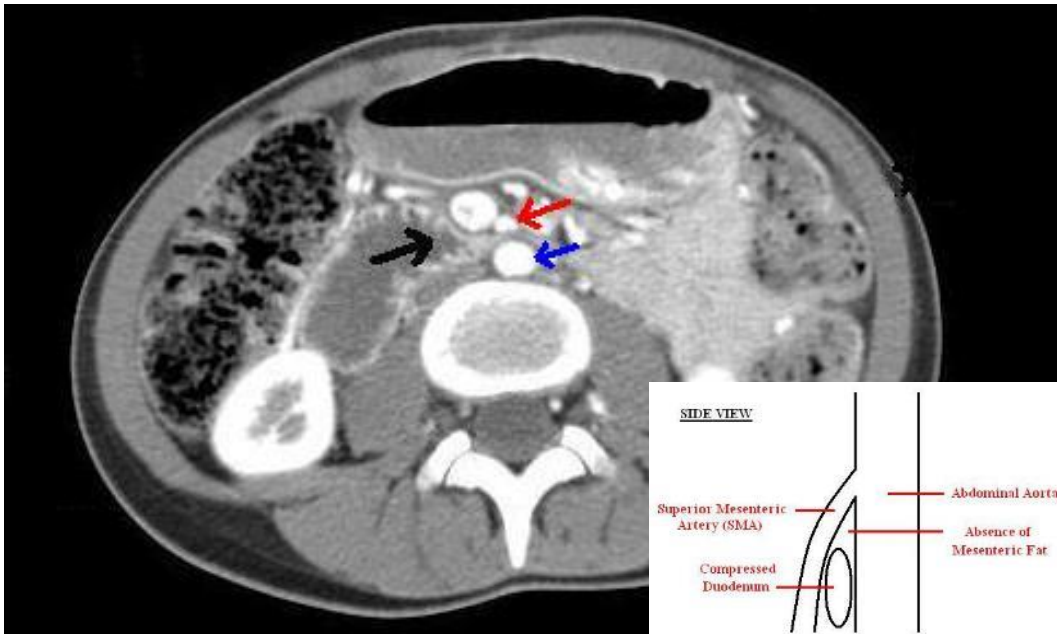



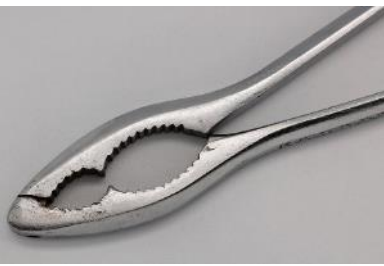


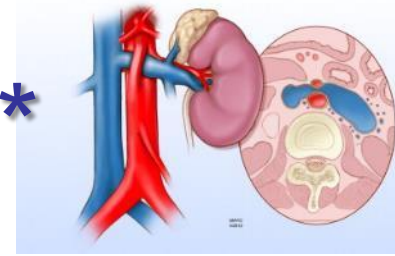
# Syndrome of a. mesenterica superior\*

- normal angle between AoA and AMS: 38–56°
- reduced angle of 6–25 ° + lack of retroperitoneal and visceral fat → syndrome of AMS = compression of pars inferior duodeni
- *very rare (Rokitansky-Wilkie's syndrome)*

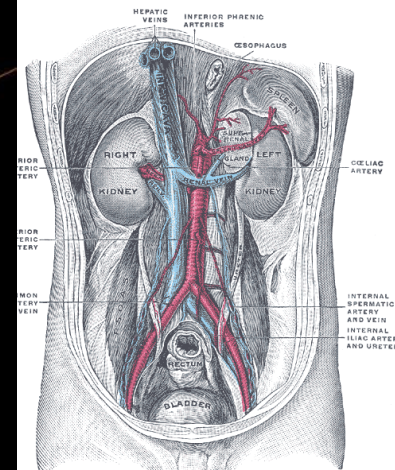
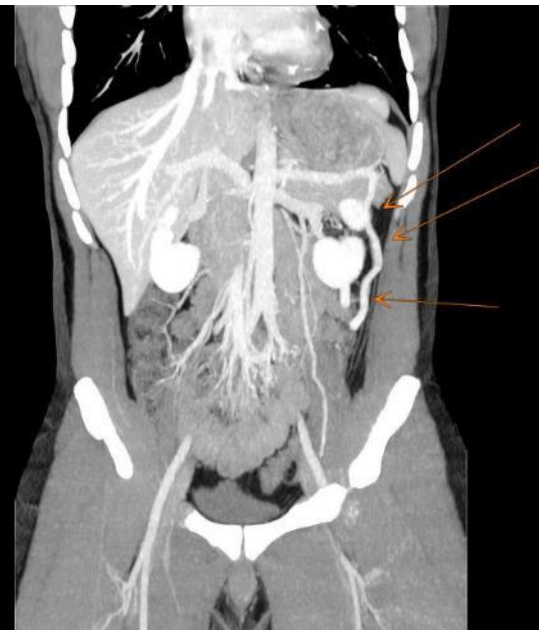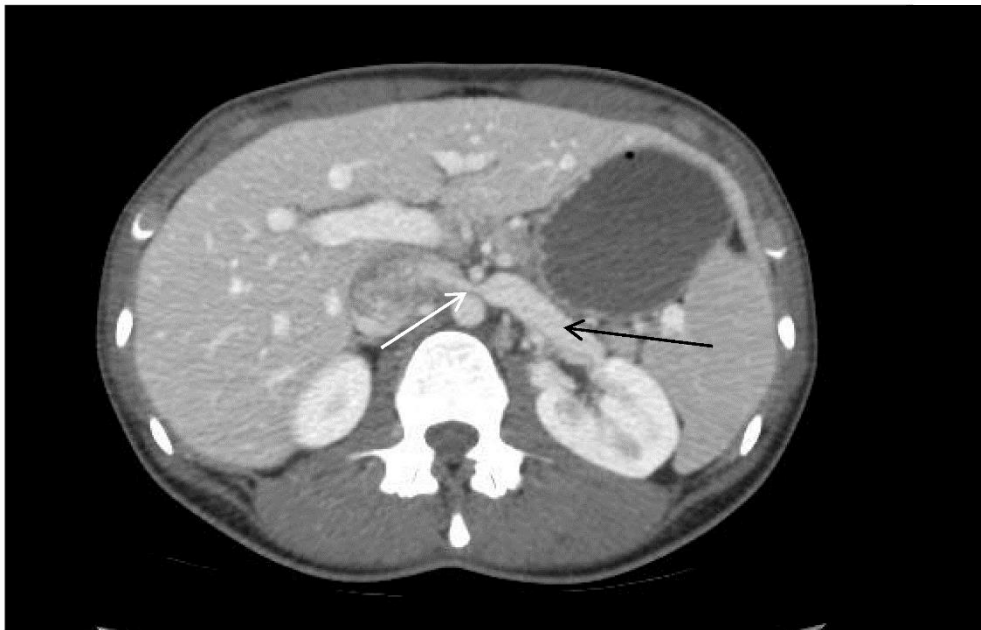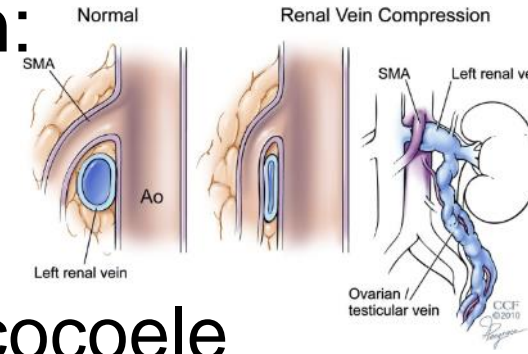




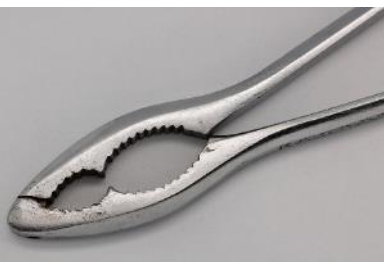# Nutcracker syndrome\*

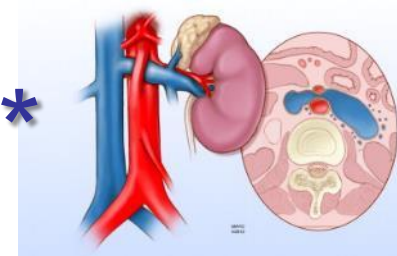


- compression of v. renalis sin. between:
  - aorta abdominalis (dorsally)
  - a. mesenterica superior (ventrally)
- intermittent hematuria, collaterals, varicocoele

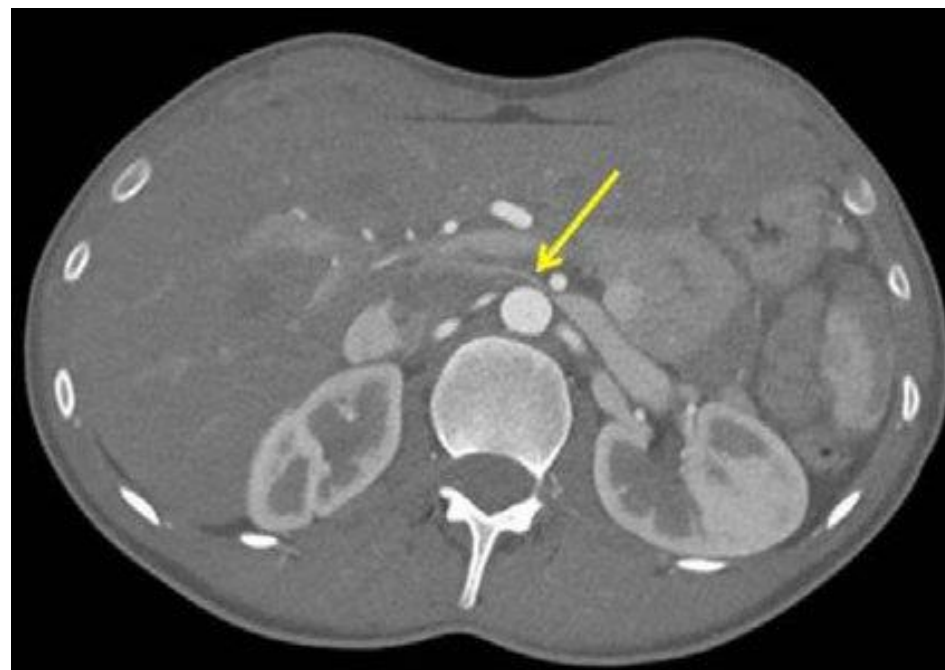



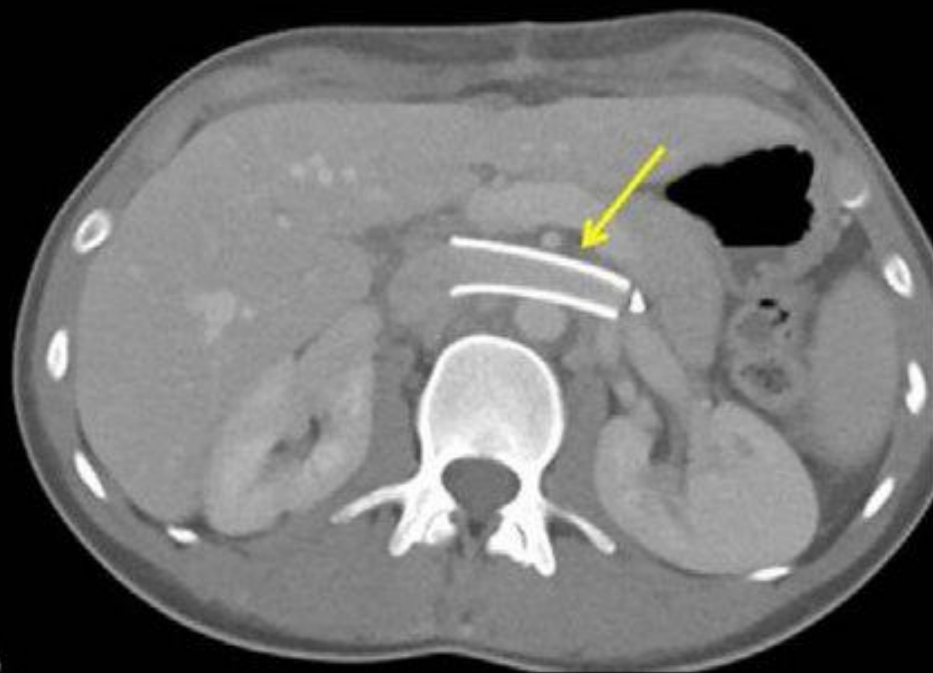# Nutcracker syndrome\*



- treatment – stenting of v. renalis sinistra



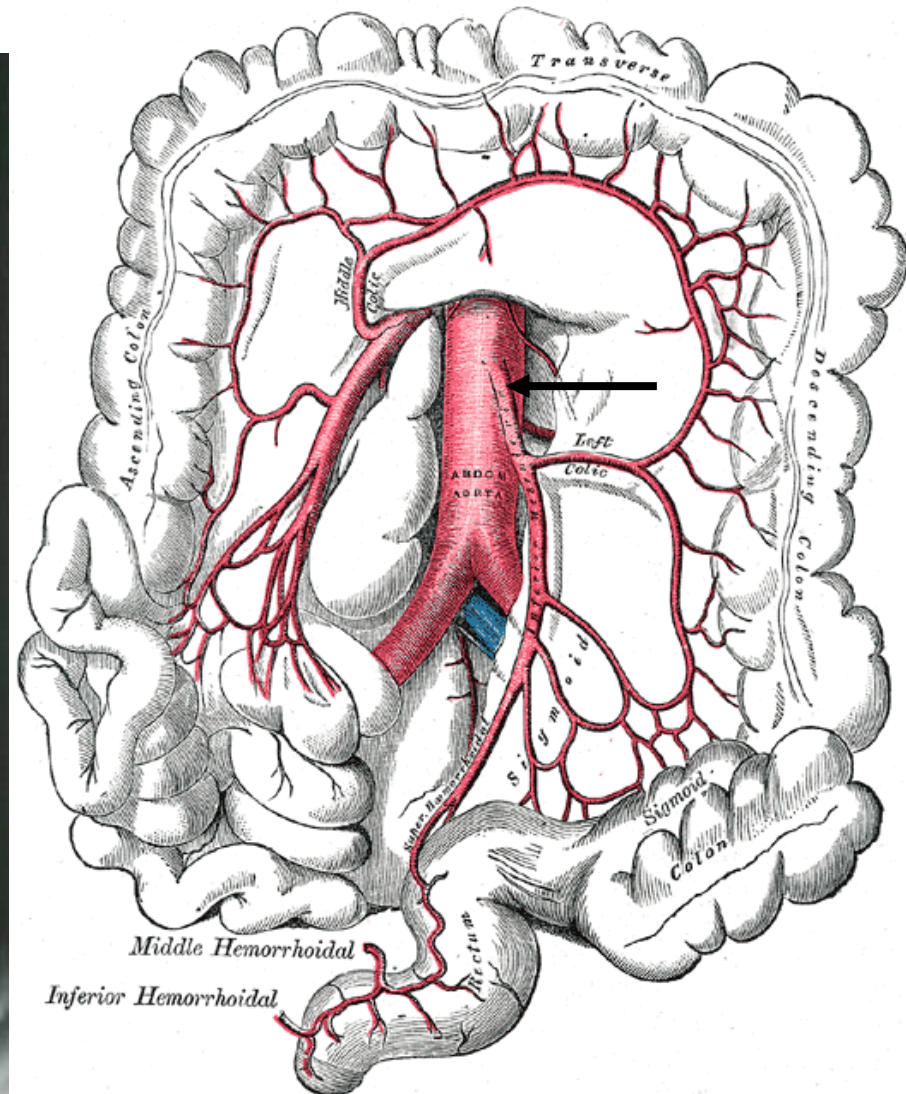
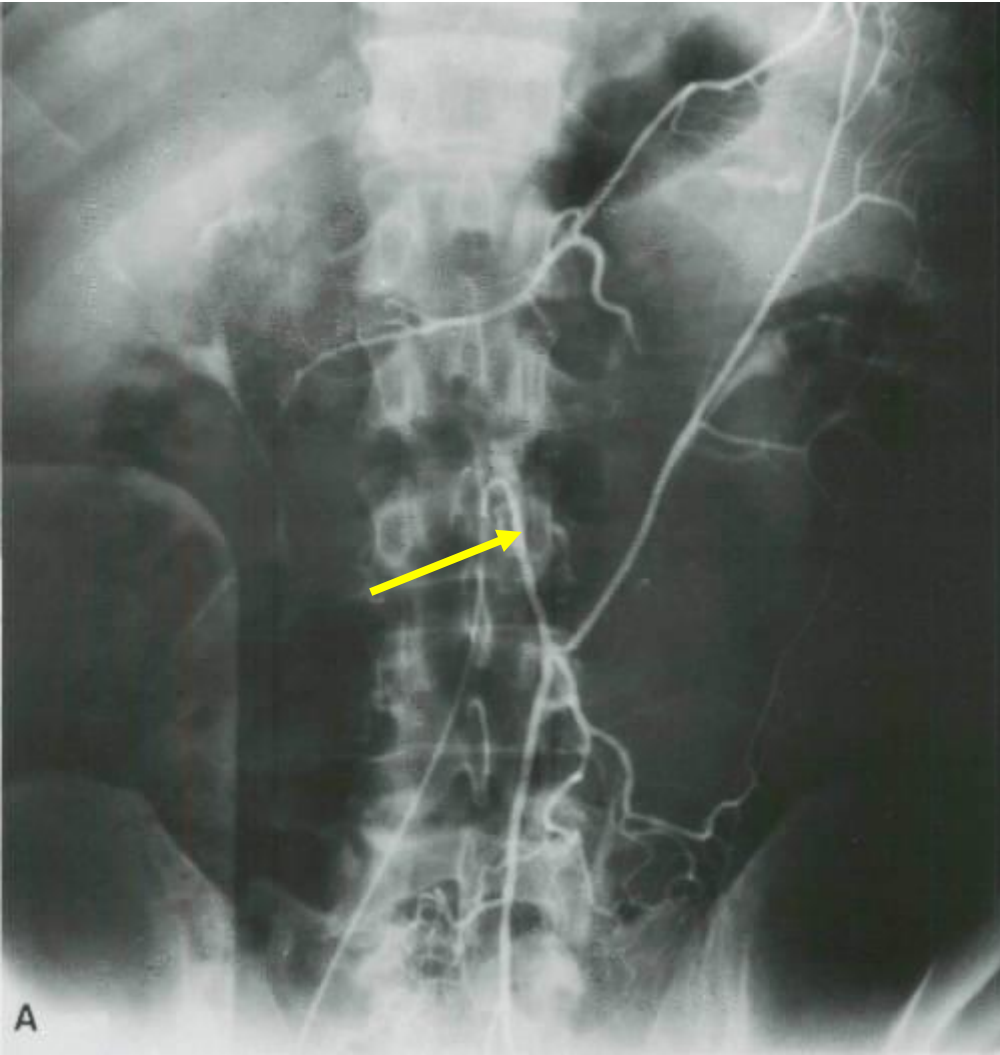
Preoperative CT Scan



Postoperative CT Scan

# Arteria mesenterica inferior

- L3



# Large intestine – arterial supply

- **a. mesenterica sup.**

→ a. ileocolica → a. caecalis ant. + post., a. appendicularis, r. colicus, r. ilealis

→ a. colica dx. (*for colon ascendens*)

→ a. colica media (*for colon transversum*)

- **a. mesenterica inf.**

→ a. colica sin. (*for colon descendens*)

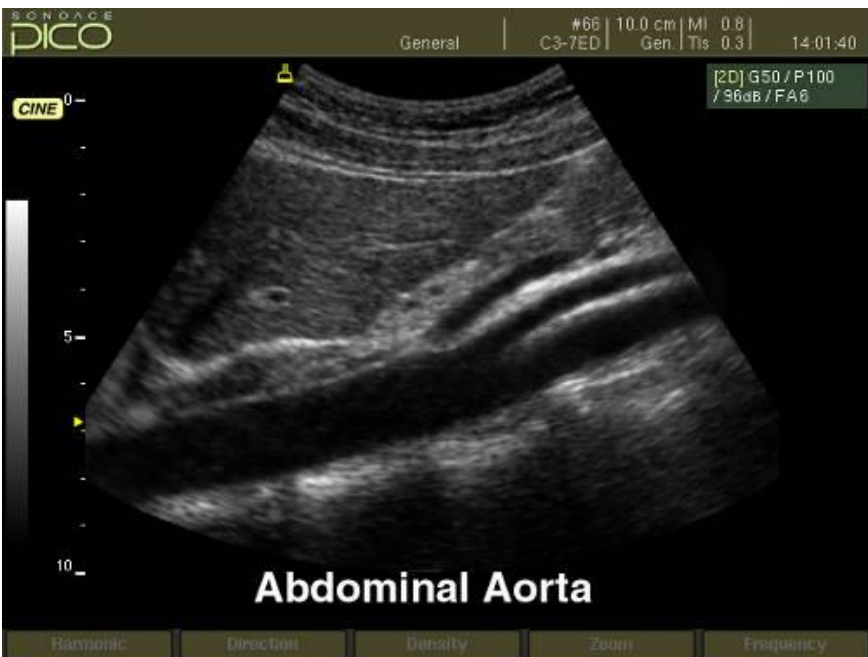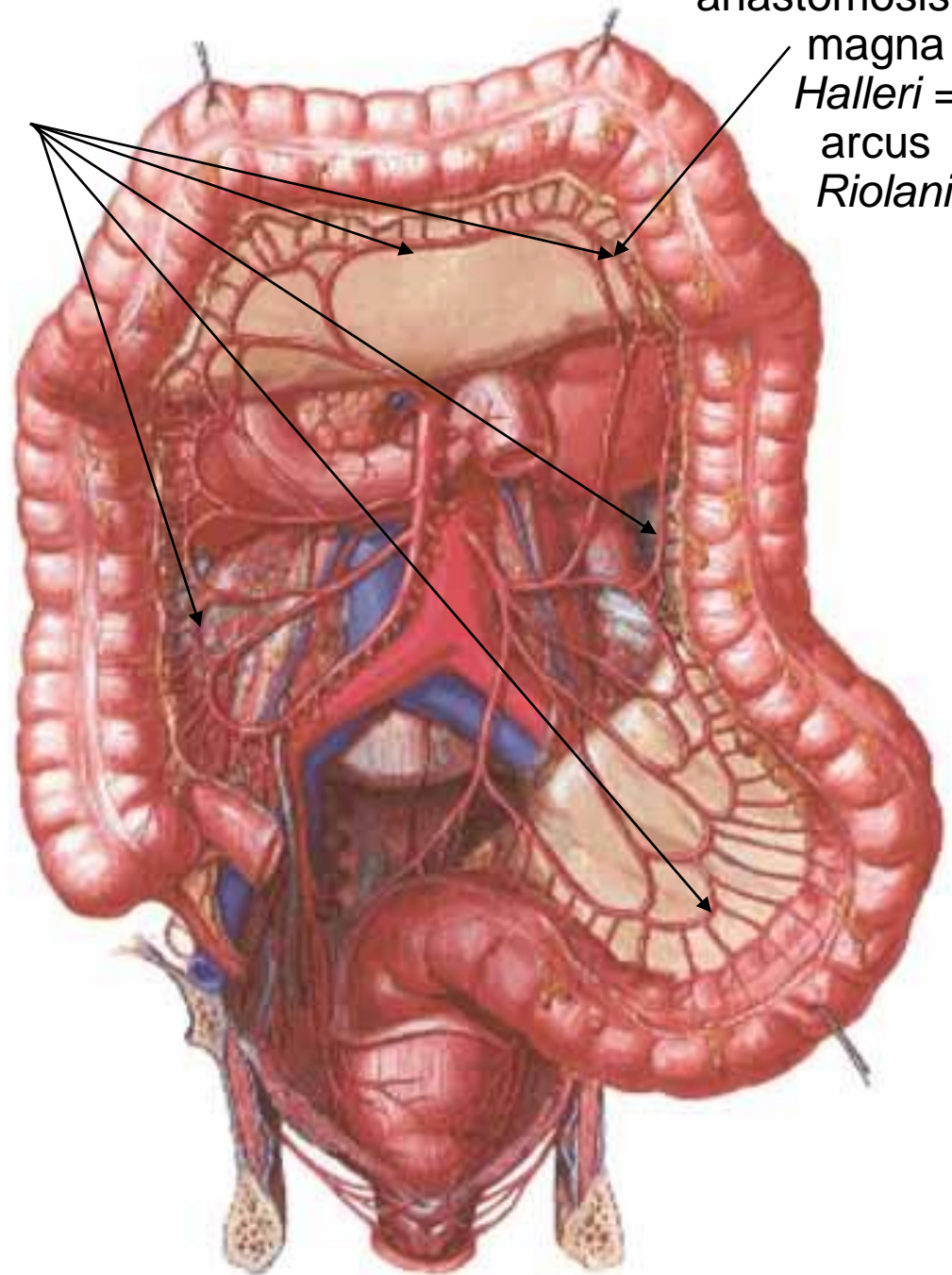
→ aa. sigmoideae (3-4)

arteria marginalis coli *Drummondi*

anastomosis magna *Halleri* = arcus *Riolani*

arteria marginalis  
coli  
*Drummondii*

anastomosis  
magna  
*Halleri* =  
arcus  
*Riolani*



# Arteria iliaca communis

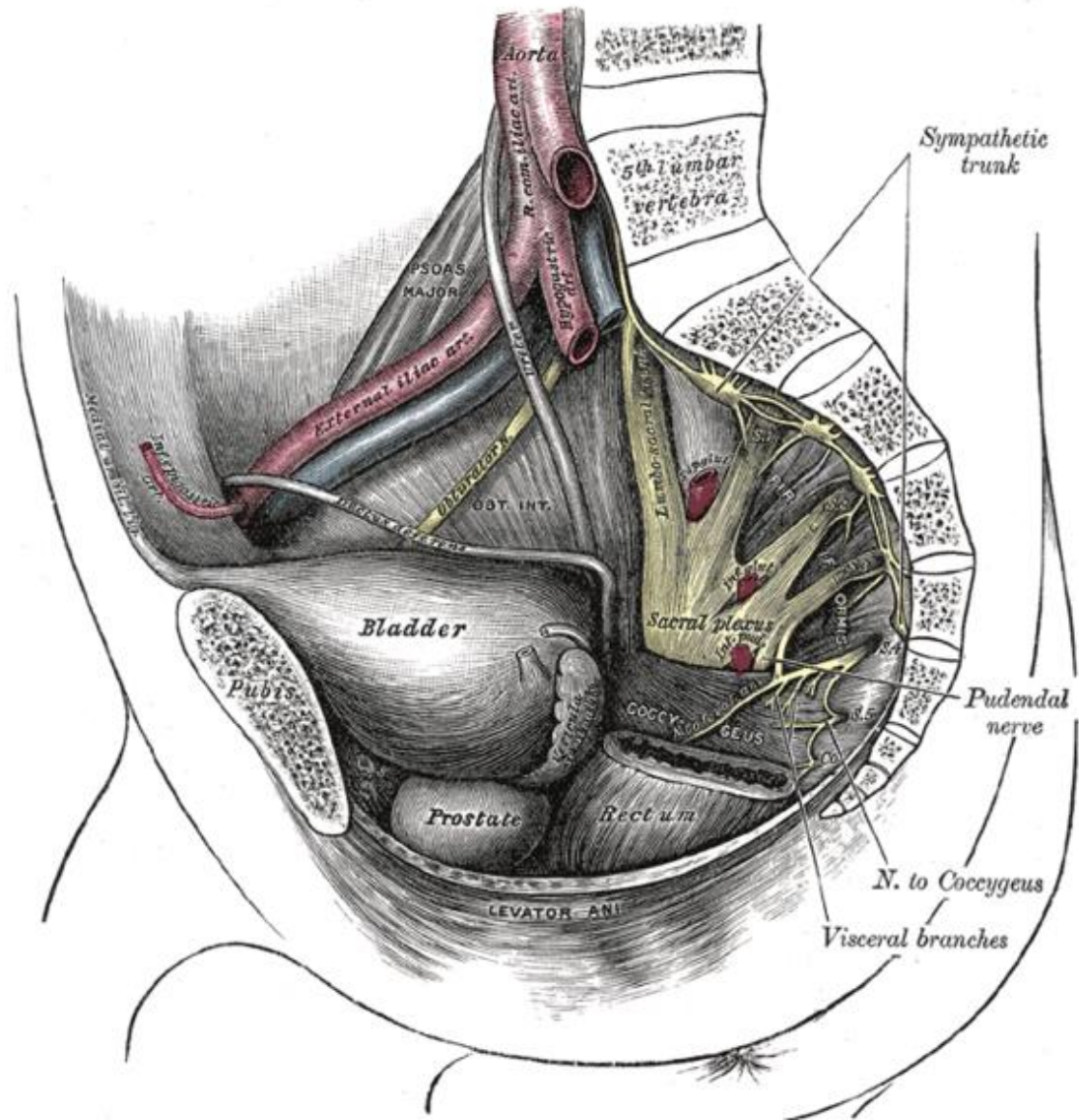
- 4 cm long
- 1 cm wide

origin: L4

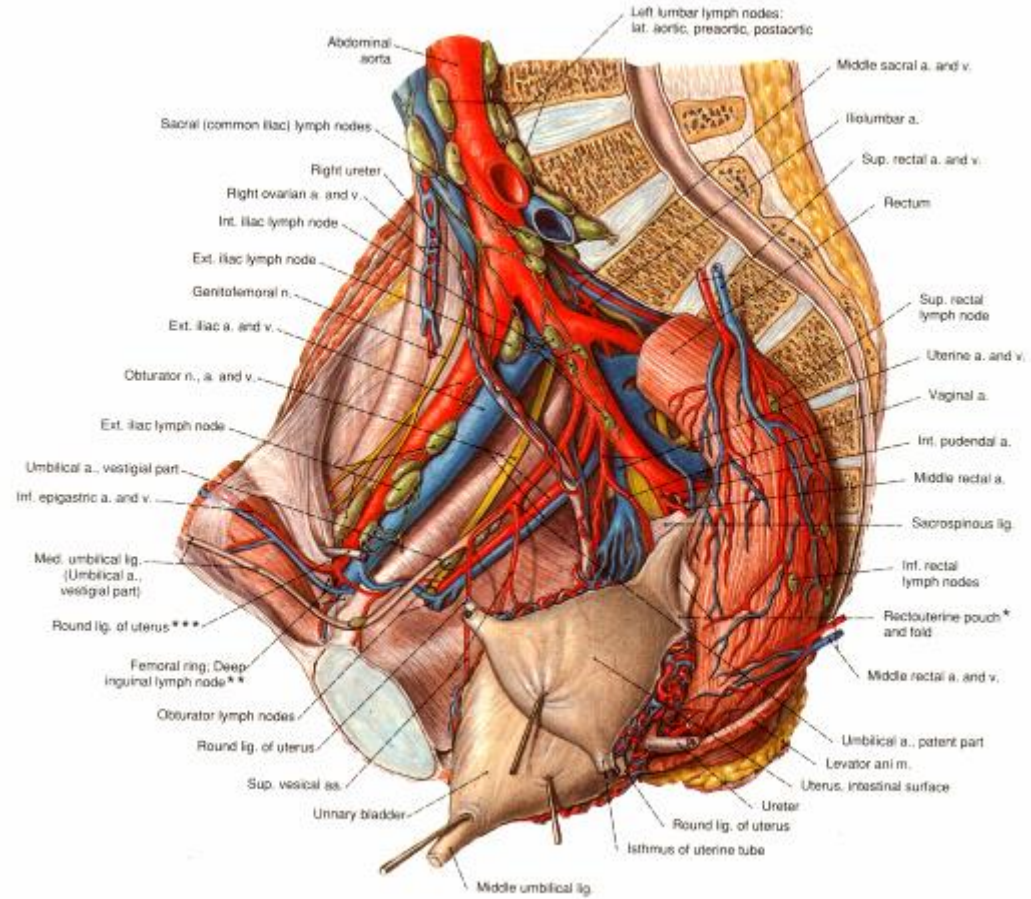
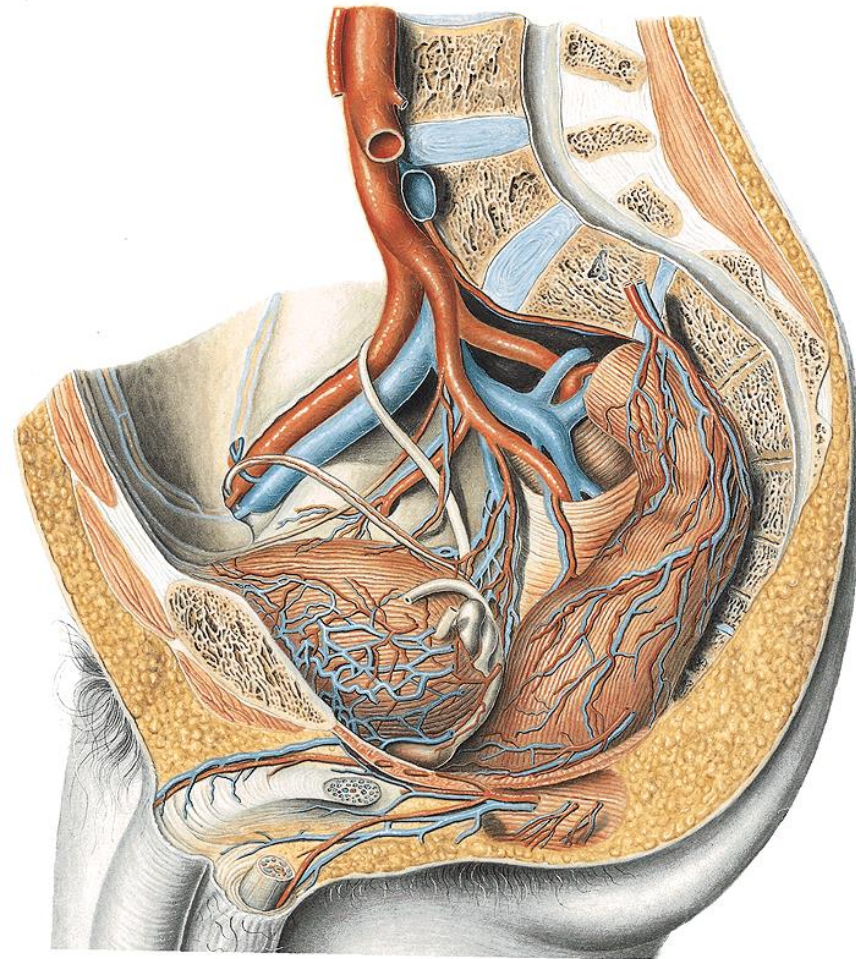
- medial to m. psoas major
- dorsal to ureter

end: bifurcation  
ventral to articulatio  
sacroiliaca

- a. iliaca externa
- a. iliaca interna

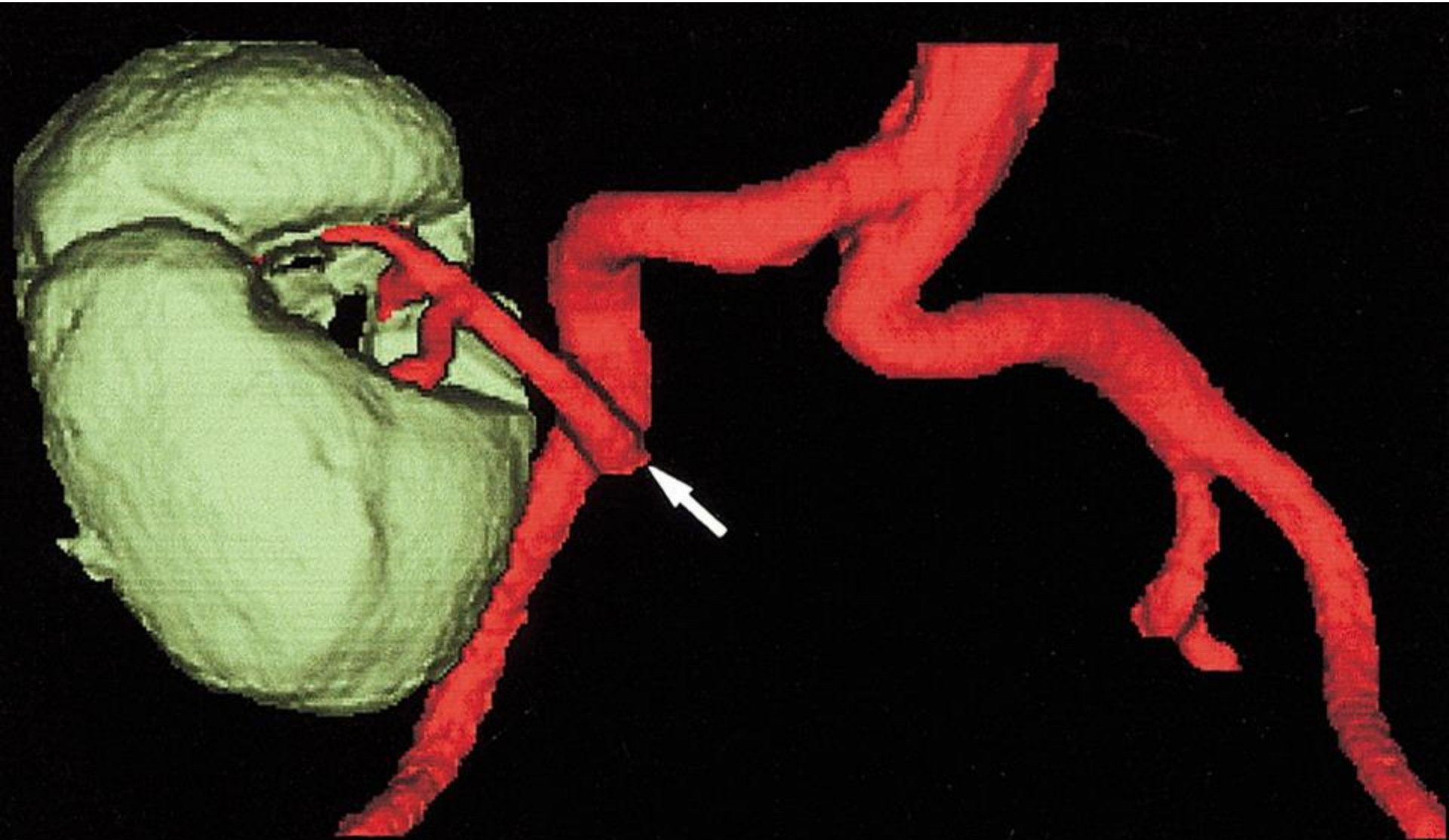


# Arteriae iliaca





# Transplanted kidney to AIC

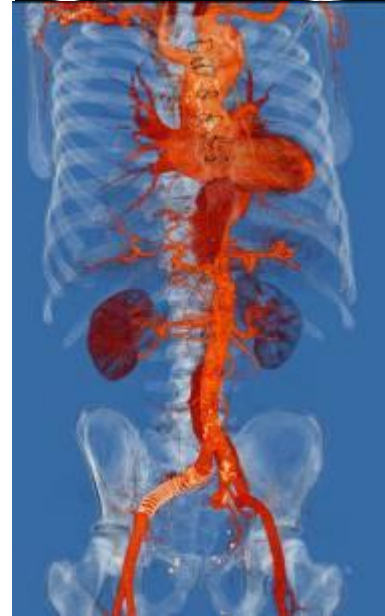
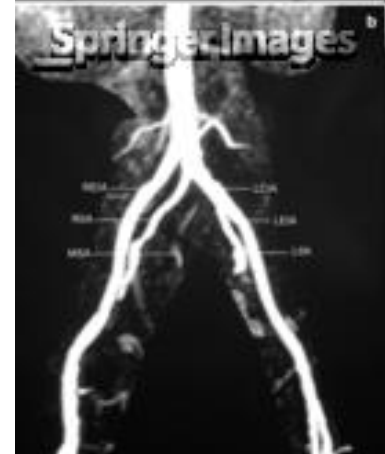
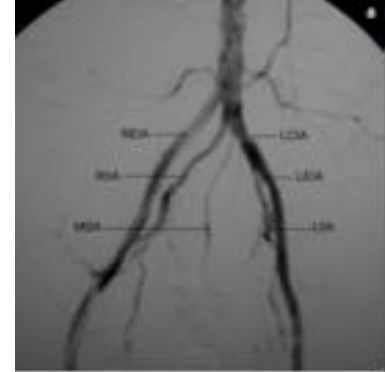# Arteria iliaca externa

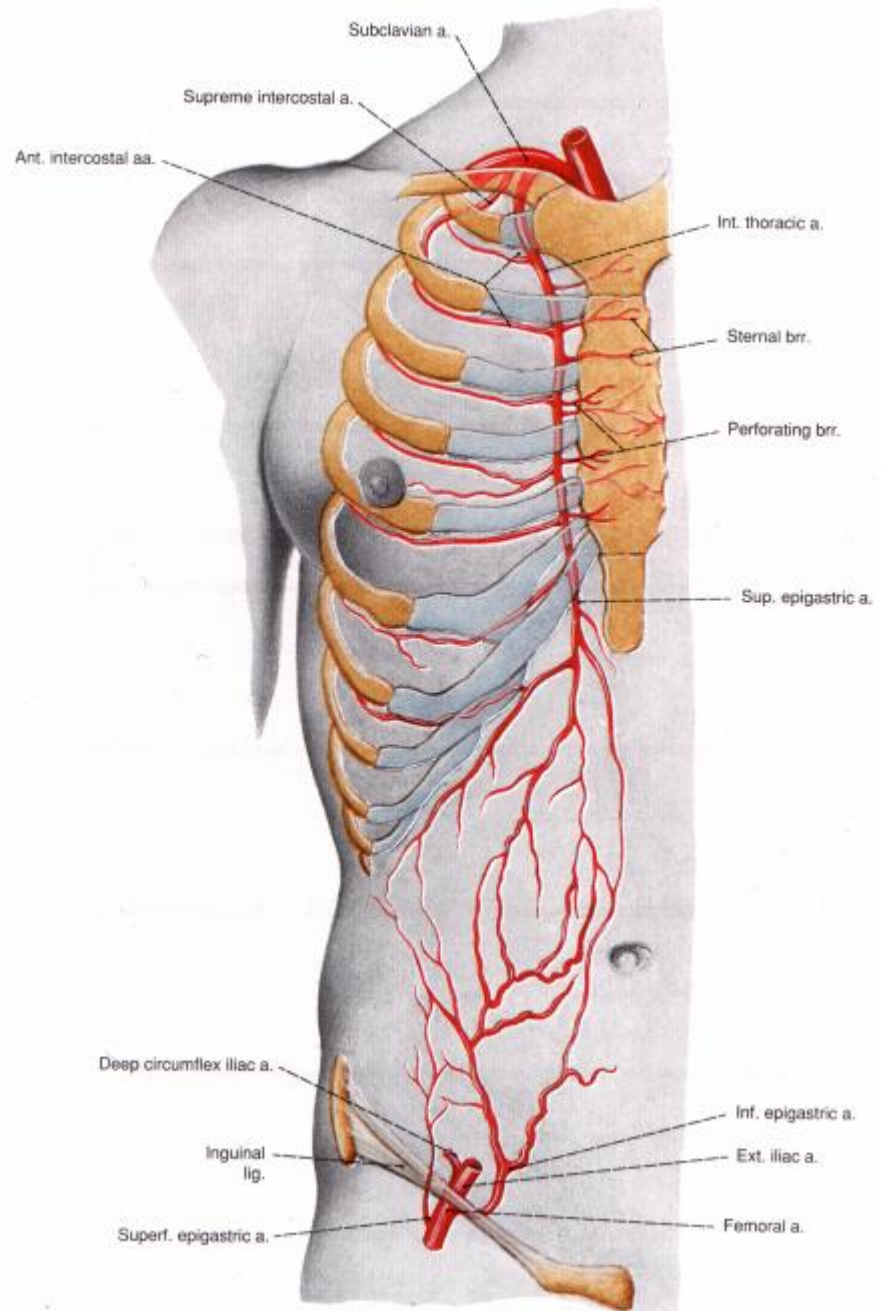
articulatio sacroiliaca → lacuna vasorum  
(→ a. femoralis)

dorsal to ureter

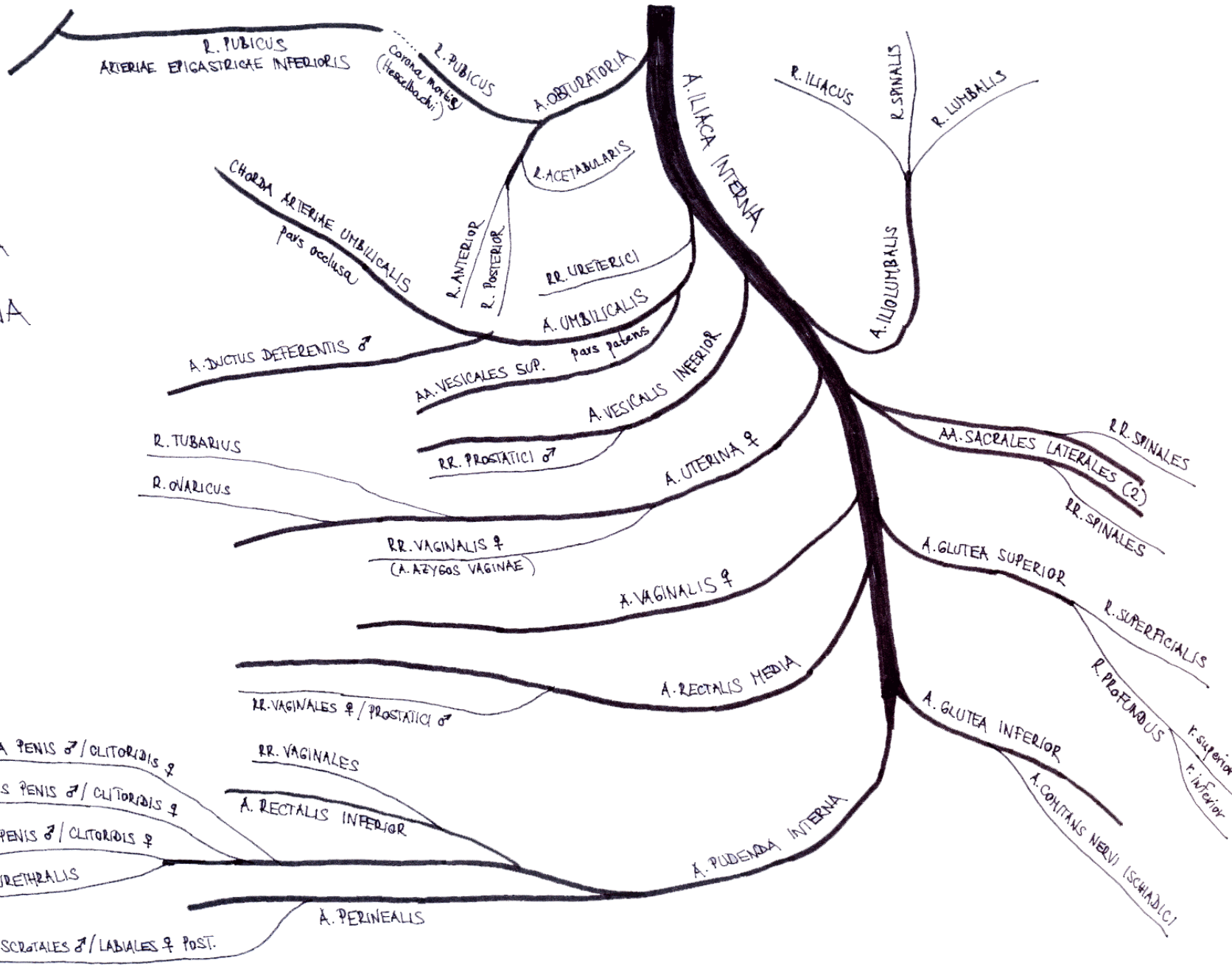
- a. circumflexa ilium profunda
- a. epigastrica inferior
  - r. pubicus
  - *a. obturatoria accessoria/aberrans = corona mortis Hesselbachi*
  - a. crematerica ♂ / a. lig. teretis uteri ♀
  - r. medialis + lateralis
  - *cutaneous perforators*
  - *clinical abbreviation „DIEP“*
  - *cutaneous / musculo-cutaneous flaps*



# Arterie epigastricae



V  
 VEVE  
 ARTERIA  
 ILIACA  
 INTERNA



R. PUBICUS  
 ARTERIAE EPICASTRICAE INFERIORIS

R. PUBICUS  
 Corona mortis  
 (Hesselbach)

A. OBTURATORIA

R. ILLIACUS

R. SPINALIS

R. LUMBALIS

A. ILIACA INTERNA

A. ILLIOLUMBALIS

R. ACETABULARIS

CHORDA ARTERIAE UMBILICALIS  
 pars oclusa

R. ANTERIOR  
 R. POSTERIOR

RR. URETERICI

A. UMBILICALIS  
 pars patens

A. DUCTUS DEFERENTIS ♂

AA. VESICALES SUP.

A. VESICALIS INFERIOR

RR. PROSTATICI ♂

A. UTERINA ♀

AA. SACRALES LATERALES (2)

RR. SPINALES

RR. SPINALES

R. TUBARIUS

R. OVARICUS

RR. VAGINALIS ♀  
 (A. AZYGOS VAGINAE)

A. VAGINALIS ♀

A. GLUTEA SUPERIOR

R. SUPERFICIALIS

R. PROFUNDUS

r. superior  
 r. inferior

A. RECTALIS MEDIA

RR. VAGINALES ♀ / PROSTATICI ♂

A. GLUTEA INFERIOR

A. COCHLANS NERVI ISCHIADICI

A. PROFUNDA PENIS ♂ / CLITORIDIS ♀

A. DORSALIS PENIS ♂ / CLITORIDIS ♀

A. BULBI PENIS ♂ / CLITORIDIS ♀

A. URETHRALIS

RR. VAGINALES

A. RECTALIS INFERIOR

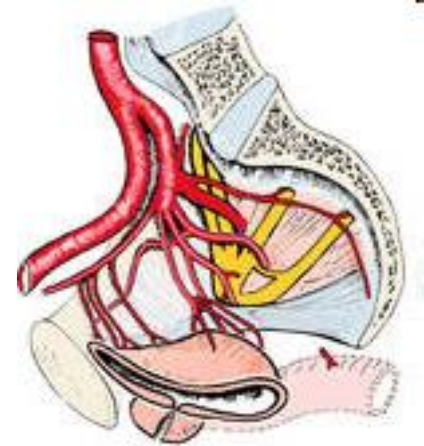
A. PUDENDA INTERNA

A. PERINEALLIS

RR. SCROTALIS ♂ / LABIALES ♀ POST.

# Arteria iliaca interna

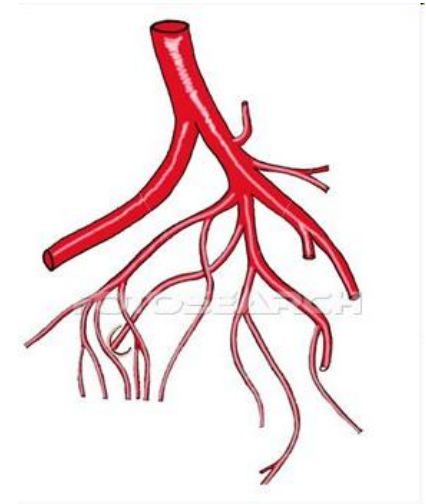
- lesser pelvis + buttocks
- obsolete term „a. hypogastrica“
- short (3-4 cm)
  - anterior division
    - 3 branches
  - posterior division
    - all organs of lesser pelvis
    - *ligation in postpartal haemorrhage*



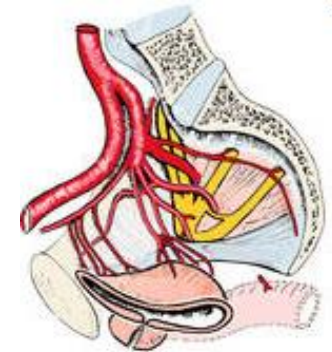
# Arteria iliaca interna - branches

## parietal branches: 5

- a. iliolumbalis
  - r. iliacus, lumbalis, spinalis
- a. obturatoria
  - *canalis obturatorius*
- aa. sacrales laterales sup. + inf. (→2)
  - *foramina sacralia anteriora*
  - rr. spinales
- a. glutea superior
  - *foramen suprapiriforme*
  - r. superficialis + profundus
- a. glutea inferior
  - *foramen infrapiriforme*
  - a. comitans nervi ischiadici

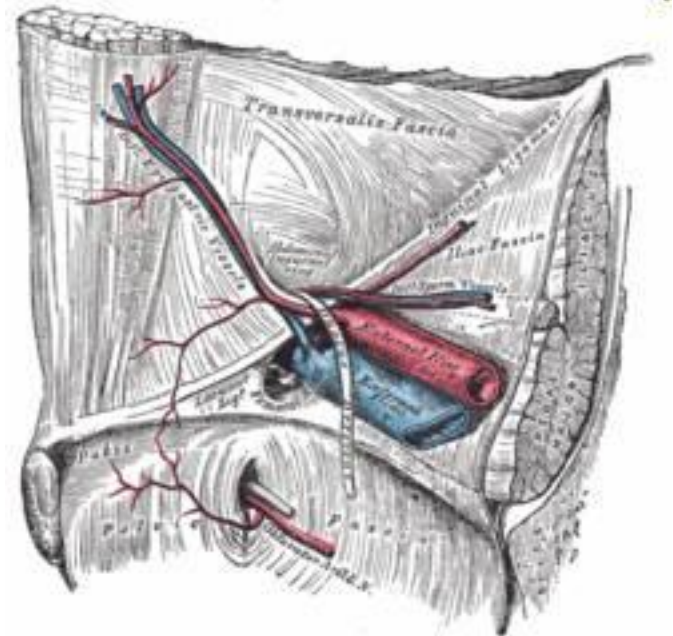
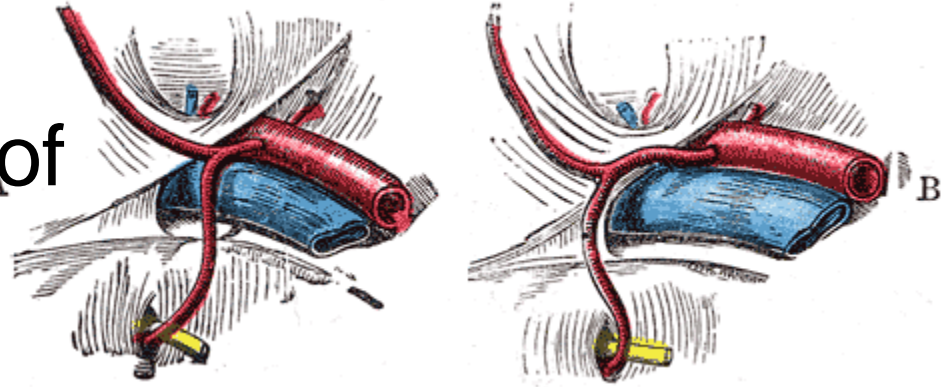


gd304006 www.fotosearch.com

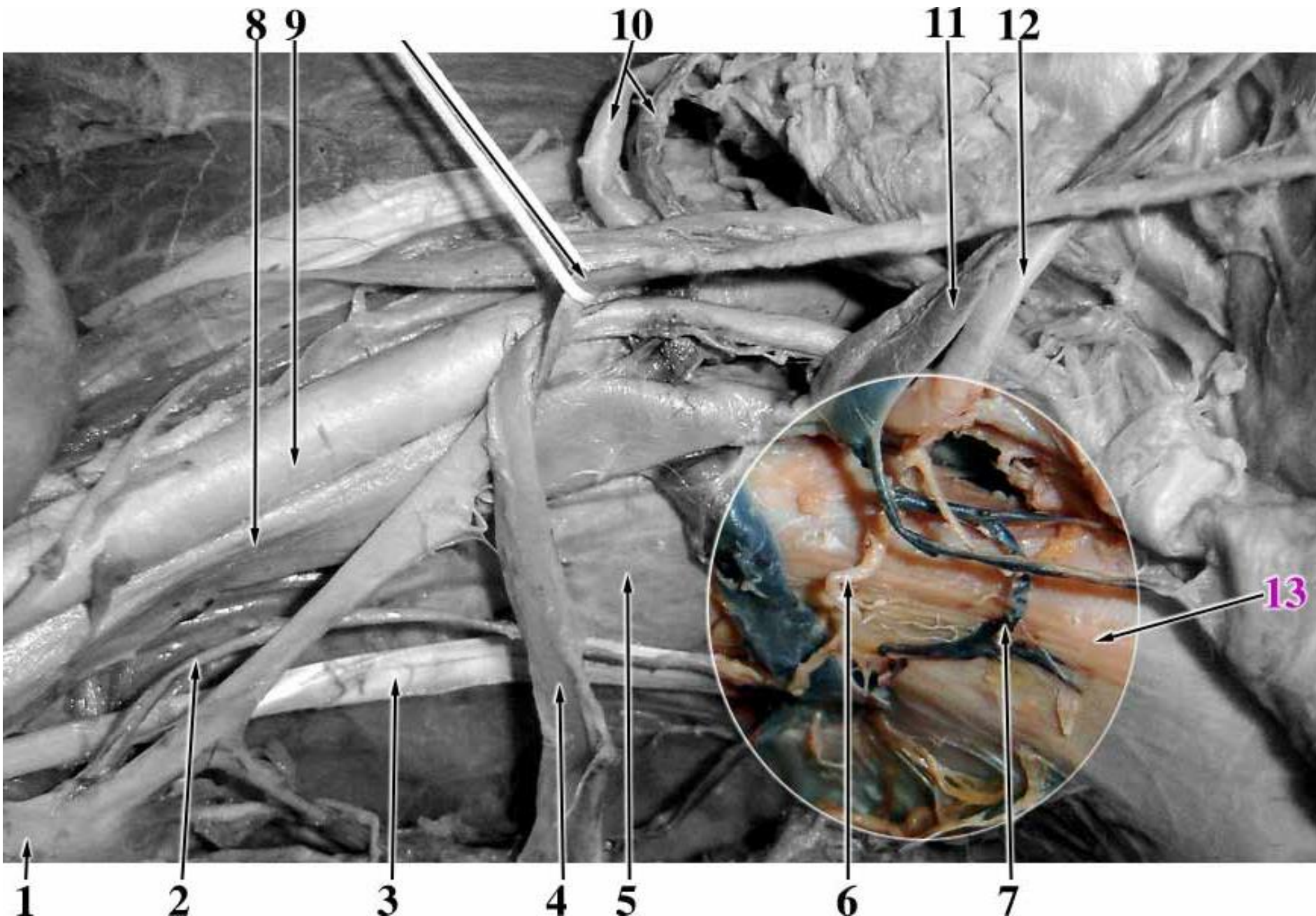


# Arteria obturatoria

- 2nd ventral branch
- from anterior division of AII
- caudal to nerve
- r. pubicus
- *corona mortis*
- canalis obturatorius
- r. acetabularis
- r. anterior + posterior
- medial side of thigh



# Vasa obturatoria accessoria aberrans

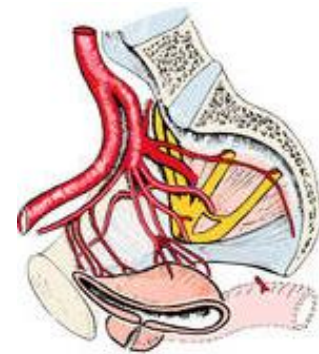
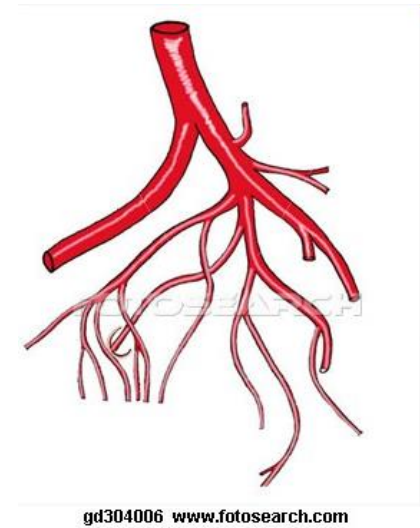




# Arteria iliaca interna – branches

## visceral branches: 6

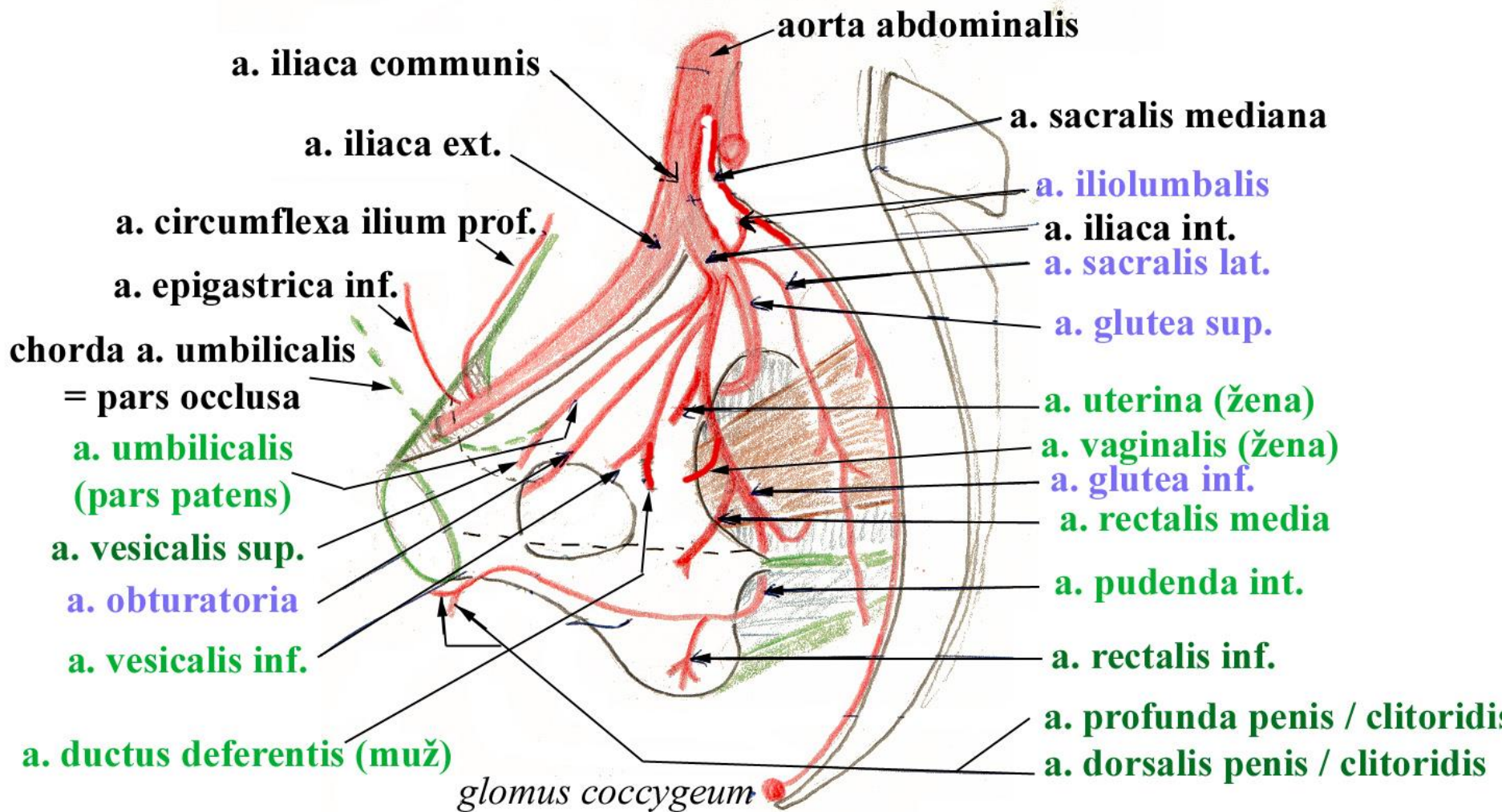
- a. umbilicalis
  - aa. vesicales superiores
  - a. ductus deferentis ♂
- a. vesicalis inferior
  - rr. prostatici ♂
- a. uterina ♀
  - r. ovaricus
  - r. tubarius
  - ventral to ureter
- a. rectalis media
  - rr. prostatici ♂ / rr. vaginales ♀
- a. vaginalis ♀
- a. pudenda interna



*parietální větve*

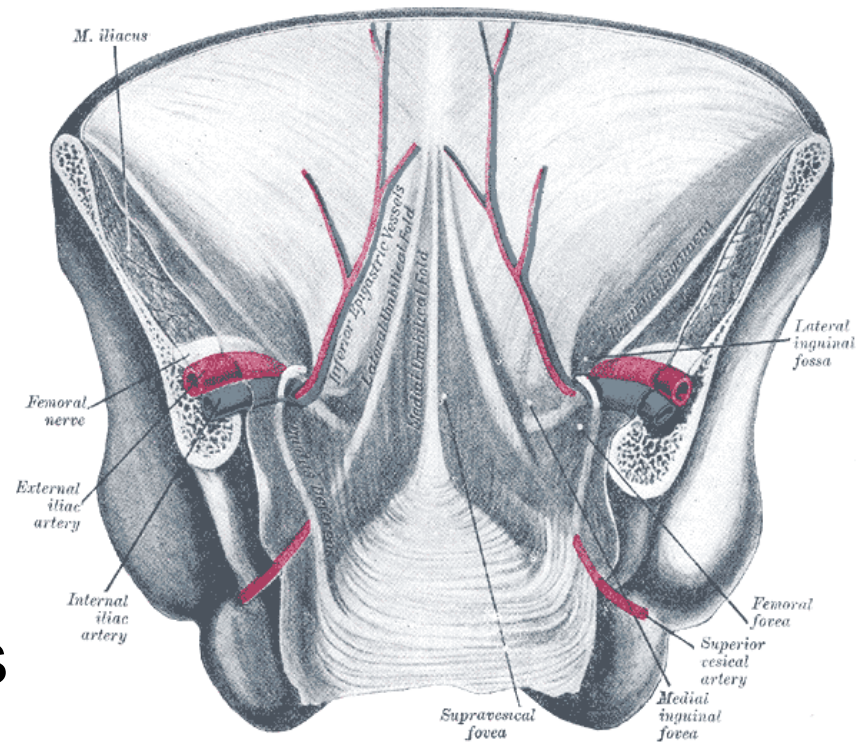
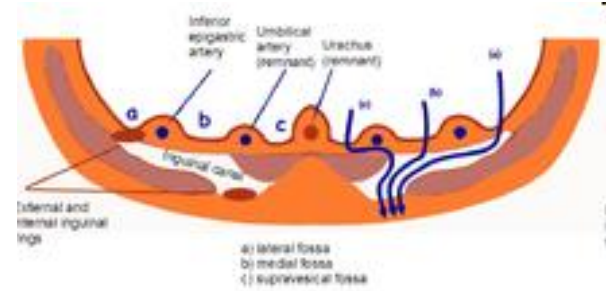
# TEPNY PÁNVE

*viscerální větve*



# Arteria umbilicalis

- pars patens
  - aa. vesicales superiores
  - a. ductus deferentis ♂
- pars occlusa
  - fetal vessel with unoxygenated blood leading to placenta
  - lig. umbilicale mediale (chorda a. umbilicalis)
  - fascia vesicoumbilicalis



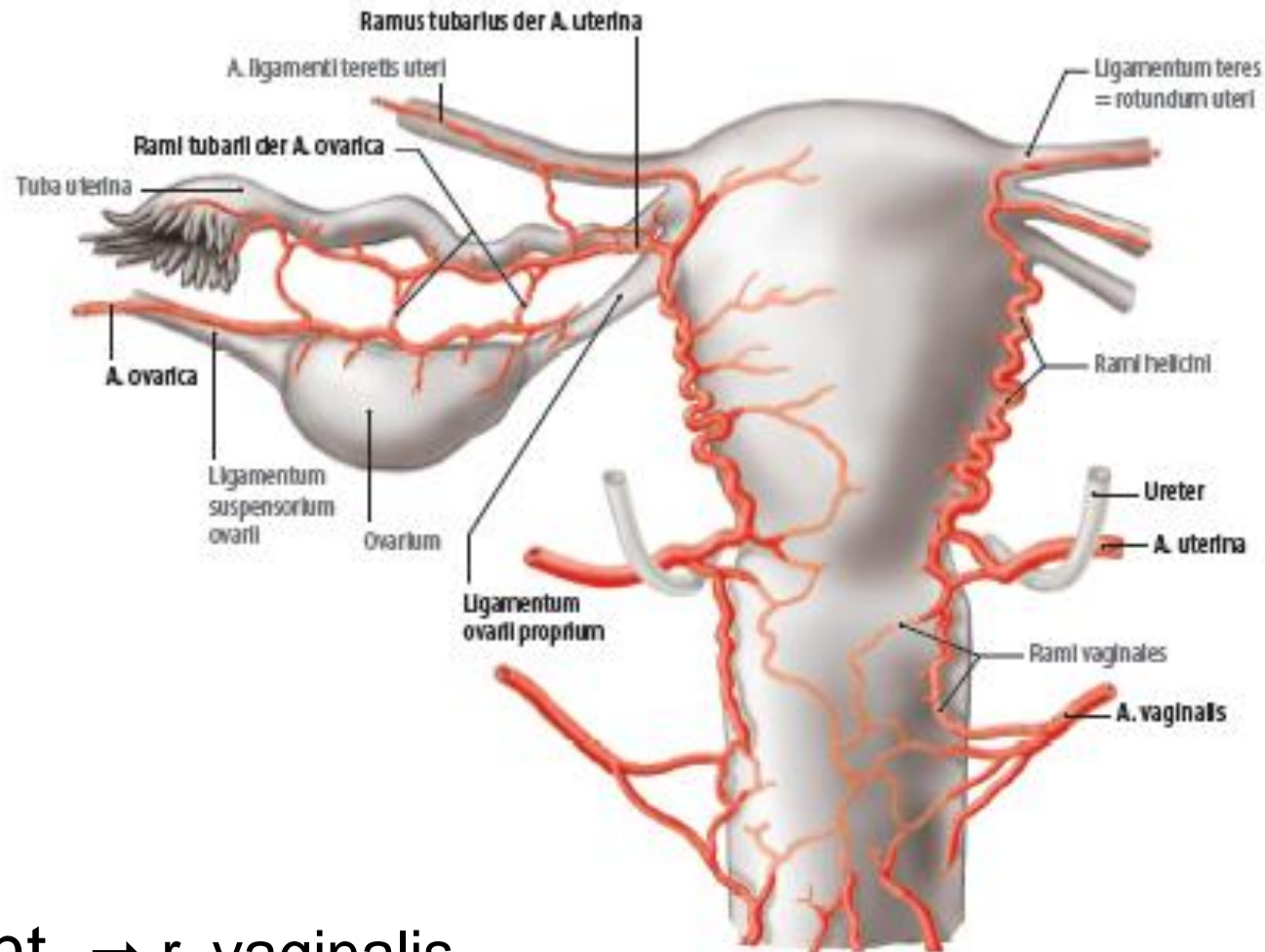
# Arteries of female internal genital organs

## Ao. abdominalis:

- a. ovarica
  - r. tubarius
  - r. ovaricus

## A. iliaca interna:

- a. uterina
  - r. tubarius
  - r. ovaricus
  - r. vaginalis
- a. vaginalis
- a. pudenda int. → r. vaginalis

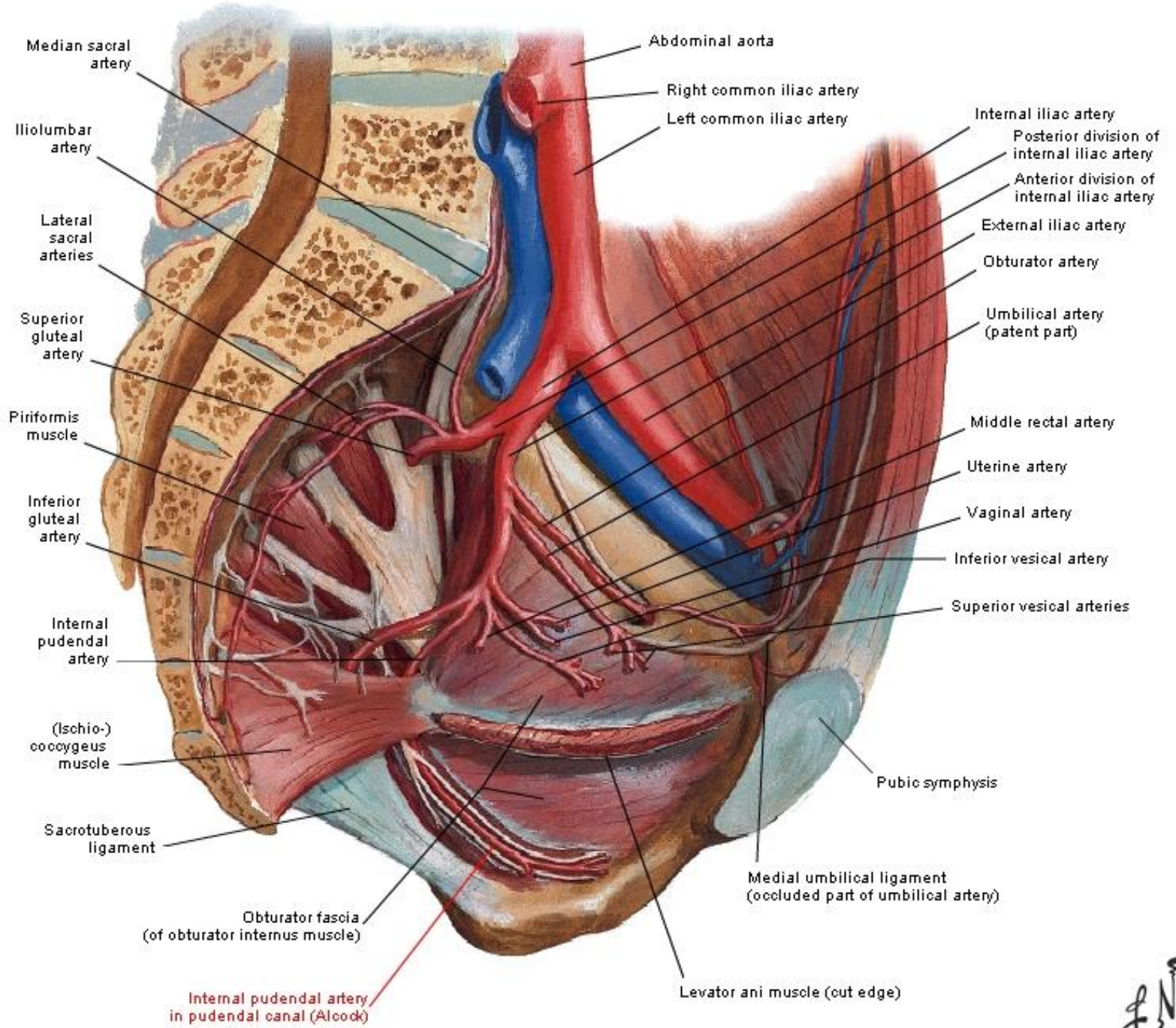


# Arteria pudenda interna

topography: foramen infrapiriforme → foramen ischiadicum minus → fossa ischioanalis (canalis pudendalis *Alcocki*)

branches:

- a. rectalis inferior
  - rr. vaginales ♀
- a. perinealis
- rr. scrotales ♂ / labiales ♀ anteriores
- a. urethralis
- a. bulbi penis ♂ / vestibuli ♀
- a. dorsalis penis ♂ / clitoridis ♀
- a. profunda penis ♂ / clitoridis ♀



Median sacral artery

Iliolumbar artery

Lateral sacral arteries

Superior gluteal artery

Piriformis muscle

Inferior gluteal artery

Internal pudendal artery

(Ischio-)coccygeus muscle

Sacrotuberous ligament

Obturator fascia (of obturator internus muscle)

Internal pudendal artery in pudendal canal (Alcock)

Abdominal aorta

Right common iliac artery

Left common iliac artery

Internal iliac artery

Posterior division of internal iliac artery

Anterior division of internal iliac artery

External iliac artery

Obturator artery

Umbilical artery (patent part)

Middle rectal artery

Uterine artery

Vaginal artery

Inferior vesical artery

Superior vesical arteries

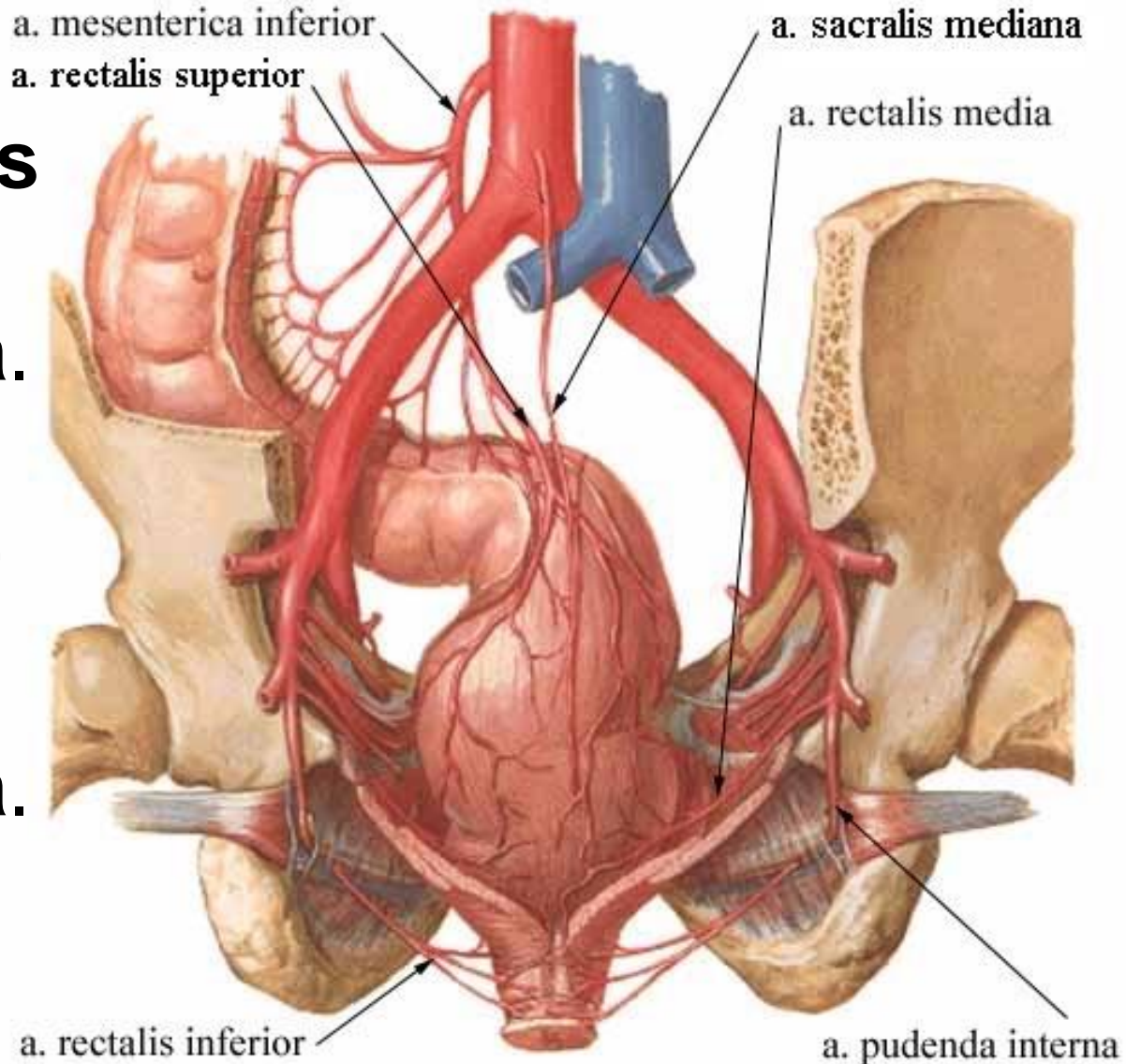
Pubic symphysis

Medial umbilical ligament (occluded part of umbilical artery)

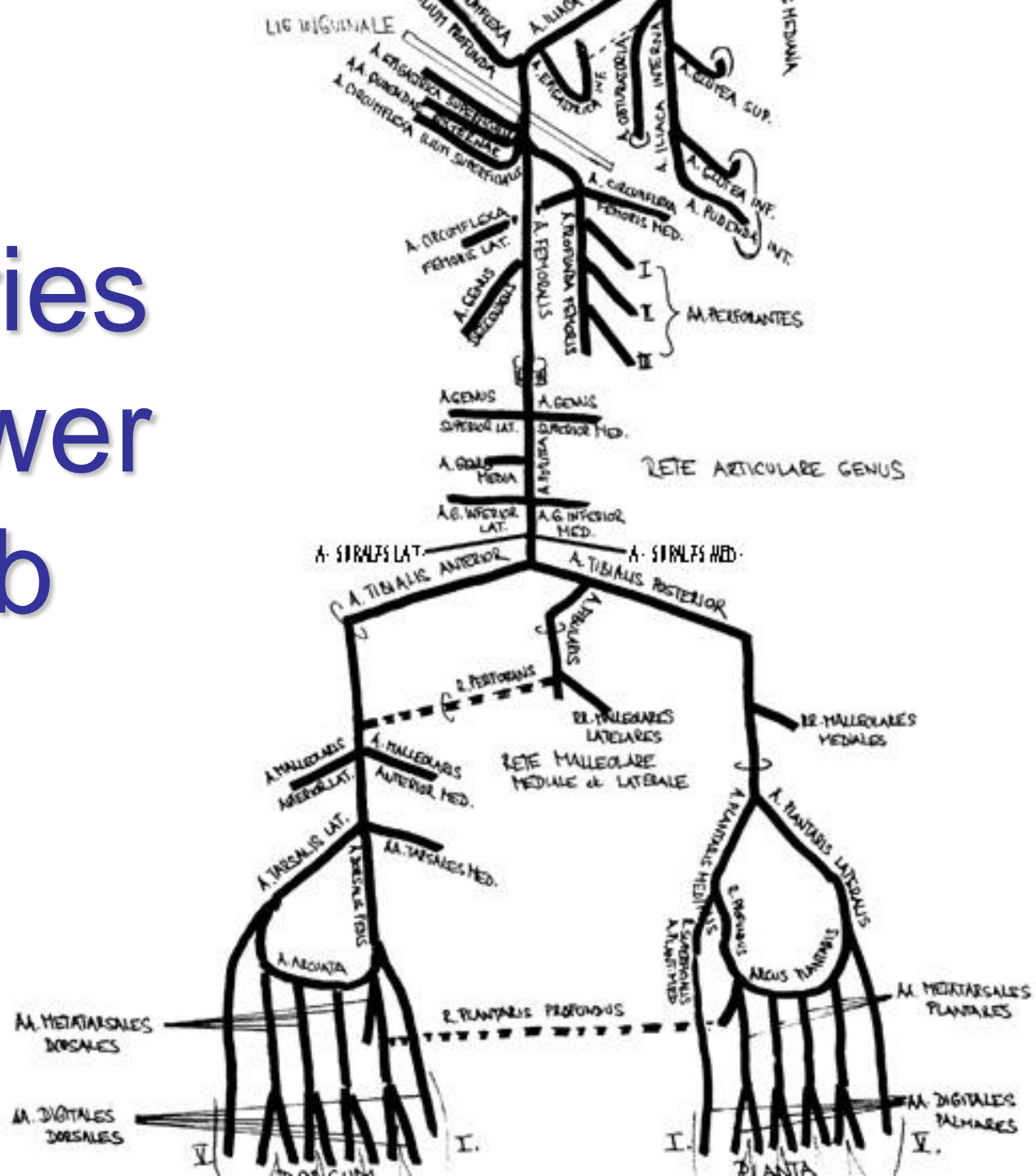
Levator ani muscle (out edge)

# Rectum

- **a. mesenterica inf.** → **a. rectalis sup.**
- **a. iliaca int.** → **a. rectalis media**
  - present in 50%, insignificant for rectum
- **a. iliaca int.** → **a. pudenda int.** → **a. rectalis inf.**



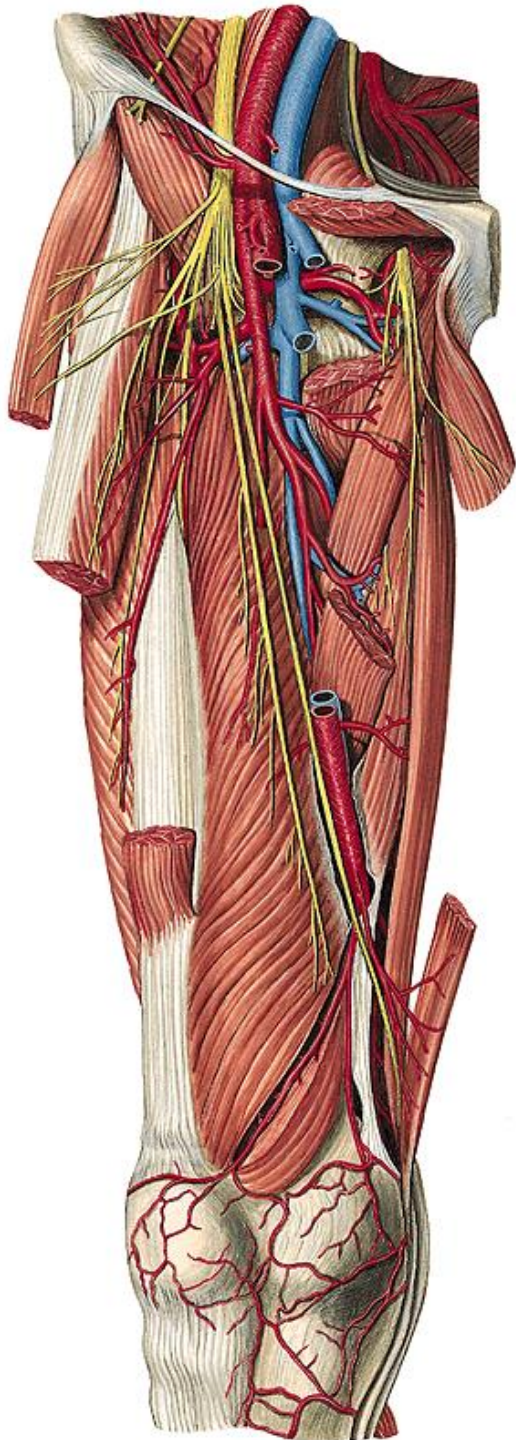
# Arteries of lower limb



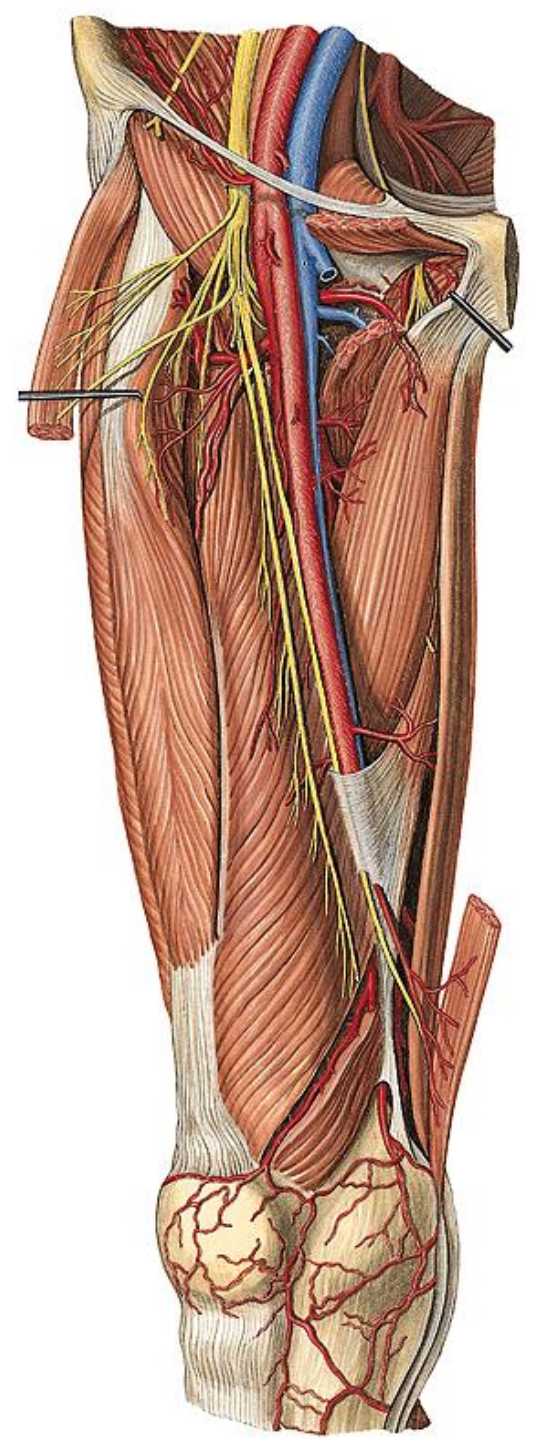


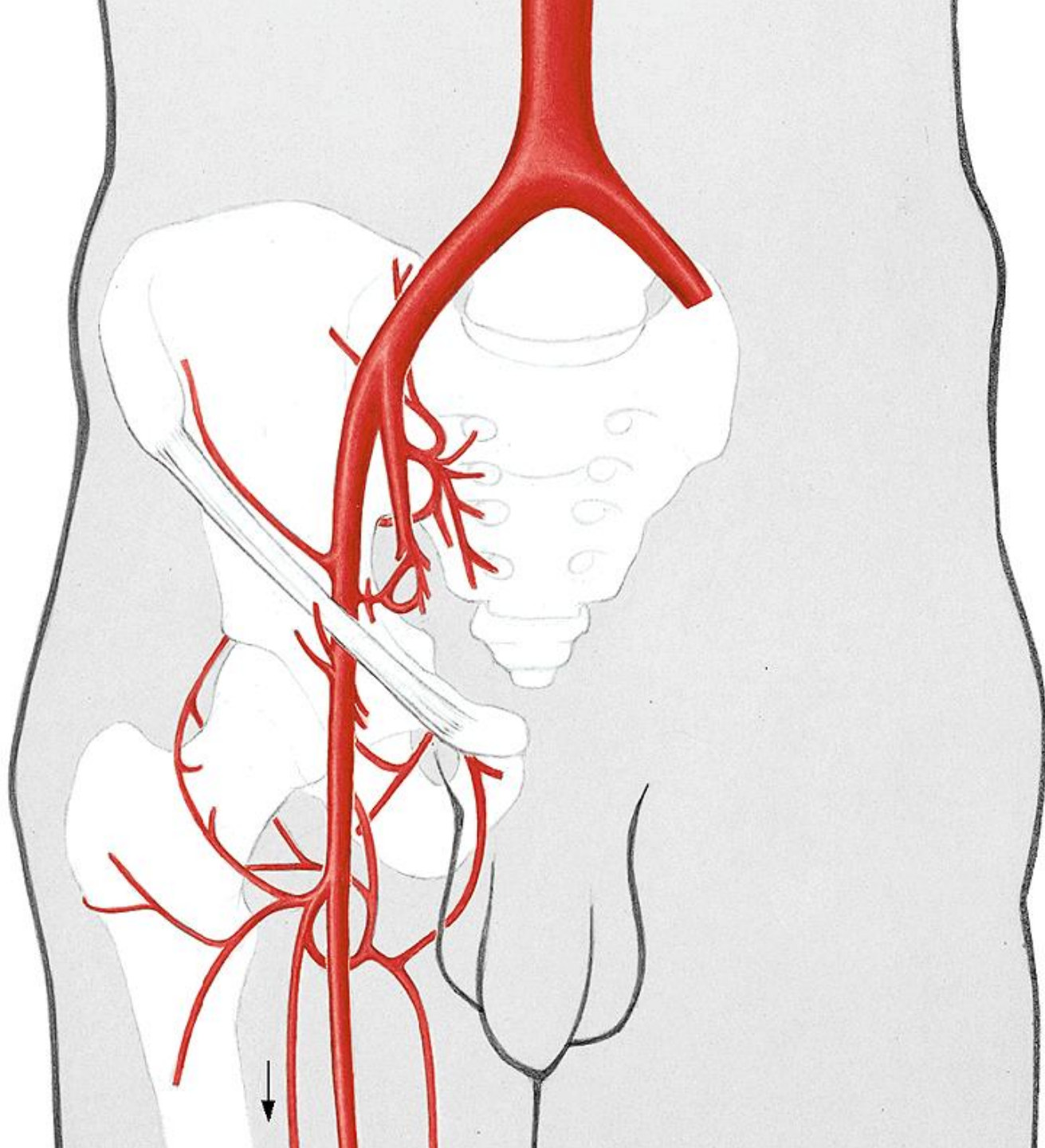
# Arteria femoralis

- compression point
- pulse measurement
- ultrasound examination
- catheterization site
- *atherosclerosis – by-passes*
- topography within lacuna vasorum: „CLOVAN“  
lacuna vasorum → trigonum femorale (fossa iliopectinea) → canalis adductorius *Hunteri* → hiatus adductorius
- 3 parts: trigonum femorale, subsartorial, inside canalis adductorius



# Arteria femoralis



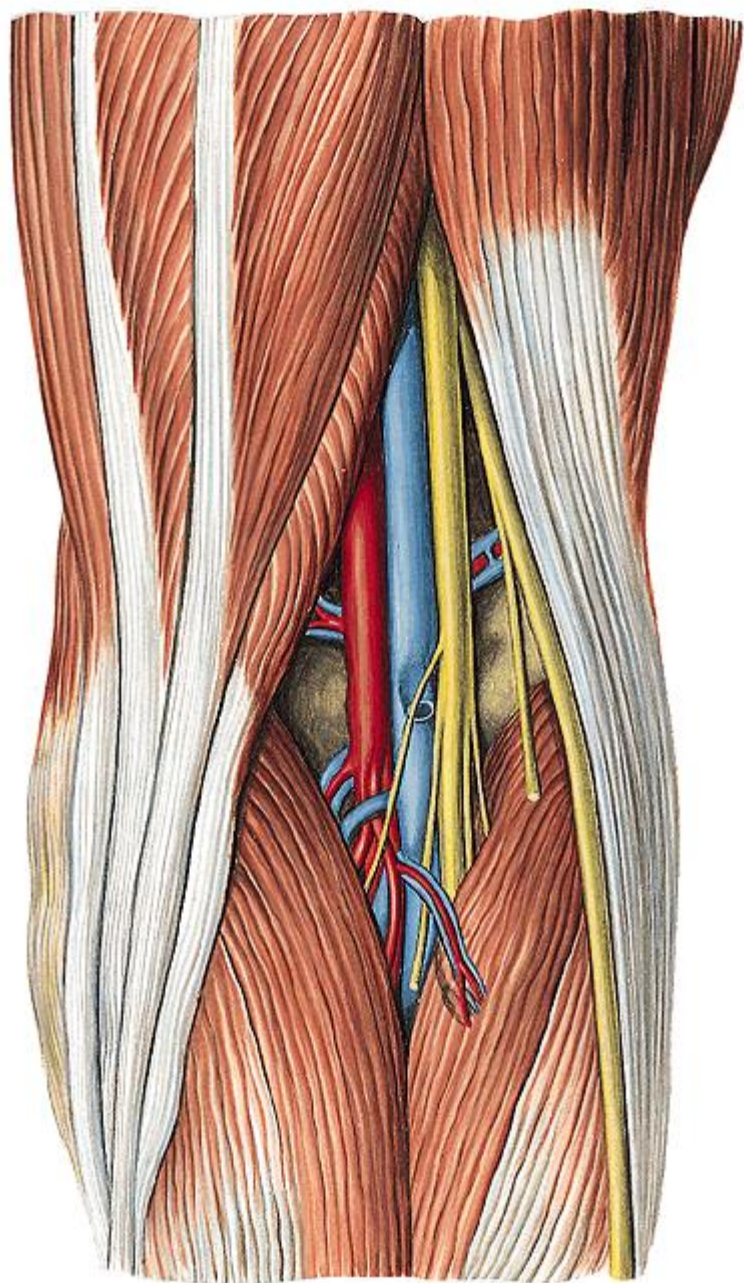
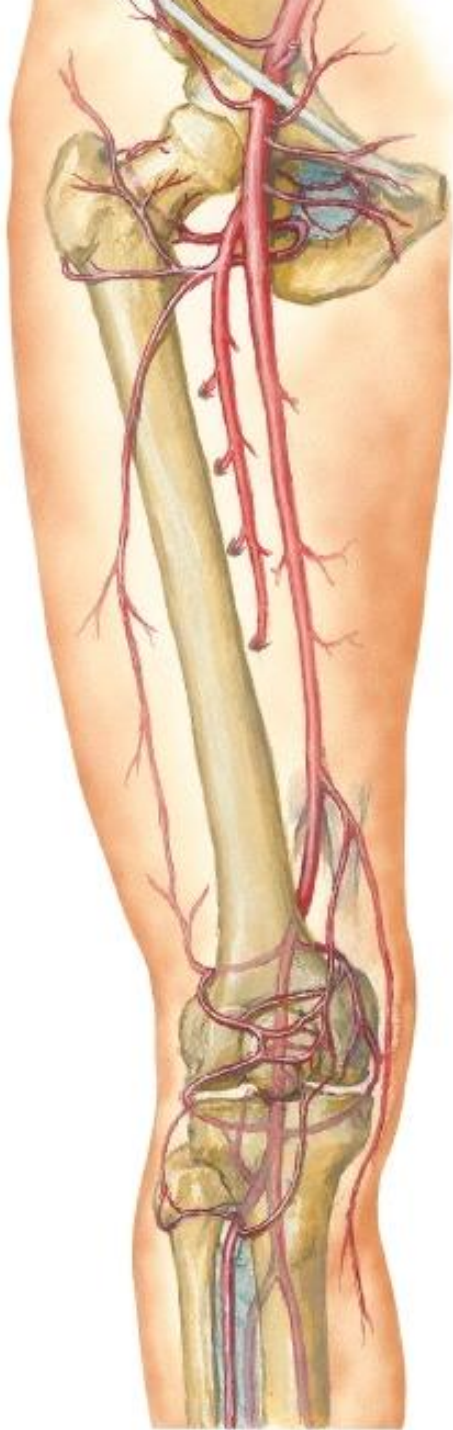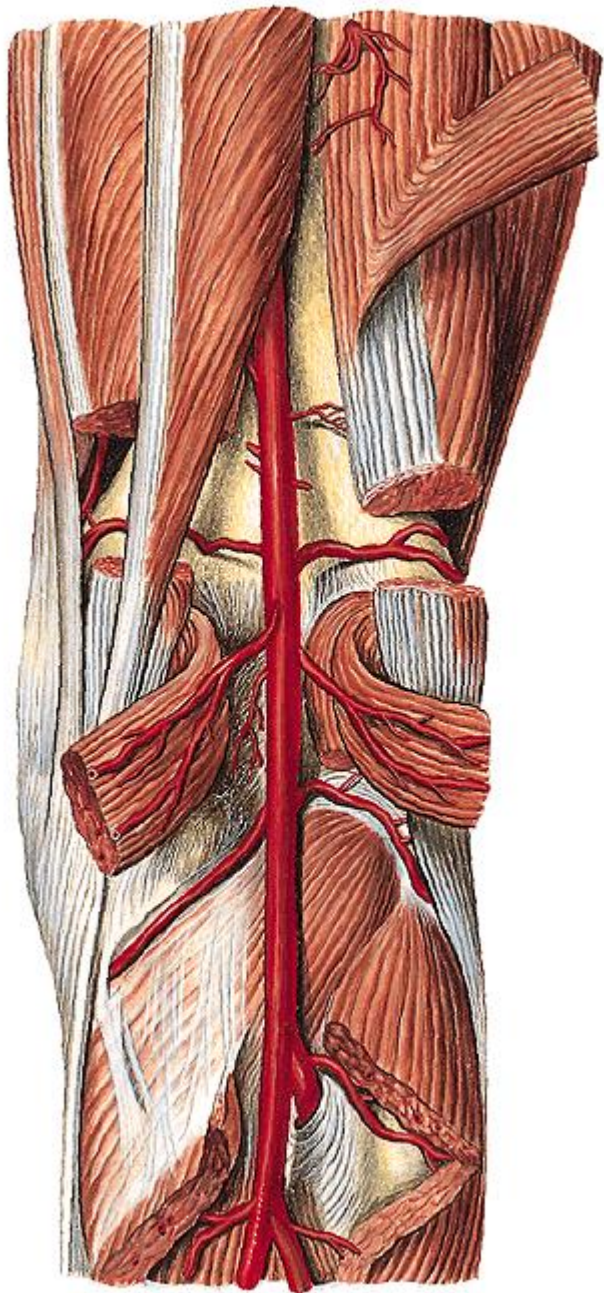


# Arteria femoralis – branches

- a. epigastrica superficialis
  - *pedicle artery for cutaneous flap*
- aa. pudendae externae
- a. circumflexa ilium profunda
- a. profunda femoris
  - a. circumflexa femoris med.
    - art. coxae (r. acetabularis), posterior side of thigh
    - a. circumflexa femoris lat.
      - r. ascendens, transversus, descendens
      - anterior and lateral side of thigh
  - aa. perforantes (3-4)
    - posterior side of thigh
    - *collaterals in stenosis/occlusion of a. femoralis*
- a. genus descendens
  - origin within canalis adductorius
  - r. saphenus, rr. articulares

# Arteria poplitea

- hiatus adductorius → fossa poplitea
- elastic artery (thin tunica media) - *aneurysms*
- rete articulare genus
- rete patellare
- *compression point*
- *pulse measurement*
- *ultrasound examination*
- topography within fossa poplitea: „AVEN“  
bifurcation into a. tibialis ant. + post.

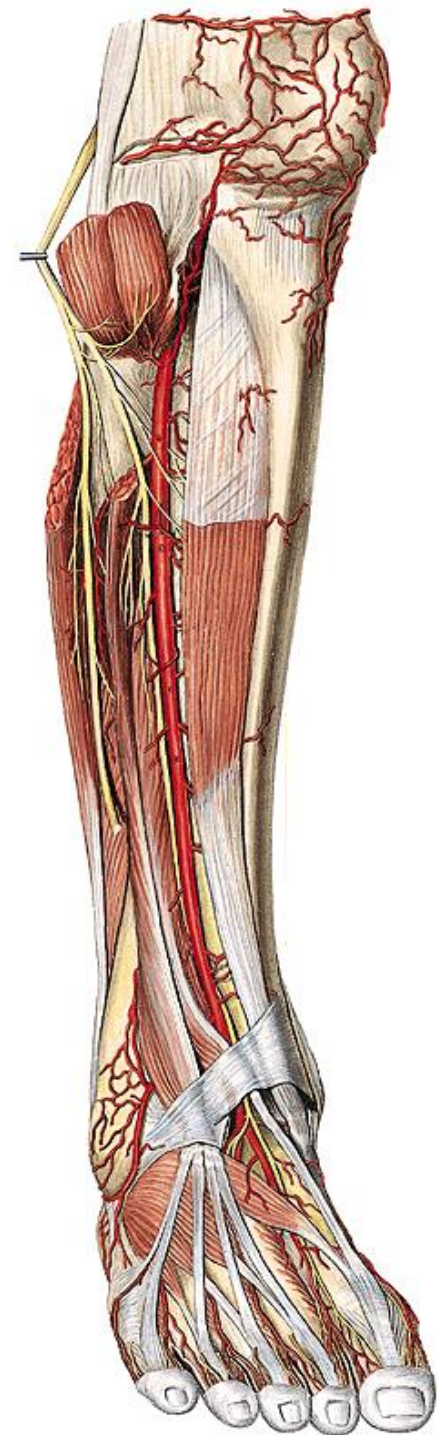


# Arteria poplitea – branches

- a. superior lat./med. genus
  - around epicondyles
- aa. surales
  - for heads of m. gastrocnemius
- a. media genus
  - into art. genus towards ligg. cruciata and membrana synovialis
- a. inferior lat./med. genus
  - under heads of m. gastrocnemius and ligg. collateralia
- *contribute to both rete*

# Arteria tibialis anterior

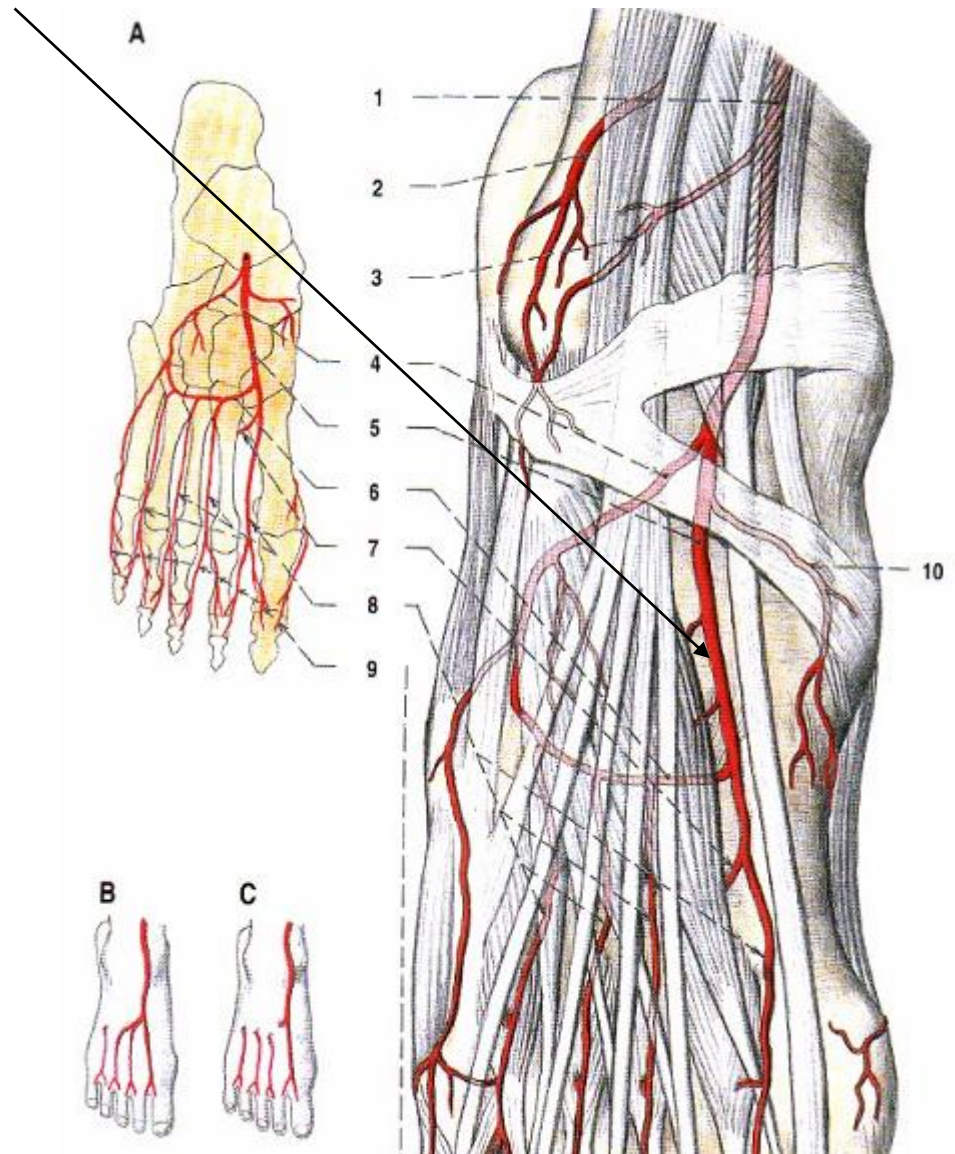
- proximally through membrana interossea cruris
- runs with n. fibularis profundus
- fixed to membrane with *vincula*
  - almost unmoveable → bleeding in fracture
- (a. recurrens tibialis post.)
  - before passage through membrane, into rete art. genus
- a. recurrens tibialis ant.
  - behind passage through membrane, into rete art. genus
- a. malleolaris anterior lat./med.
  - rete malleolare lat./med.
- under retinaculum mm. extensorum sup.+ inf.
  - a. dorsalis pedis





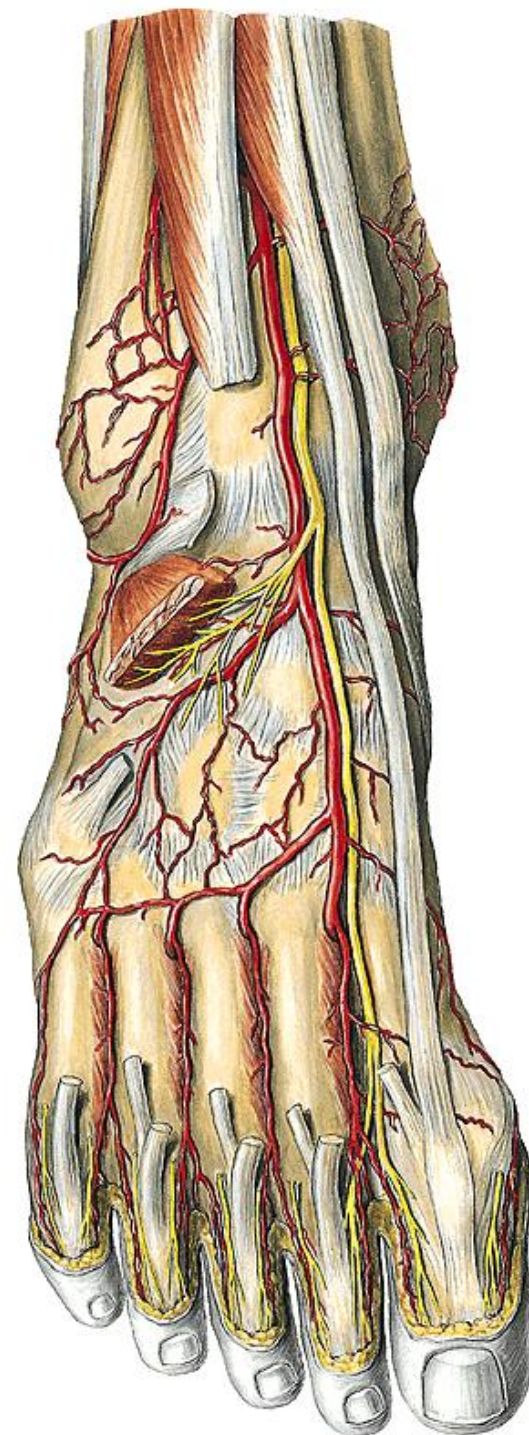
# Arteria dorsalis pedis

- *compression point*
- *pulse measurement*
- *ultrasound examination*
- continues as a. arcuata in 10% only



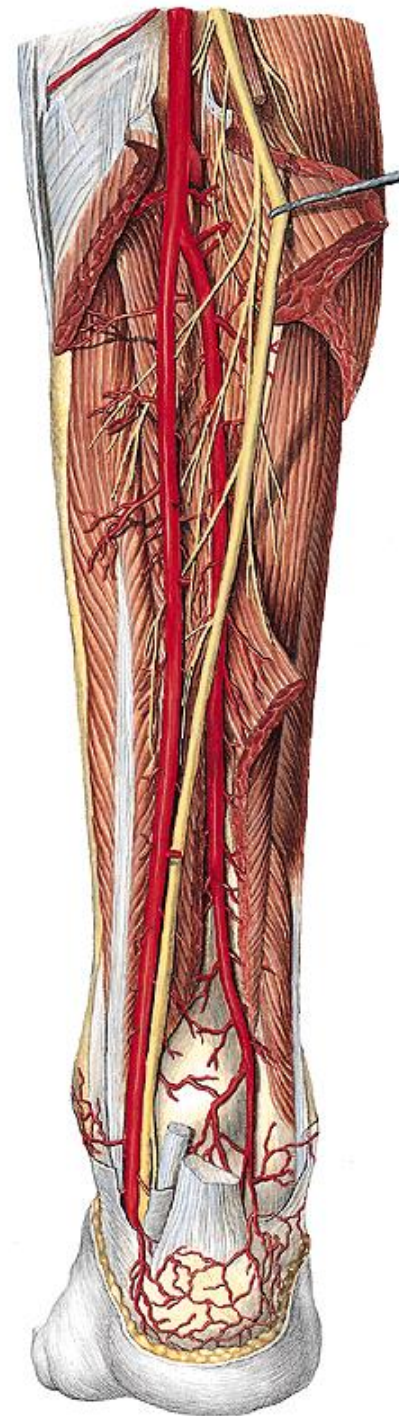
# Arteria dorsalis pedis

- a. tarsalis lat.
  - origin at level of caput tali
- aa. tarsales med.
- (a. arcuata – 10 %)
  - aa. metatarsales dorsales
  - aa. digitales dorsales
  - r. plantaris profundus
    - thick anastomosis with arcus plantaris prof.
    - 1st intermetatarsal space



# Arteria tibialis posterior

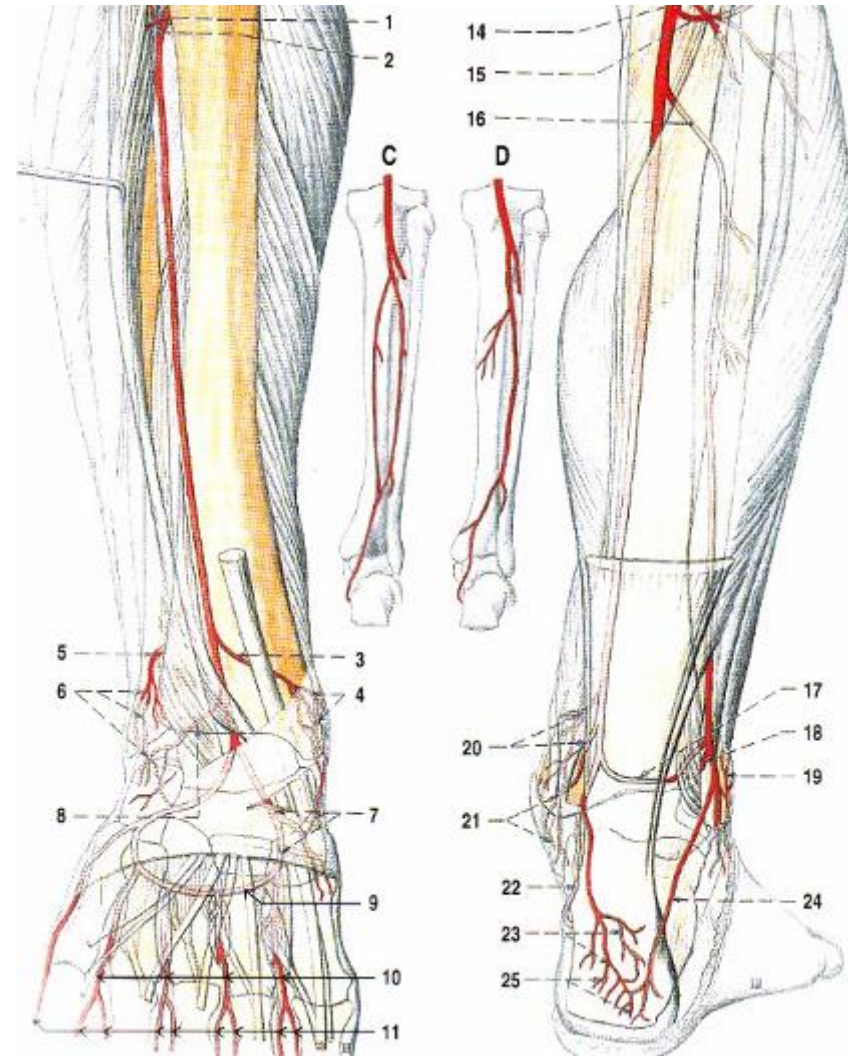
- arcus tendineus m. solei
- runs with s n. tibialis
- canalis malleolaris
  - topography: „TIDIVANEH“
  - bifurcation into a. plantaris med. + lat.
- *compression point*
- *pulse measurement*
- *ultrasound examination*



# Arteria tibialis posterior

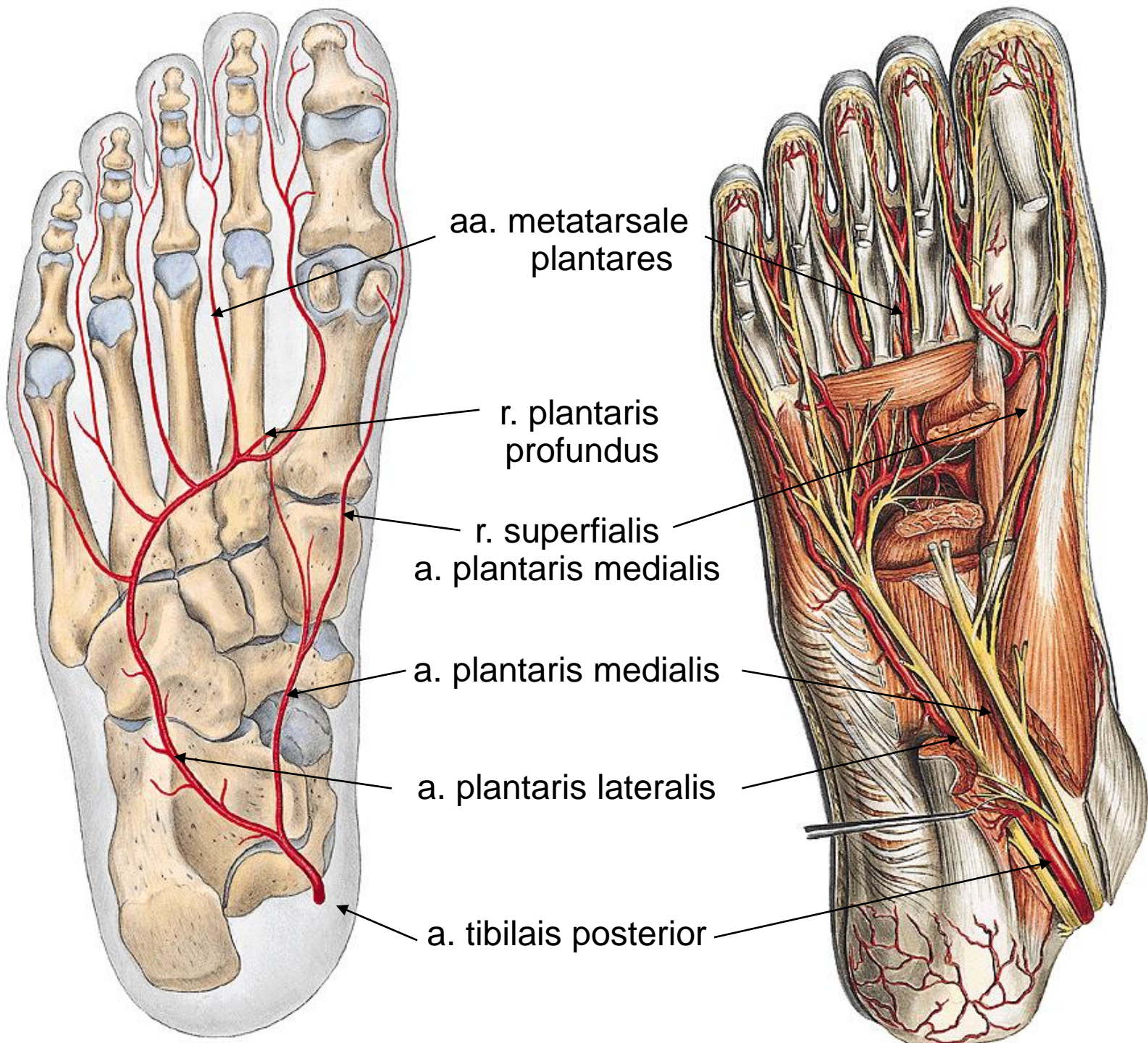
origin – clinical term „truncus tibiofibularis“

- r. circumflexus fibulae
- a. fibularis
  - canalis musculofibularis *Hyrtl*
  - r. communicans (with ATP)
  - r. perforans
    - through membrana interossea cruris ventrally
  - rr. malleolares lat.
  - rr. calcanei → rete calcaneum
  - *collateral in stenosis/occlusion of ATP*
- rr. malleolares med. → rete malleolare med.
- rr. calcanei → rete calcaneum



# Arteries of planta

- a. plantaris medialis
  - r. superficialis
  - r. profundus → arcus plantaris profundus
- a. plantaris lat. → arcus plantaris profundus
  - aa. metatarsales plantares
    - rr. perforantes (2 from each) – into aa. metatarsales dorsales
  - aa. digitales plantares communes → aa. digitales plantares propriae
- (arcus plantaris superficialis)



# Arteries of LL – clinical relevance

- atherosclerosis – ischaemic disease of lower limbs (peripheral vascular disease)
  - by-passes
  - stents
- diabetes mellitus (microangiopathy)
- trombangiitis obliterans (endangiitis von Winiwarter-Buerger)
- *claudications*