DEVELOPMENT OF THE DIGESTIVE SYSTEM

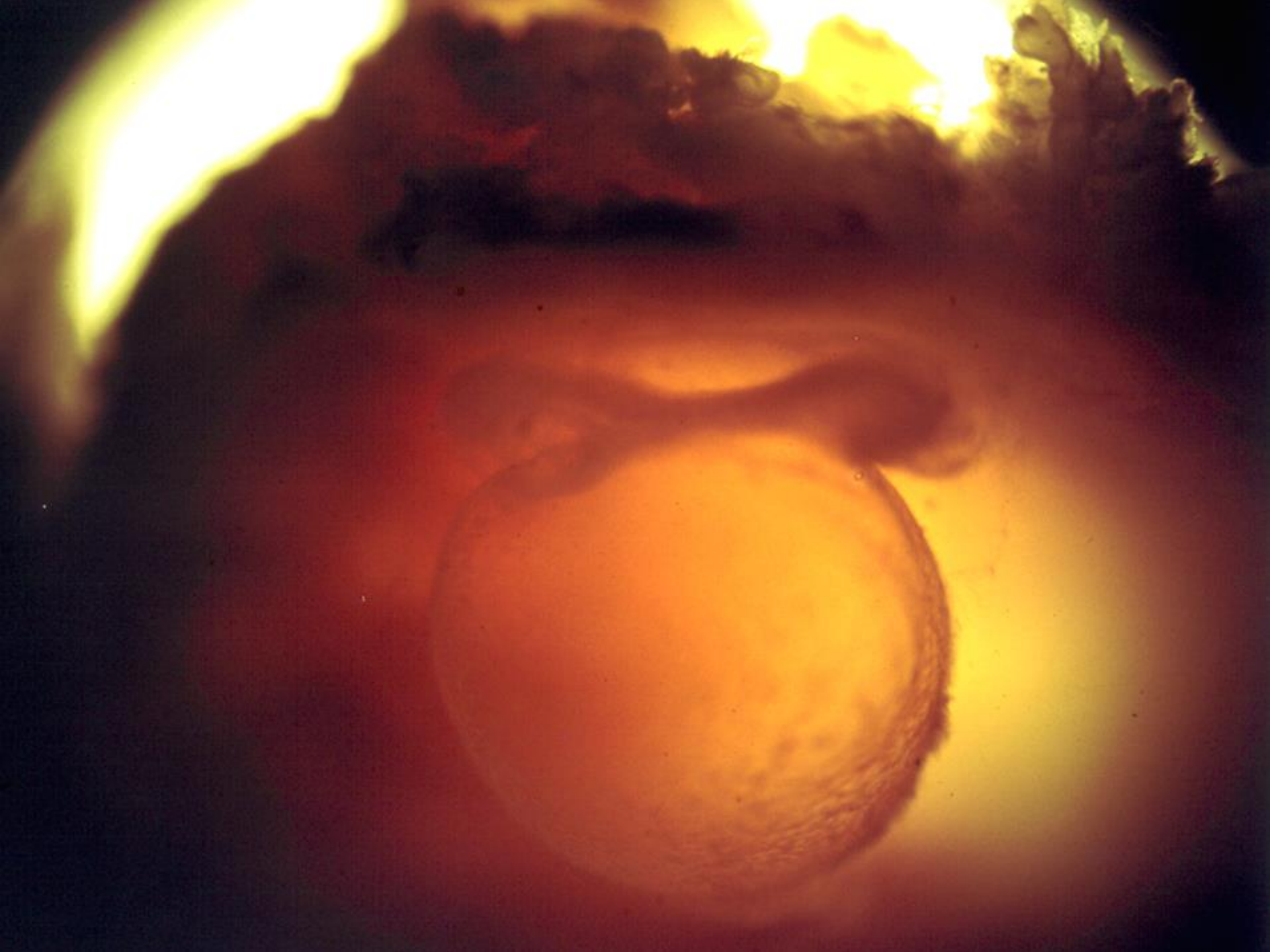

folding of the embryo and development of amniotic folds changes the trilaminar germ disc into the three-dimensional tube

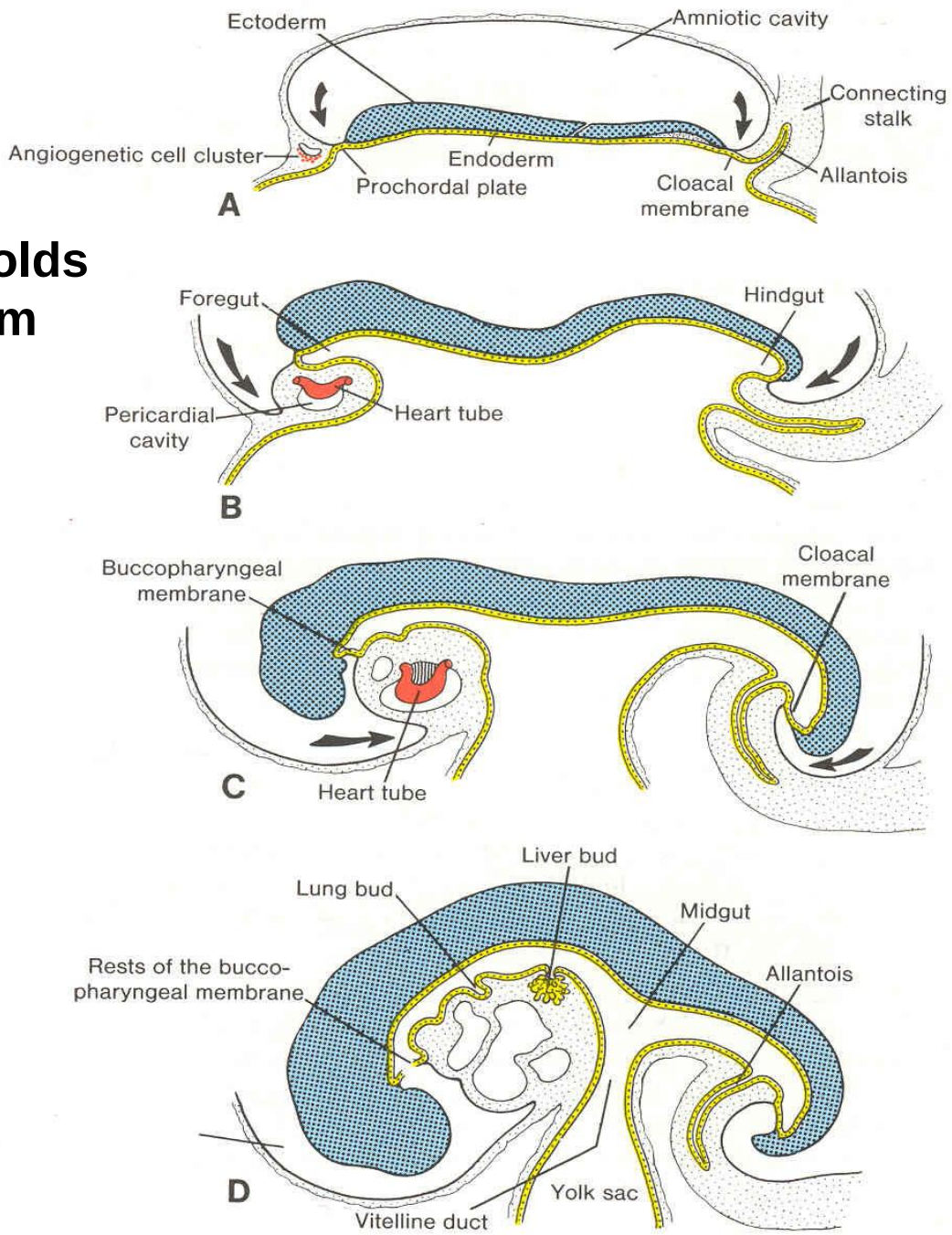

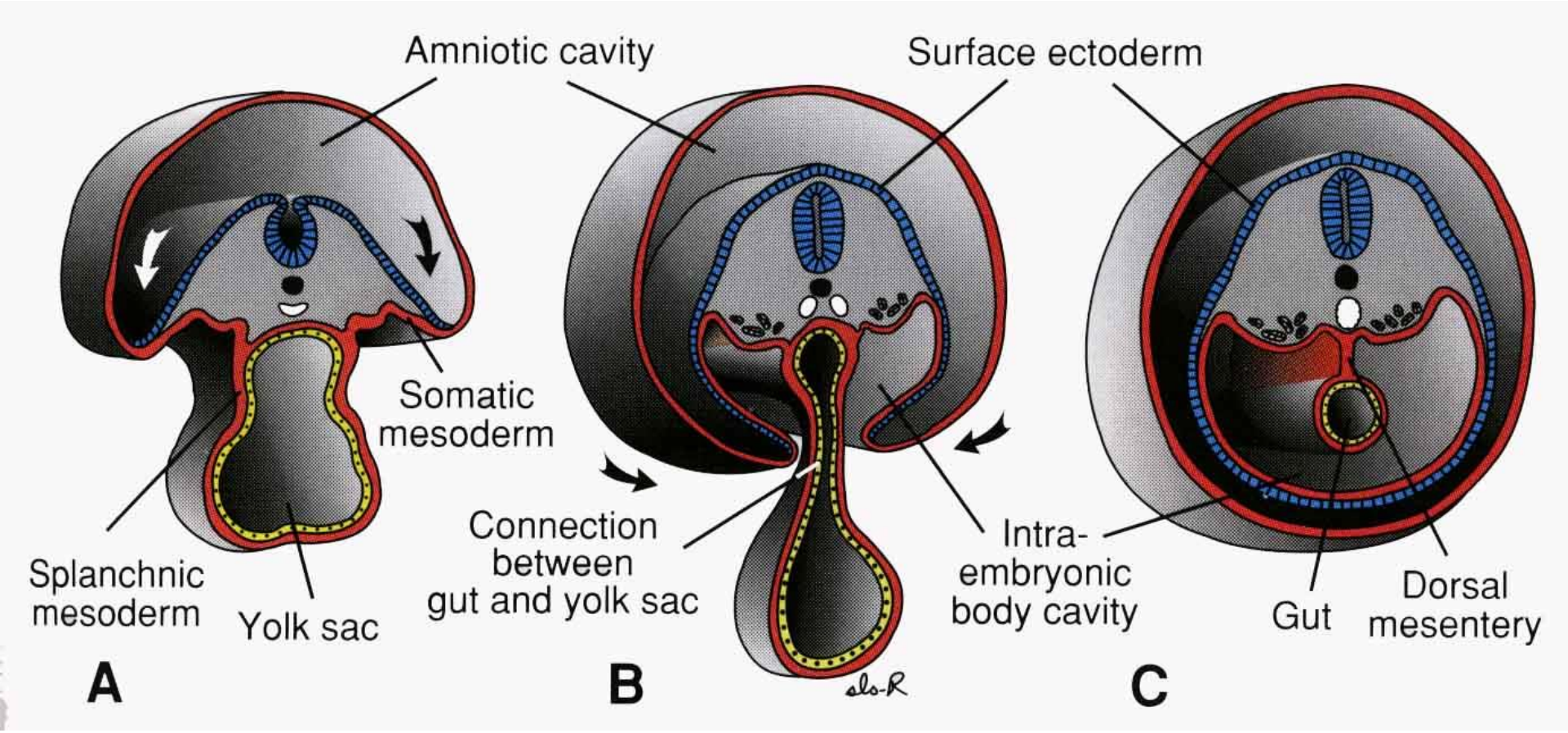
Amniotic cavity
Surface ectoderm
Somatic mesoderm
Splanchnic mesoderm
Yolk sac
Connection between gut and yolk sac
Intra-embryonic body cavity
Gut
Dorsal mesentery
A
B
C

ts

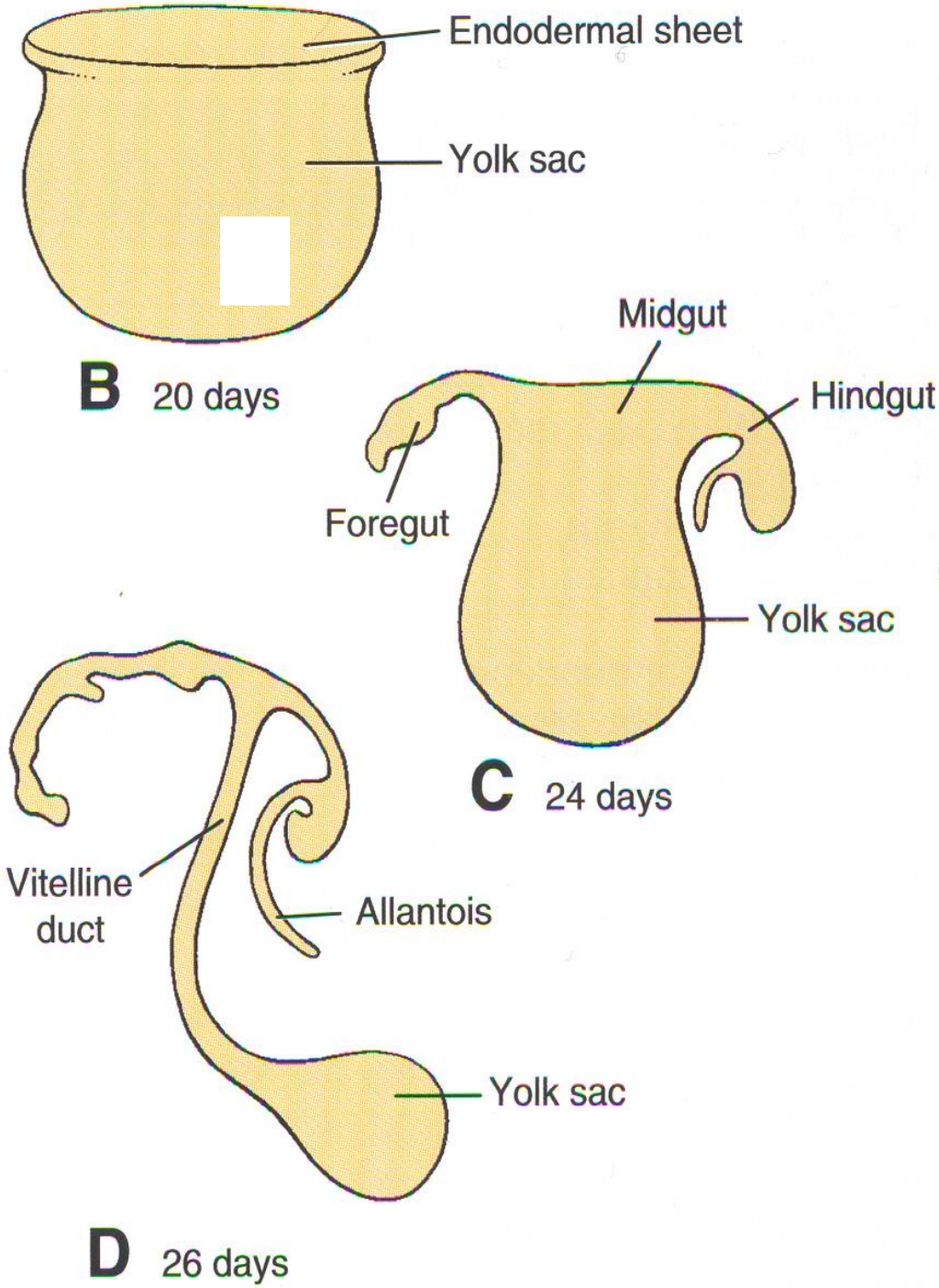
Endodermal sheet
Yolk sac
B 20 days
Midgut
Hindgut
Foregut
Yolk sac
C 24 days
Vitelline duct
Allantois
Yolk sac
D 26 days

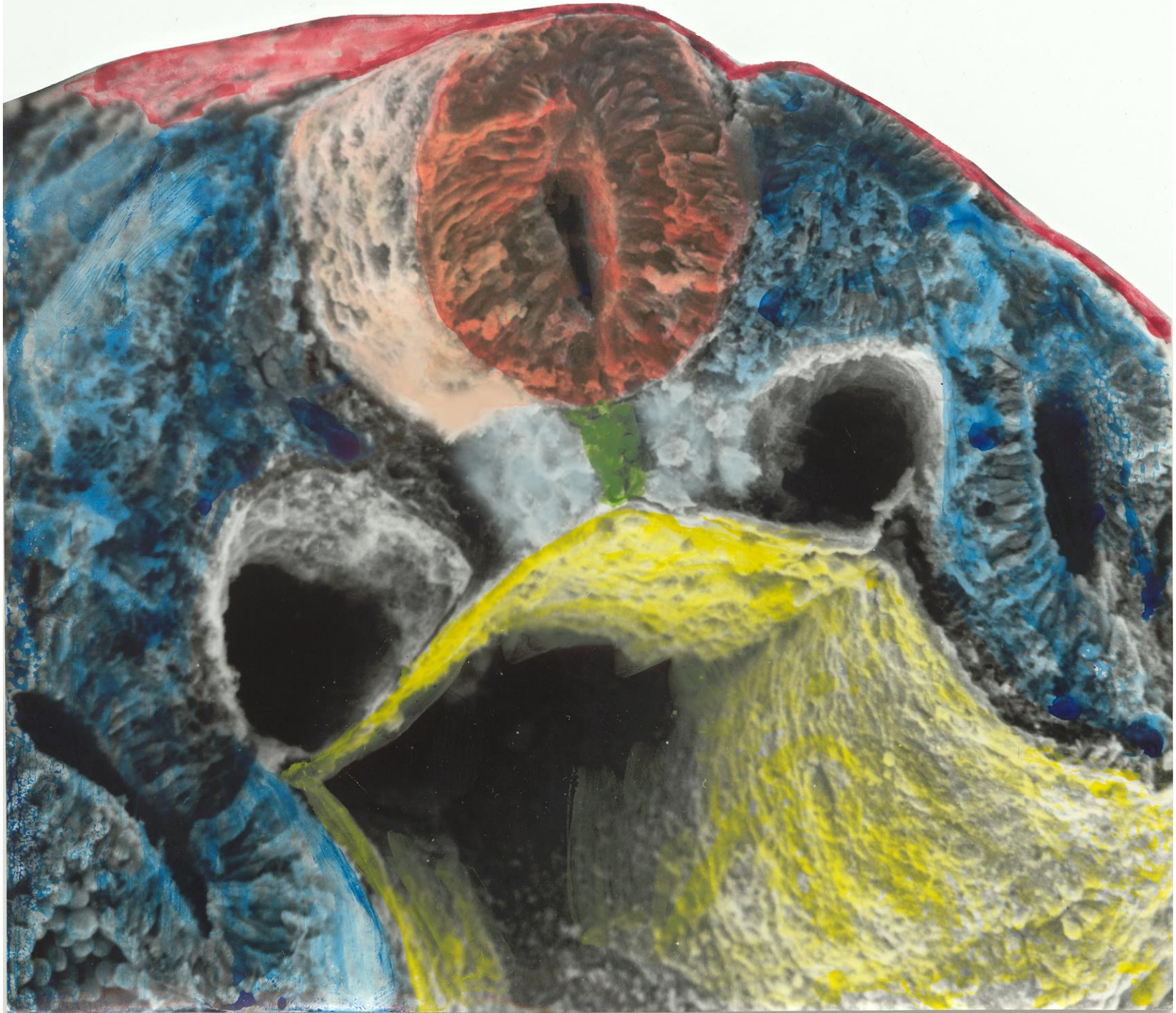

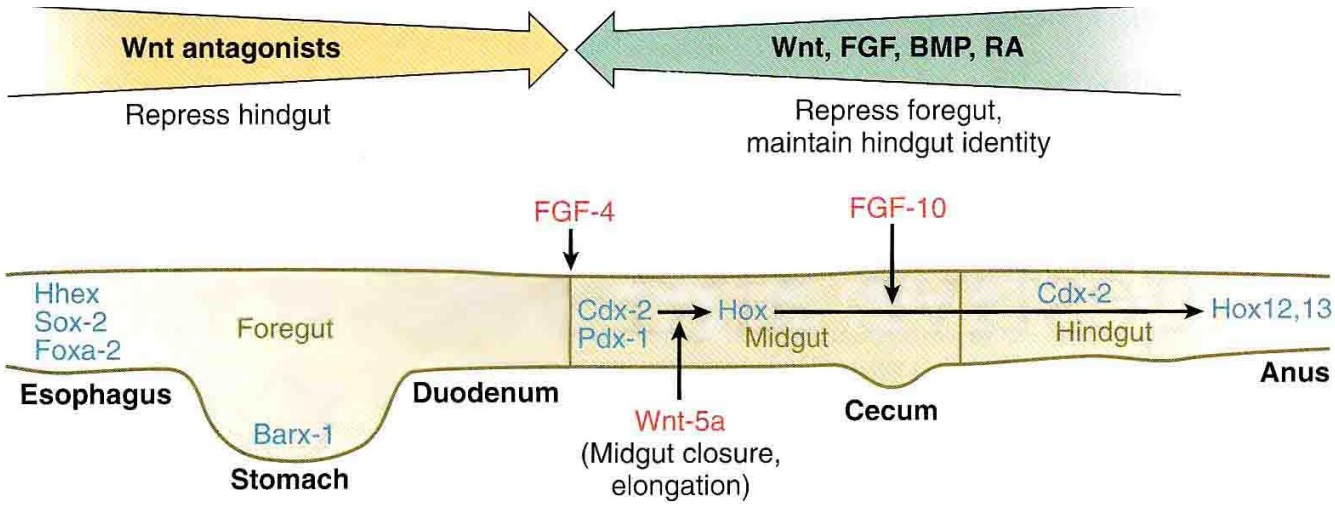

Red letters
signaling molecules

blue letters
transcription factors

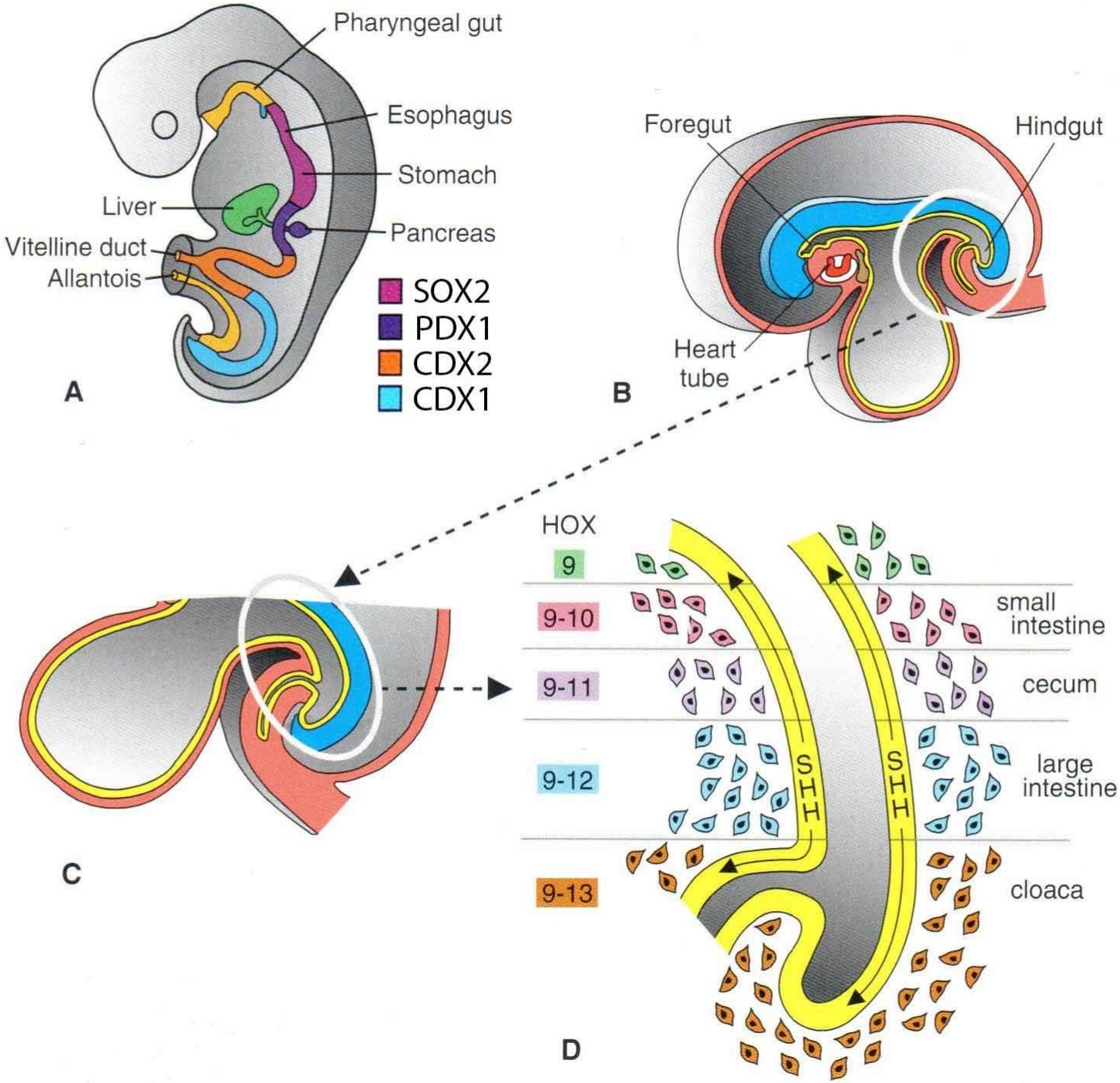
Pharyngeal gut
Esophagus
Stomach
Liver
Pancreas
Vitelline duct
Allantois
SOX2
PDX1
CDX2
CDX1
A
Foregut
Hindgut
Heart tube
B
C
HOX
9
9-10
9-11
9-12
9-13
small intestine
cecum
large intestine
cloaca
SHH
SHH
D

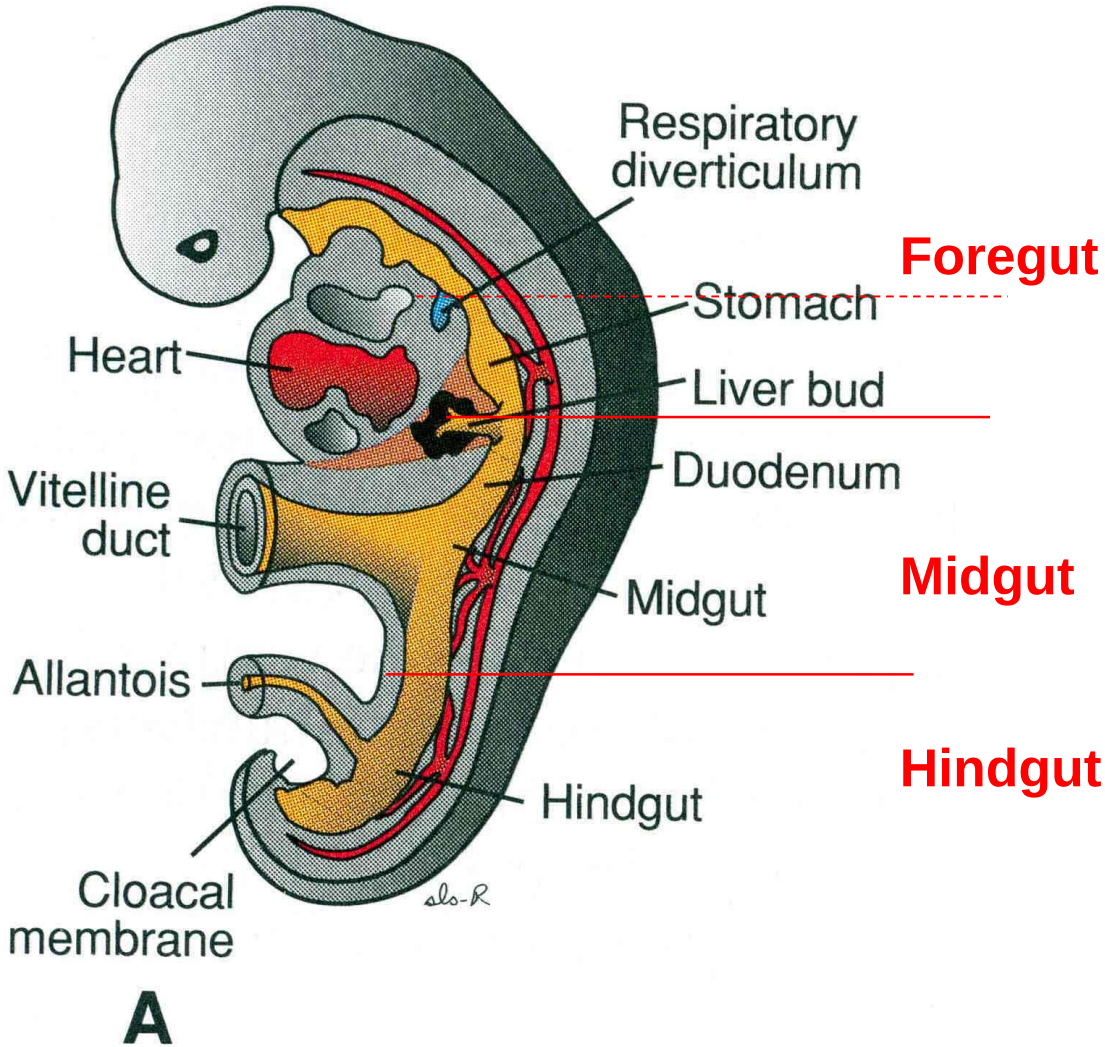

Foregut

faryngeal gut (primitive pharynx)

caudal portion of foregut

Midgut

Hindgut

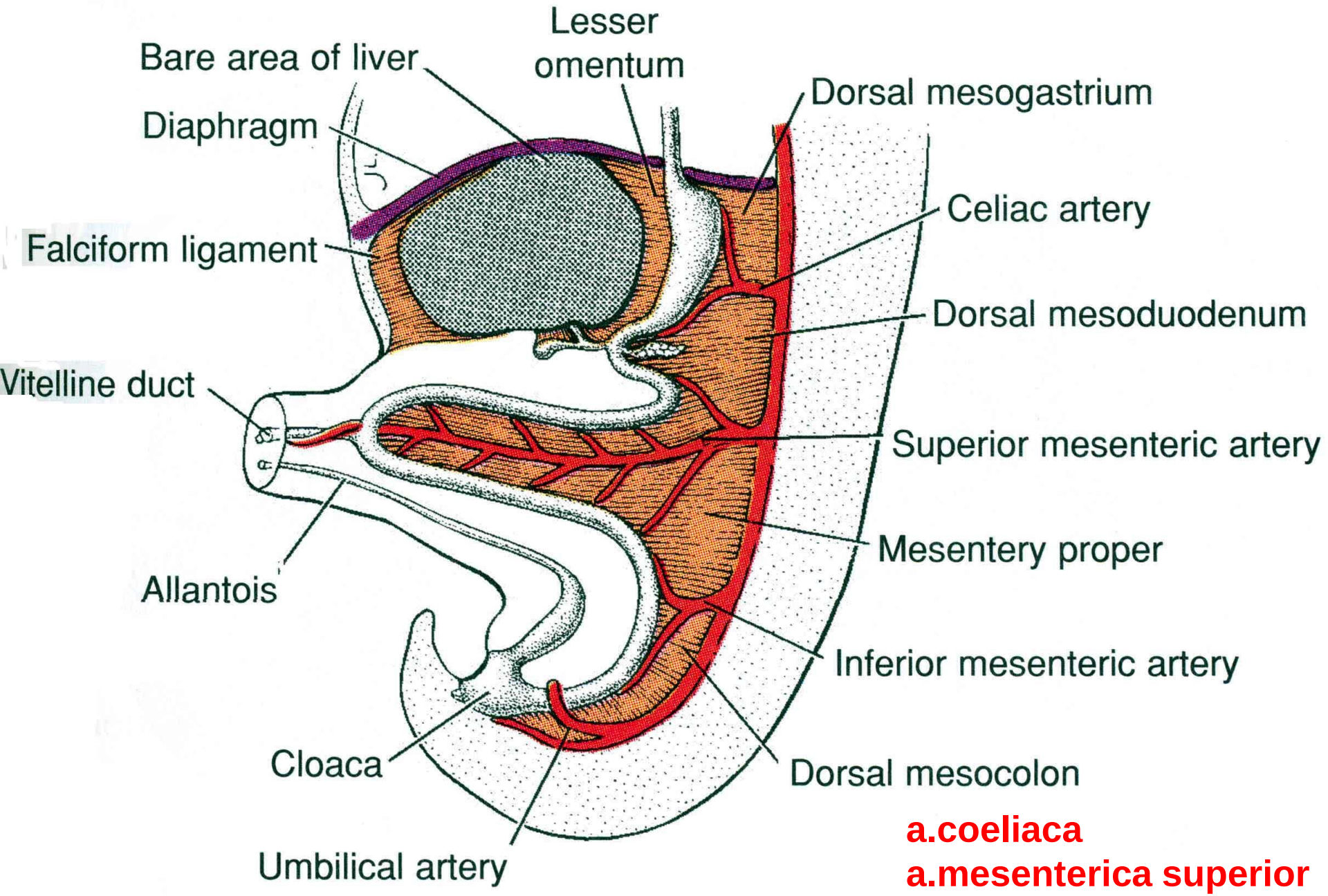

a.coeliaca
a.mesenterica superior
a.mesenterica inferior

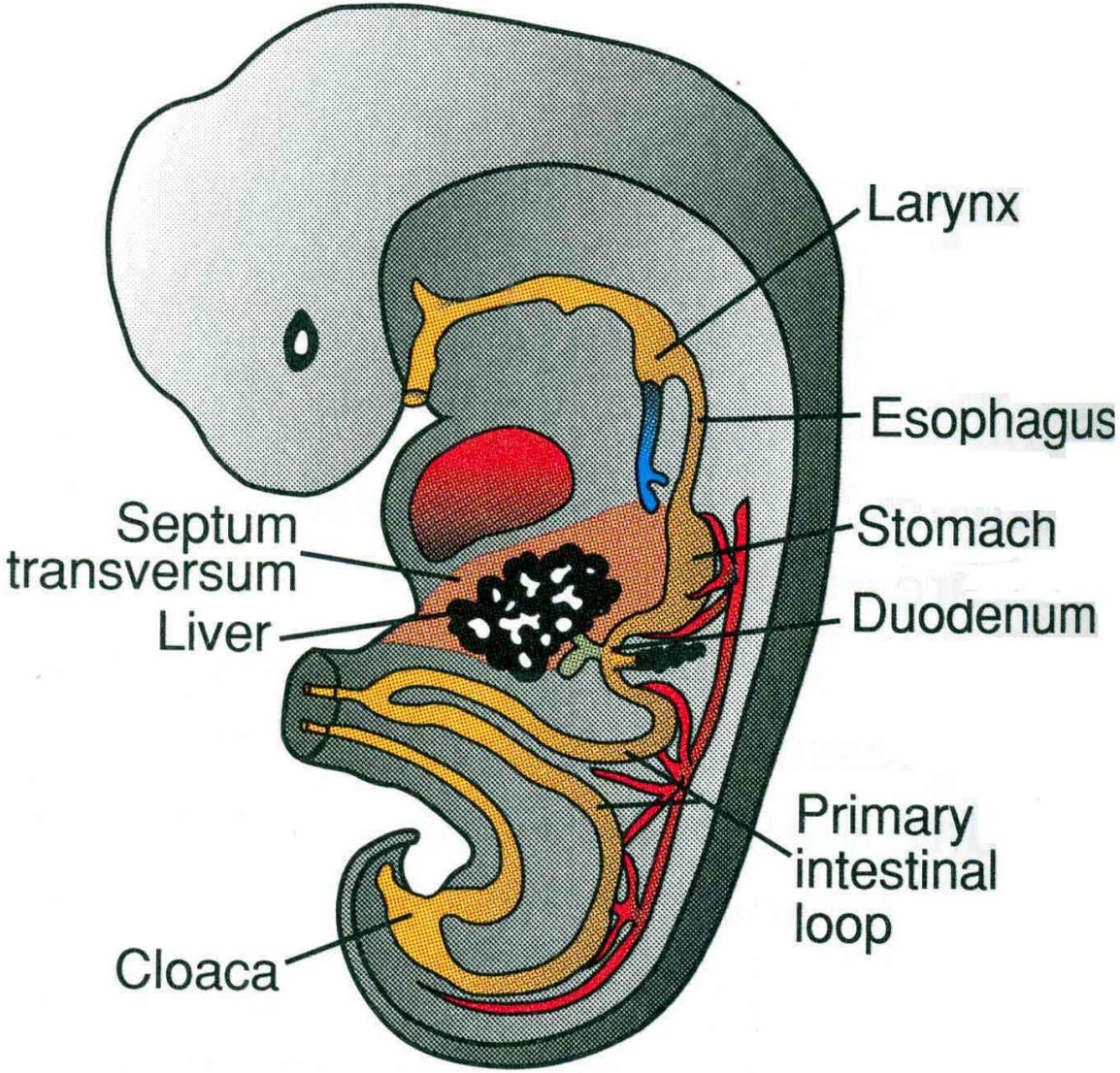

duodenal loop

primary intestinal loop (umbilical loop)

B

Development of esophagus

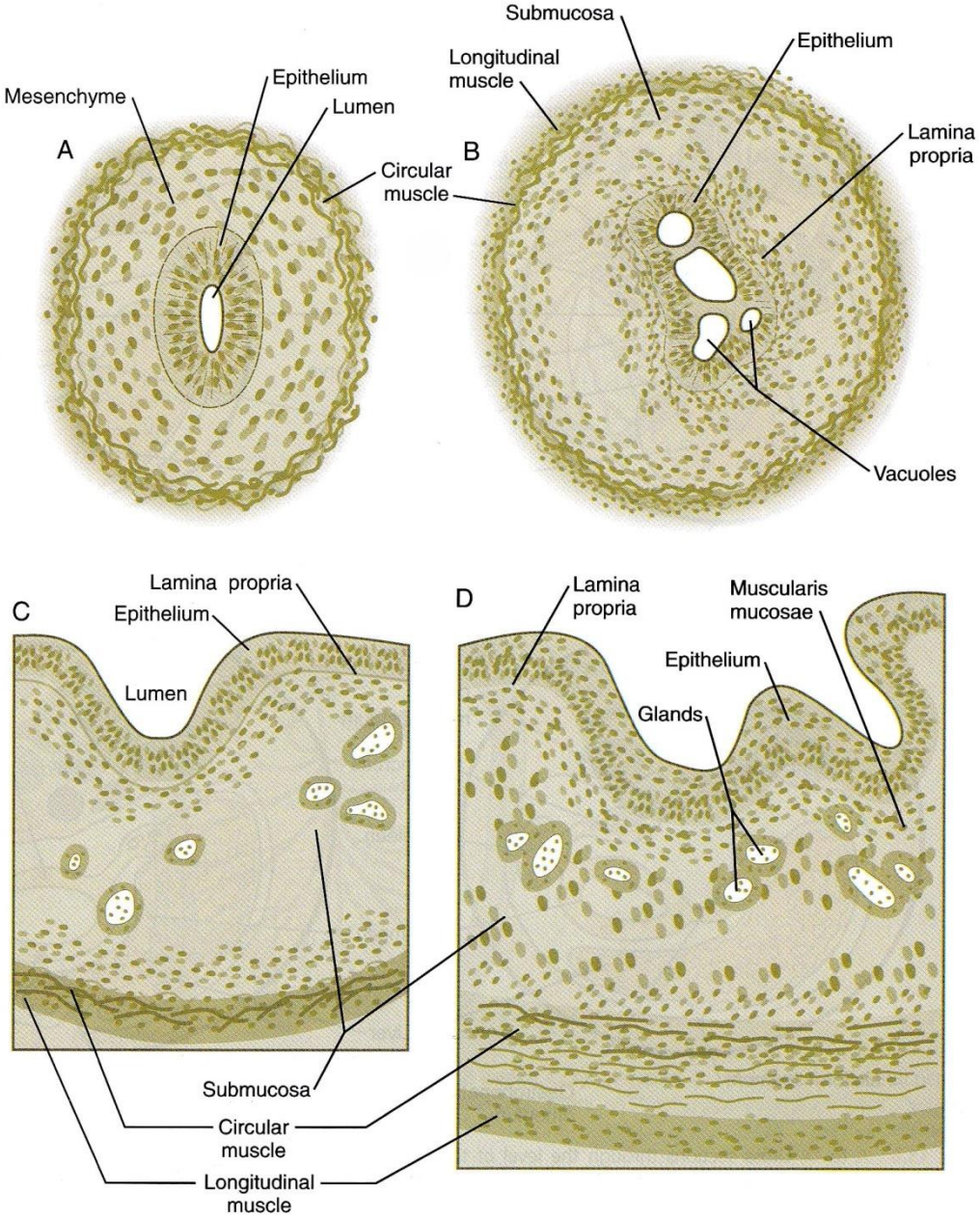

Tracheoesophageal septum

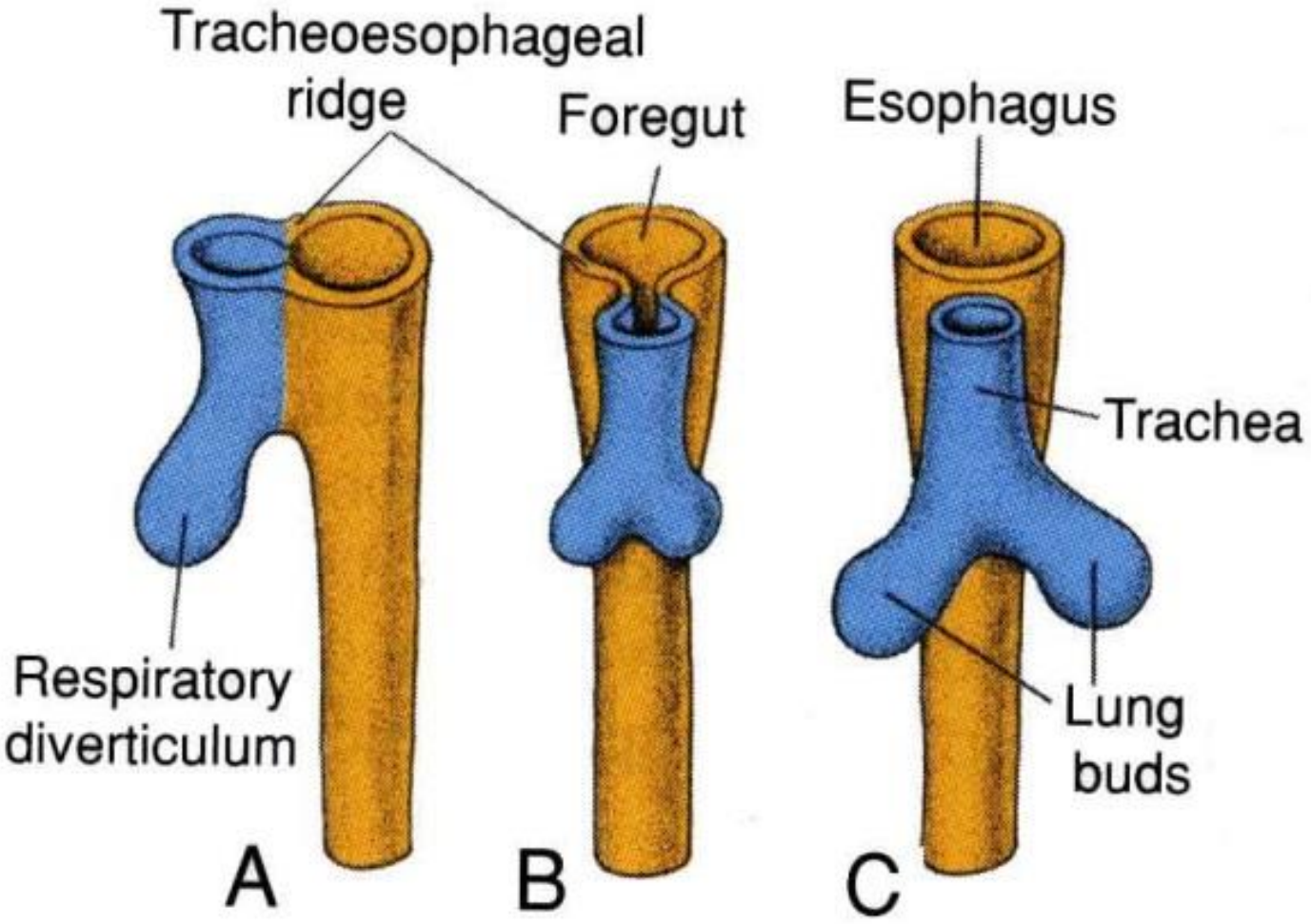

Esophageal atresia, tracheoesophageal fistula

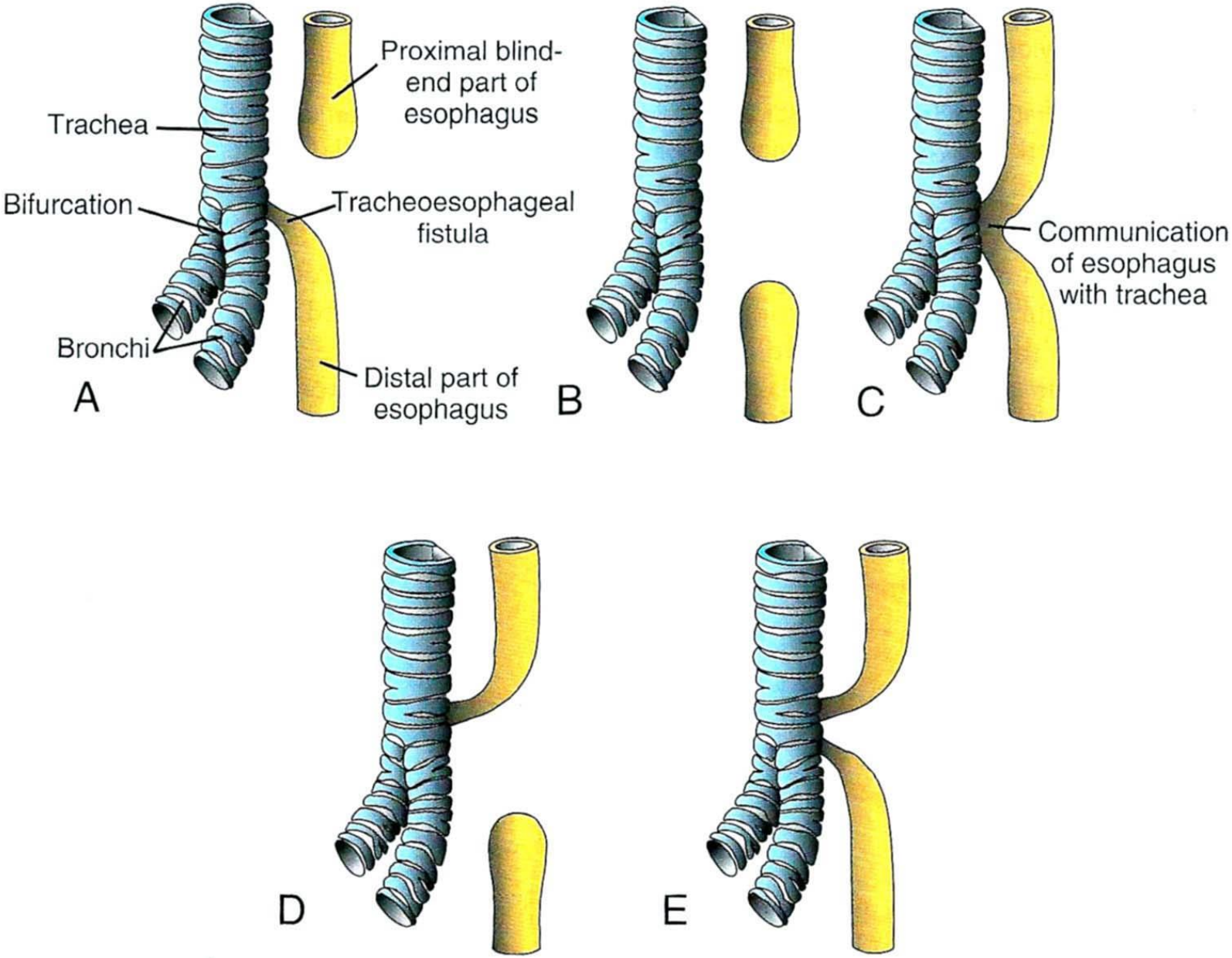

Development of stomach

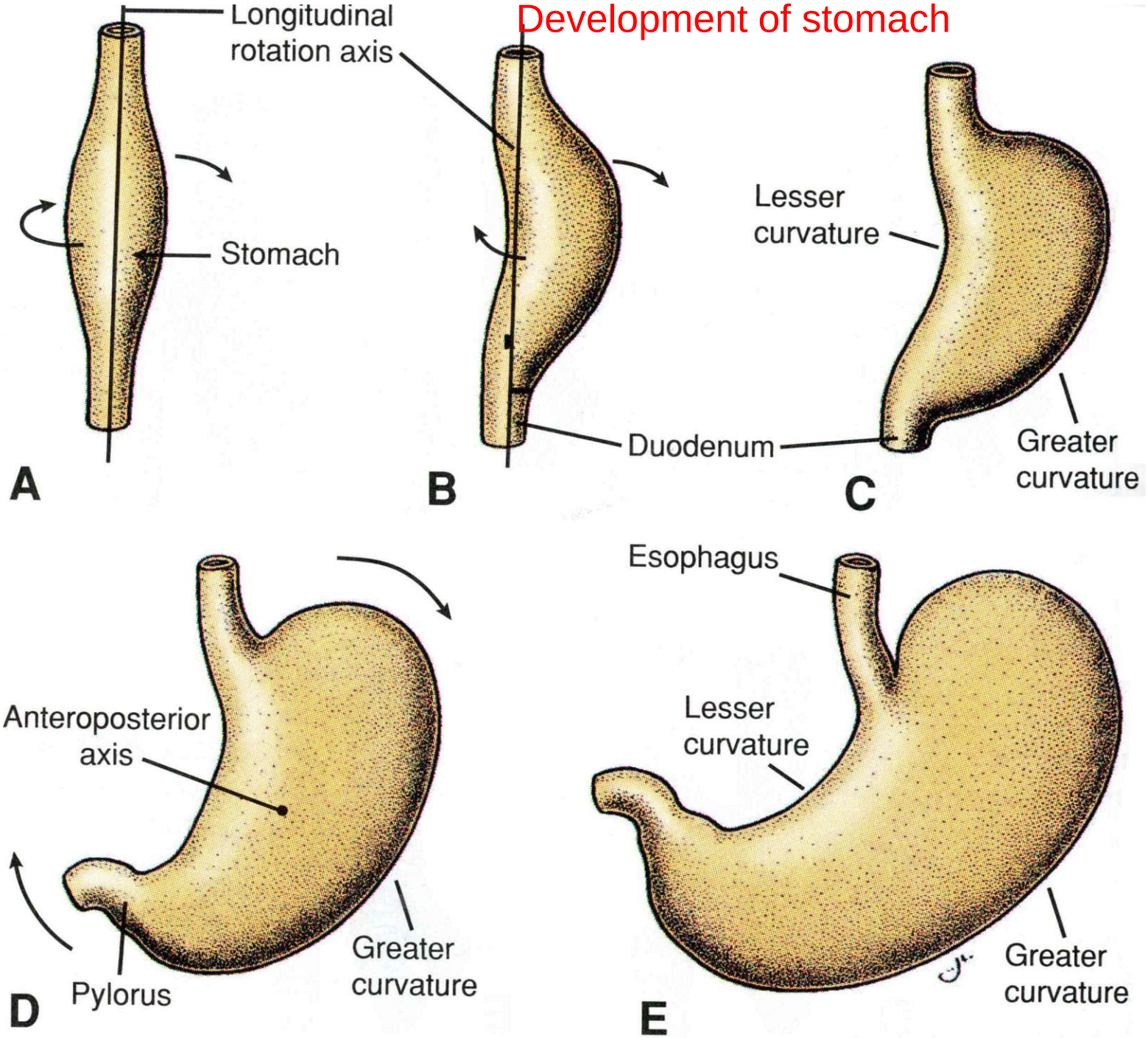

Histogenesis

mucosal secretory cells develop step by step

gastric mucosa forms at the end of the 2nd month
(rugae, first gastric pits)

early fetal period – individual cell types featuring gastric mucosa

specific cell types complete their differentiation at late fetal period

production of HCl early after birth

Pyloric stenosis

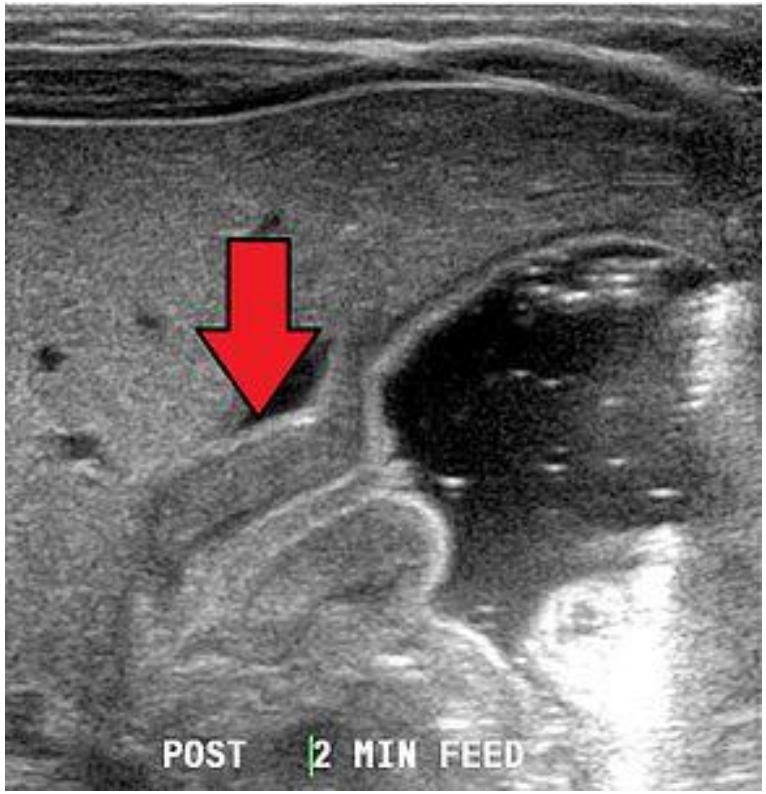

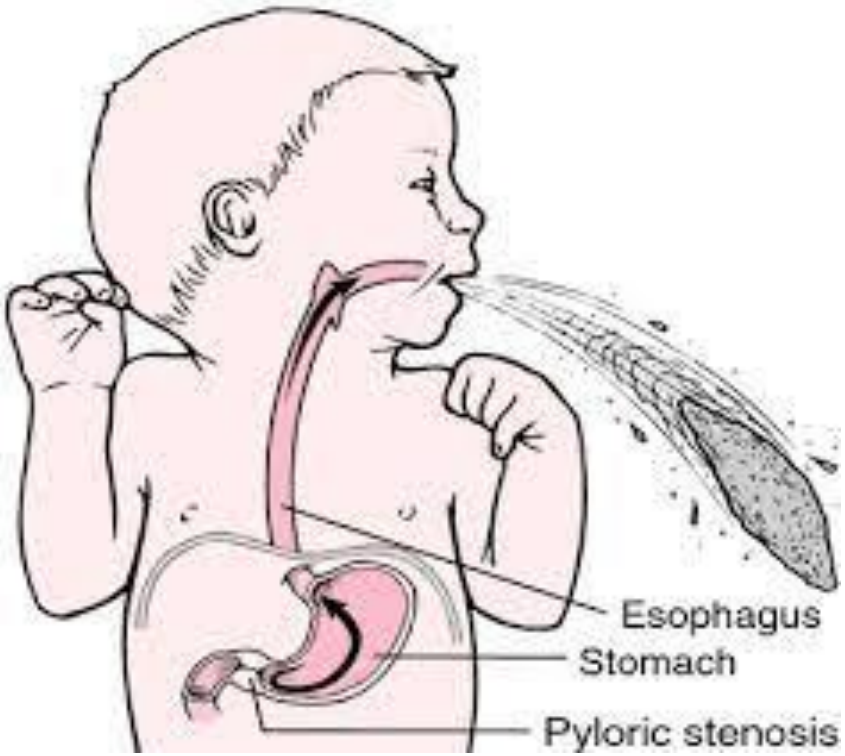

functional defect – hypertrophy of m. sphincter pylori
males 1:150, females 1:750
projectile vomiting without the presence of bile

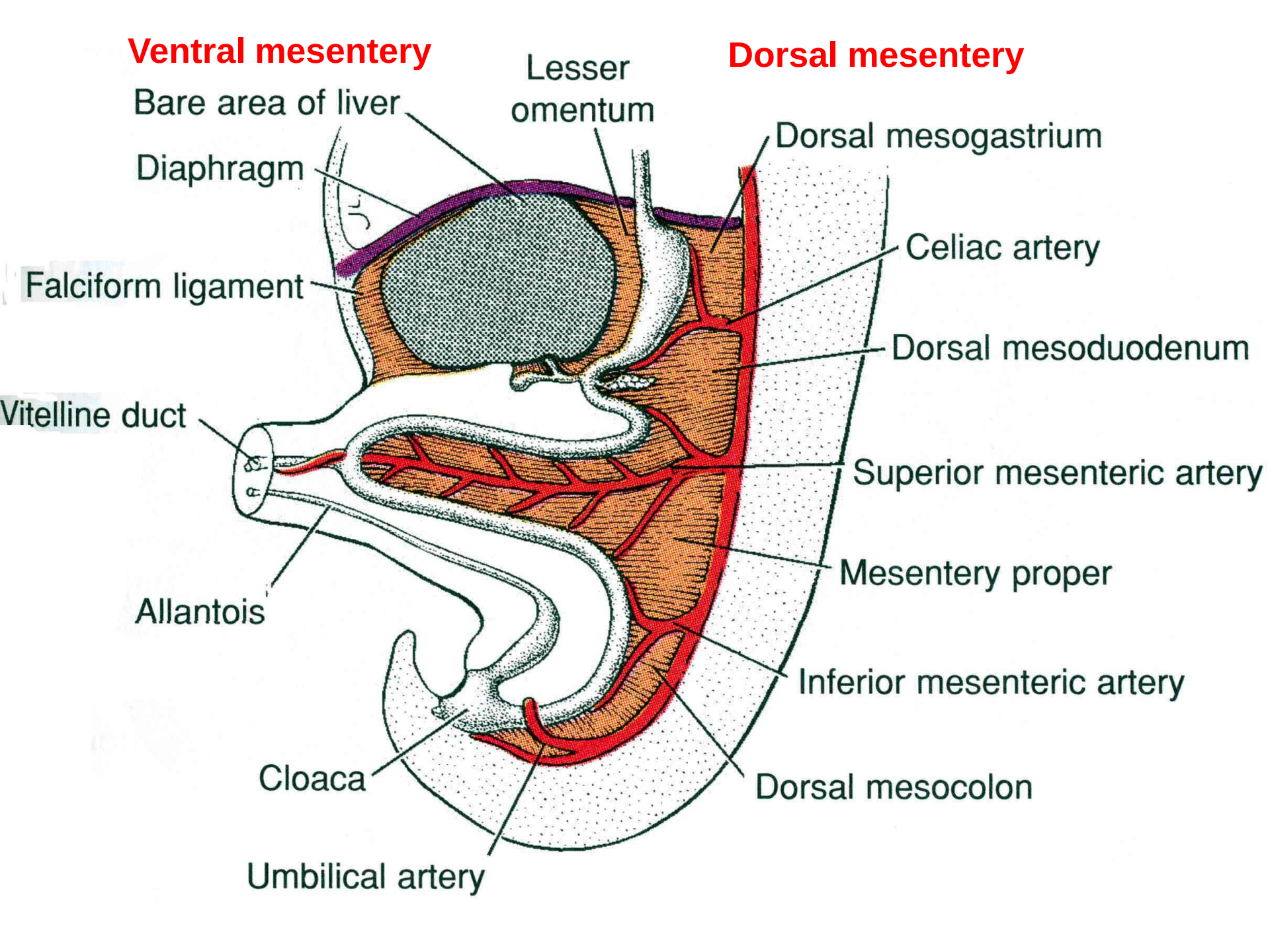
Ventral mesentery
Dorsal mesentery
Lesser omentum
Bare area of liver
Dorsal mesogastrium
Diaphragm
Celiac artery
Falciform ligament
Dorsal mesoduodenum
Vitelline duct
Superior mesenteric artery
Mesentery proper
Allantois
Inferior mesenteric artery
Cloaca
Dorsal mesocolon
Umbilical artery

Mesenteries

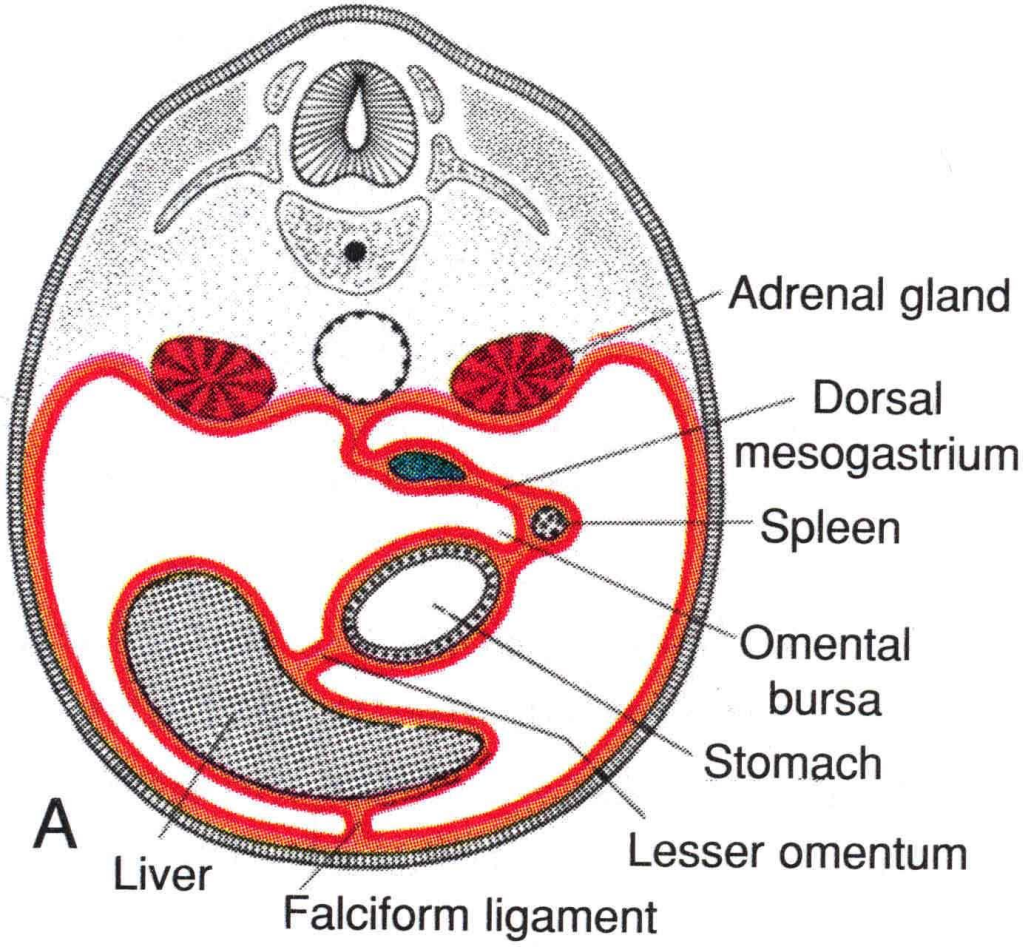

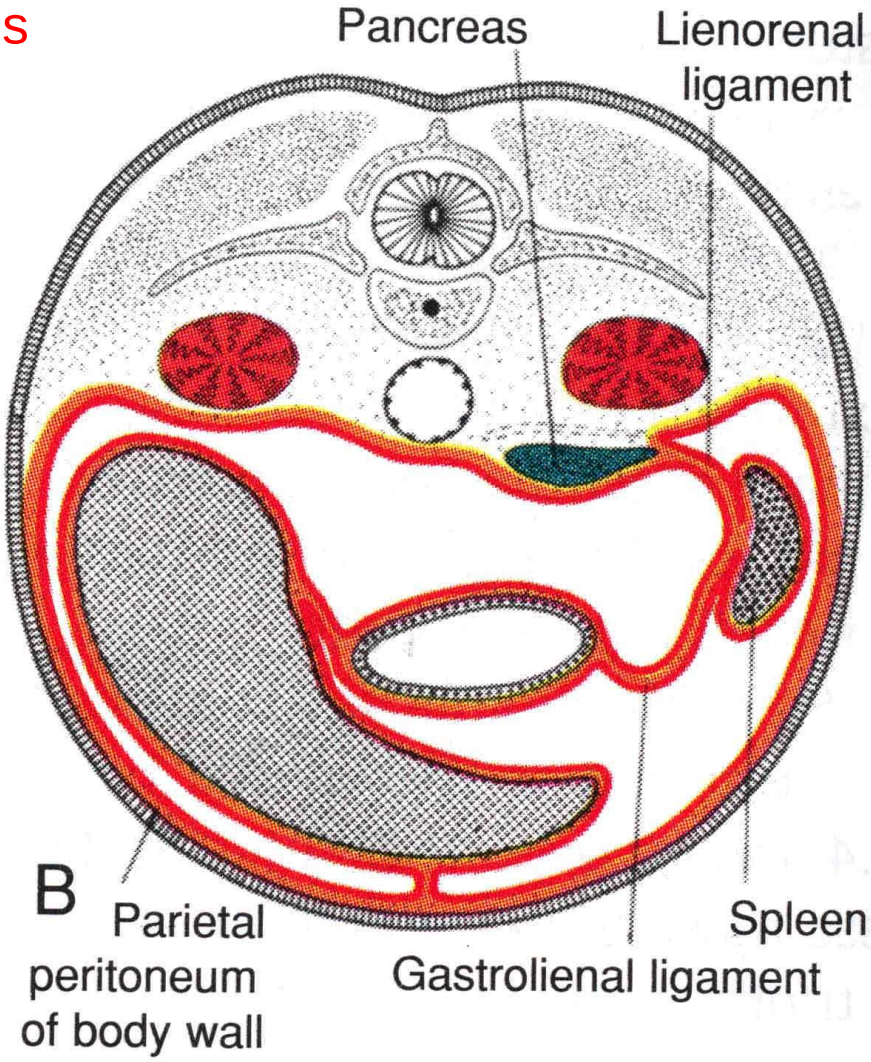

Development of liver

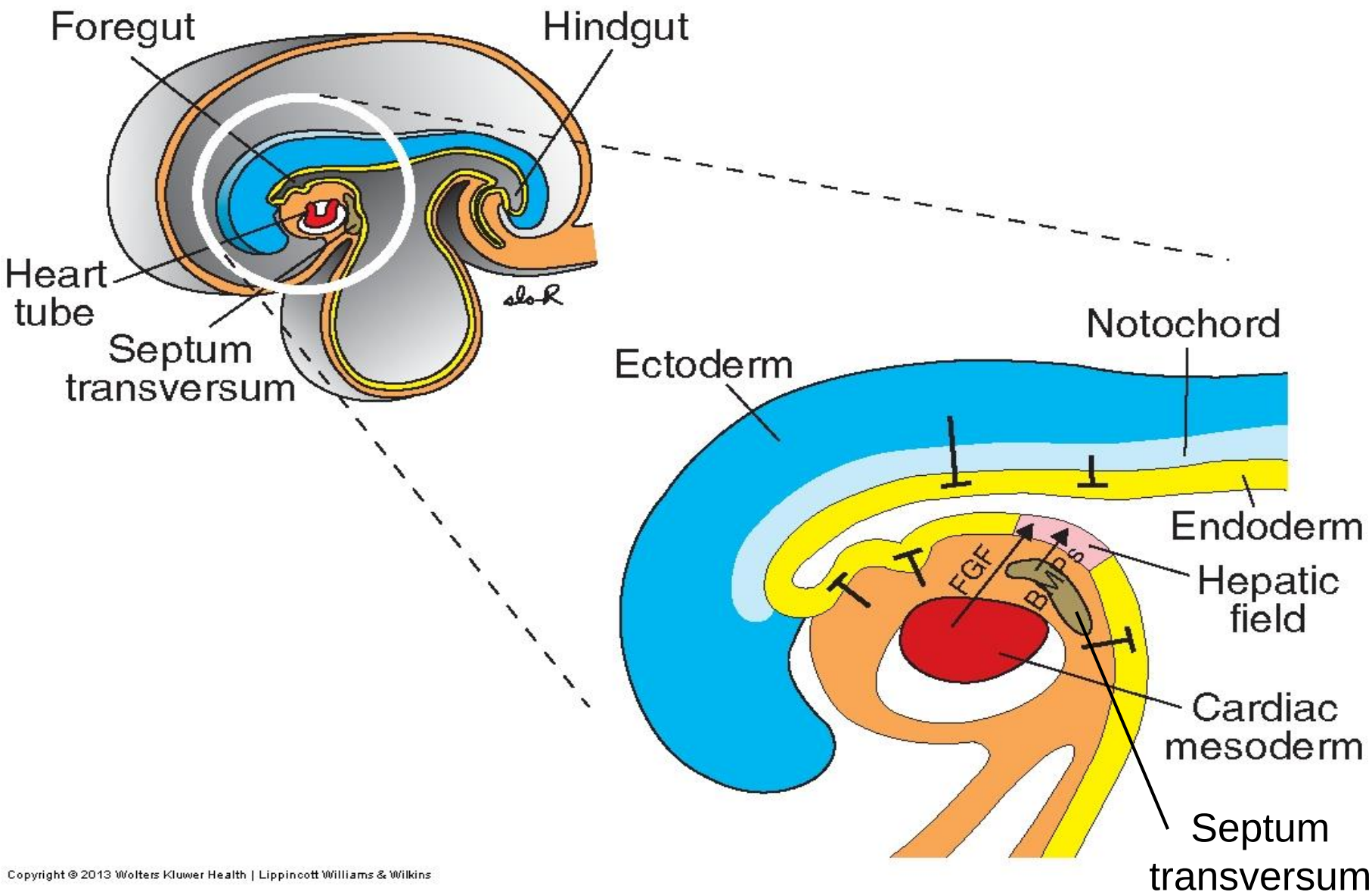

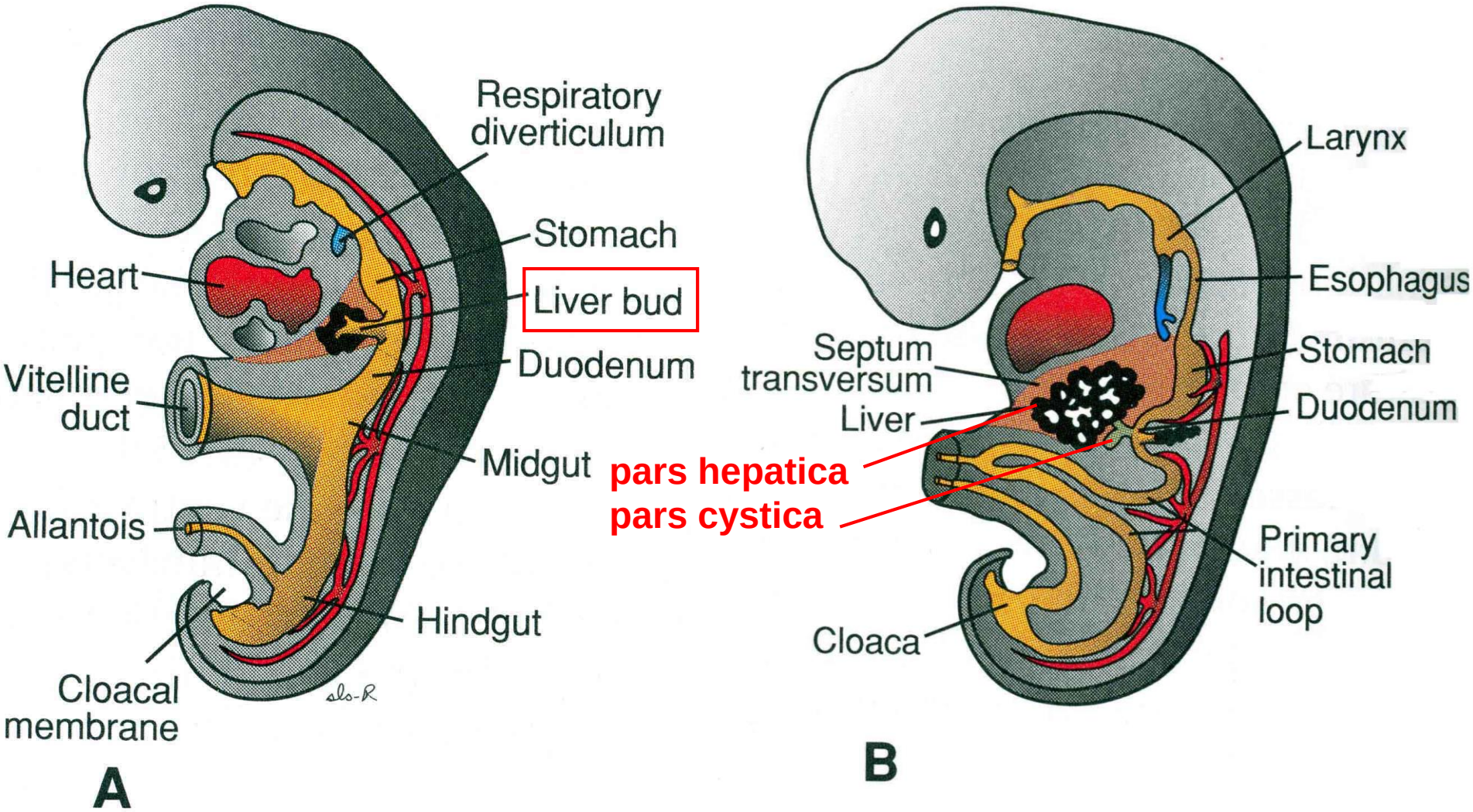
Respiratory diverticulum
Stomach
Heart
Liver bud
Duodenum
Vitelline duct
Midgut
Allantois
Hindgut
Cloacal membrane
A
Larynx
Esophagus
Septum transversum
Stomach
Liver
Duodenum
pars hepatica
pars cystica
Primary intestinal loop
Cloaca
B


porta hepatis
V
B
A


gallbladder


haemopoiesis

Biliary atresia, duplication of gallbladder

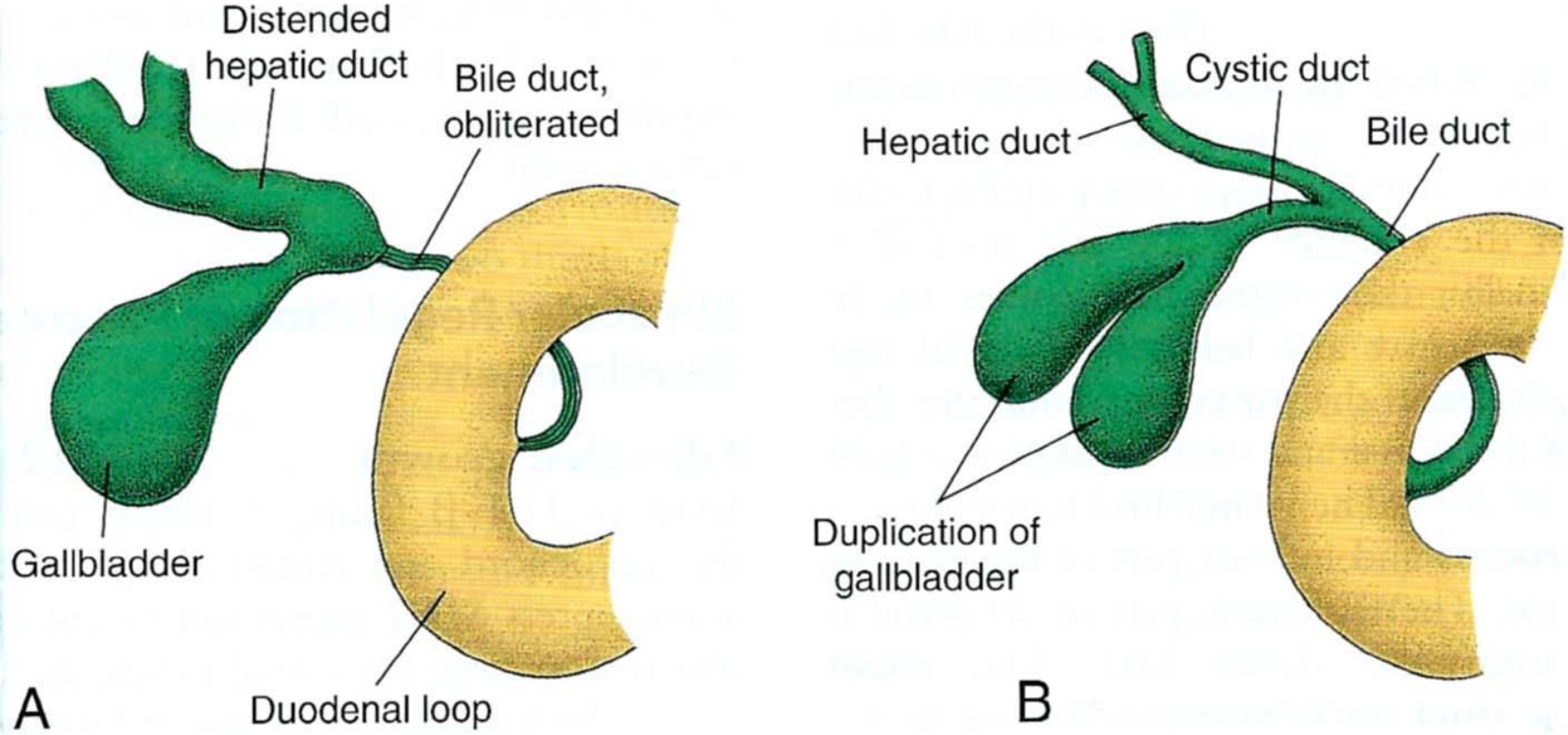

Development of pancreas

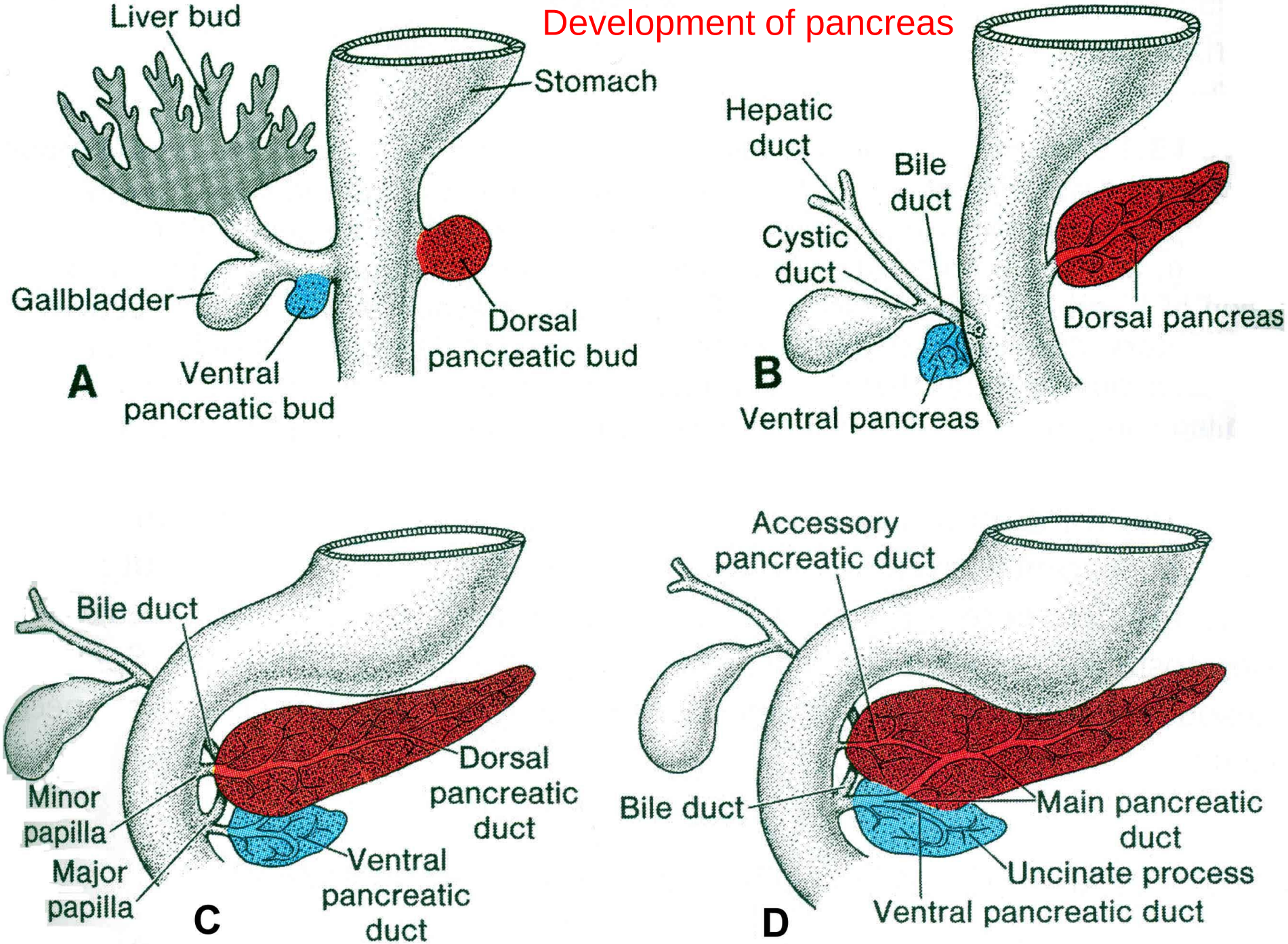

duodenum

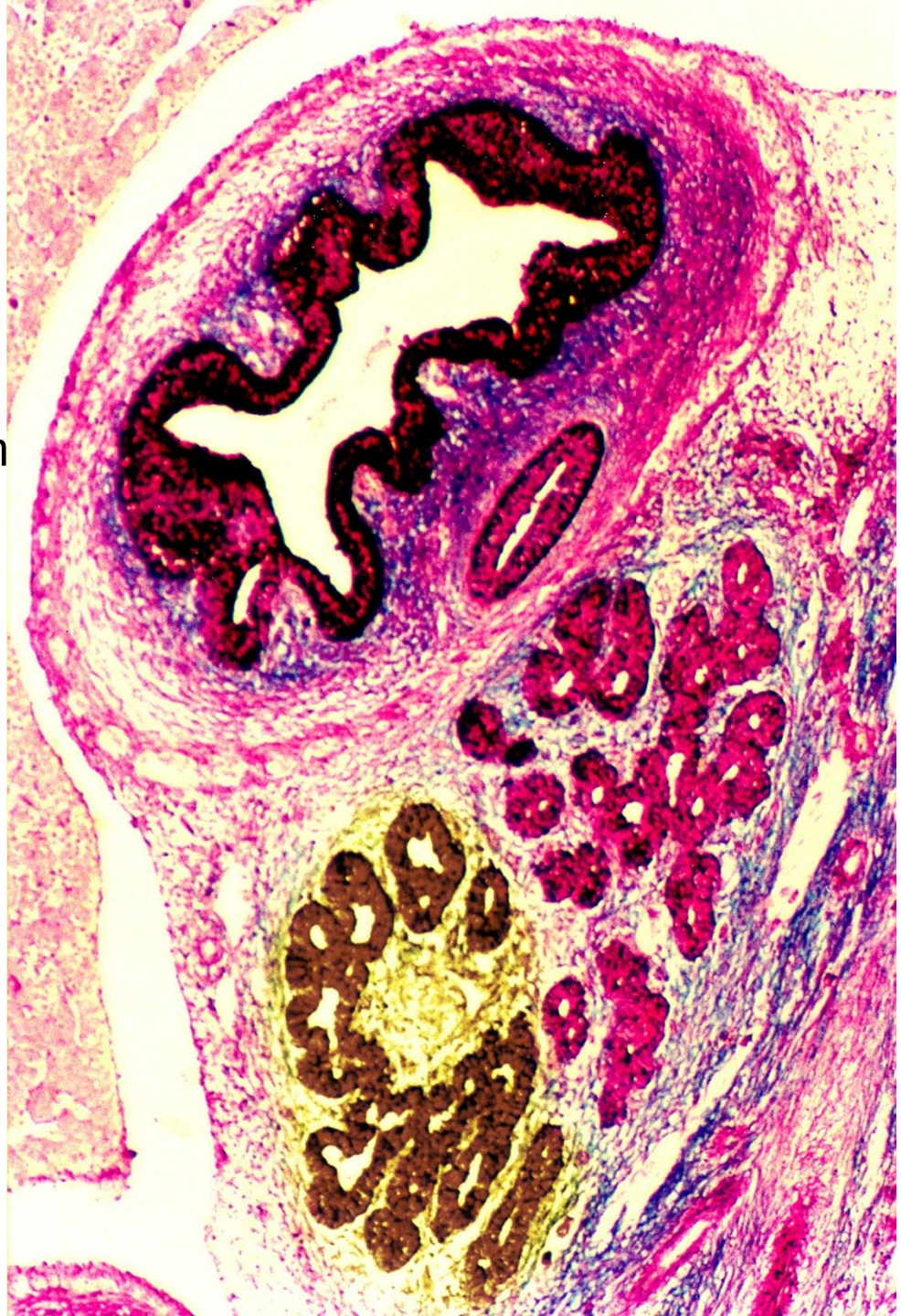

pancreas

Aberrant pancreatic tissue (stomach, duodenum, Meckel's diverticulum)

Fig. 1 Enhanced computed tomography showing a 4 × 4 cm heterogeneous solid submucosal tumor (*arrowheads*) arising from the posterior wall of the pyloric antrum

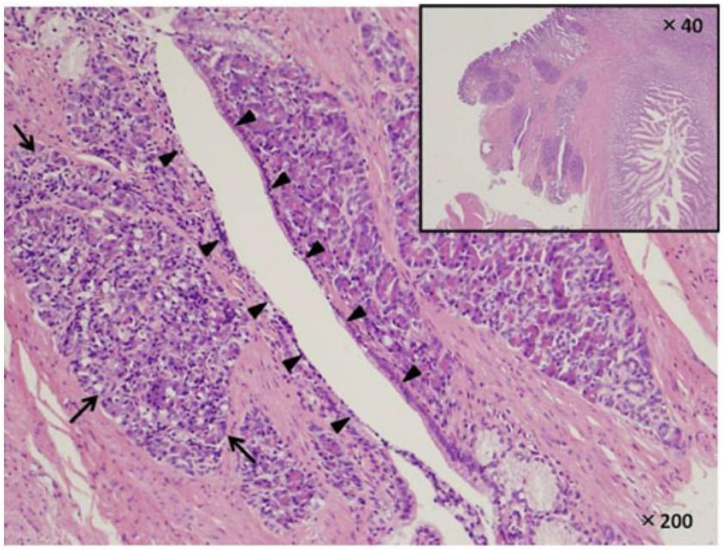

Fig. 2 Histopathology shows aberrant pancreatic tissue (*arrows*) with acini and ductal components (*arrowheads*)

Pancreas anulare

1 : 20.000
duodenal stenosis

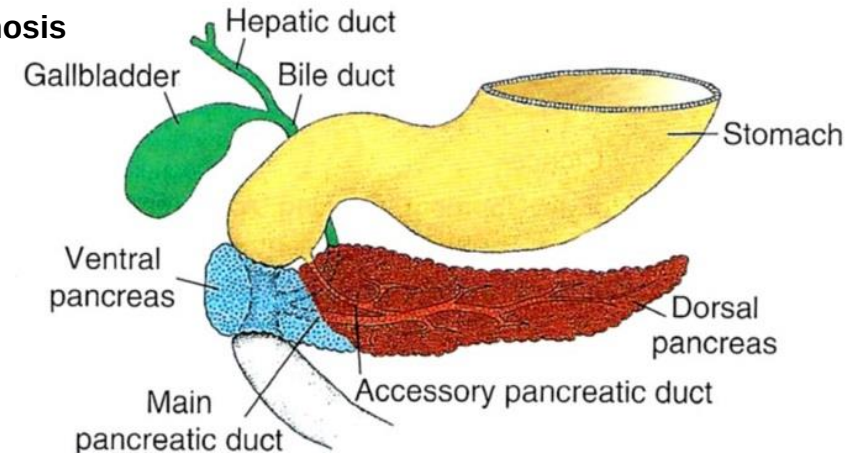

Pancreas divisum

5 – 8 %
asymptomatic

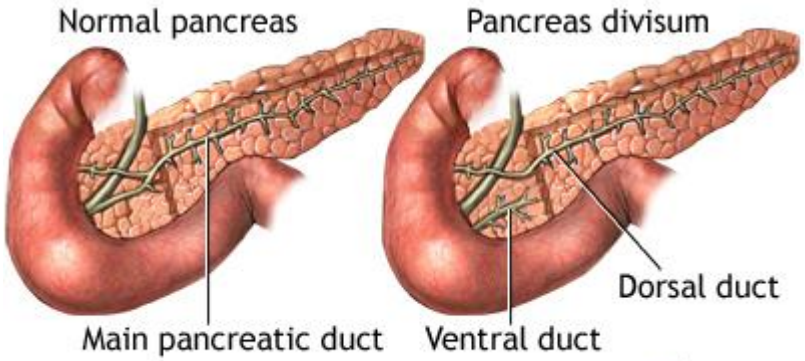

Development of intestines

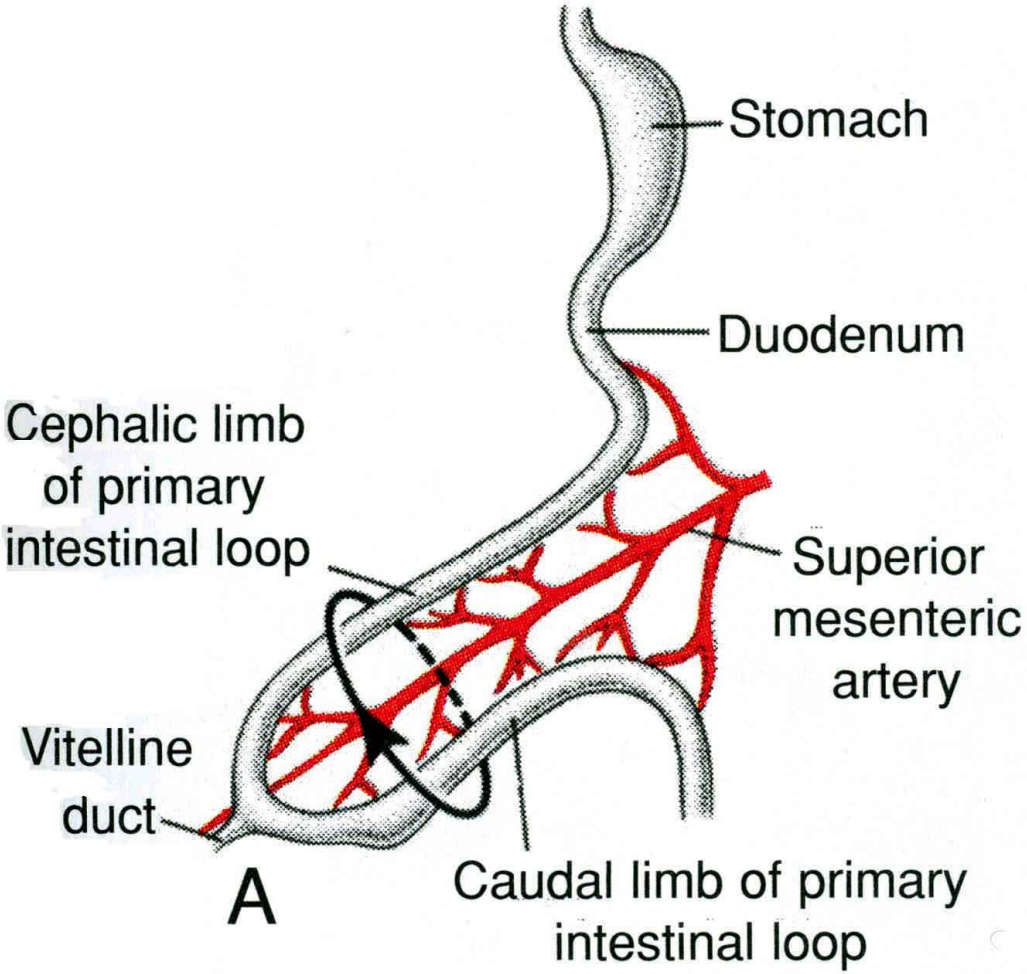

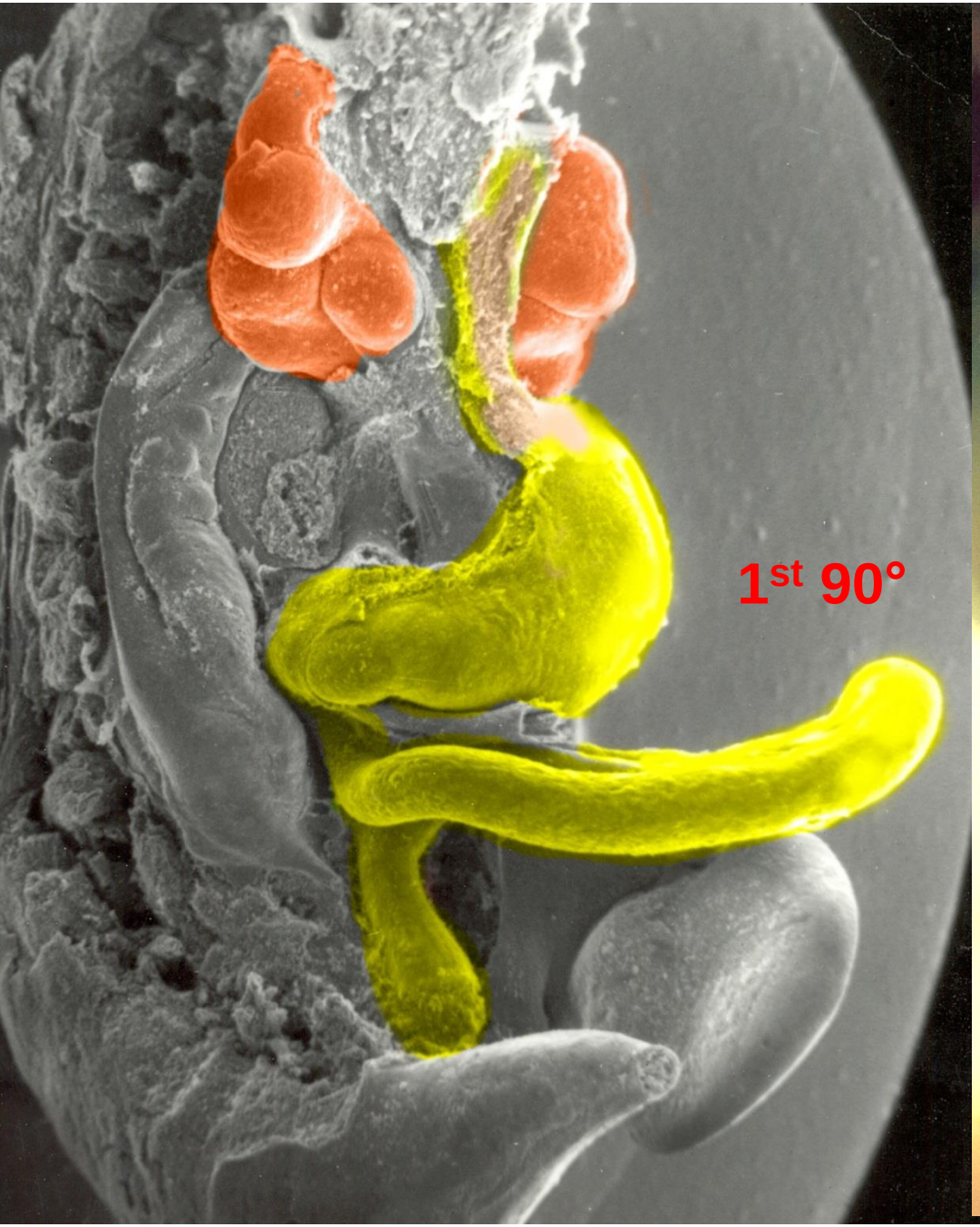
1st 90°

2nd 90°

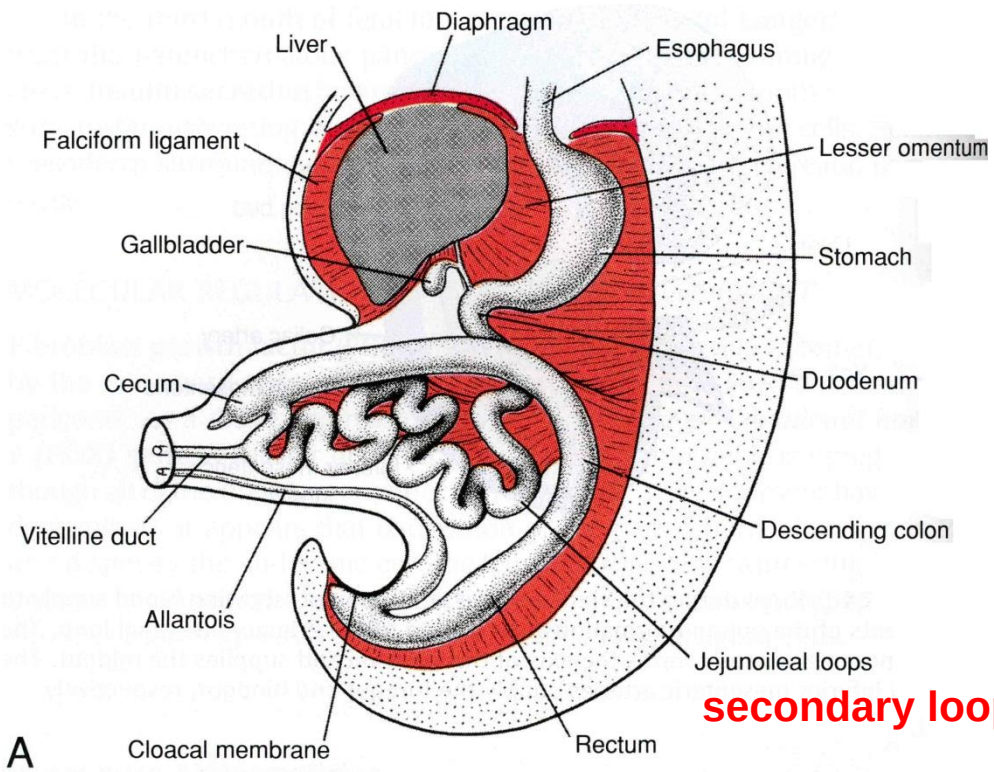

secondary loops

3rd 90°

cecal bud descent

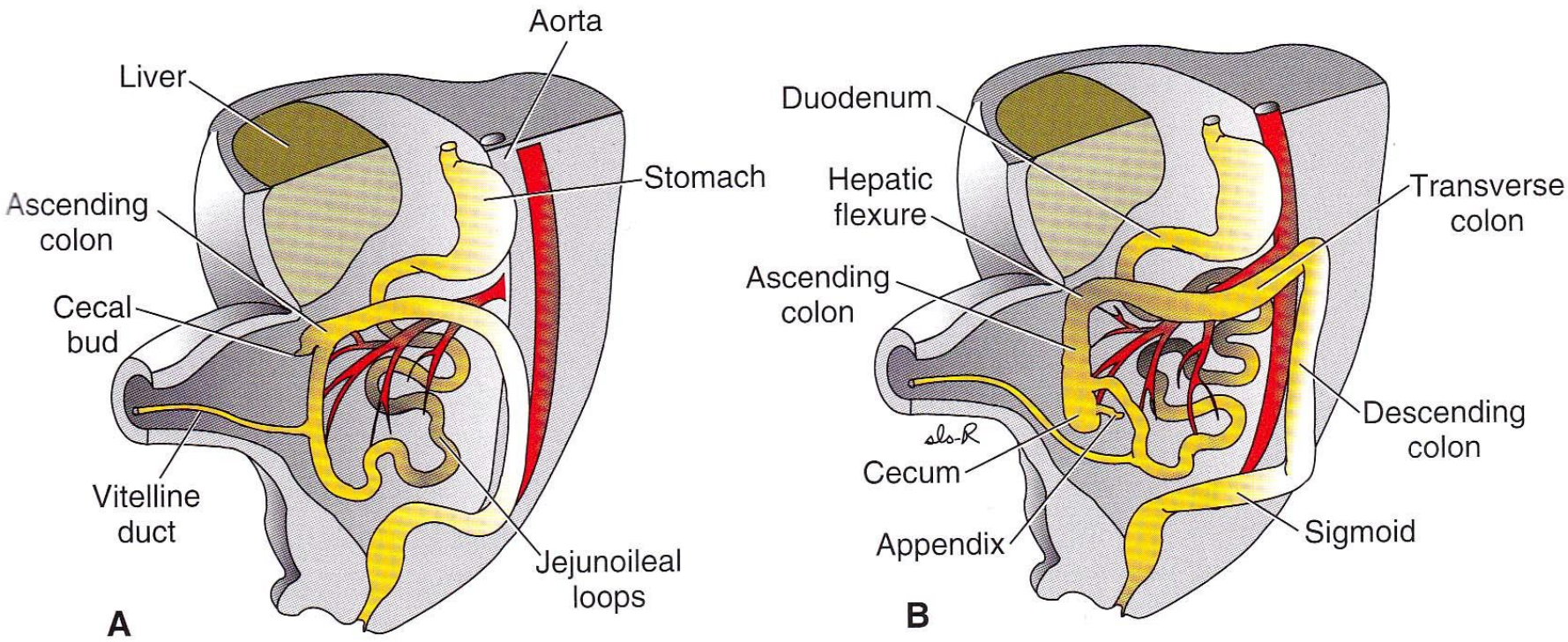

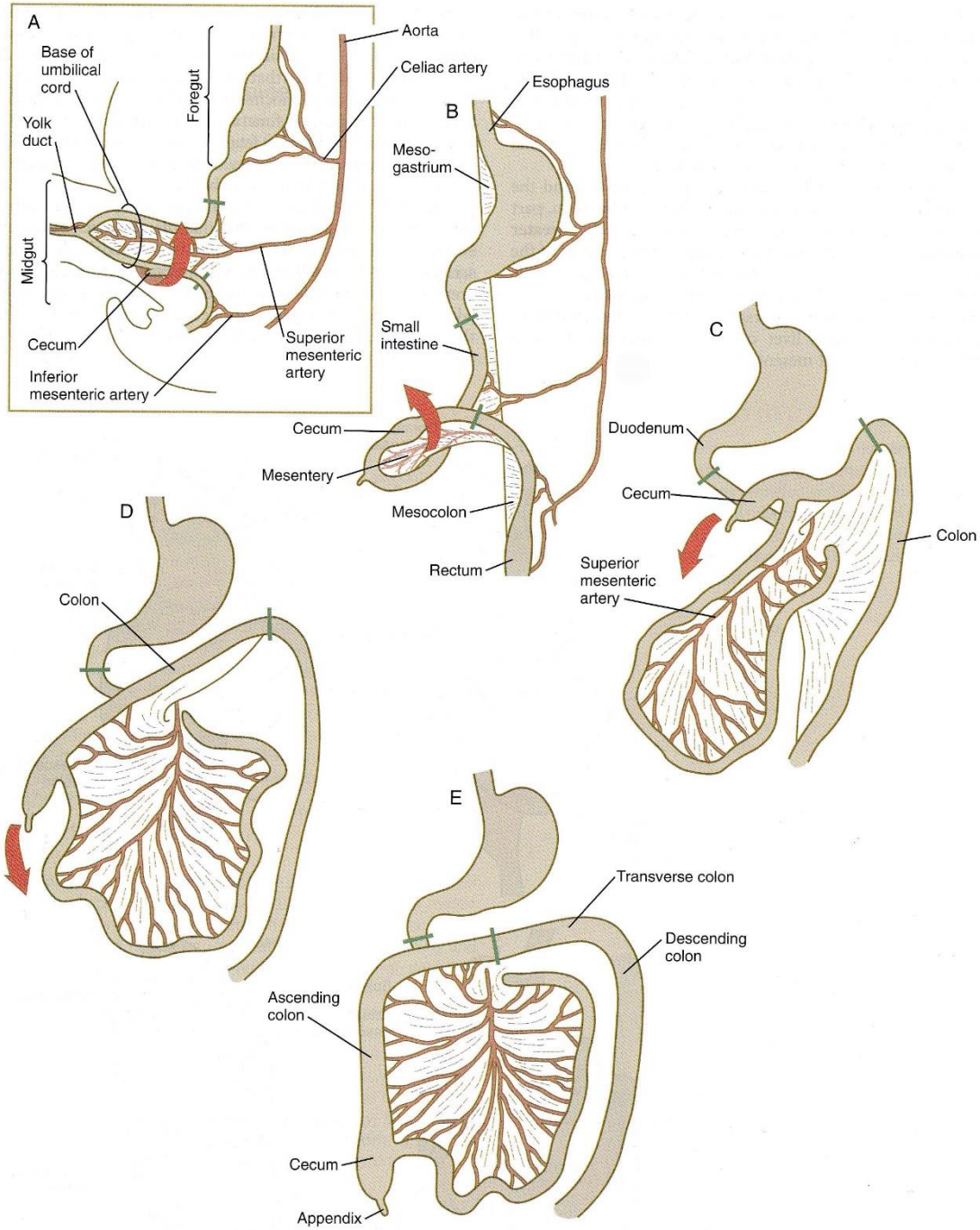

Fig. 15.7 Stages in the development and rotation of the gut. A, At 5 weeks. B, At 6 weeks. C, At 11 weeks. D, At 12 weeks. E, Fetal period. Areas between the *green lines* represent the midgut, which is supplied by the superior mesenteric artery.

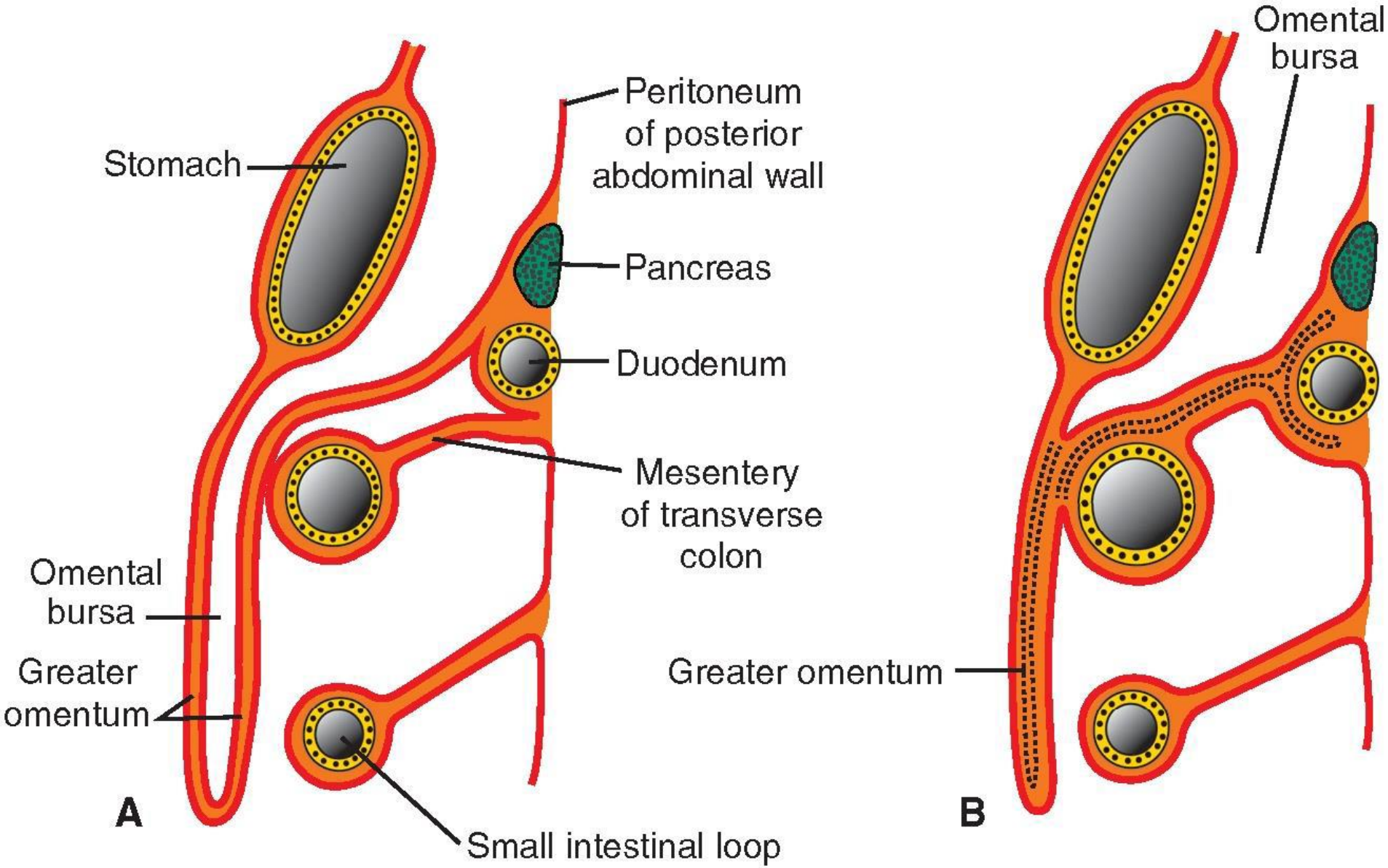

Abnormal rotation of the umbilical loop

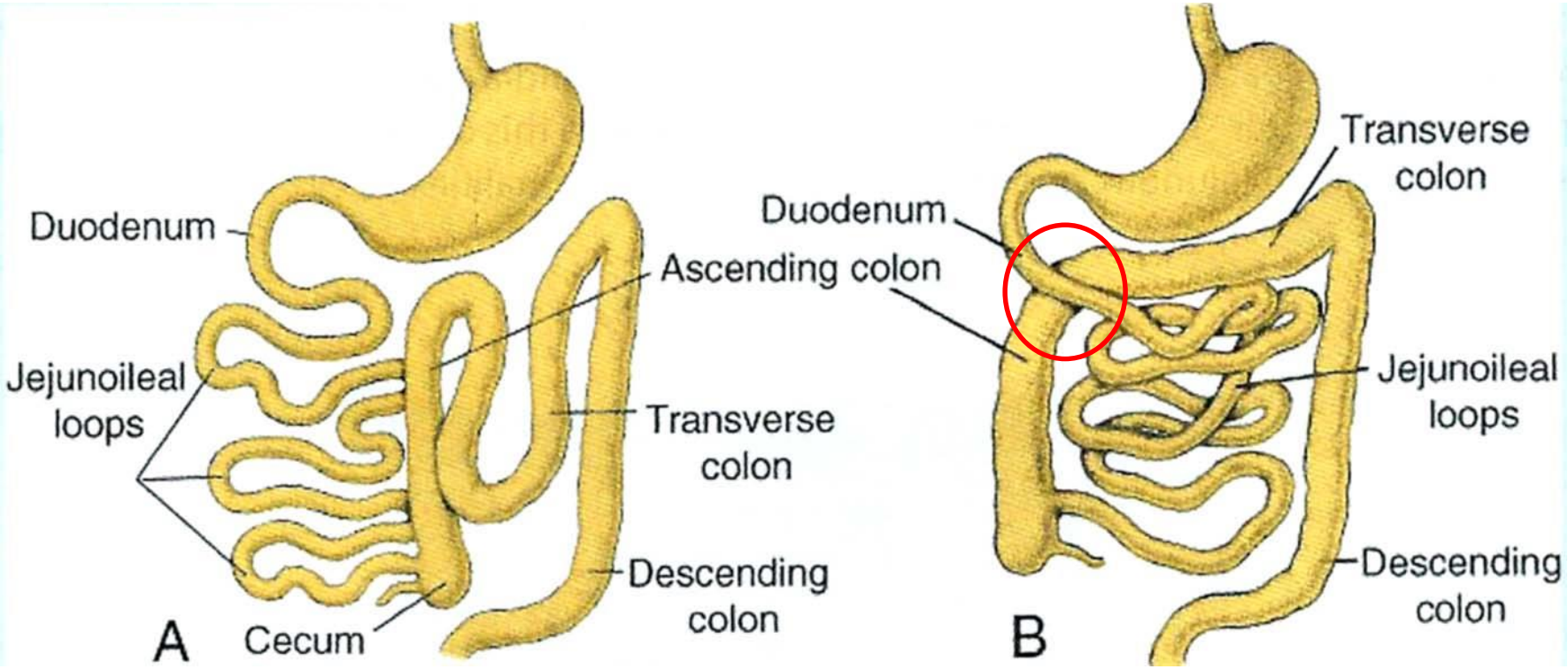

insufficient rotation **reversed rotation**

Anomal cloasure of ductus ophaloentericus

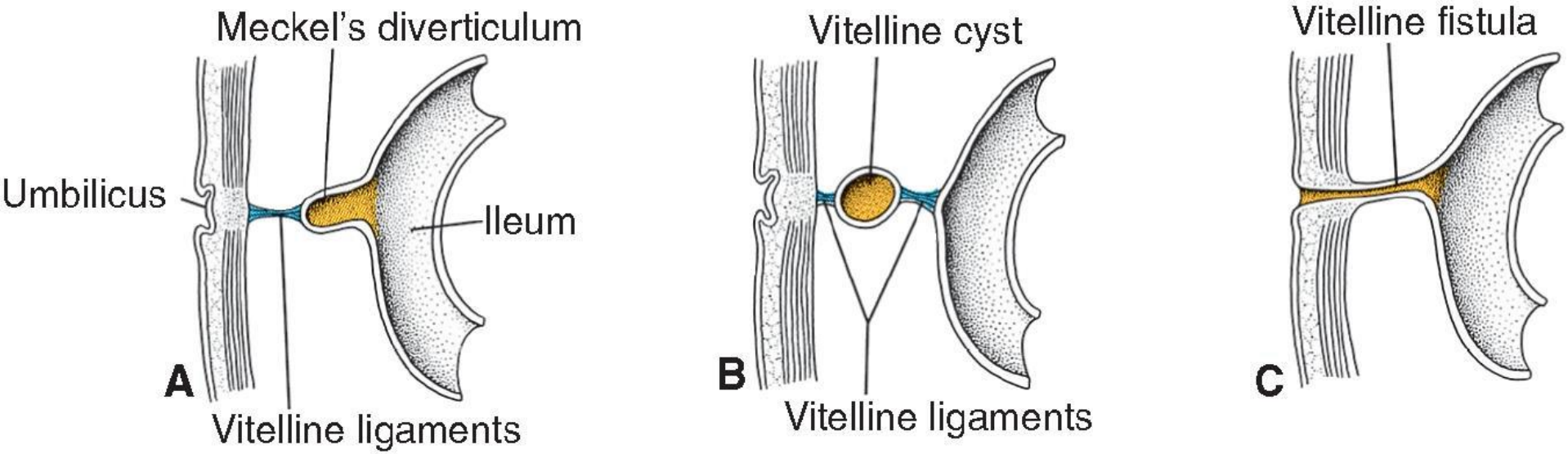

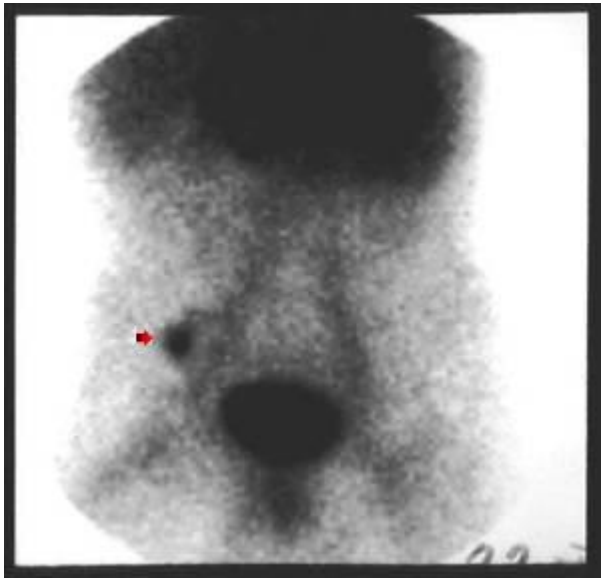

http://www.surgical-tutor.org.uk/default-home.htm?tutorials/meckels.htm~right

Diverticulum ilei *Meckeli*

- 2 %
- 0-100 cm from ostium ileocaecale

http://www.learningradiology.com/archives2009/COW%20378-Meckels%20Tic/caseoftheweek378page.htm

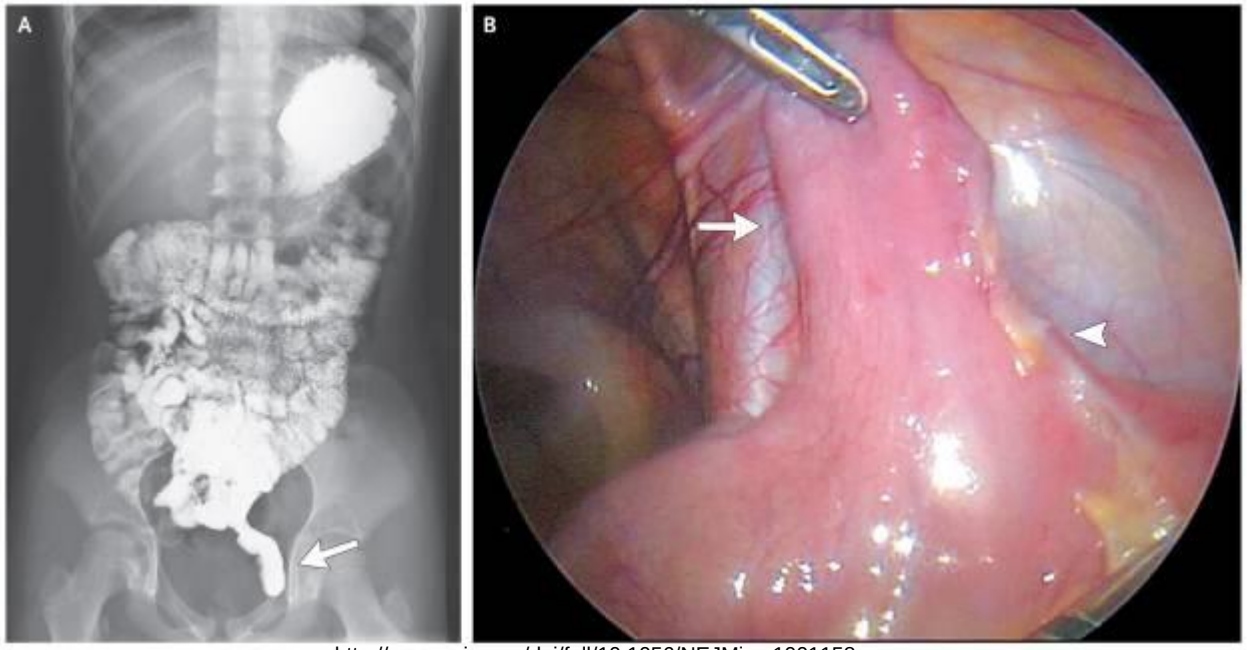

http://www.nejm.org/doi/full/10.1056/NEJMicm1001158

http://www.surgical-tutor.org.uk/default-home.htm?tutorials/meckels.htm~right

Histogenesis of intestine

early primitive gut
lined with simple columnar epithelium lying on splanchnic mesoderm

fast proliferation of epithelium temporarily obliterates lumen
(6th – 7th week)

during several weeks, recanalization proceeds
to form definitive intestinal lumen – lack of recanalization can cause
atresia or stenosis

small secondary lumina lined with stratified epithelium
small aggregates of mesoderm within epithelium
as a background of villus stroma
intestinal villi develop lined with simple columnar epithelium
crypts develop lined with intestinal stem cells

goblet cells and enteroendocrine cells in the second trimester

Physiological umbilical herniation

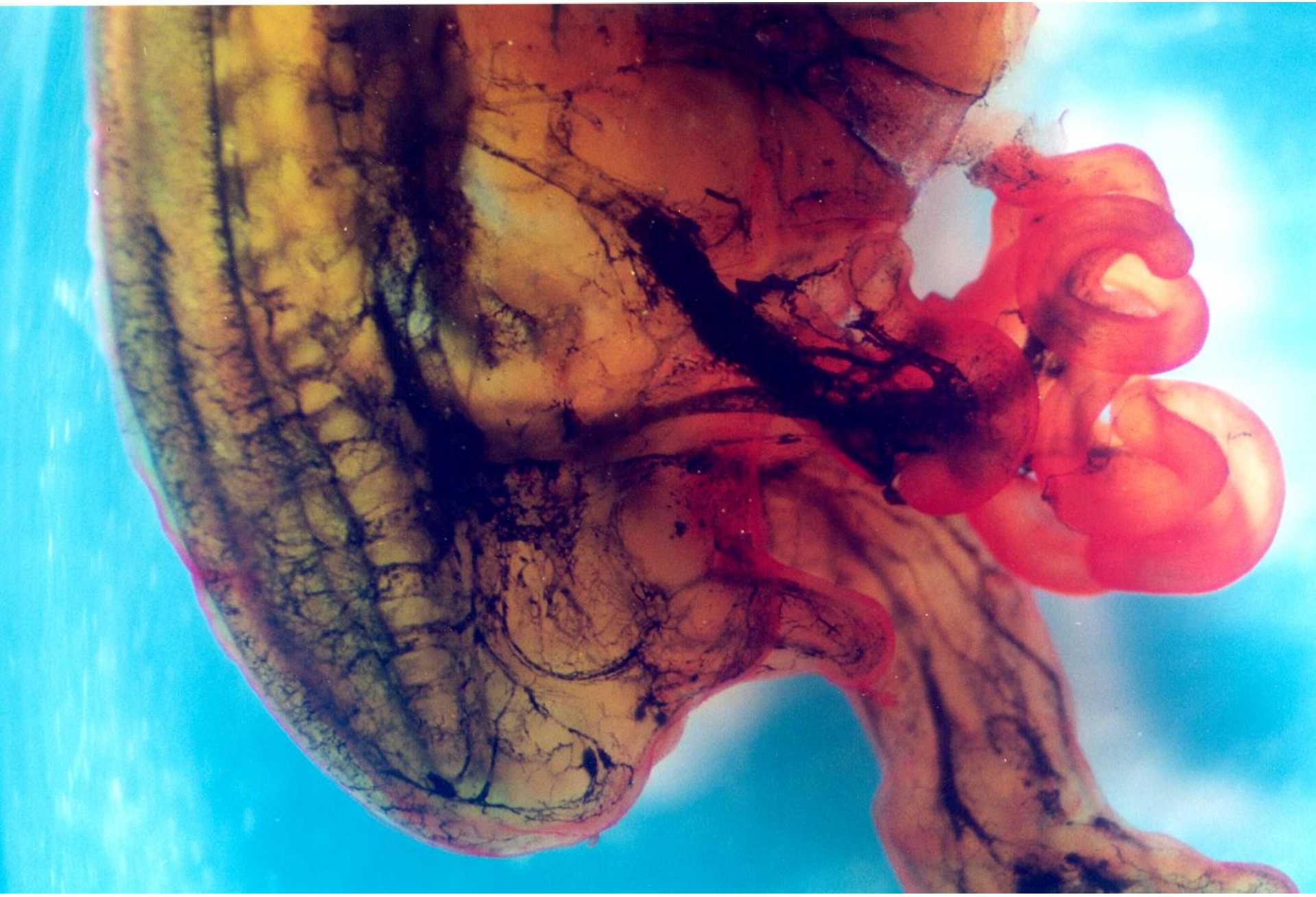

intestinal loops in the umbilical coelom (physiological hernia)

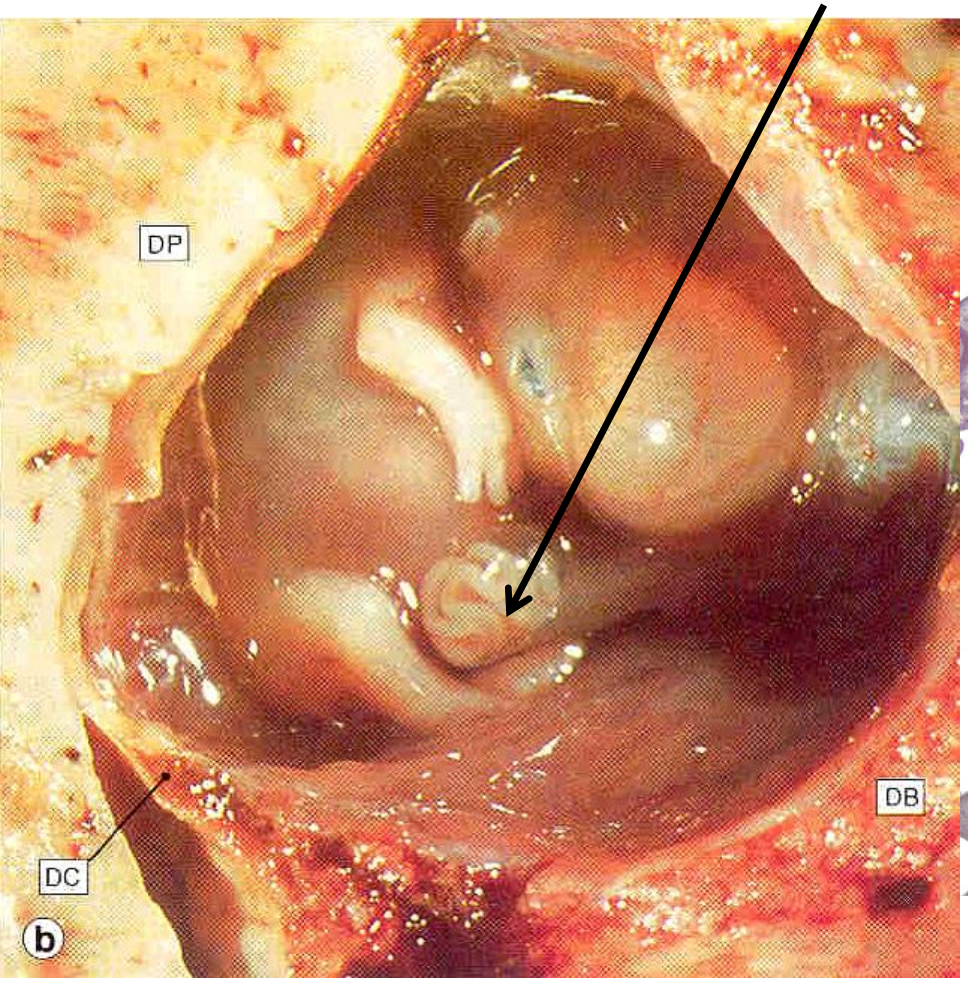

Omphalocele

Gastroschisis

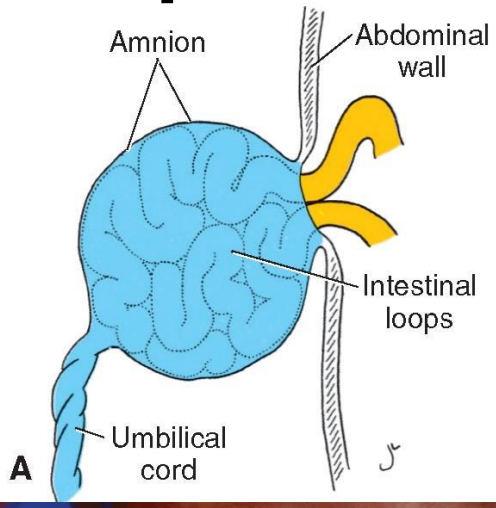

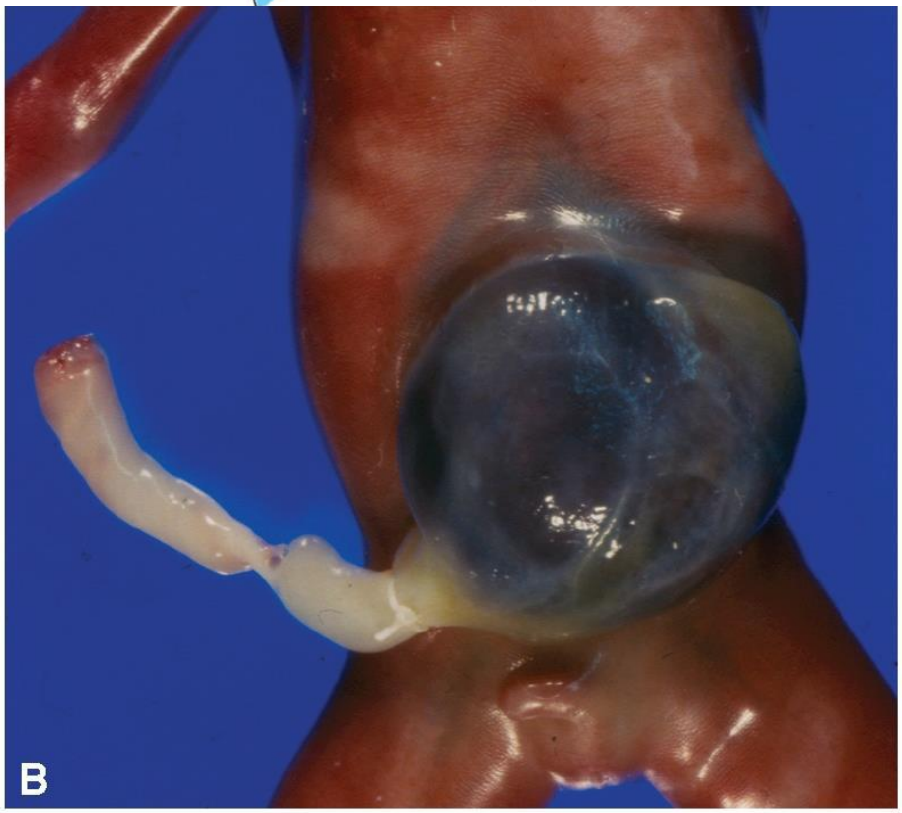

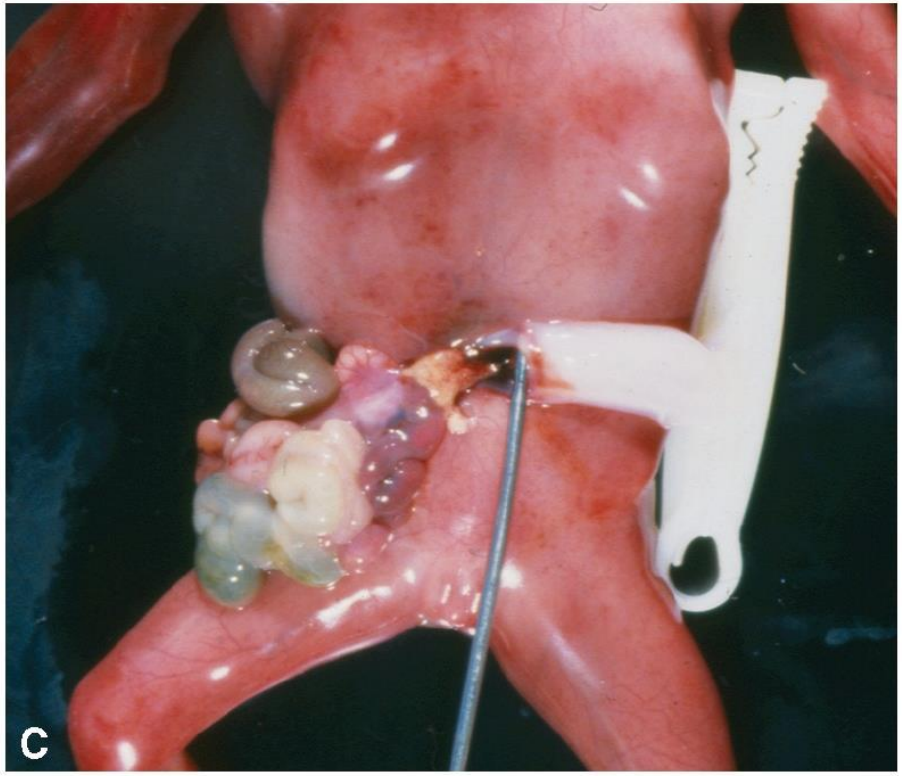

Cloaca, formation of urorectal septum

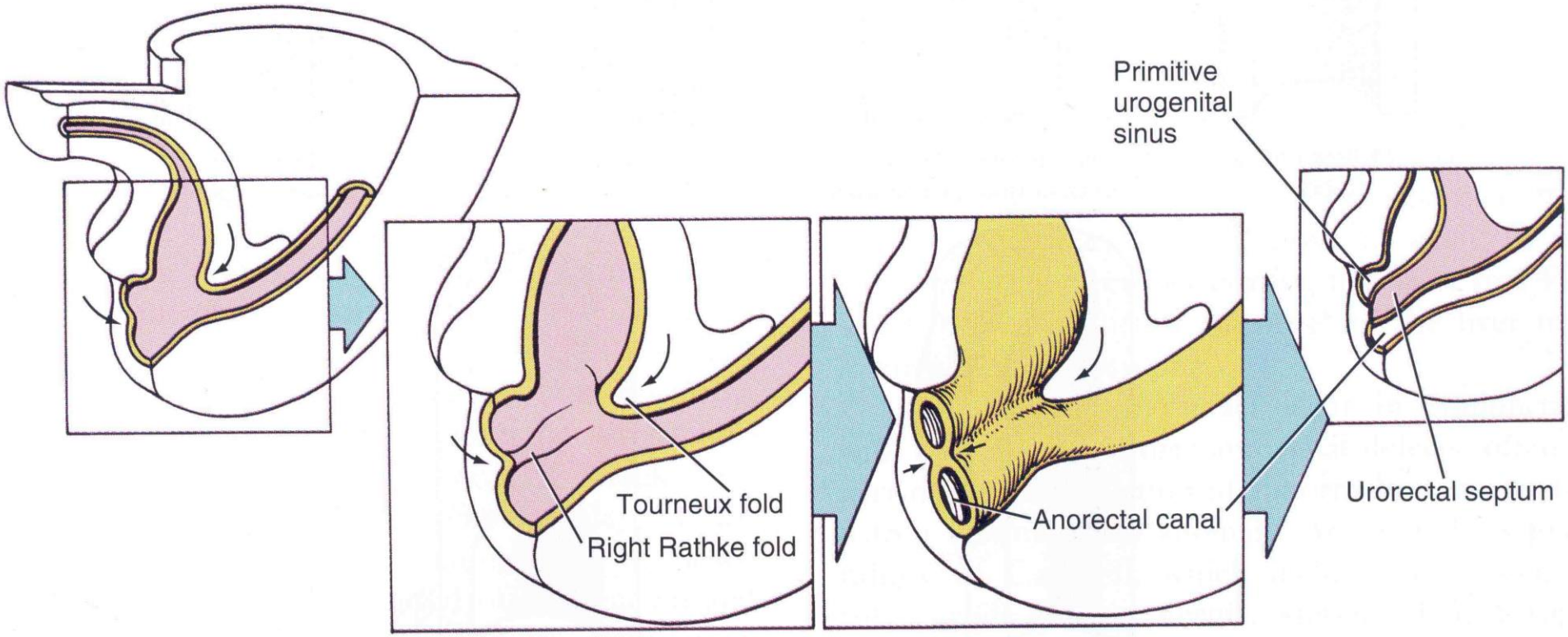

4th week 5th week 6th week 7th week

8th week

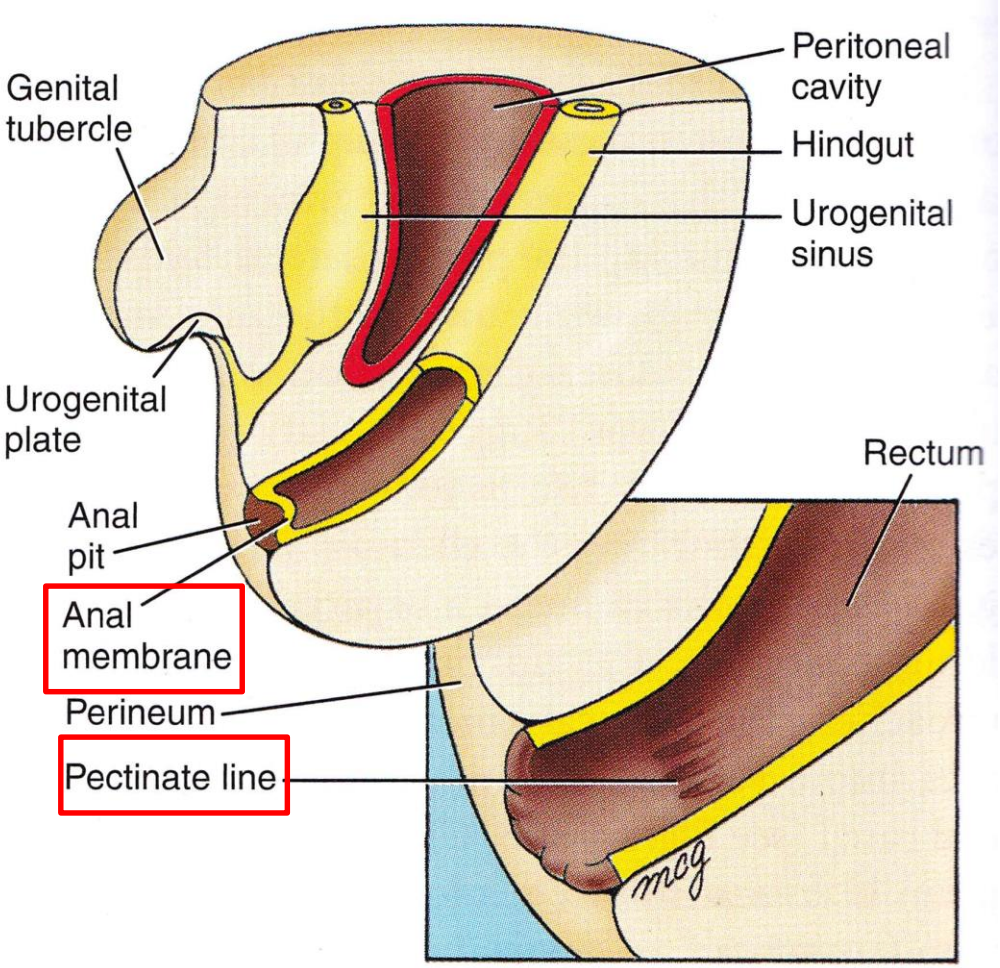

fetus

Megacolon congenitum
(Hirschprung's disease)

- inborn agangliosis of large intestine
- defect of neuroblast migration from neural crest
- multiplication of atypical nerve endings with acetylcholinesterase activity

Hirschprung's disease (types)

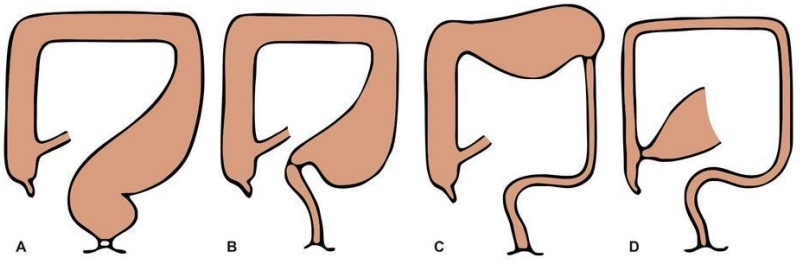

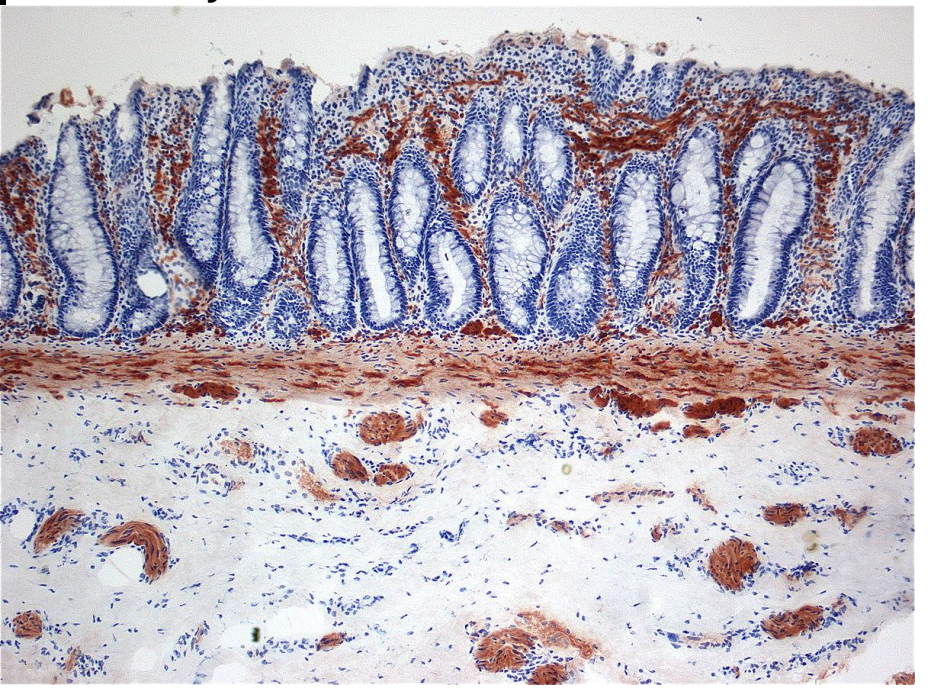

proof of acetylcholinesterase

DEVELOPMENT
OF THE RESPIRATORY SYSTEM

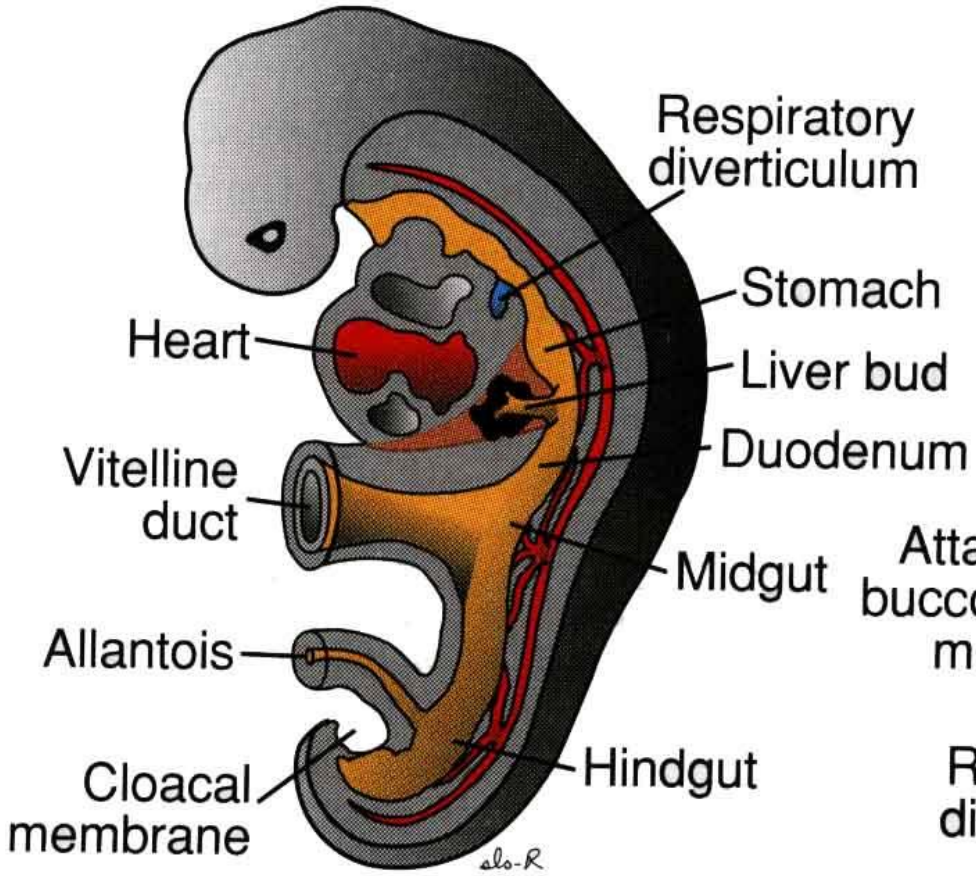
Respiratory diverticulum
Stomach
Heart
Liver bud
Duodenum
Vitelline duct
Midgut
Allantois
Hindgut
Cloacal membrane
A

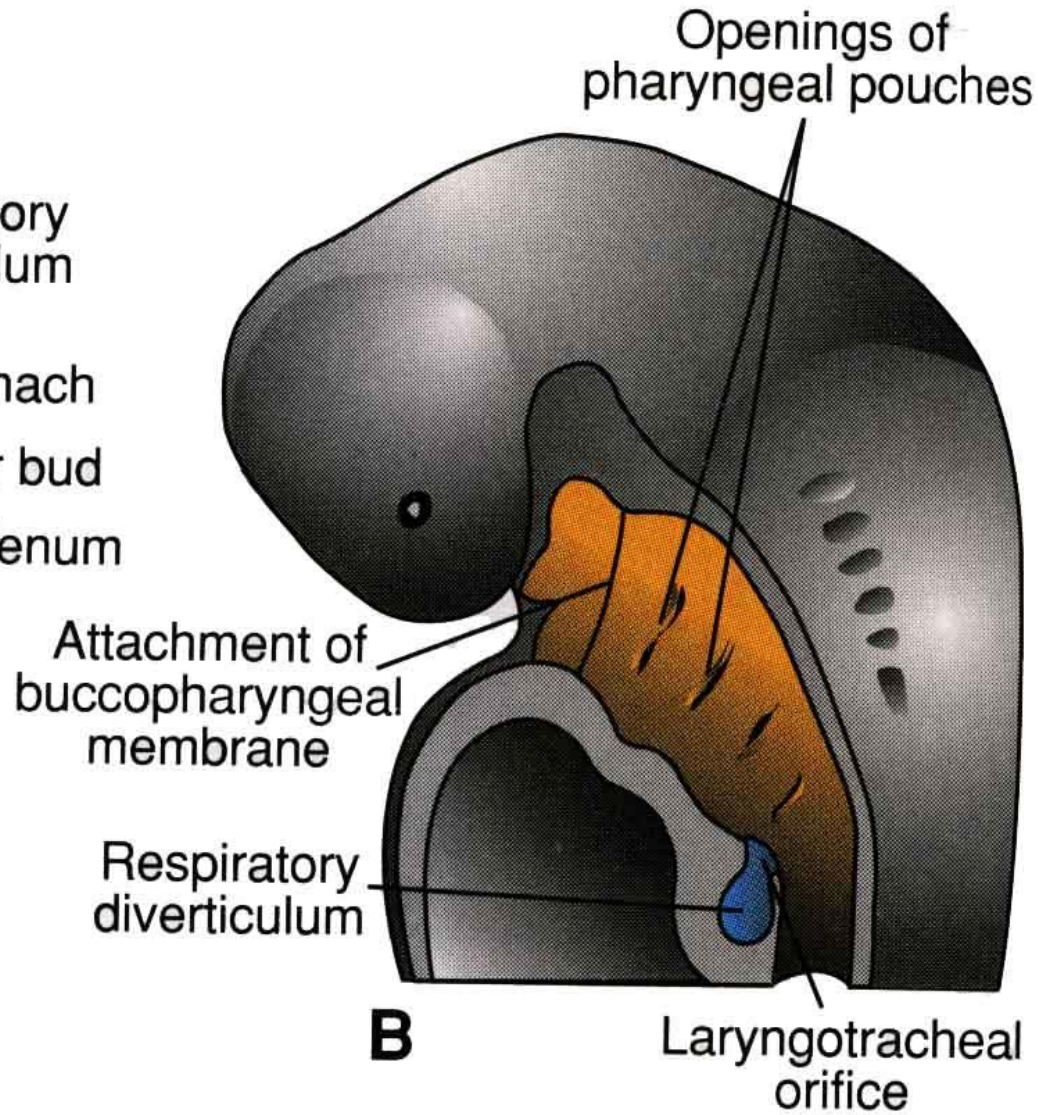
Openings of pharyngeal pouches
Attachment of buccopharyngeal membrane
Respiratory diverticulum
B
Laryngotracheal orifice

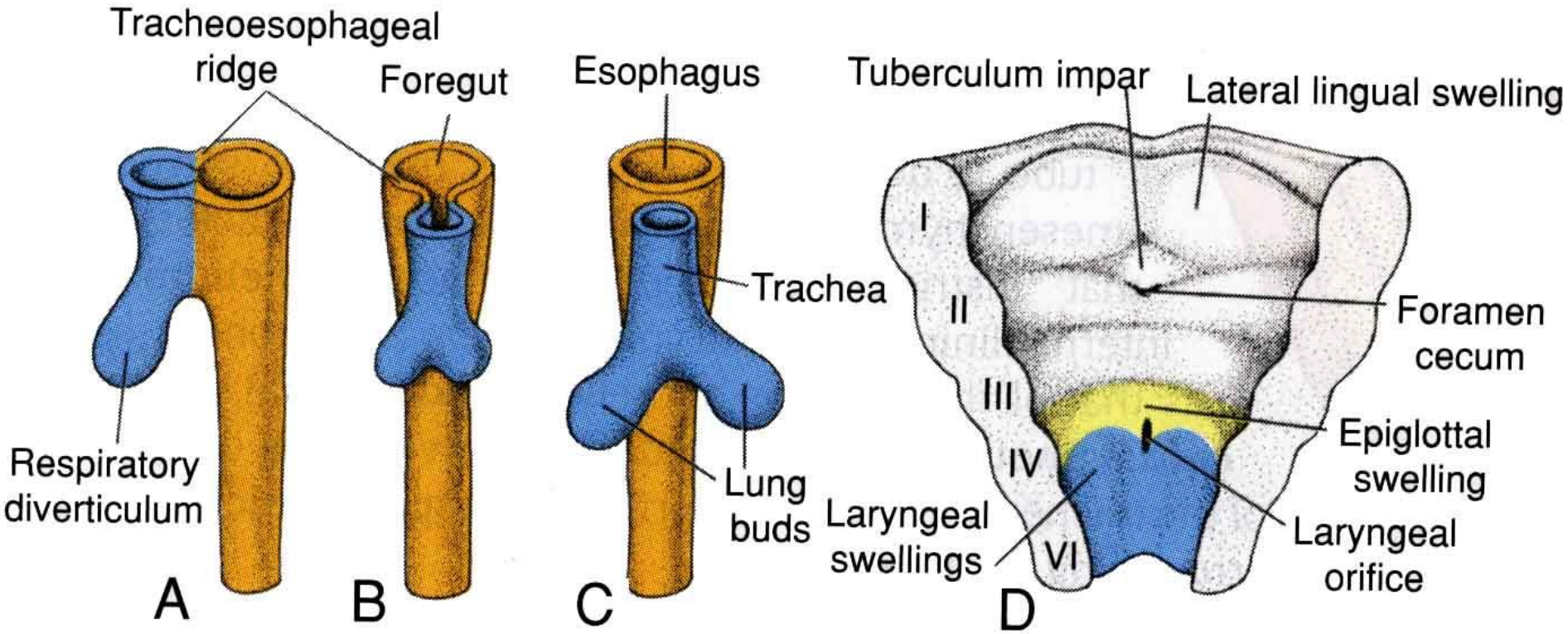
Tracheoesophageal ridge
Foregut
Esophagus
Tuberculum impar
Lateral lingual swelling
Trachea
Foramen cecum
Respiratory diverticulum
Lung buds
Epiglottal swelling
Laryngeal swellings
Laryngeal orifice
I
II
III
IV
VI
A
B
C
D

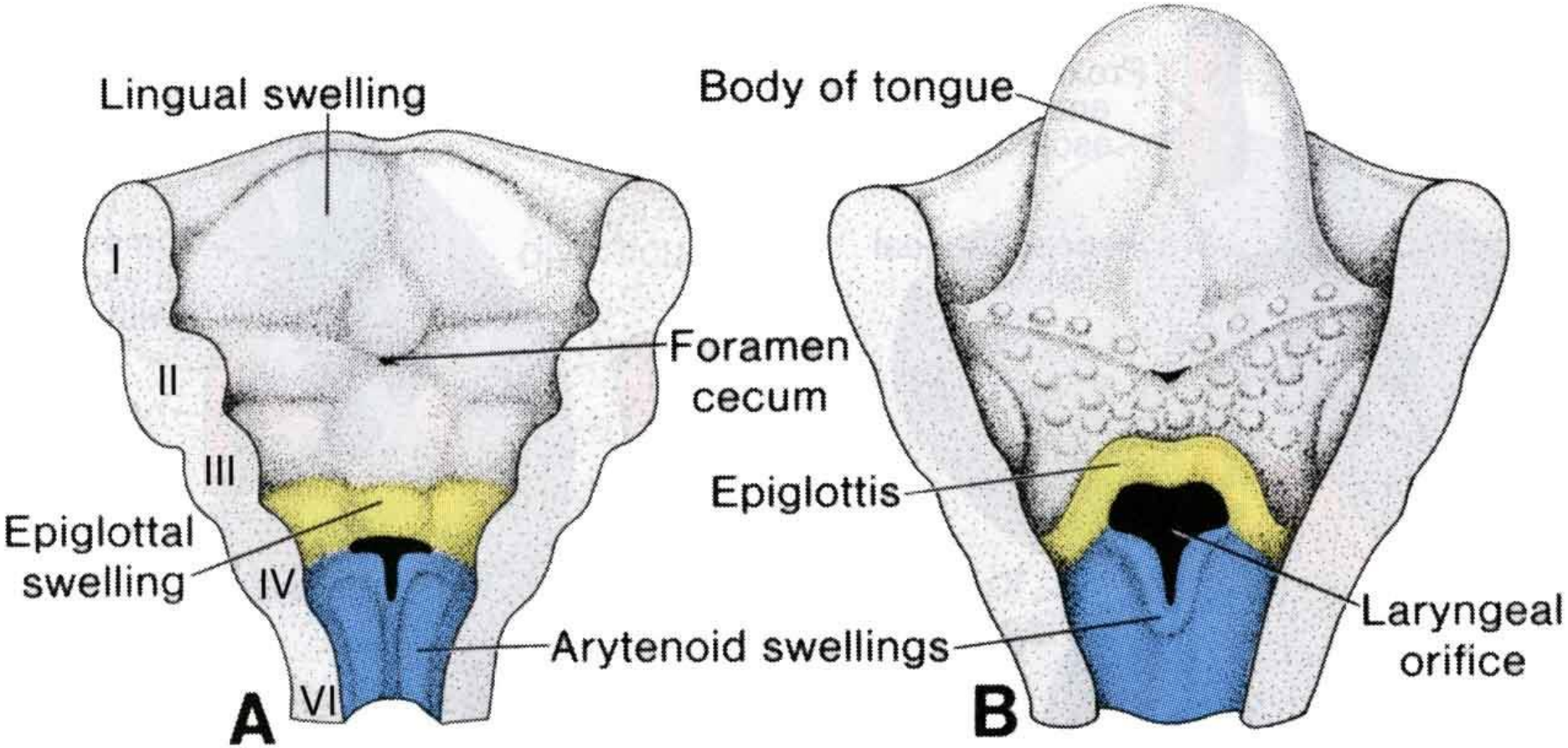
Lingual swelling
I
II
III
IV
VI
Foramen cecum
Epiglottal swelling
Arytenoid swellings
A
Body of tongue
Epiglottis
Laryngeal orifice
B

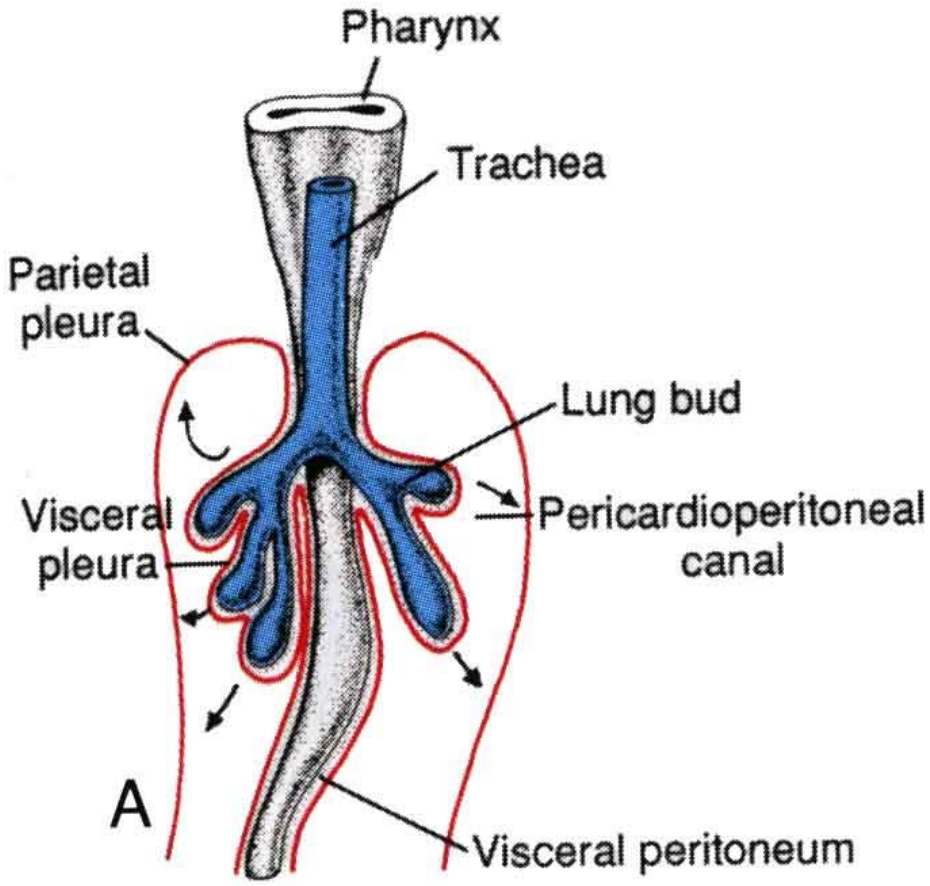
Pharynx
Trachea
Parietal pleura
Lung bud
Visceral pleura
Pericardioperitoneal canal
A
Visceral peritoneum

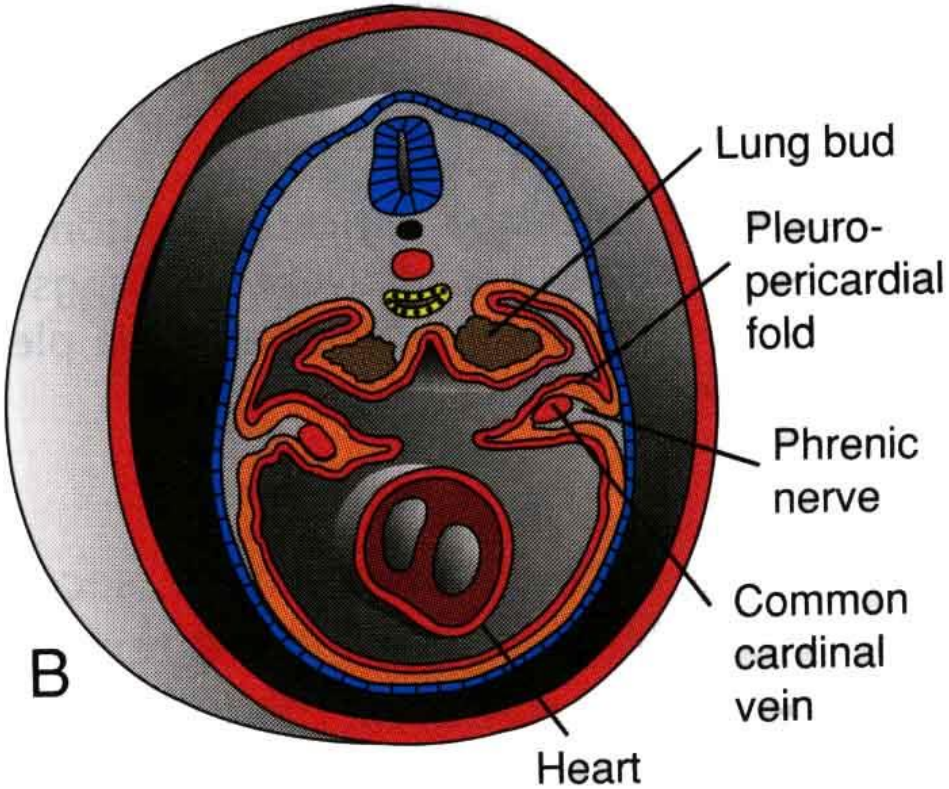
Lung bud
Pleuro-pericardial fold
Phrenic nerve
Common cardinal vein
B
Heart


100.0 u

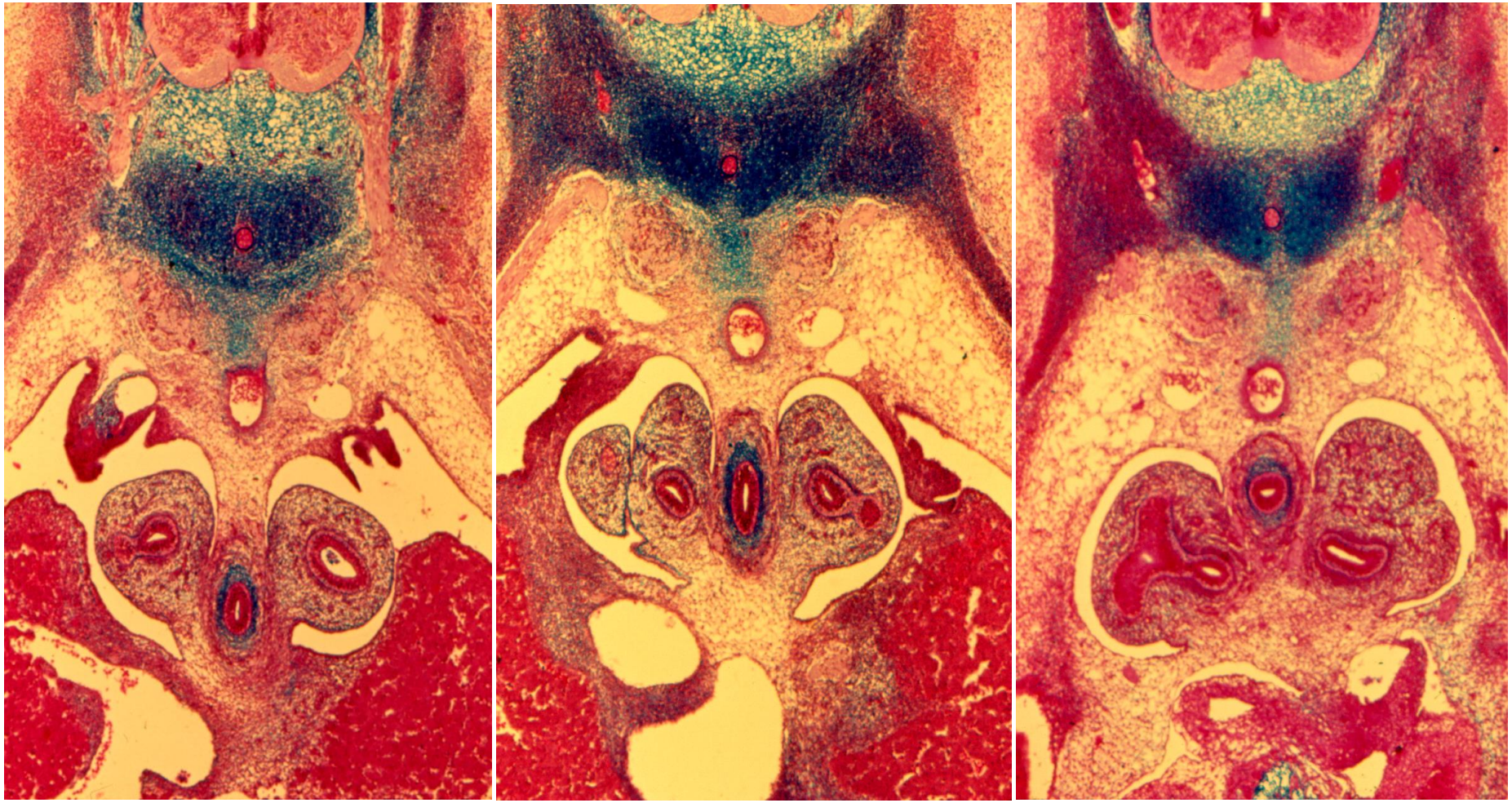

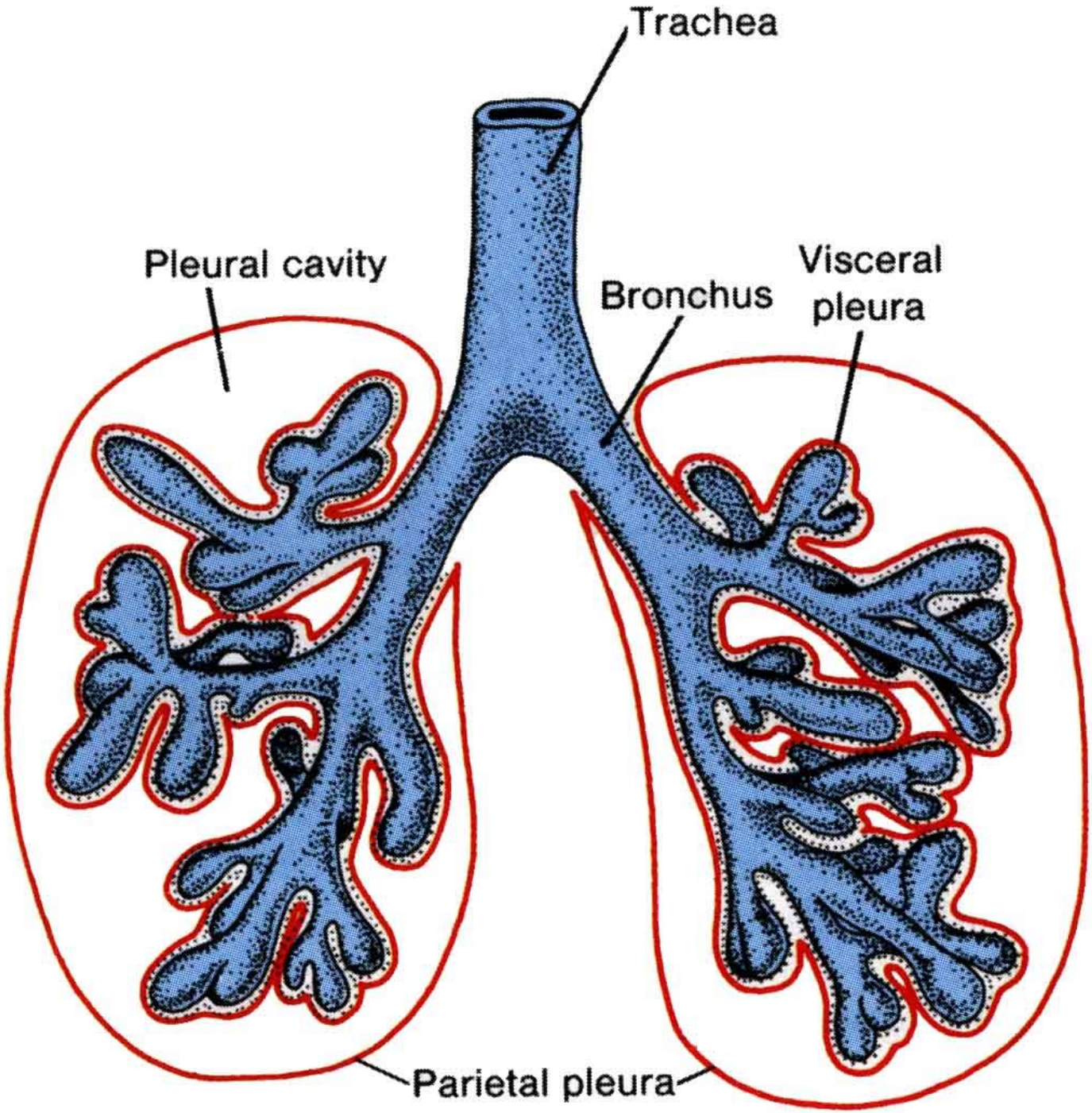
Trachea
Pleural cavity
Bronchus
Visceral pleura
Parietal pleura

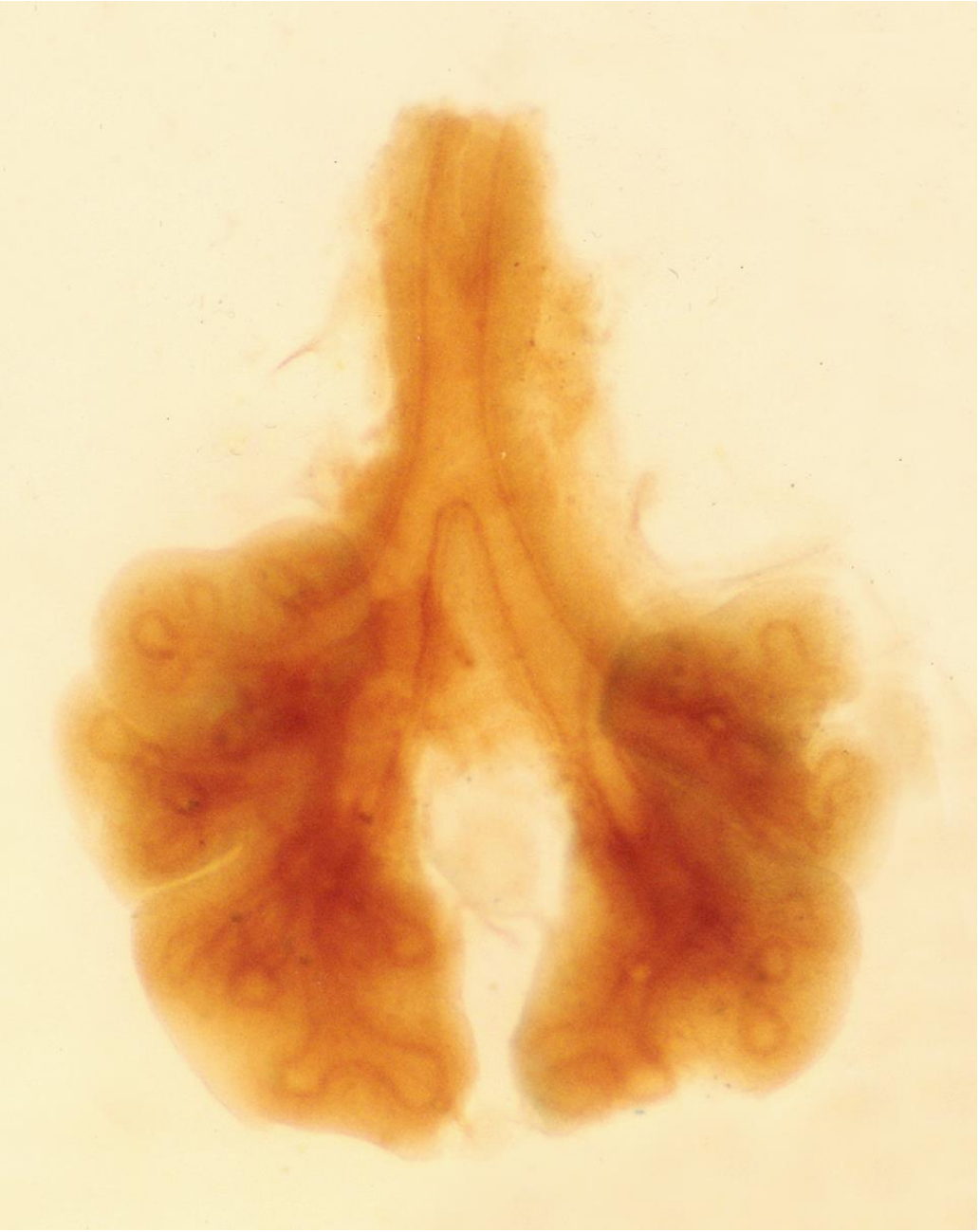

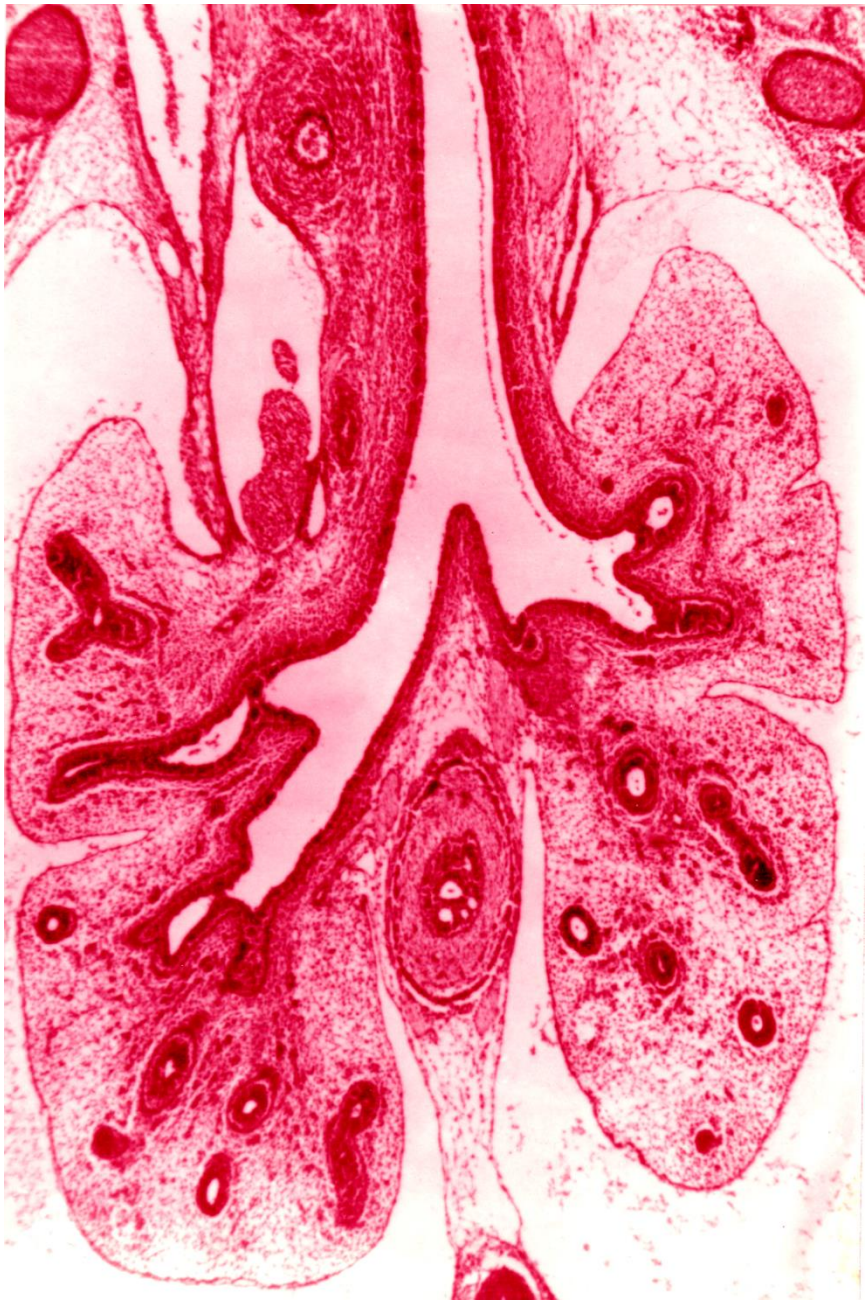

Maturation of the Lungs

Pseudoglandular period	5–16 weeks	Branching has continued to form terminal bronchioles. No respiratory bronchioles or alveoli are present.
Canalicular period	16–26 weeks	Each terminal bronchiole divides into 2 or more respiratory bronchioles, which in turn divide into 3–6 alveolar ducts.
Terminal sac period	26 weeks to birth	Terminal sacs (primitive alveoli) form, and capillaries establish close contact.
Alveolar period	8 months to childhood	Mature alveoli have well-developed epithelial endothelial (capillary) contacts.

Pseudoglandular period

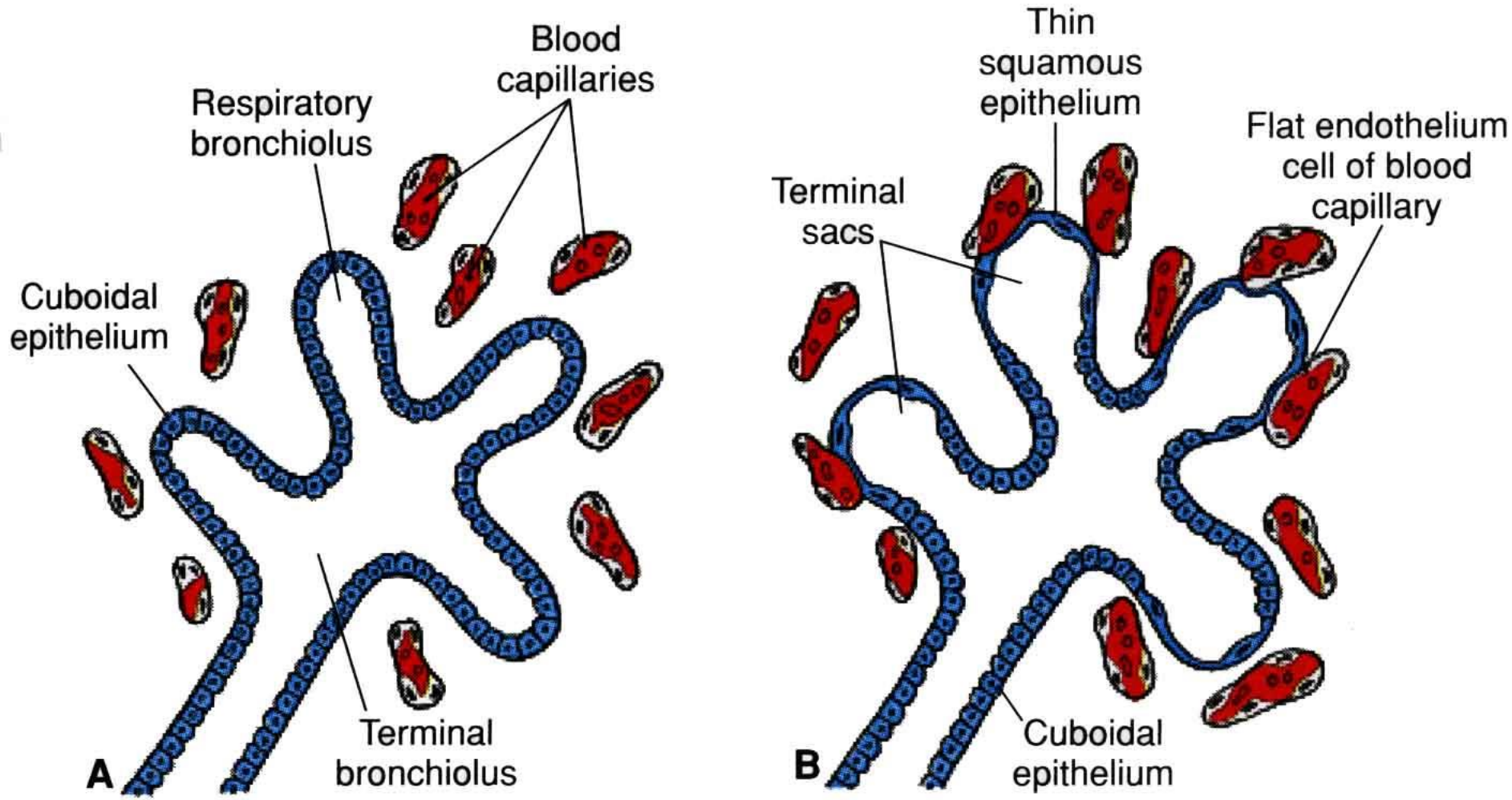
Blood capillaries
Respiratory bronchiolus
Cuboidal epithelium
Terminal bronchiolus
A
Thin squamous epithelium
Flat endothelium cell of blood capillary
Terminal sacs
Cuboidal epithelium
B

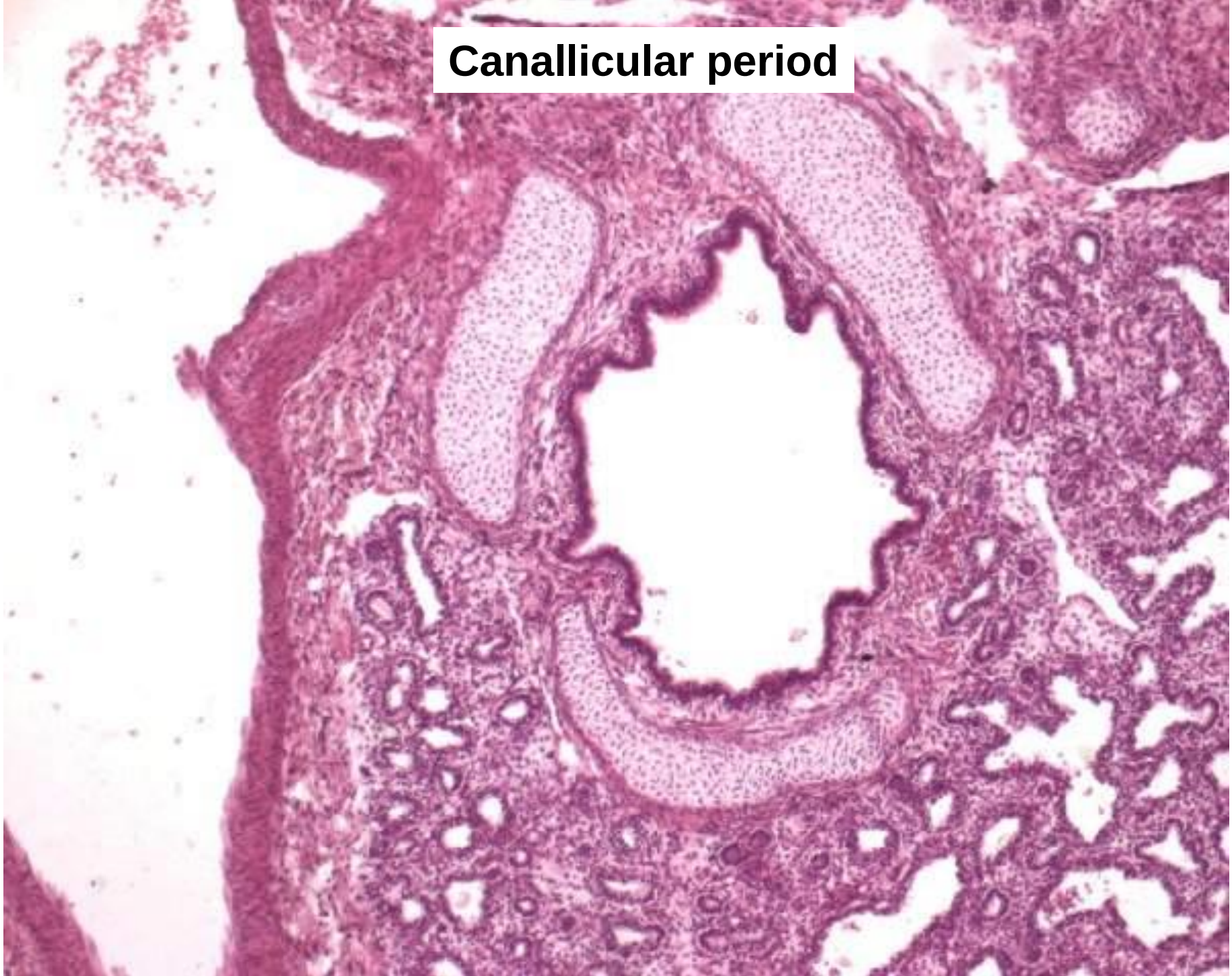
Canallicular period

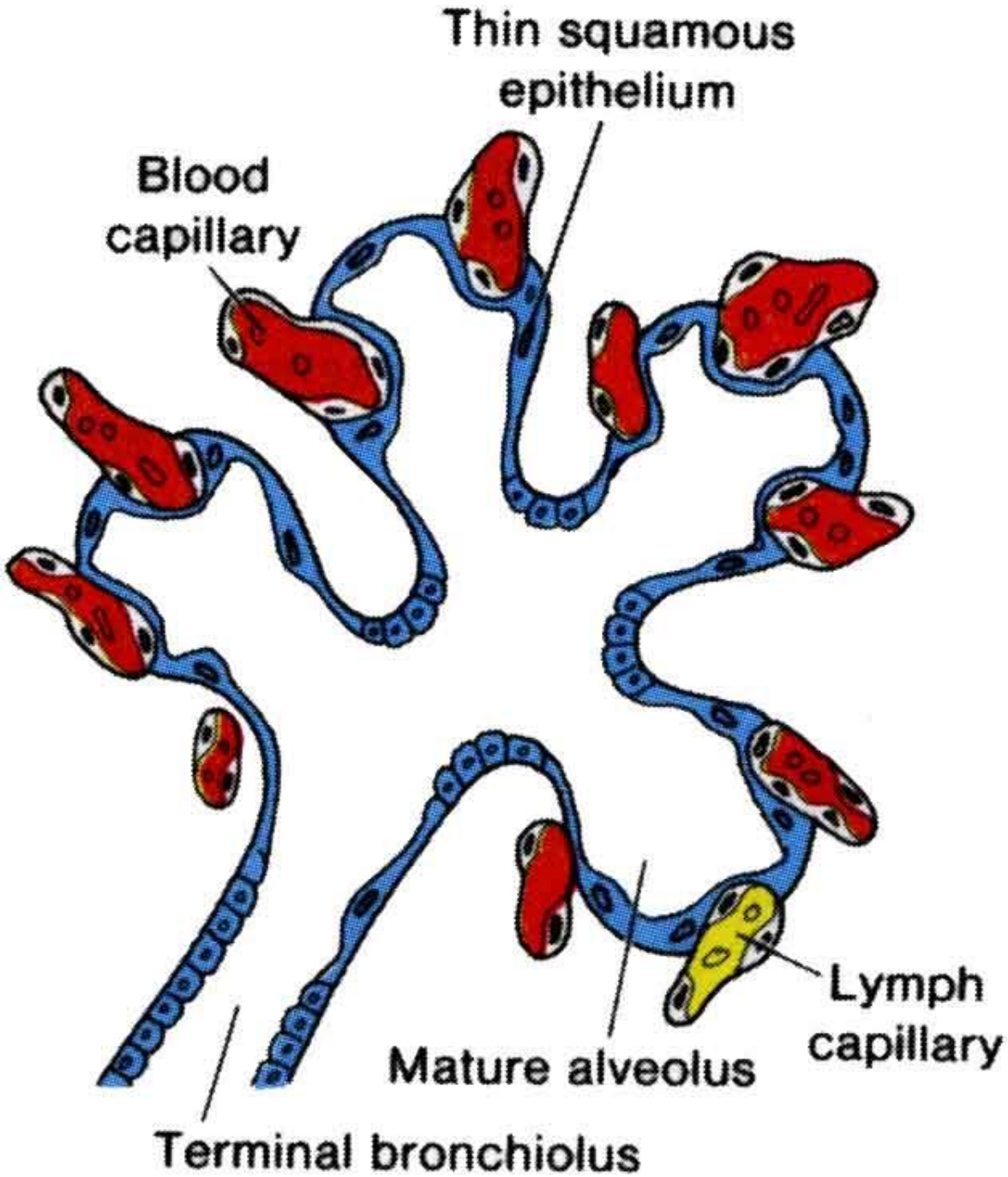
Thin squamous
epithelium
Blood
capillary
Lymph
capillary
Mature alveolus
Terminal bronchiolus

DEVELOPMENT OF THE COELOM AND DIAPHRAGM

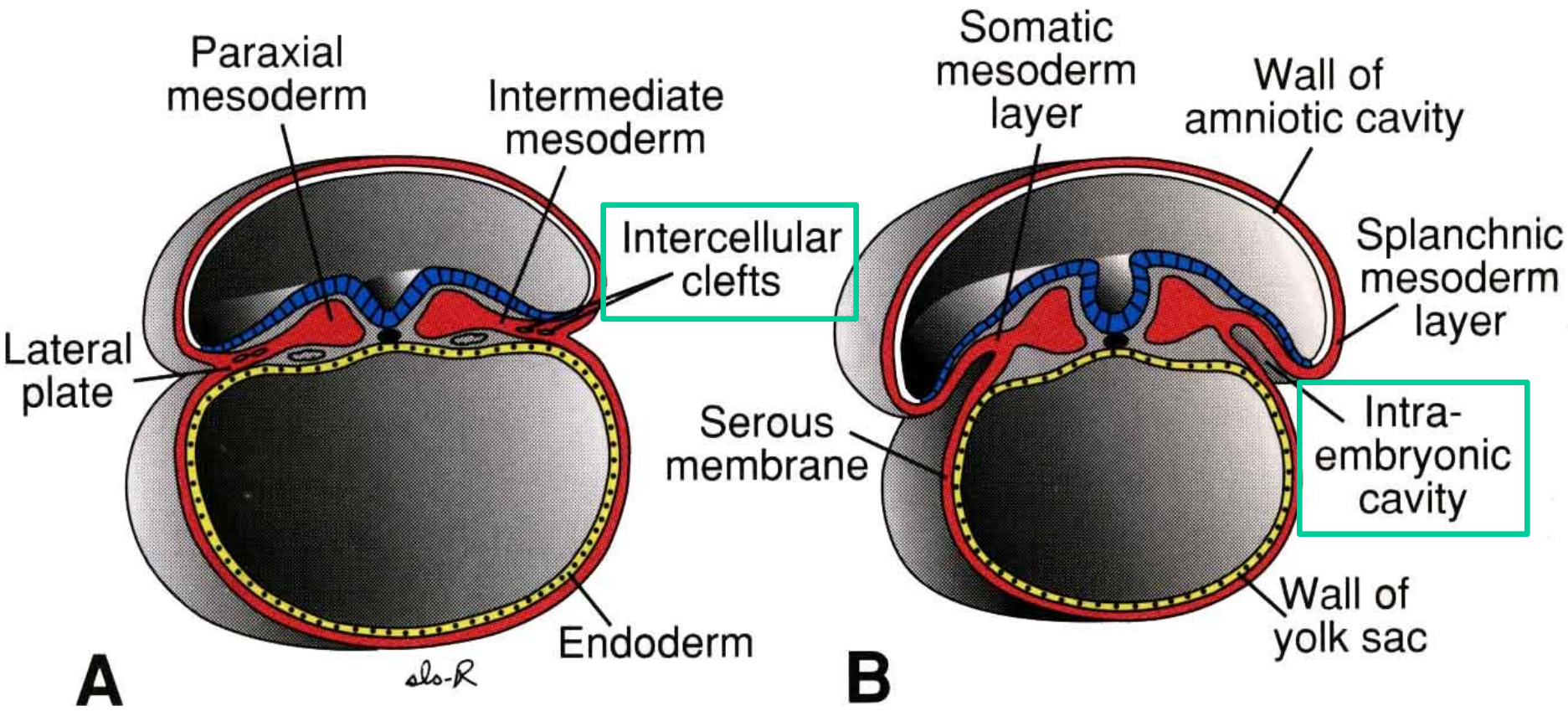

19 days

20 days

19th day

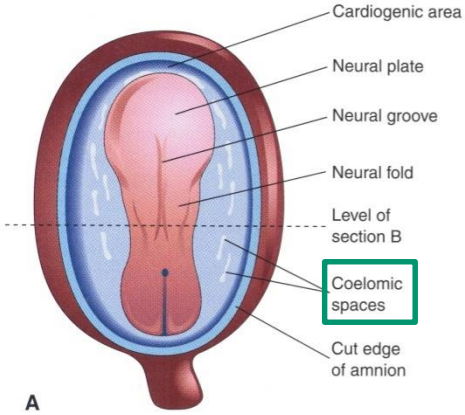

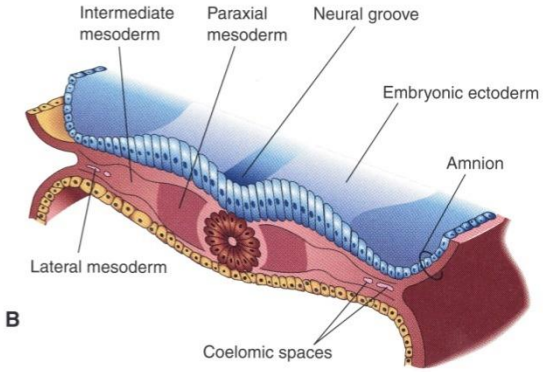

20th day

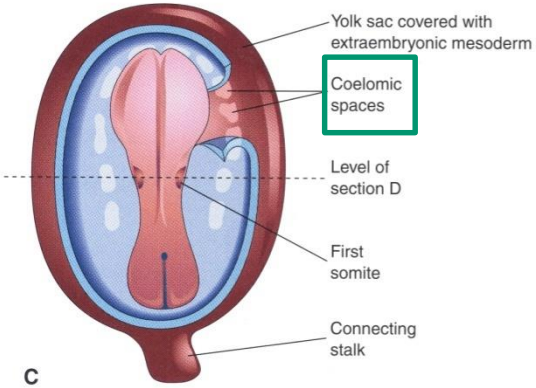

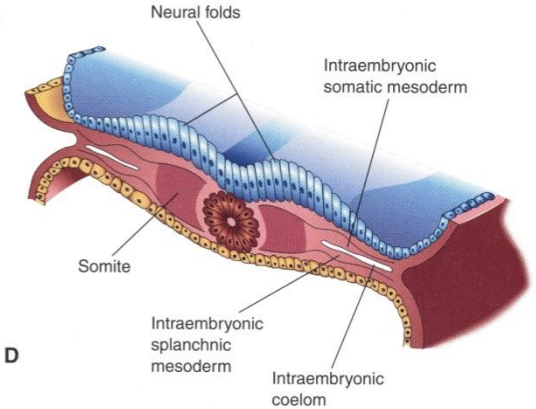

21st day

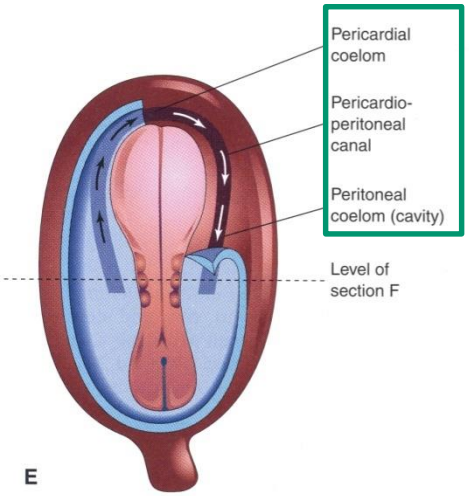

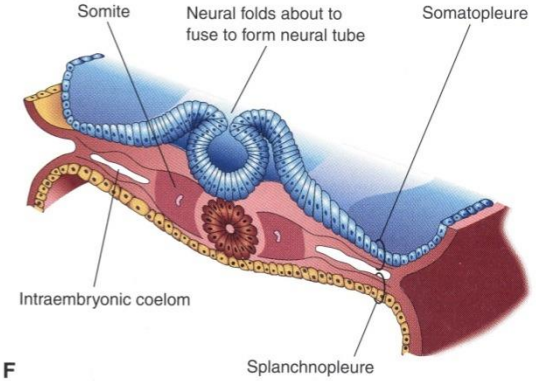

Lateral folding (rolling up)

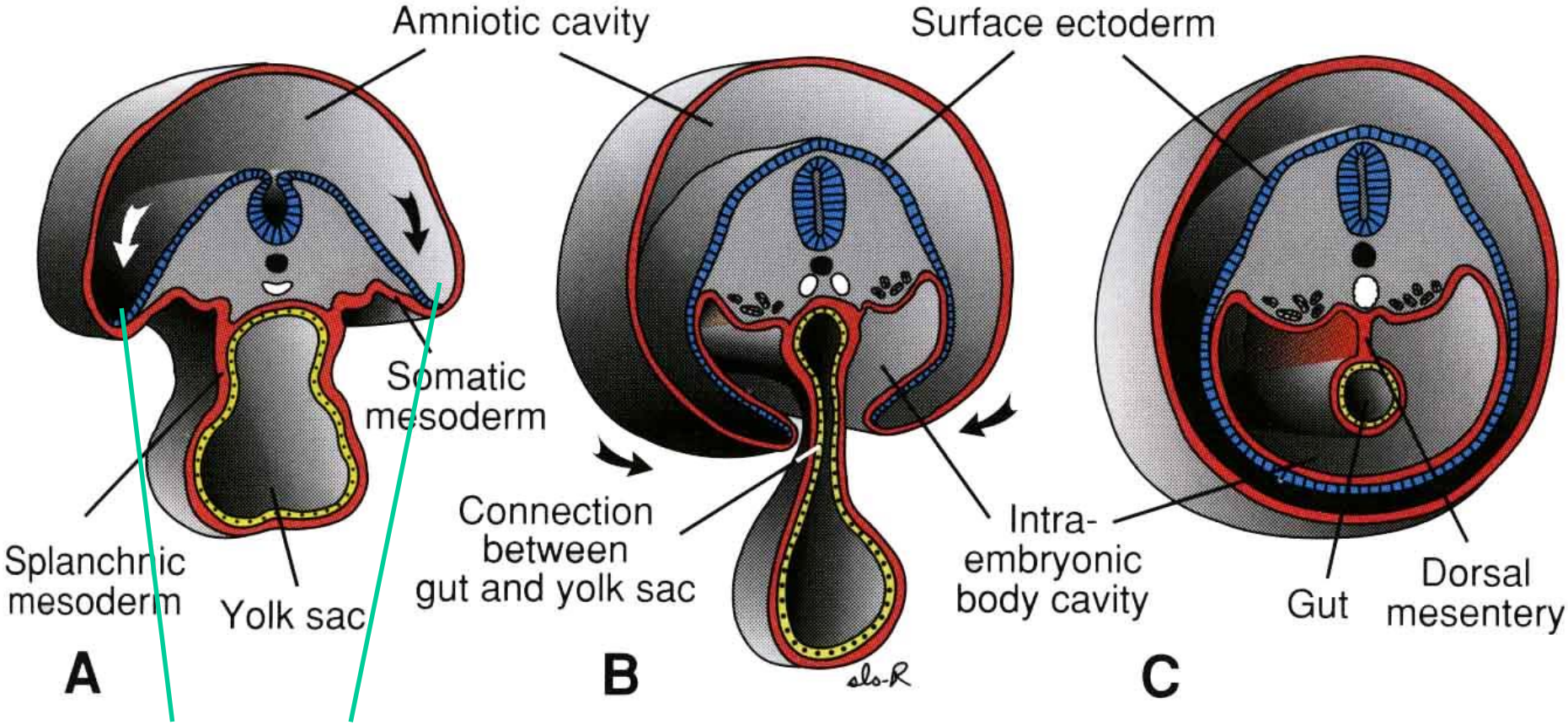

lateral body wall folds

21 days

24 days

28 days

Craniocaudal folding

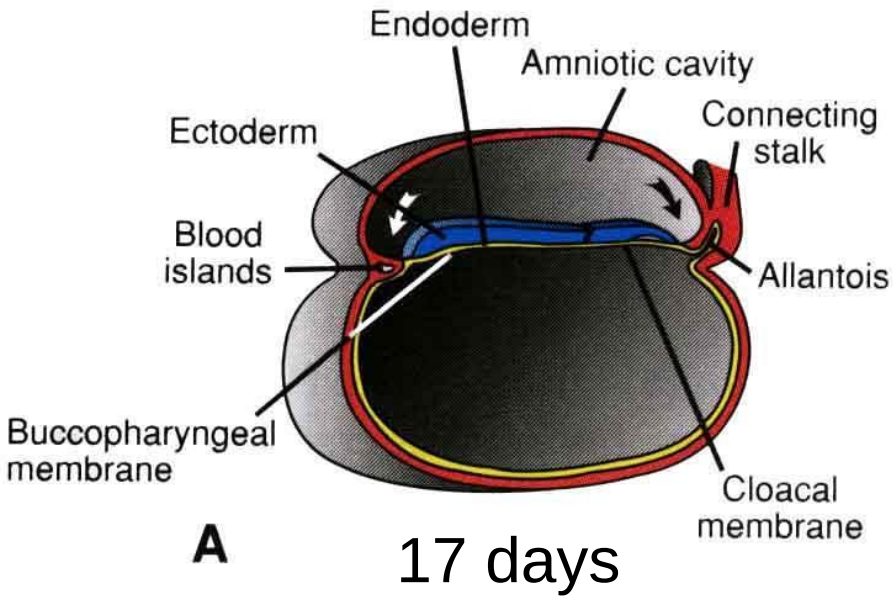

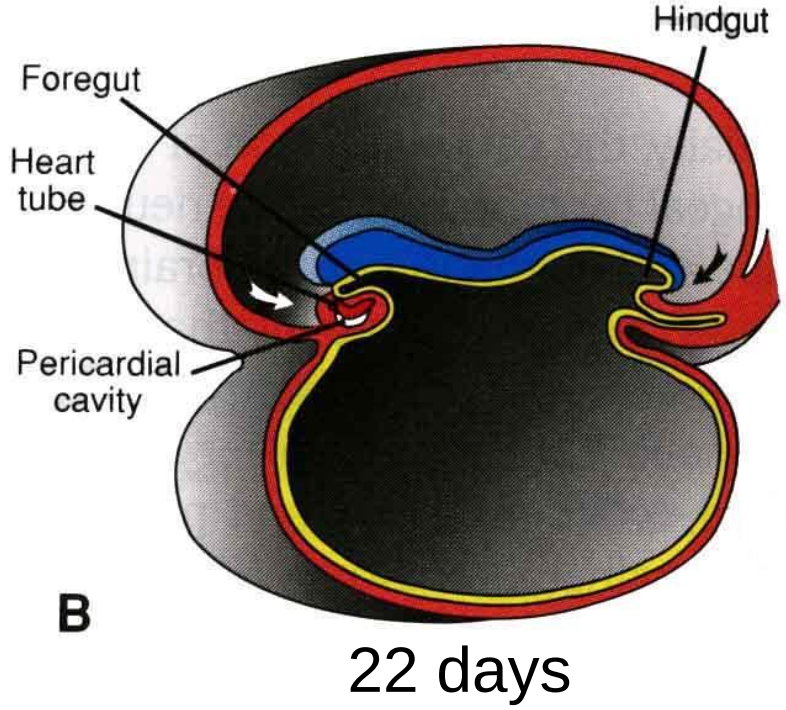

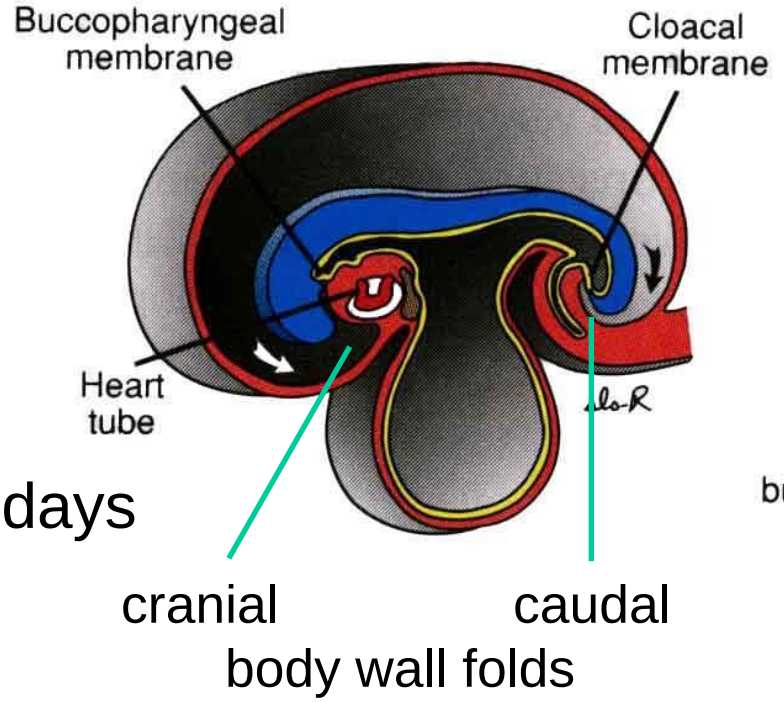

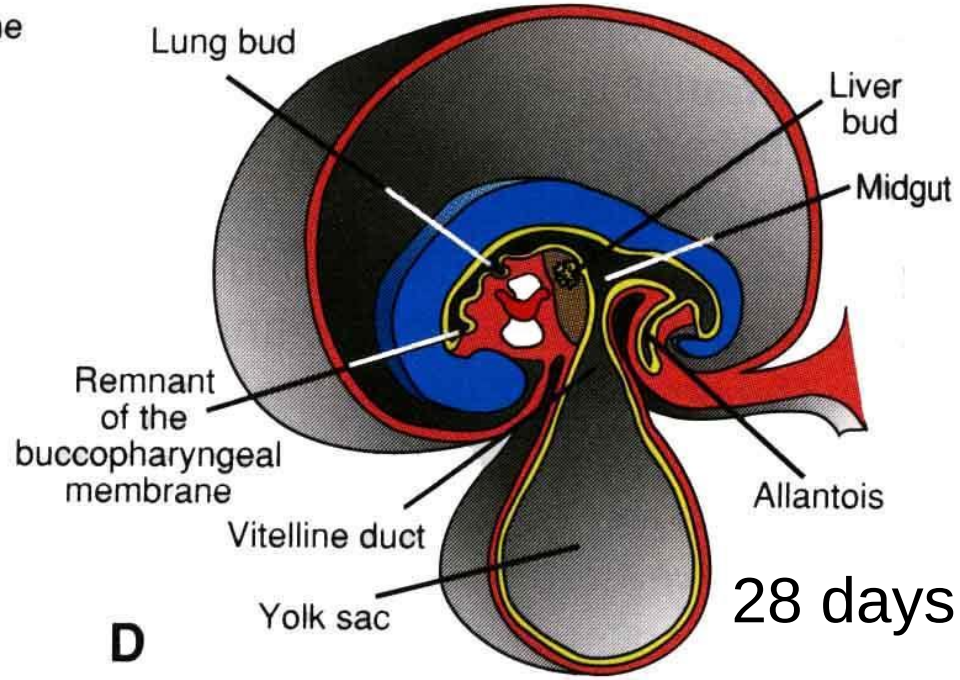

Intraembryonic coelom (24th day)

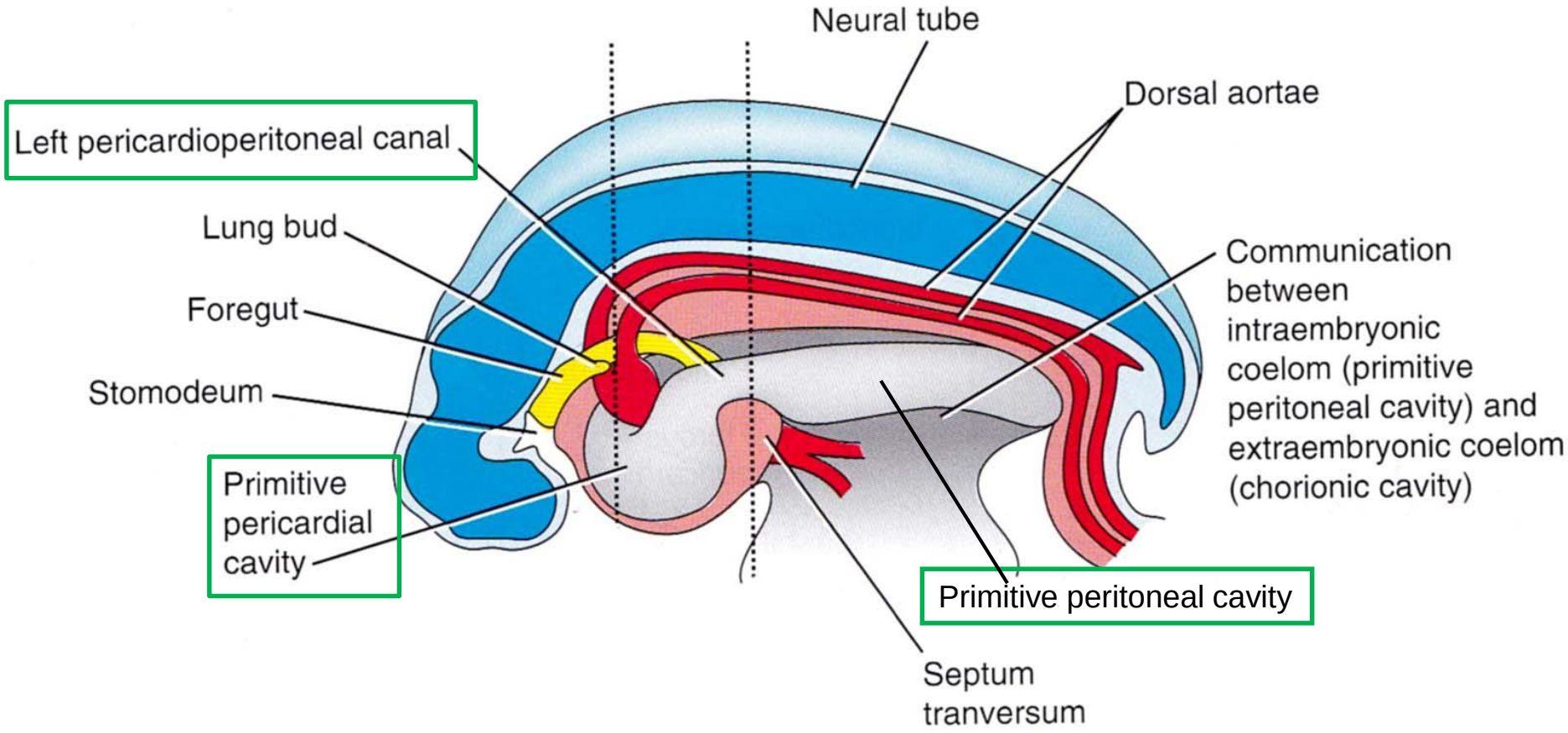

Separation of pericardial cavity from pericardoperitoneal canals

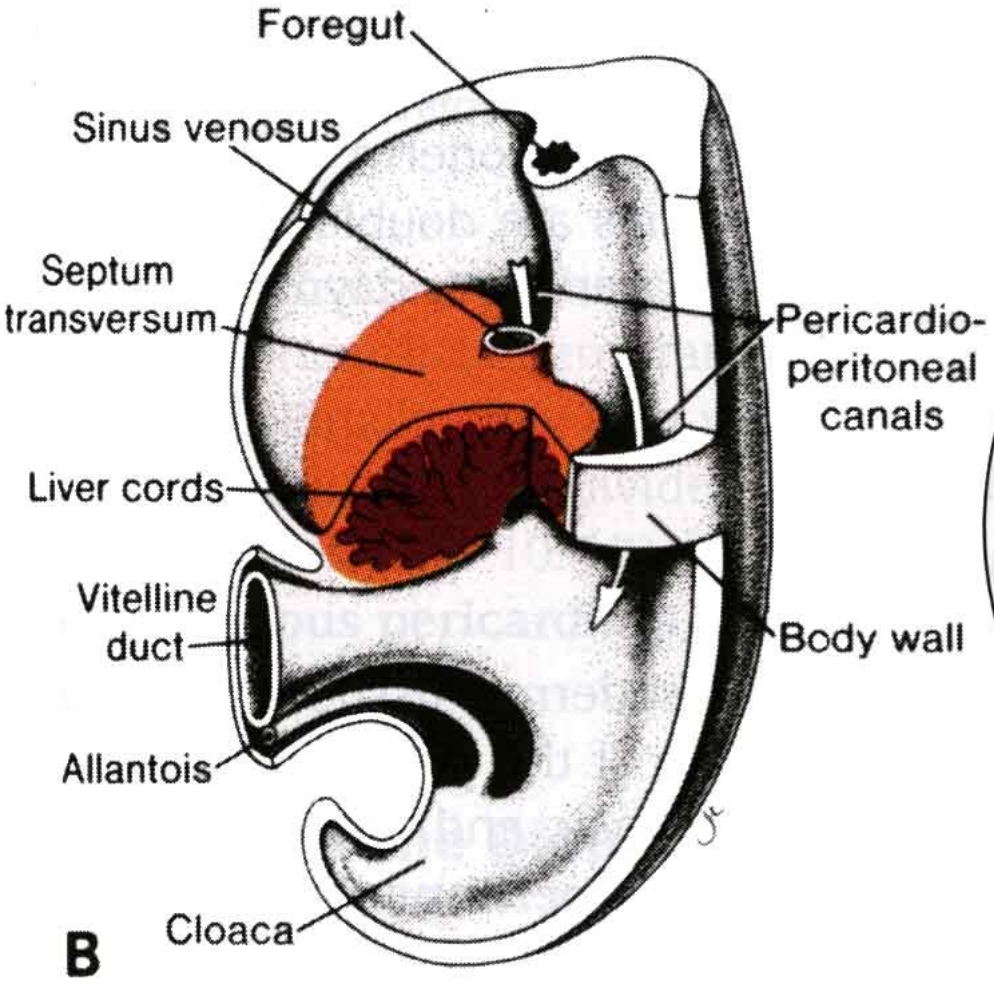

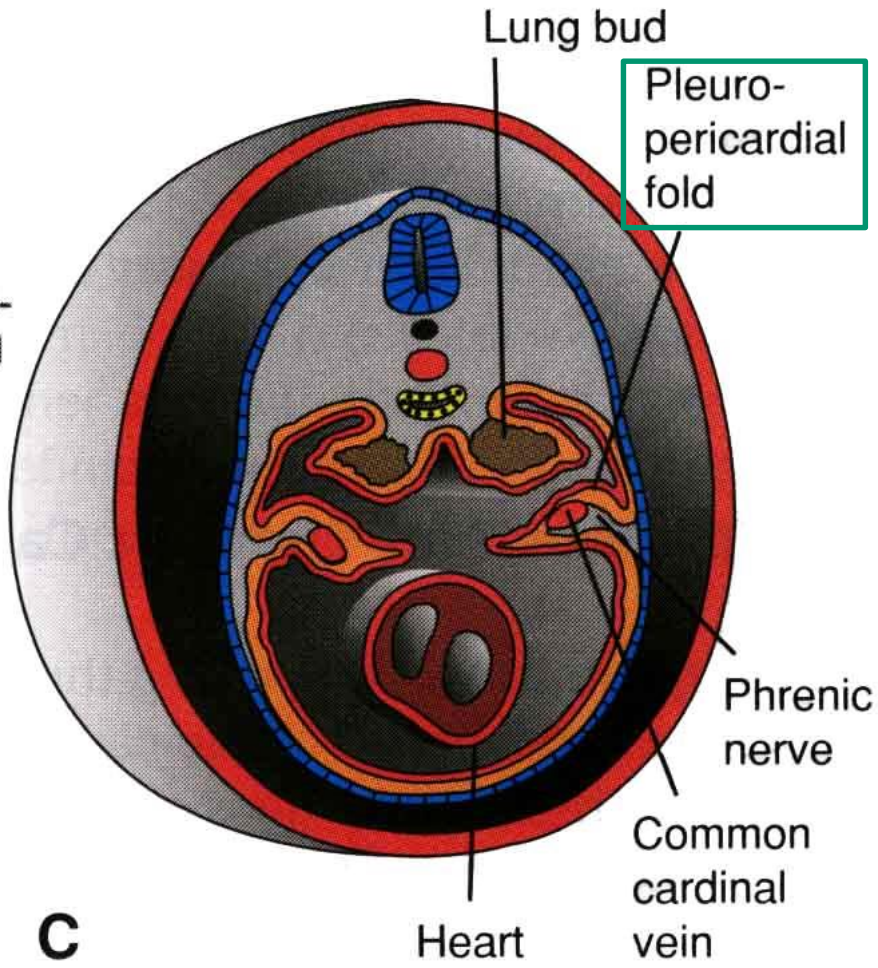

5th week

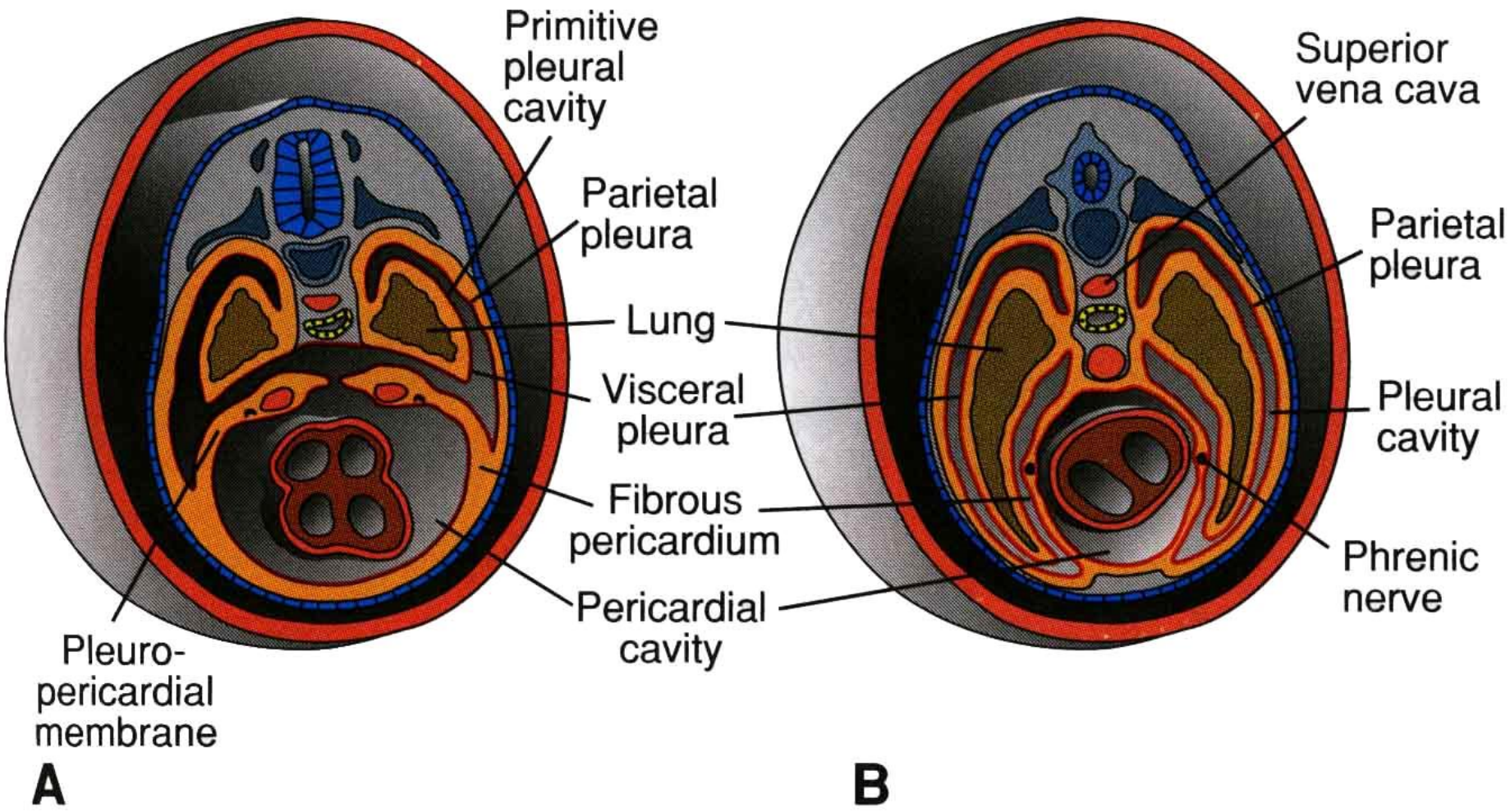

6th week

7th week

Separation of peritoneal cavity from pericardoperitoneal canals

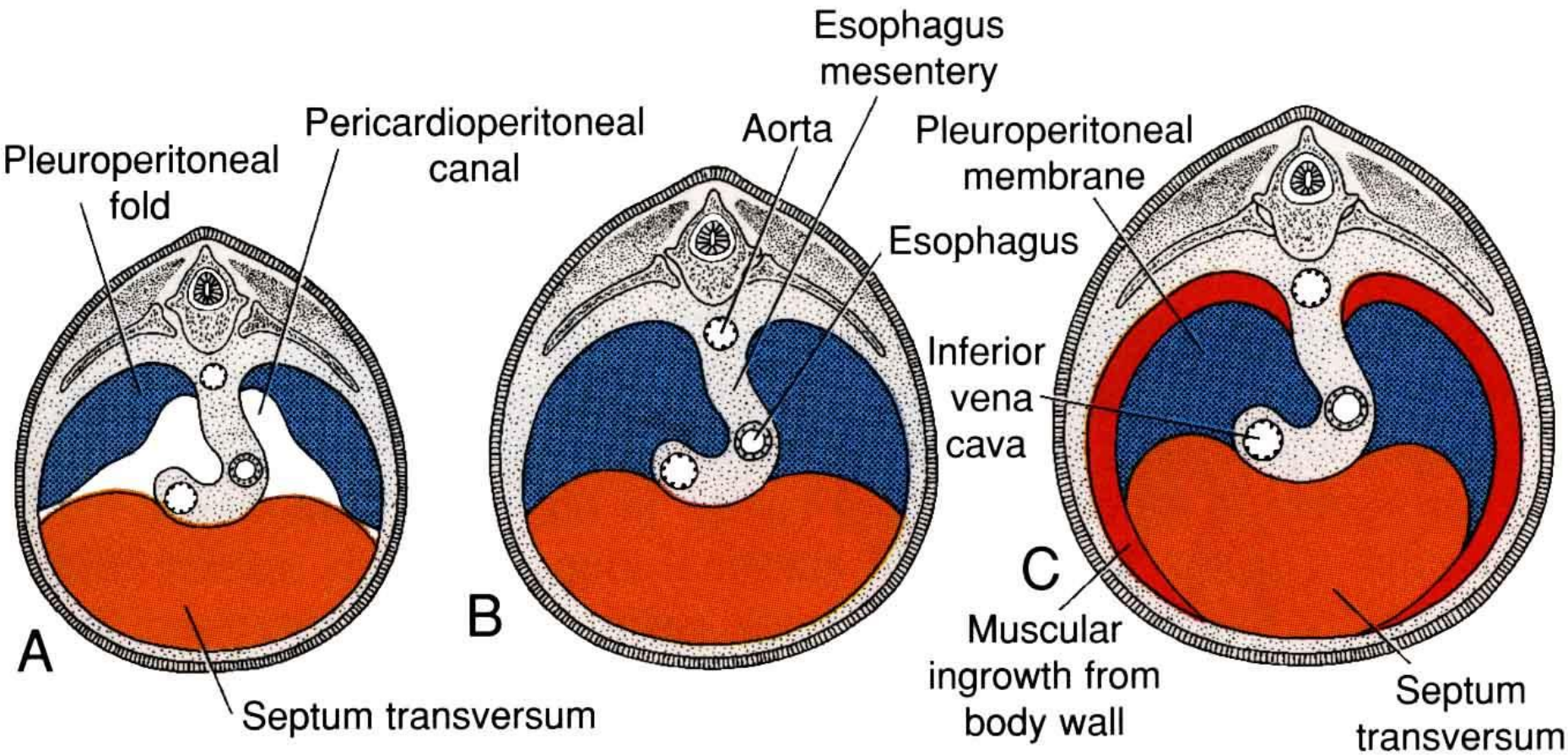

4 anlages:
- pleuroperitoneal folds (somatopleura)
- septum transversum (splanchnopleura)
- mesentery (splanchnopleura)
- abaxial muscles of cervical somites via the body wall

Congenital diaphragmatic hernia

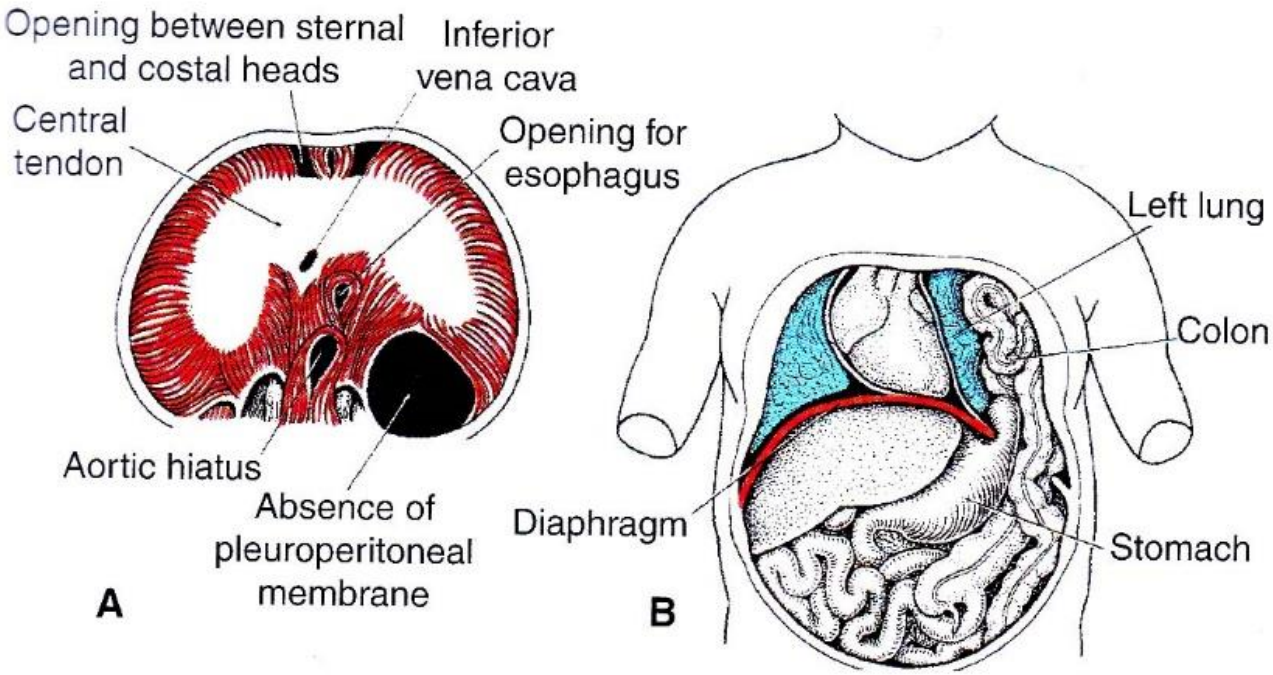

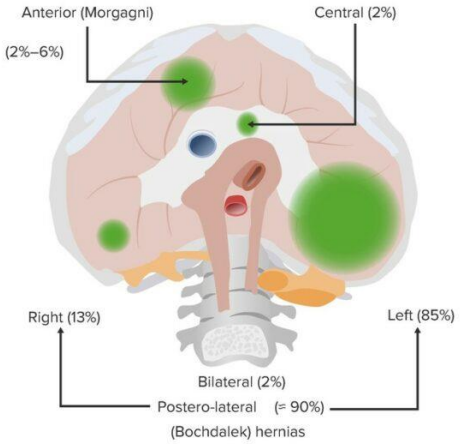

1 : 2.000