Endocrine system

Hormonal signalling

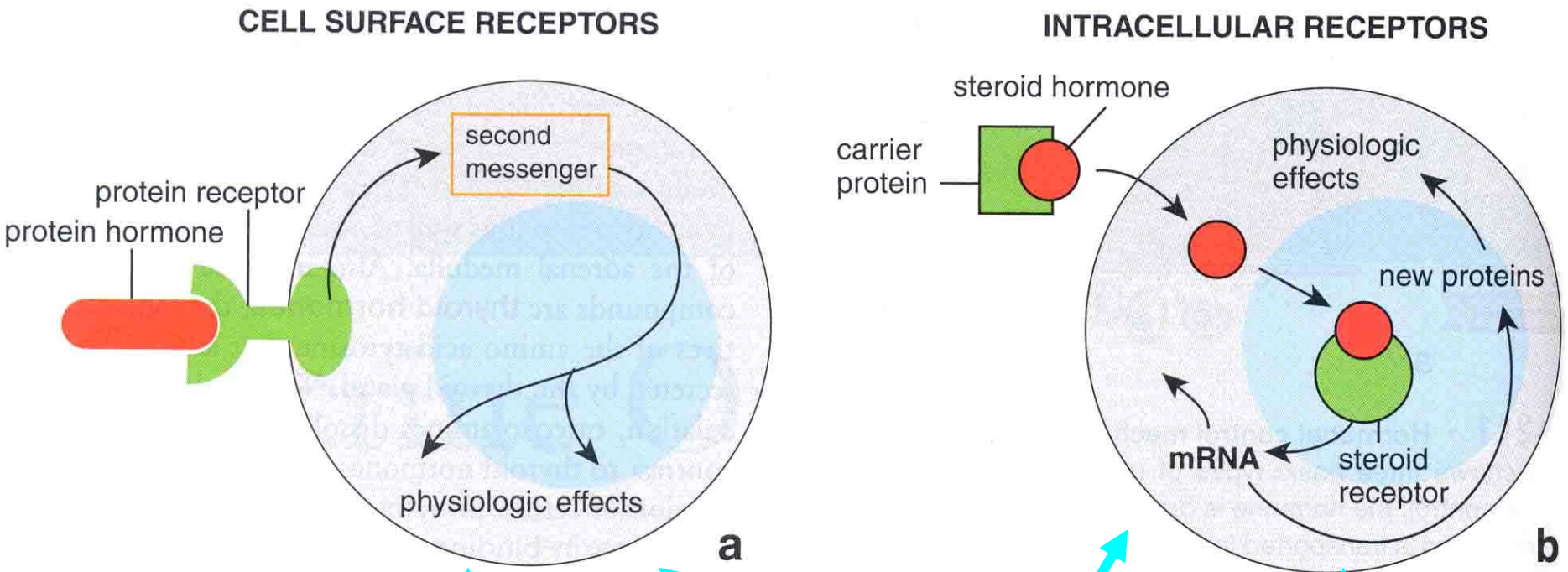

peptides and proteins

biogenic amines

steroids

other small hydrophobic molecules

Ways of secretion

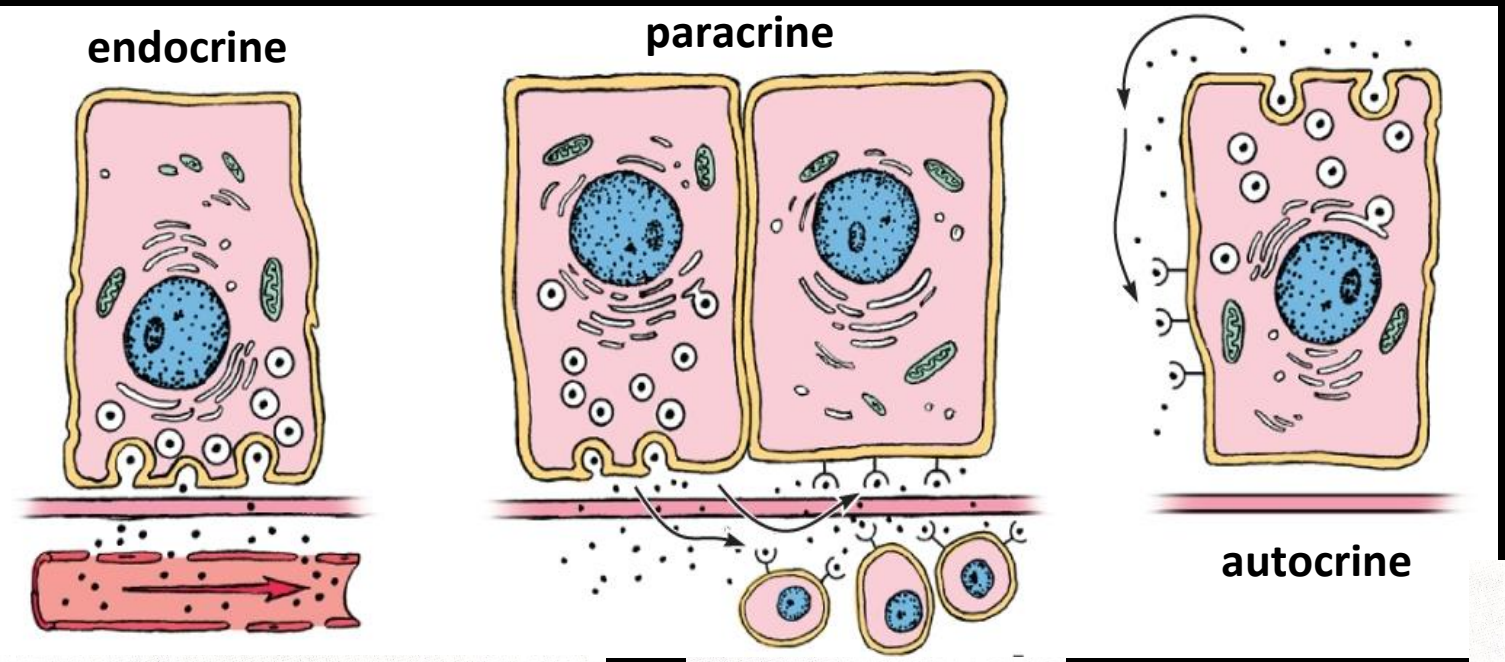

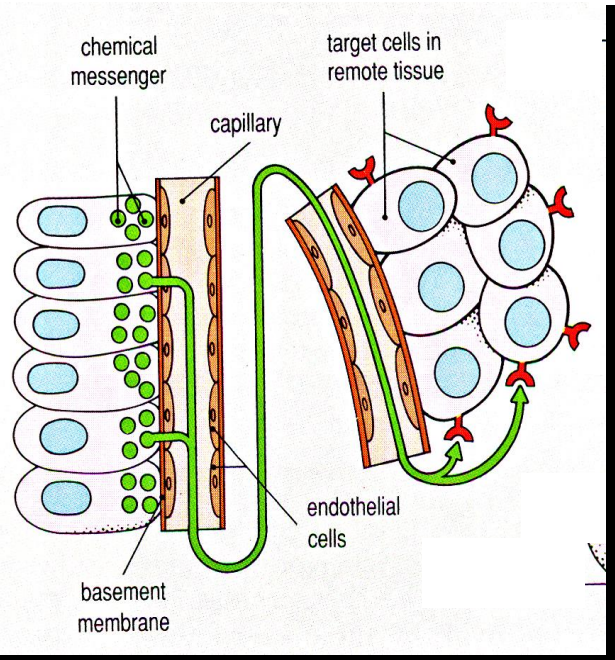

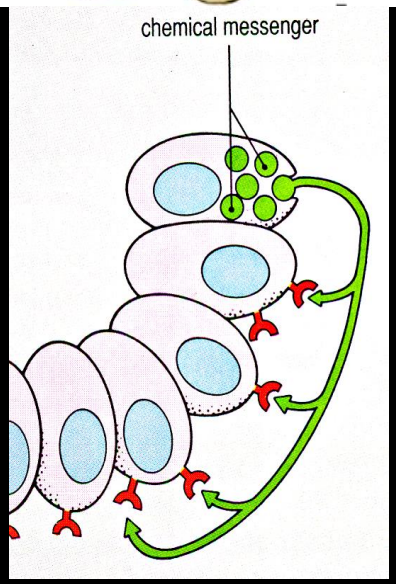

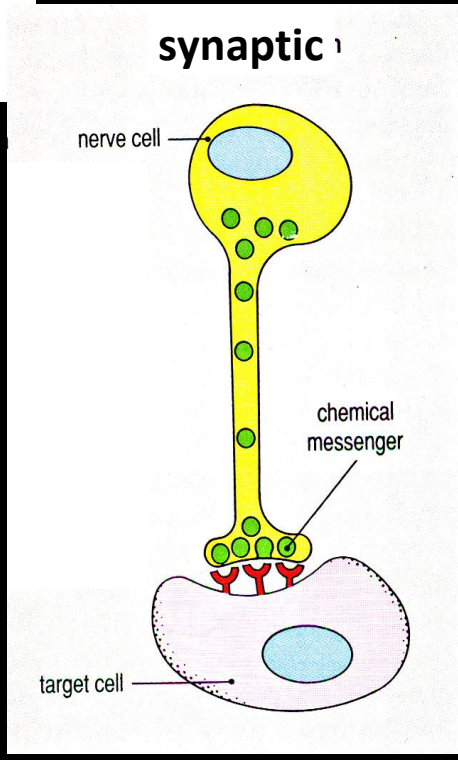

Endocrine glands

- pituitary gland (adenohypophysis + neurohypophysis)
- pineal gland (corpus pineale, epiphysis)
- thyroid gland
- parathyroid glands
- adrenal glands (cortex and medulla)
- Langerhans' islets of pancreas
- endocrine cells in heart, kidneys, gonads, placenta
- cells of DNES - difuse endocrine system (epithelium of digestive and respiratory tracts)
- endothelial cells, hepatocytes

General schema

- stroma – reticular connective tissue
- parenchyme
  - trabecular epithelium (adenohypophysis, parathyroid glands, adrenal glands, Langerhans' islets)
  - epithelium arranged in follicles (thyroid gland)
  - specialized nerve tissue (neurohypophysis, pineal gland)

Pituitary gland

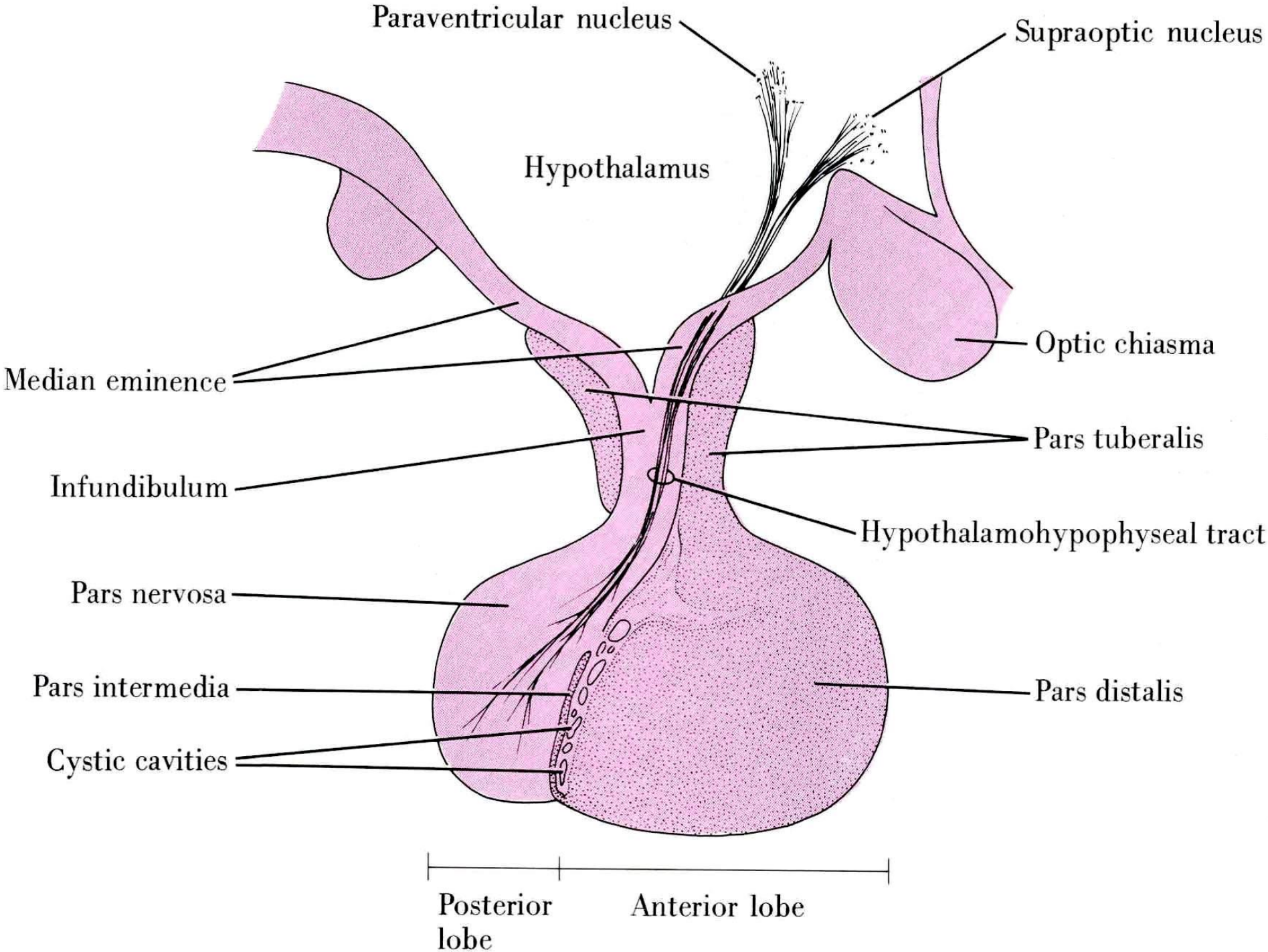
Paraventricular nucleus
Supraoptic nucleus
Hypothalamus
Optic chiasma
Median eminence
Pars tuberalis
Infundibulum
Hypothalamohypophyseal tract
Pars nervosa
Pars intermedia
Pars distalis
Cystic cavities
Posterior lobe
Anterior lobe

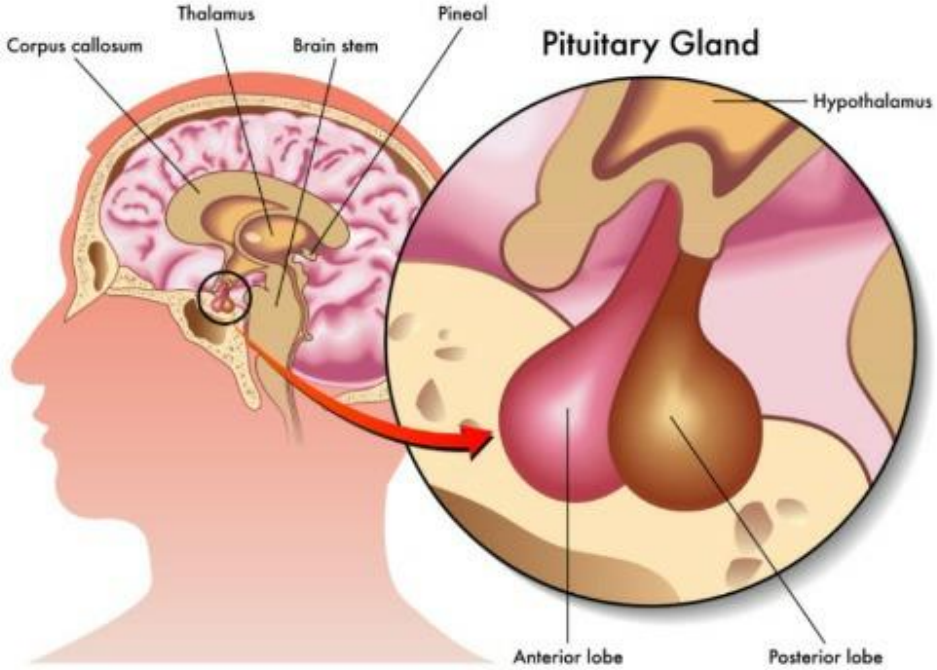
Thalamus
Pineal
Corpus callosum
Brain stem
Pituitary Gland
Hypothalamus
Anterior lobe
Posterior lobe


PITUITARY GLAND
BRAIN NUTS
imgflip.com

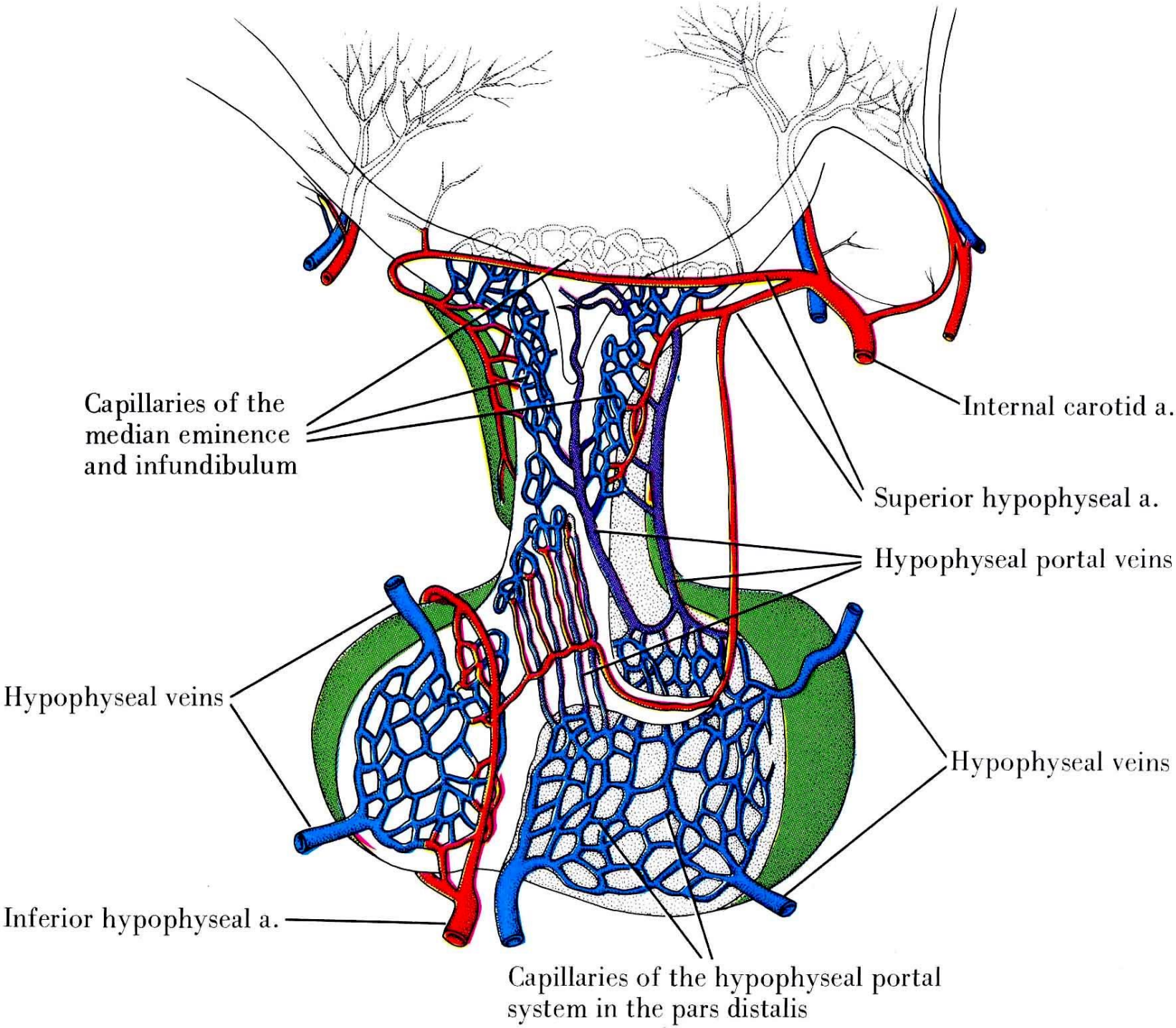
Capillaries of the median eminence and infundibulum
Internal carotid a.
Superior hypophyseal a.
Hypophyseal portal veins
Hypophyseal veins
Hypophyseal veins
Inferior hypophyseal a.
Capillaries of the hypophyseal portal system in the pars distalis

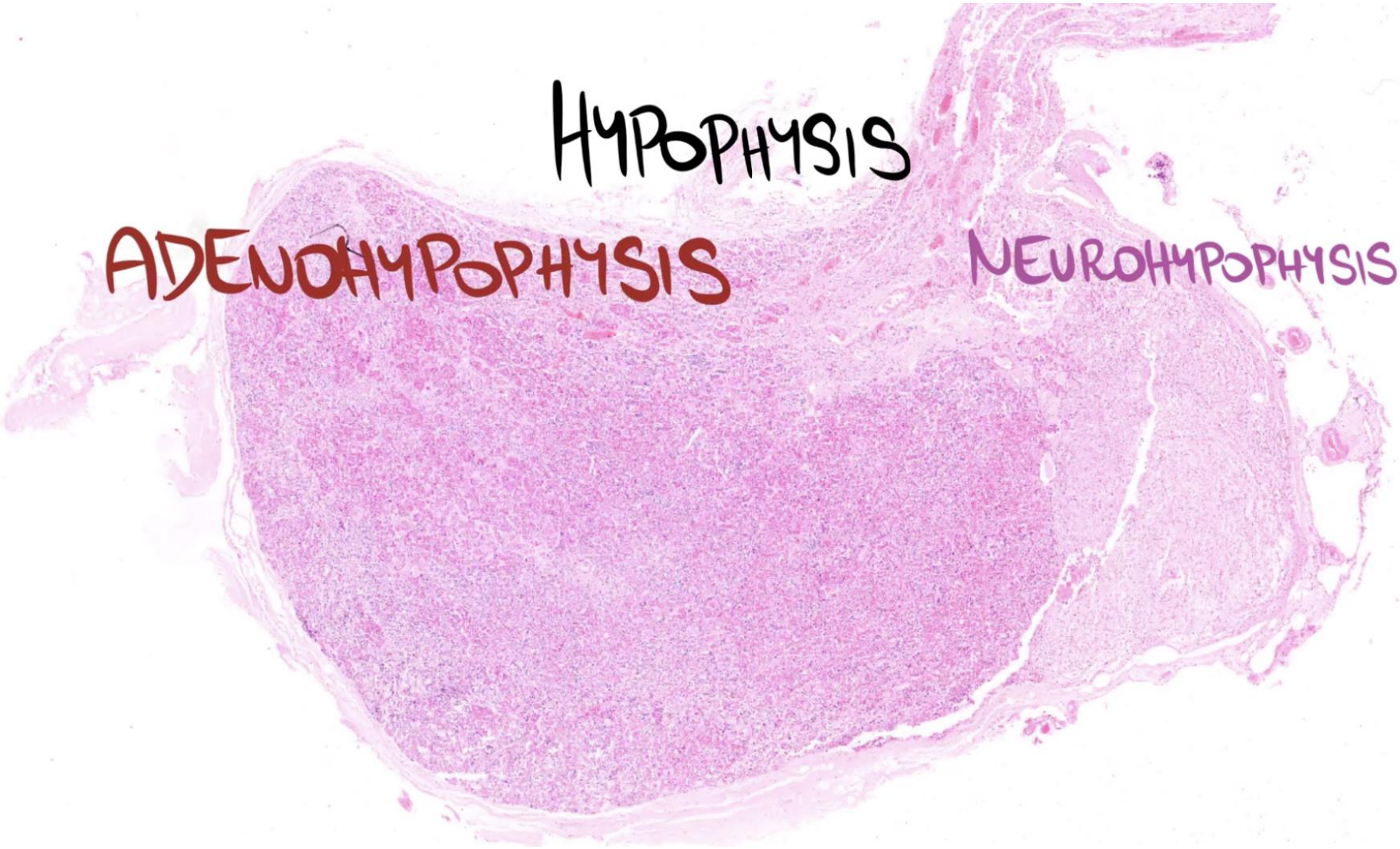
HYPOPHYSIS
ADENOHYPOPHYSIS
NEUROHYPOPHYSIS

ADENOHYPOPHYSIS

↳ 3 PARTS =>

1. PARS DISTALIS
2. PARS TUBERALIS
3. PARS INTERMEDIA

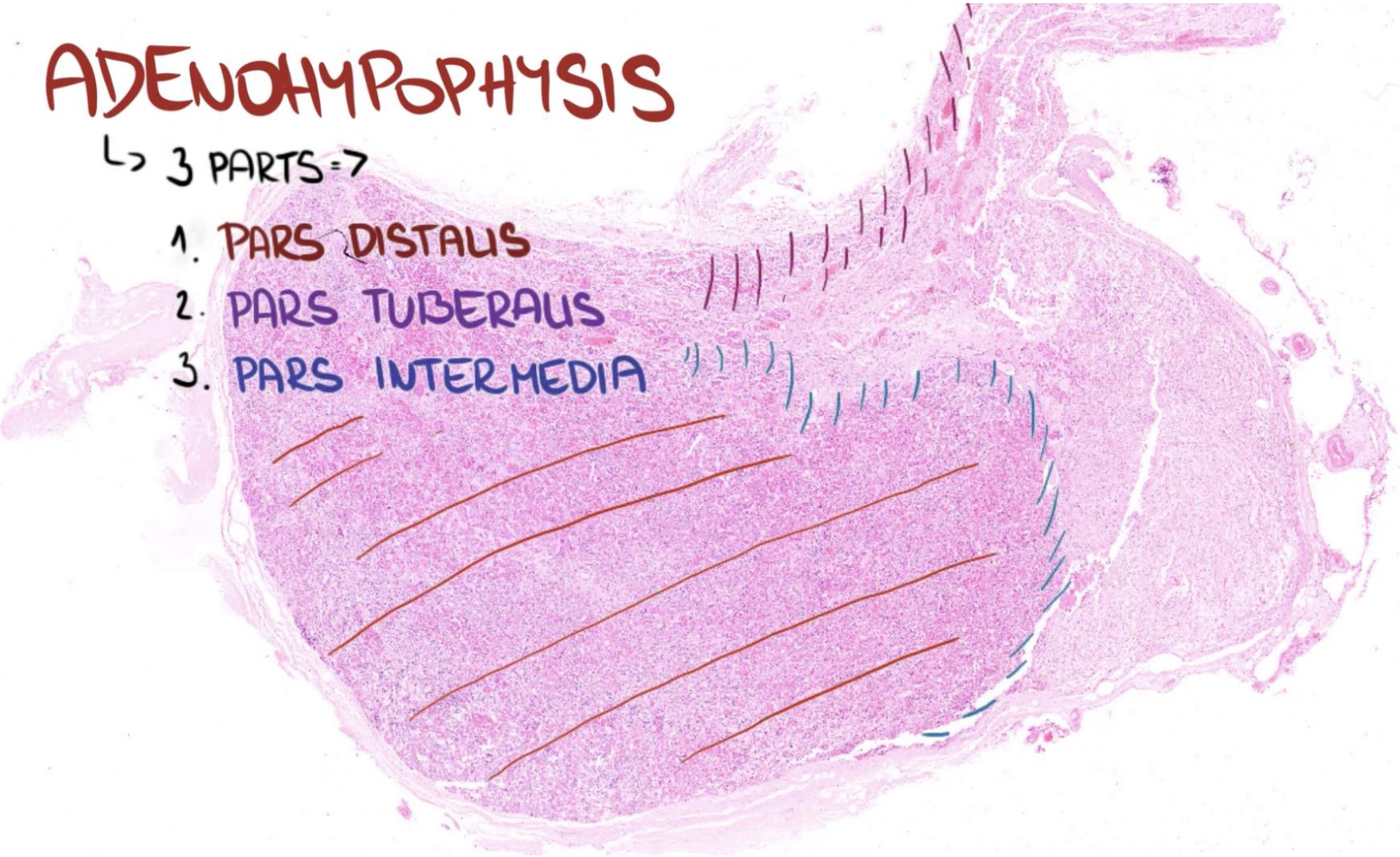

Adenohypophysis – pars distalis

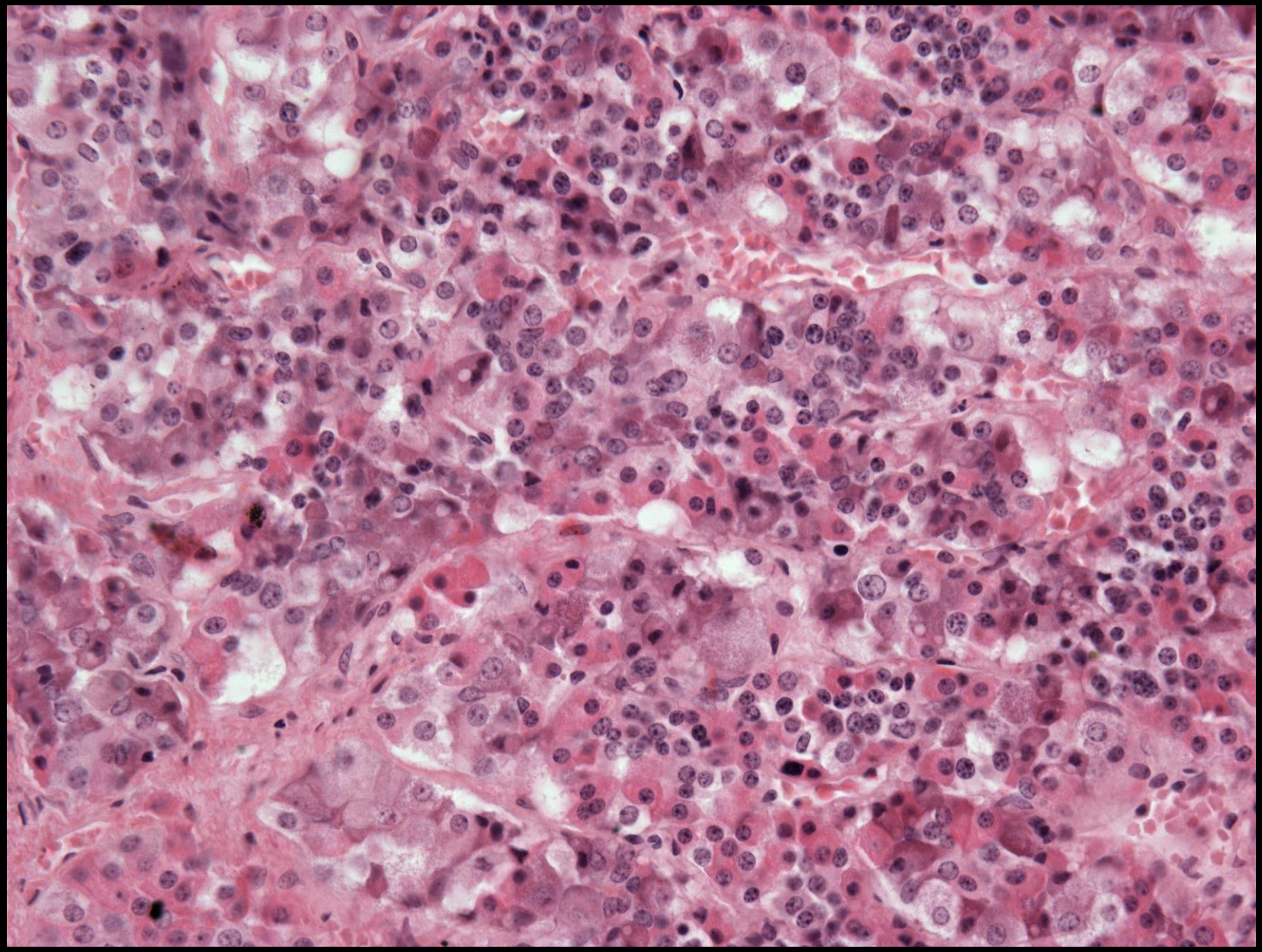

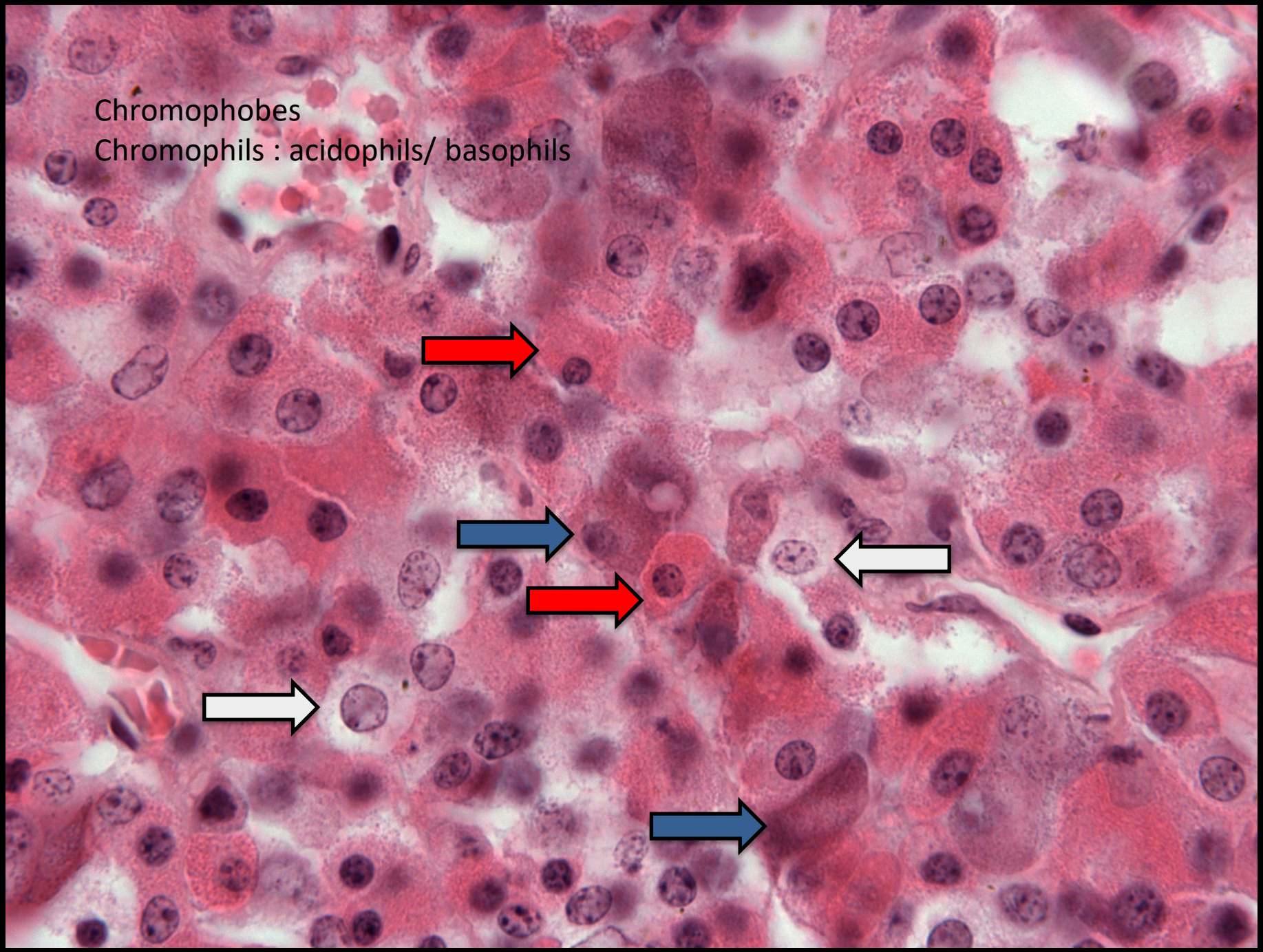
Chromophobes
Chromophils : acidophils/ basophils

THE PITUITARY GLAND HORMONES

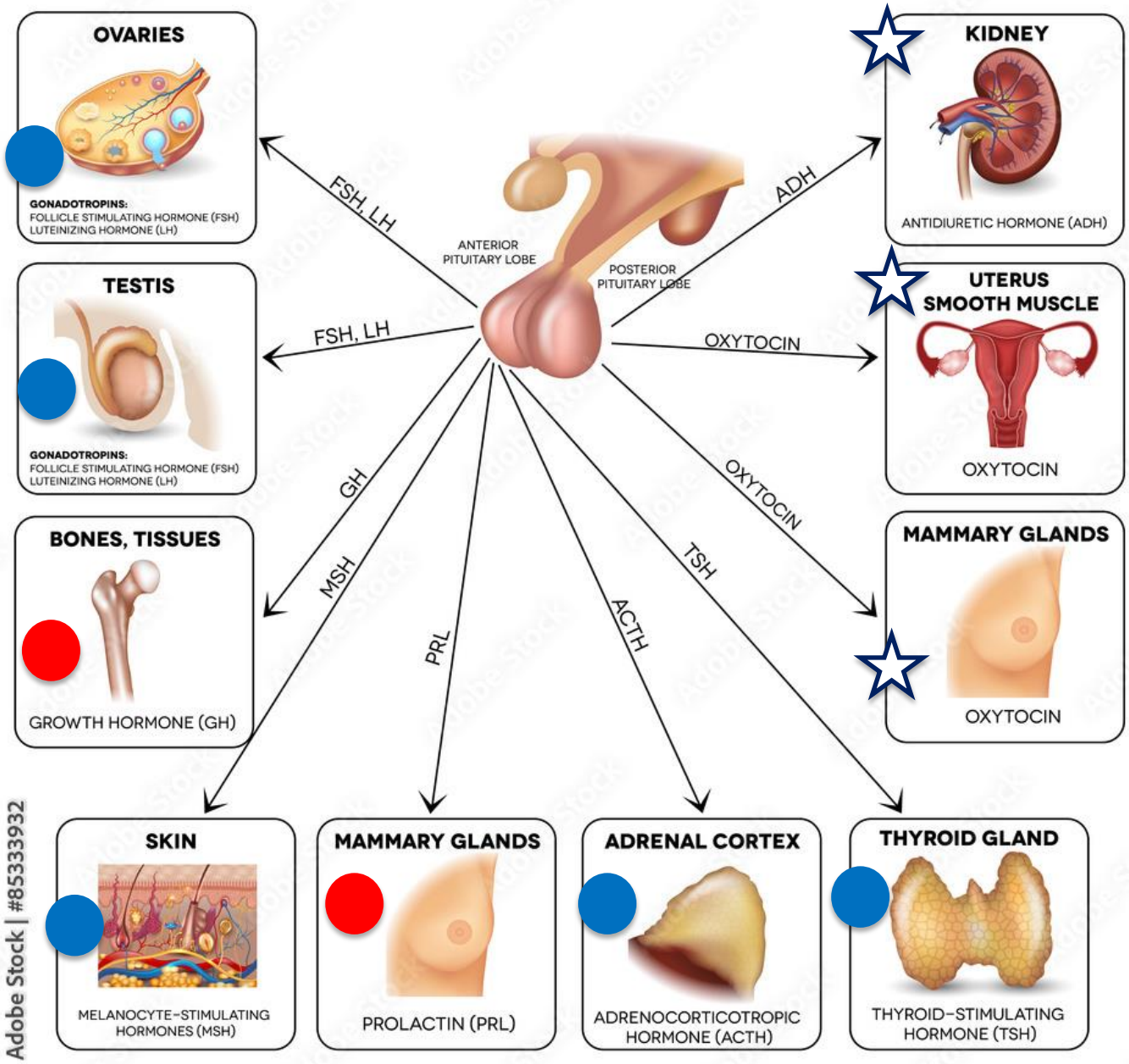

acidophilic cells

STH
GHRH
ghrelin
somatostatin
NFB

PRL (LTH)
PRH
TRH
GnRH
estrogens
breast feed
dopamin

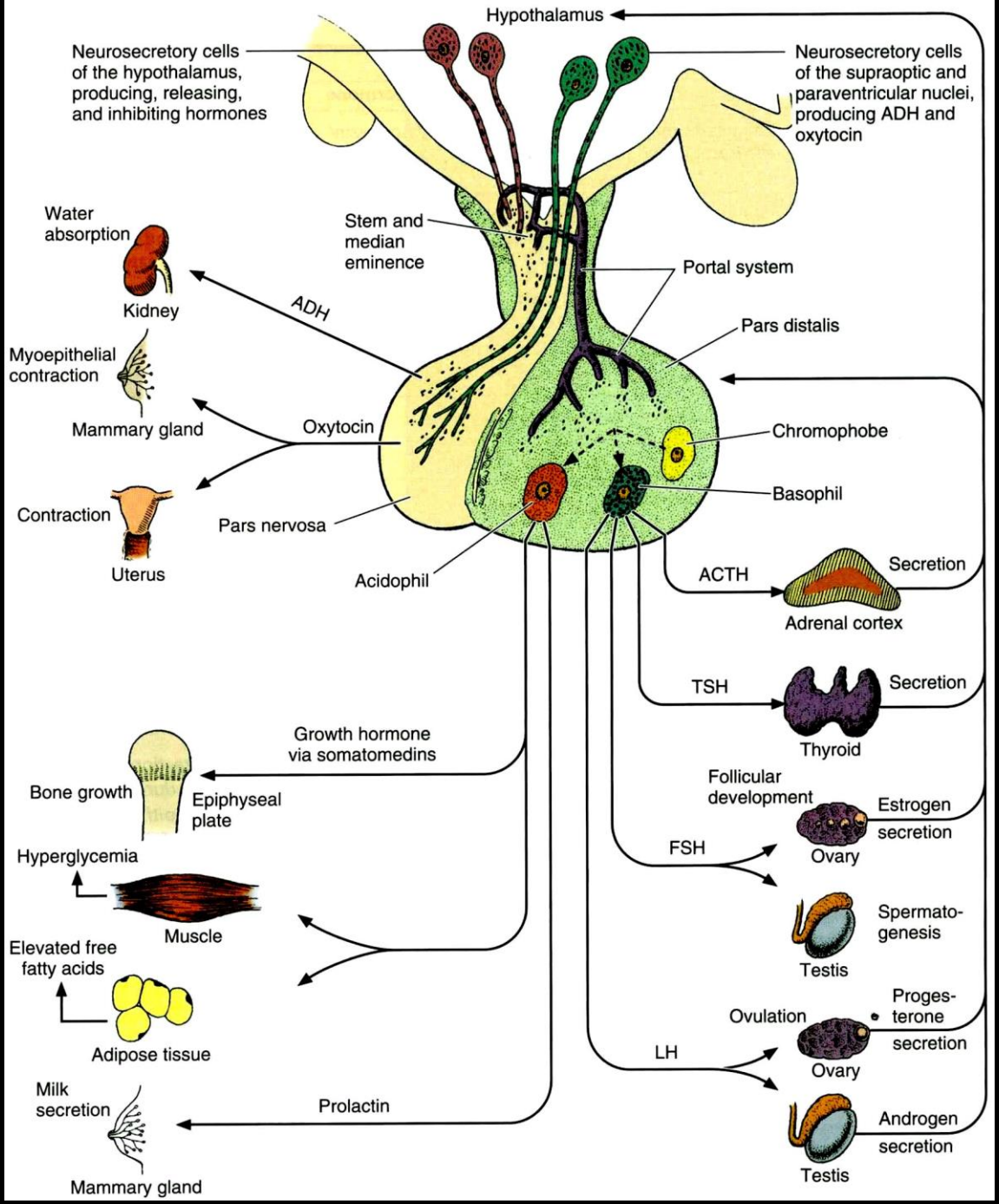

basophilic cells

TTH
TRH
NFB

FSH / LH
GnRH
FSH-activin
NFB
FSH-inhibin

ACTH
CRH
NFB

MSH

hormone **stimulation** **inhibition** **NFB = negative feedback**

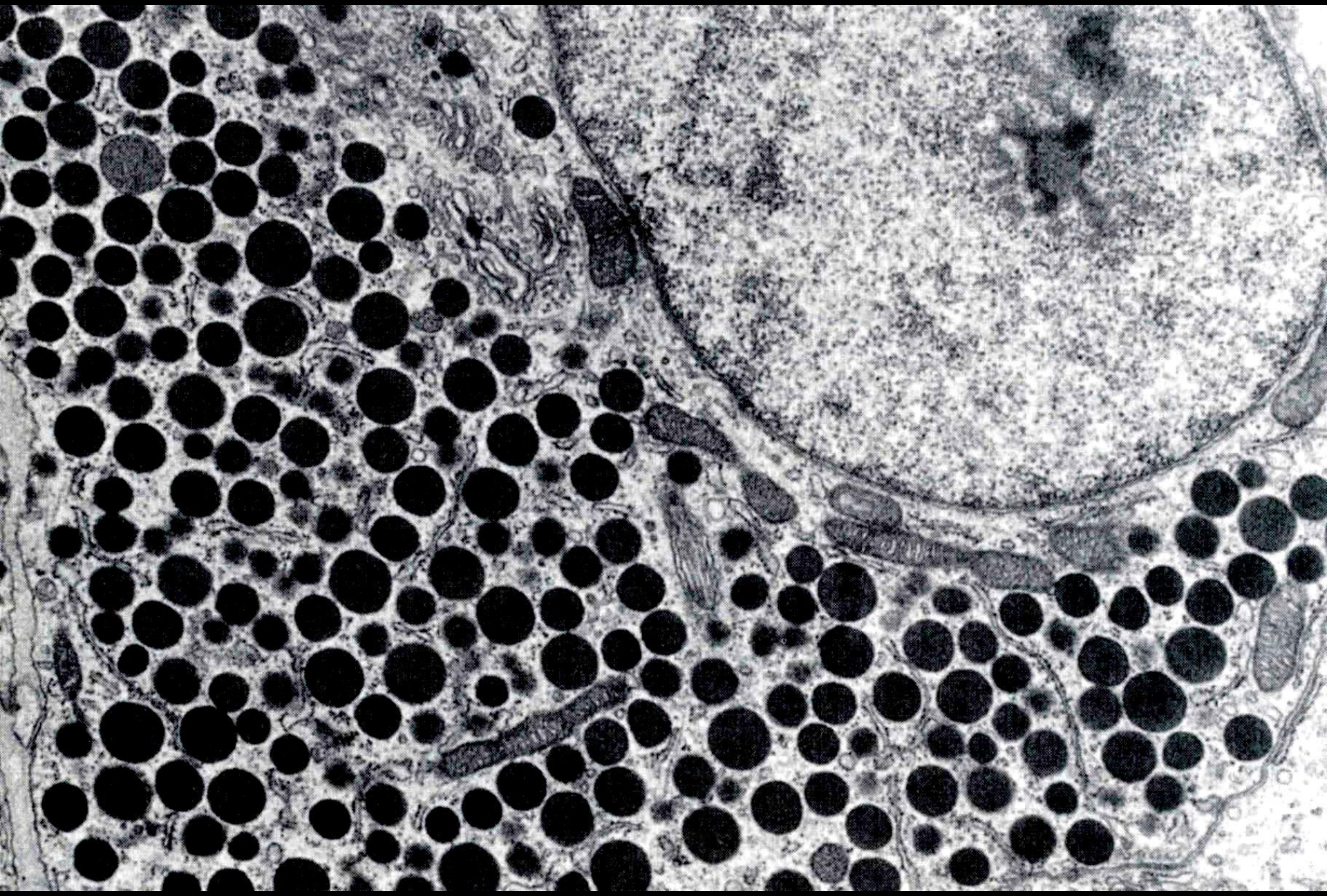

ADENOHYPOPHYSIS

CHROMOPHOBES

↳ HETEROGENOUS GROUP OF CELLS

1. FOLLICULOSTELATE
2. STEM CELLS
3. DEGRANULATED CELLS





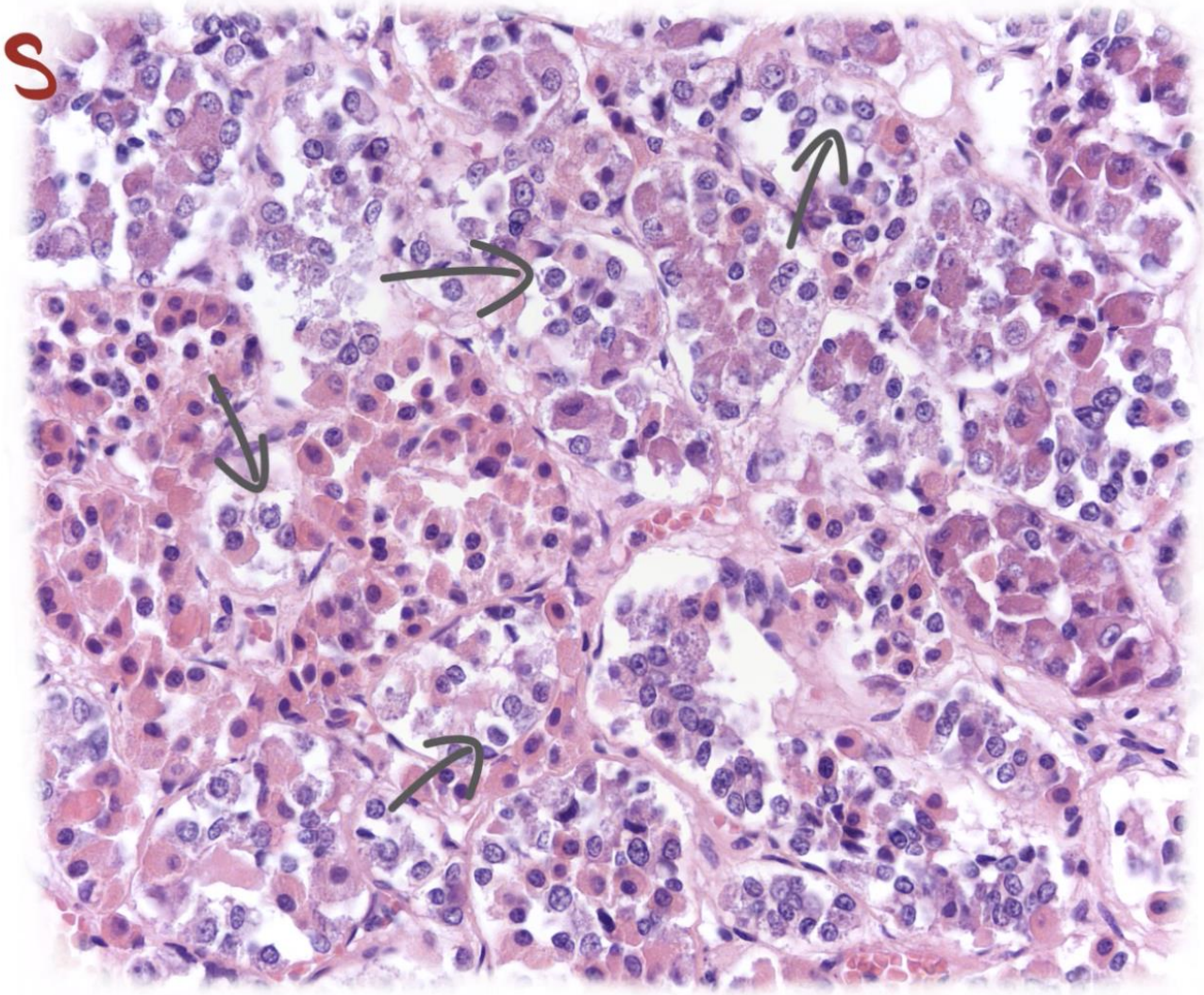

Pars intermedia

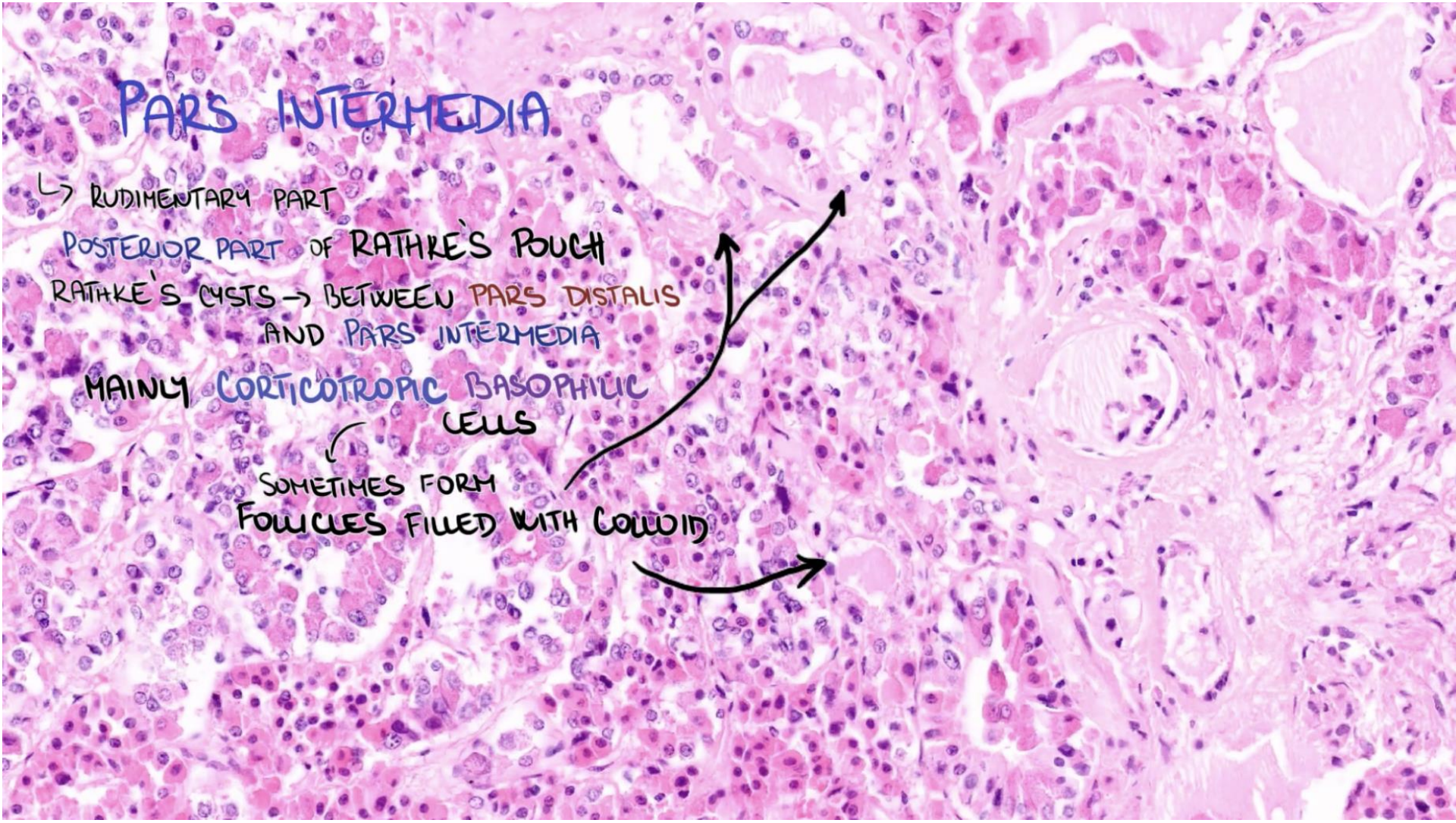

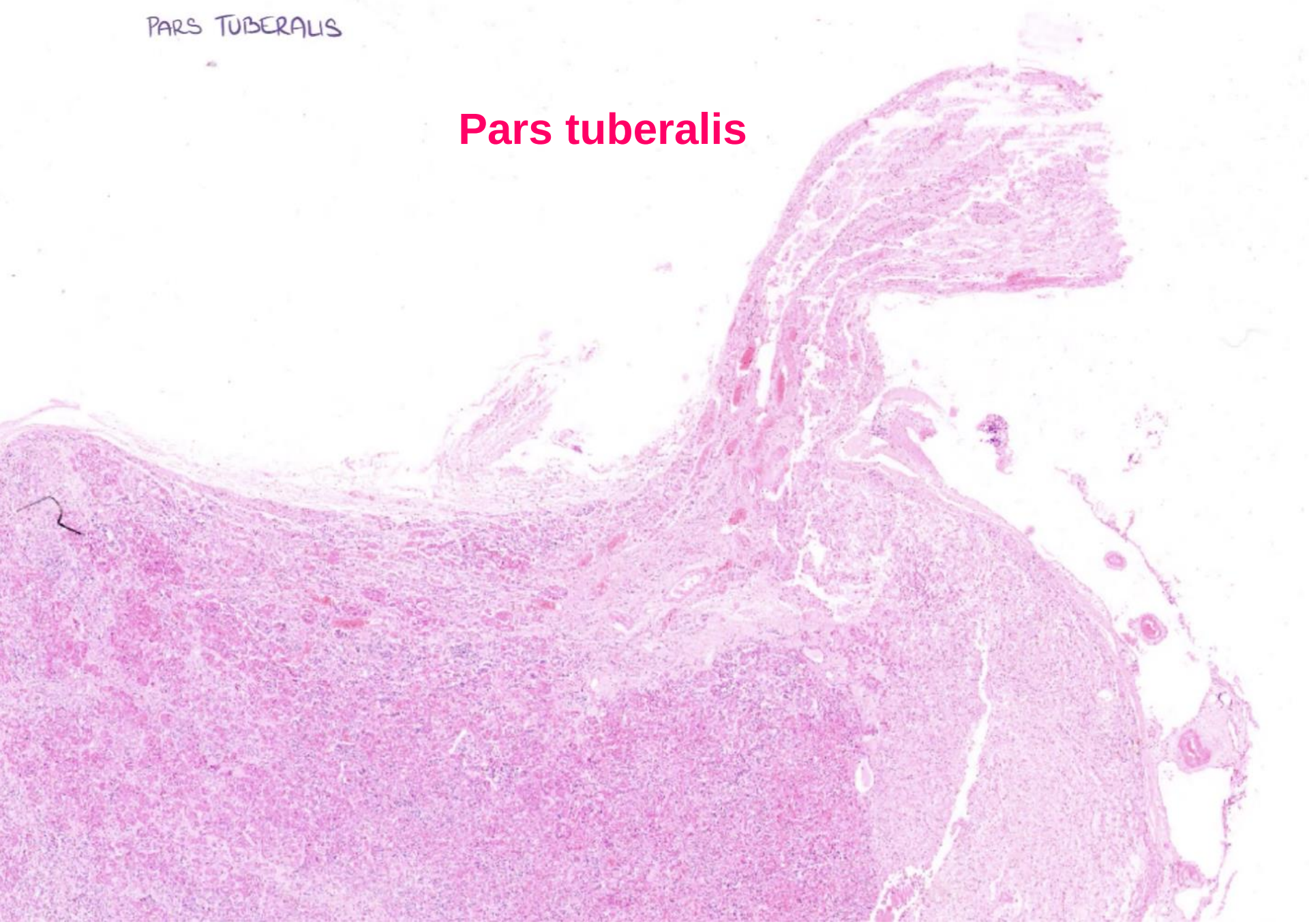

Pars tuberalis

Neurohypofysa

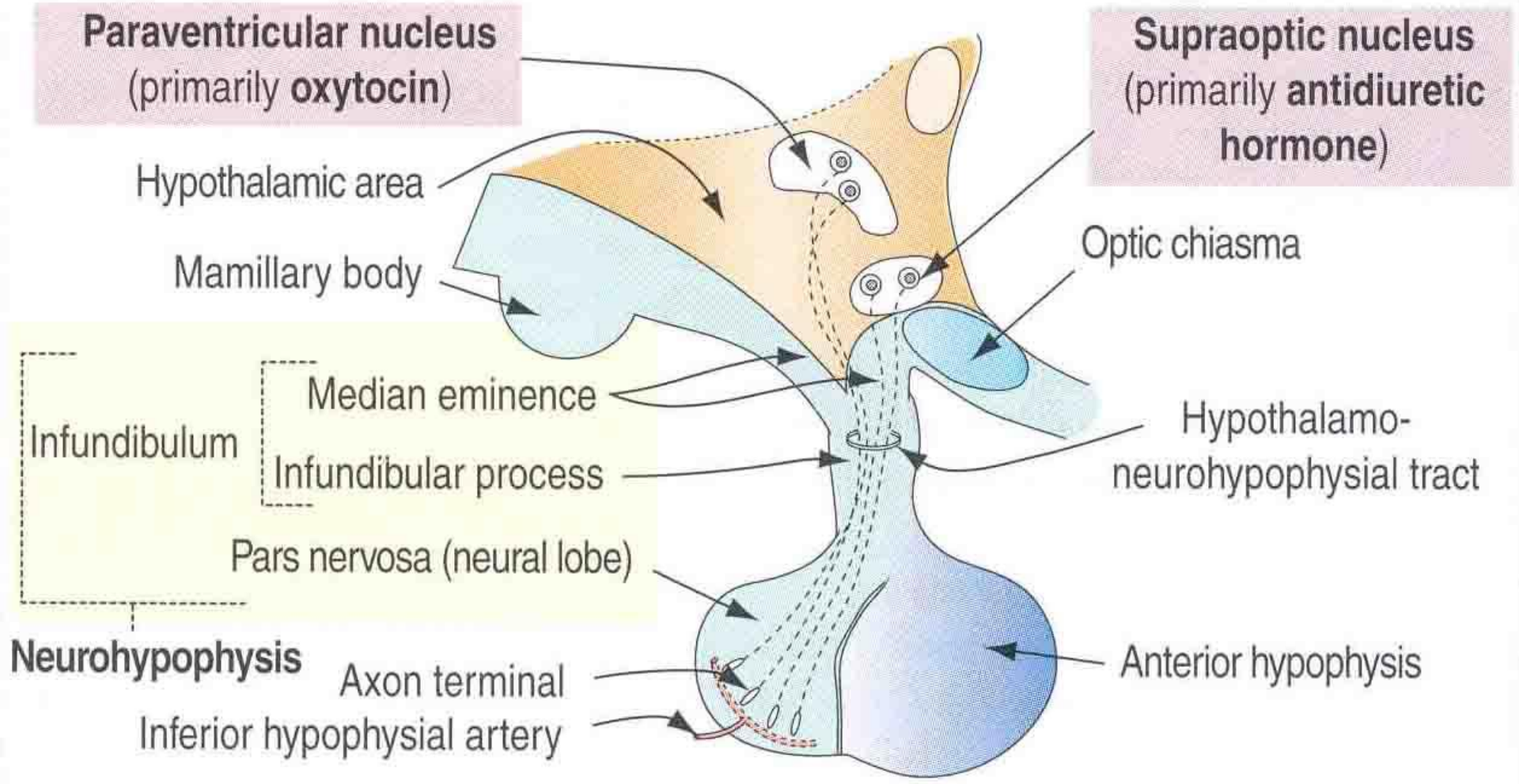

HYPOTHALAMUS

TWO HYPOTHALAMIC NUCLEI

SUPRAOPTIC

↑OSMOLARITY OF THE BLOOD → PRODUCE ADH↓

ALCOHOL :D

↓

COLLECTING DUCTS OF KIDNEYS

→ INCORPORATION OF AQUAPORIN CARRIERS

H_2O

!

↓ OMG! (30L/DAY)

↑URINATION

→ DIABETES INSIPIDUS

PARAVENTRICULAR

↓

OXYTOCIN

↓

STIMULATES MYOEPITHELIAL CELLS

+ UTERUS CONTRACTIONS

NEUROHYPOPHYSIS

→ STORES AND RELEASES 2 HORMONES

ADH
(ANTIDIURETIC HORMONE)
VASOPRESSIN

OXYTOCIN

PRODUCED IN
SECRETORY NEURONS
(LIKE REGULAR NEURONS ☺)
~ CONDUCT IMPULSES ~

MORE DEVELOPED GER
+
FREE POLYRIBOSOMES

:SPECIAL FUNCTION: → HORMONE PRODUCTION!

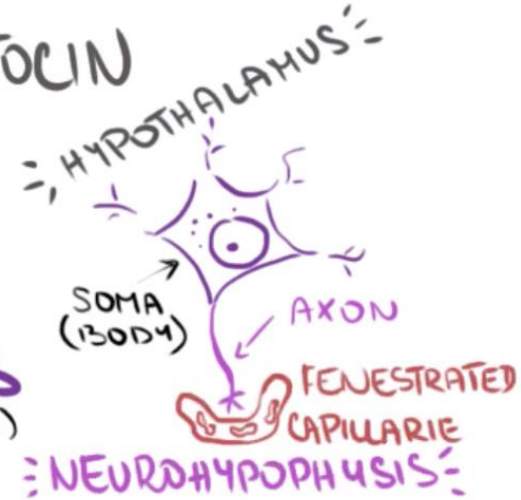

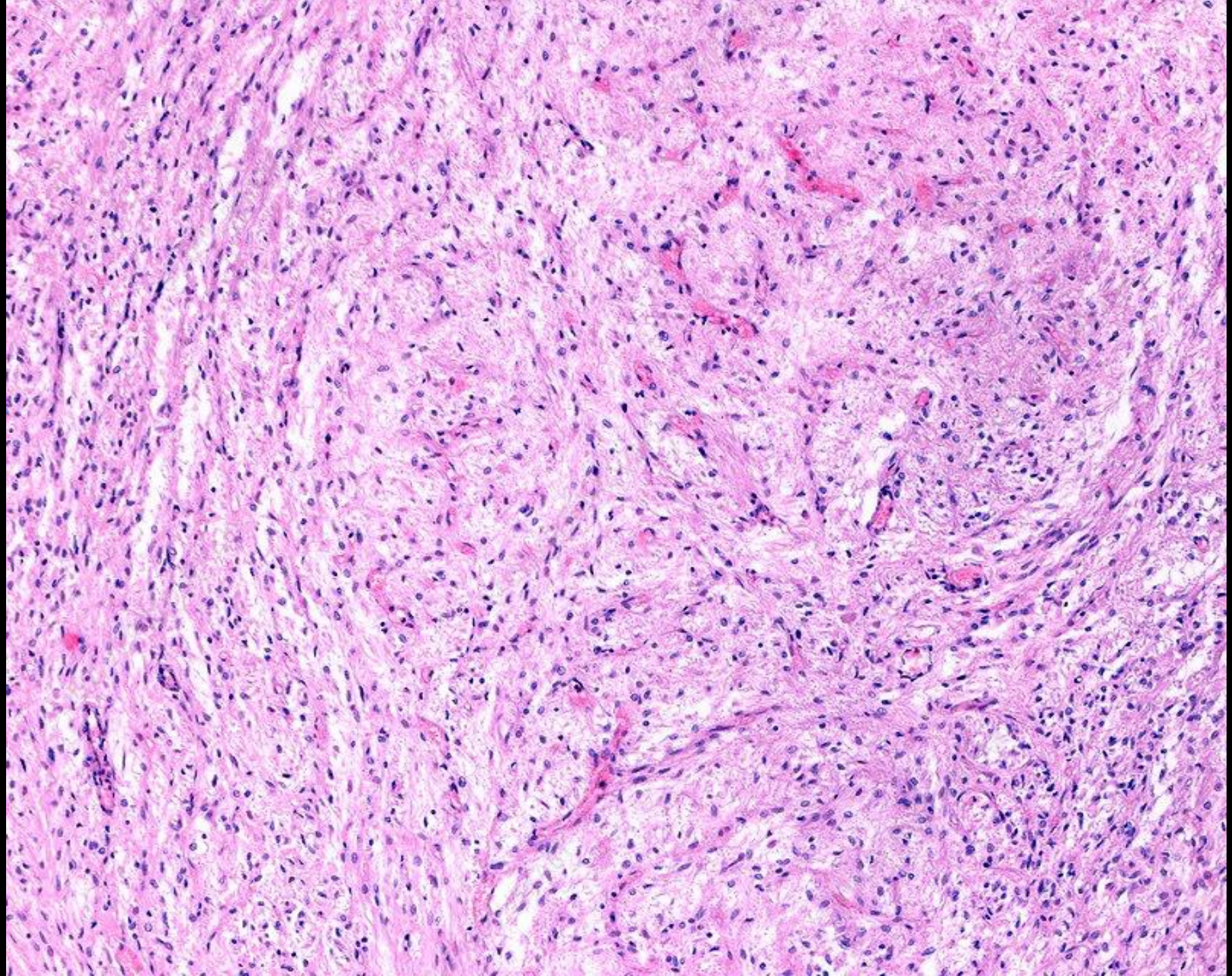

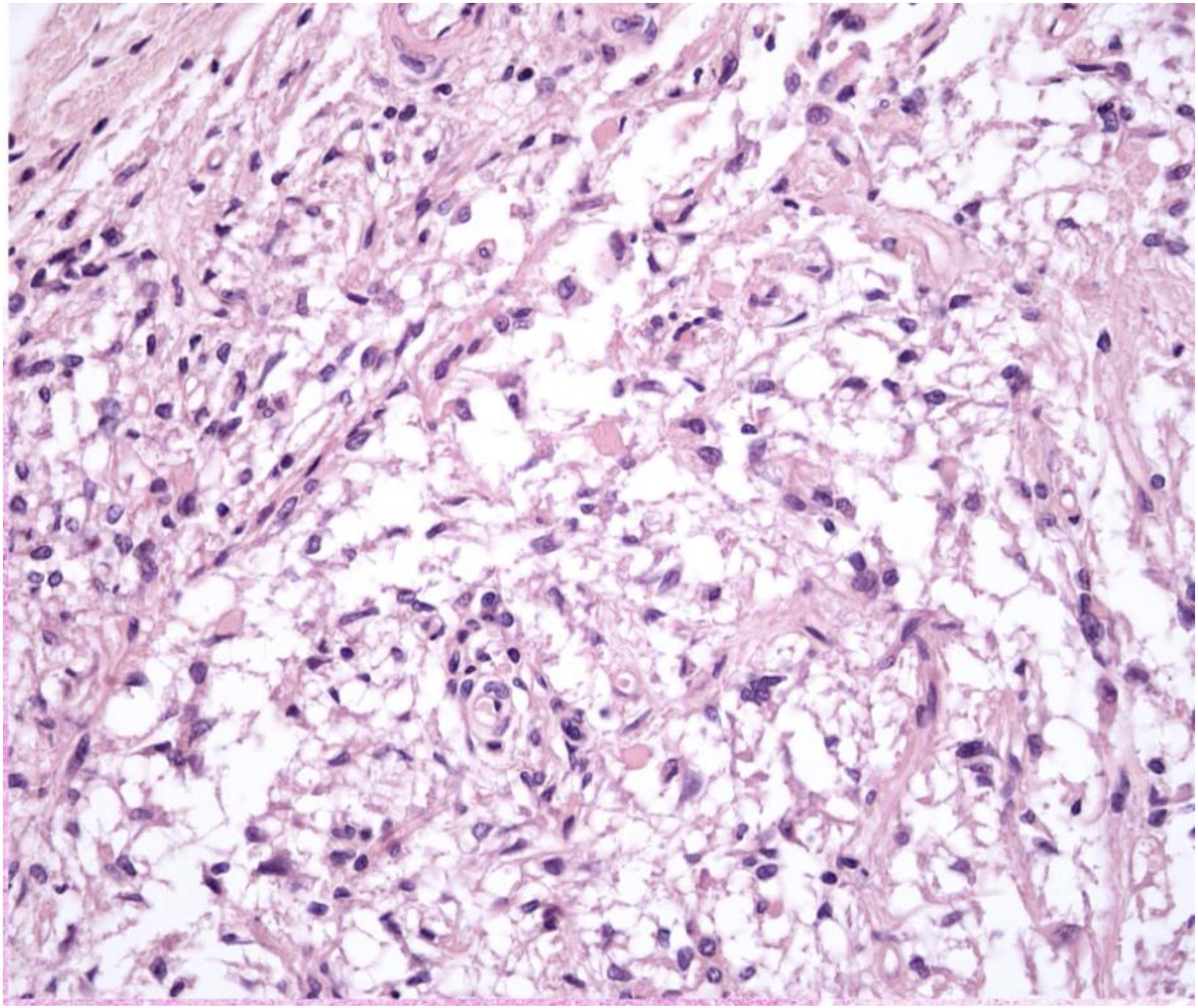

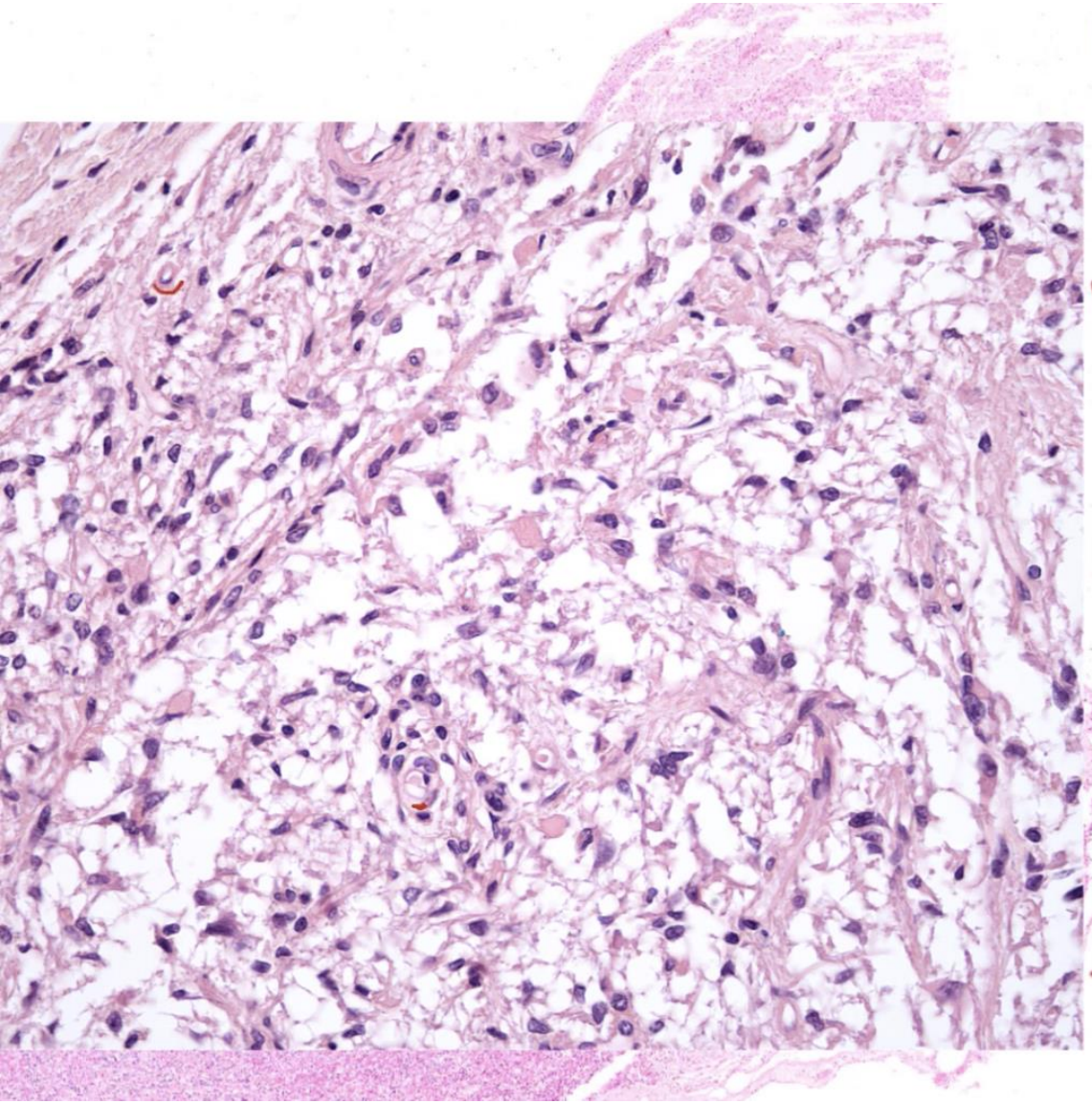

NEUROHYPOPHYSIS

PARS NERVOSA

⇓

! ~~SECRETORY~~ CELLS

COMPOSED OF:

NEURAL TISSUE
(UNMYELINATED AXONS)

+

SPECIAL GLIAL CELLS

PITUICYTES

+ FENESTRATED CAPILLARIES

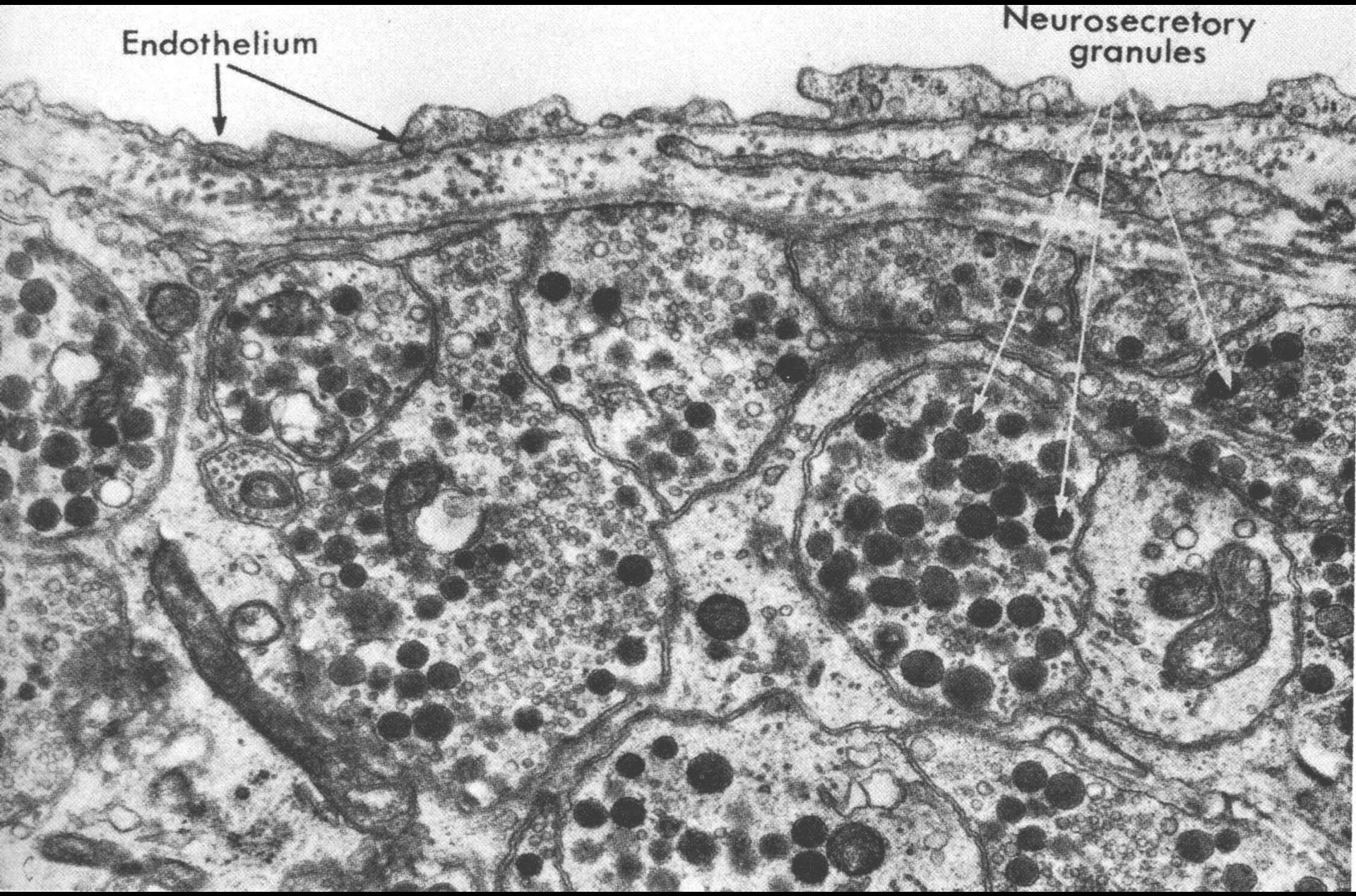
Endothelium
Neurosecretory granules

Development of pituitary gland

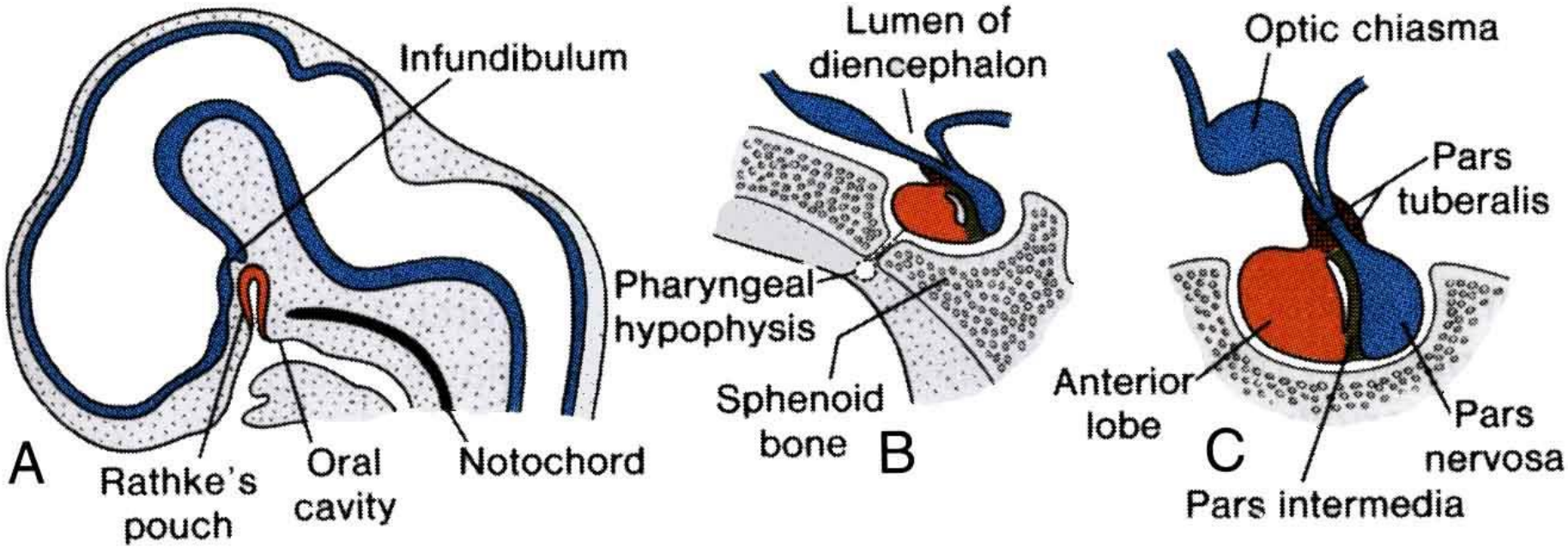

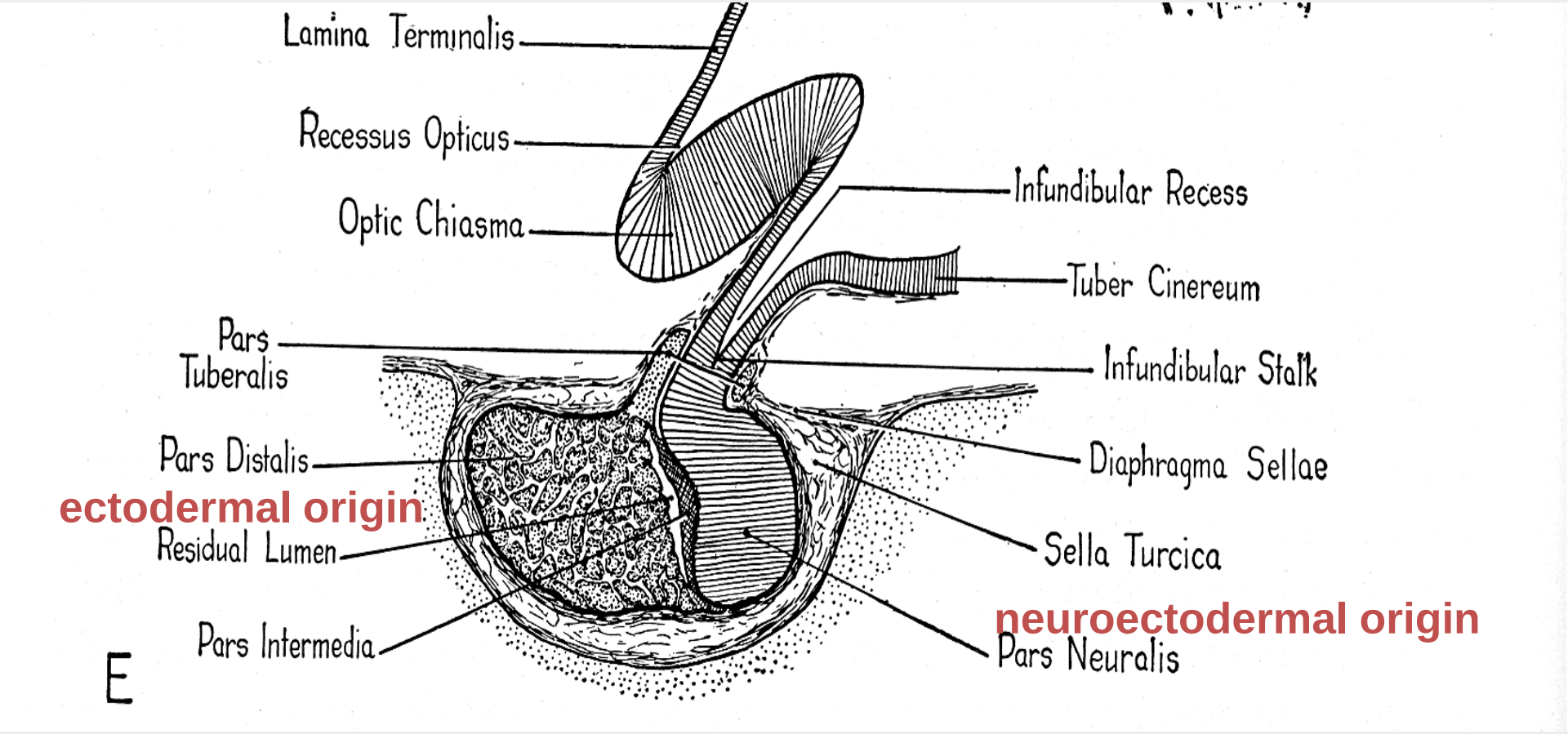
Lamina Terminalis
Recessus Opticus
Optic Chiasma
Infundibular Recess
Tuber Cinereum
Pars Tuberalis
Infundibular Stalk
Pars Distalis
Diaphragma Sellae
ectodermal origin
Residual Lumen
Sella Turcica
neuroectodermal origin
Pars Intermedia
Pars Neuralis
E

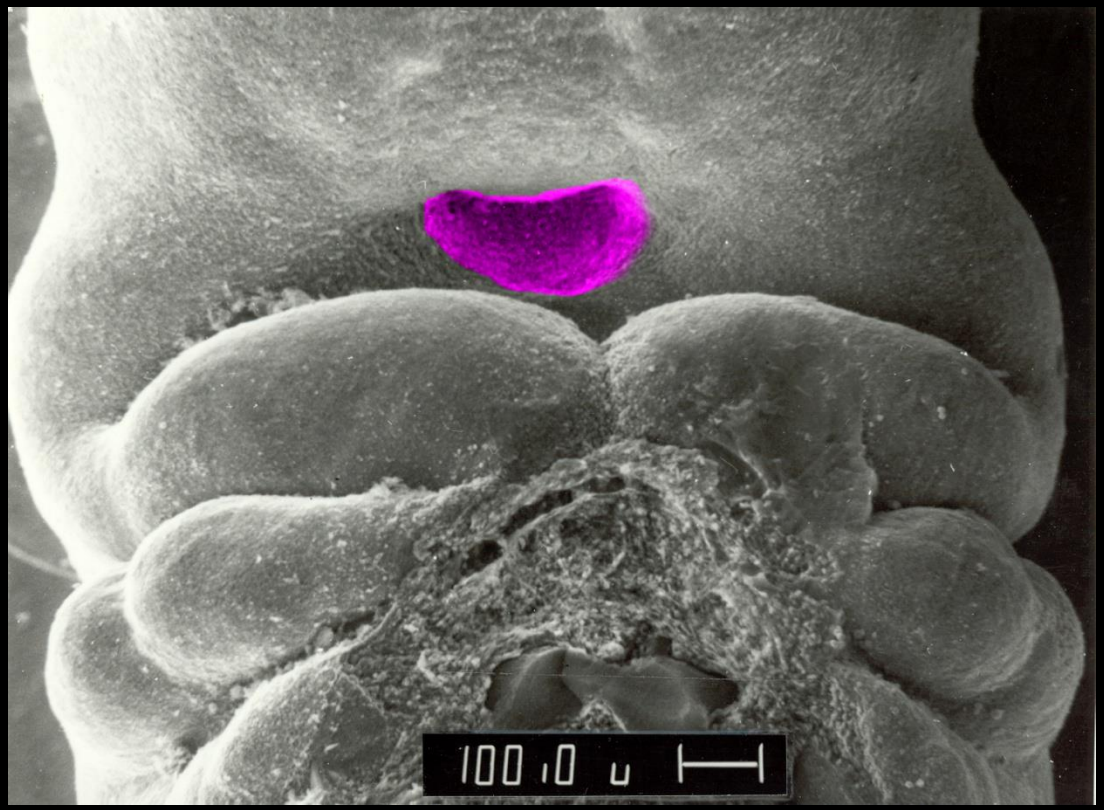
100.0 u

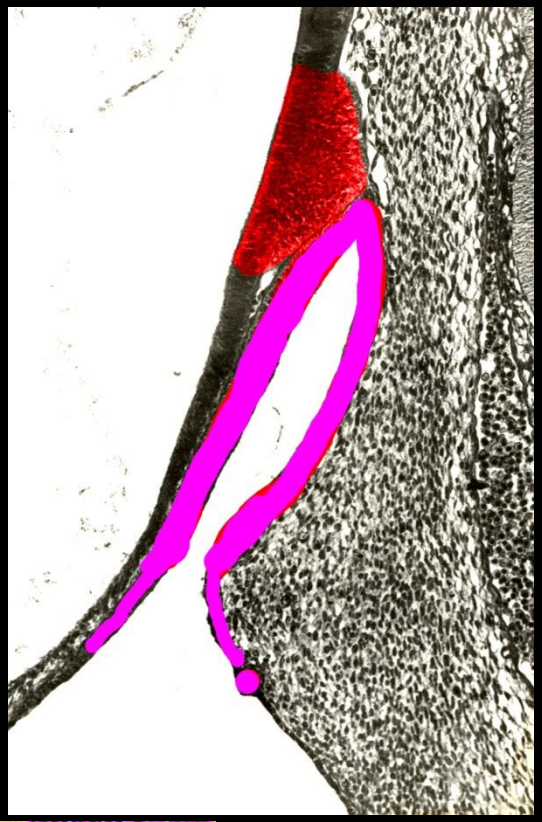

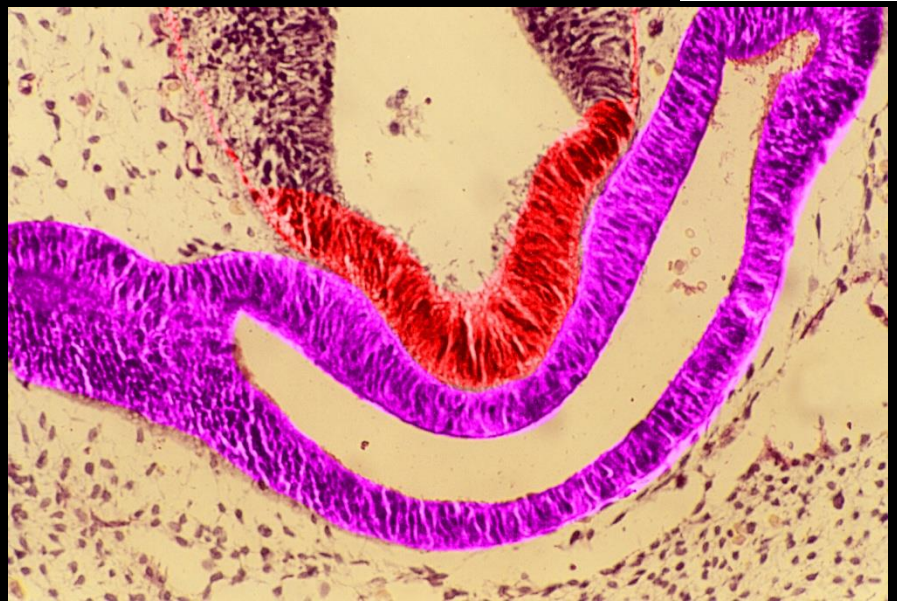

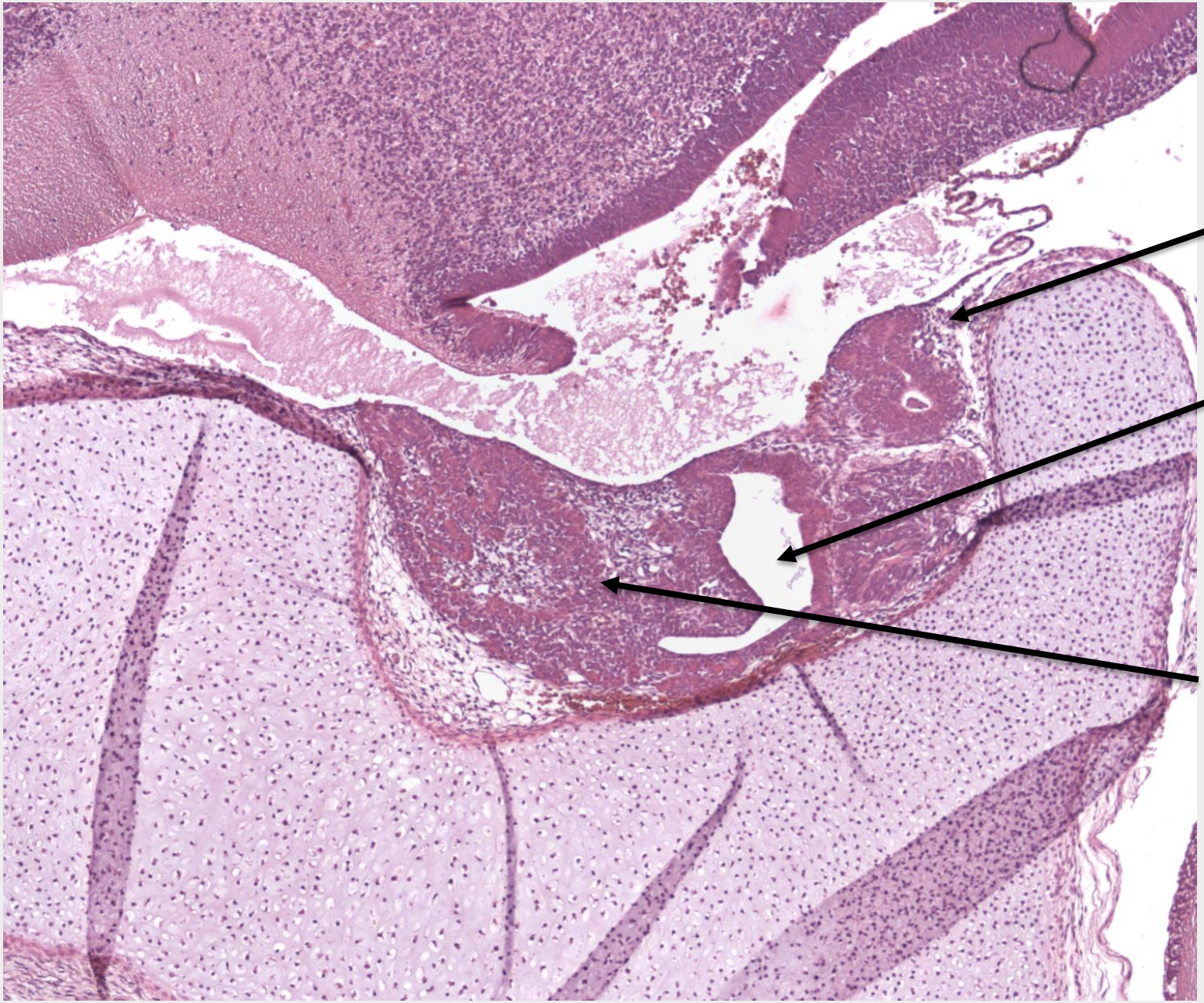
Neurohypophysis
Rathke´s pouch - lumen
Adenohypophysis

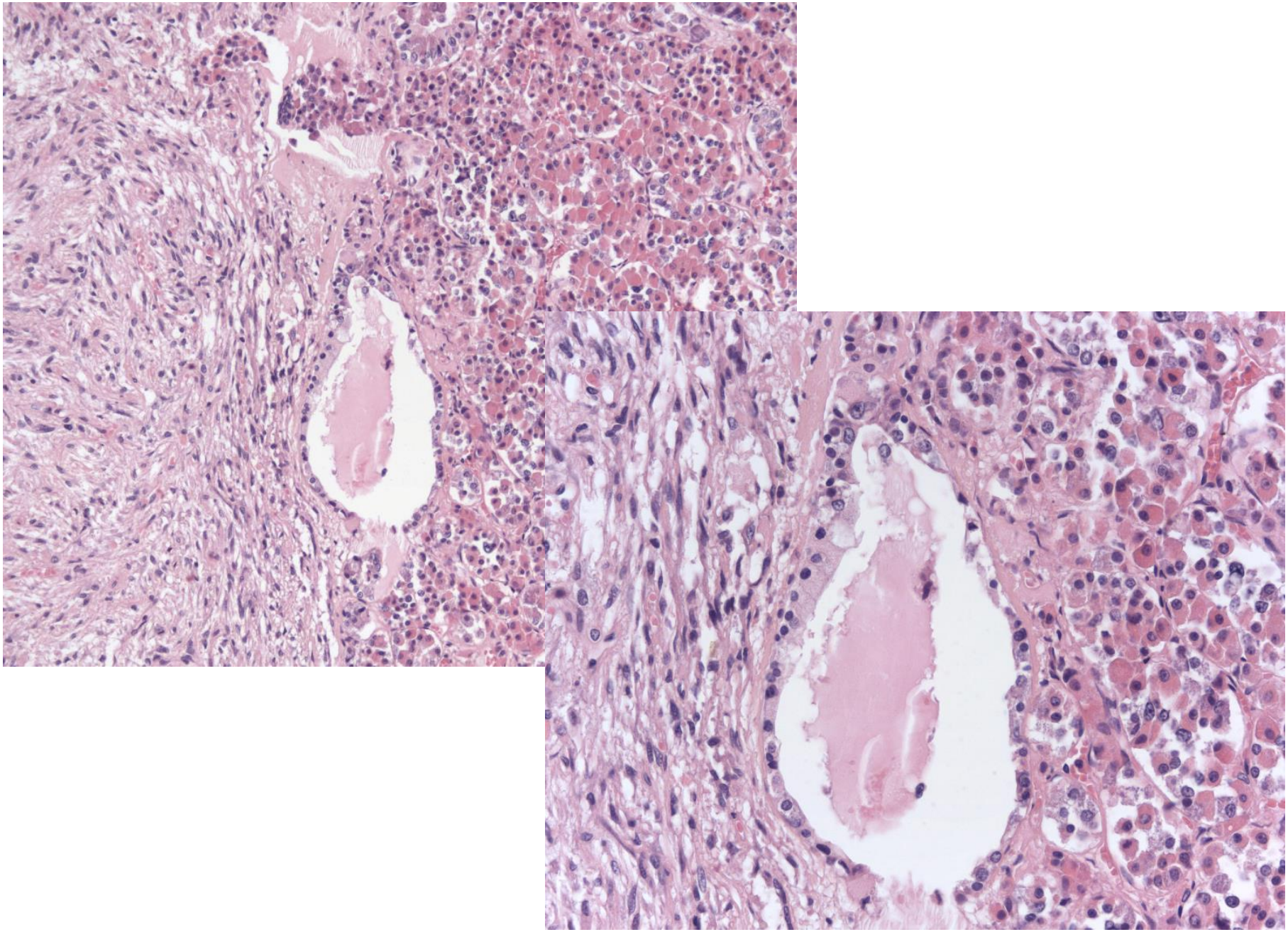

Pineal gland (corpus pineale, epiphysis)

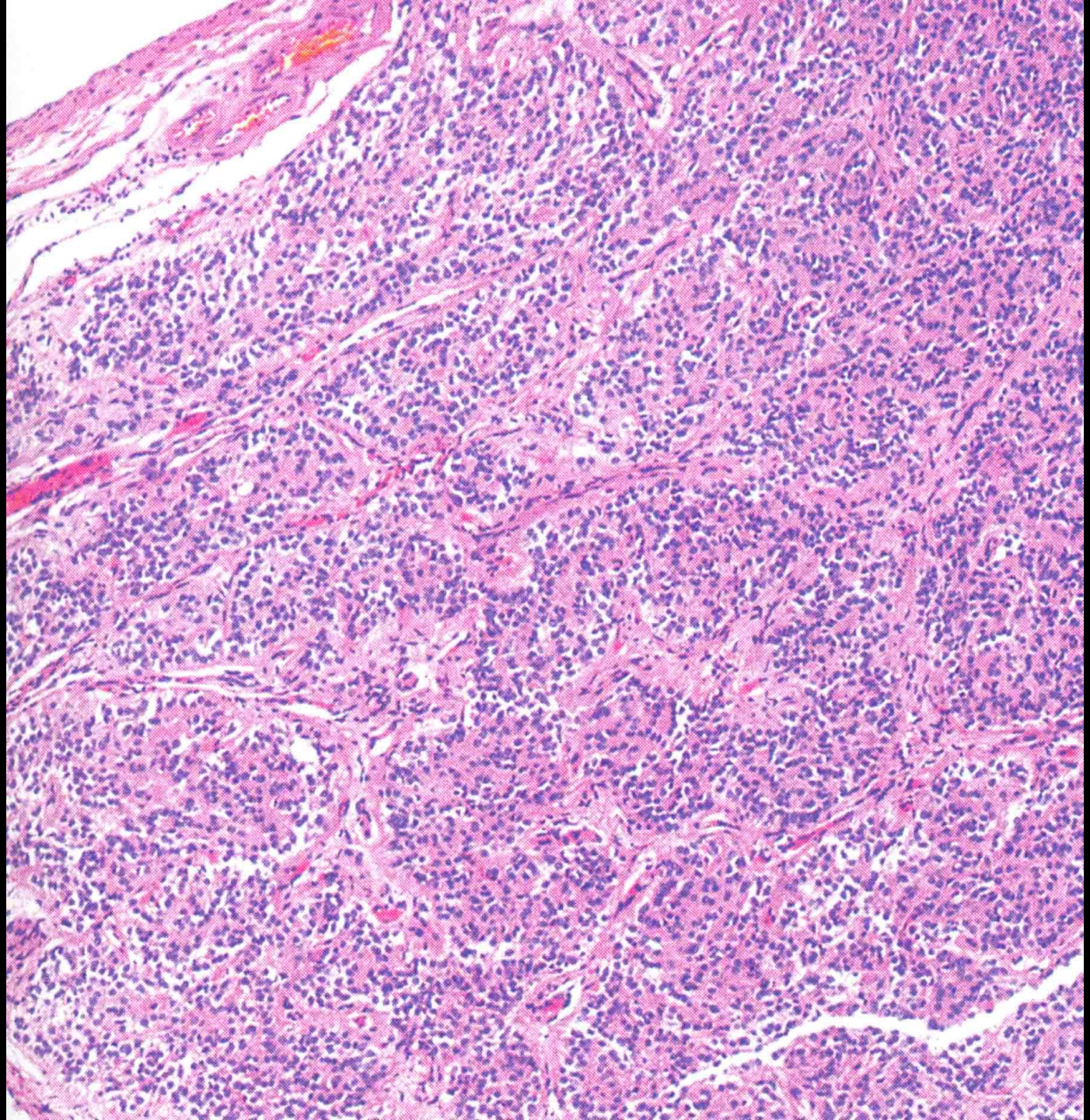

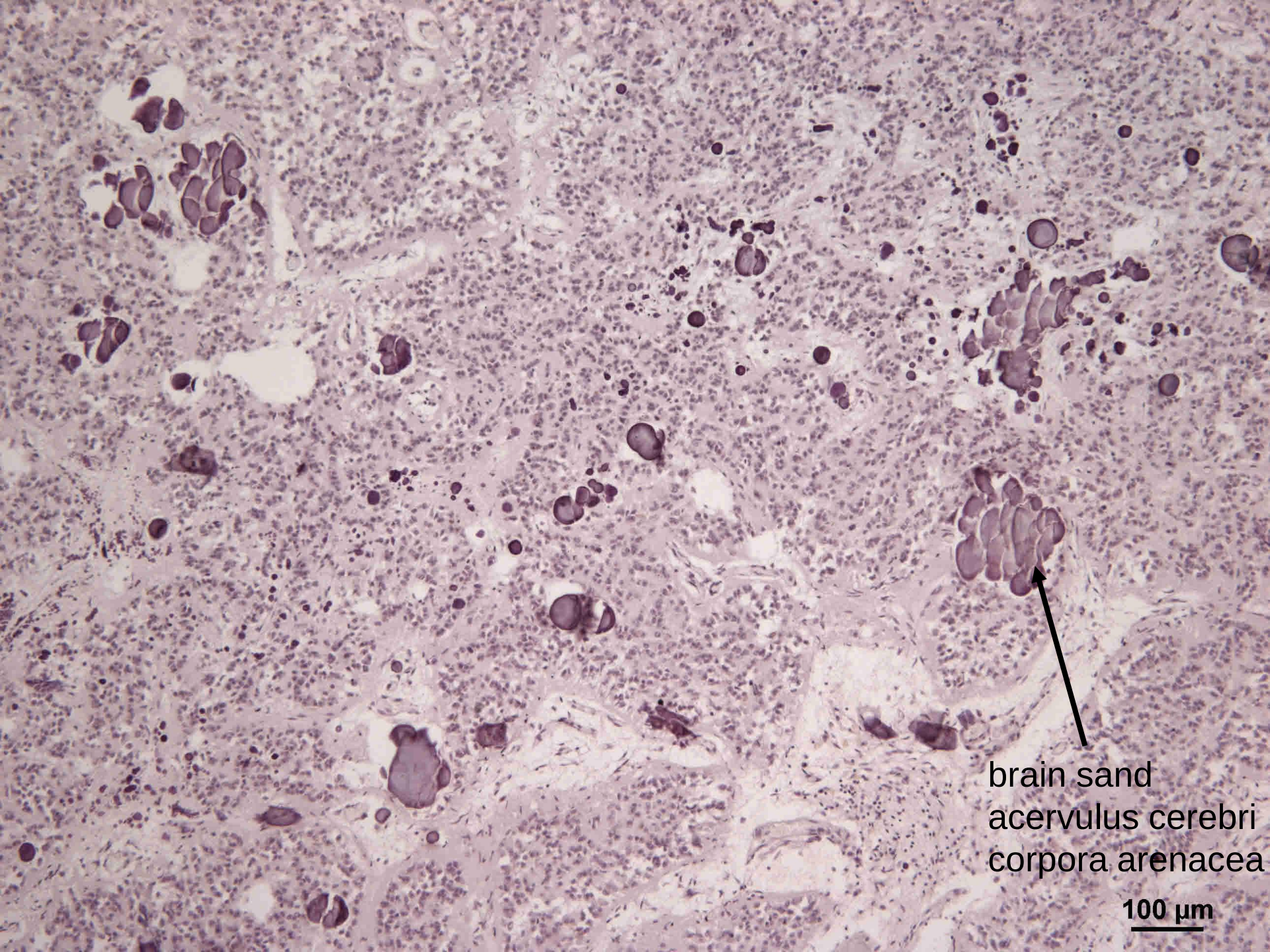
brain sand
acervulus cerebri
corpora arenacea
100 µm

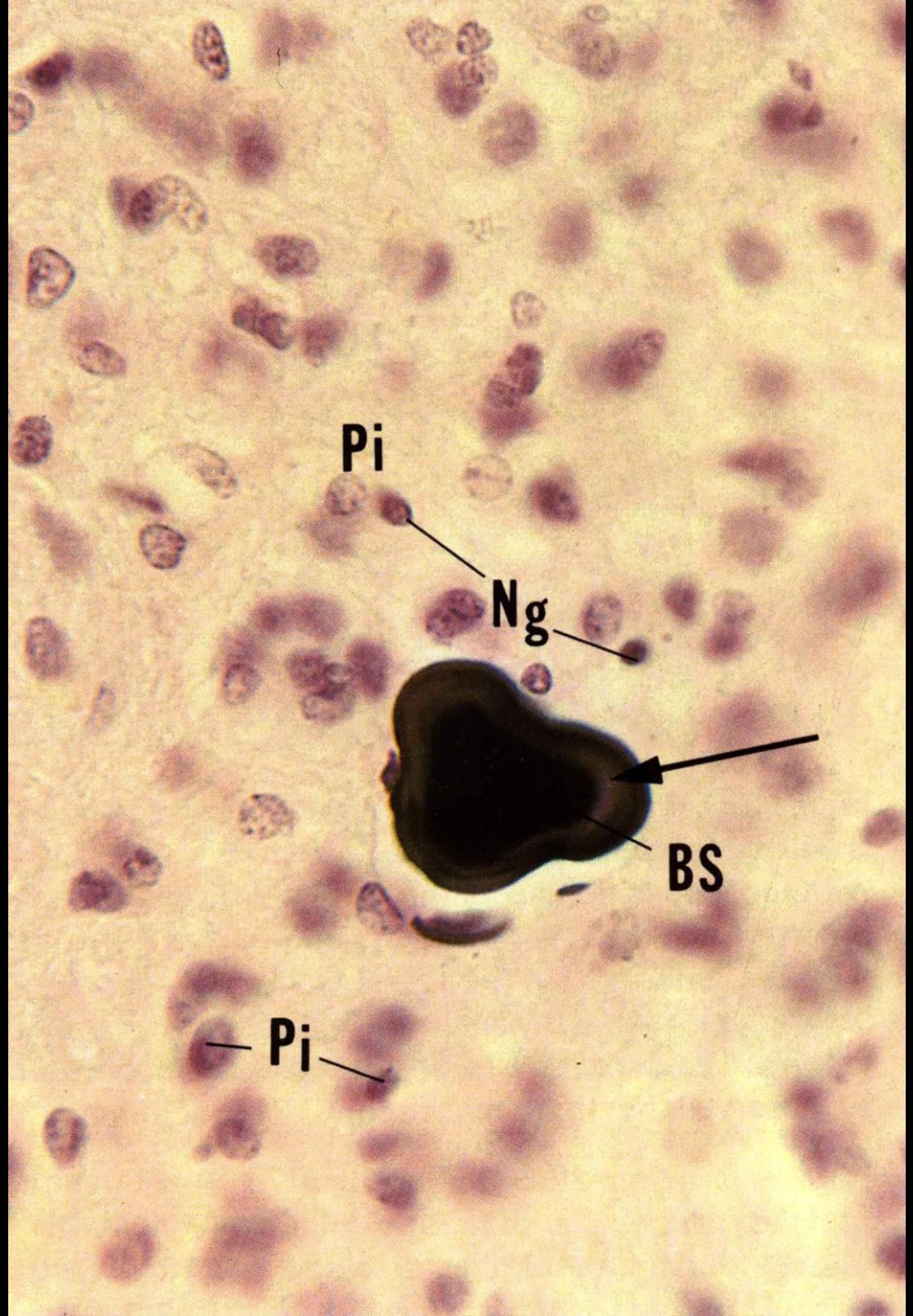
Pi
Ng
BS
Pi

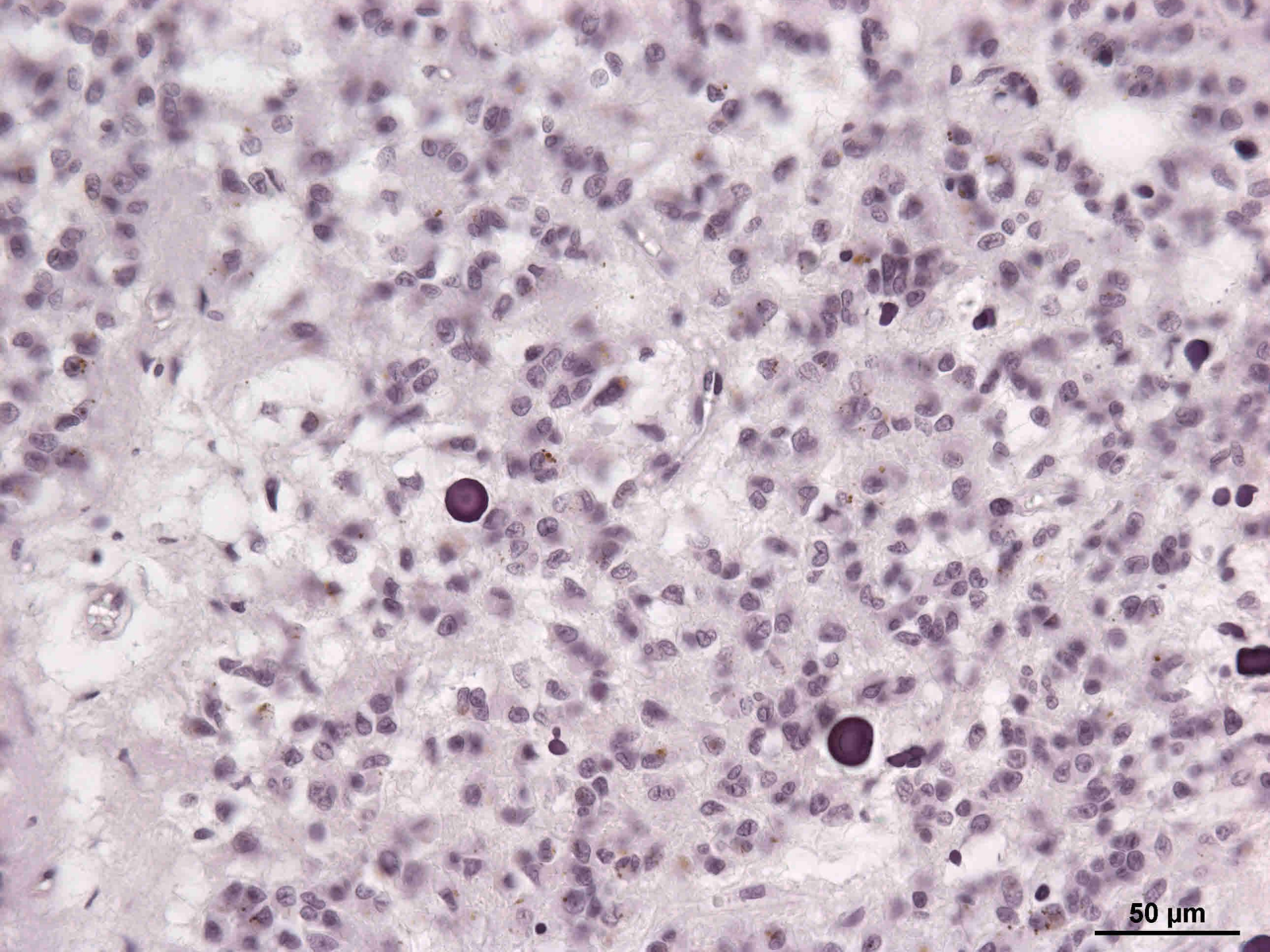
50 µm

It is famous for the big development of the "third eye" on the head, visible in the young, called parietal eye © Southland Museum & Art Gallery, Invercargill

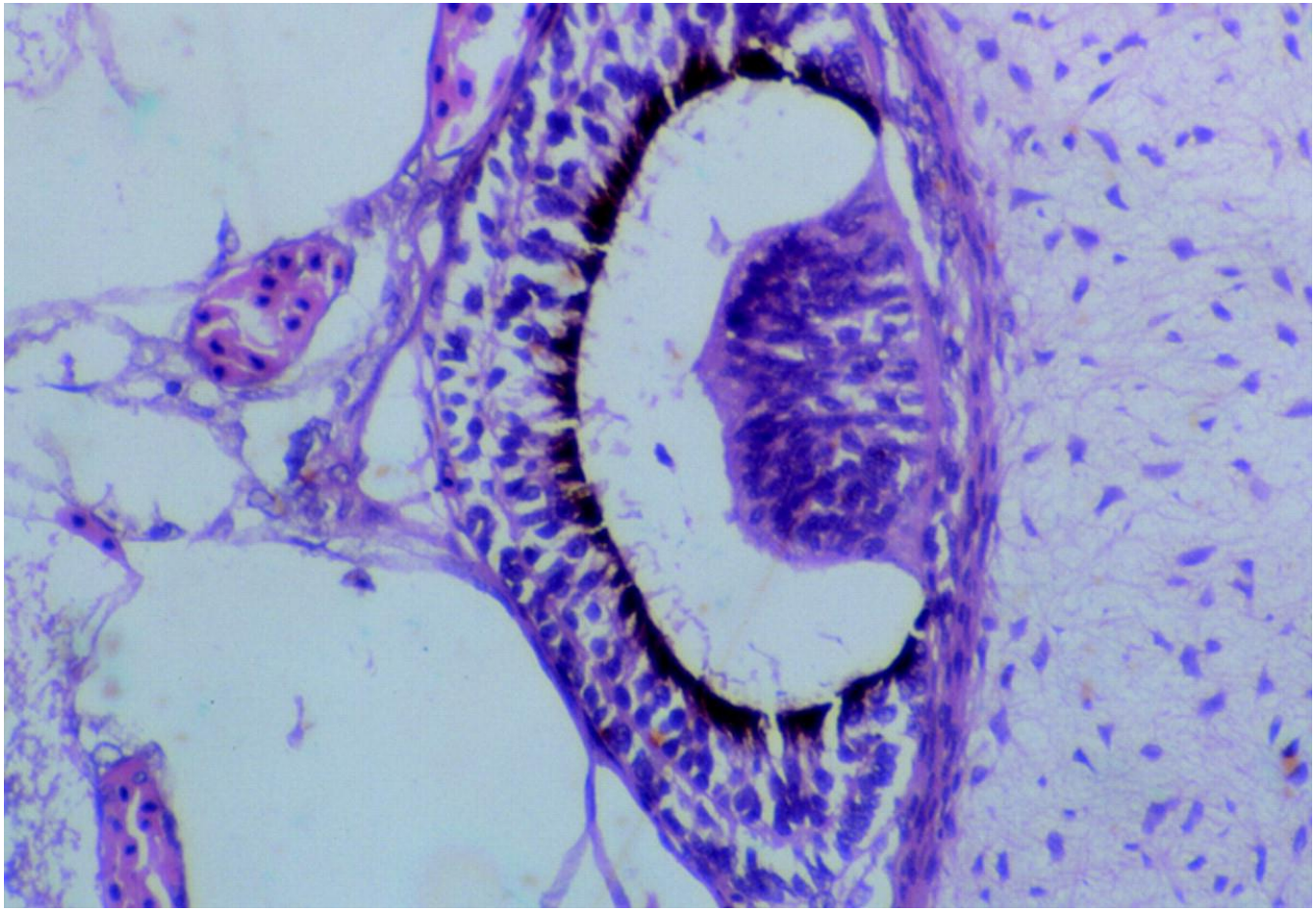

Schwab IR, O'Connor GR
The lonely eye
British Journal of Ophthalmology 2005;89:256.

Marques, Bruno & Mcintosh, Jacqueline & Hatton, William & Shanahan, Danielle. (2019). Bicultural landscapes and ecological restoration in the compact city: The case of Zealandia as a sustainable ecosanctuary. JoLA - Journal on Landscape Architecture. 14. 44-53. 10.1080/18626033.2019.1623545.

"What do you look for in a partner?"

Decalcified pineal gland.

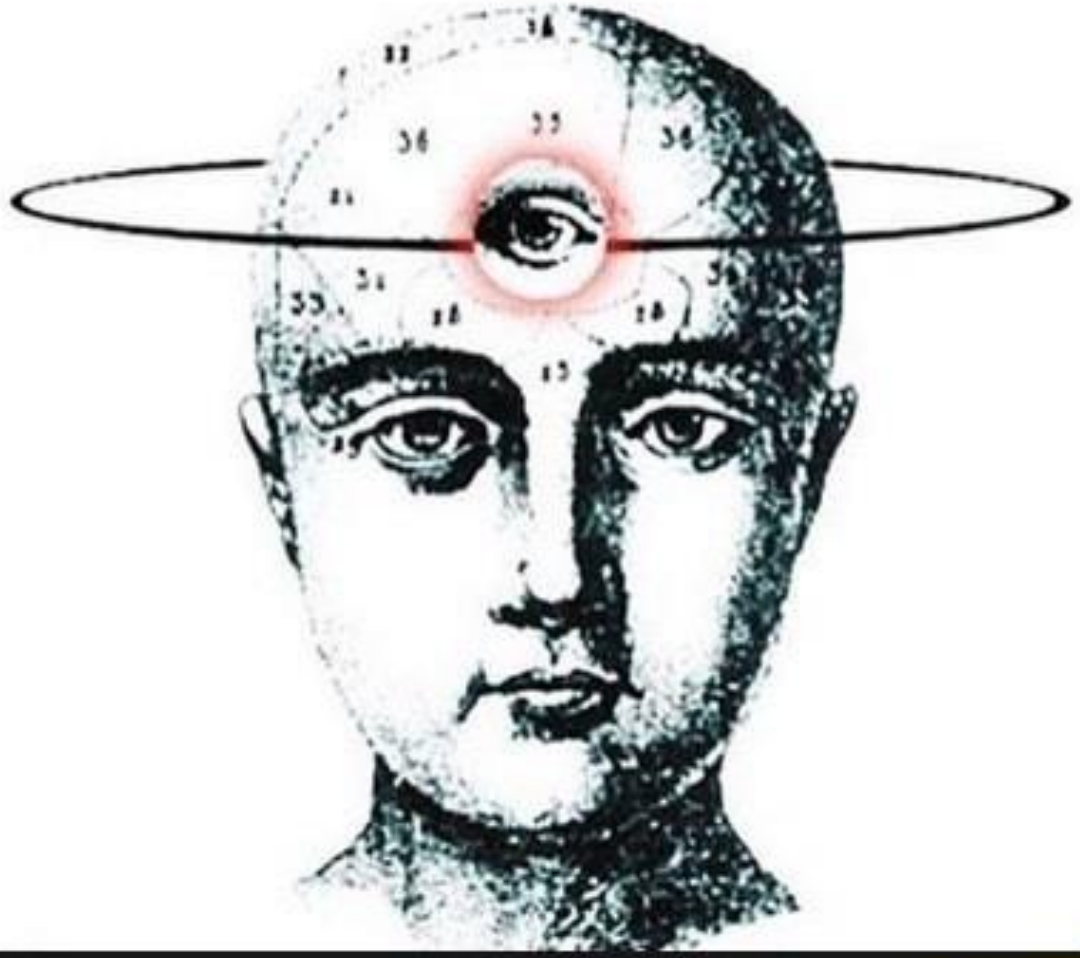

Thyroid gland

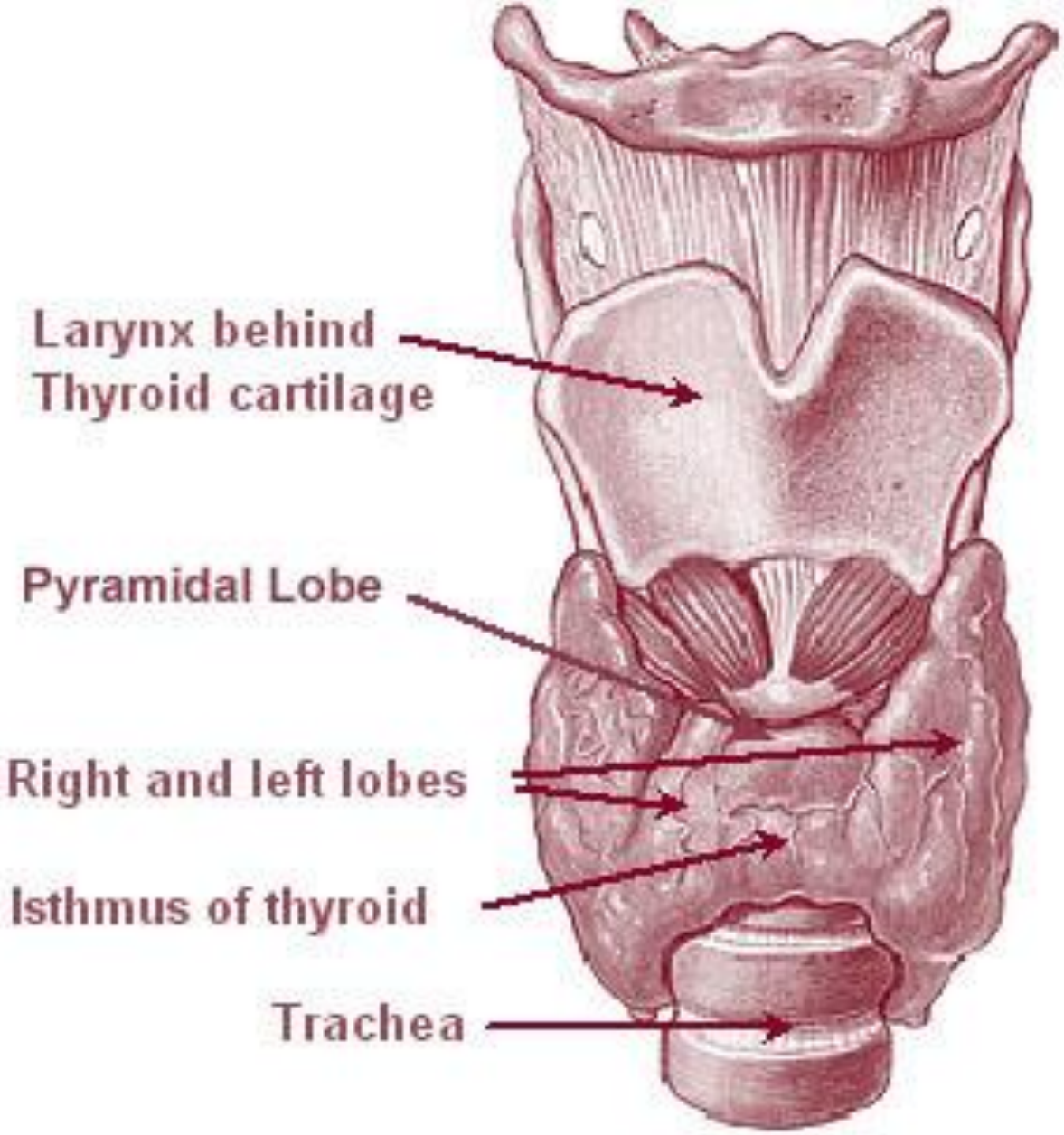
Larynx behind
Thyroid cartilage
Pyramidal Lobe
Right and left lobes
Isthmus of thyroid
Trachea

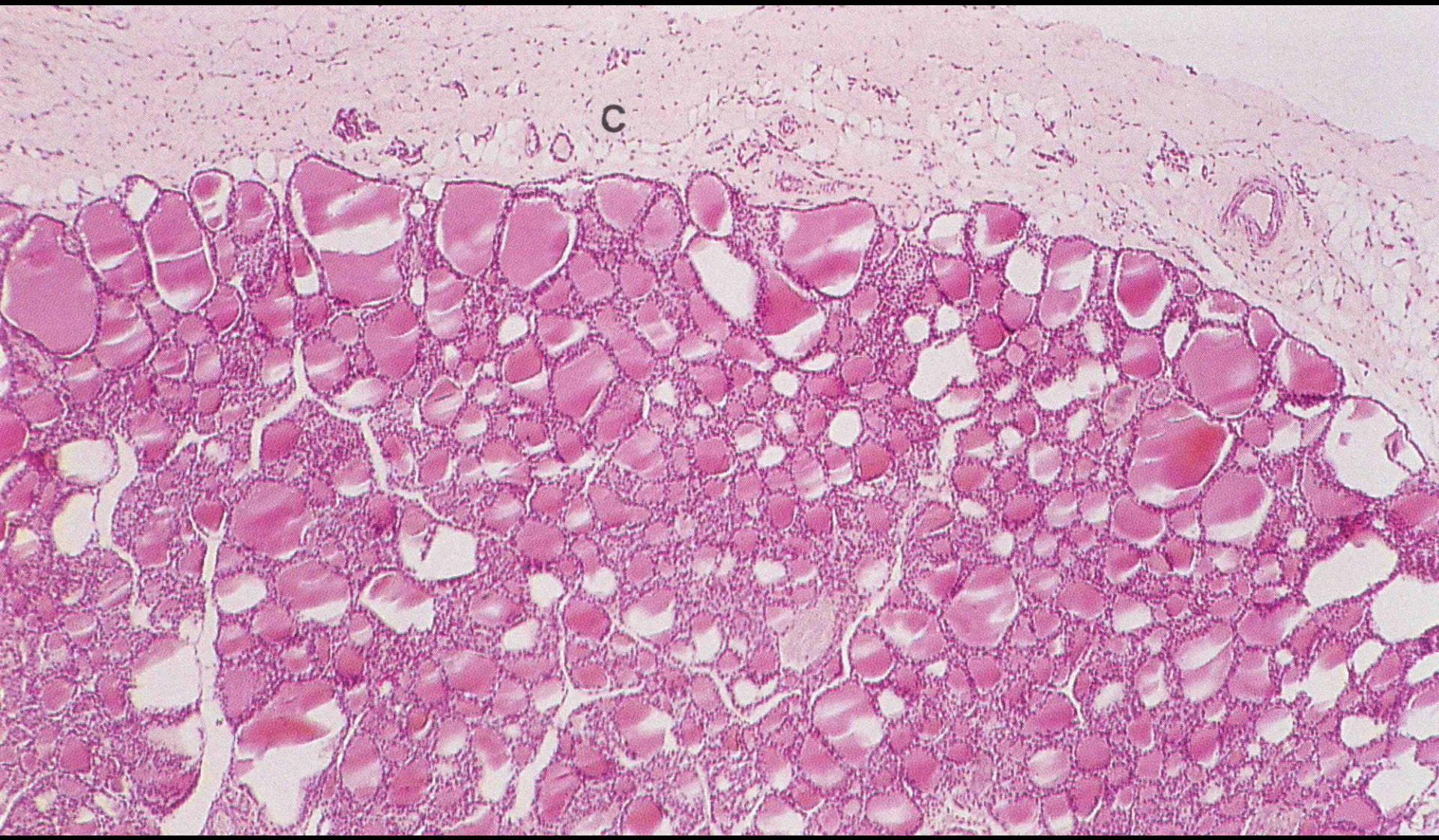
C

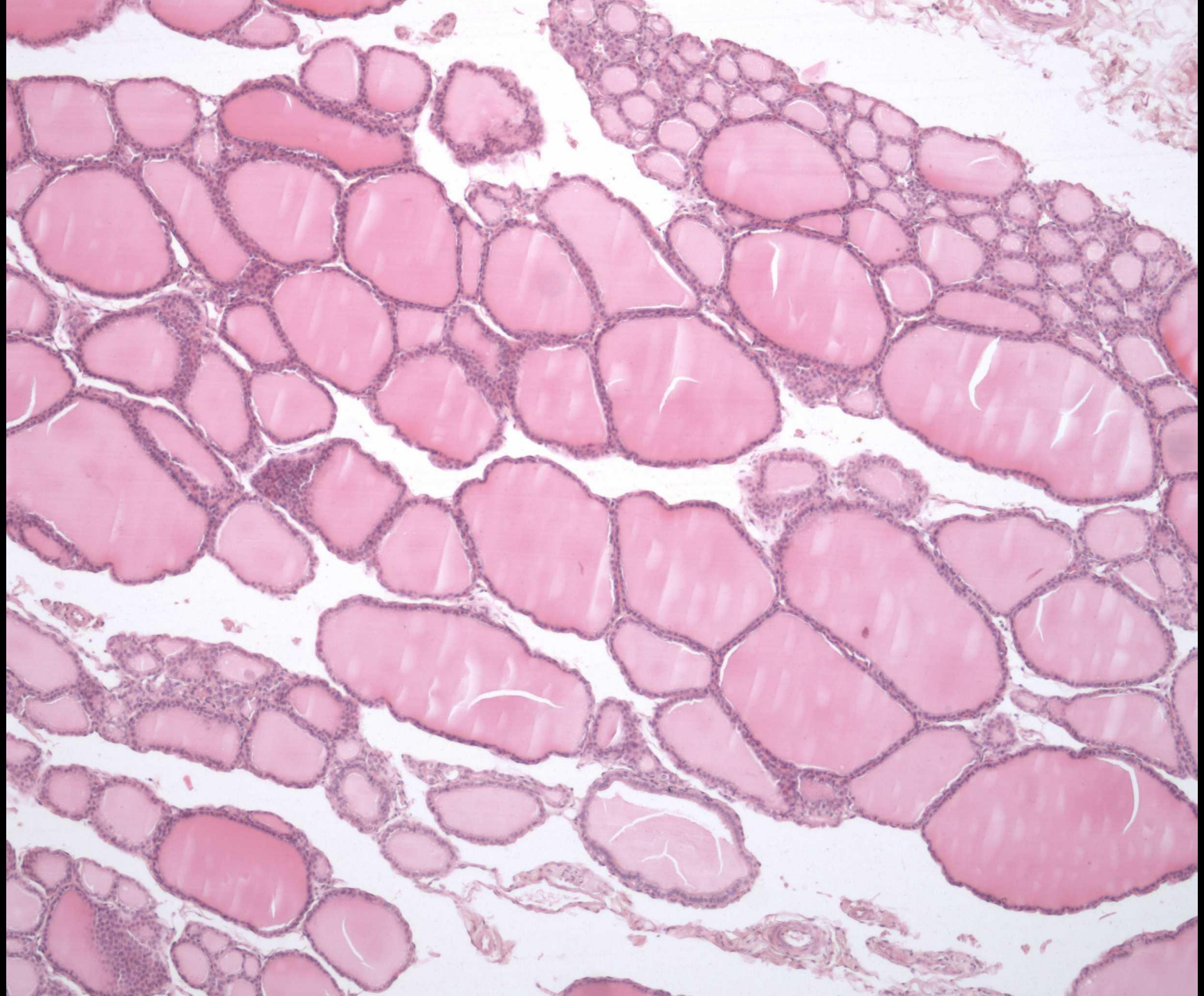


Thyrocytes- follicles
Stroma: reticular connective tissue

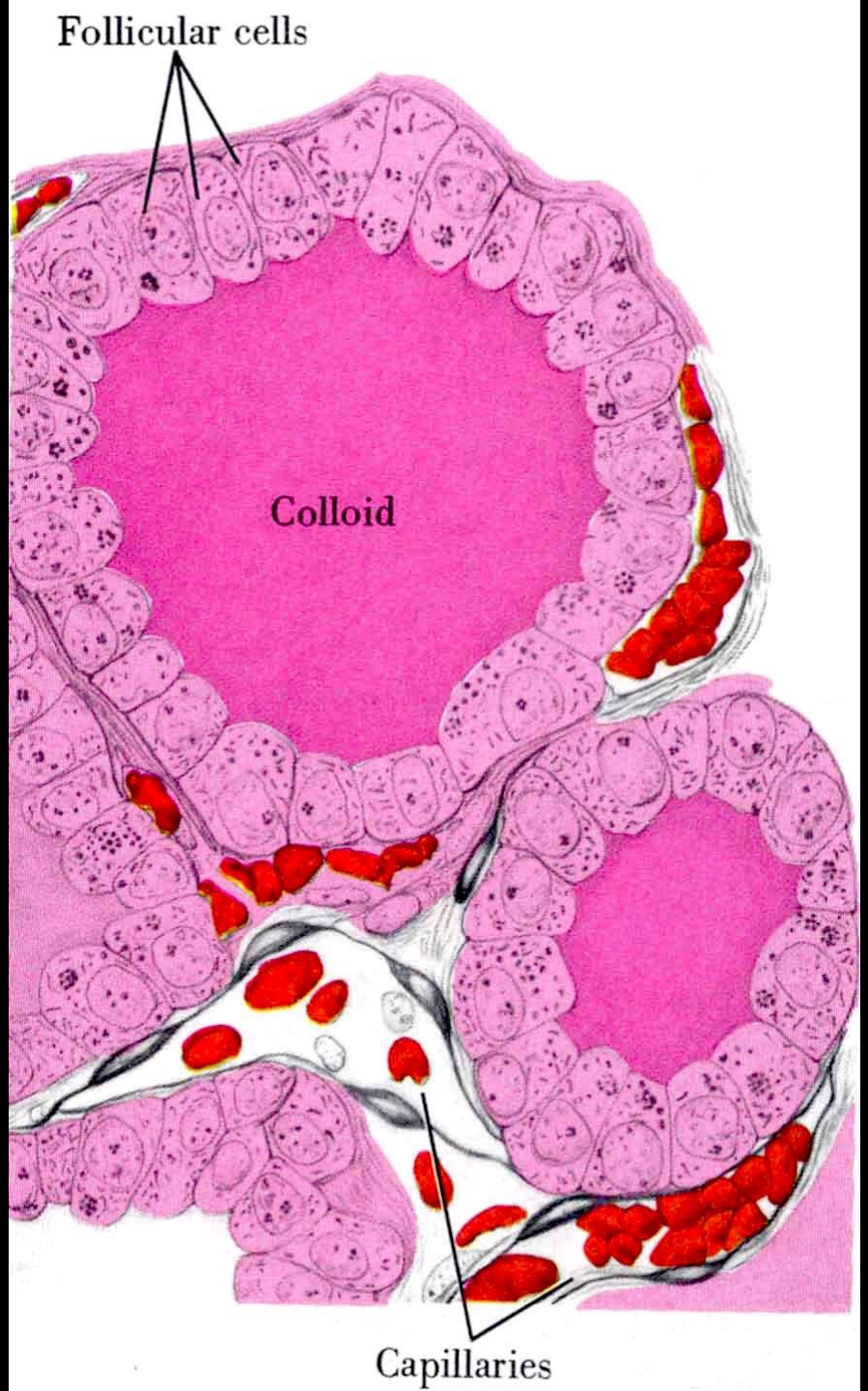
Follicular cells
Colloid
Capillaries

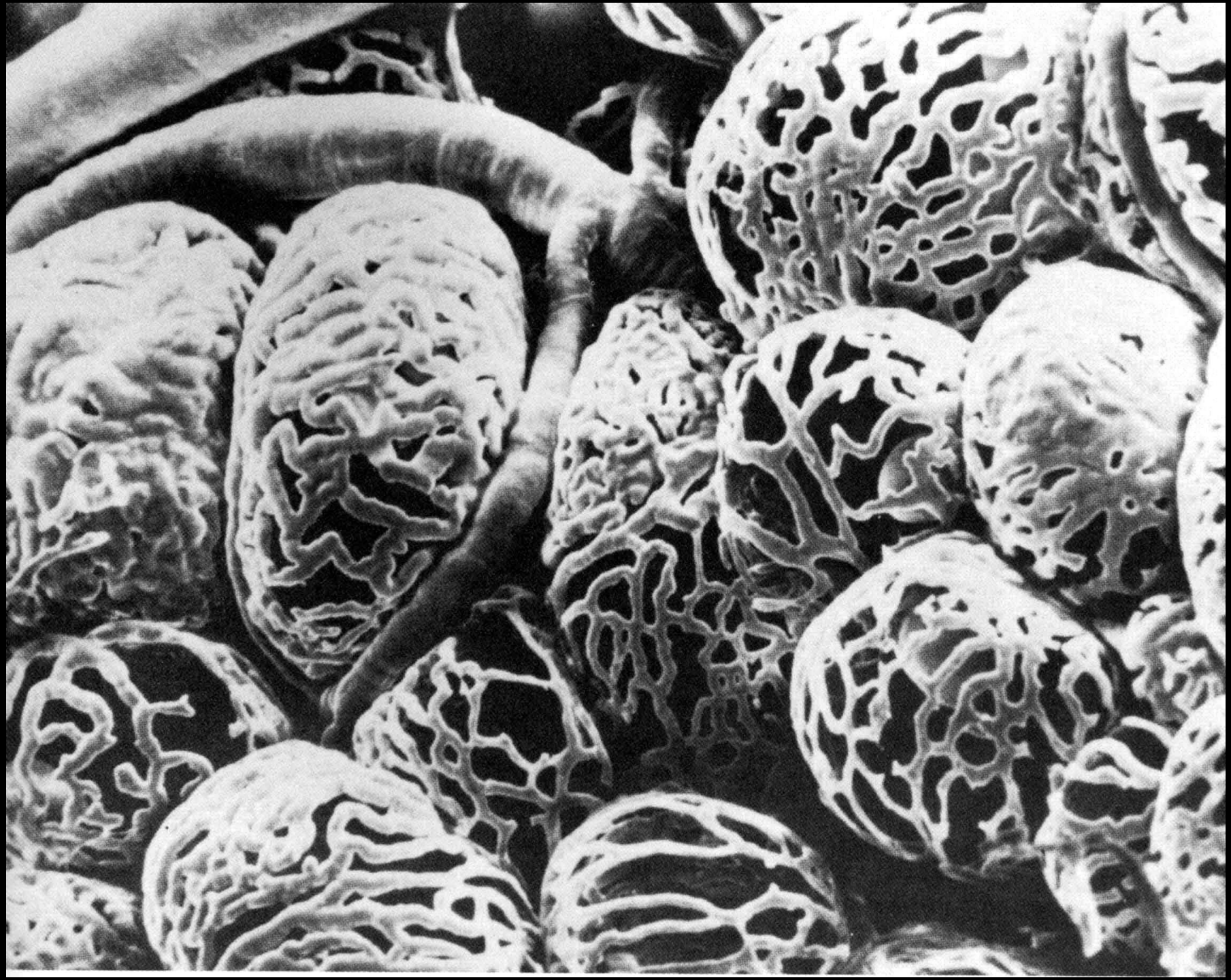

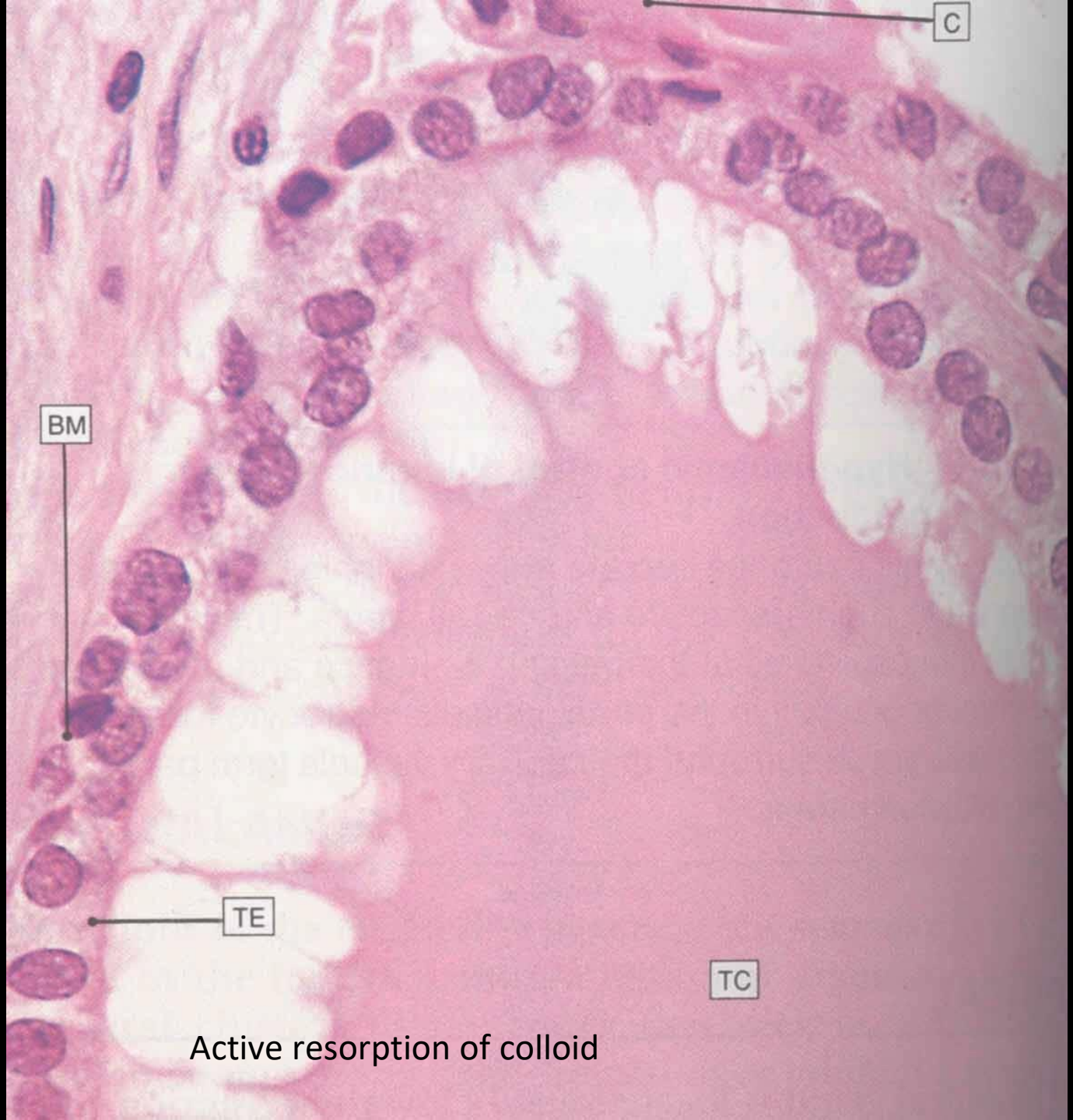

Active resorption of colloid

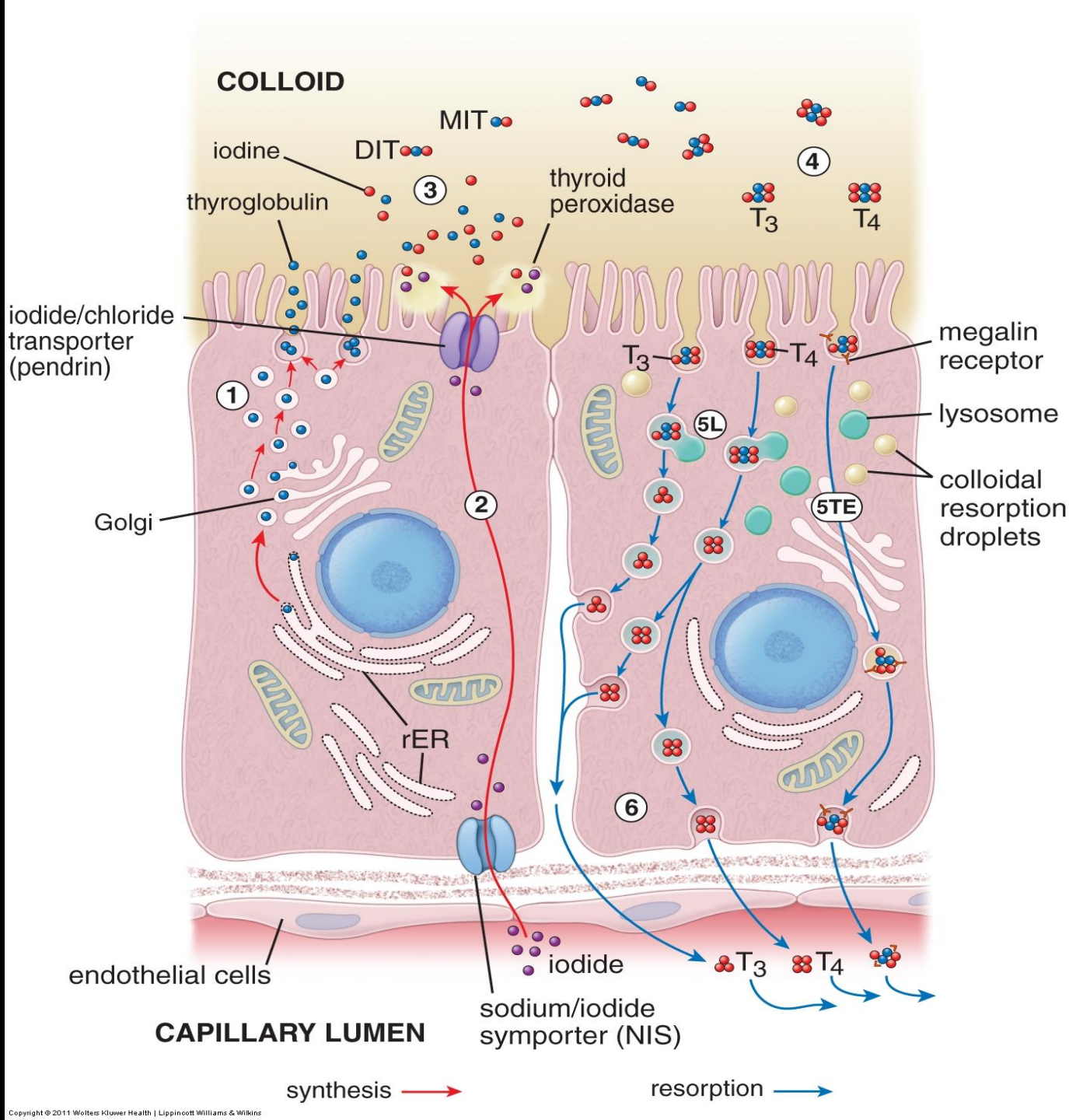

hormones:
T3 (triiodothyronine)
T4 (thyroxine)

Exophthalmos (bulging eyes)

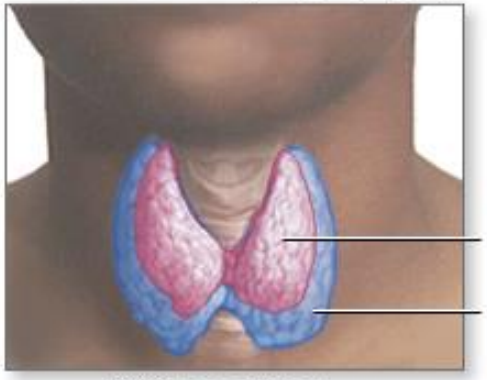

Diffuse goiter

Graves' disease is a common cause of hyperthyroidism, an over-production of thyroid hormone, which causes enlargement of the thyroid and other symptoms such as exophthalmos, heat intolerance and anxiety

ADAM.

Disorder of the thyroid gland

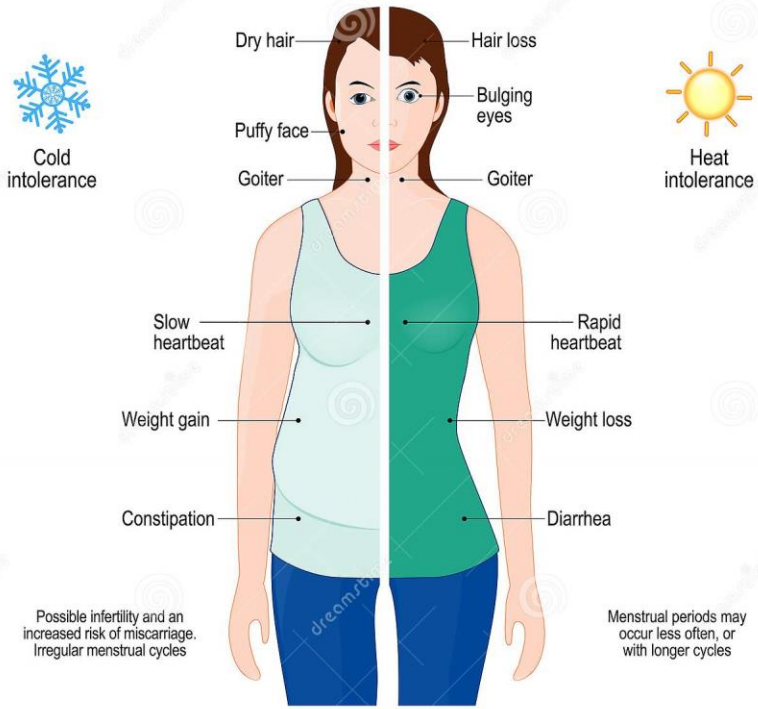

Parafollicular (C) cells

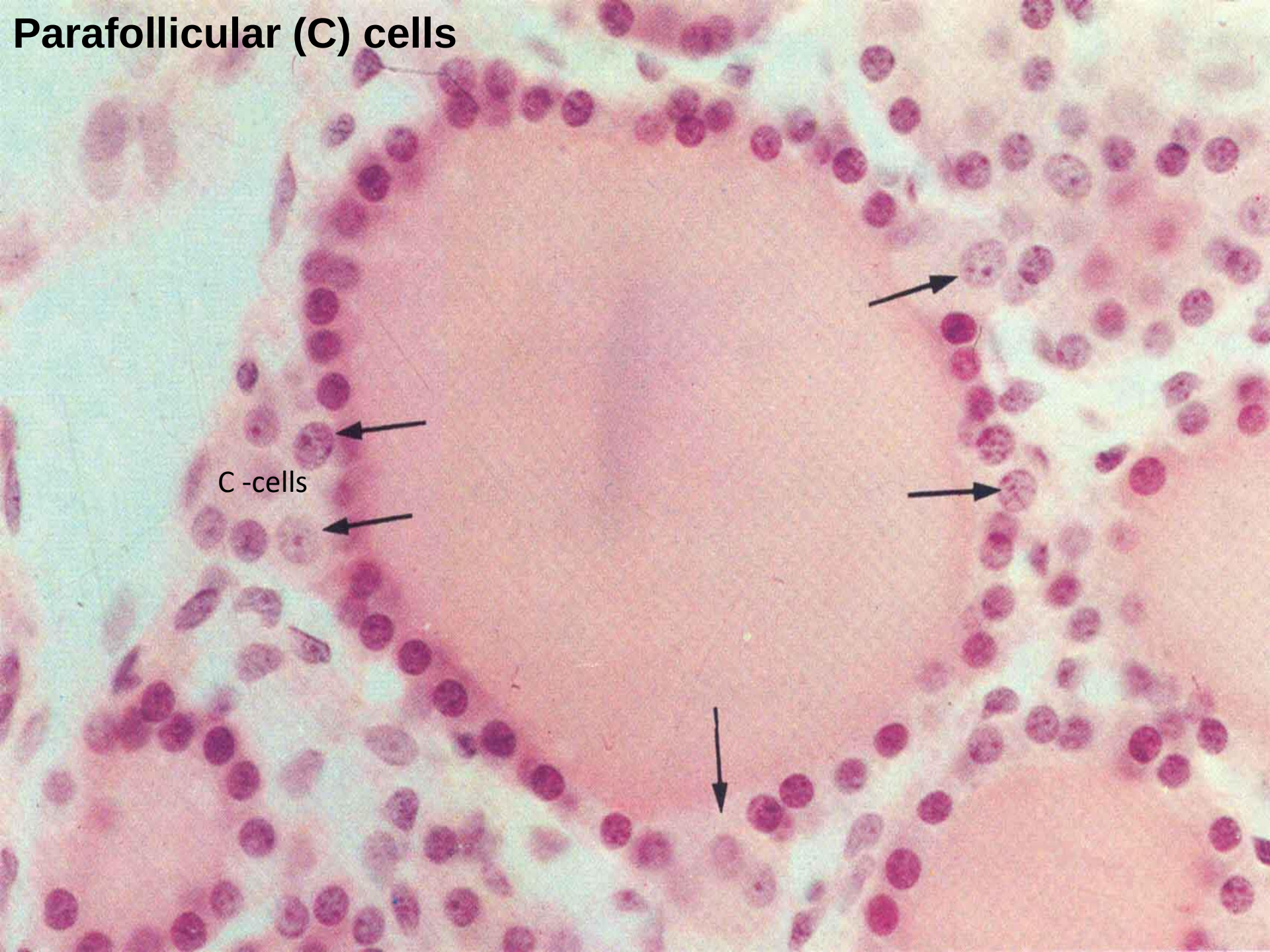

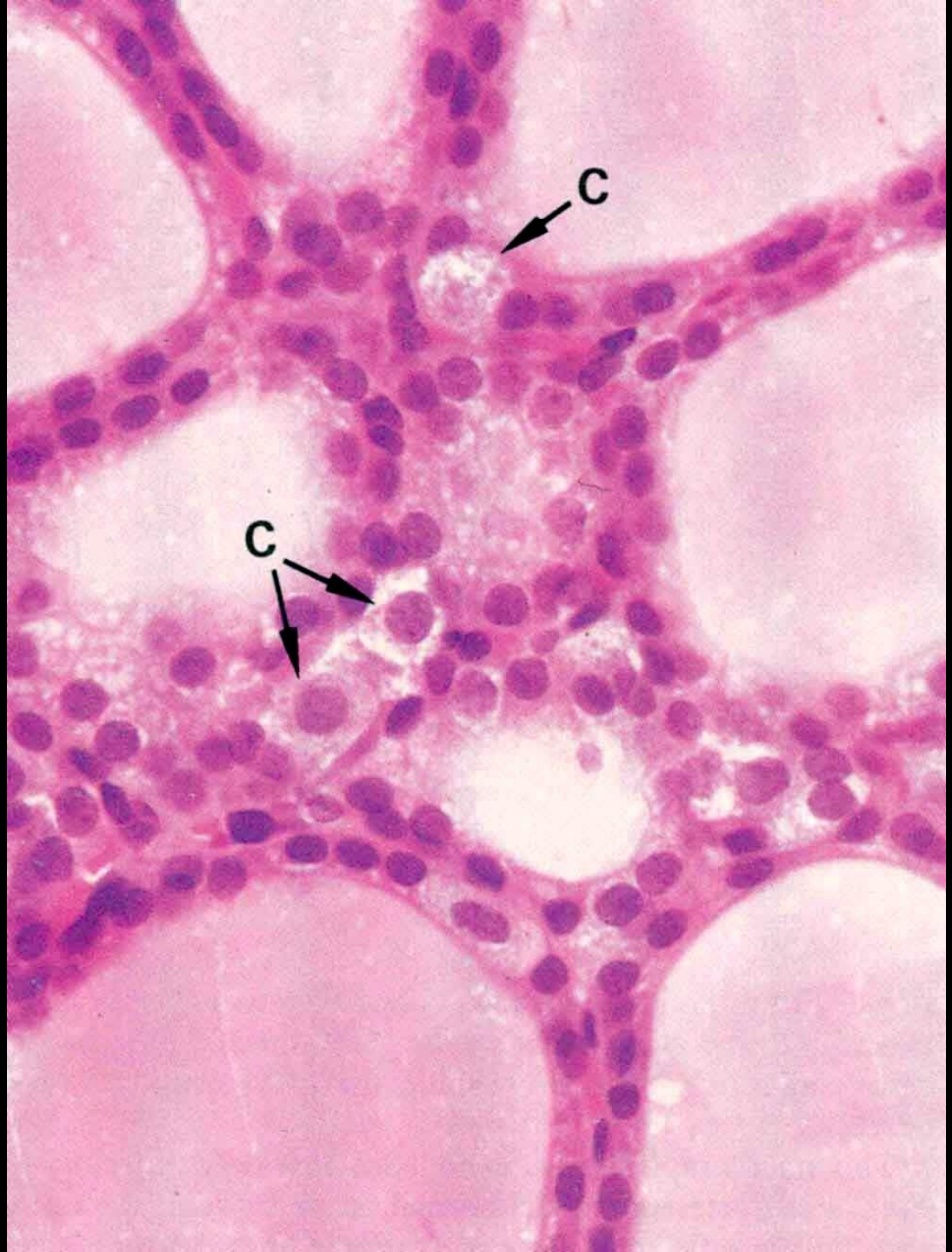
C
C

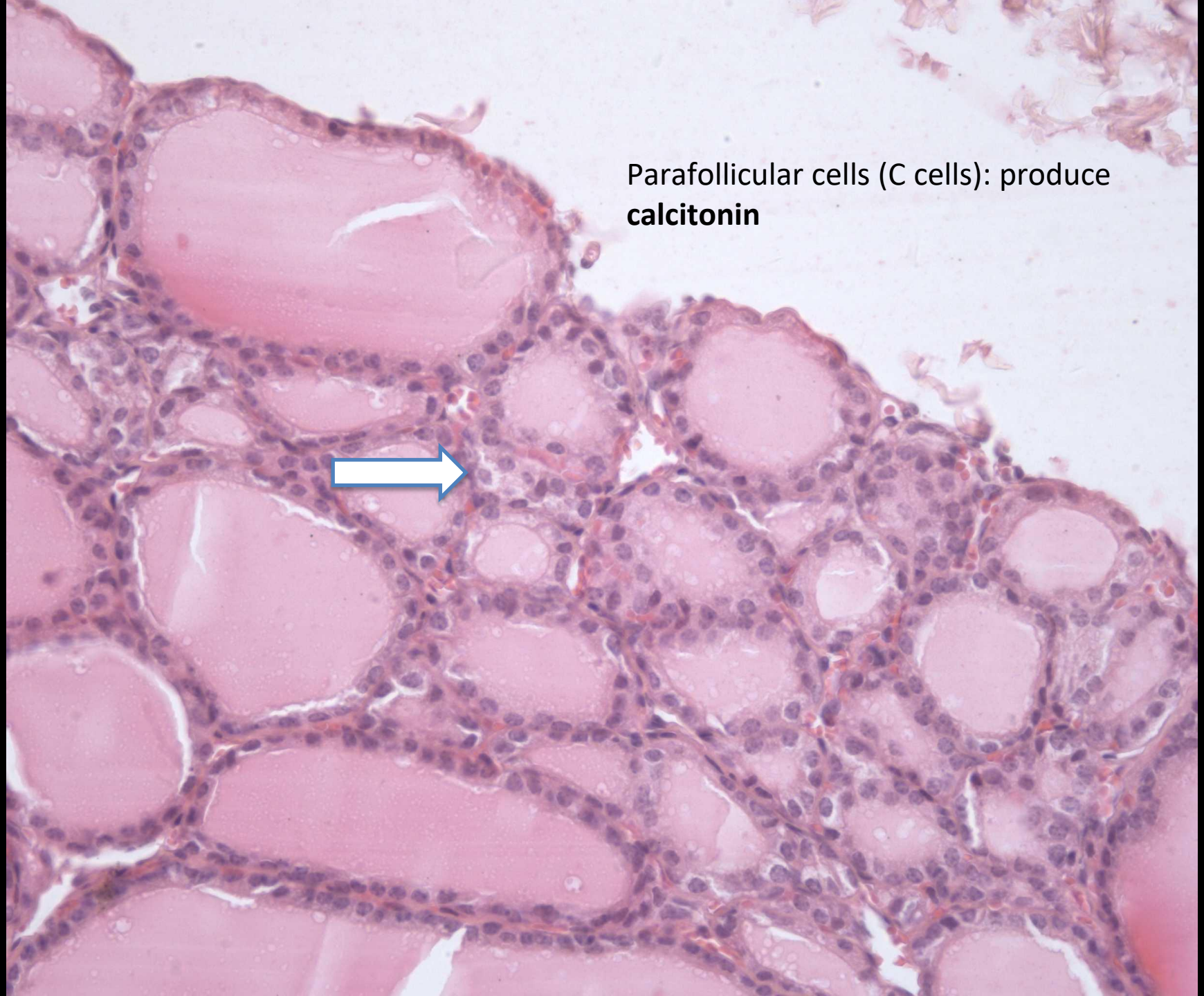
Parafollicular cells (C cells): produce
calcitonin

Development of thyroid gland

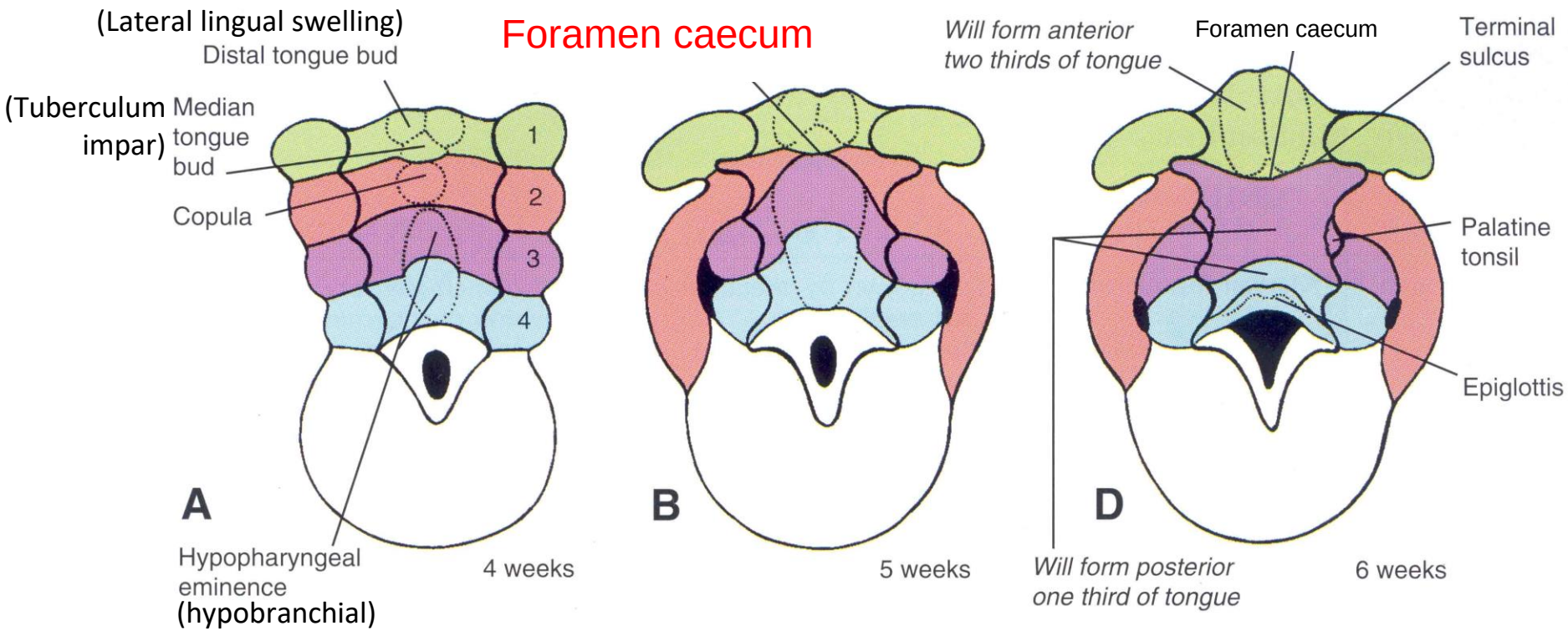

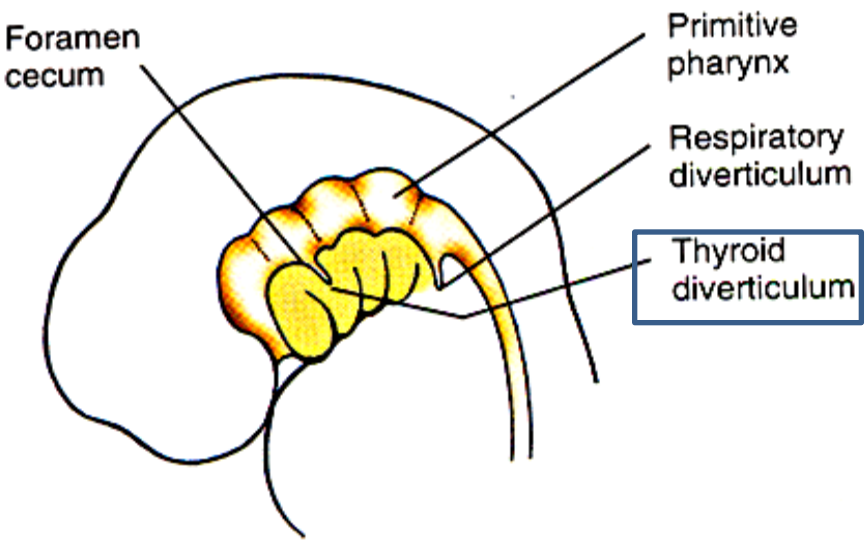

4th week

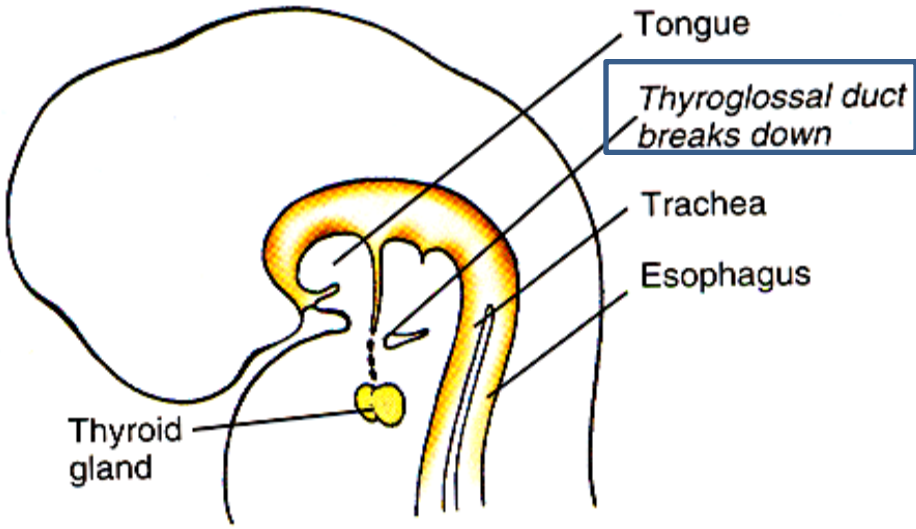

Late 5th week

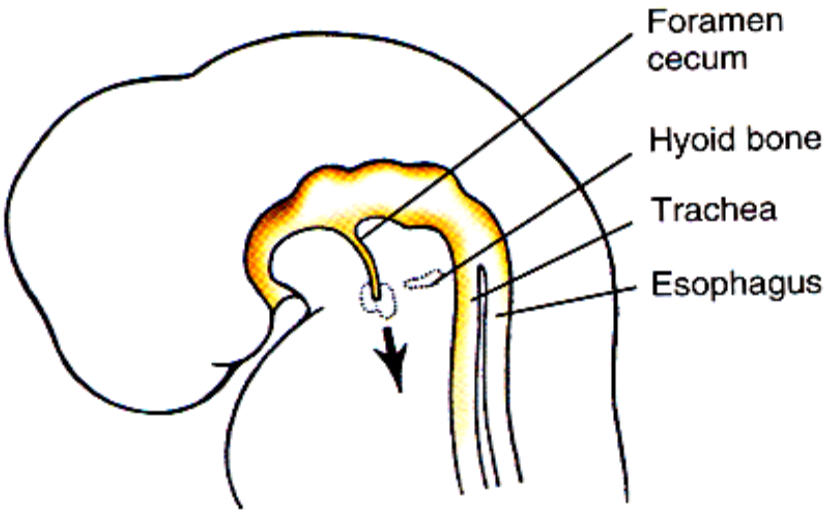

Early 5th week

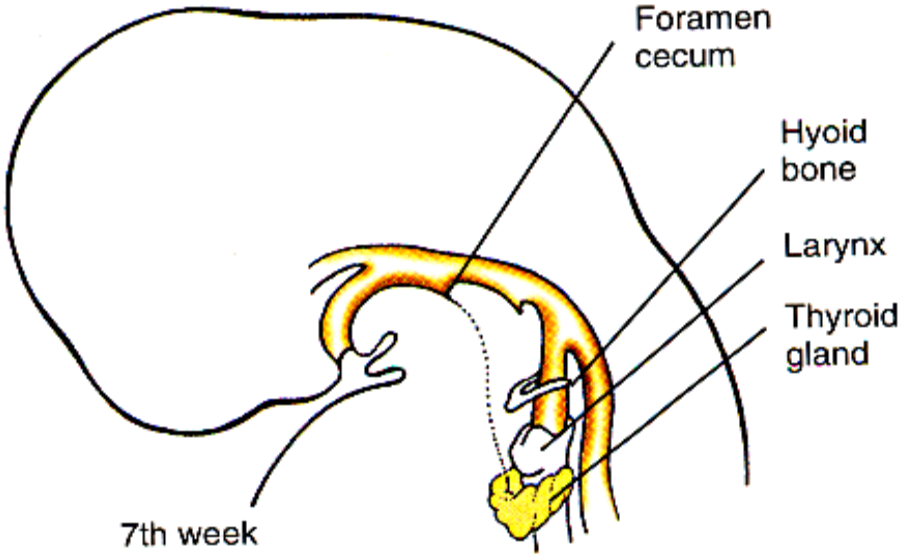

7th week

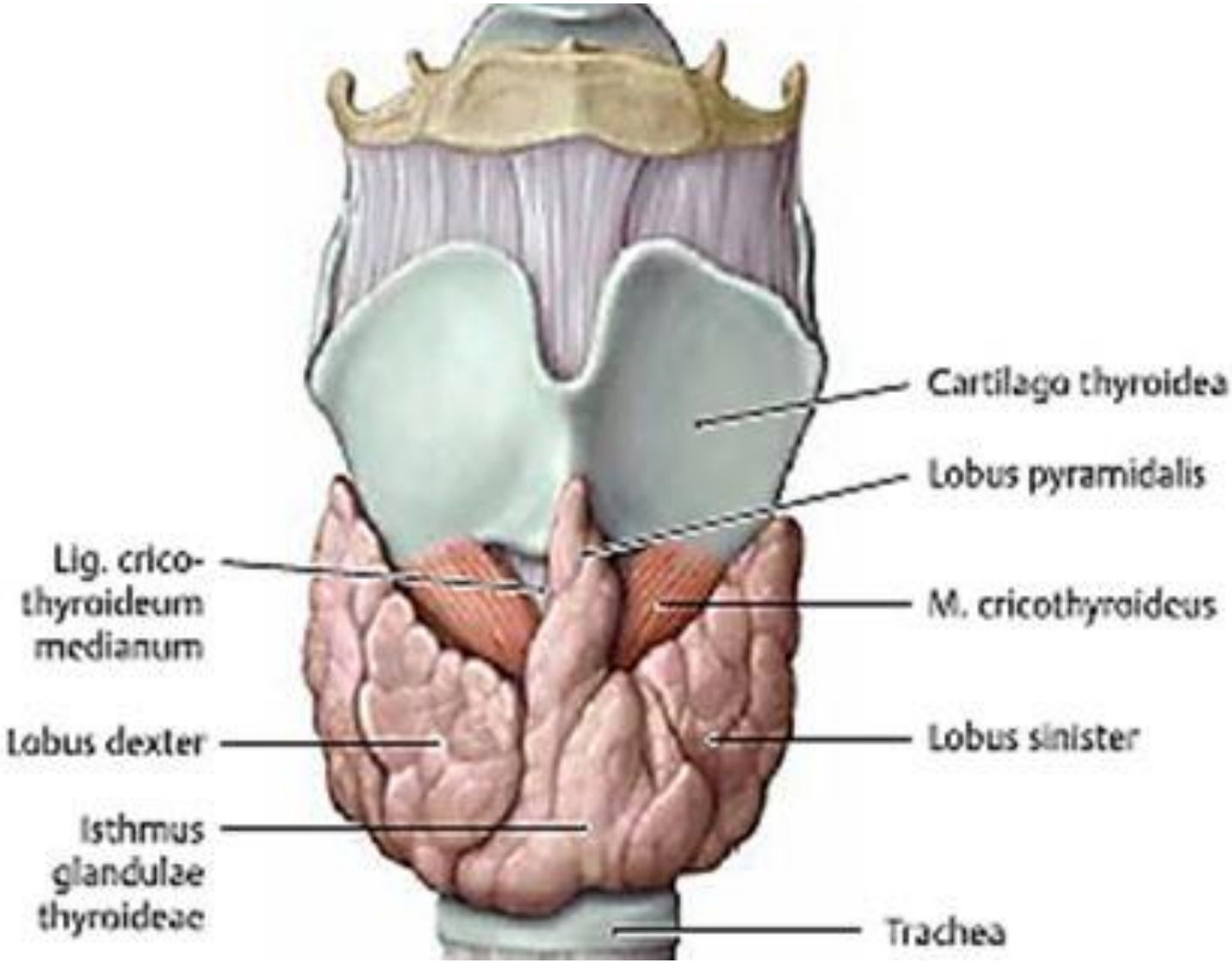
Cartilago thyroidea
Lobus pyramidalis
Lig. crico-
thyroideum
medianum
M. cricothyroideus
Lobus dexter
Lobus sinister
Isthmus
glandulae
thyroideae
Trachea

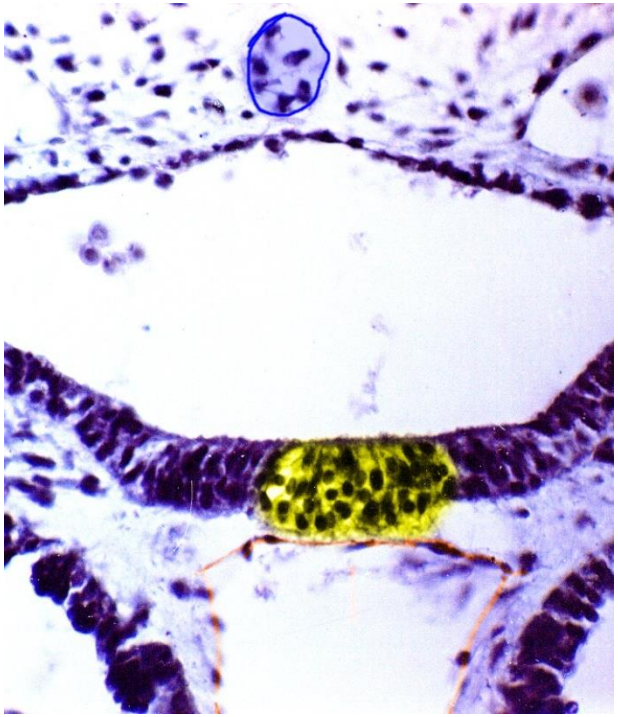

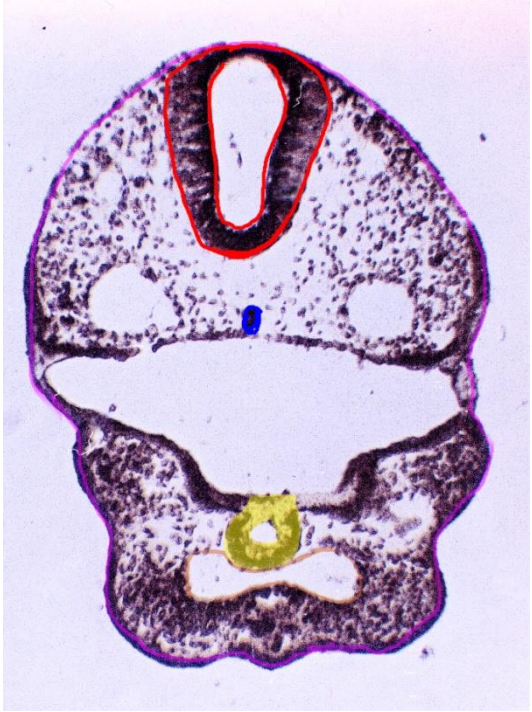

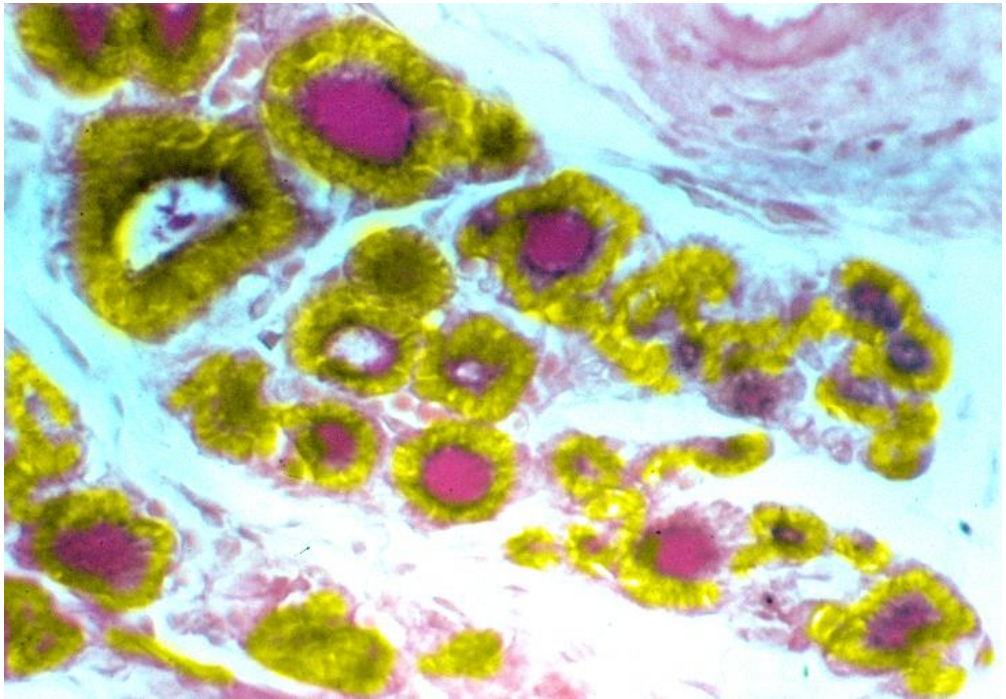

Development of parathyroid glands

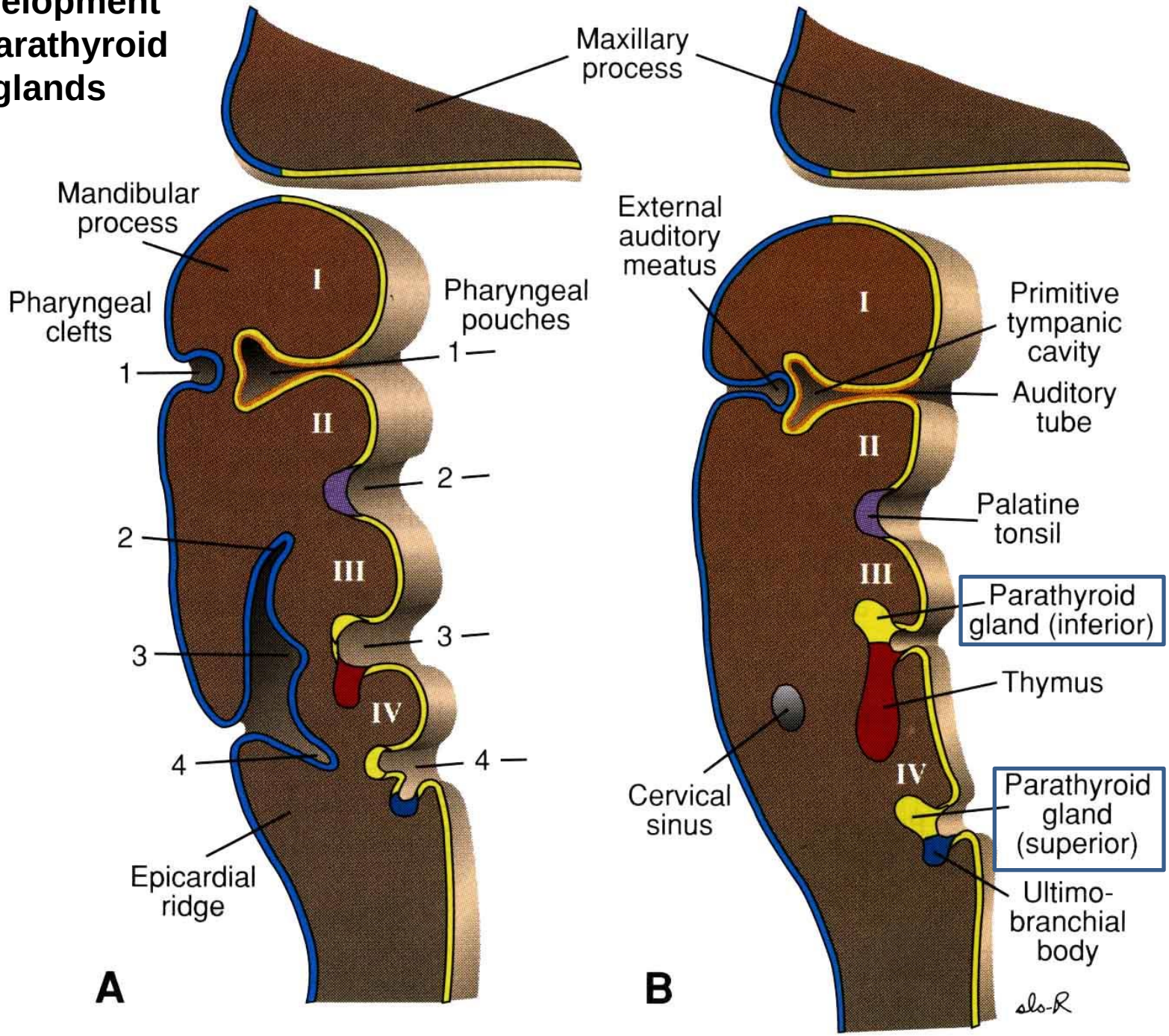

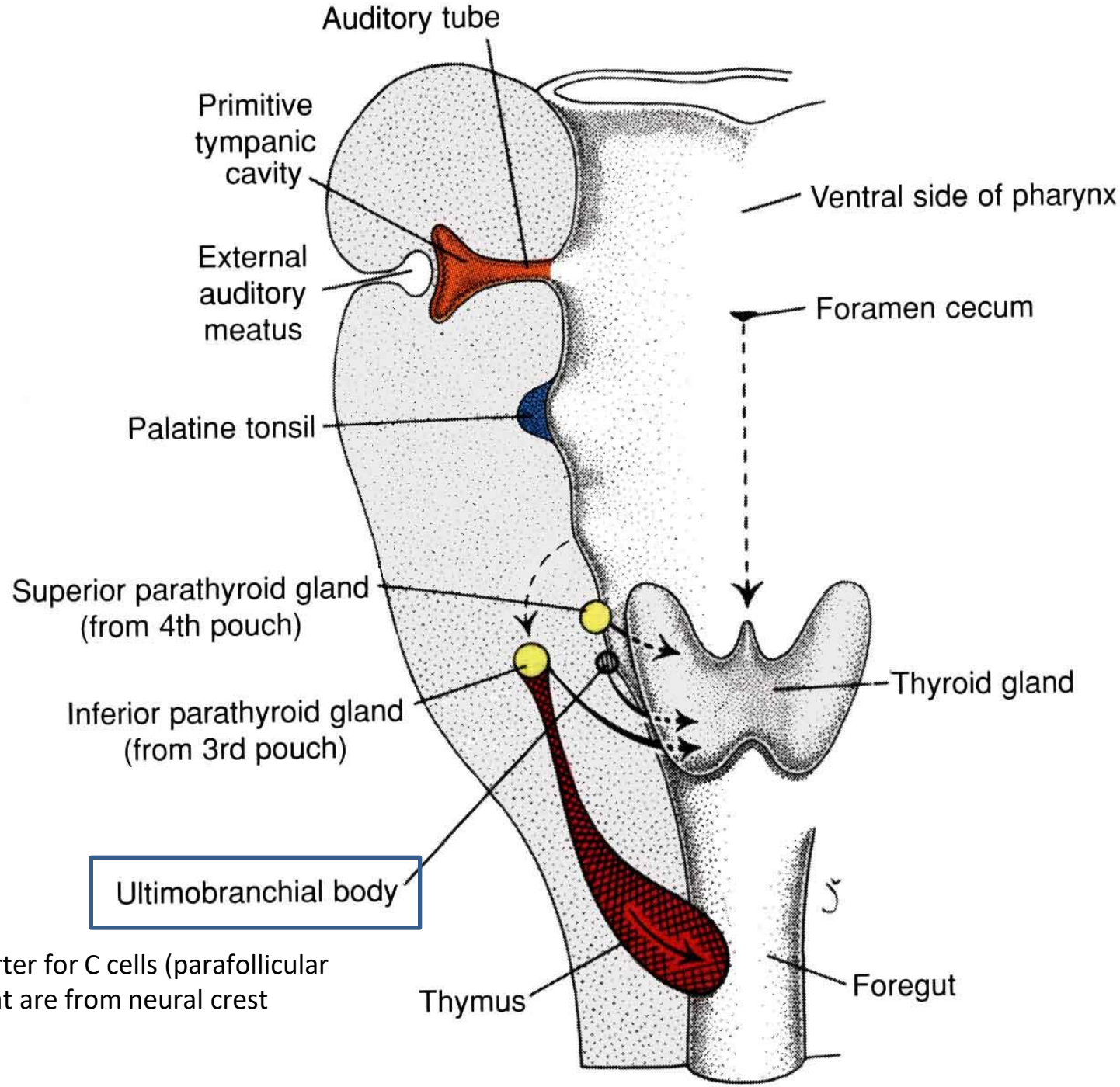

Transporter for C cells (parafollicular cells) that are from neural crest

Parathyroid glands (bodies)

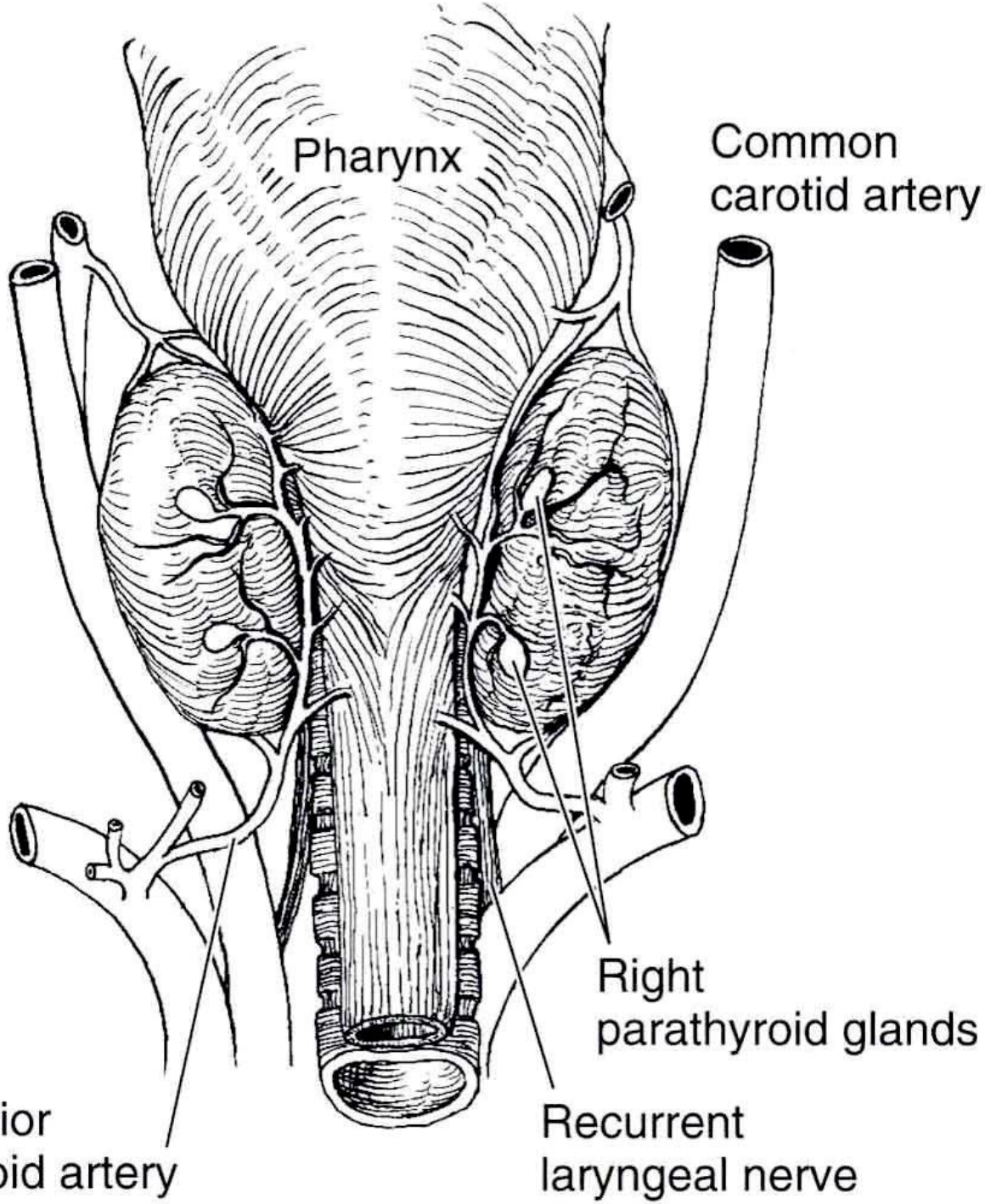
Pharynx
Common carotid artery
Right parathyroid glands
Inferior thyroid artery
Recurrent laryngeal nerve

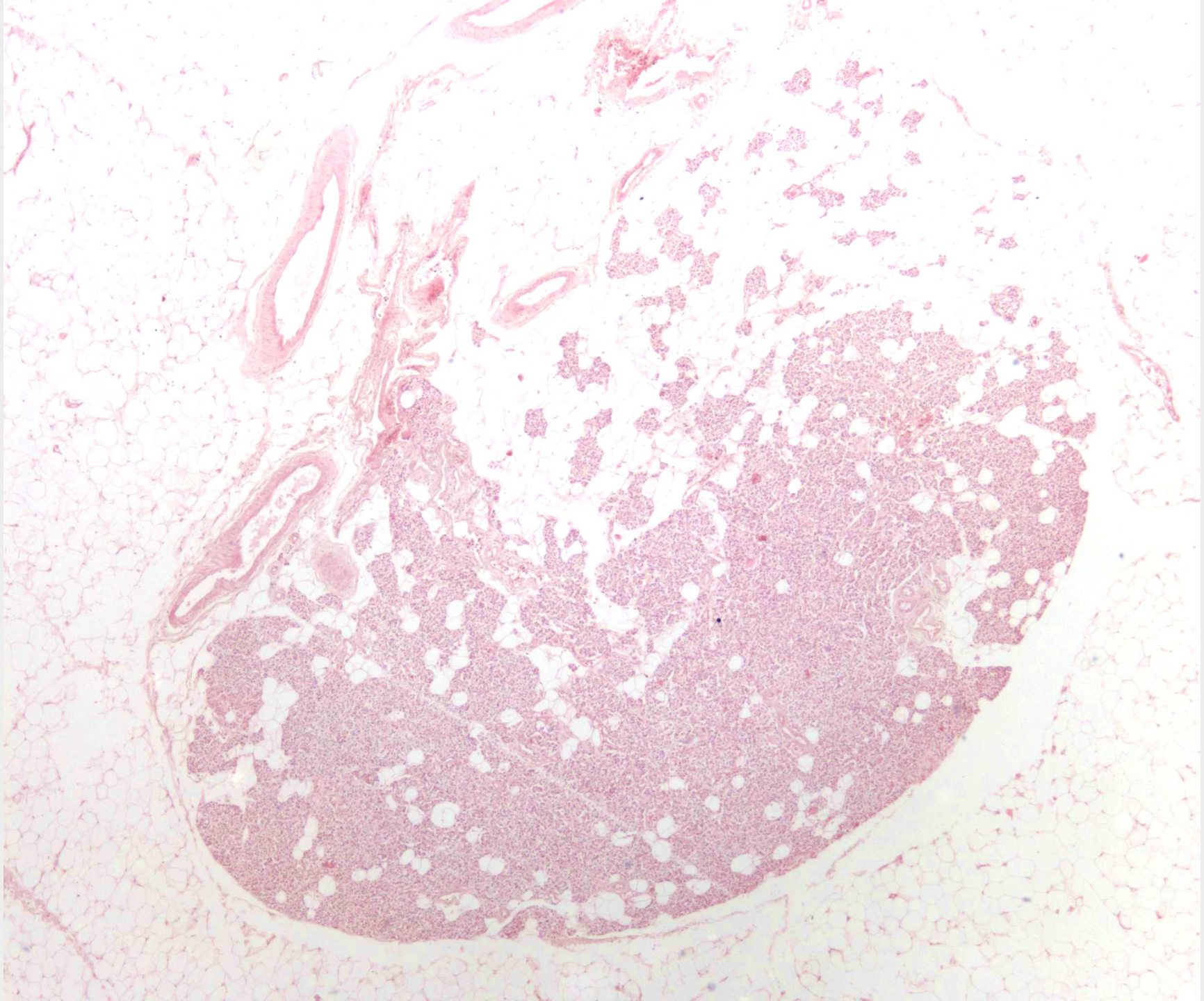

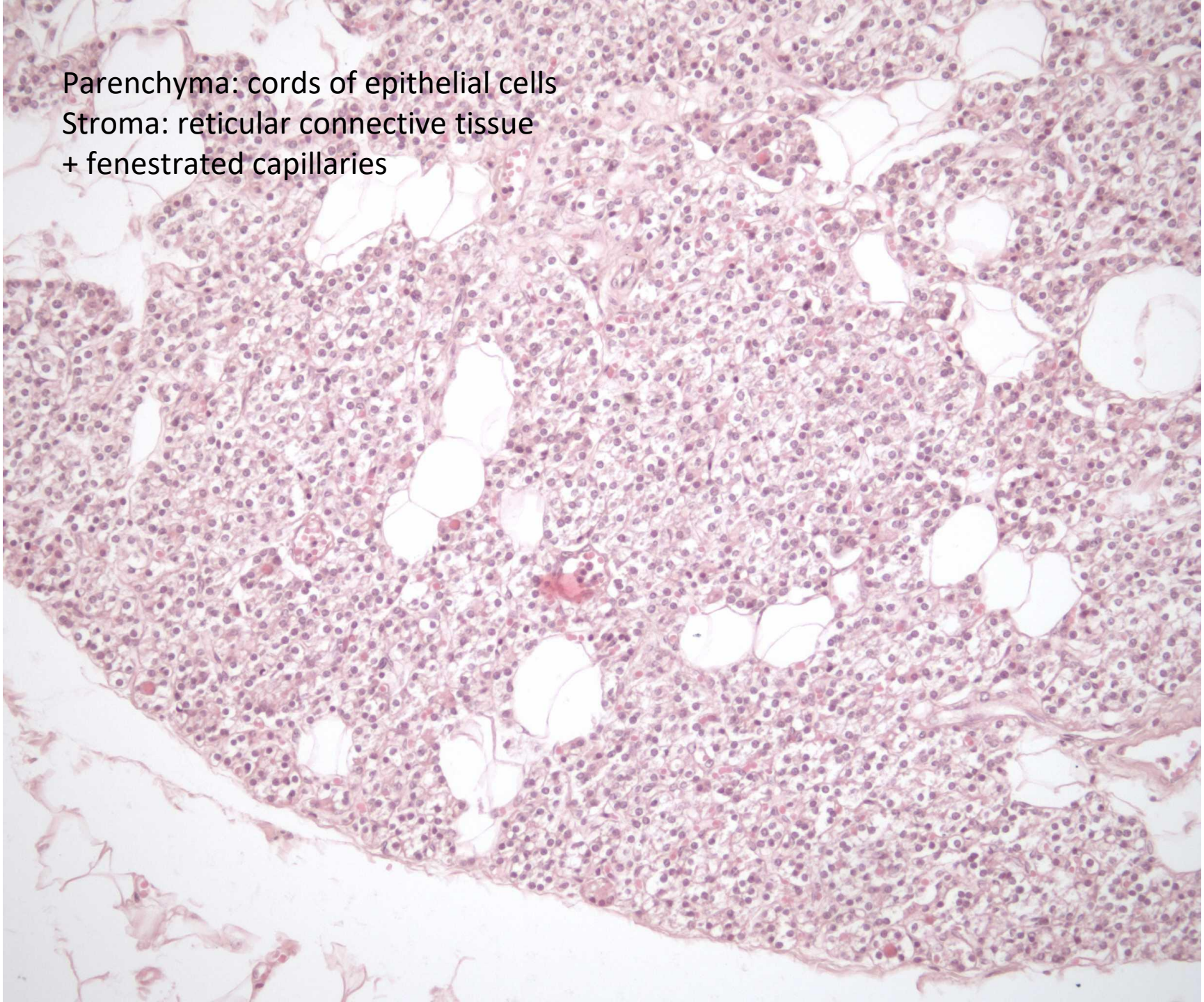
Parenchyma: cords of epithelial cells
Stroma: reticular connective tissue
+ fenestrated capillaries

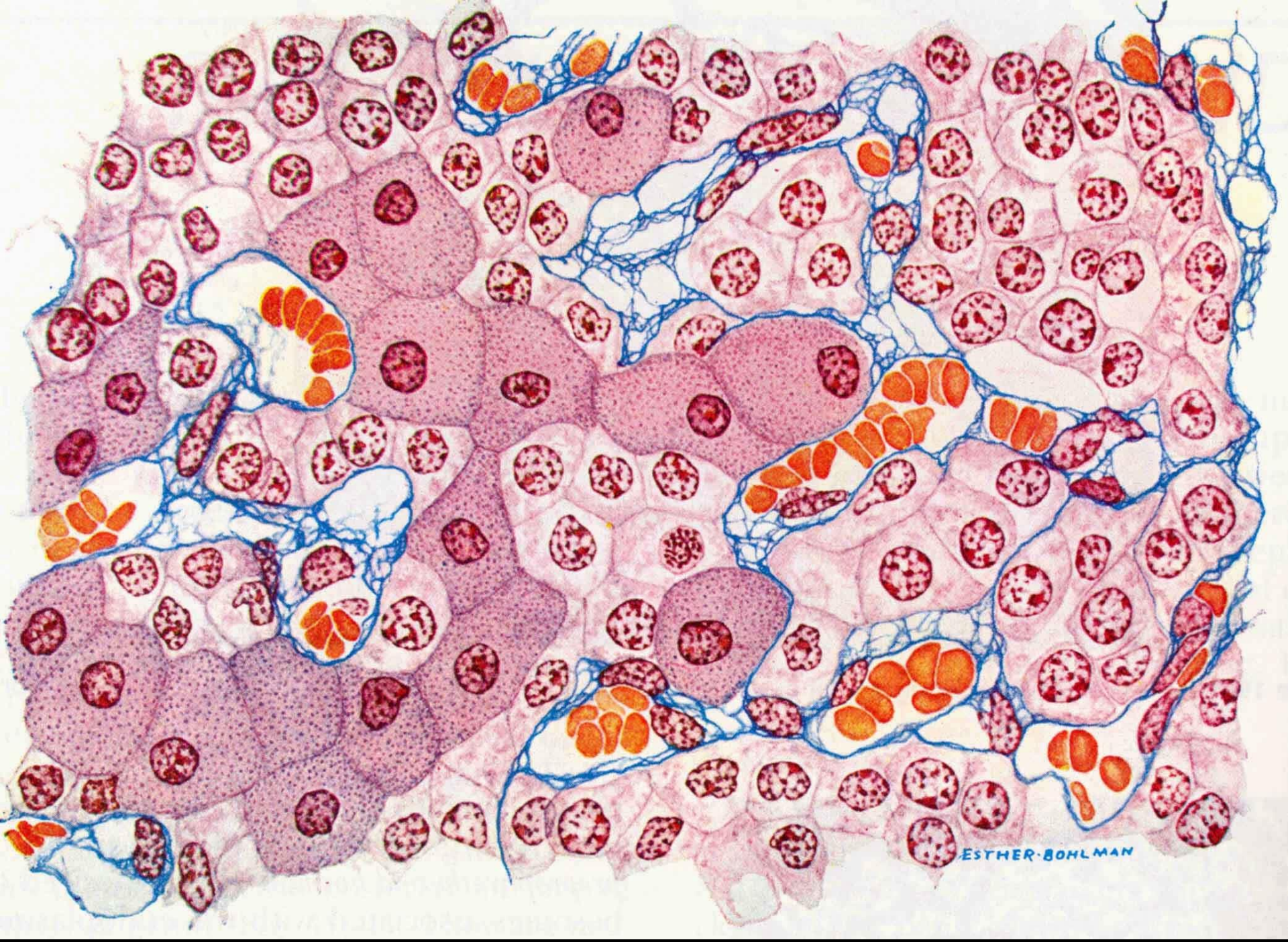
ESTHER·BOHLMAN

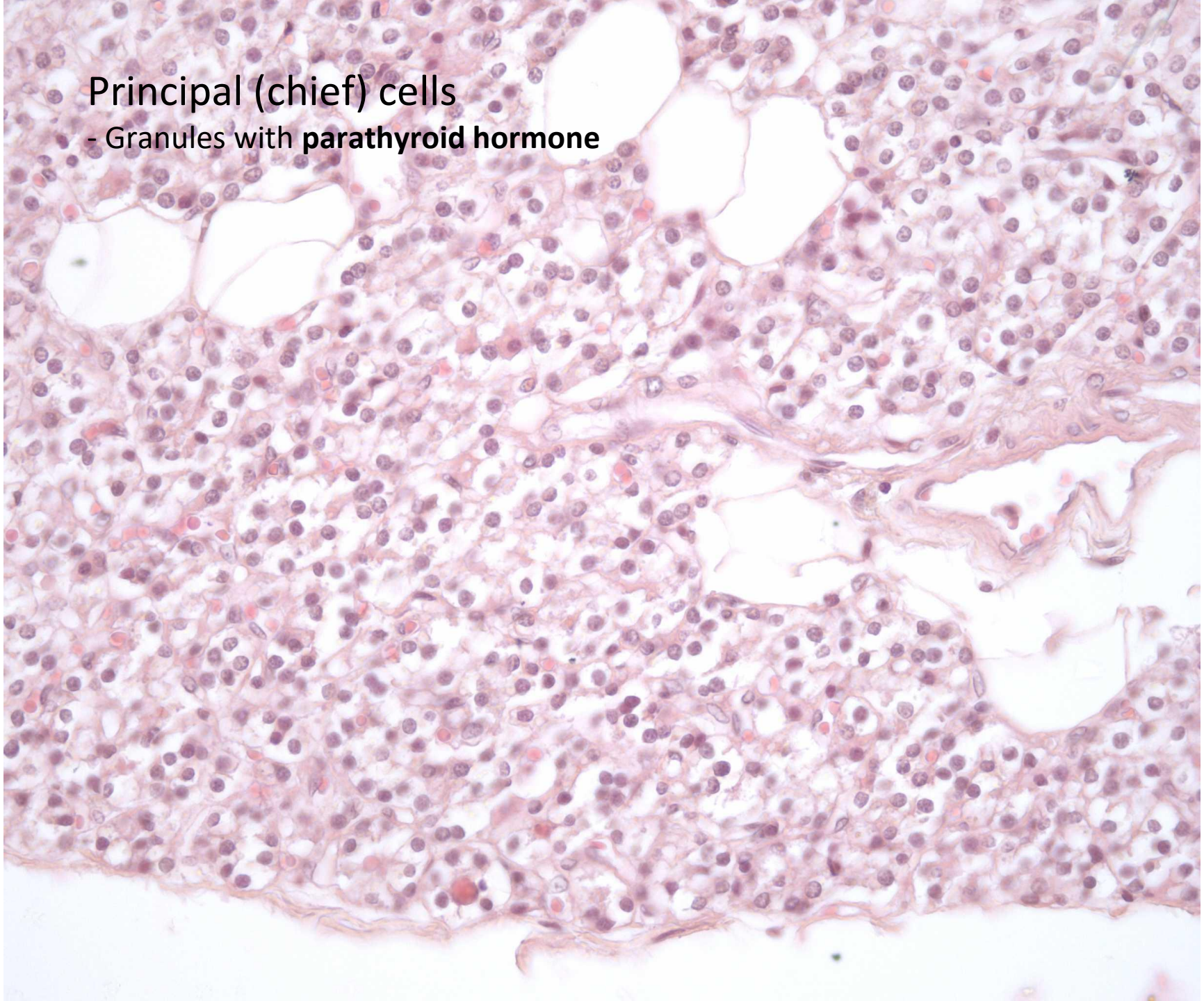
Principal (chief) cells
- Granules with **parathyroid hormone**

Regulation of PTH – Direct pathway

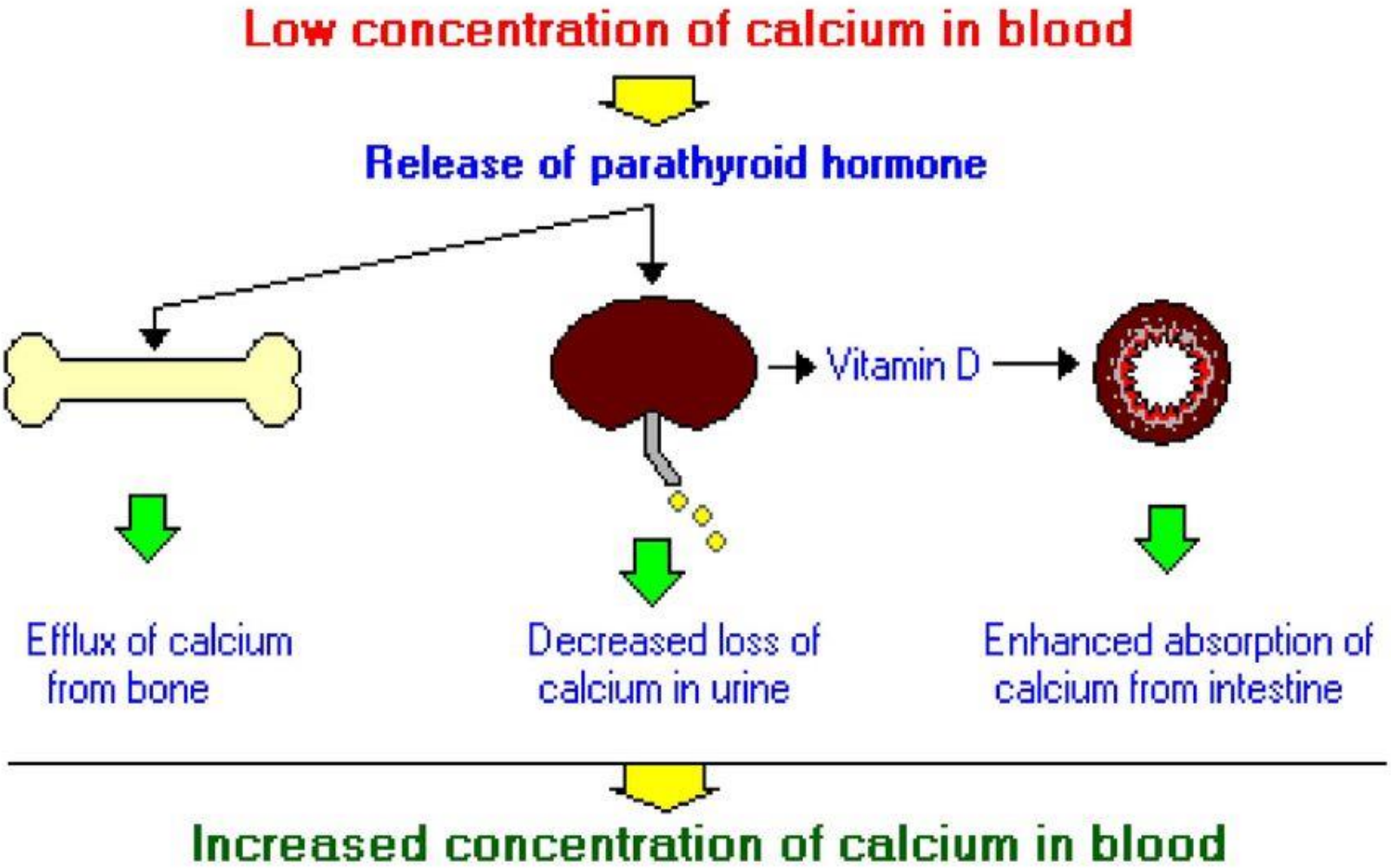

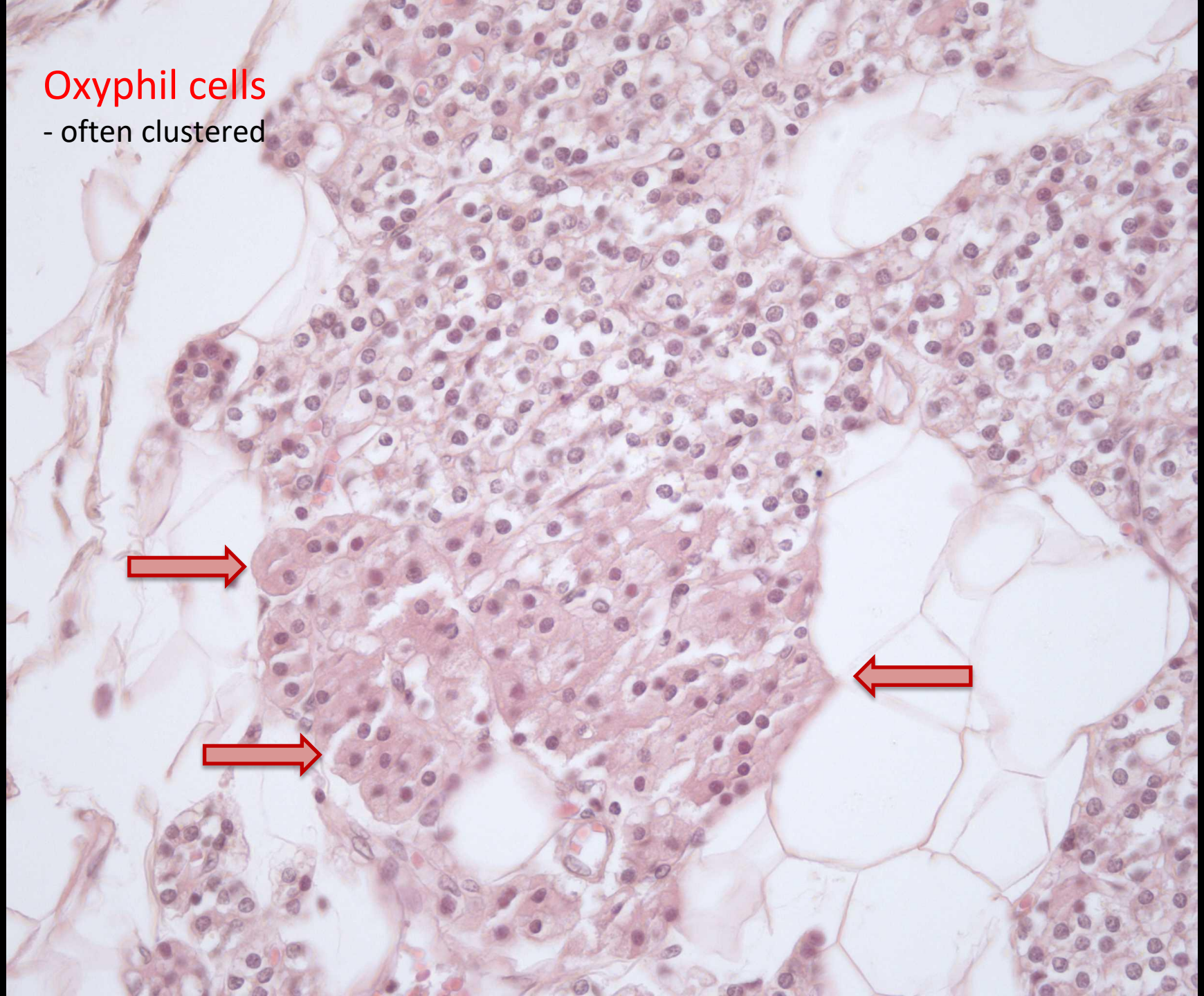
Oxyphil cells
- often clustered

C

Adrenal glands

Anatomy of the Adrenal Gland

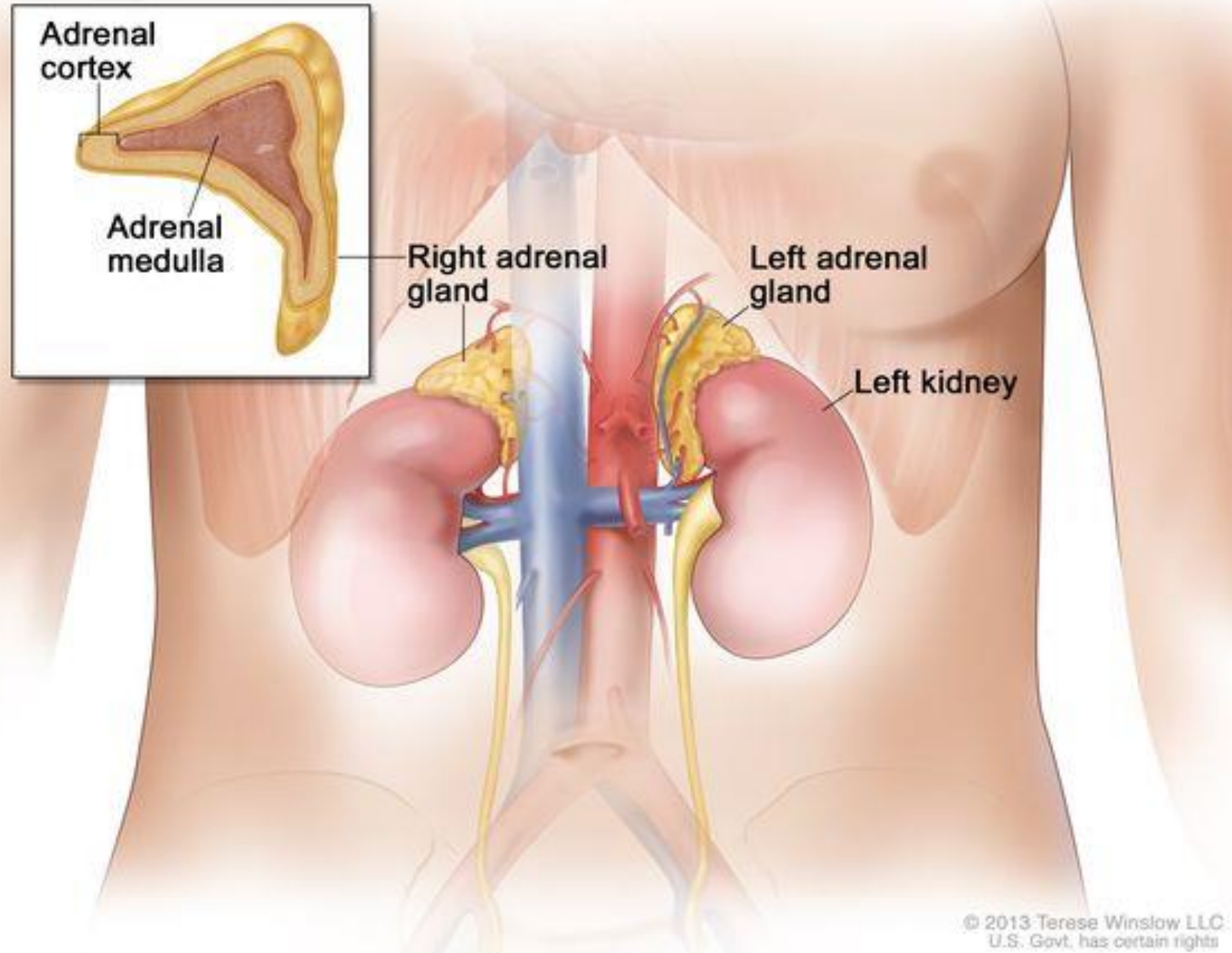

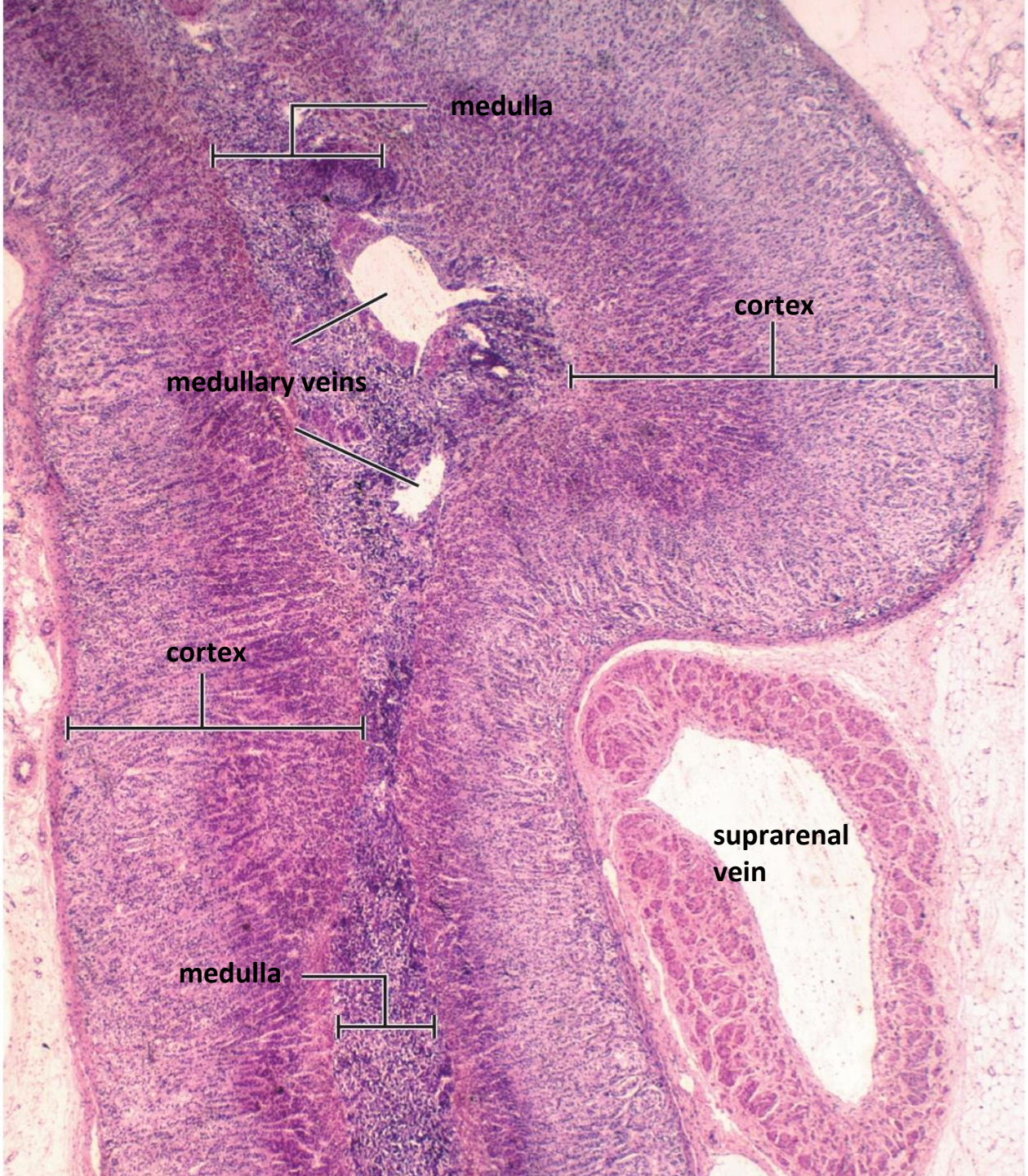
medulla
cortex
medullary veins
cortex
suprarenal
vein
medulla

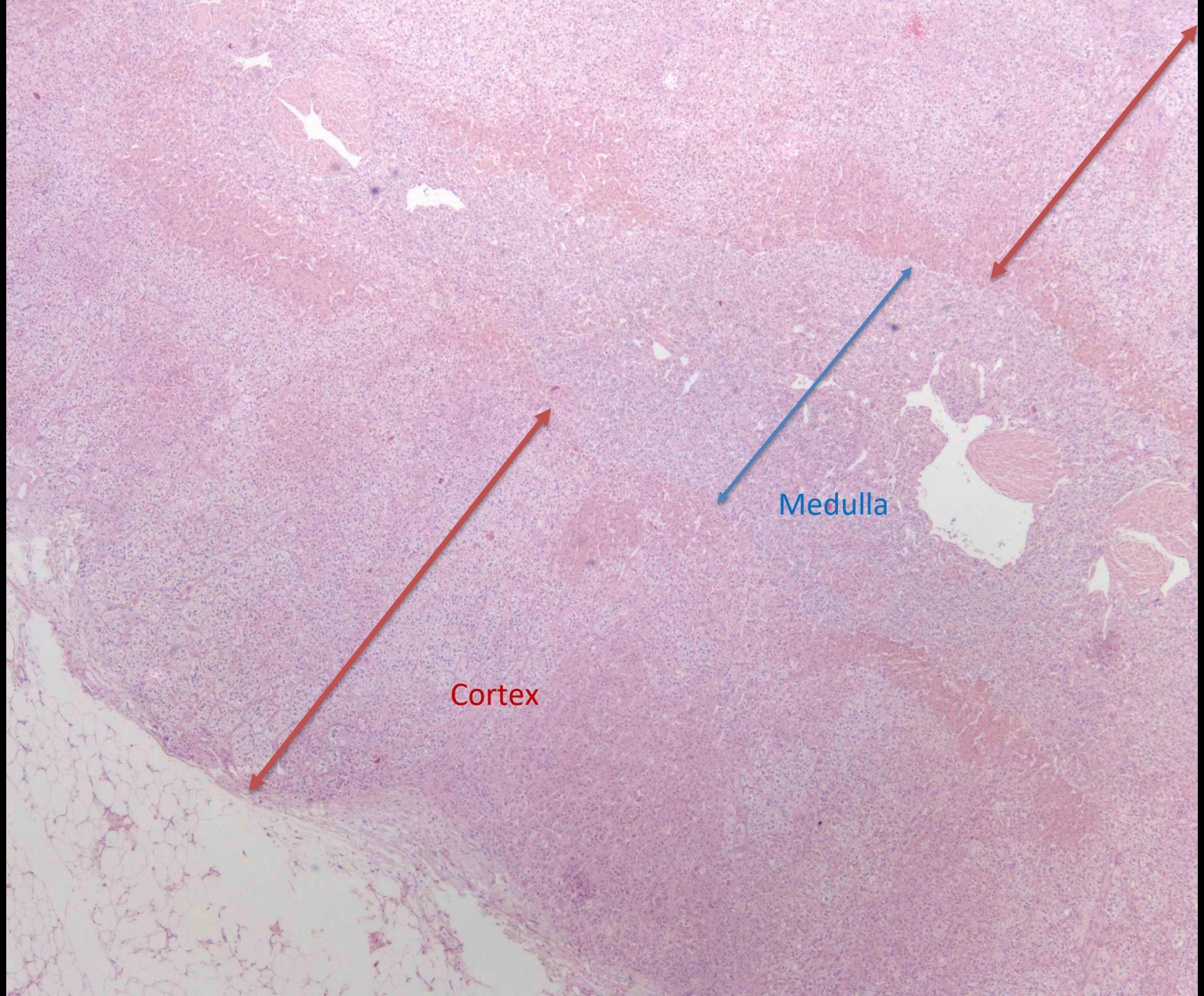
Medulla
Cortex

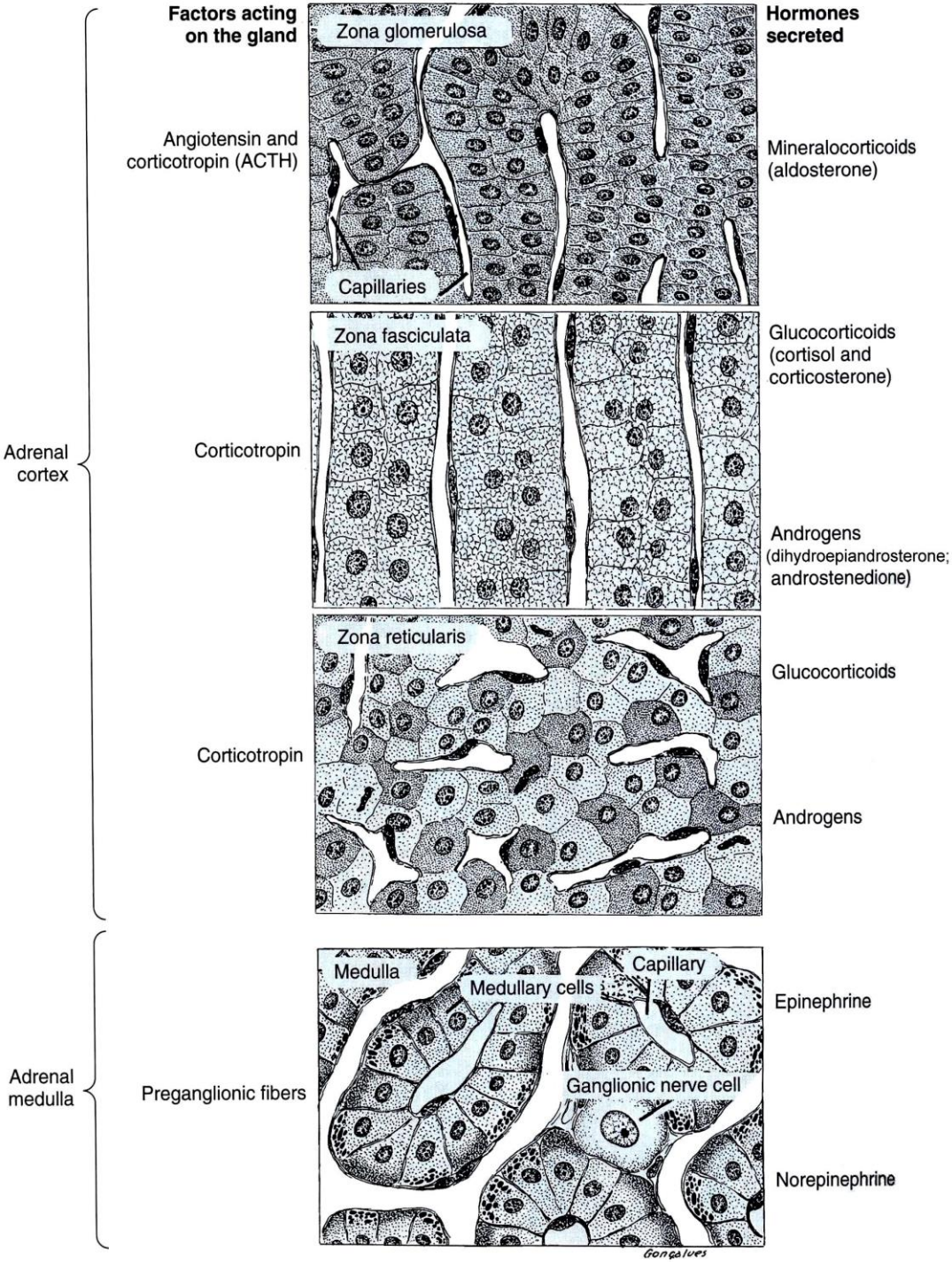
Factors acting on the gland
Hormones secreted
Zona glomerulosa
Angiotensin and corticotropin (ACTH)
Mineralocorticoids (aldosterone)
Capillaries
Zona fasciculata
Glucocorticoids (cortisol and corticosterone)
Adrenal cortex
Corticotropin
Androgens (dihydroepiandrosterone; androstenedione)
Zona reticularis
Glucocorticoids
Corticotropin
Androgens
Medulla
Capillary
Medullary cells
Epinephrine
Adrenal medulla
Preganglionic fibers
Ganglionic nerve cell
Norepinephrine
Gonçalves

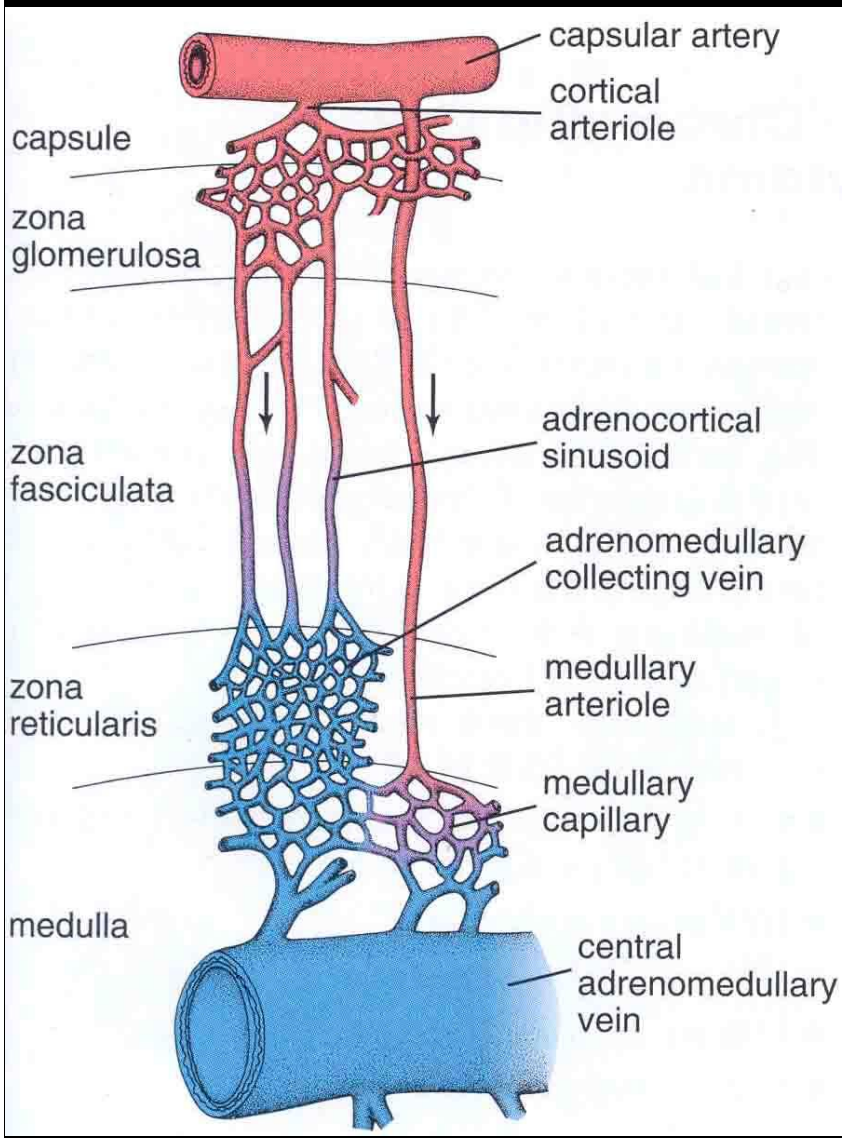
capsular artery
cortical arteriole
capsule
zona glomerulosa
zona fasciculata
adrenocortical sinusoid
adrenomedullary collecting vein
zona reticularis
medullary arteriole
medullary capillary
medulla
central adrenomedullary vein

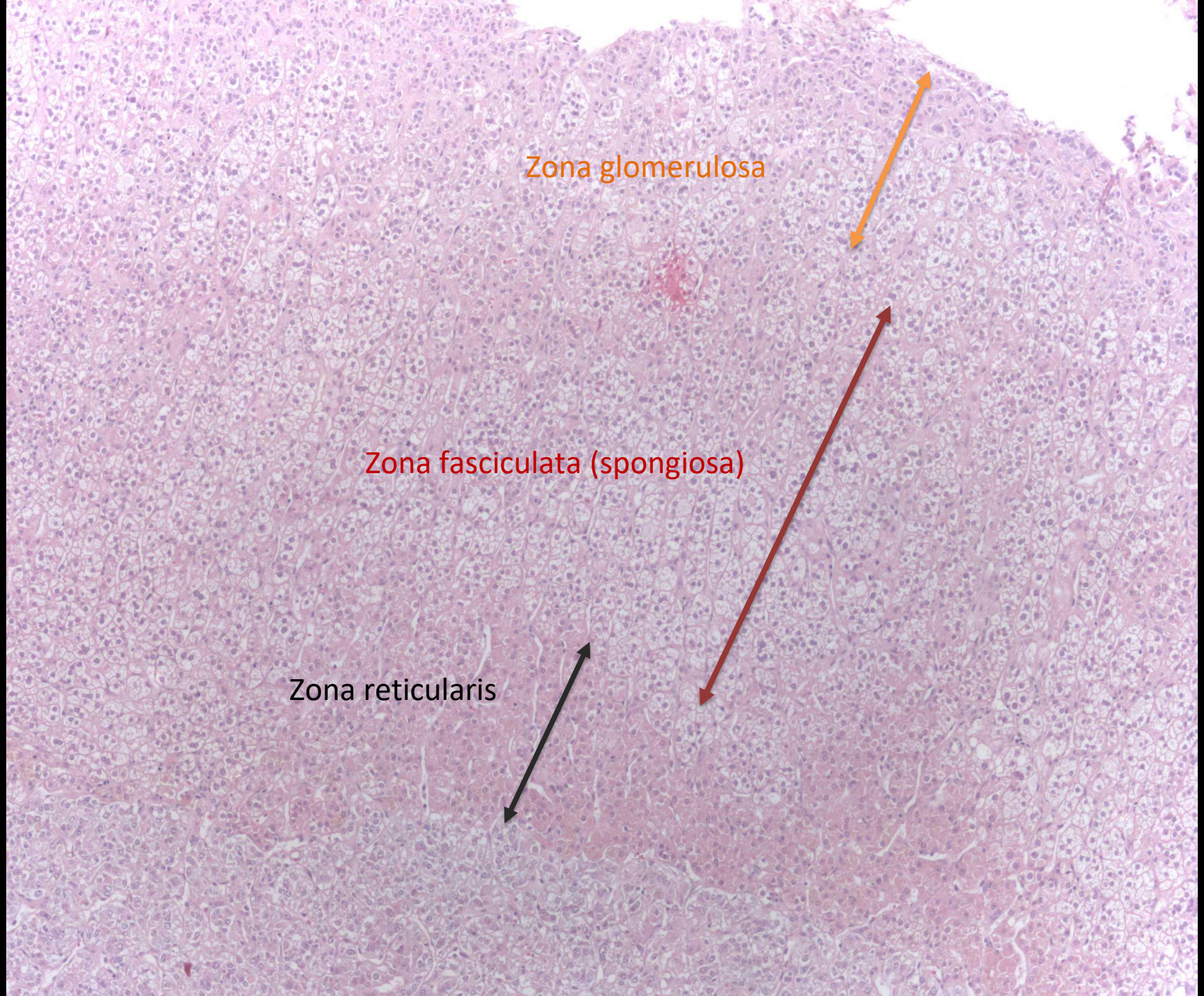
Zona glomerulosa
Zona fasciculata (spongiosa)
Zona reticularis

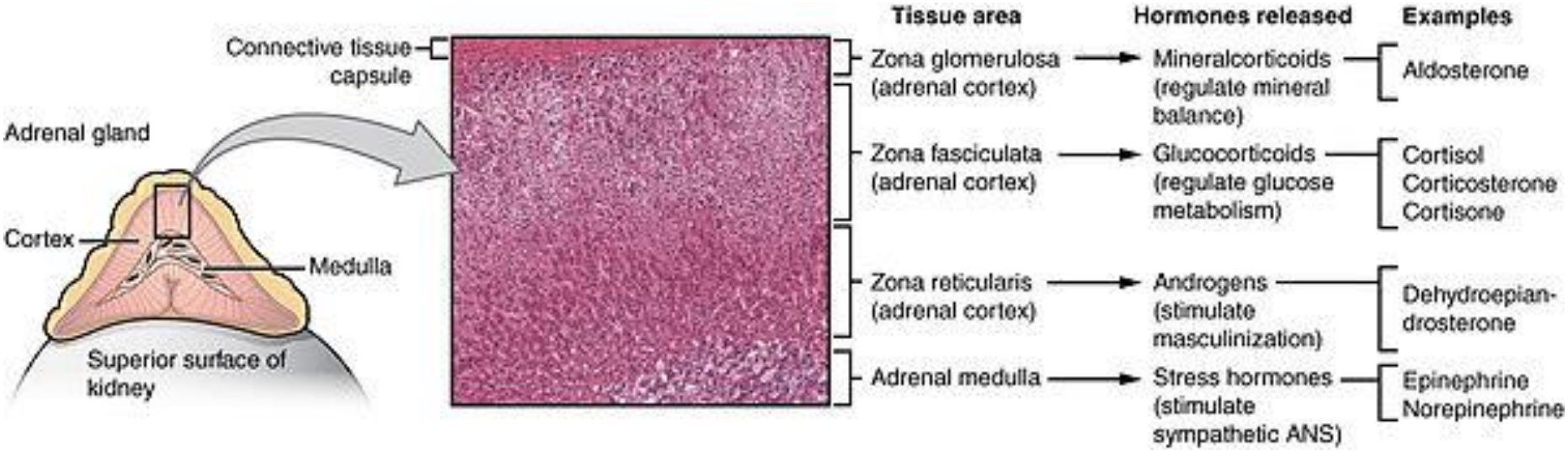
Tissue area
Hormones released
Examples
Connective tissue capsule
Adrenal gland
Cortex
Medulla
Superior surface of kidney
Zona glomerulosa (adrenal cortex)
Mineralcorticoids (regulate mineral balance)
Aldosterone
Zona fasciculata (adrenal cortex)
Glucocorticoids (regulate glucose metabolism)
Cortisol
Corticosterone
Cortisone
Zona reticularis (adrenal cortex)
Androgens (stimulate masculinization)
Dehydroepiandrosterone
Adrenal medulla
Stress hormones (stimulate sympathetic ANS)
Epinephrine
Norepinephrine

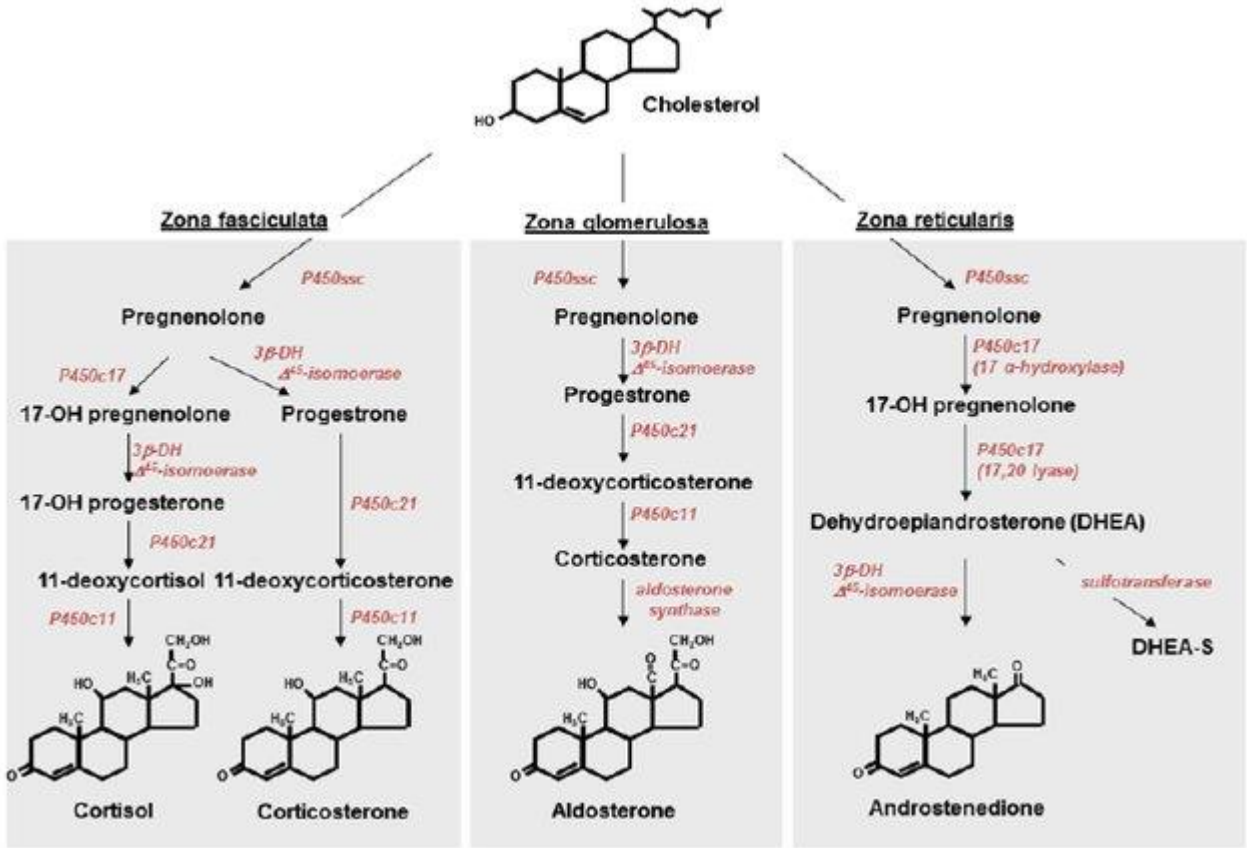
Cholesterol
Zona fasciculata
Zona glomerulosa
Zona reticularis
P450ssc
Pregnenolone
P450c17
3β-DH
Δ5-isomoerase
17-OH pregnenolone
Progestrone
3β-DH
Δ5-isomoerase
17-OH progesterone
P450c21
P450c21
11-deoxycortisol
11-deoxycorticosterone
P450c11
P450c11
Cortisol
Corticosterone
P450ssc
Pregnenolone
3β-DH
Δ5-isomoerase
Progestrone
P450c21
11-deoxycorticosterone
P450c11
Corticosterone
aldosterone synthase
Aldosterone
P450ssc
Pregnenolone
P450c17
(17 α-hydroxylase)
17-OH pregnenolone
P450c17
(17,20 lyase)
Dehydroepiandrosterone (DHEA)
3β-DH
Δ5-isomoerase
sulfotransferase
DHEA-S
Androstenedione

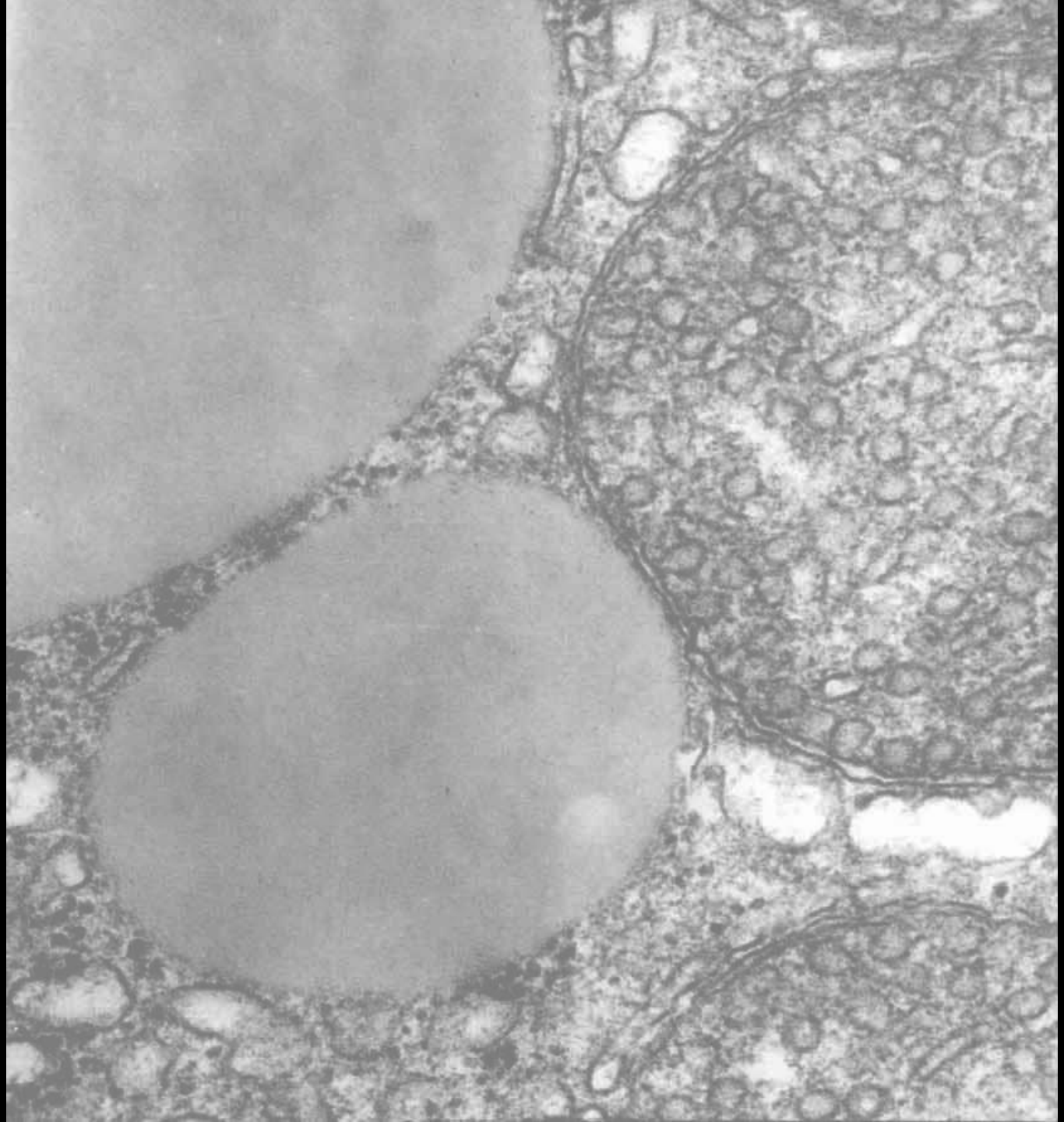

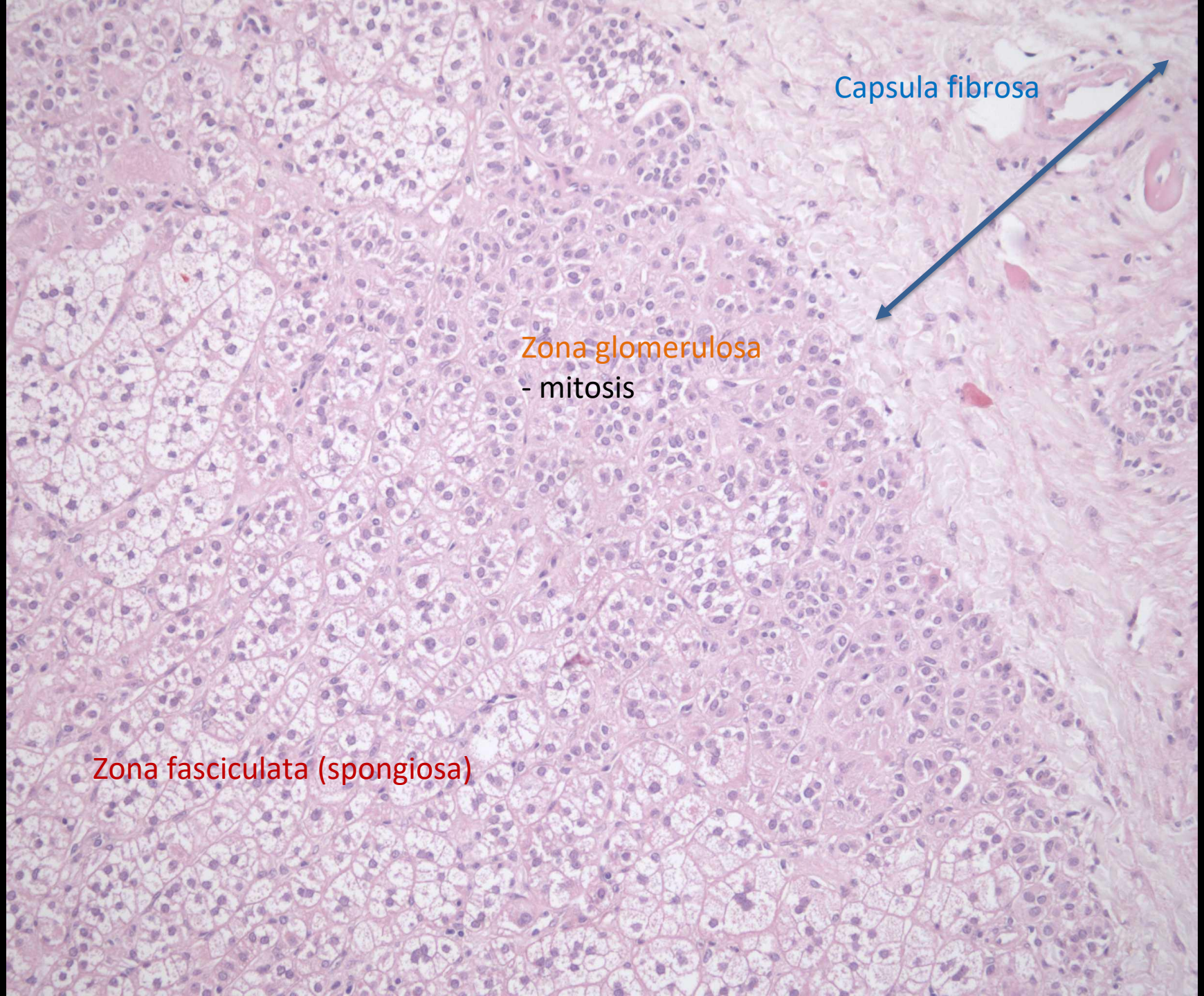
Capsula fibrosa
Zona glomerulosa
- mitosis
Zona fasciculata (spongiosa)

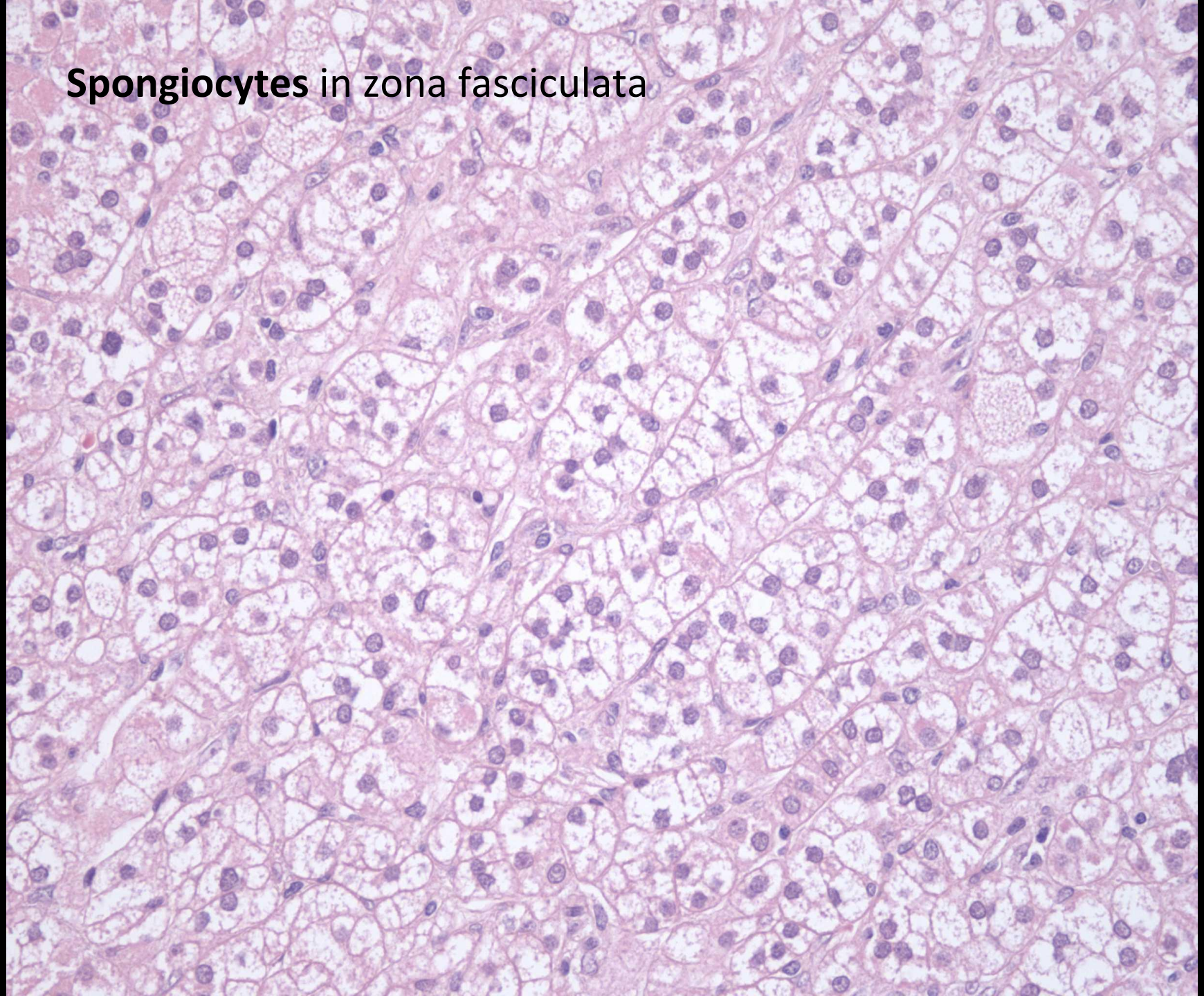
Spongiocytes in zona fasciculata

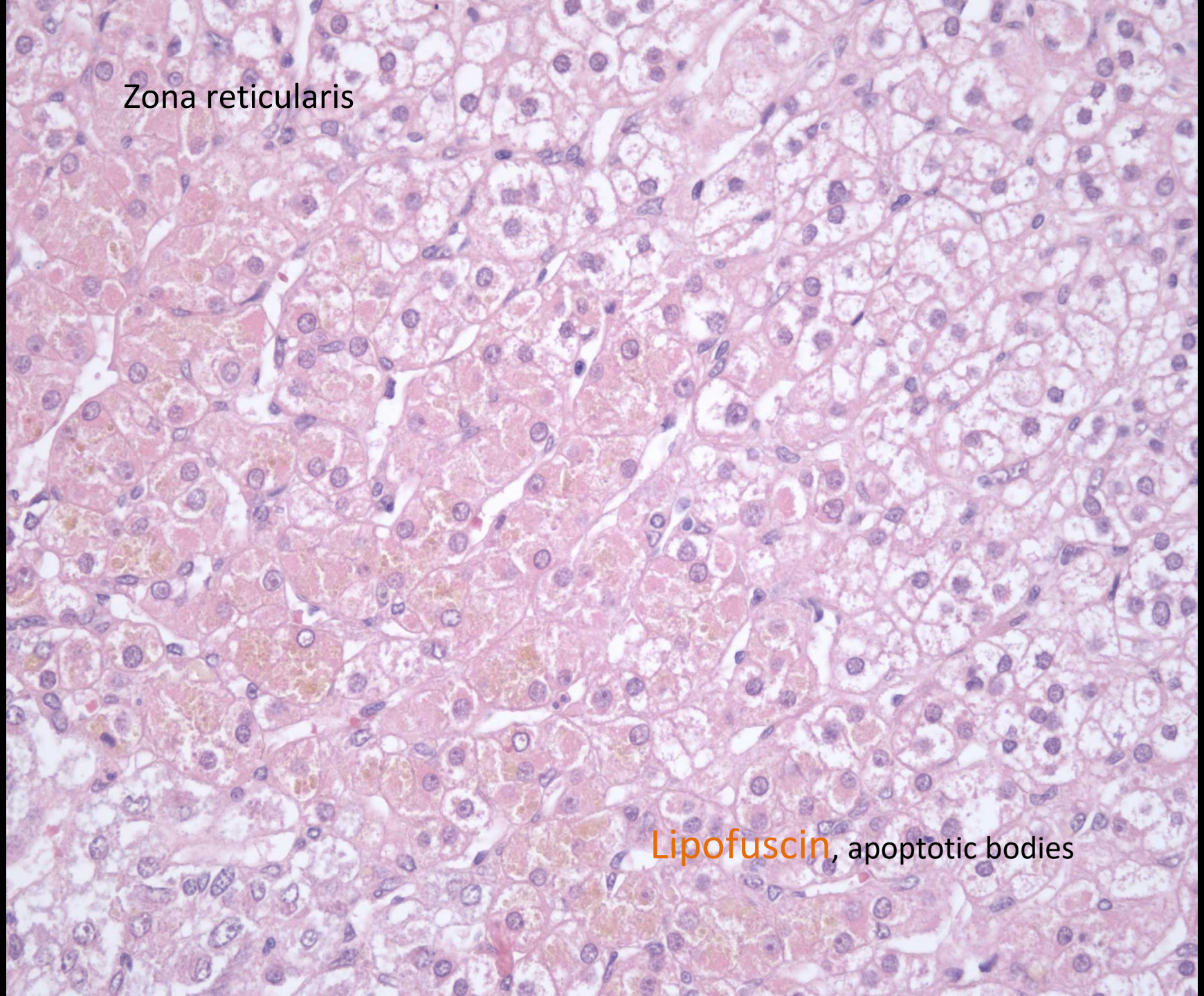
Zona reticularis
Lipofuscin, apoptotic bodies

Development of adrenal glands

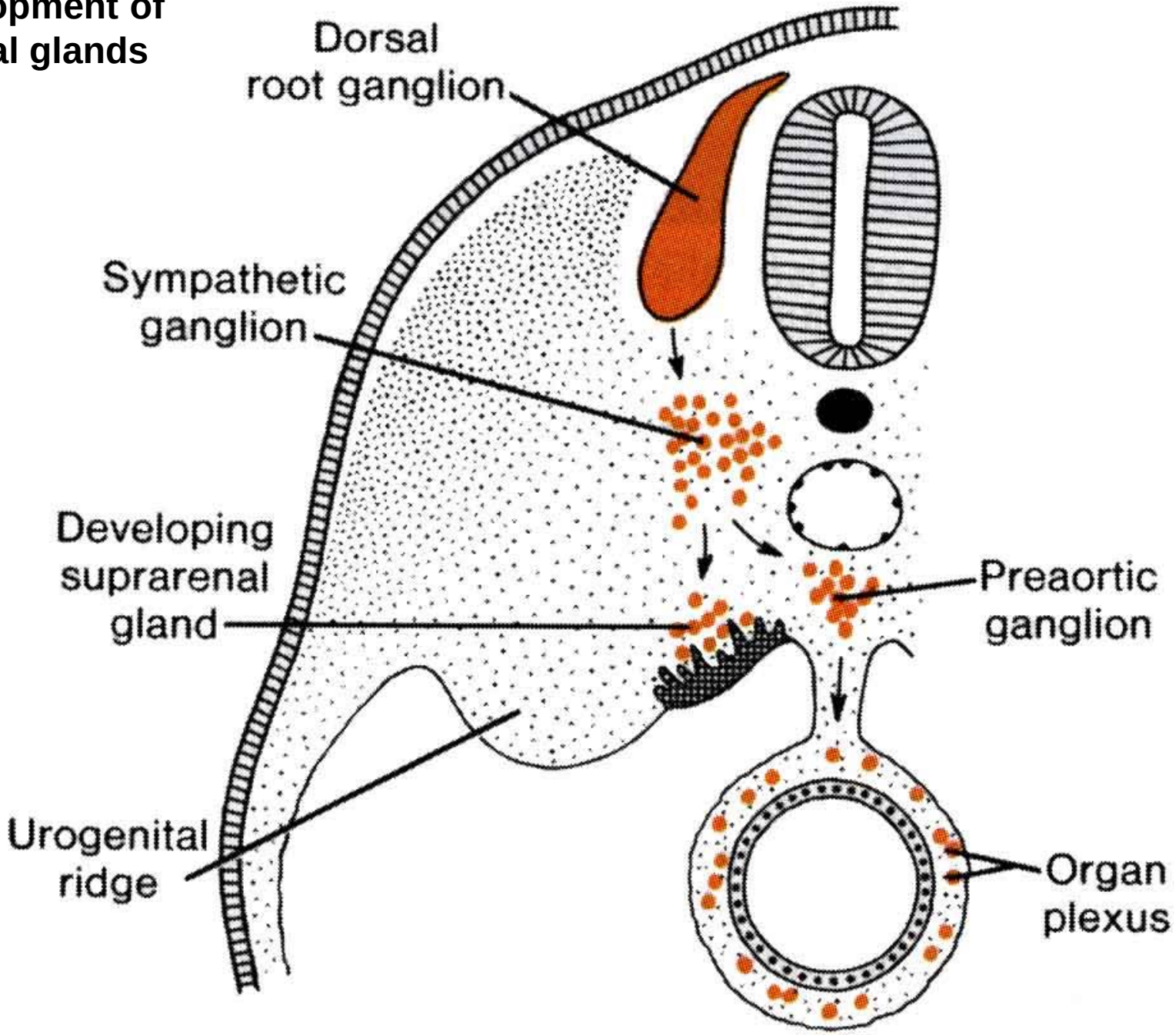

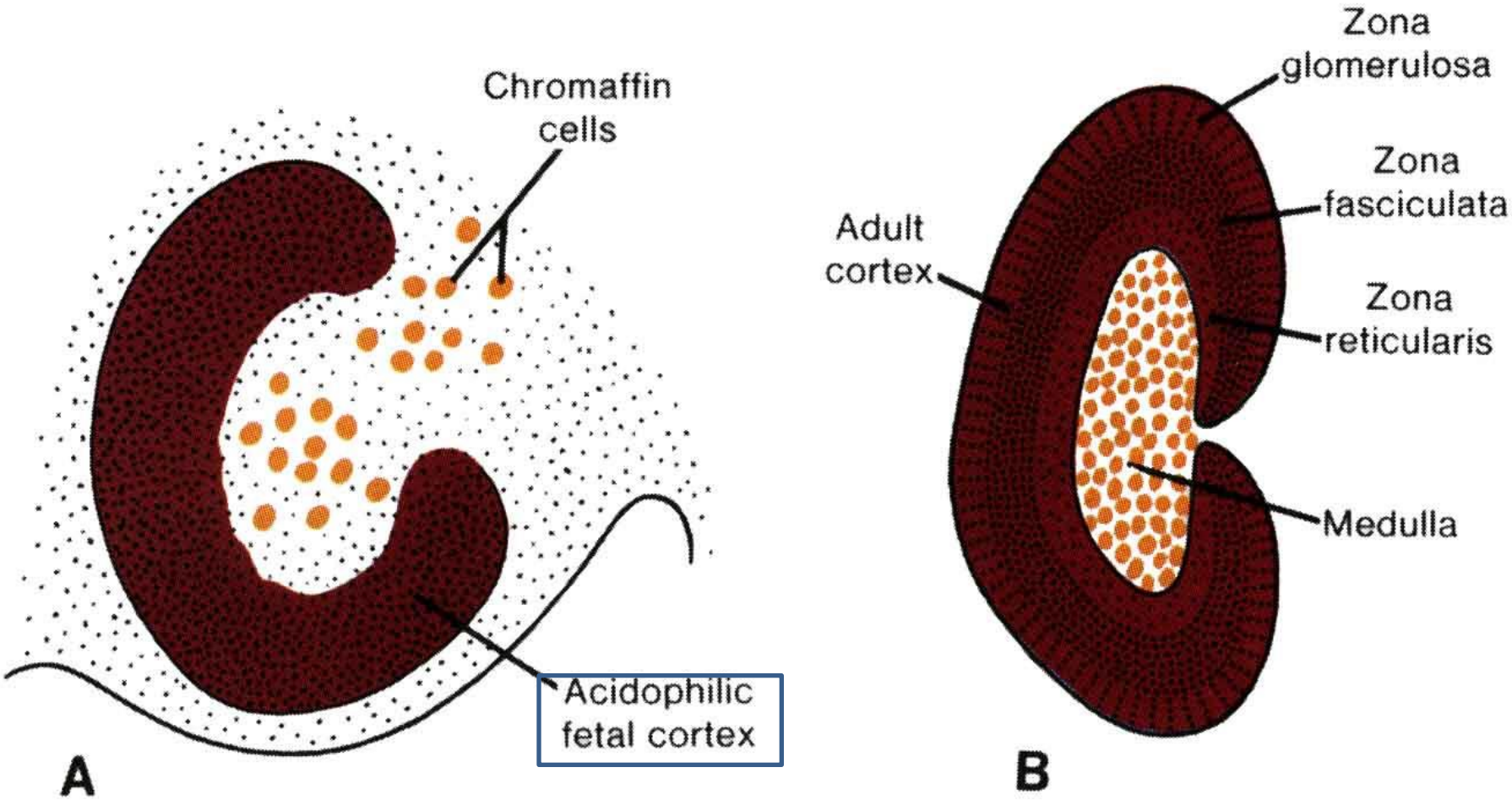
Chromaffin cells
Acidophilic fetal cortex
A
Zona glomerulosa
Zona fasciculata
Adult cortex
Zona reticularis
Medulla
B

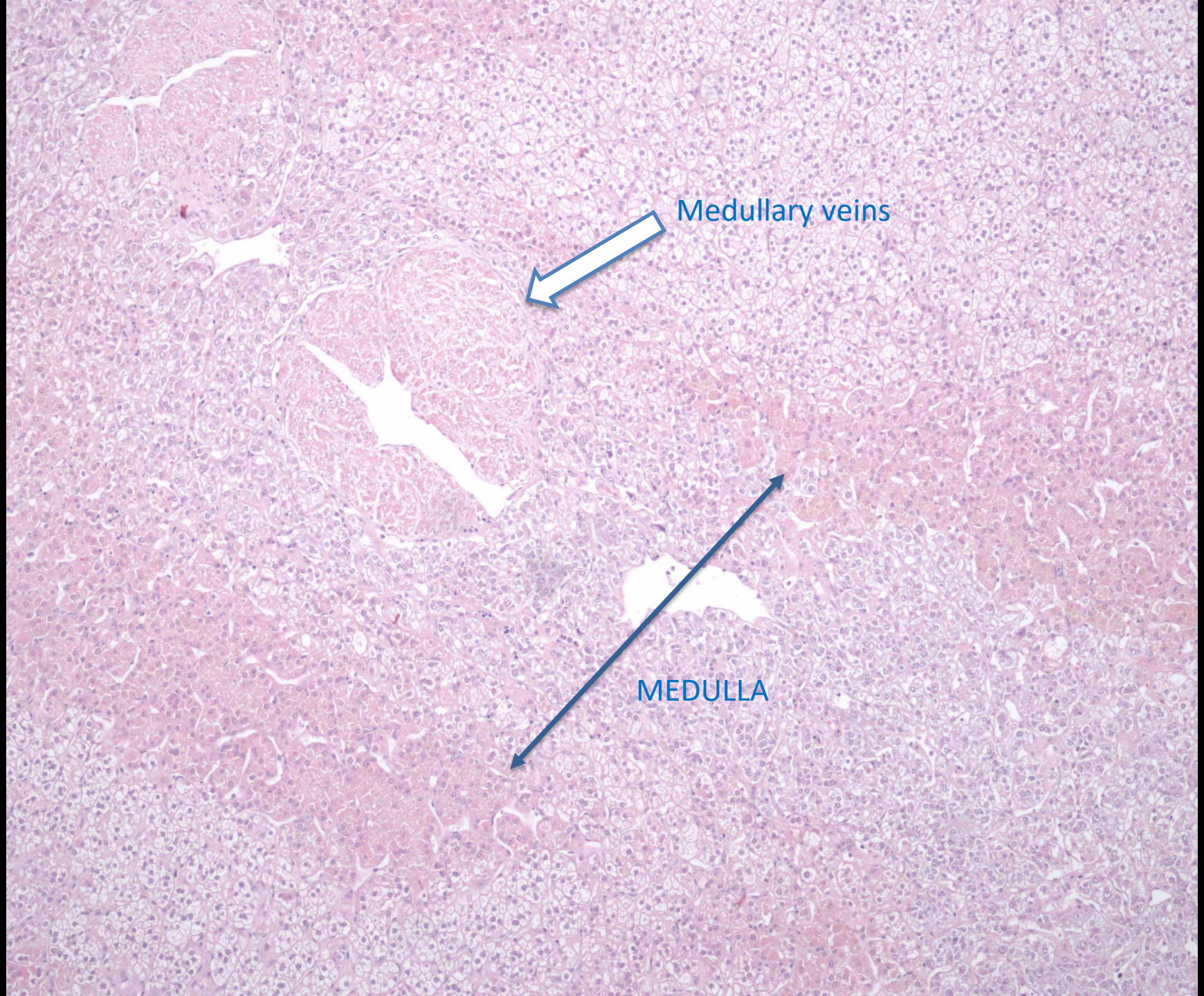
Medullary veins
MEDULLA

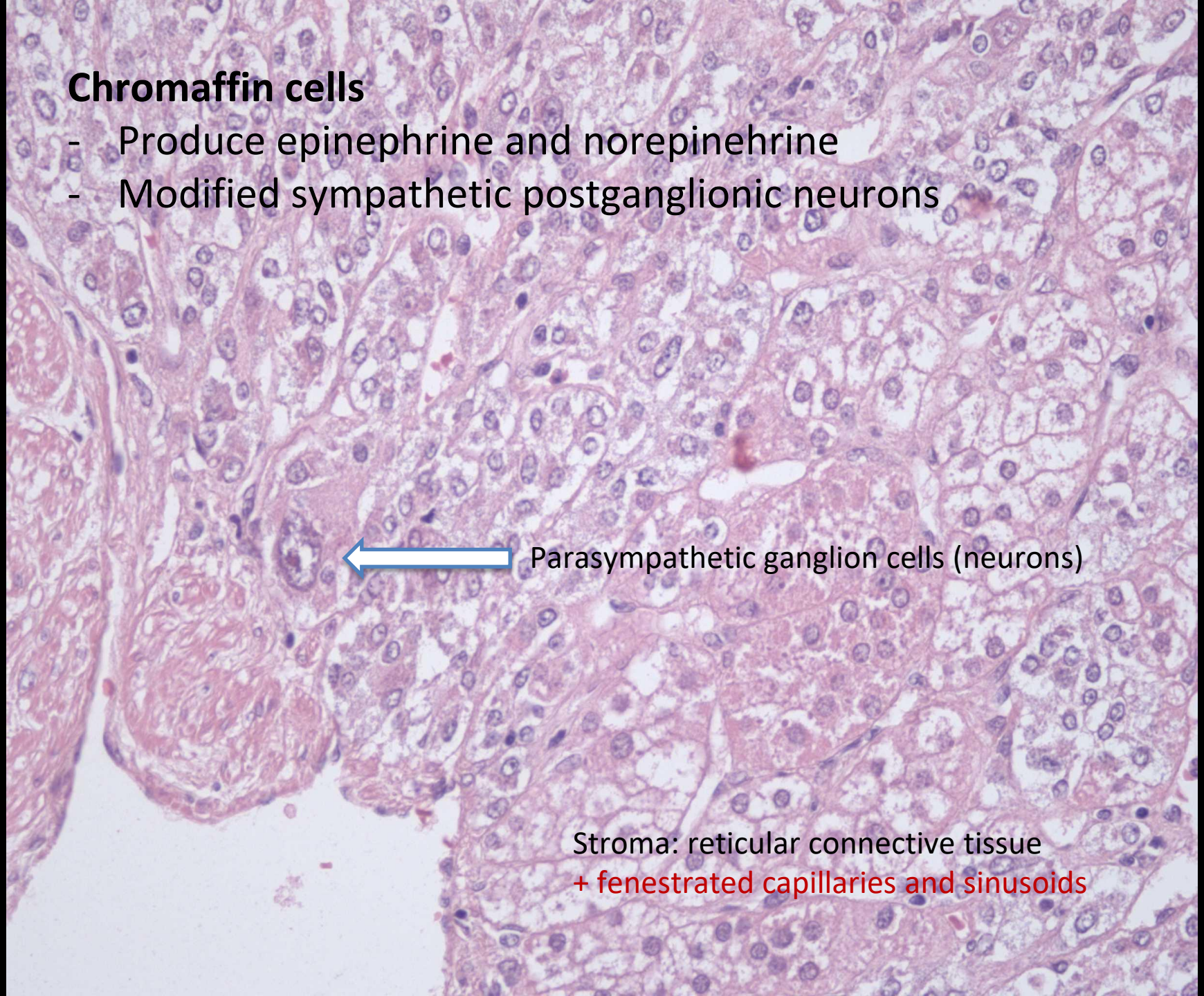
Chromaffin cells
- Produce epinephrine and norepinehrine
- Modified sympathetic postganglionic neurons
Parasympathetic ganglion cells (neurons)
Stroma: reticular connective tissue
+ fenestrated capillaries and sinusoids

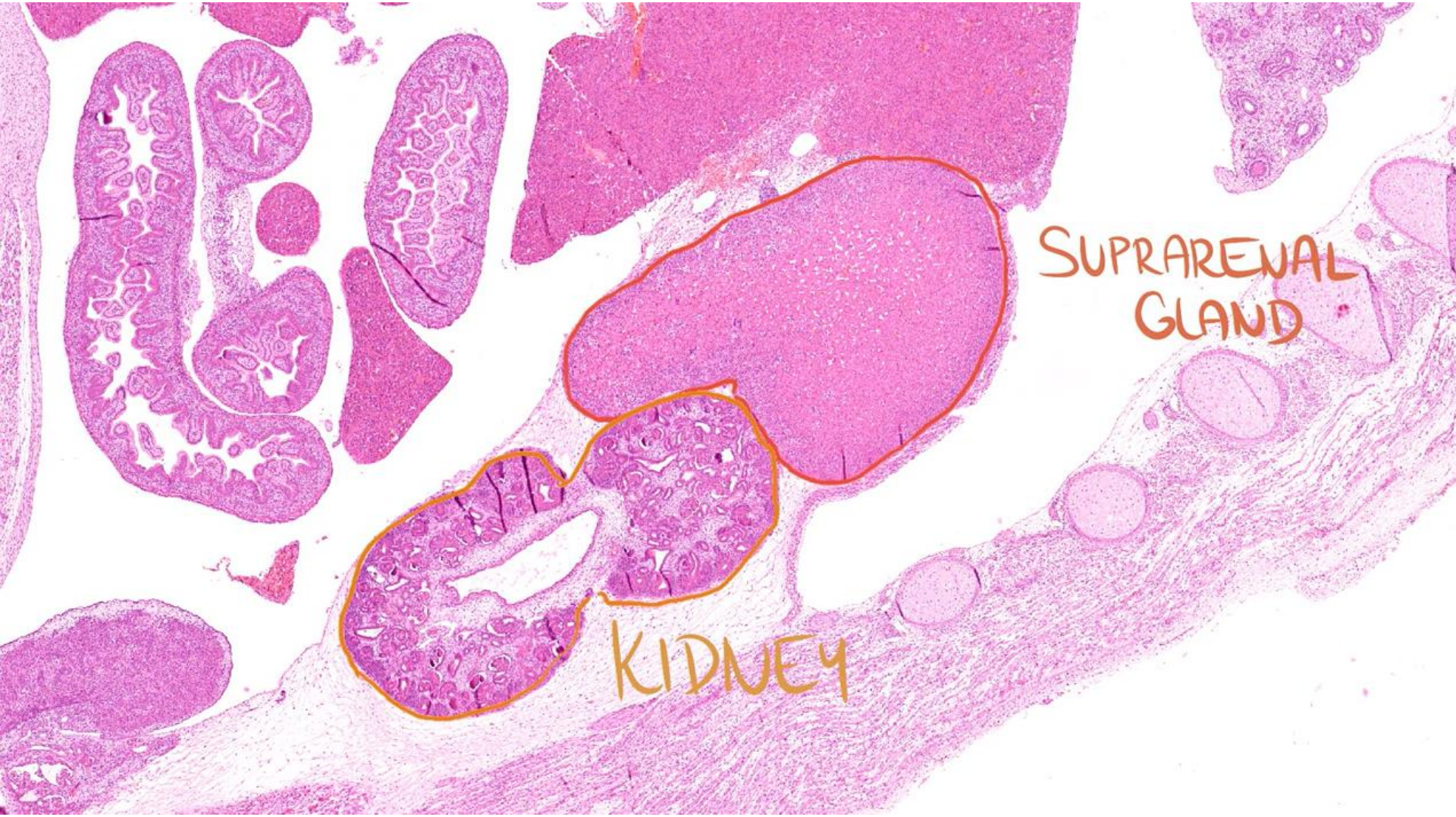
SUPRARENAL
GLAND
KIDNEY


SUPRARENAL GLAND
EOSINOPHILIC CELLS
PRIMITIVE CORTEX
SURROUNDED BY
SECONDARY CORTEX
(DEFINITIVE)

SYMPTOMS
of Cushing's syndrome

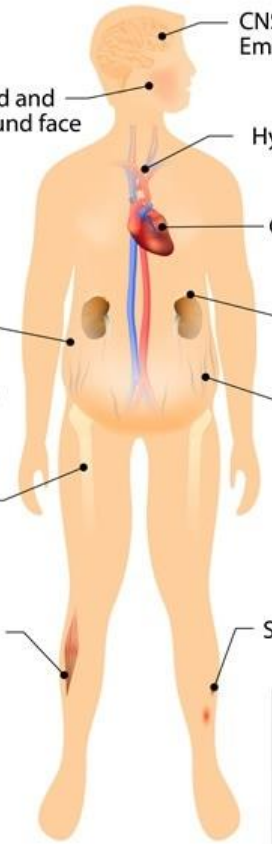

CNS irritability
Emotional disturbances

Red and round face

Hypertension

Cardiac hypertrophy

Obesity (fat deposition on abdomen and back of neck)

Hyperplasia, tumor

Purple striae

Osteoporosis

Muscle wasting

Skin ulcers

In females:
- amenorrhea, hirsutism

In males:
- erectile dysfunction

Addison's disease

Adrenal glands not produce sufficient steroid hormones

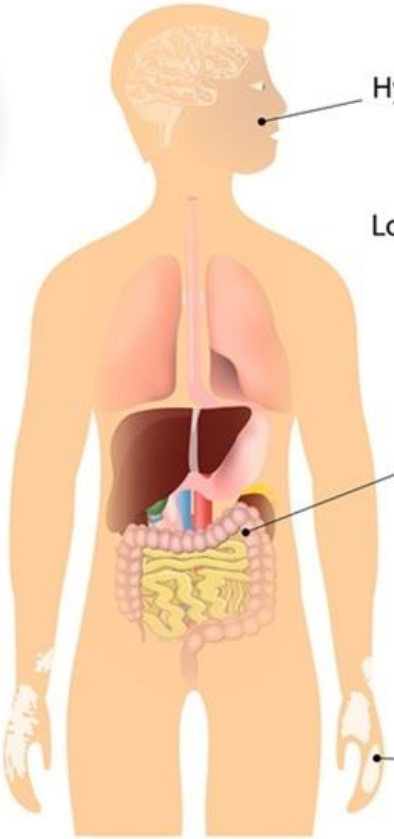

Skin
Hyperpigmentation

Low blood pressure
Weakness
Weight loss

Gastrointestinal
Nausea
Diarrhea
Vomiting
Constipation
Abdominal pain

Skin
Vitiligo

Adrenal crisis:
- fever;
- syncope;
- convulsions;
- hypoglycemia;
- hyponatremia;
- severe vomiting and diarrhea.

Happy Friday