SECOND FACULTY OF MEDICINE
CHARLES UNIVERSITY

Endokrinní systém

MUDr. Dalibor Dráb

Ústav histologie a embryologie, 2.lékařská fakulta UK, Praha

Klinika anesteziologie, resuscitace a intenzivní péče, IKEM, Praha

QR kód hand-outu:

- V přednášce zazní informace, které si máte doplnit do hand-outu.
- Hand-out můžete použít jako základní podklad ke studiu endokrinního systému a postupně nabalovat informace získané z učebnic.

What are we up to today?

- 1. Obecný úvod k hormonům a signalizaci
- 2. Hypothalamicko-hypofyzární osa
- 3. Šišinka
- 4. Štítná žláza a přištítná tělíska
- 5. Nadledviny
- 6. Langerhansovy ostrůvky

- Zásady přednášky:
- A) ptejte se průběžně, protože jinak to zapomenete
- B) pamatujte si hlavně základní věci – budu se vám snažit je vysvětlit co nejlíp ☺
- C) pokud vám bude něco chybět v hand-outu, řekneme si to na konci přednášky

Žlázy s vnitřním vyměšováním
Glandulae endocrinae

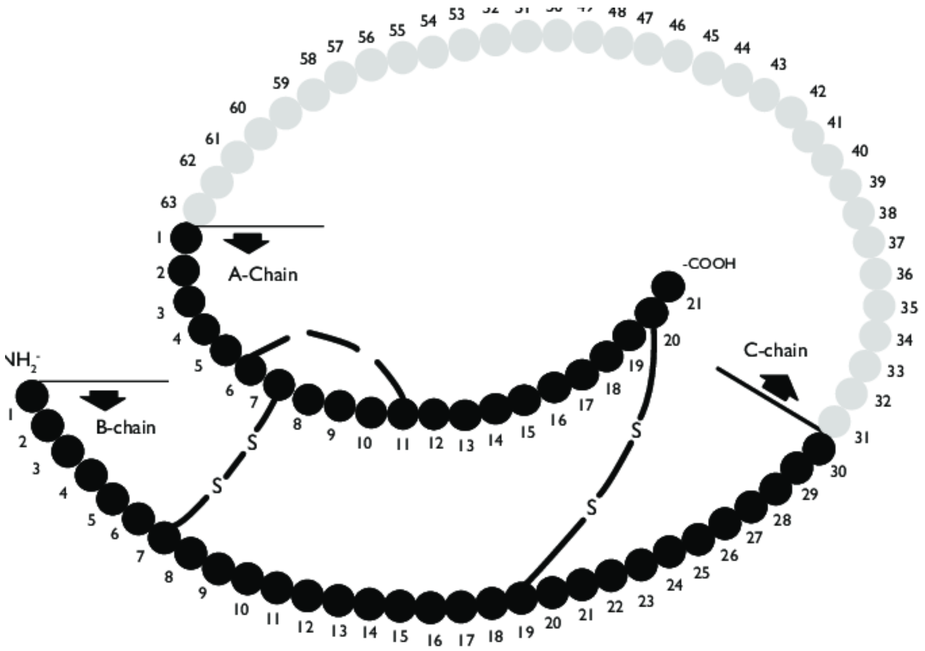

- jeden z regulačních systémů
- **hormon** (ř. hormao –pobízet, rozběhnout)
  - chemický posel tvořený žlázou s vnitřním vyměšováním a přenášený krví k cílovým orgánům

  - **proteiny** (polypeptid) – inzulín
  - **biogenní aminy** – adrenalin
  - **steroidy** – estrogeny

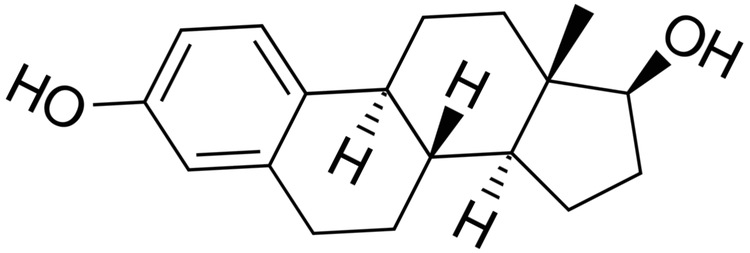

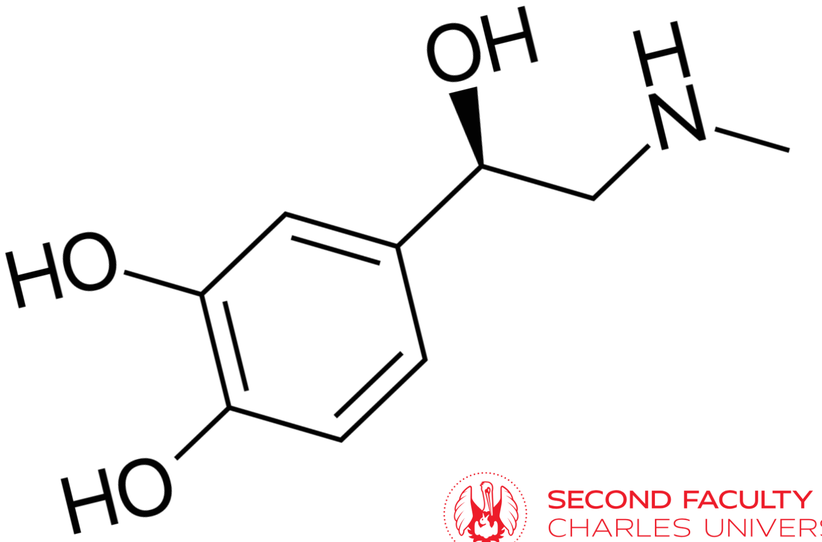

Hormonální signalizace

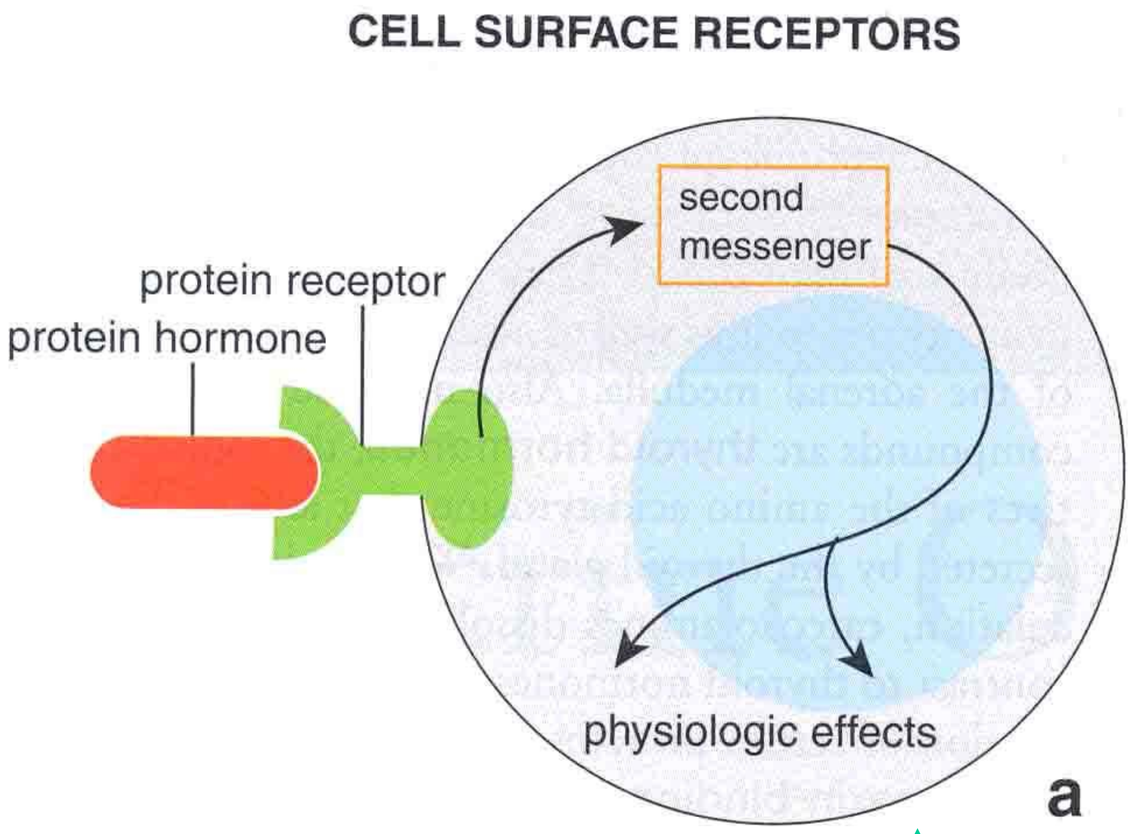

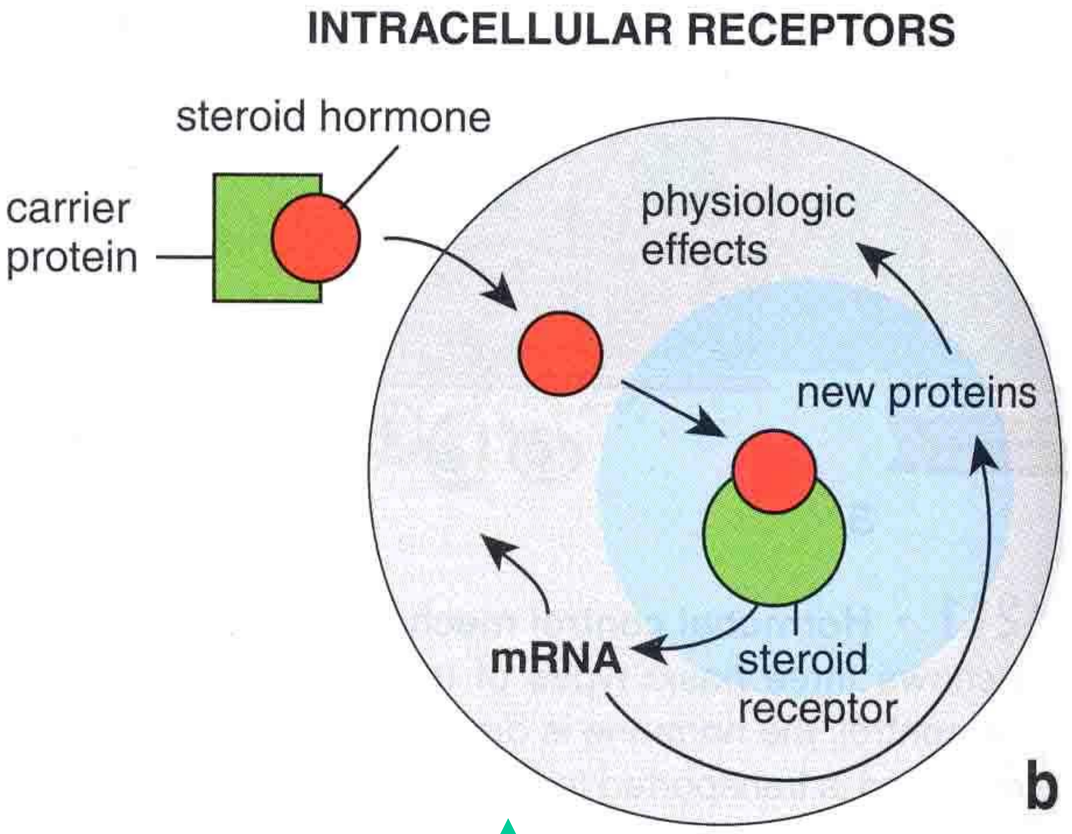

peptidy a proteiny
biogenní aminy

steroidy
a další malé
hydrofóbní molekuly [thyroidea]

Působení hormonu na cílovou strukturu (orgán, buňku)

autokrinní sekrece

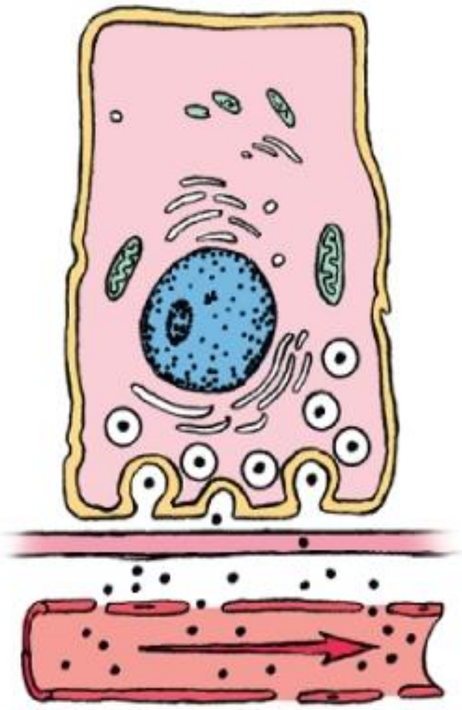

endokrinní sekrece

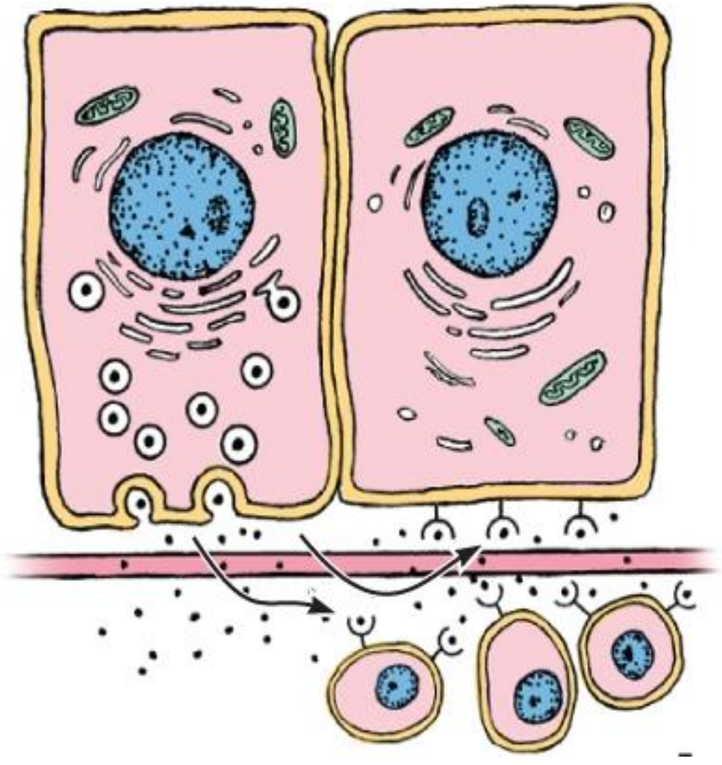

parakrinní sekrece

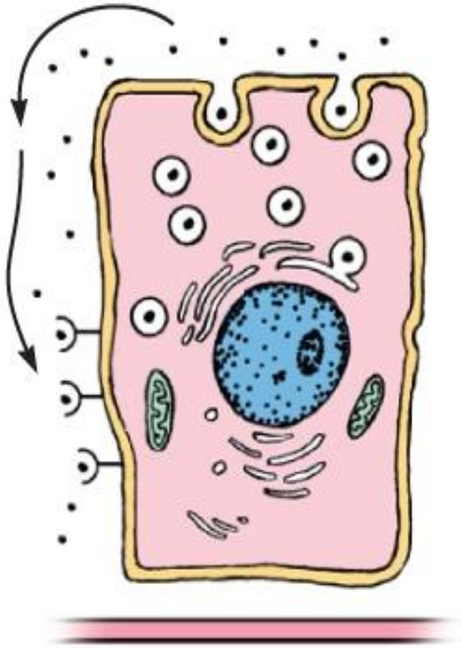

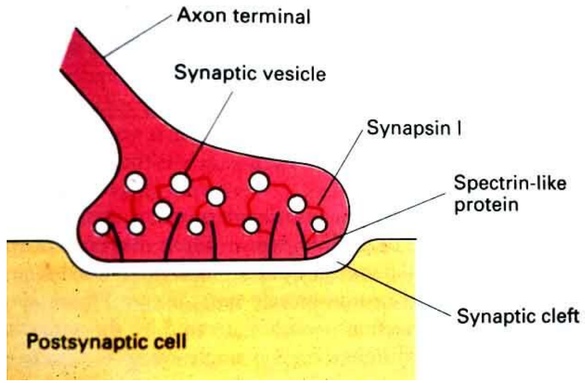

synaptická sekrece

Žlázy s vnitřním vyměšováním

- žlázy

- roztroušené (diseminované) buňky

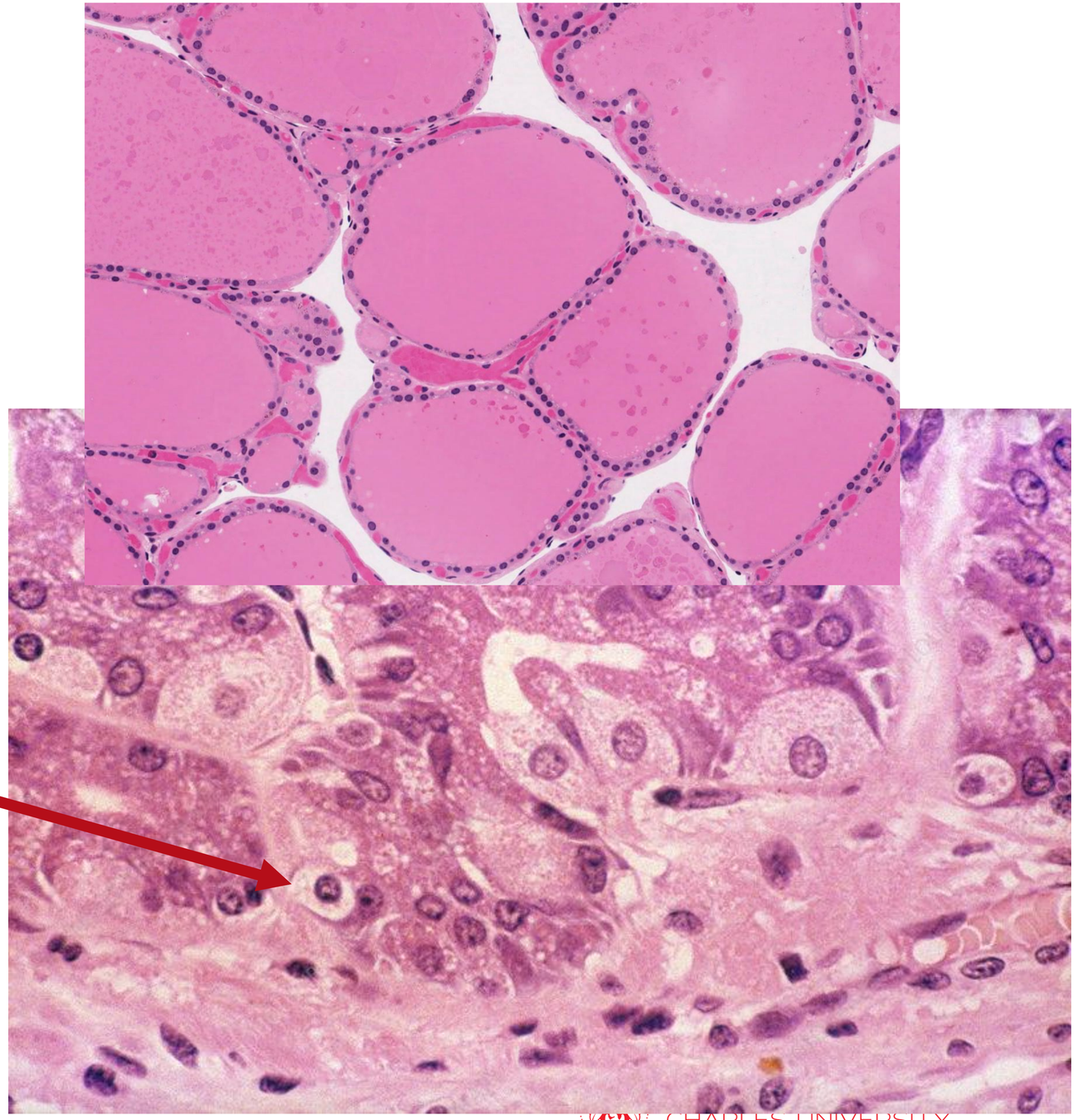

Endokrinní žlázy

- **hypothalamus** + **hypofýza** (adenohypofýza + neurohypofýza)
- **šišinka** (corpus pineale, epifýza)
- **štítná žláza**
- **příštítné žlázy**
- **nadledviny** (kůra a dřeň)
- **Langerhansovy ostrůvky** pankreatu

- endokrinní buňky v srdci, ledvinách, gonádách, placentě
- buňky DNES (epitel trávicího a dýchacího systému)
- endotelové buňky, hepatocyty

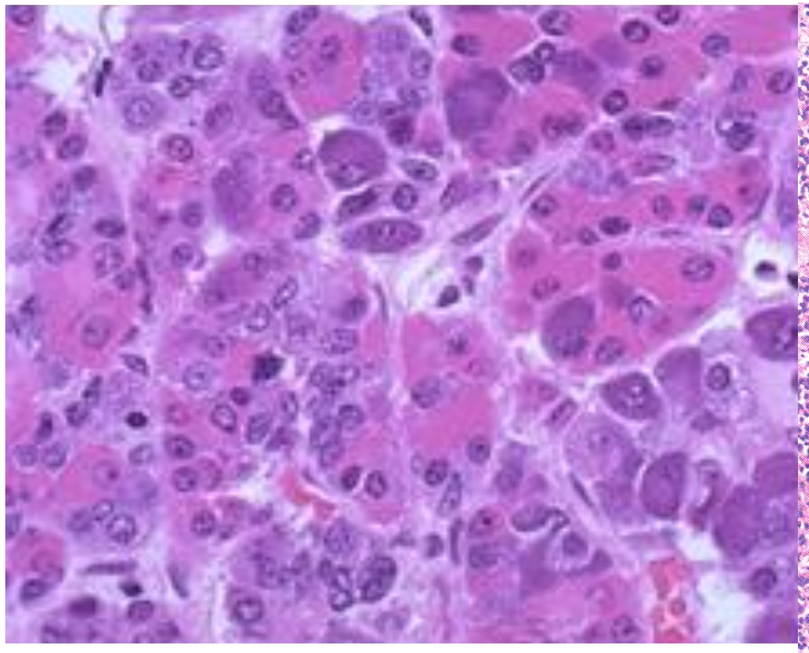

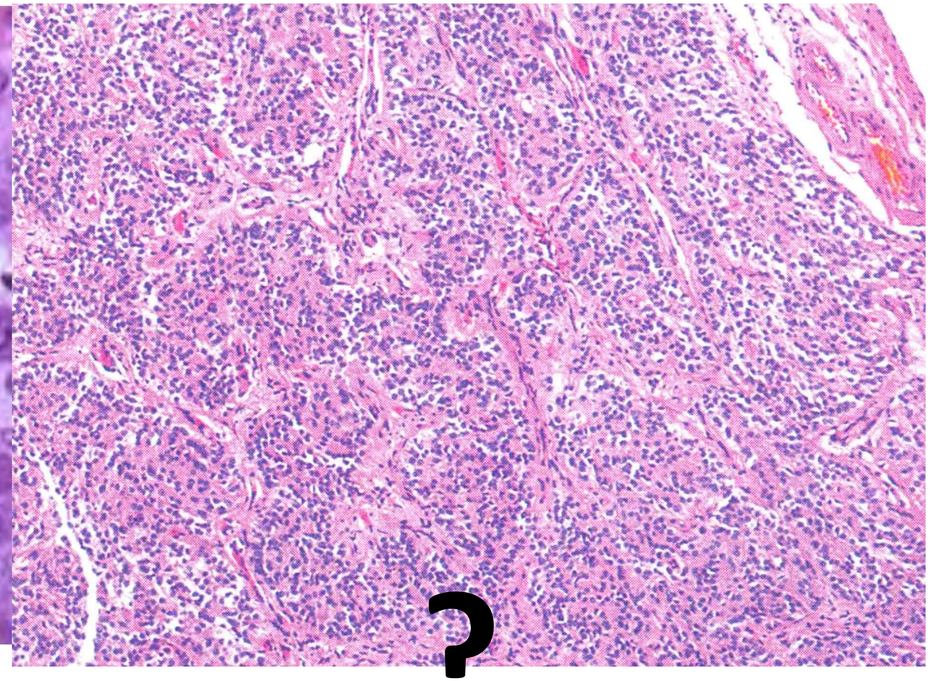

?

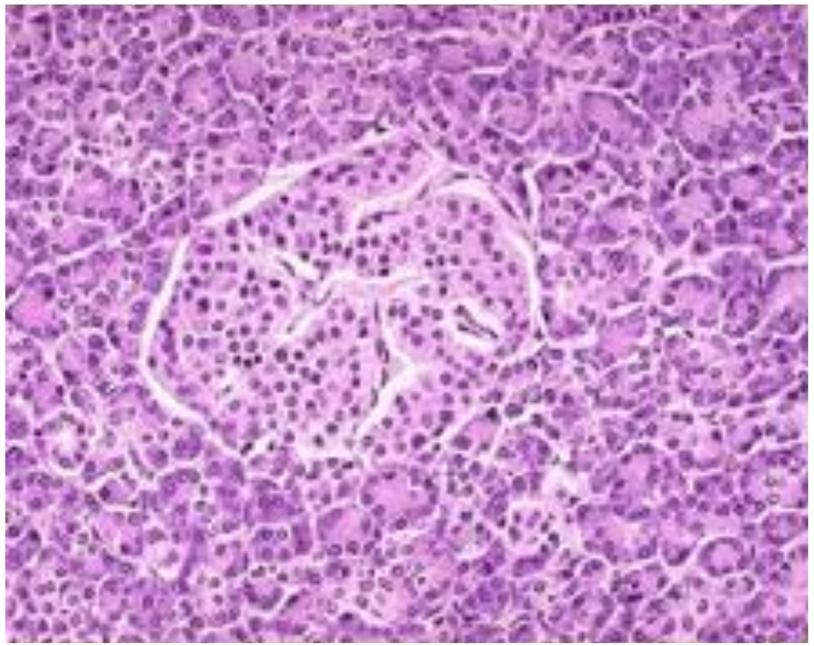

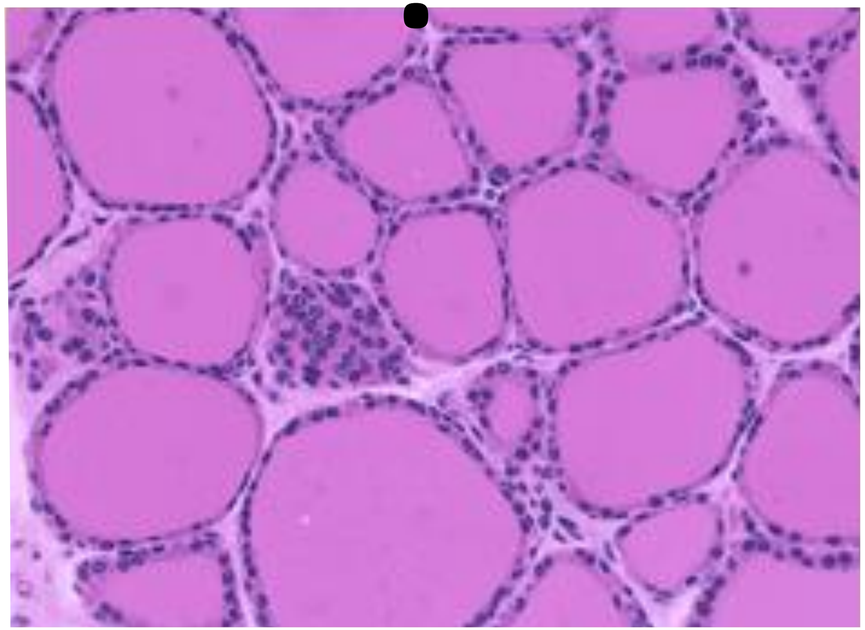

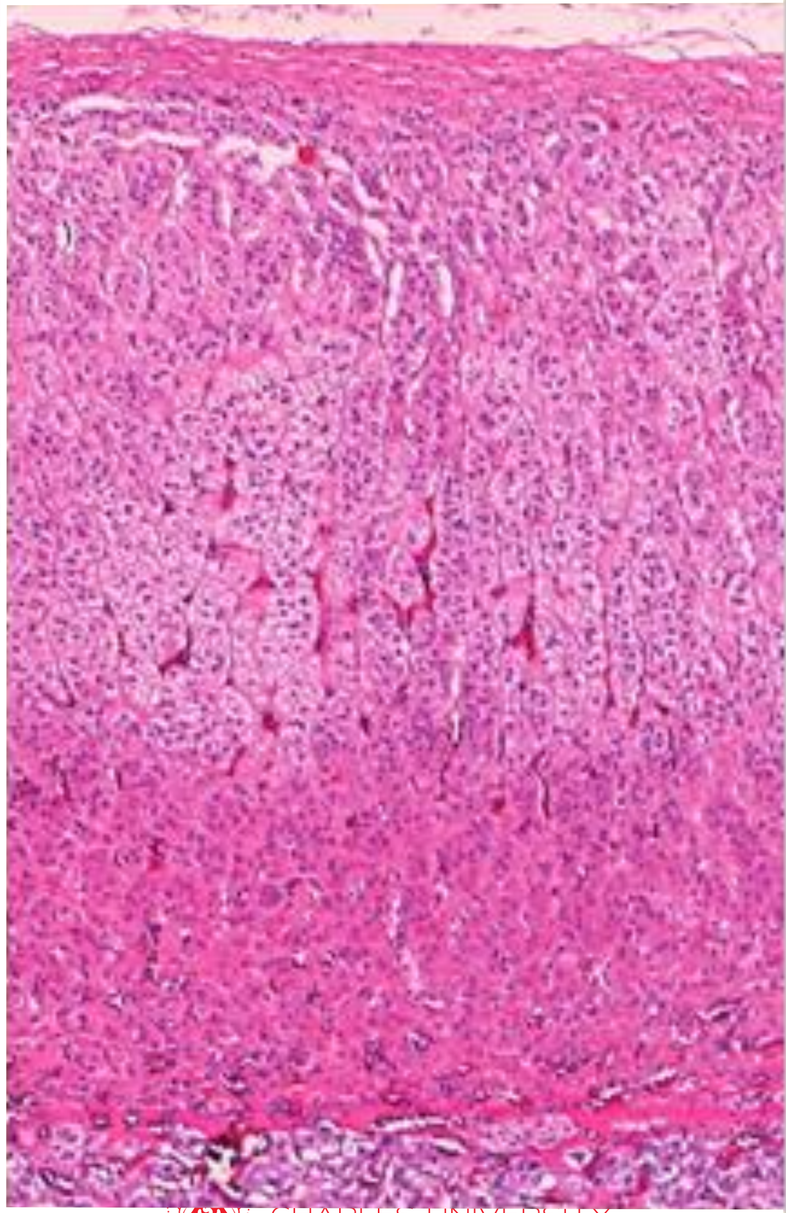

CHARLES UNIVERSITY

Obecné stavební schéma

- **stroma** – retikulární vazivo

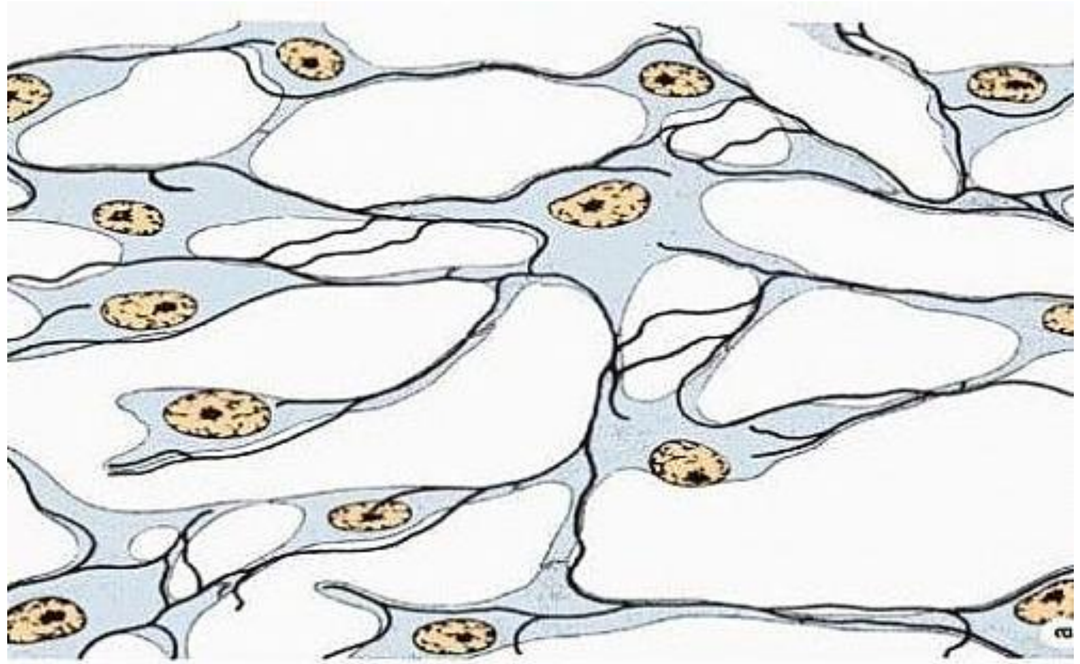

- **parenchym**
  - trámčitý epitel (adenohypofýza, příštítné žlázy, nadledviny, Langerhansovy ostrůvky)
  - plošný epitel uspořádaný do folikulů (štítná žláza)
  - specializovaná nervová tkáň (neurohypofýza, šišinka)

Hypothalamo-hypofyzární systém



Hypothalamus + hypophysis

Systema hypothalamo-hypophysiale

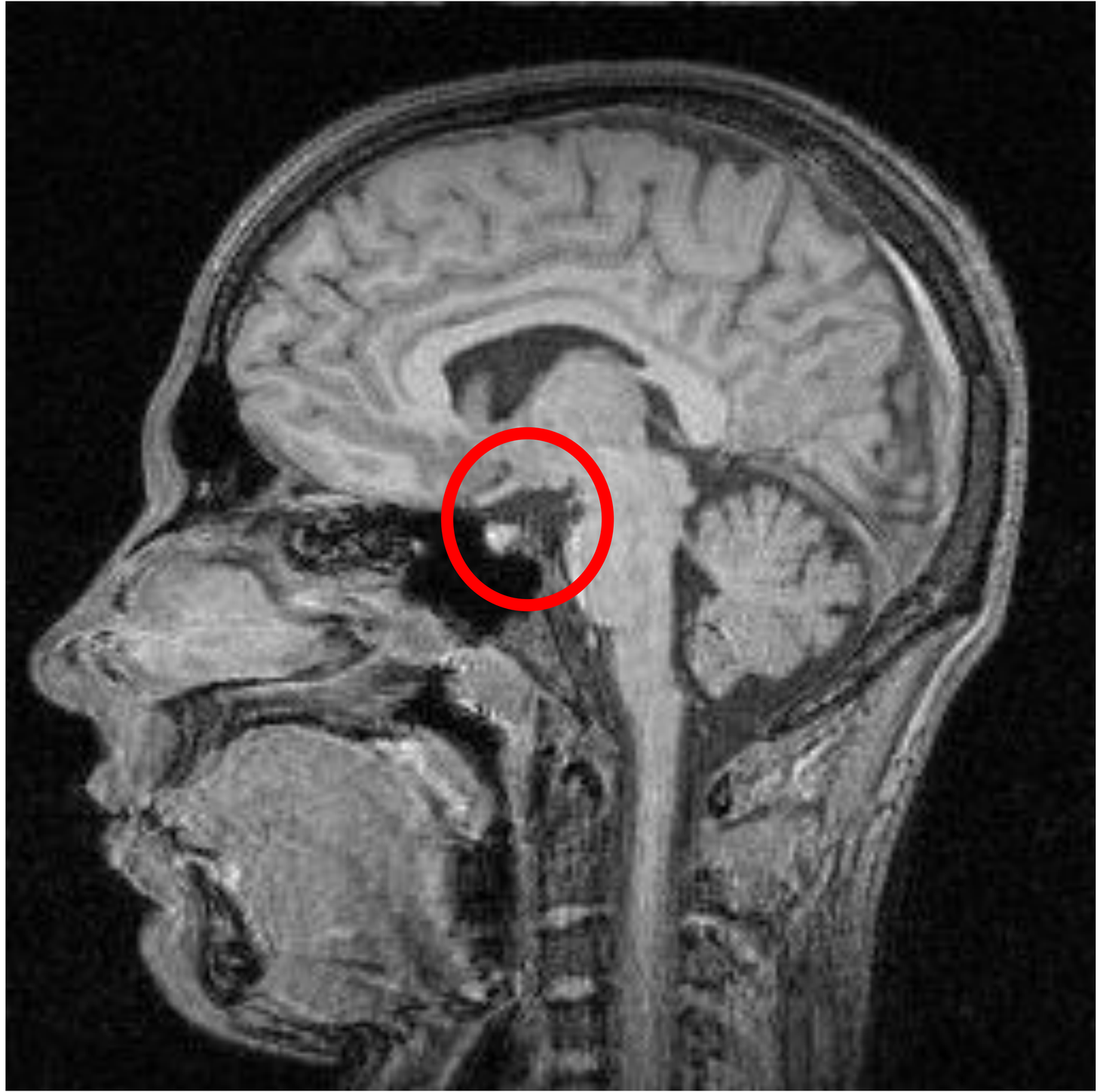

Podhrbolí – *Hypothalamus*

- bazální část mezimozku (*diencephalon),* bazálně od III. komory

- funkce
  - sběrné centrum informací z těla i okolí
  - nejvyšší autonomní ústředí
  - součást limbického systému
  - řídí ostatní žlázy s vnitřním vyměšováním
  - Termostat těla

- corpora mammillaria, tuber cinereum, <u>infundibulum, hypophysis</u>

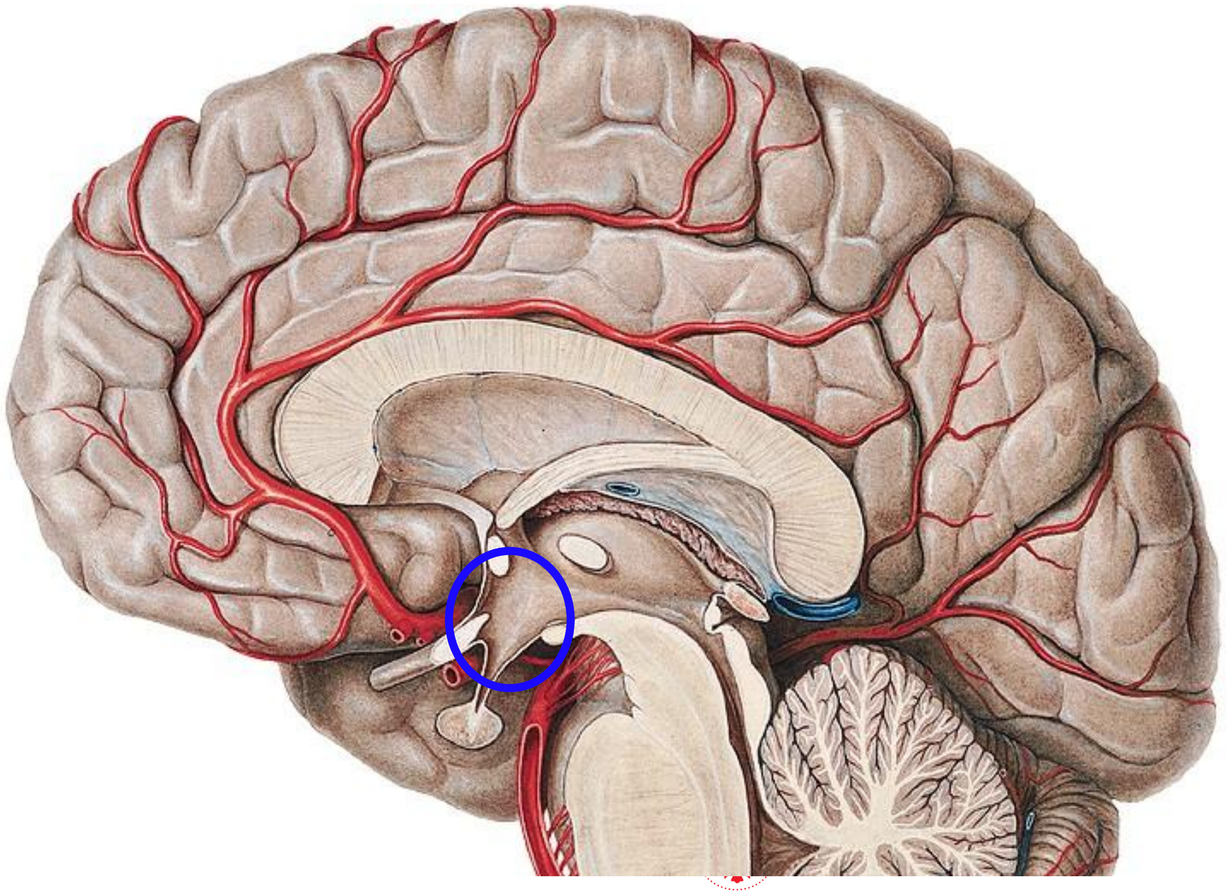

Hypothalamus

- přední hypothalamus
  - **ncl. paraventricularis + supraopticus – oxytocin a vazopresin (ADH)**
    (+ ncl. chiasmaticus, preopticus, anteriorní jádra a suprachiasmatická jádra)

- střední hypothalamus (tuber cinereum)
  - (+ ncl. DM a VM)
  - **ncl. arcuatus** a okolí – řízení adenohypofýzy
    - uvolňovací (releasing) = **liberiny**
      - hormony **SRH, PRH, GnRH, TRH, CRH**
    - tlumivé (inhibiting)= **statiny**
      - hormony **somatostatin, PIH** (= dopamin)

- zadní (kaudální) hypothalamus (corpora mammillaria, ncl. posterior)

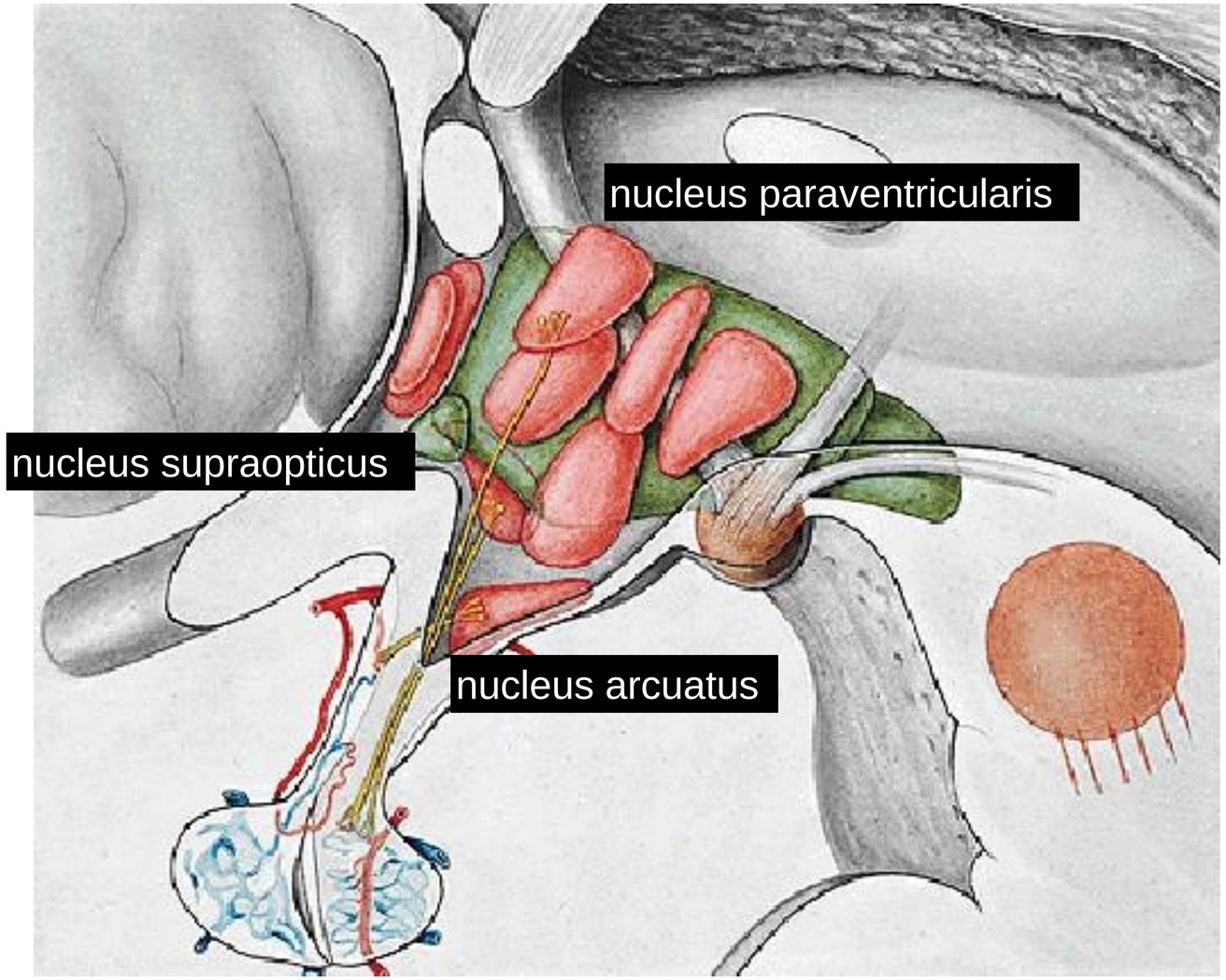

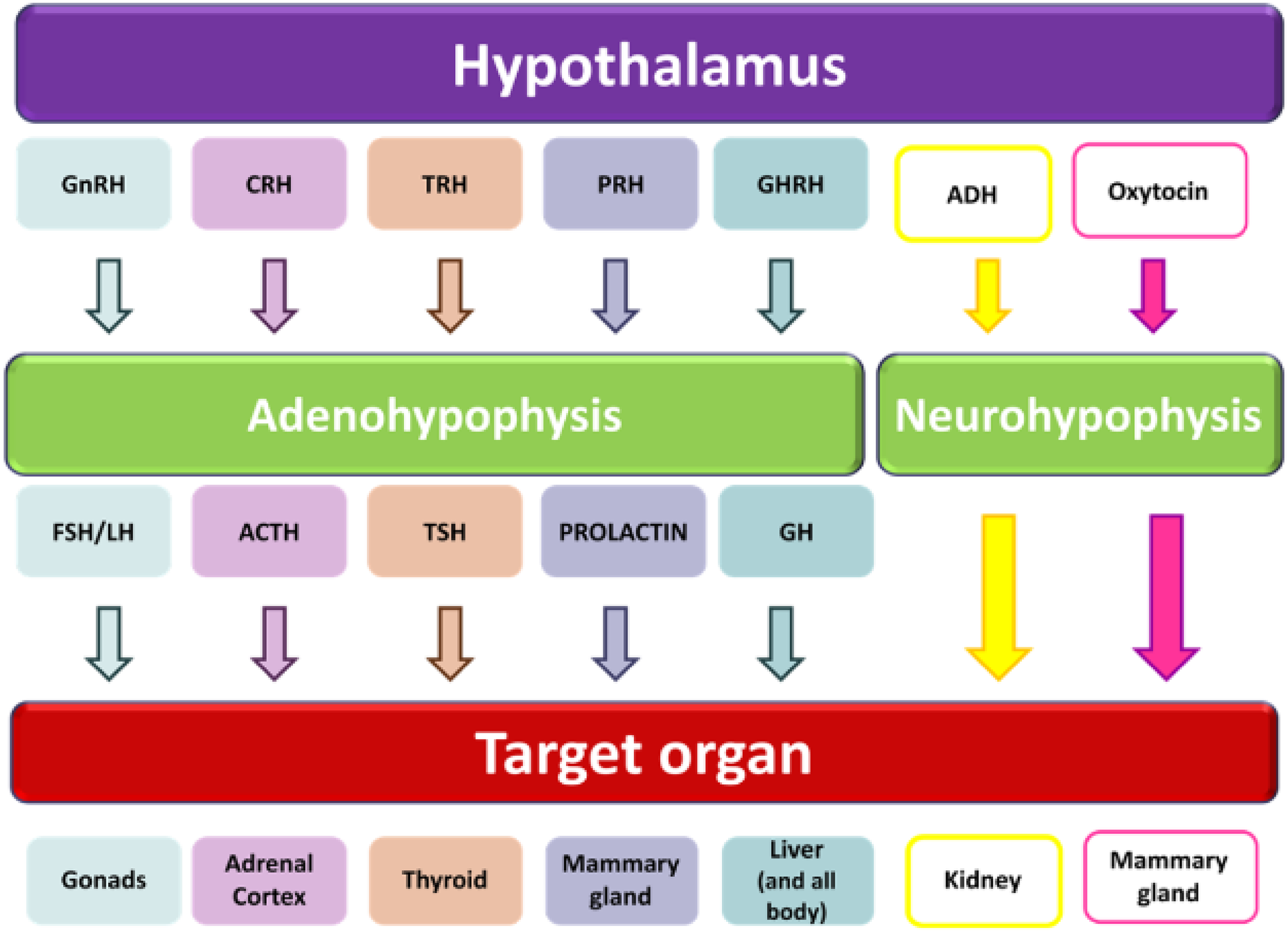

LTY OF MEDICINE
VERSITY

Hypofýza – anatomie

„dvojitá žláza“
- dvě rozdílné tkáně

- tvoří ji dva laloky
  - přední = adenohypofýza
  - zadní = neurohypofýza
- uložena v *sella turcica ossis sphenoidalis*
  - transsfenoidální operační přístup
- kryta tvrdou plenou – *diaphragma sellae*
  - foramen diaphragmatis *Pacchioni* – obsahuje podvěskovou stopku (*infundibulum*)

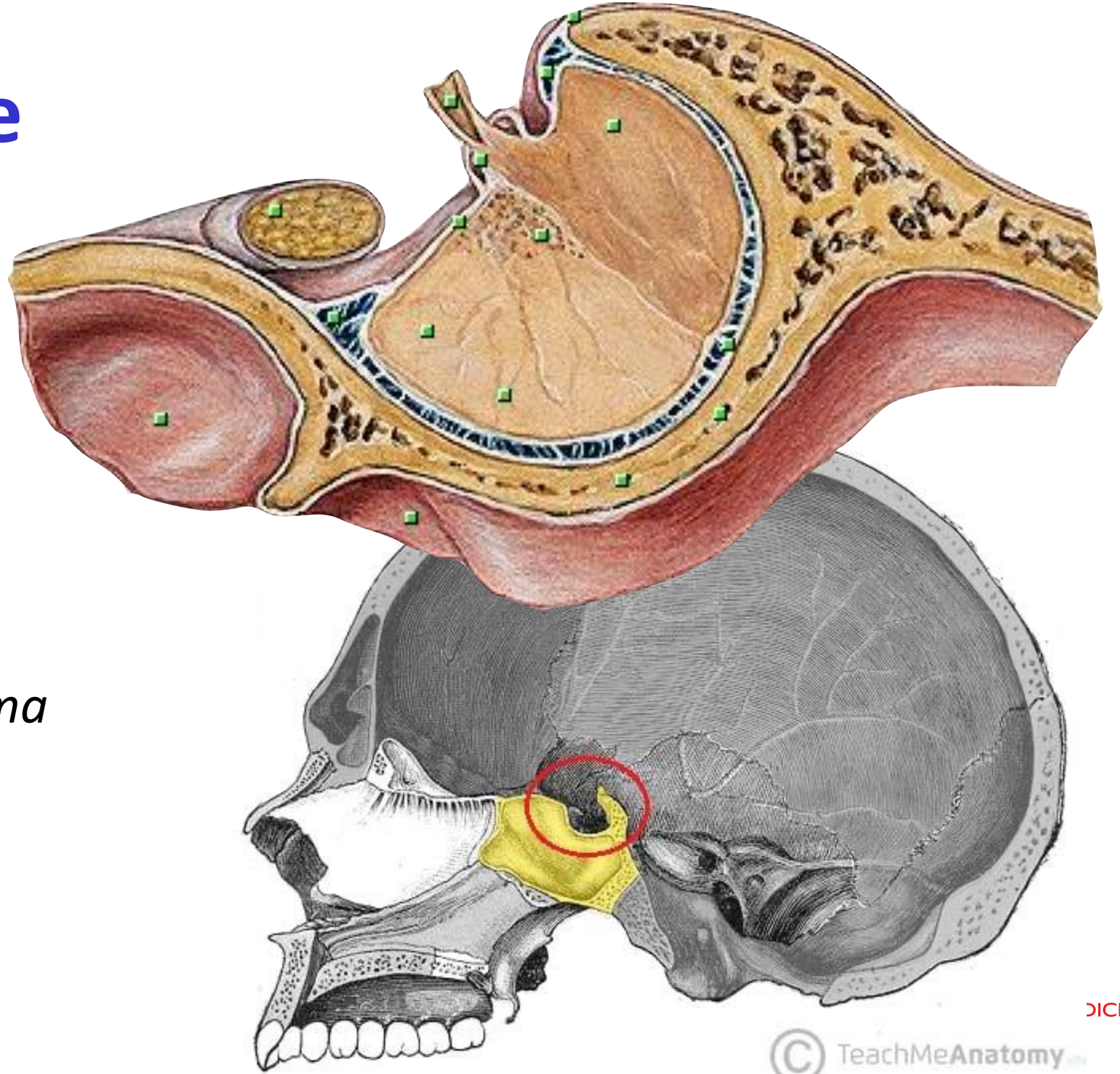

DICINE



Tekiner, Halil. (2015). A cultural history of the Turkish saddle. Journal of Turkish Studies. 10. 319-319. 10.7827/TurkishStudies.8071.

Hypofýza – vývoj

- **Rathkeho** výchlipka - **ektoderm**
  - 3. týden: ve stropě ústní dutiny (*stomodeum*)
  - výchlipka směrem k mezimozku
  - adenohypofýza
- výchlipka báze mezimozku
  - neurohypofýza
  - diferenciace v pituicyty (glie)

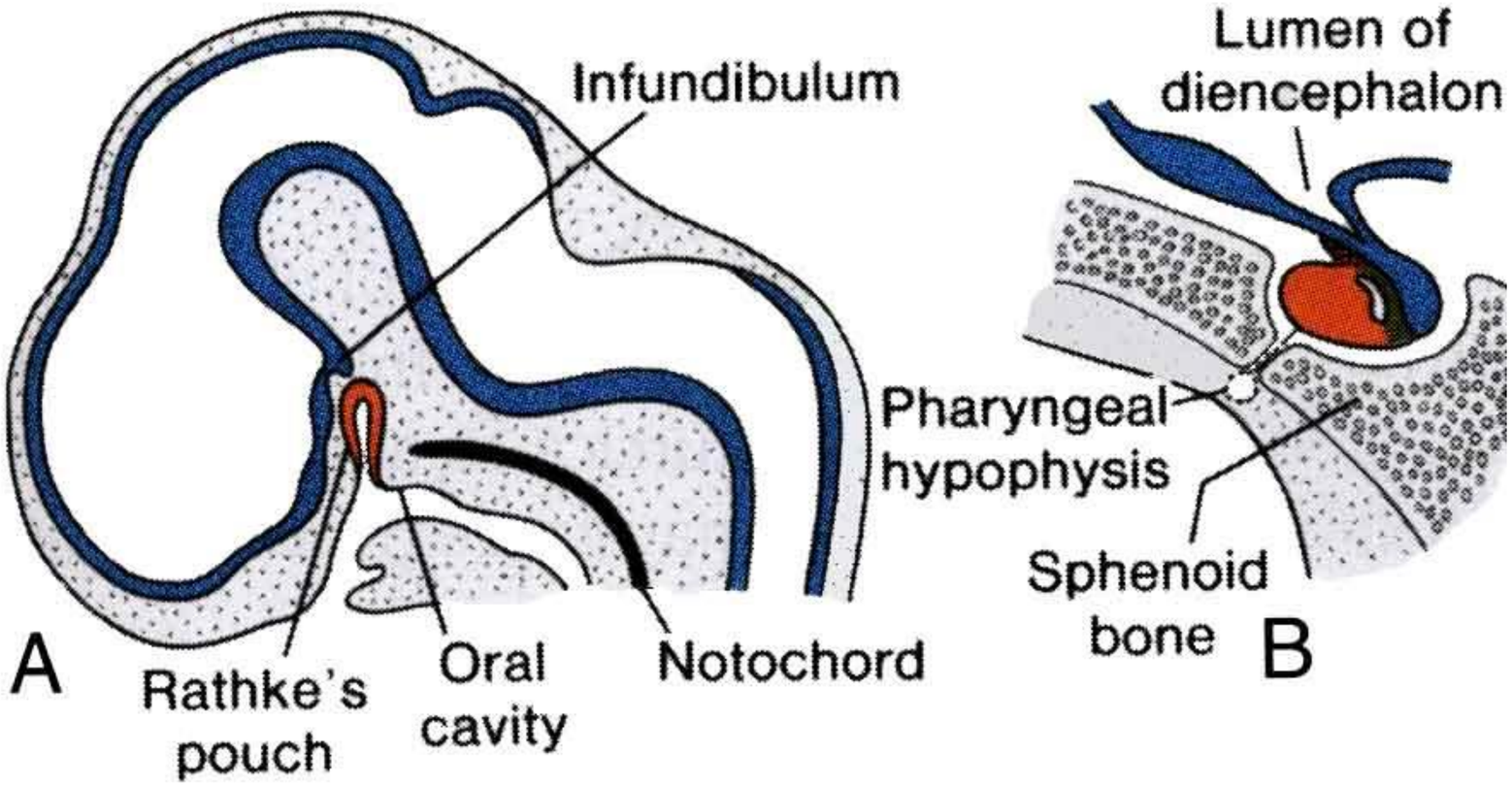

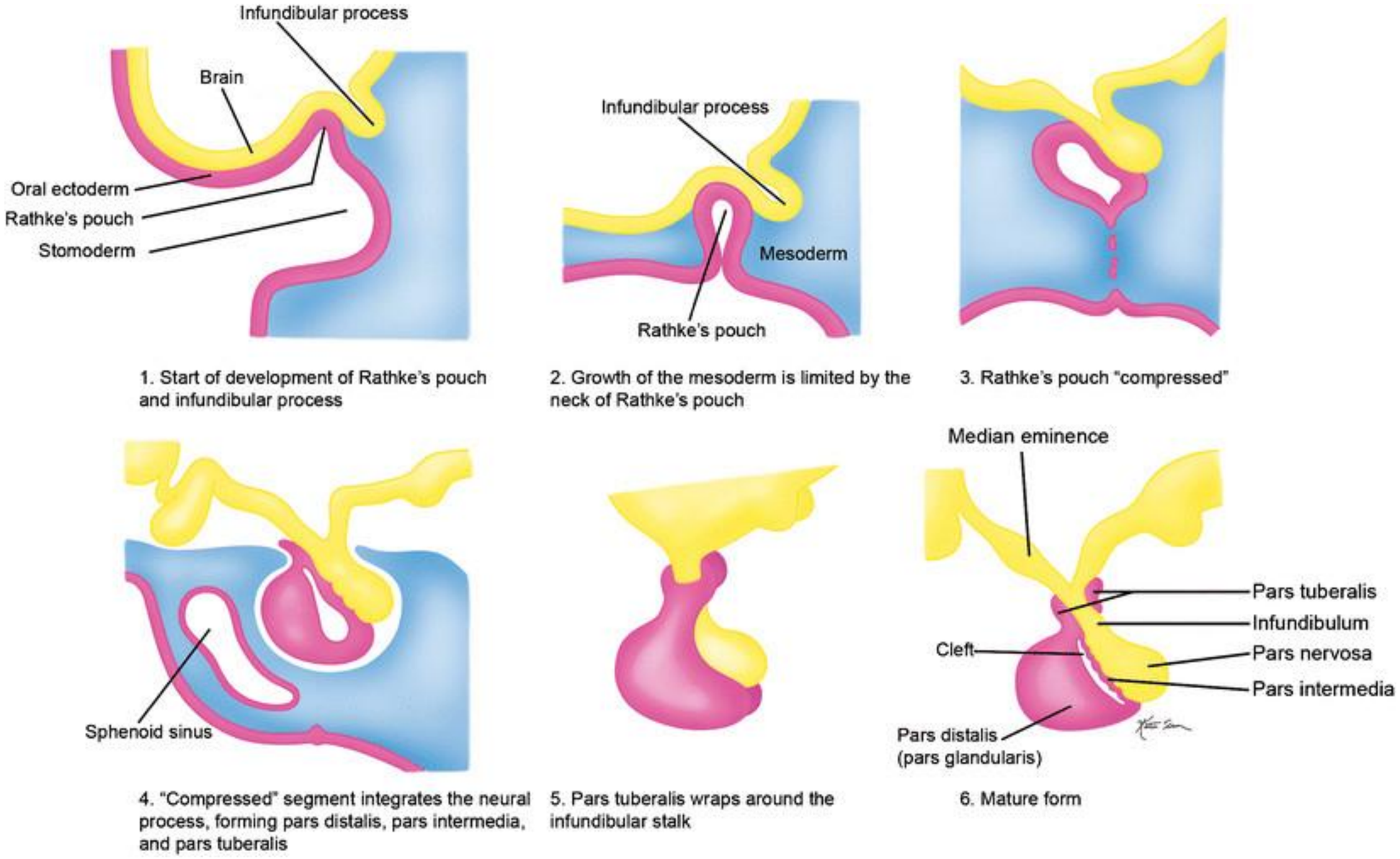

Shields, Rachel & Mangla, Rajiv & Almast, Jeevak & Meyers, Steven. (2015). Magnetic resonance imaging of sellar and juxtasellar abnormalities in the paediatric population: an imaging review. Insights into imaging. 6. 10.1007/s13244-015-0401-5.

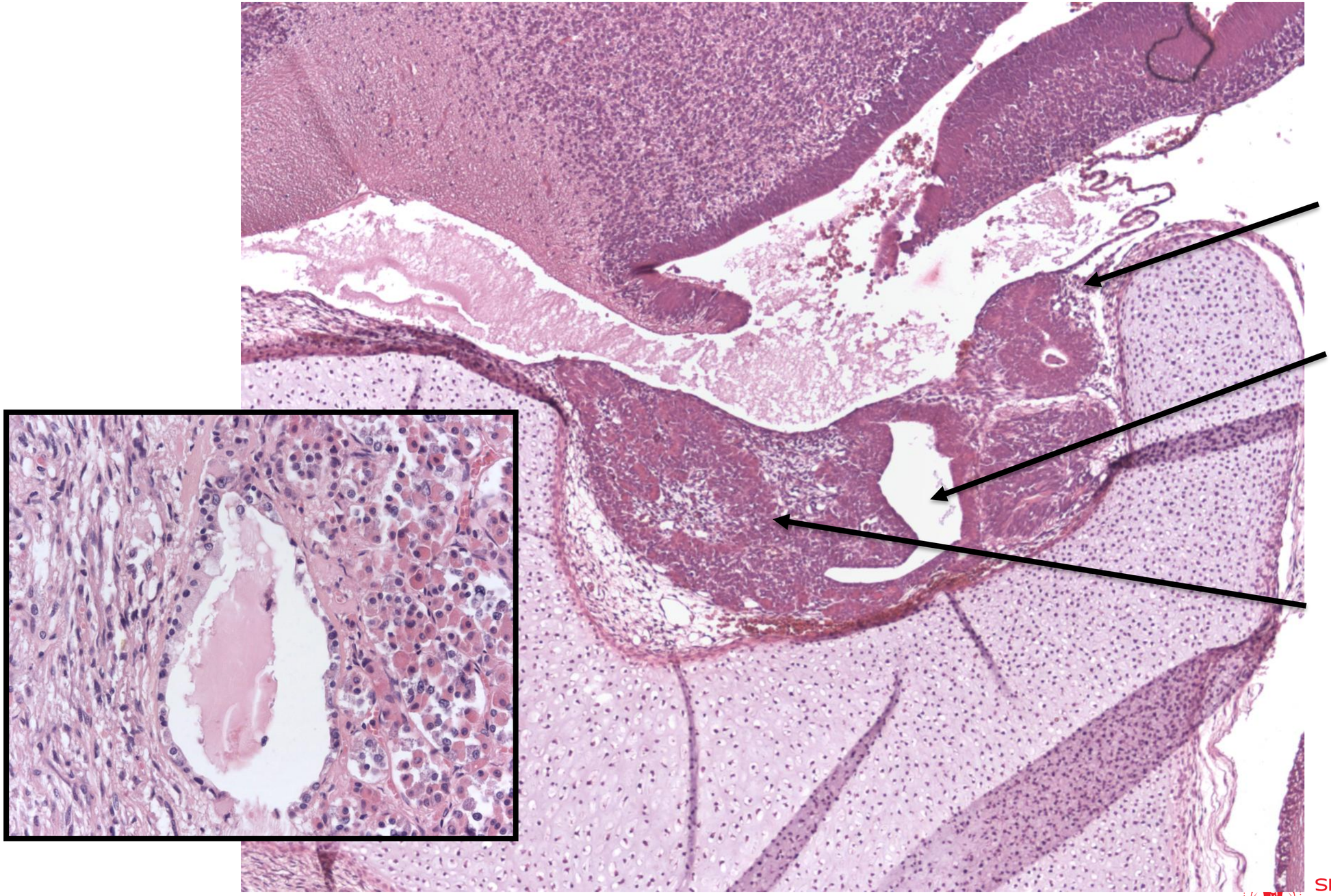
Neurohypophysis
Rathke´s pouch - lumen
Adenohypophysis

Adenohypophysis

Hypofýza (glandula pituitaria)

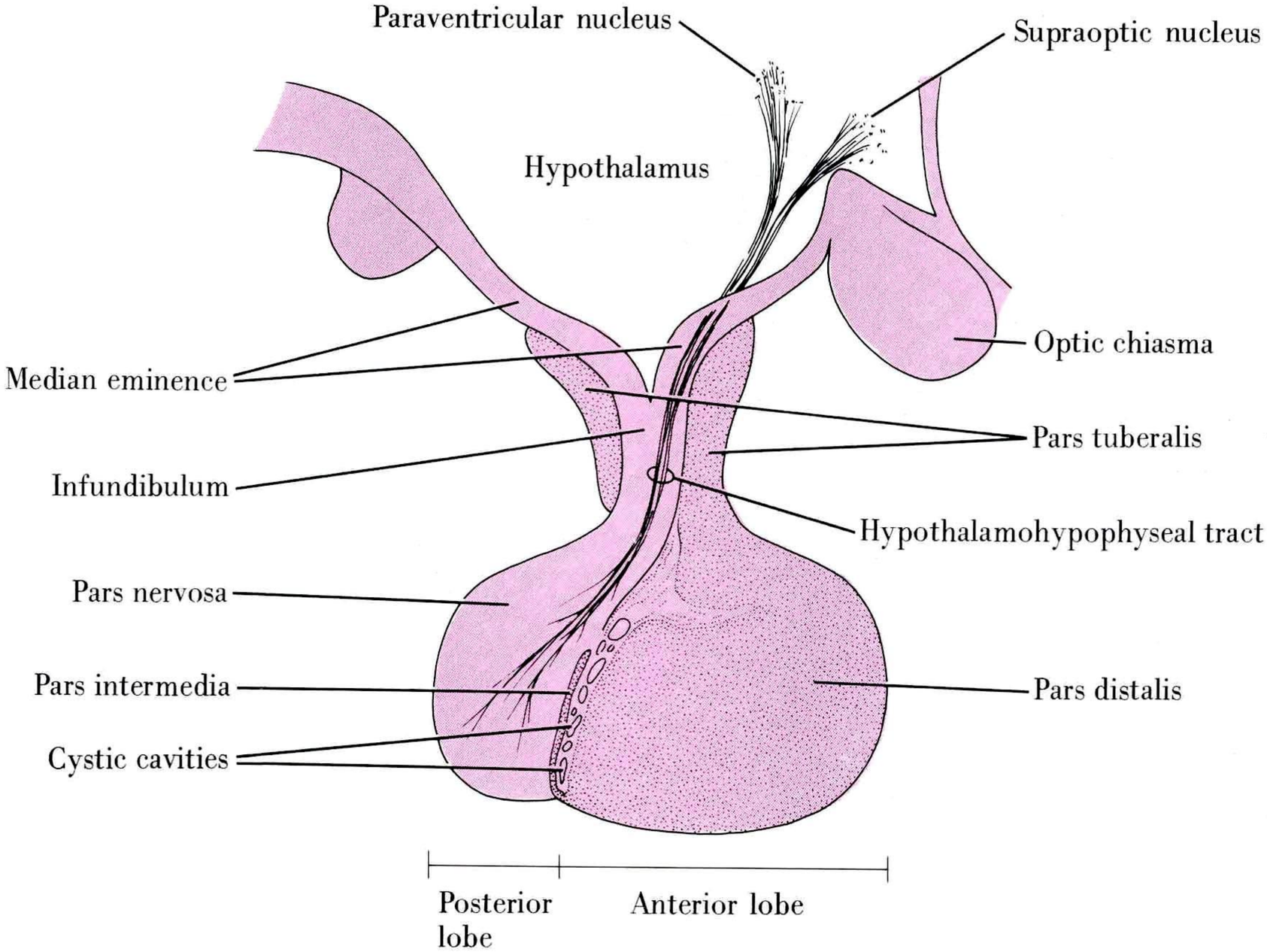

HYPOPHYSIS

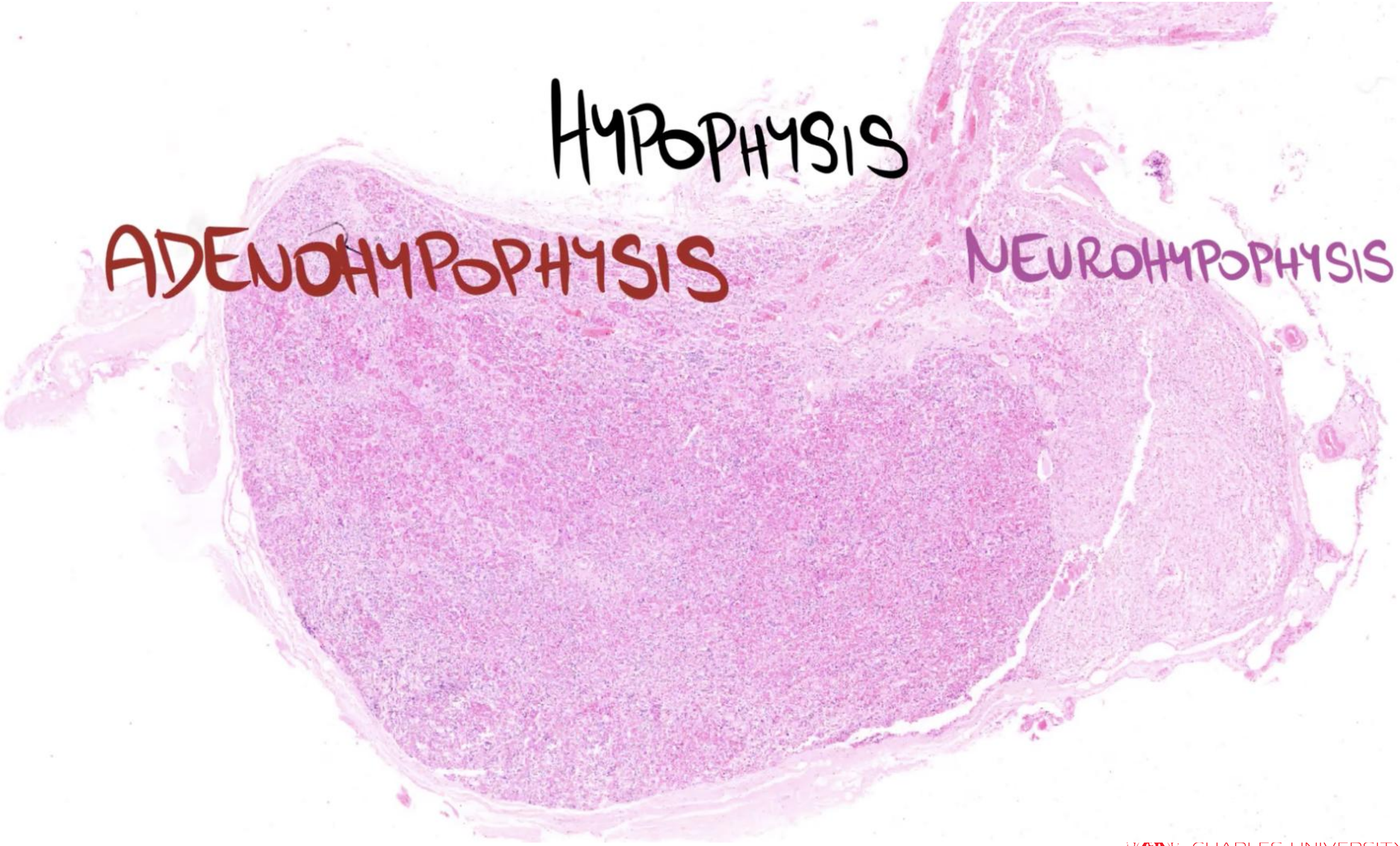

- **a.hypophysialis inf.** - pars cavernosa ACI -> neurohypofýza
- **a.hypophysialis sup.** - pars communicans ACI —> primární kapilární síť -> vv. hypophysiales portales -> sekundární kapilární síť.
- **vv. hypophysiales** -> sinus cavernosus

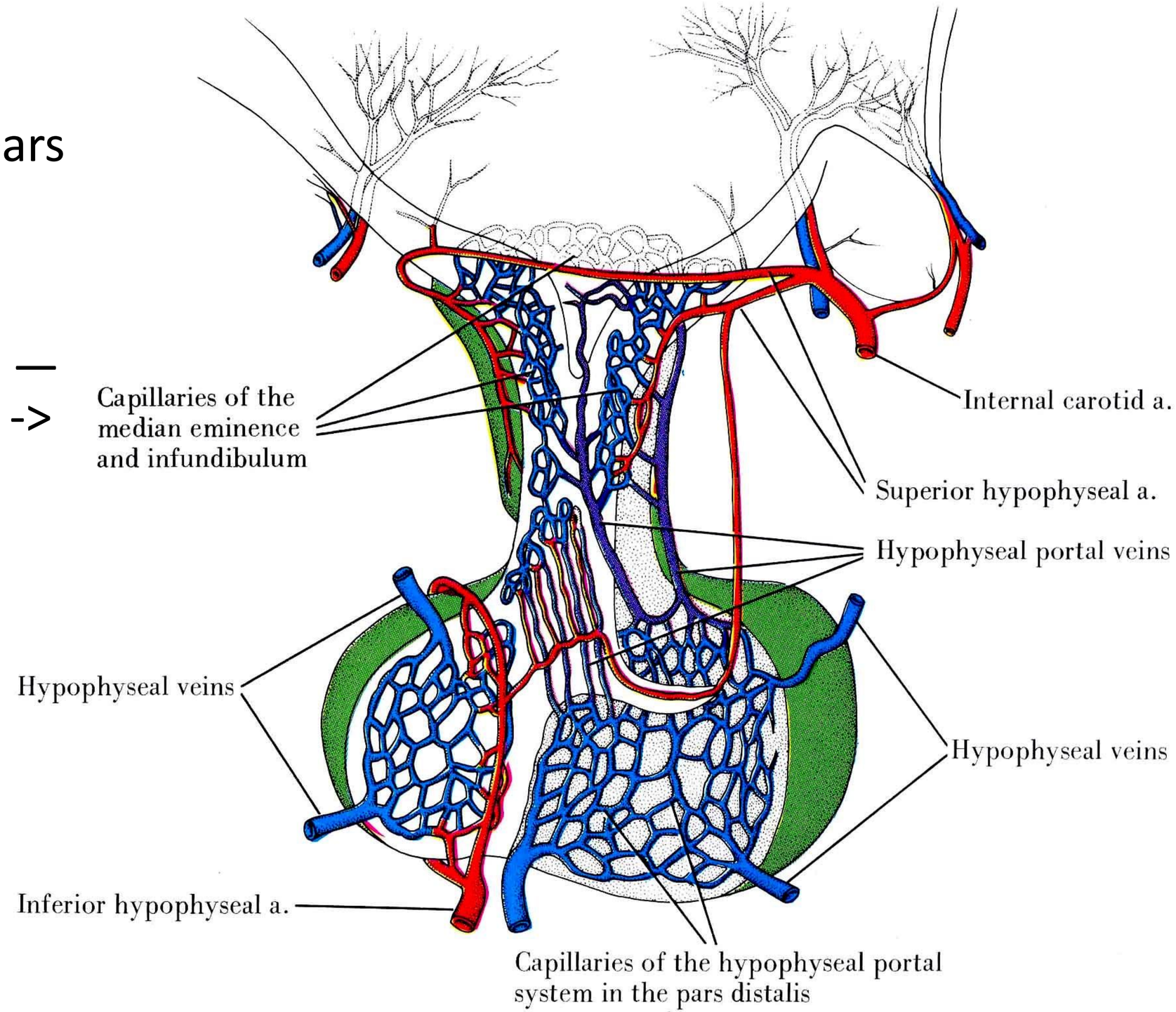

E

ADENOHYPOPHYSIS

↳ 3 PARTS ⇒

1. PARS DISTALIS
2. PARS TUBERALIS
3. PARS INTERMEDIA

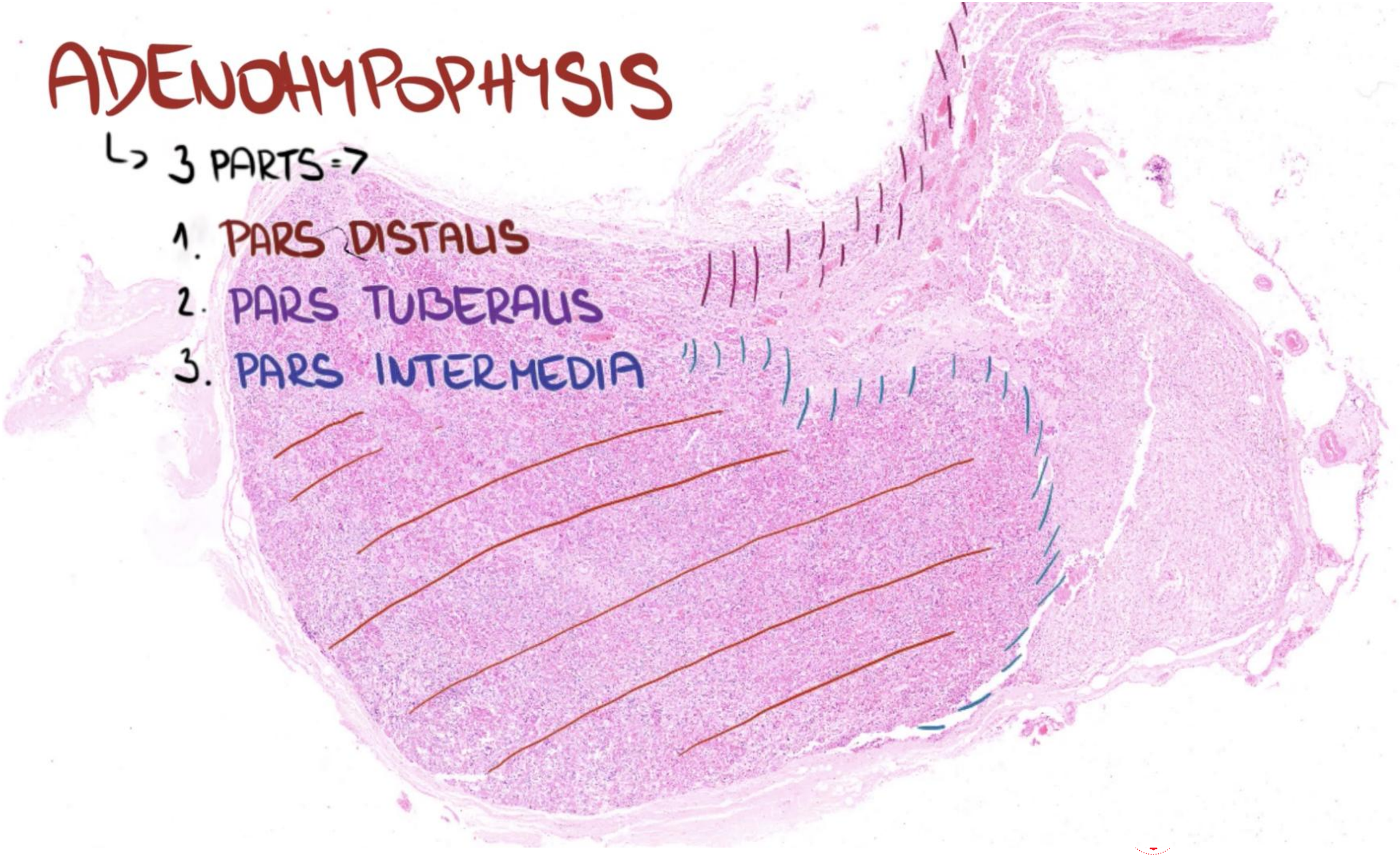

Pars distalis adenohypophysis

- trámce epitelových buněk
- mezi nimi fenestrované vlásečnice
- na HE 3 typy buněk
  - acidofilní (jednoduché proteiny)
  - bazofilní (glykoproteiny)
    - PAS-pozitivní
  - chromofóbní
    - bez granul
    - nediferencované elementy
    - **Folikulostelární** buňky

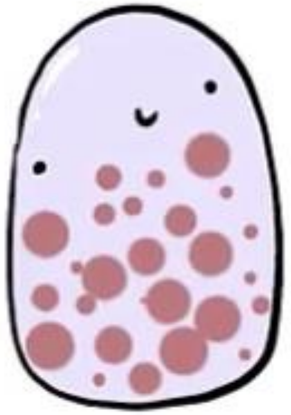

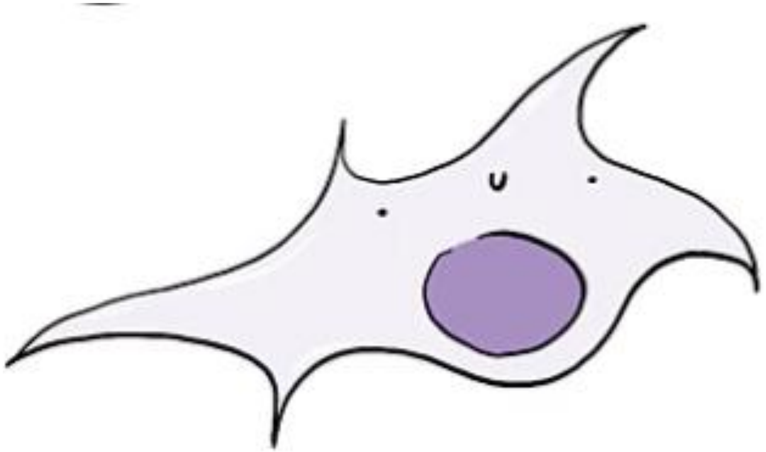

Pars distalis – acidofilní buňky

- **α – buňky (somatotropní)**
  - hrubá granula, GER
  - okolo jádra zóna bez granul (GA)
  - **růstový hormon (somatotropin, GH)**
- **ε – buňky (laktotropní)**
  - obvykle malé, nepočetné
  - zvýšení počtů v těhotenství a při kojení
  - drobná granula (zvětšení v těhotenství)
  - **prolaktin (PRL)**

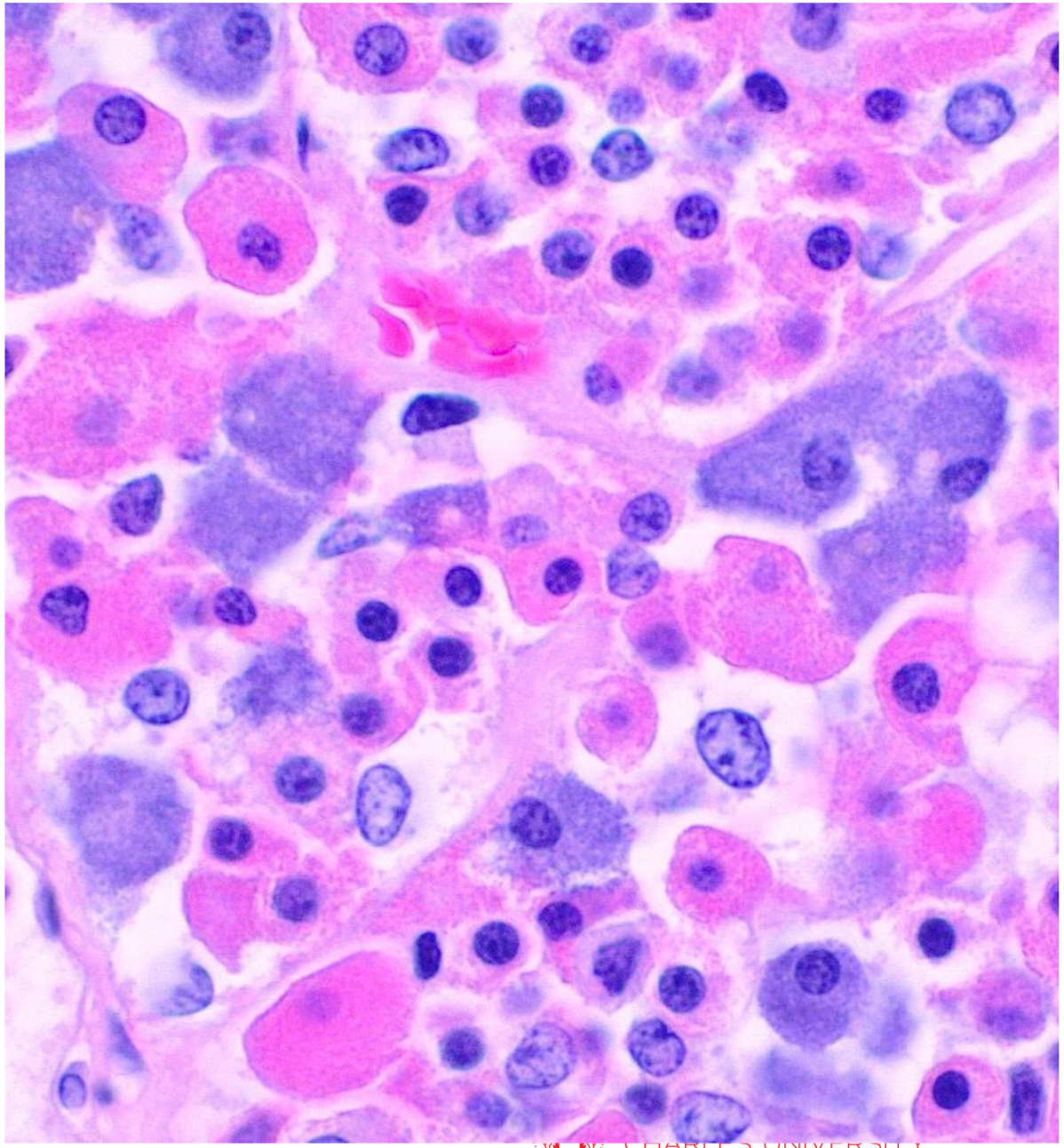

CHARLES UNIVERSITY

Pars distalis – bazofilní buňky

- **β_1 – buňky (adrenokortikotropní)**
  - velká granula při buněčné membráně
  - **ACTH, β-MSH**, Met-enkefalin, endorfin
- **β_2 – buňky (thyreotropní)**
  - velké buňky, malá granula u BM
  - **TSH**
- **δ – buňky (gonadotropní)**
  - velké buňky, středně velká granula
  - **FSH, LH**

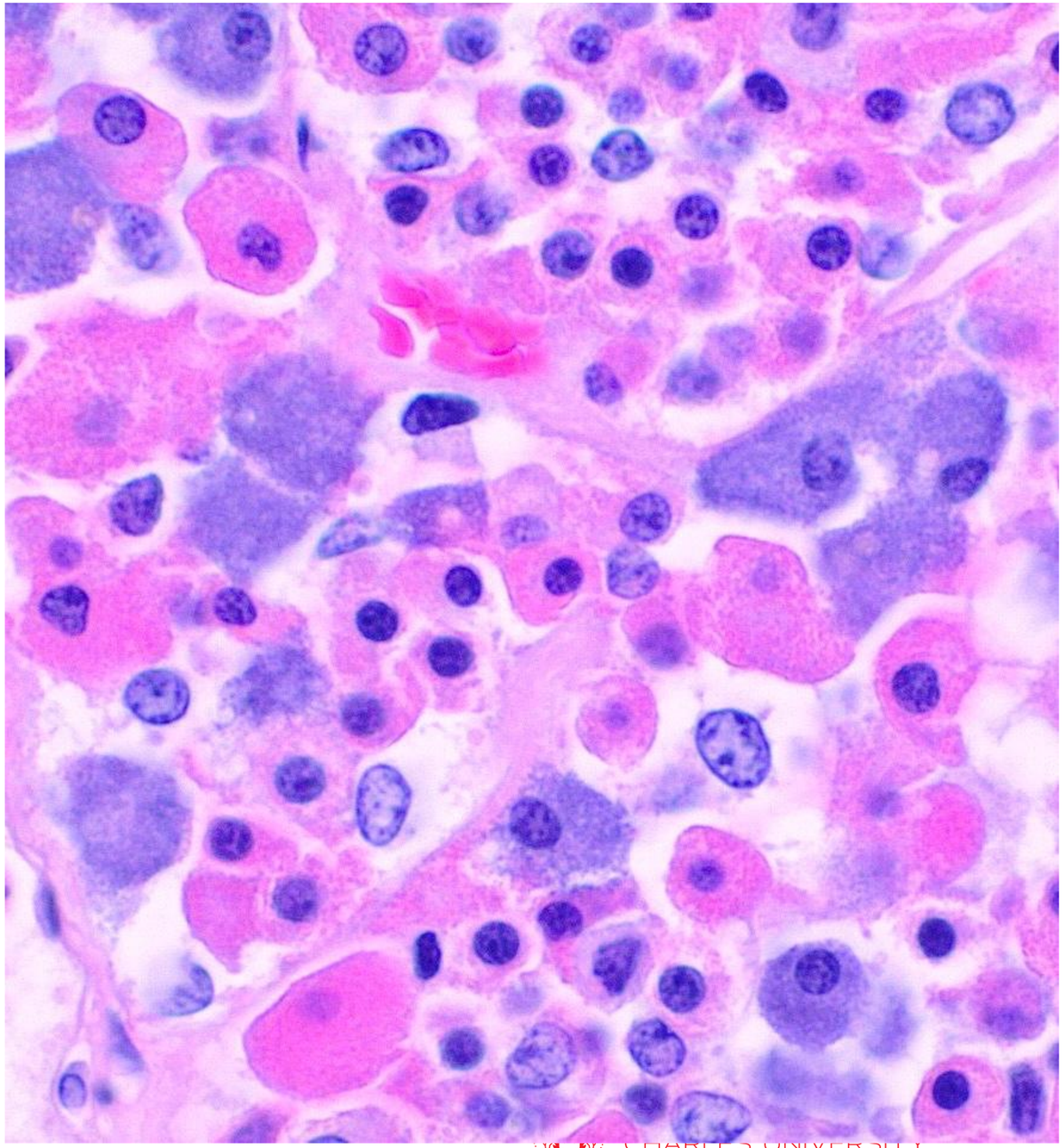

Chromofóbní buňky
chromofilní buňky : acidofilní / bazofilní

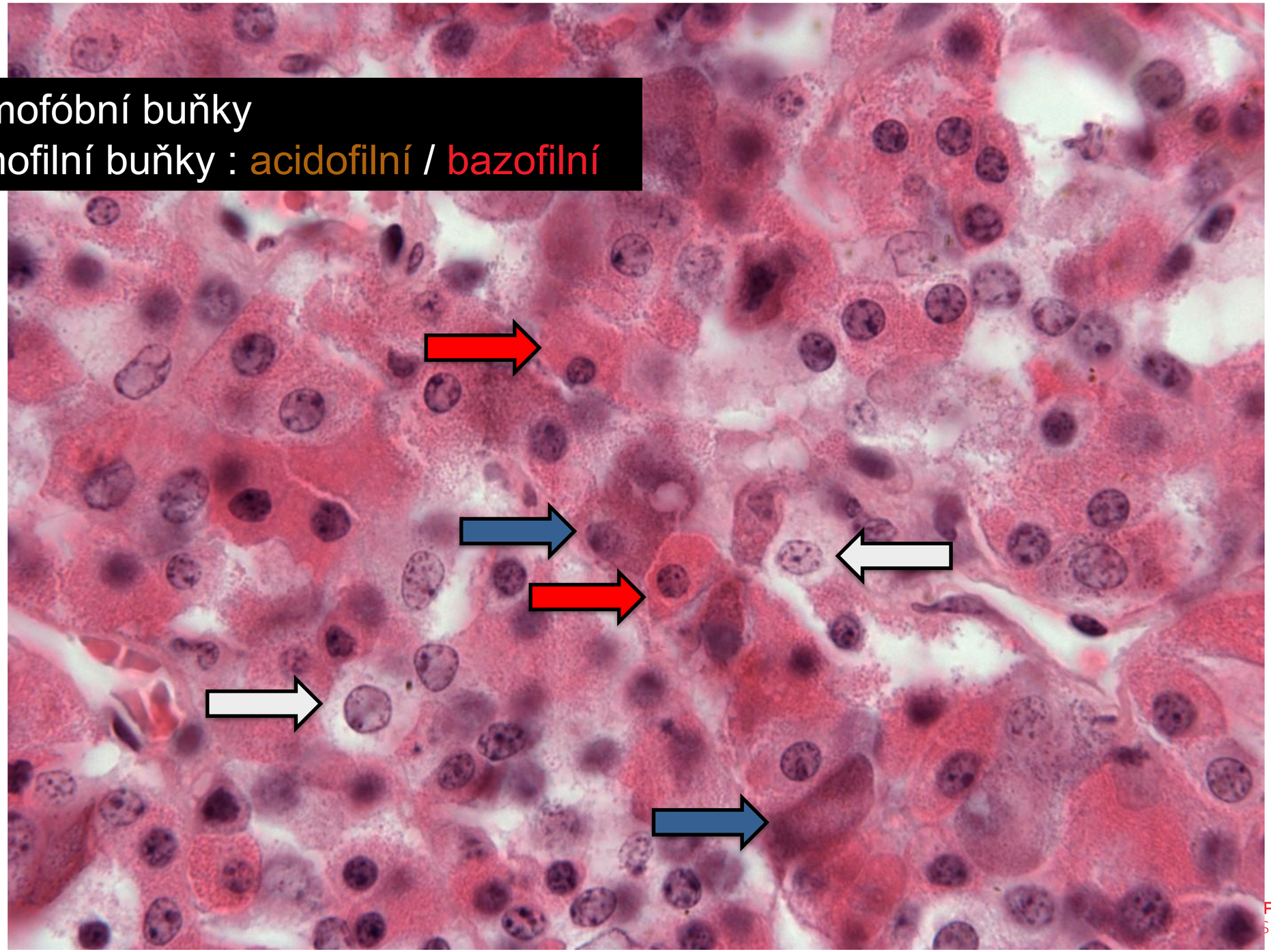

STH
GHRH
ghrelin
somatostatin
NFB

PRL (LTH)
PRH
TRH
GnRH
estrogeny
kojení
dopamin

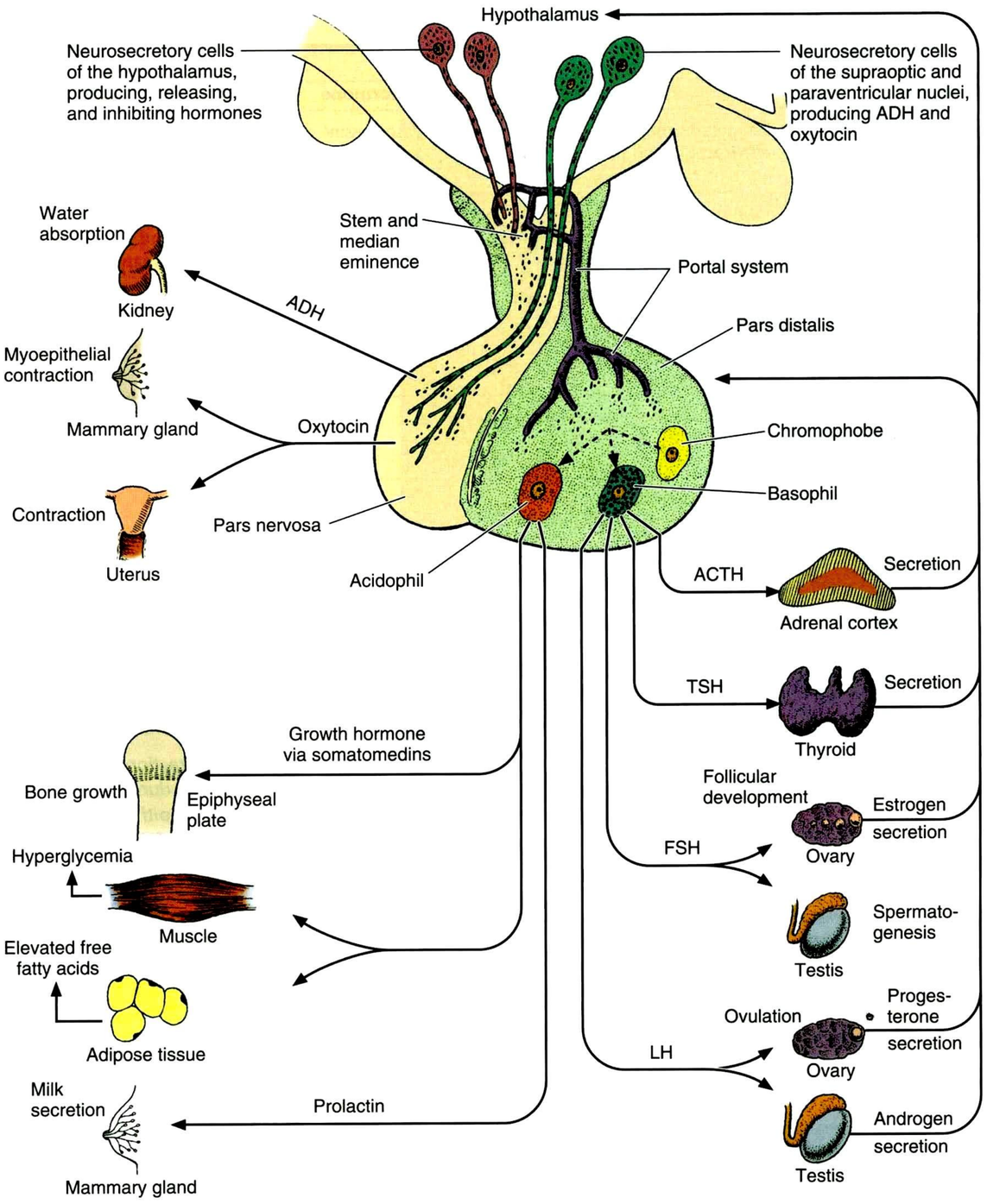

TTH
TRH
NFB

FSH / LH
GnRH
FSH-activin
NFB
FSH-inhibin

ACTH
CRH
NFB

MSH

hormon stimulace inhibice NFB = negative feedback

SECOND FACULTY OF MEDICINE
CHARLES UNIVERSITY

imunohistochemický průkaz hormonu

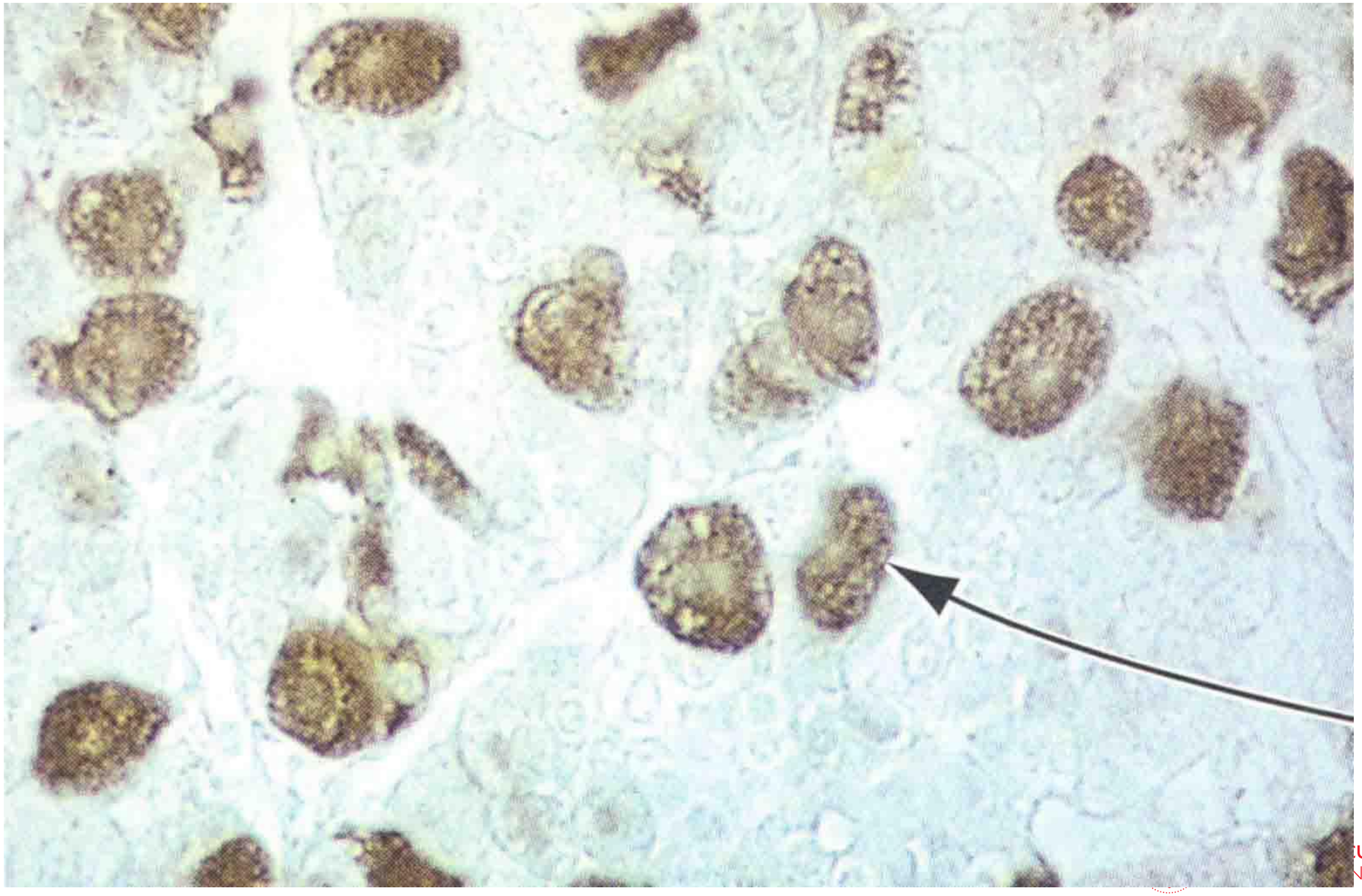

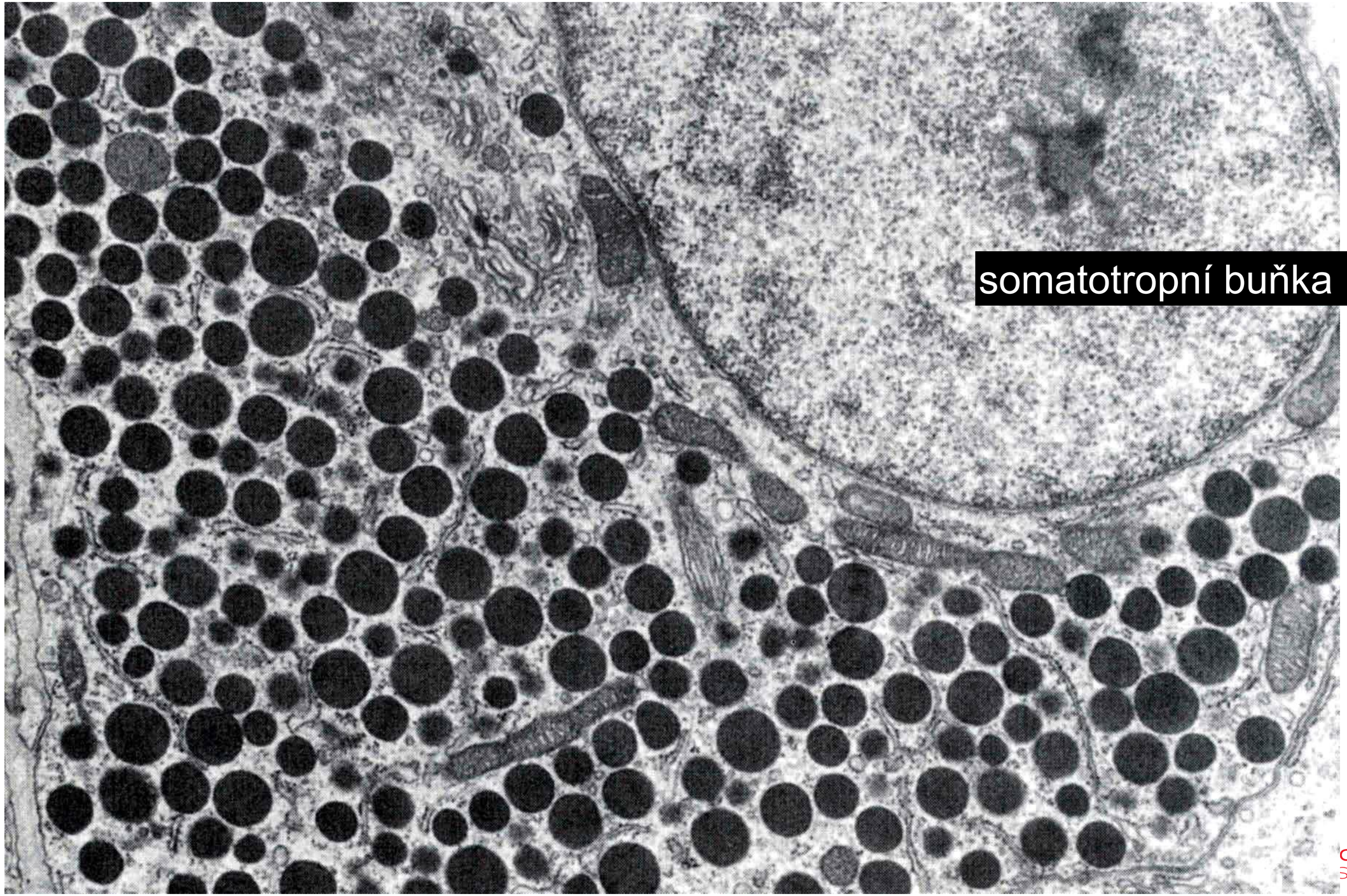

OF MEDICINE
SITY

Pars intermedia

- Rathkeho cysty (jednovrstevný epitel)
- chromofóbní buňky
- převážně bazofilní buňky

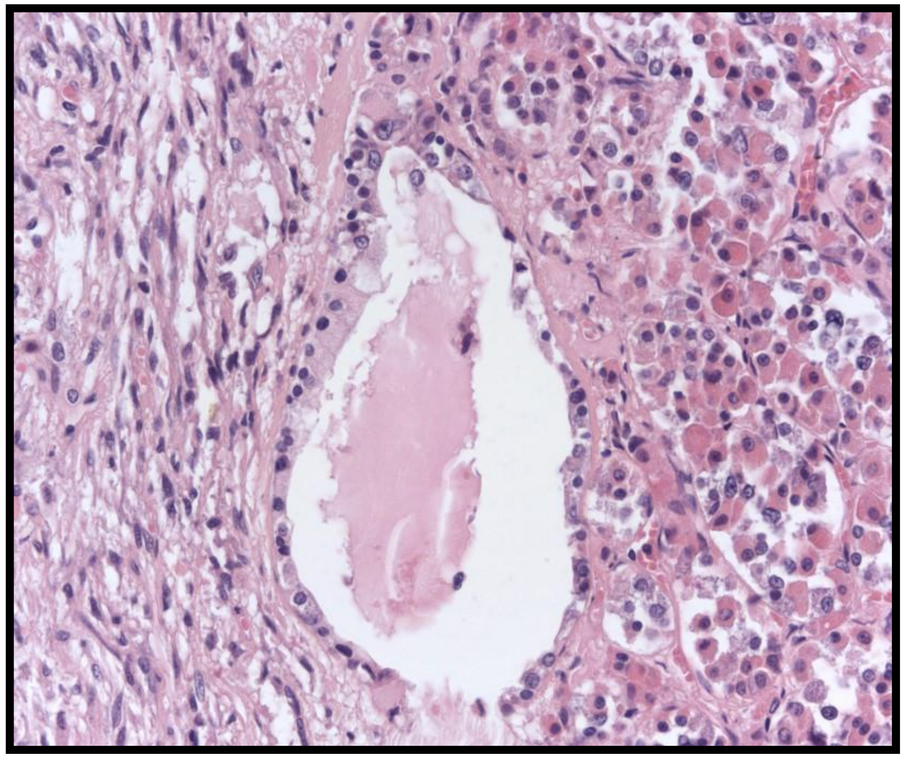

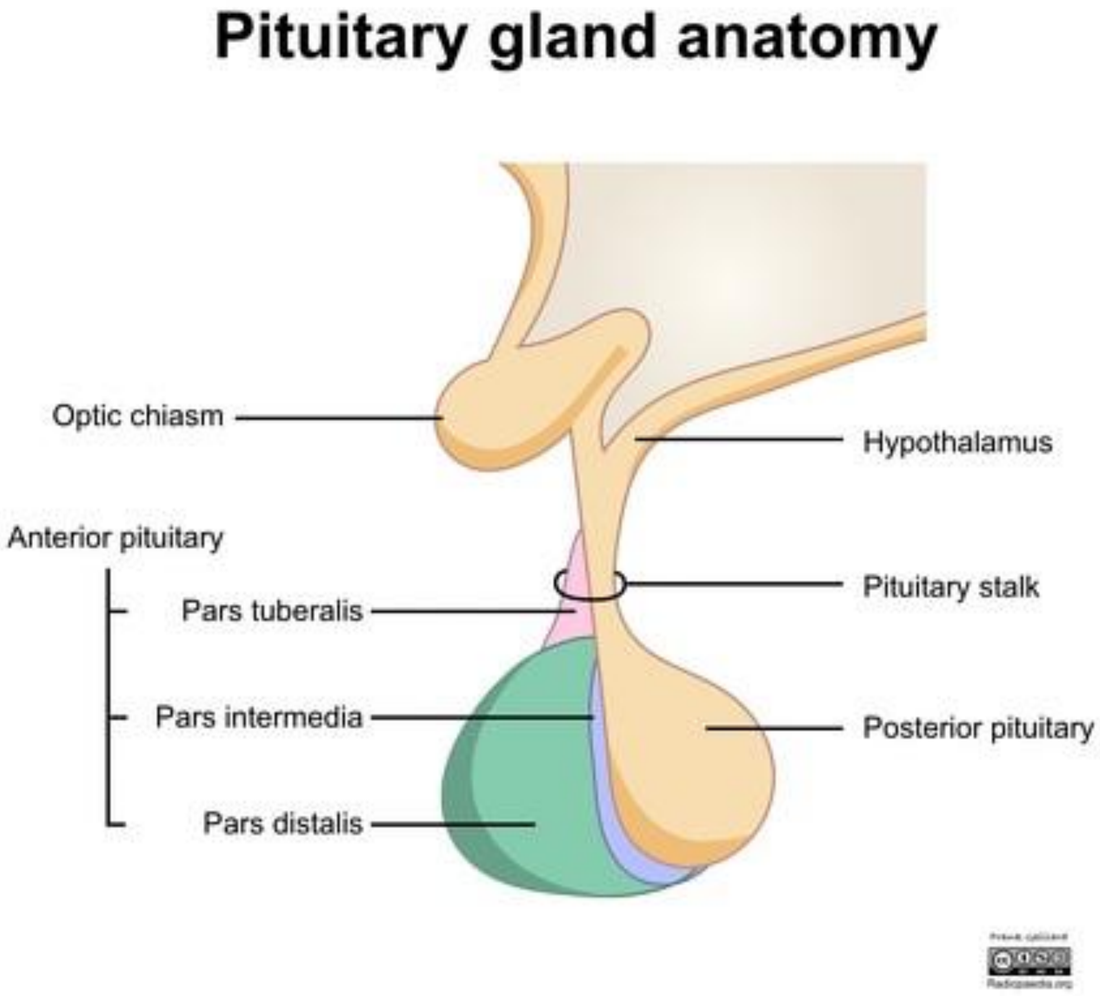

PARS INTERMEDIA

↳ RUDIMENTARY PART

POSTERIOR PART OF RATHKE'S POUCH

RATHKE'S CYSTS → BETWEEN PARS DISTALIS AND PARS INTERMEDIA

MAINLY CORTICOTROPIC BASOPHILIC CELLS

SOMETIMES FORM FOLLICLES FILLED WITH COLLOID

Pars tuberalis

- horní výběžek pars distalis, obklopující část infundibula
- převážně chromofóbní buňky + bazofilní buňky

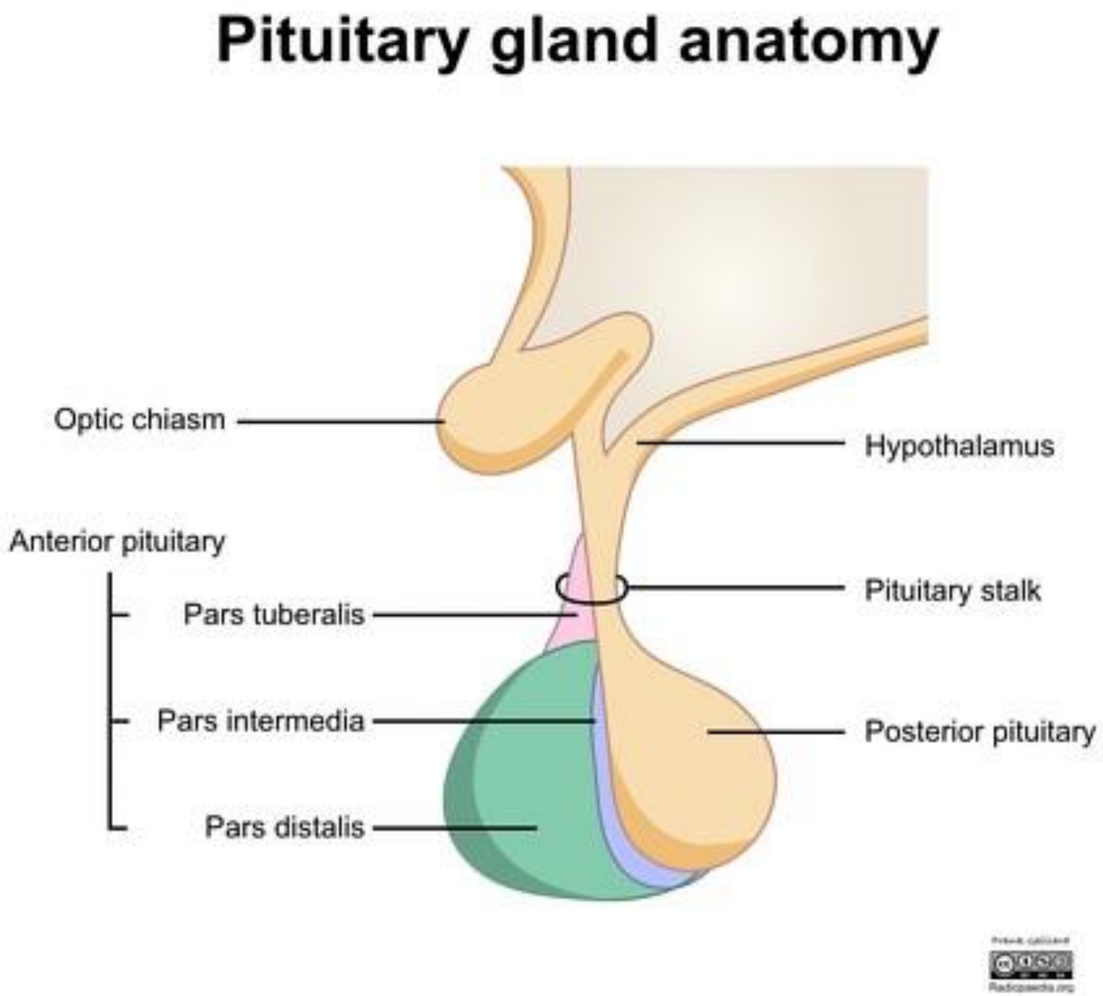

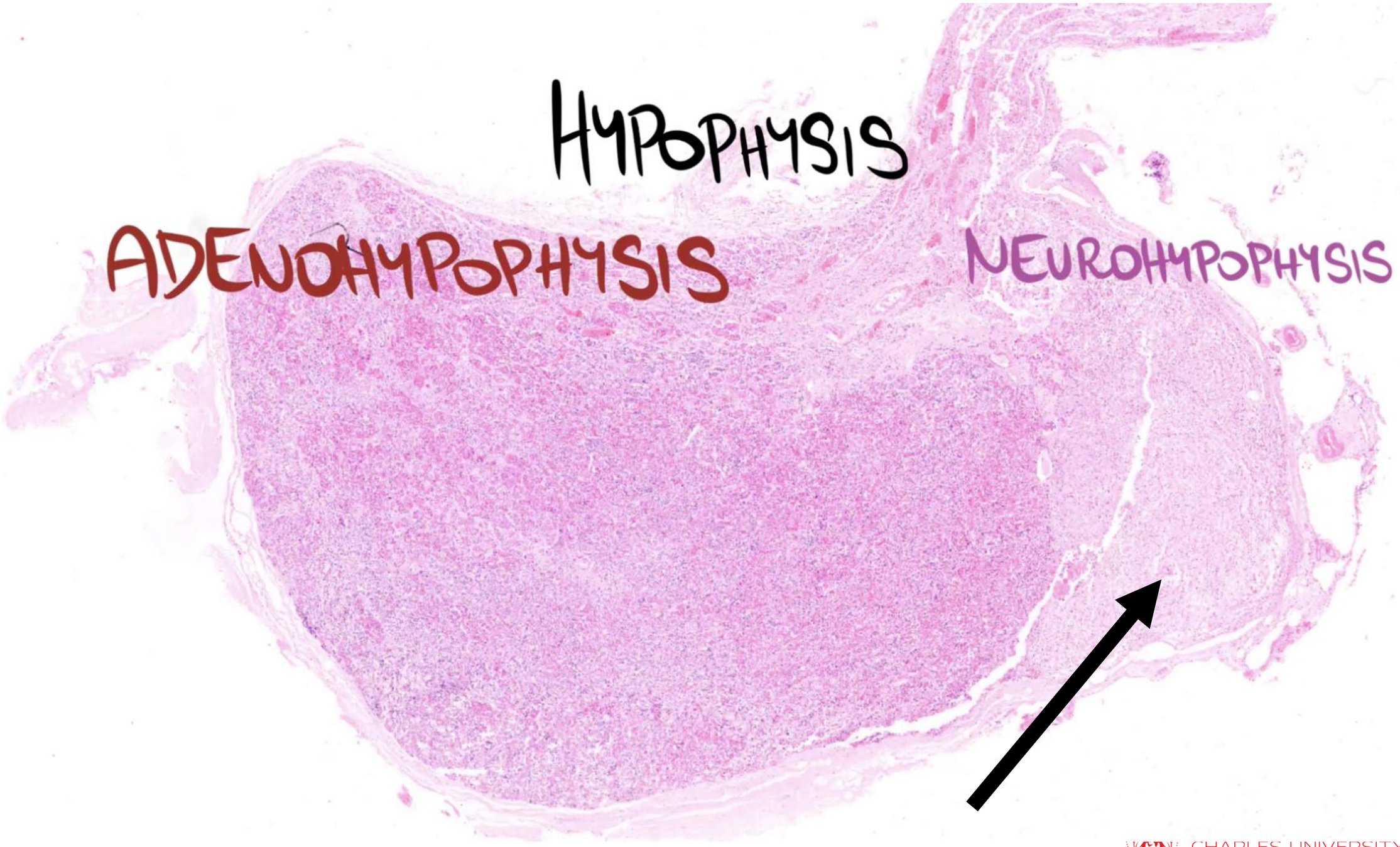
HYPOPHYSIS
ADENOHYPOPHYSIS
NEUROHYPOPHYSIS

Neurohypophysis



Zadní lalok - Neurohypofýza

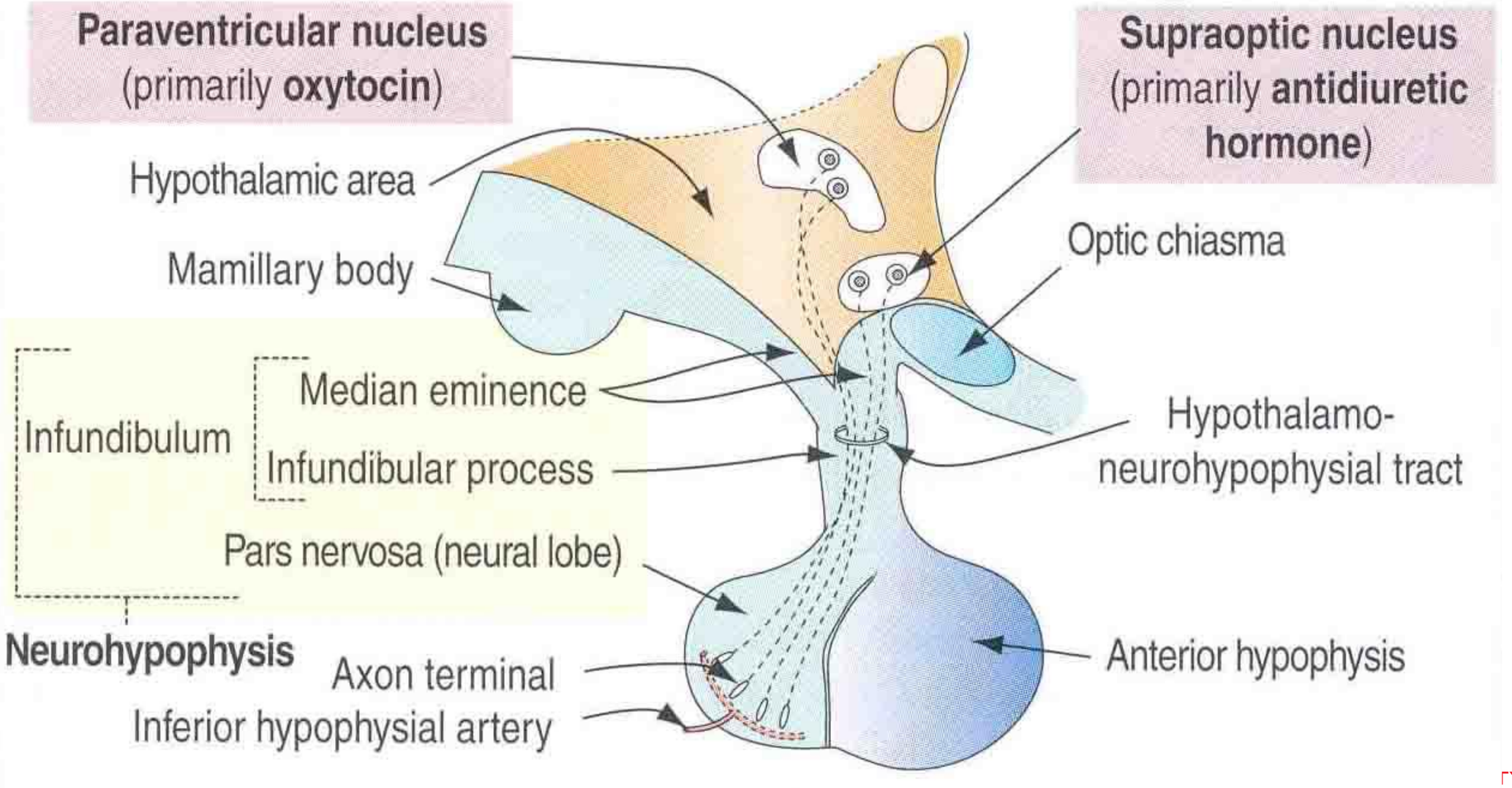

TY OF MEDICINE
ERSITY

Zadní lalok = *Neurohypophysis*

- eminentia mediana
  - dno III. mozkové komory
  - četná nemyelinizovaná nervová vlákna

- stopka (*infundibulum*)
  - tractus hypothalamohypophysialis
  - neurofibra neurosecretoria (+ vesicula neurosecretoria) = nemyelinizovaná nervová vlákna
    - některá končí u vlásečnic

- lobus nervosus (pars nervosa)

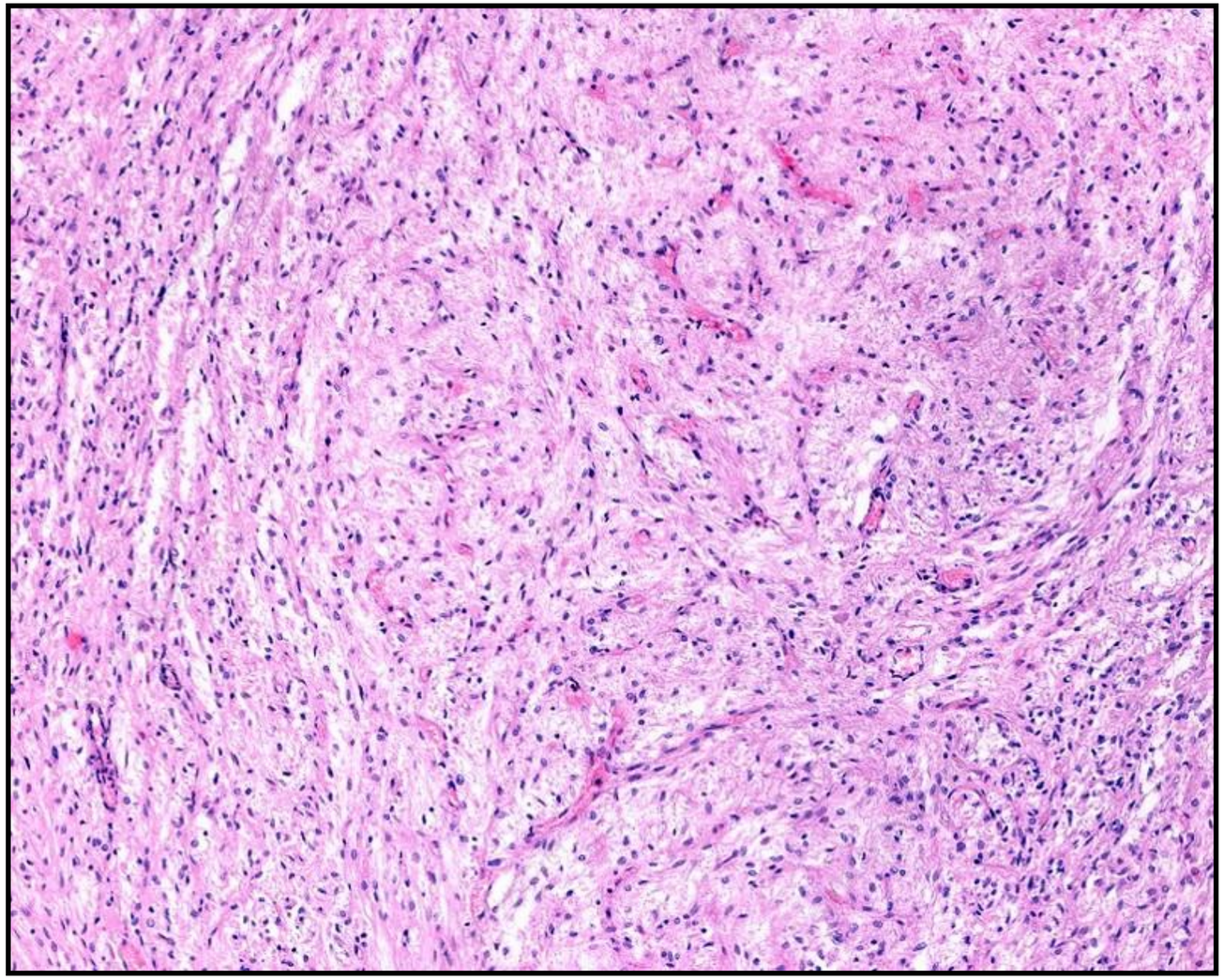

Lobus nervosus neurohypophysis

- nervová vlákna
  - axony neuronů hypotalamu
  - corpuscula neurosecretoria (Herringova tělíska) – nahromadění granul
  - **oxytocin** + **ADH** (adiuretin, antidiuretický hormon, vazopresin)
- pituicyty
  - gliové buňky
- fenestrované vlásečnice (*synapsis neurohaemalis*)

diabetes insipidus

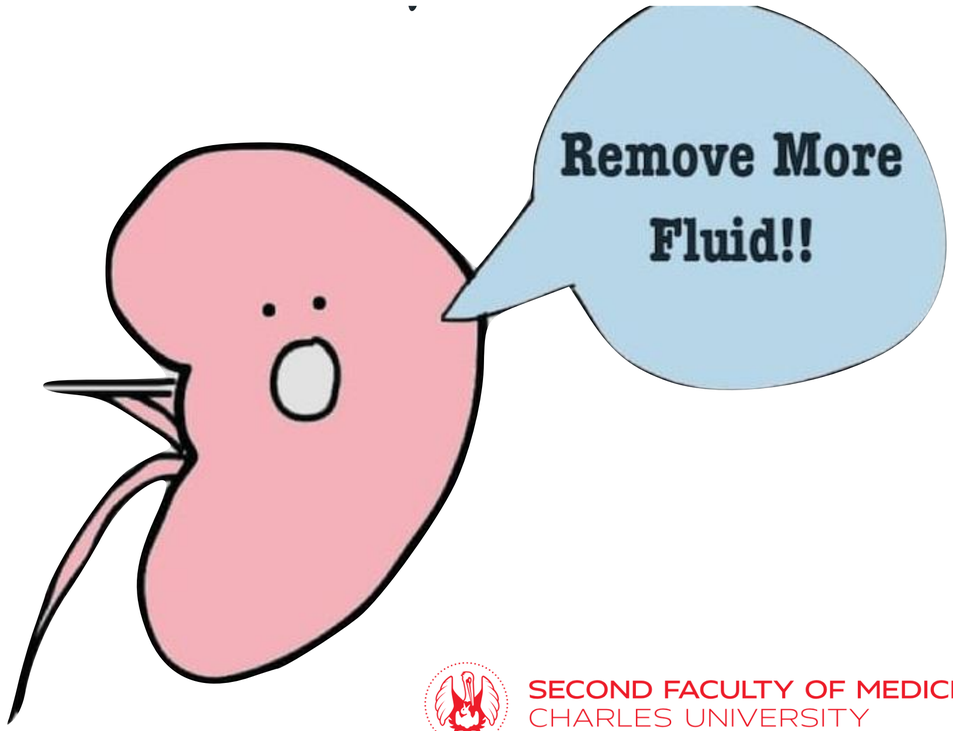

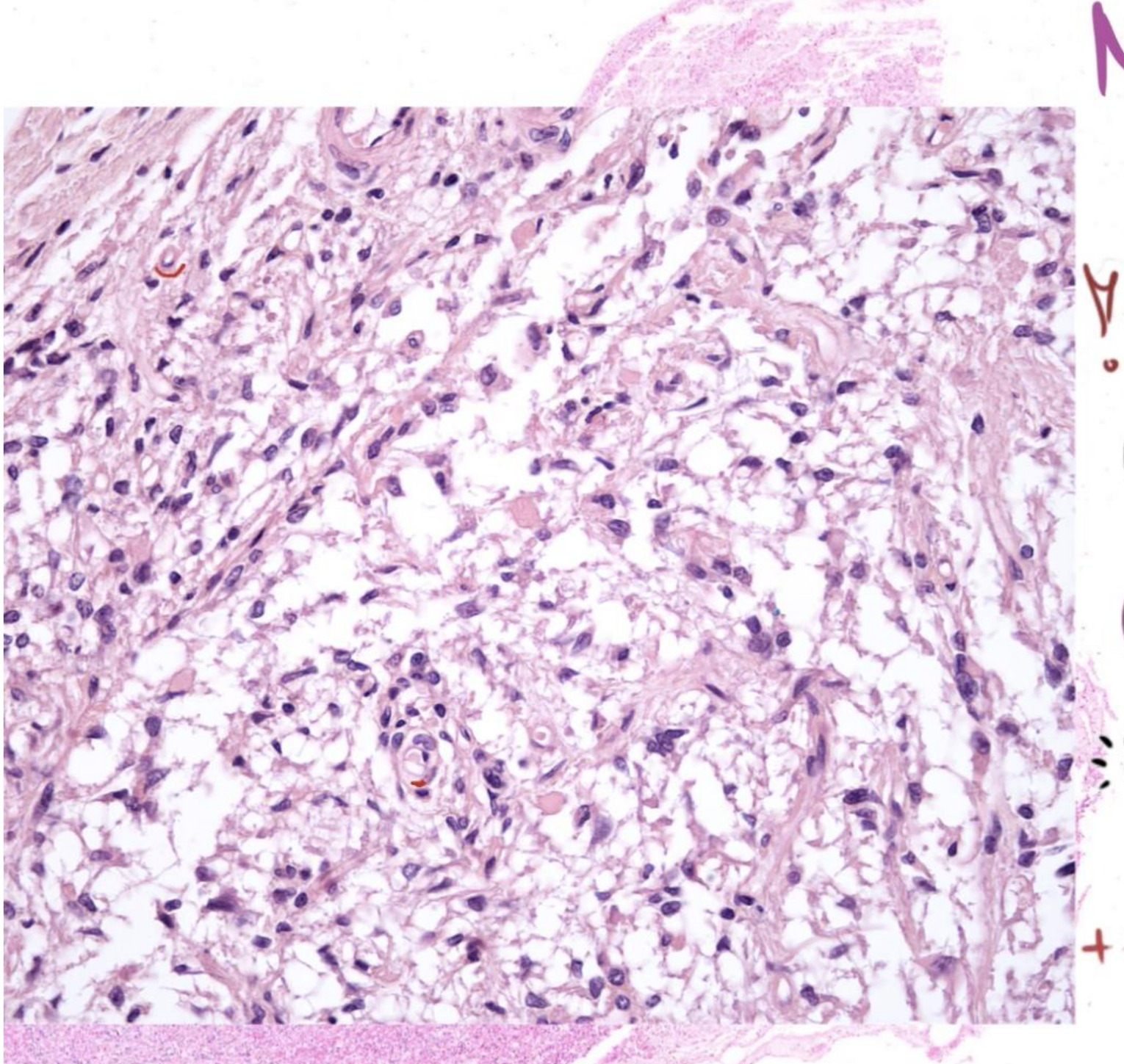

NEUROHYPOPHYSIS

PARS NERVOSA

⇓

! ~~SECRETORY~~ CELLS

COMPOSED OF:

NEURAL TISSUE
(UNMYELINATED AXONS)

+

SPECIAL GLIAL CELLS

PITUICYTES

+ FENESTRATED CAPILLARIES

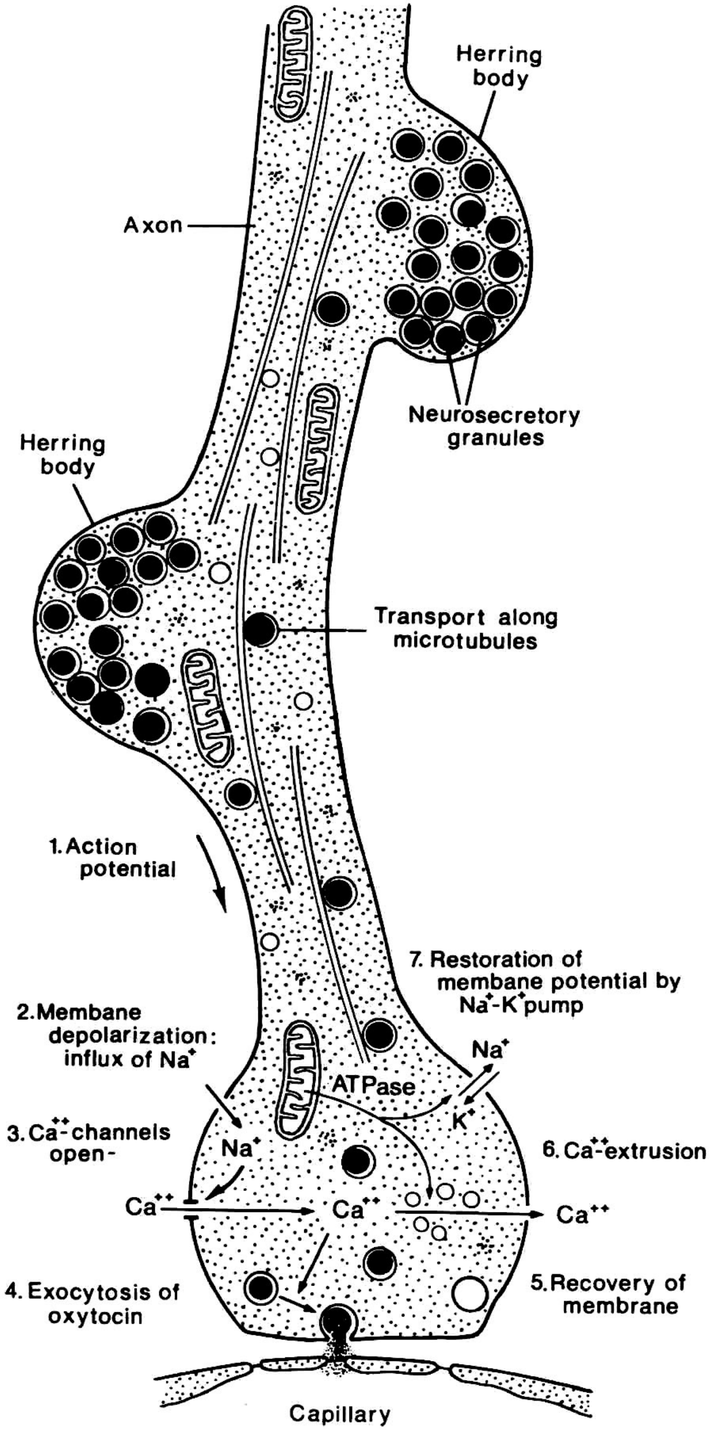

SECOND FACULTY OF MEDICINE
CHARLES UNIVERSITY

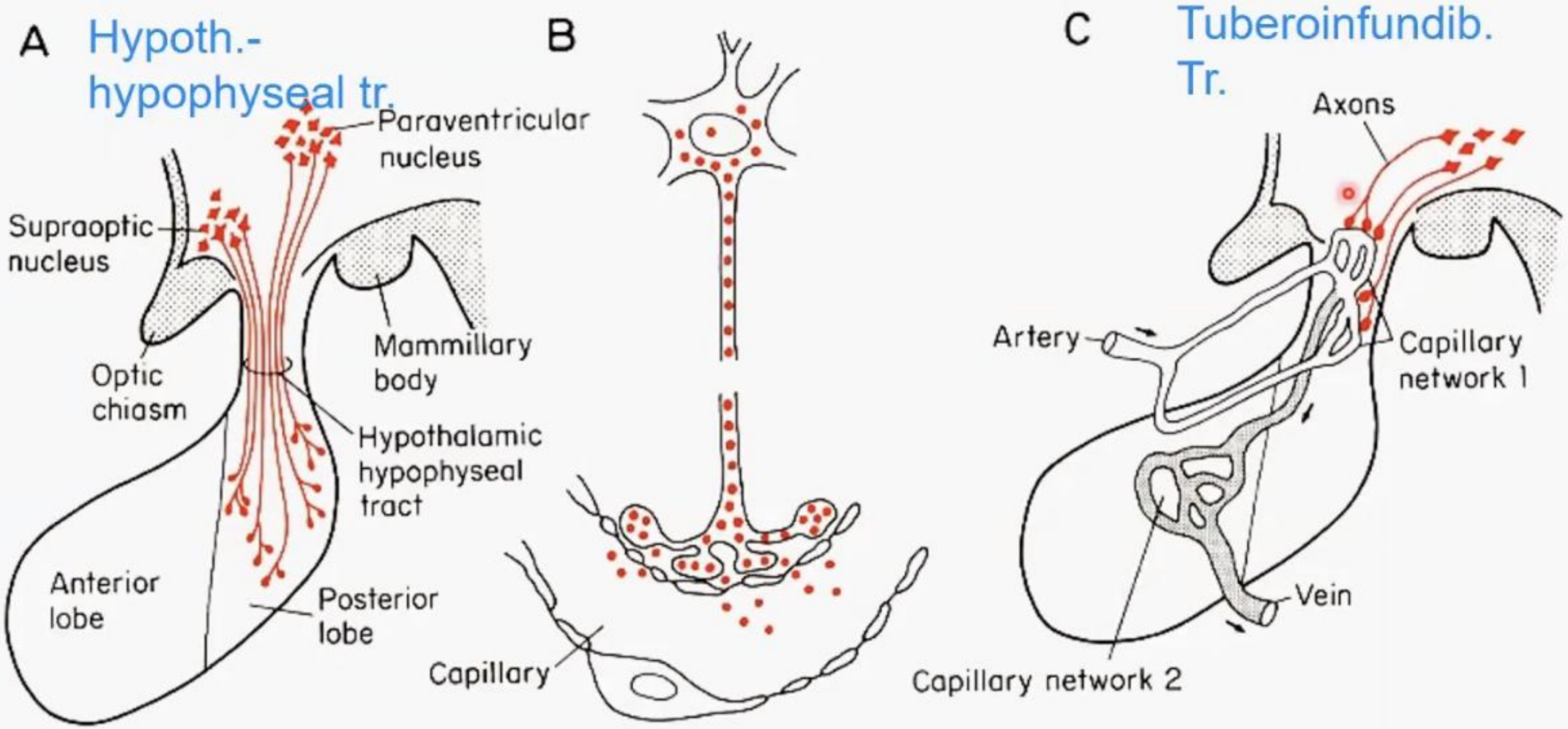

Fig. 15.5. *The relationship between the hypothalamus and the pituitary gland.* **A.** Connections from the hypothalamus to the posterior lobe. **B.** Axonal transport of peptide hormones (neuropeptides) from the hypothalamus to the pituitary. **C.** The portal vessels of the pituitary stalk ensure that releasing hormones (factors) are transported from the median eminence in the upper part of the stalk to the epithelial cells of the anterior lobe.

EDICINE

Šišinka (epifýza, corpus pineale)



Šišinka

- za horním zadním koncem

III. komory

- součást epithalamu
- “rudimentární” endokrinní žláza s tlumivým účinkem na činnost pohlavních žláz →pubertas praecox
- dorzálně vybíhá nad mozkový kmen (nad čtverohrbolí středního mozku)
- ***melatonin***
- acervulus cerebri = corpora arenacea

= vápenaté konkrementy
u dospělých) – CT, MRI

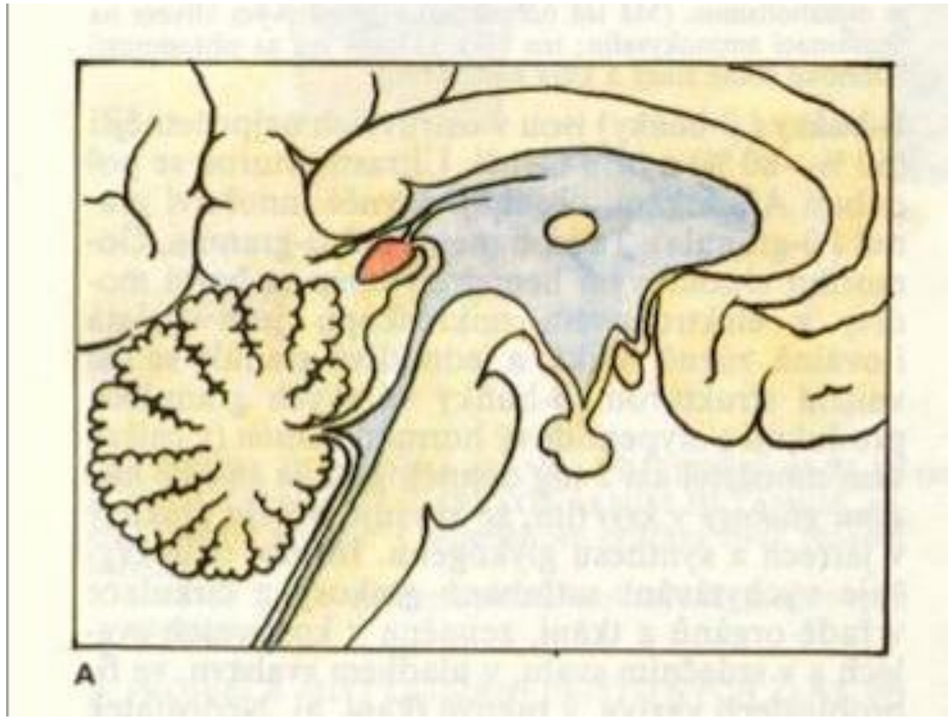

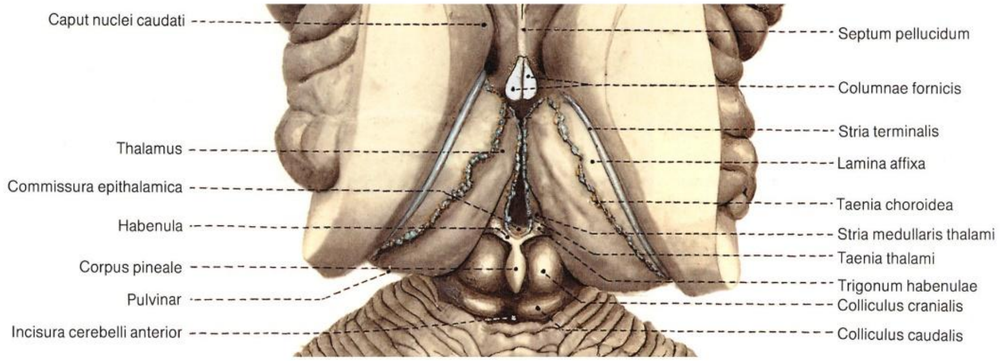

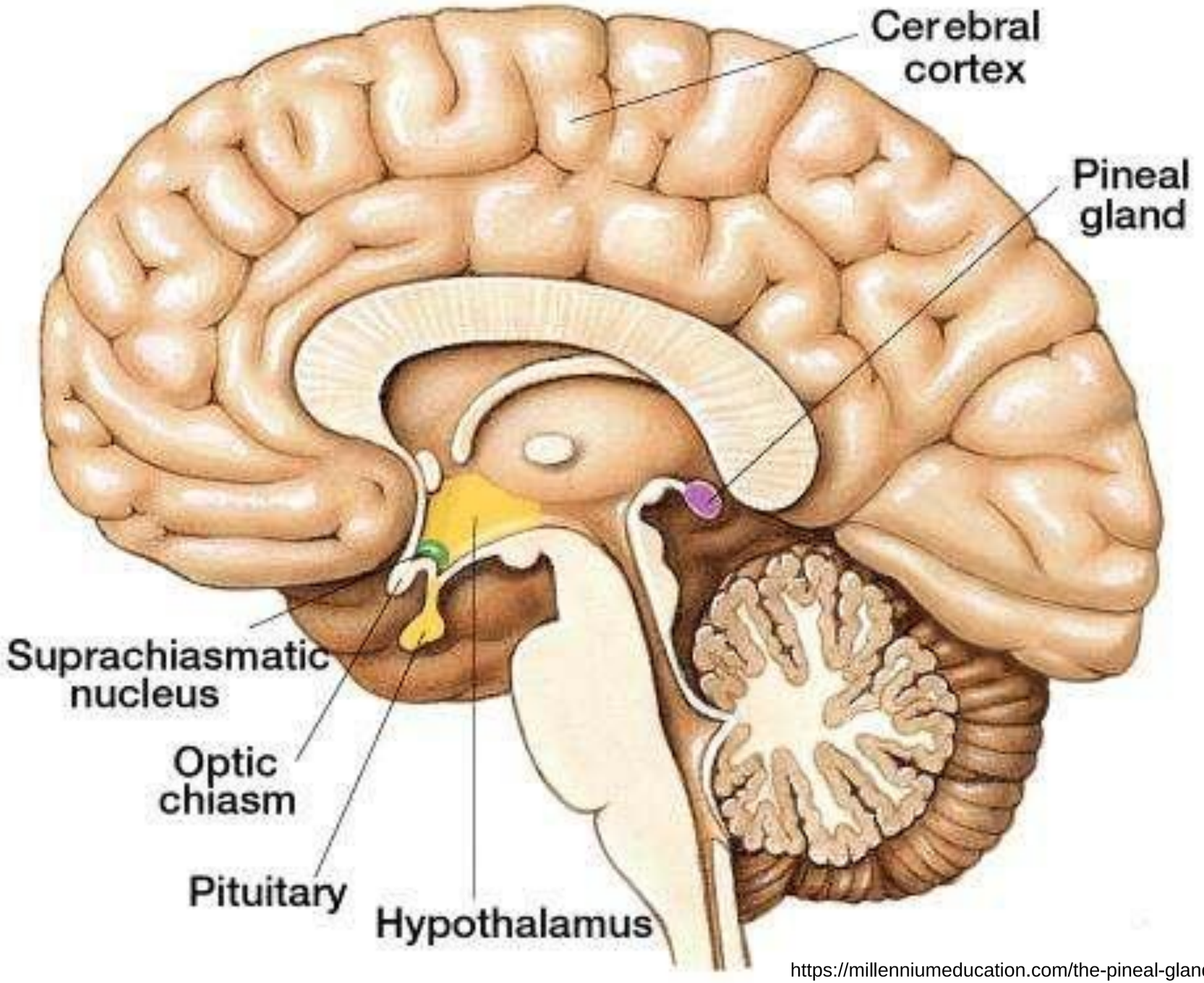

https://millenniumeducation.com/the-pineal-gland/

Šišinka – stavba

- pouzdro z ***pia mater*** → přepážky
- hlavní buňky (***pinealocyty*** = *neurony*) – 95 %, velká jádra
  - tvorba **melatoninu**
    - změna hladiny během dne
- intersticiální/astrogliové buňky (*astrocyty*)
  - tmavé tyčinkovité jádro
- n. pinealis → neurofibra non myelinata

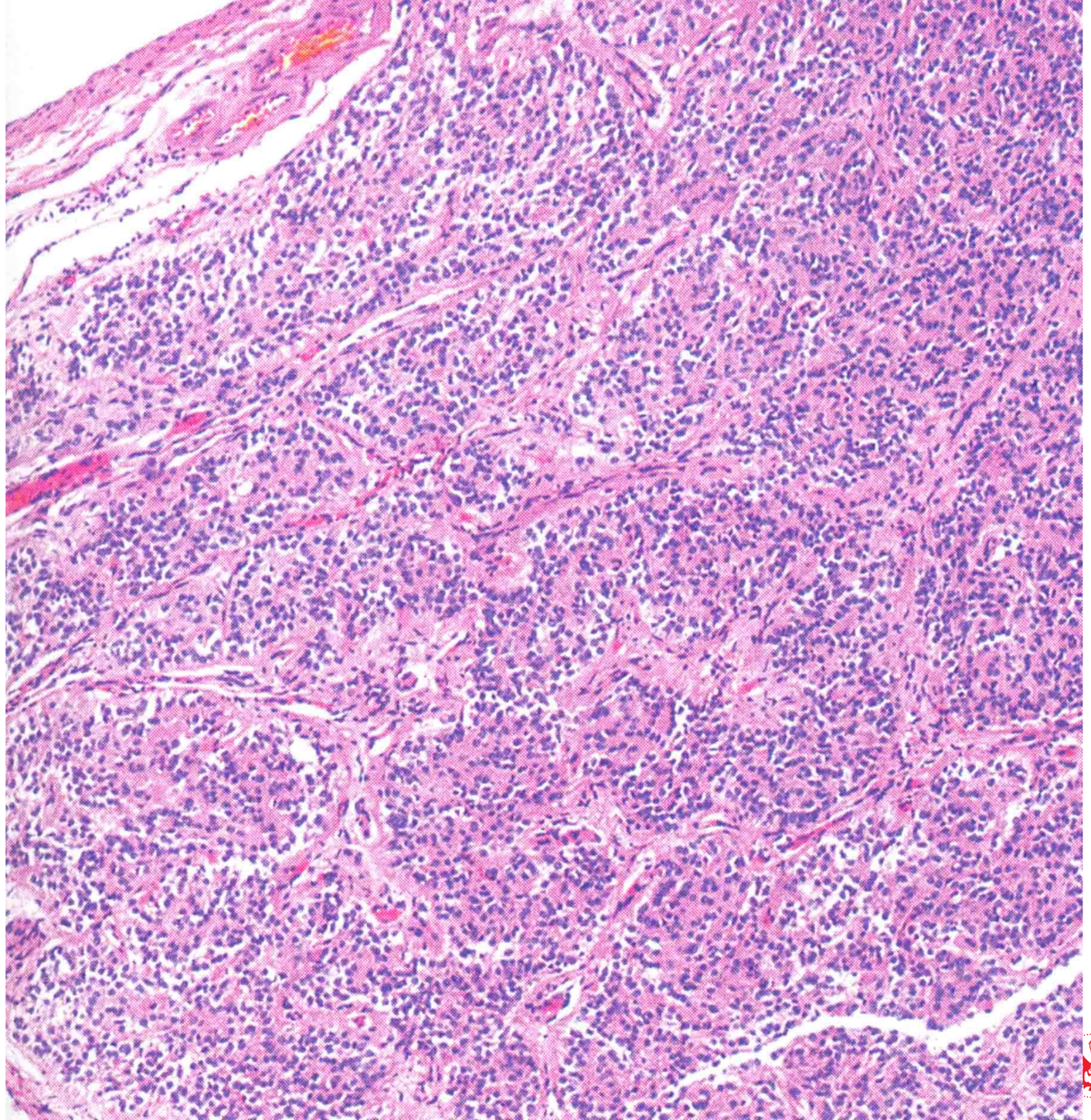

SECOND FACULTY OF MEDICINE
CHARLES UNIVERSITY

Šišinka – písek

acervulus cerebri; corpora arenacea (mozkový písek)

konkrementy bílkovinného materiálu s vápenatými solemi

- počet stoupá s věkem
- CT, MRI

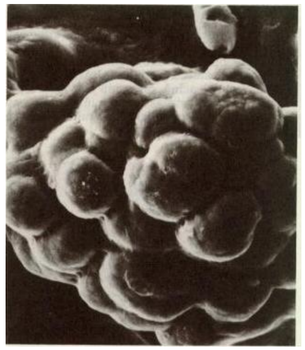

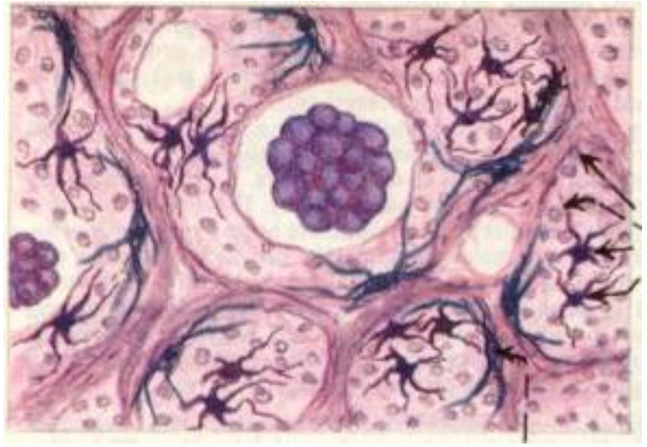

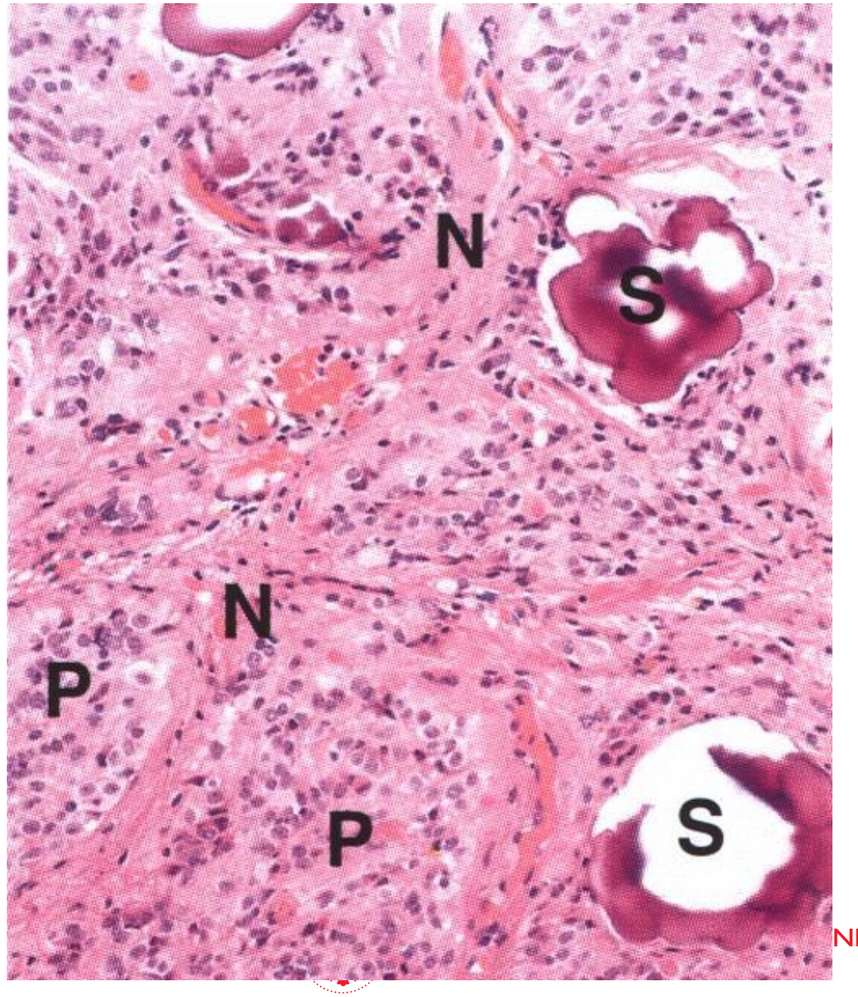

Pi = pinealocyty
Ng = neurogliové buňky
BS = acervulus cerebri
šipka = lamely

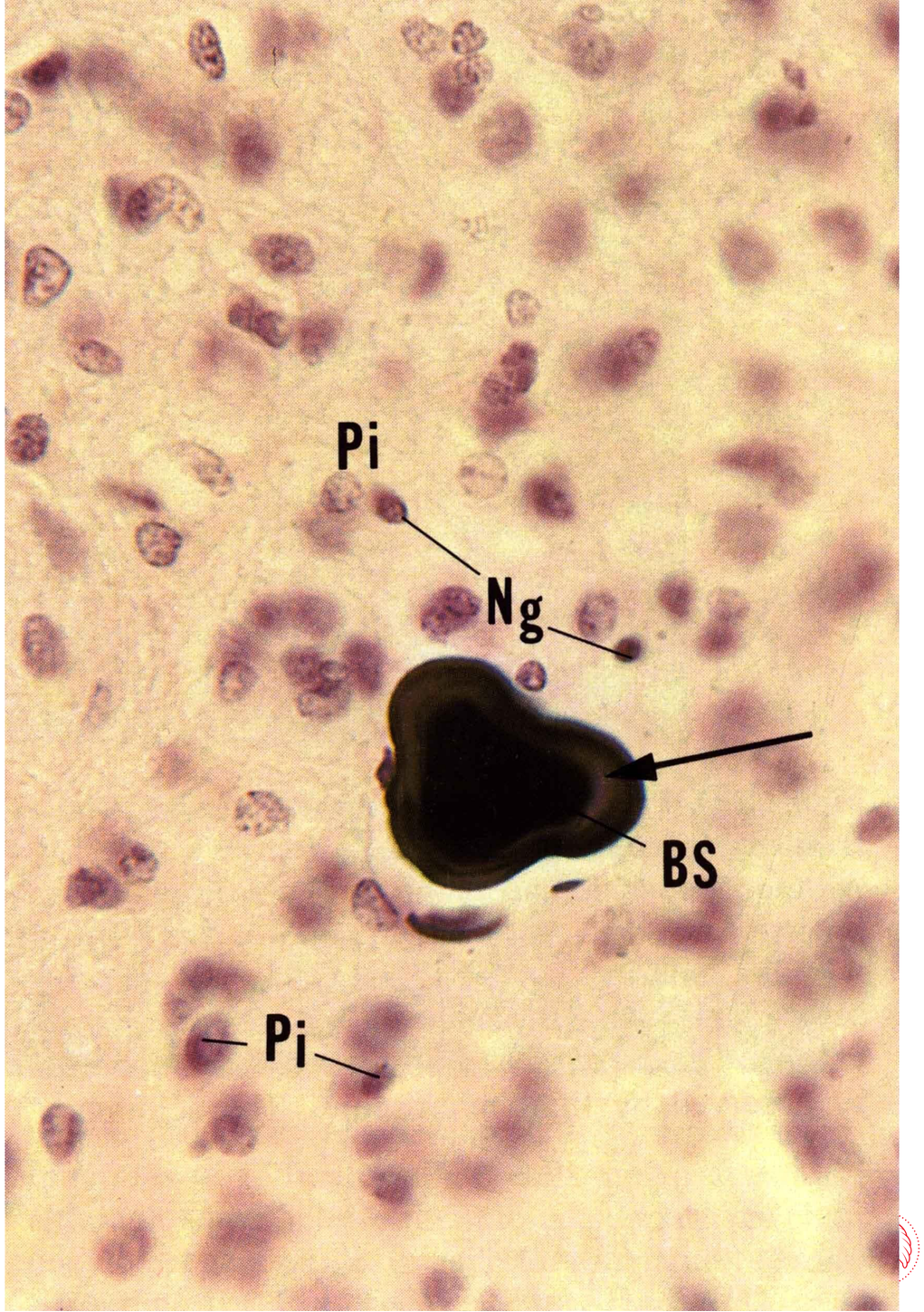

Štítná žláza (glandula thyroidea)

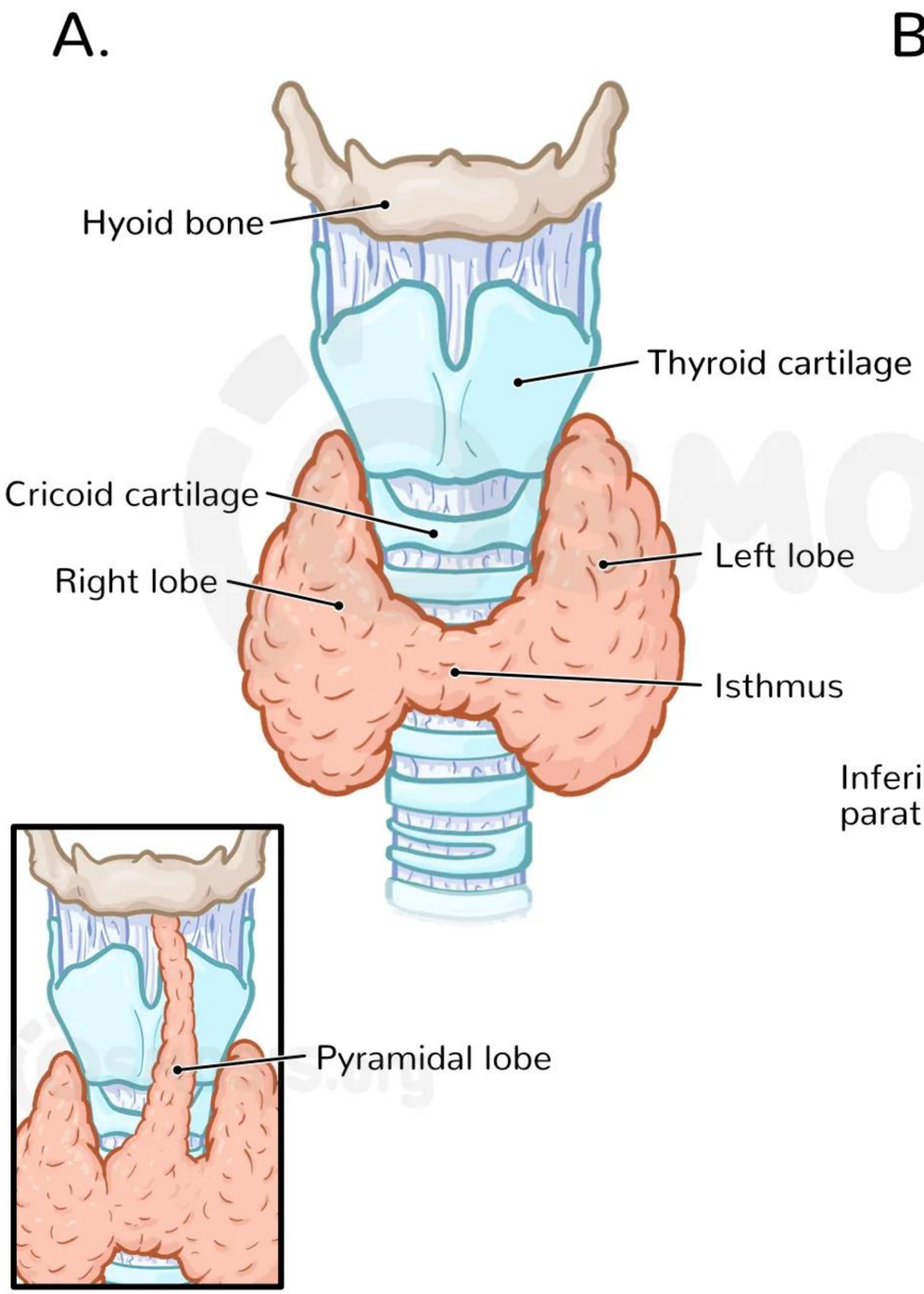

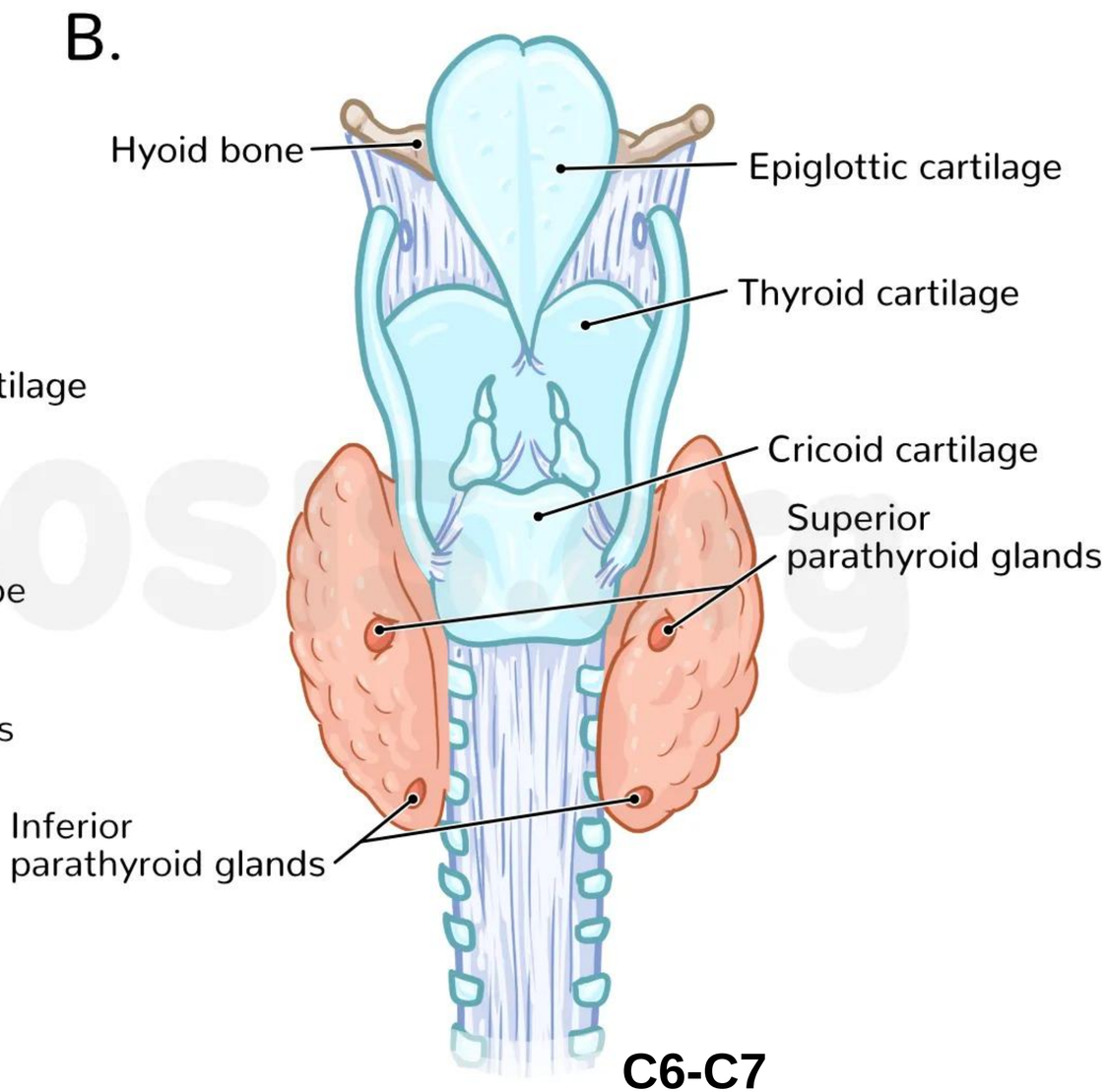

C6-C7

isthmus na 2.-4. průdušnicové chrupavce

Y OF MEDICINE
RSITY

Štítná žláza – krevní cévy

- a. thyroidea superior (← a. carotis externa)
- a. thyroidea inferior (← truncus thyrocervicalis)
  – ***křížení s n. laryngeus recurrens***
- a. thyroidea ima *Neubaueri* (← arcus aortae)
  – 2 %

- vv. thyroideae superiores et mediae → vv. jugularis interna
- vv. thyroideae inferiores → plexus thyroideus impar → v. brachiocephalica sinistra

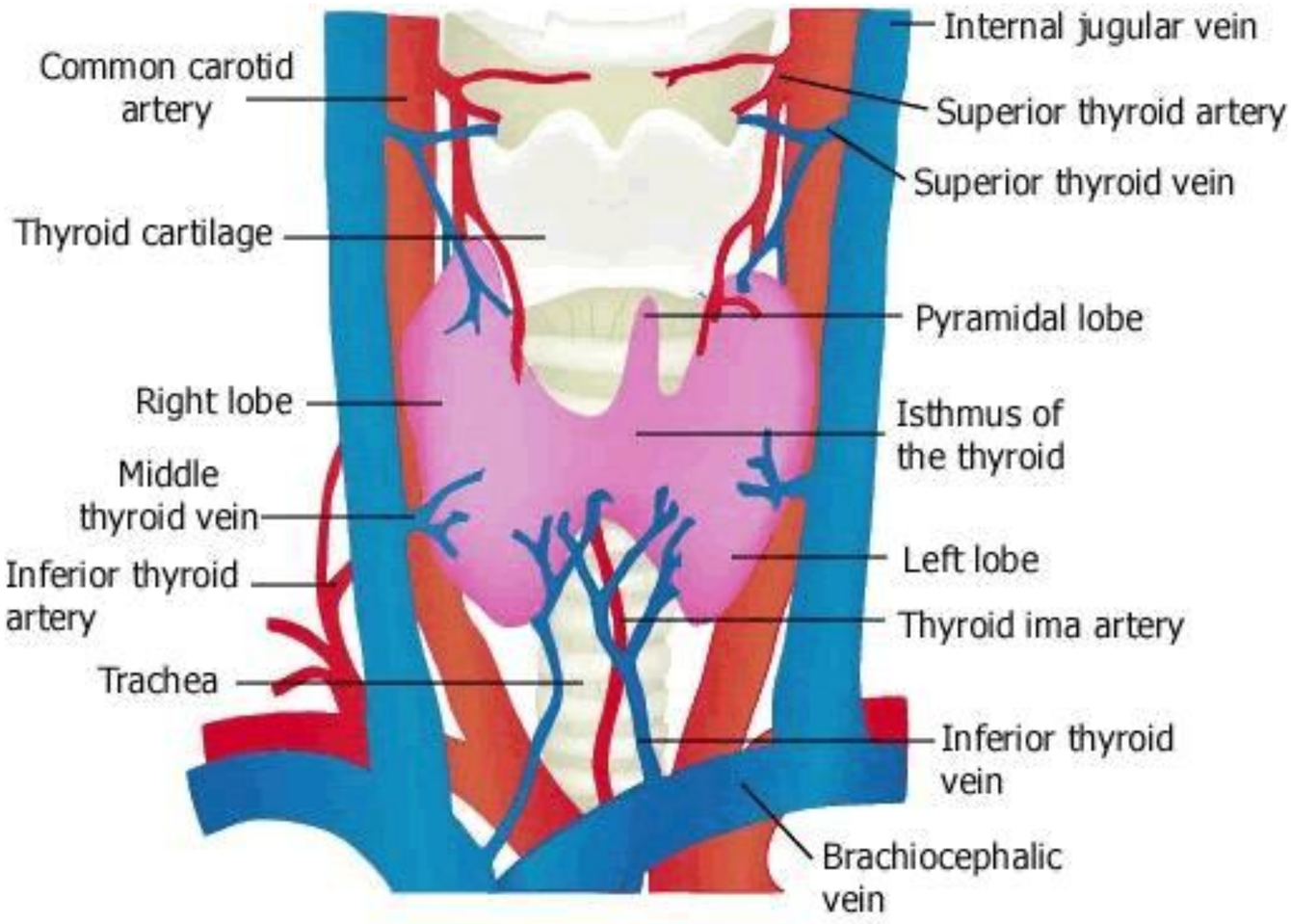

- lymfatické cévy z horní oblasti laloků a isthmu - > jugulární LU
- z dolních oblastí -> pre-, paratracheální a prelaryngeální LU
- pretracheální LU v blízkosti isthmu - the ***Delphian*** *node*

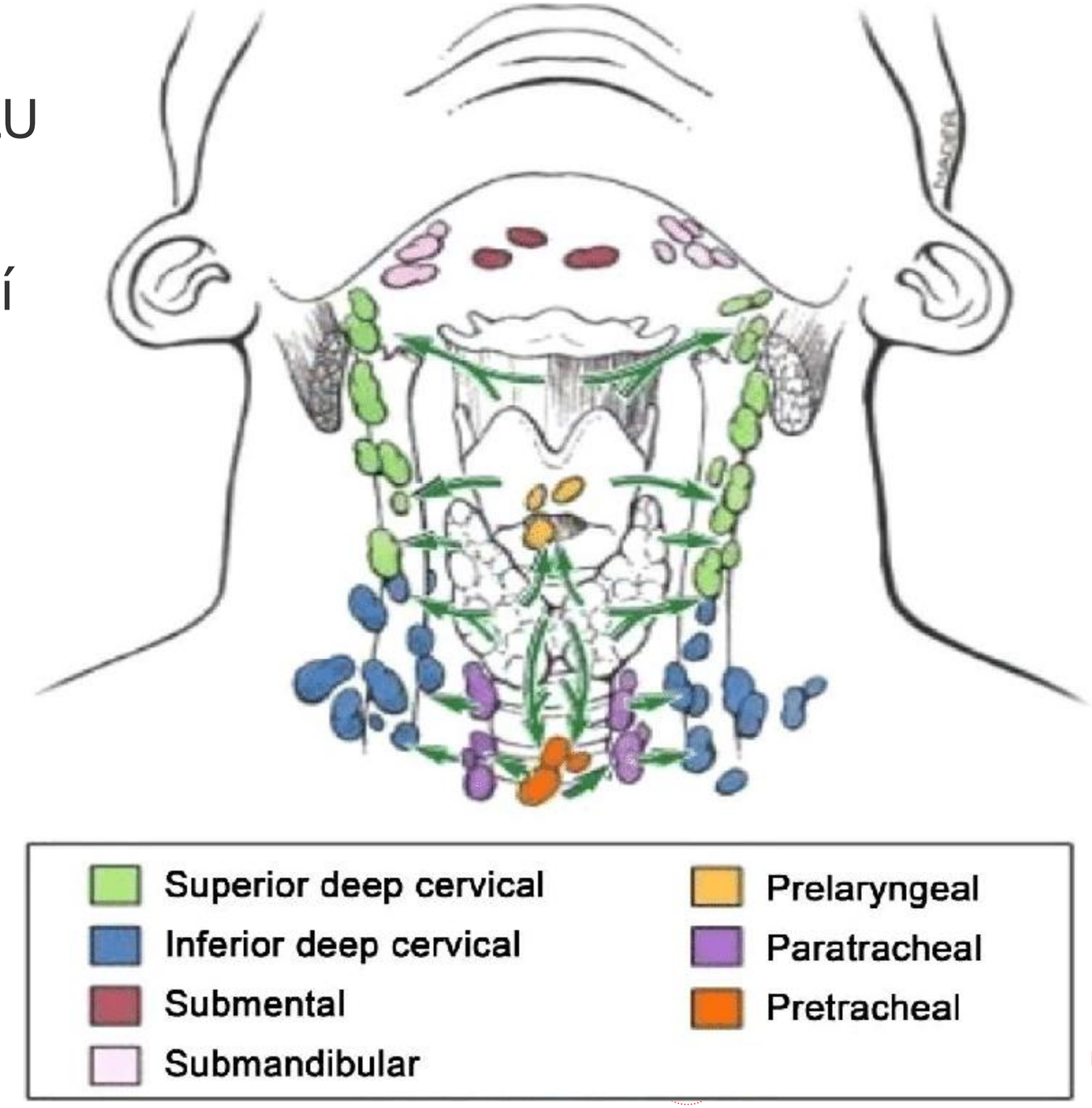

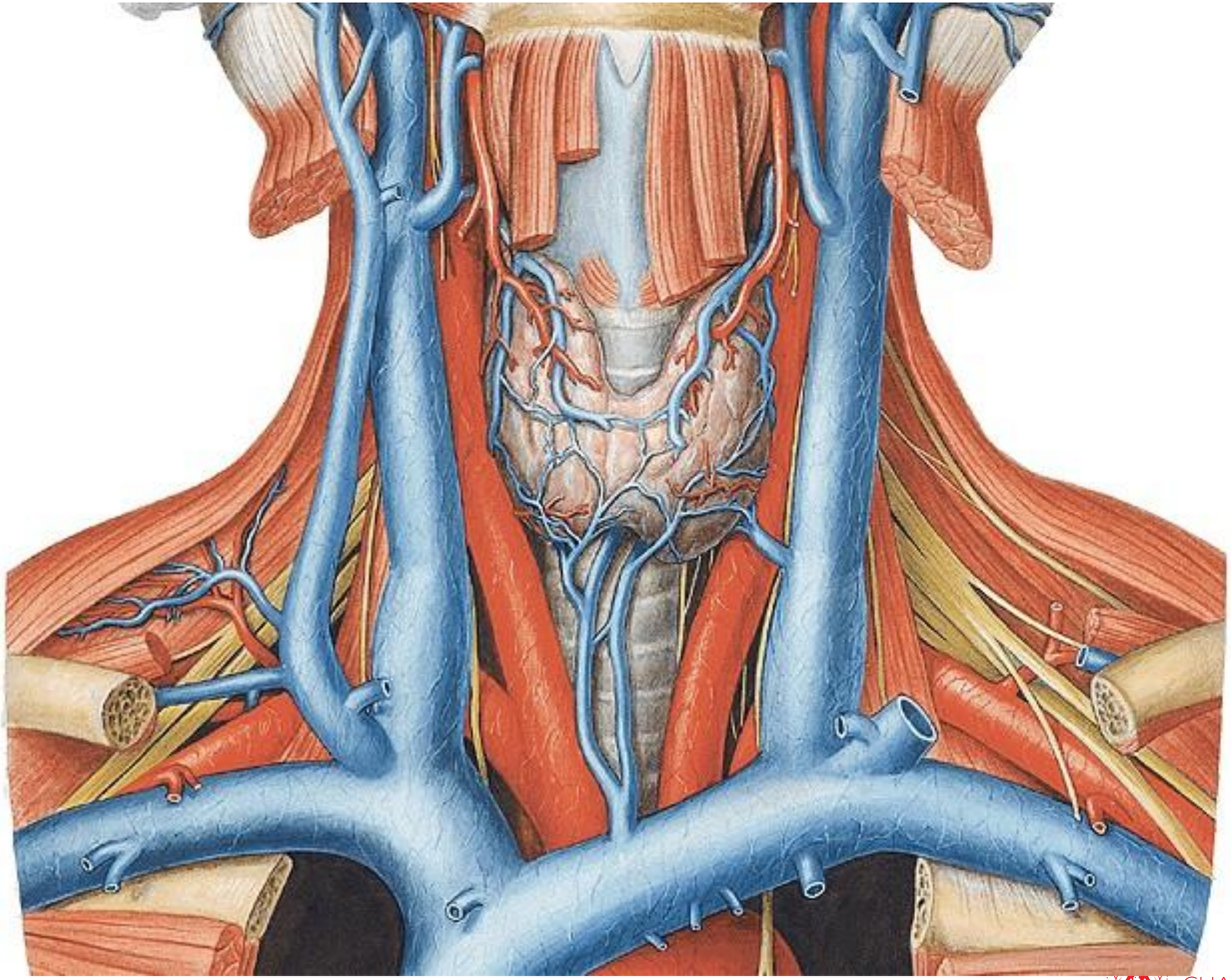

ULTY OF MEDICINE
CHARLES UNIVERSITY

Štítná žláza – vývoj

- vývoj od 24. dne
- výchlipka endodermu primitivního hltanu
- relativní i absolutní sestup → *ductus thyroglossus*
- *foramen caecum*
- *gll. thyroideae accessoriae*
- vznik laloků
- *lobus pyramidalis*
- *ligamentum suspensorium gl. thyroideae / musculus levator glandulae thyroideae* (hladký)

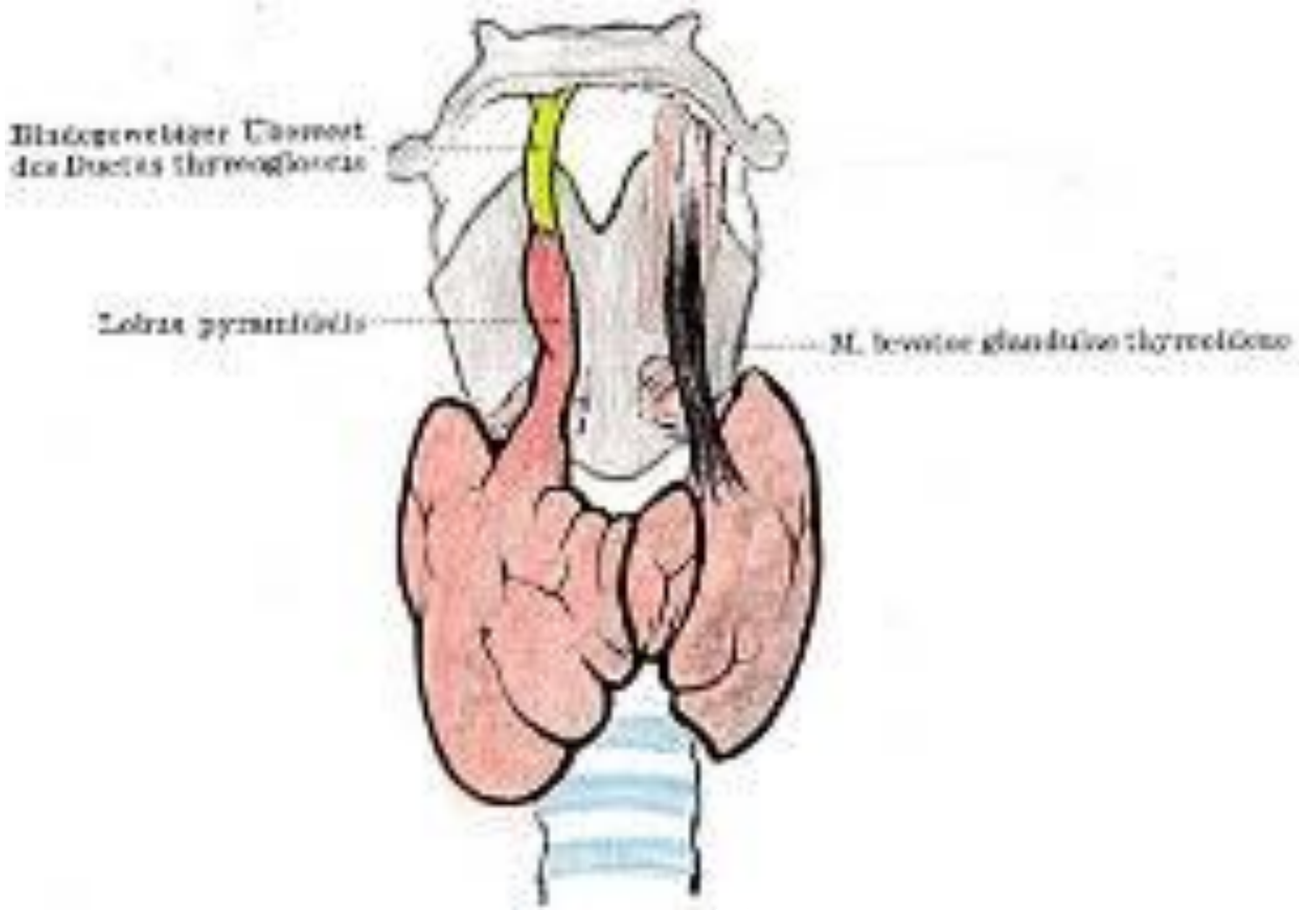

t
í
t
n
á

ž
l
á
z
a

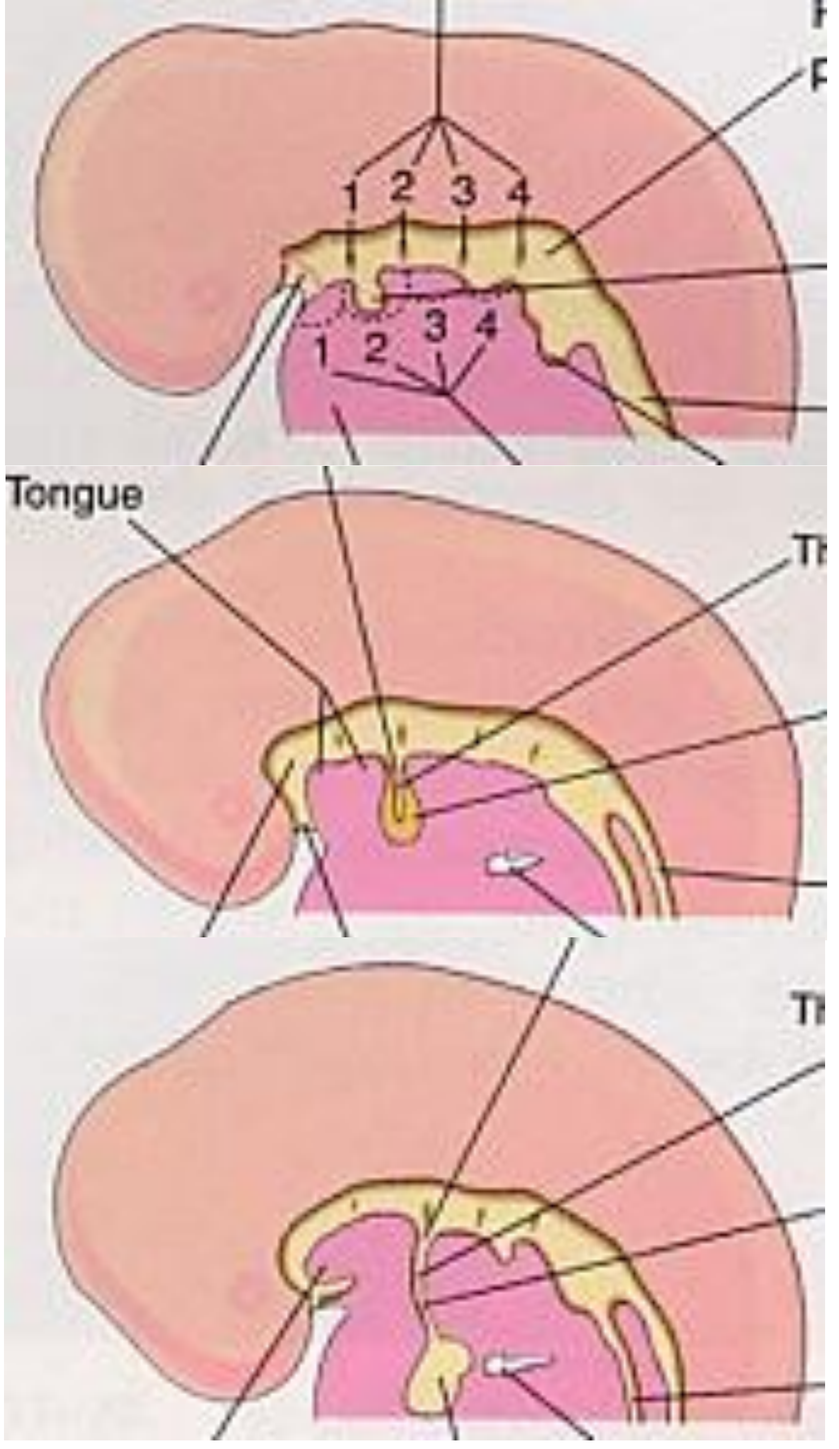

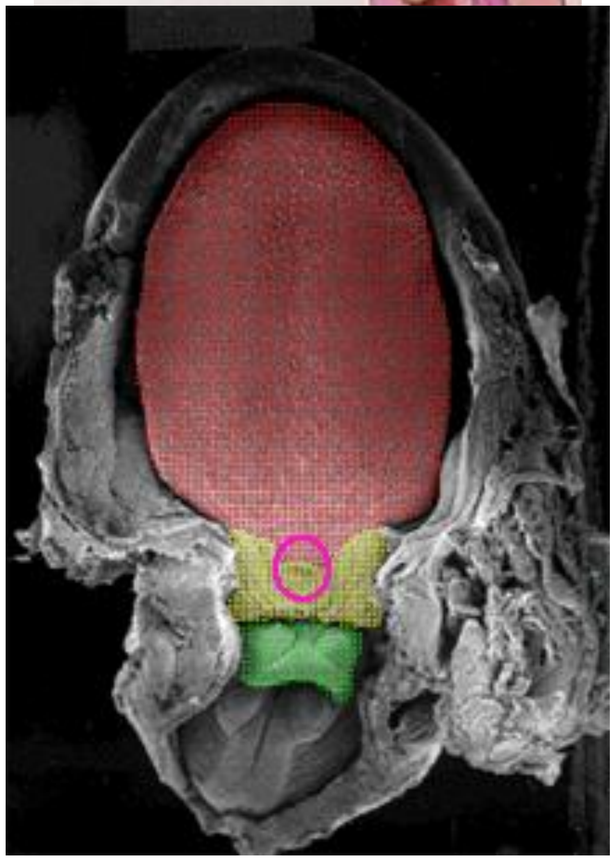

V
ý
v
o
j

Development of thyroid gland

(Lateral lingual swelling)

Foramen caecum

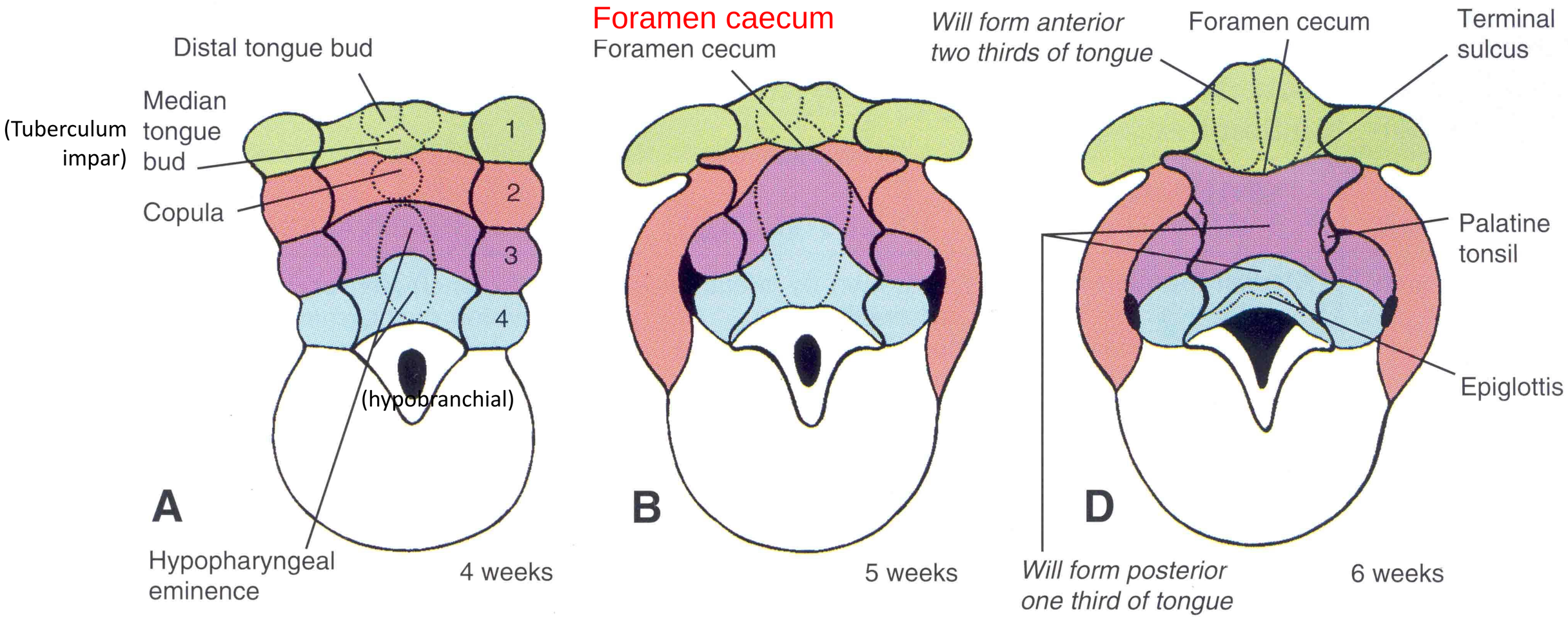

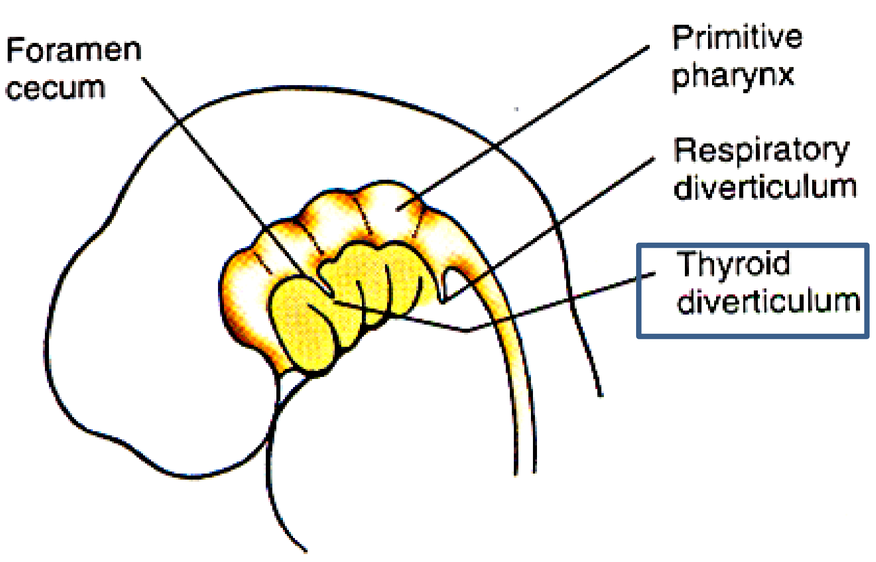

4th week

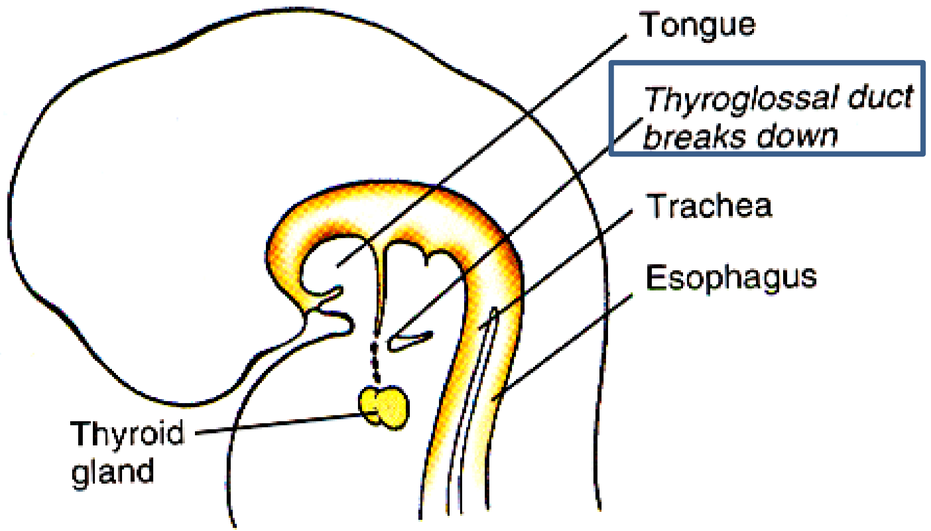

Late 5th week

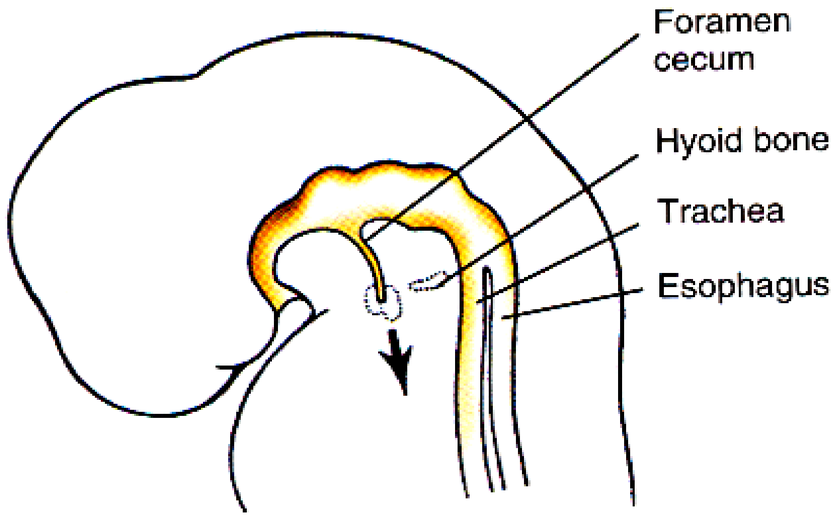

Early 5th week

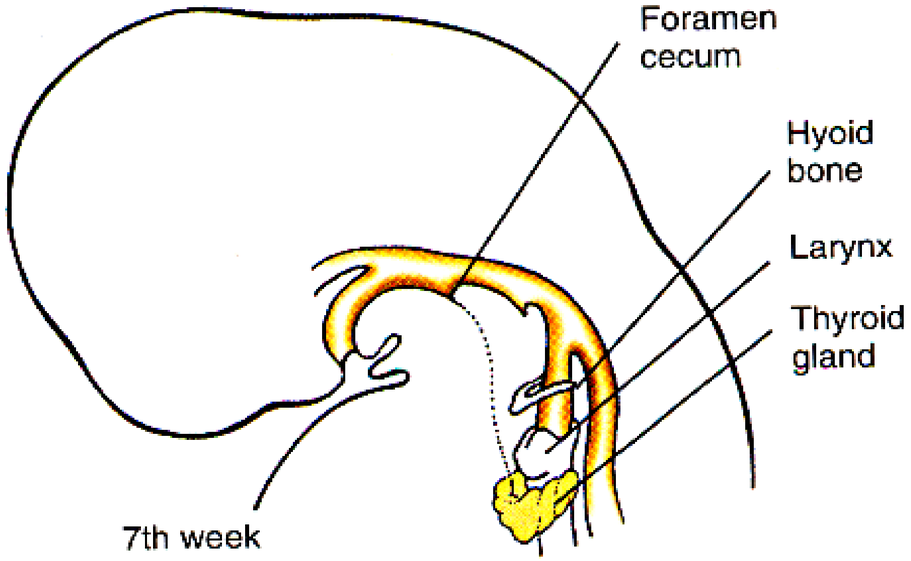

7th week

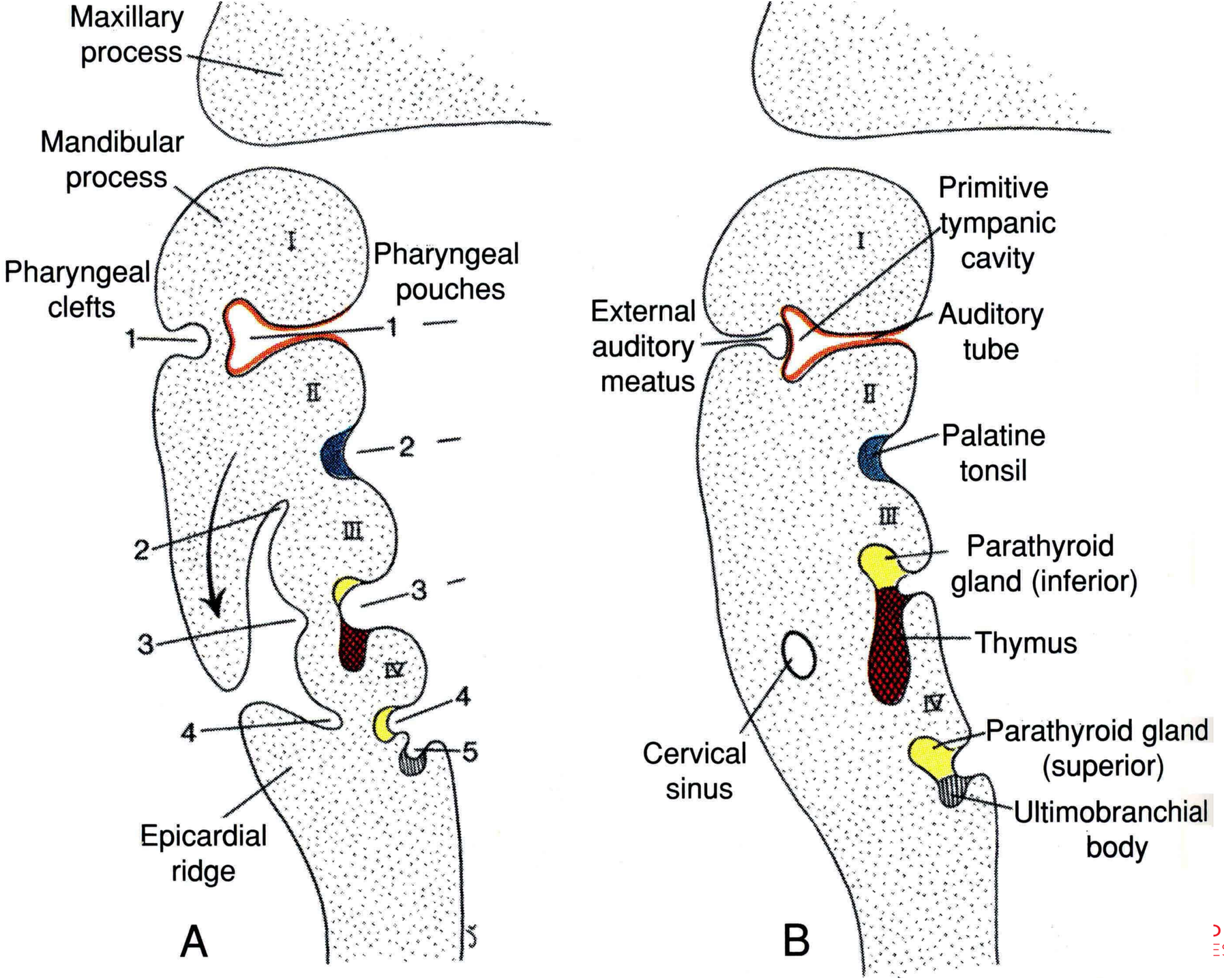

FACULTY OF MEDICINE
ES UNIVERSITY

Štítná žláza – stavba

- pouzdro (*capsula fibrosa*)
- stroma
- septa (přepážky mezi lalůčky)
- lobus → lobulus → folliculus
- folikuly (50–900 µm) – kulovité útvary
  - jednovrstevný epitel folikulárních buněk
  - obsahuje *colloidum* (koloid) – tyroglobulin
- **folikulární buňky**
  - tyroglobulin, vyštěpení T_4 a T_3
- **parafolikulární buňky** (C-buňky)
  - derivát neurální lišty z ultimofaryngového tělíska
  - leží mezi folikulárními buňkami (jednotlivě, “skupinky”),
  - bez kontaktu s koloidem
  - tvorba a střádání **kalcitoninu**

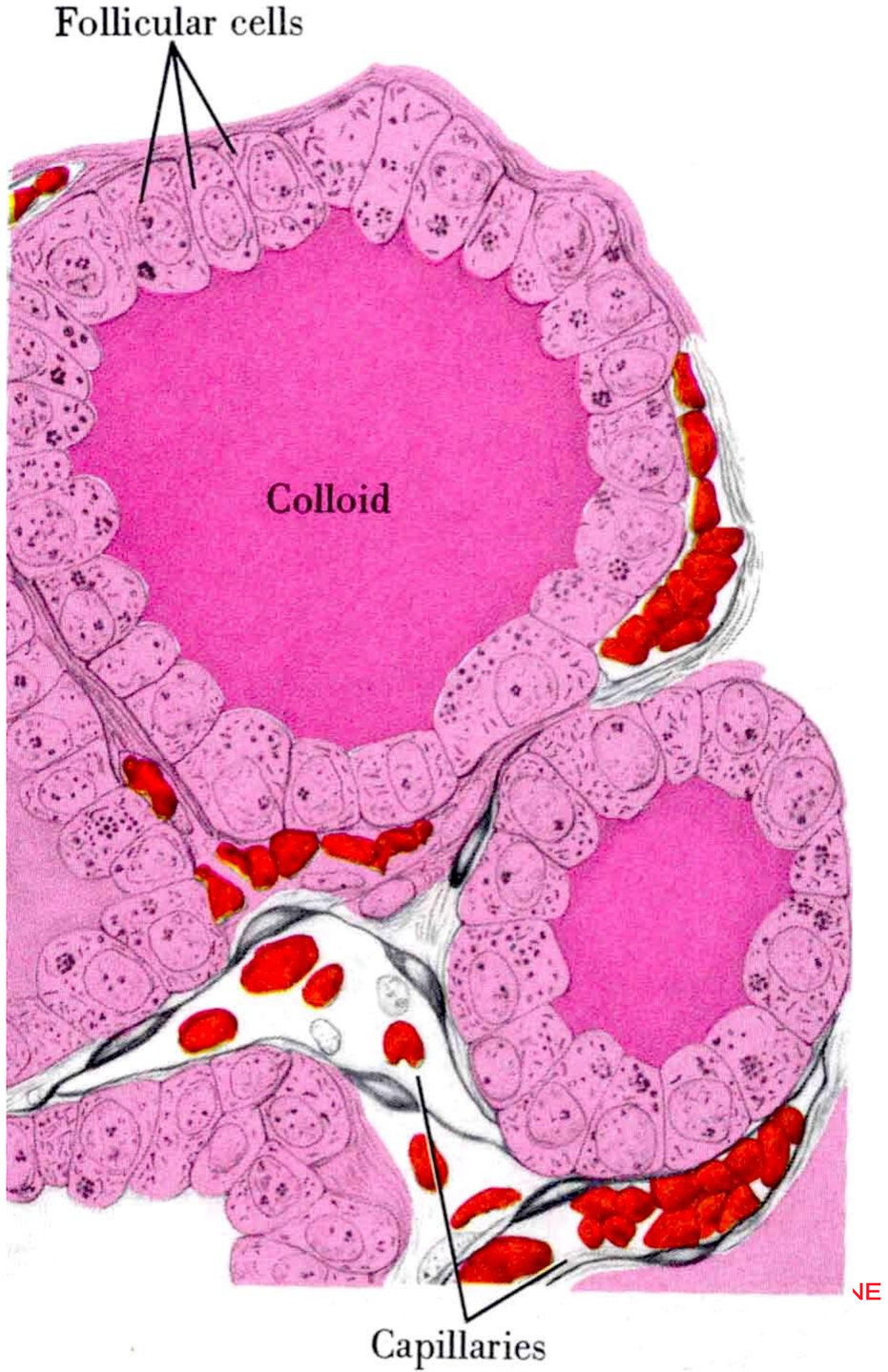

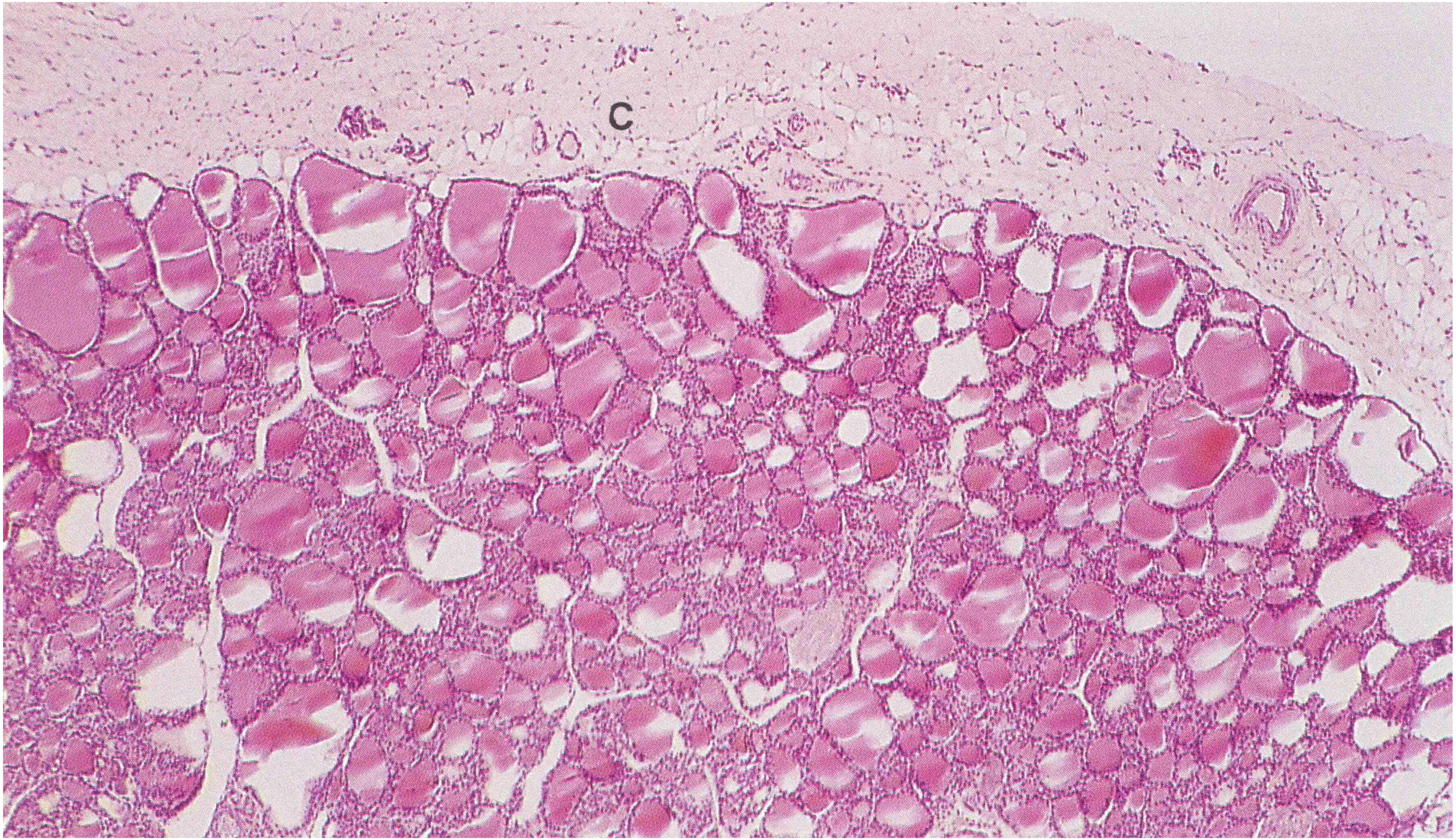
C

Thyrocyty (folikulární buňky) - folikuly
Stroma: retikulární vazivo

TE = epitel folikulu
BM = bazální membrána
TC = koloid
C = kapilára

FACULTY OF MEDICINE
UNIVERSITY

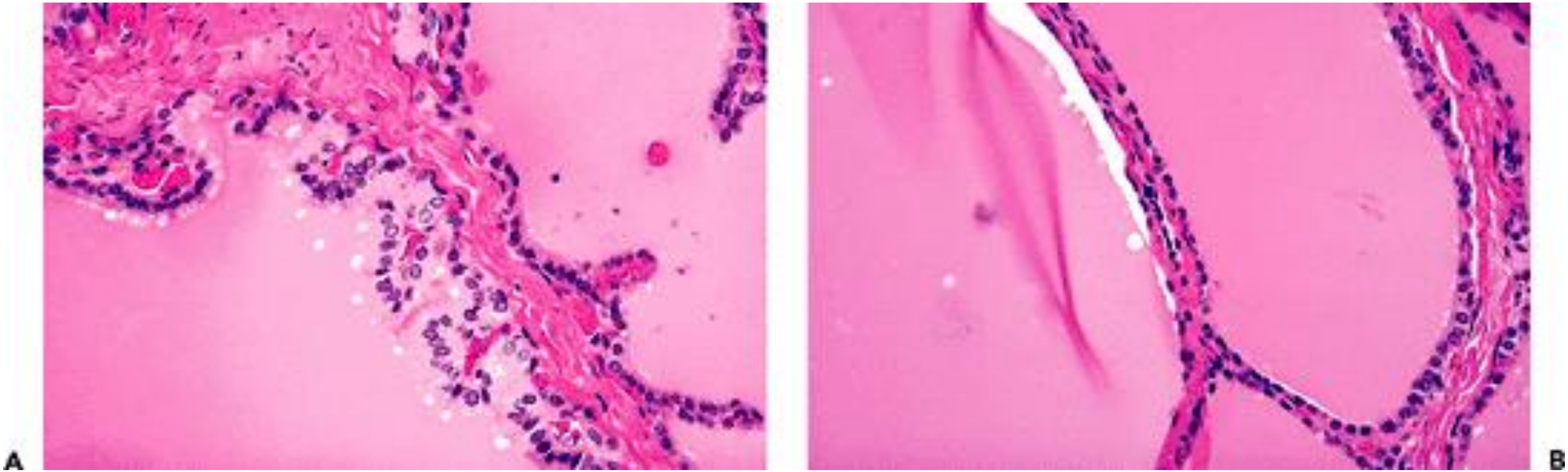

A The epithelium of one follicle is low cuboidal and relatively inactive. The adjacent follicle shows a taller epithelium and reabsorption vacuoles. **B.** The epithelium of the same follicle is flattened on one side and cuboidal on the other, as an expression of functional polarization.

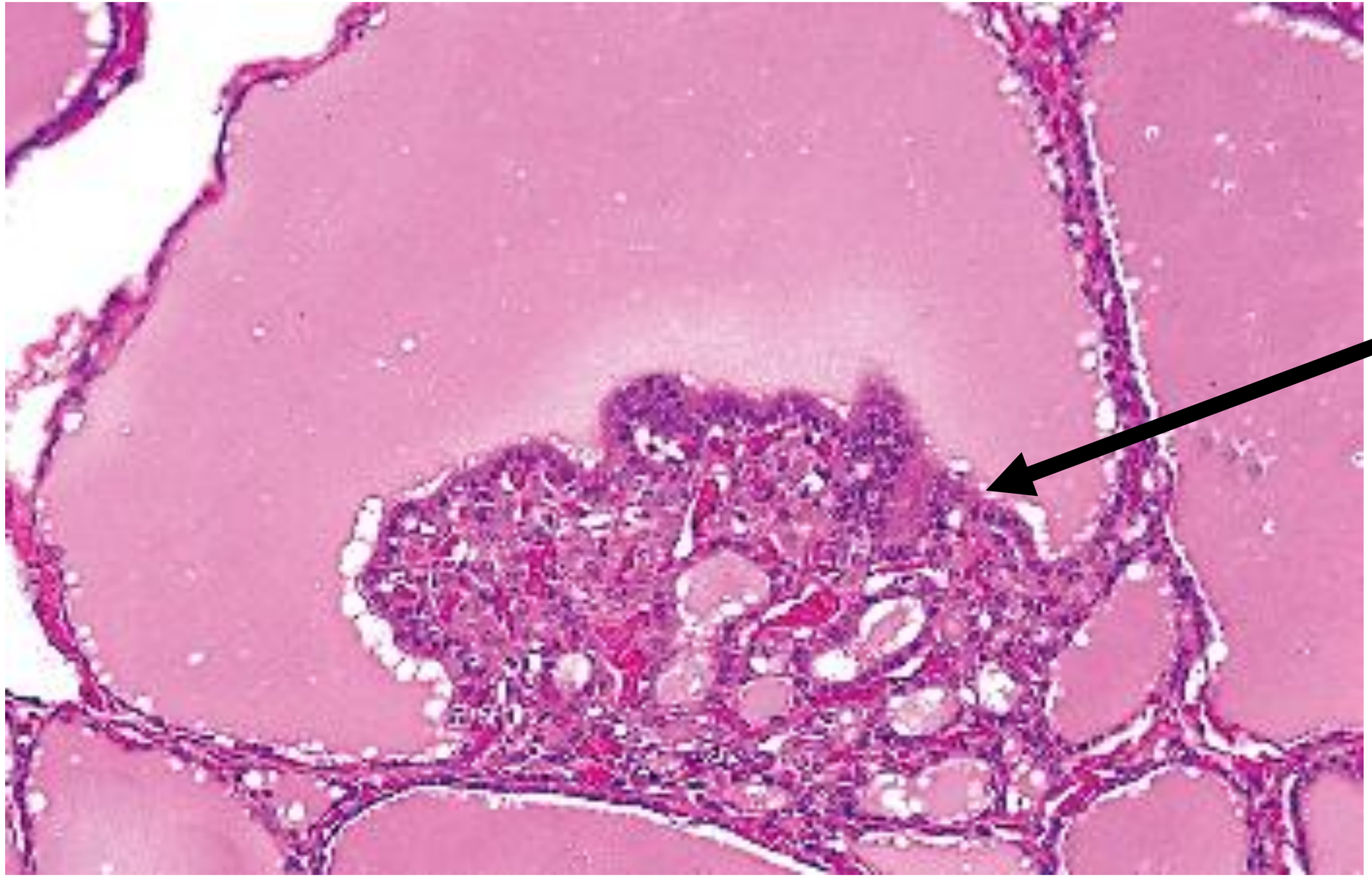

Sandersonův polštářek

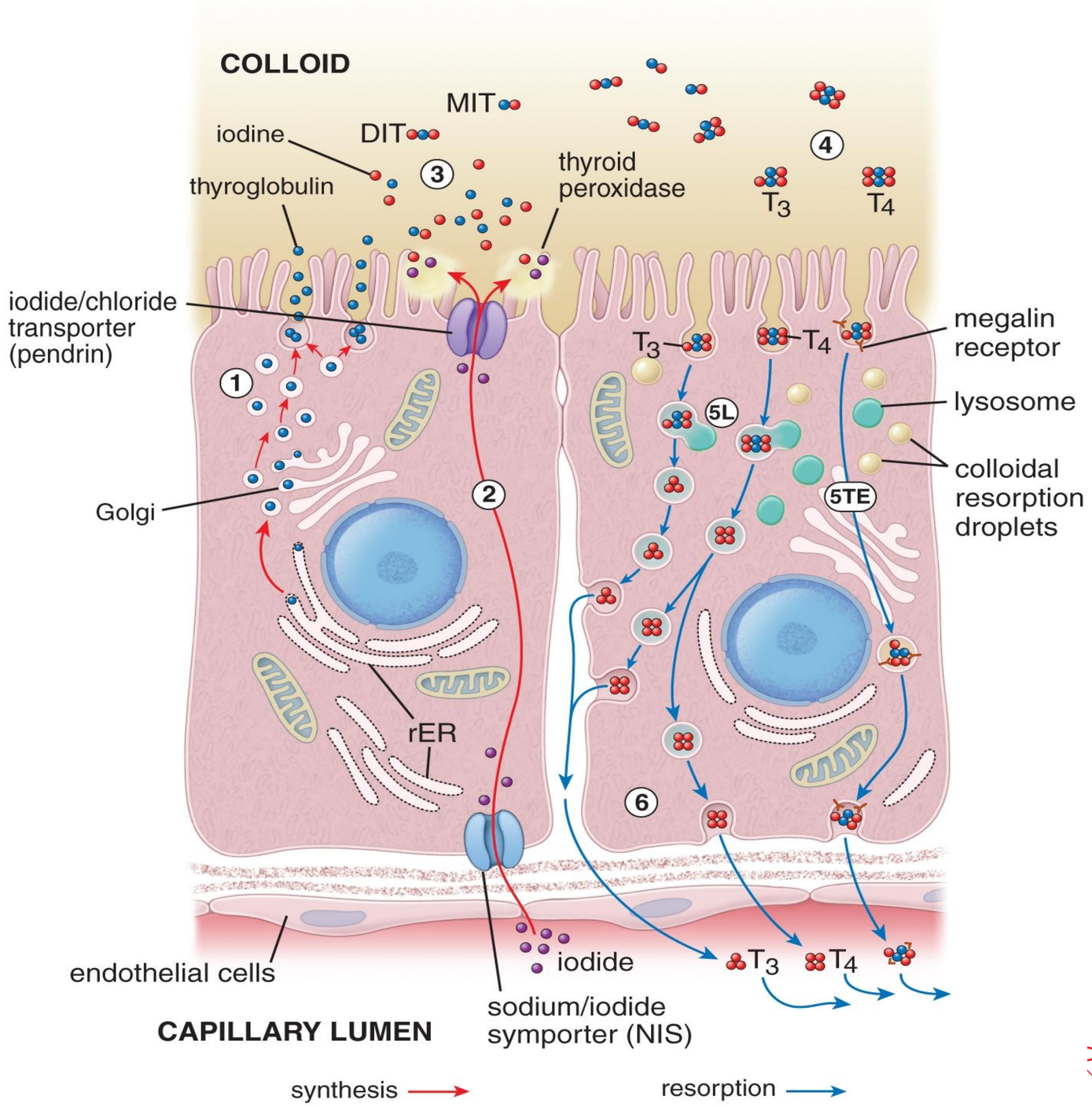

Copyright © 2011 Wolters Kluwer Health | Lippincott Williams & Wilkins

hormony:
T3 (trijódthyronin)
T4 (thyroxin)

CULTY OF MEDICINE
NIVERSITY

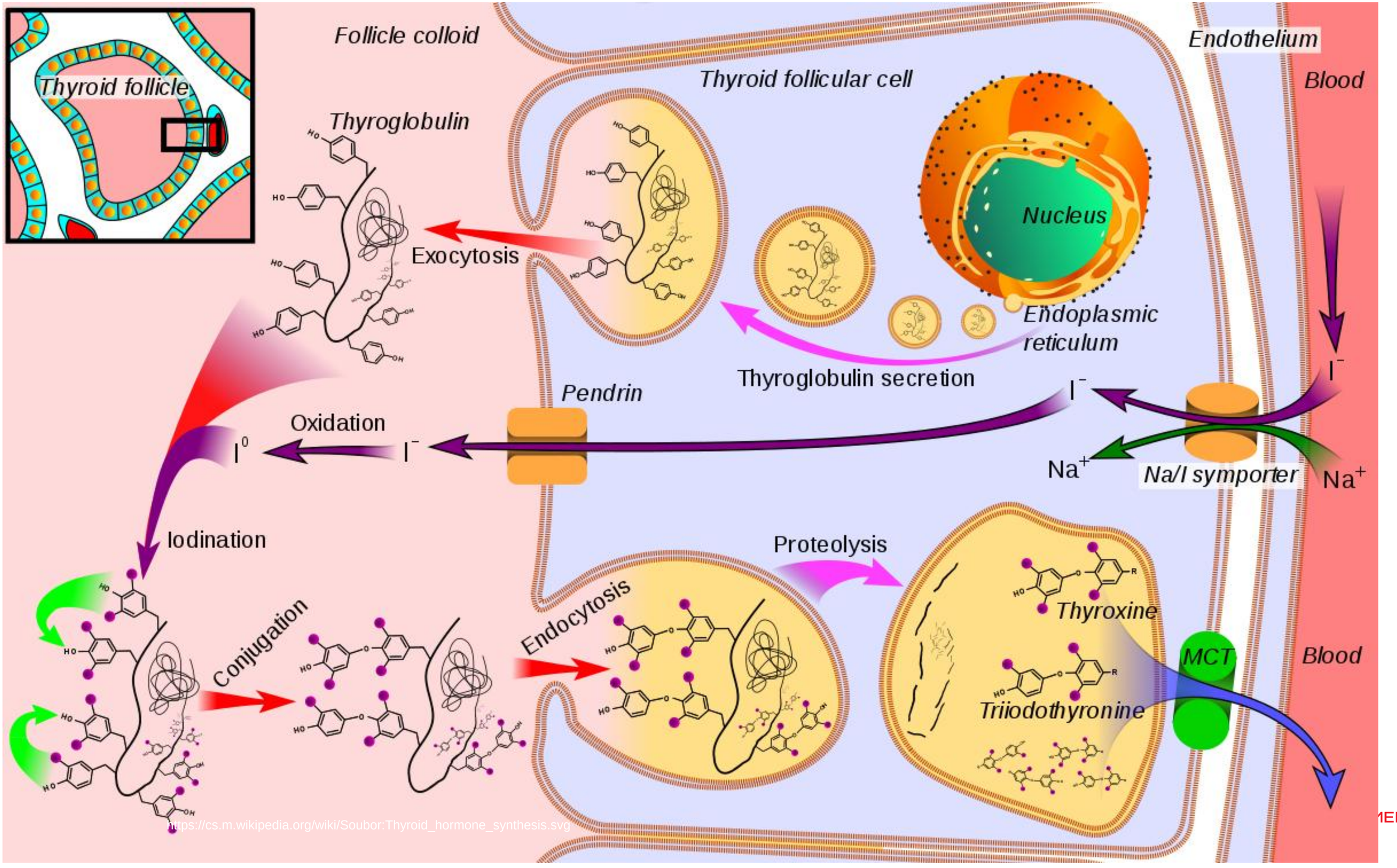

https://cs.m.wikipedia.org/wiki/Soubor:Thyroid_hormone_synthesis.svg

MEDICINE

F = folikulární buňky
T = koloid
C = parafolikulární buňky
BM = bazální membrána
Cap = kapilára
G = Golgiho komplex
V = vesikula obsahující koloid
L = lysosom splývající s vesikulou
rER = granulární ER ve folikulární buňce sousedního folikulu
M = část žírné buňky

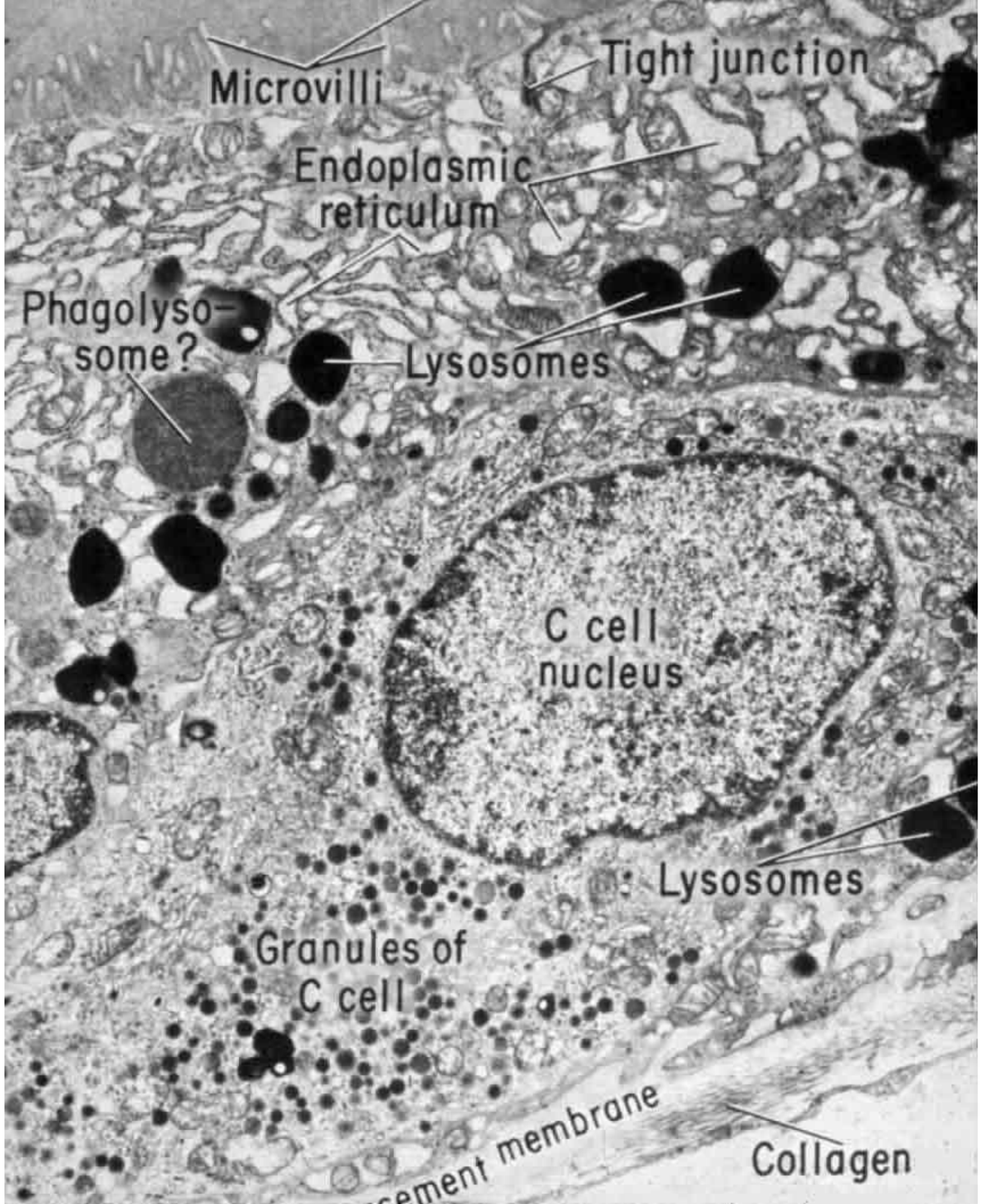
Microvilli
Tight junction
Endoplasmic
reticulum
Phagolyso-
some?
Lysosomes
C cell
nucleus
Lysosomes
Granules of
C cell
cement membrane
Collagen

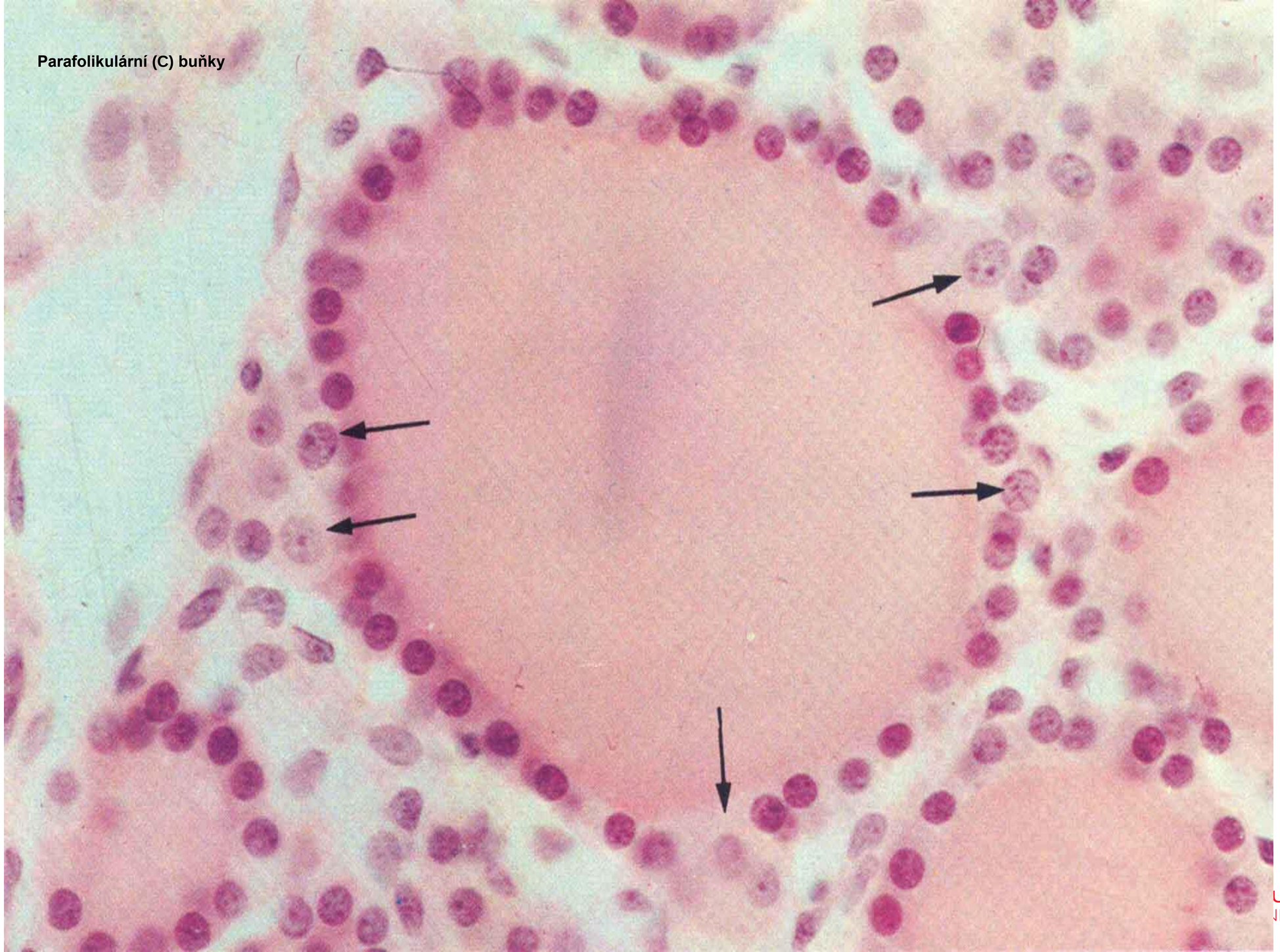

ULTY OF MEDICINE
IVERSITY

Disorder of the thyroid gland

Exophthalmos (bulging eyes)

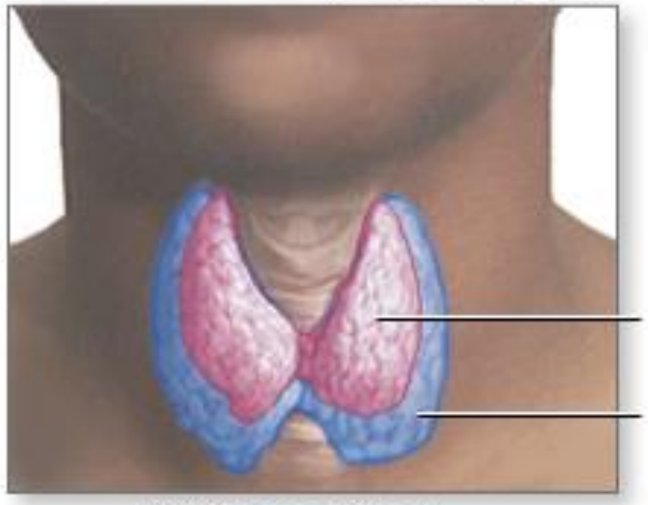

Diffuse goiter

Graves' disease is a common cause of hyperthyroidism, an over-production of thyroid hormone, which causes enlargement of the thyroid and other symptoms such as exophthalmos, heat intolerance and anxiety

ADAM

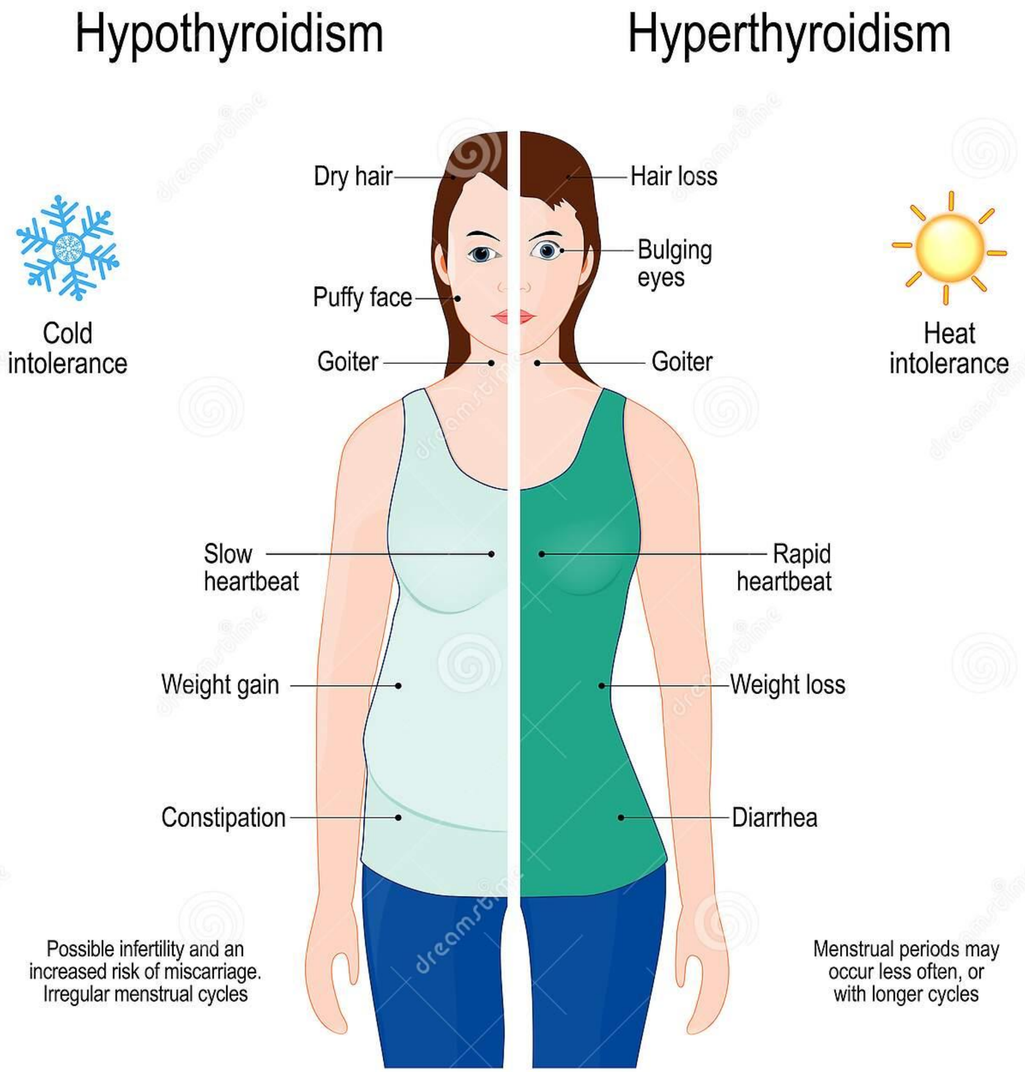

dreamstime.com
ID 192782449 © Designua

Příštítné žlázy (příštítná tělíska, glandulae parathyroideae)



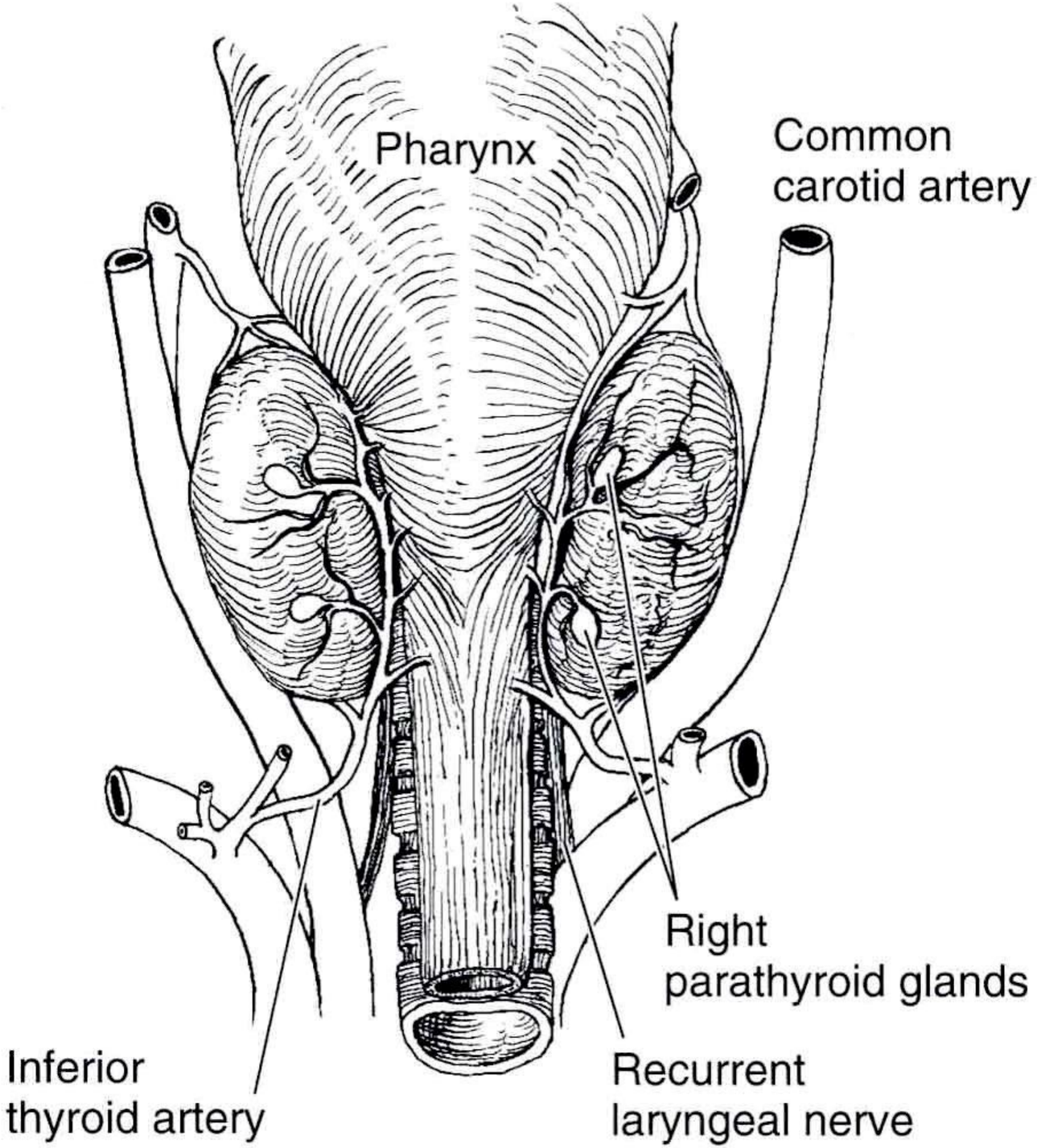
Pharynx
Common carotid artery
Right parathyroid glands
Inferior thyroid artery
Recurrent laryngeal nerve

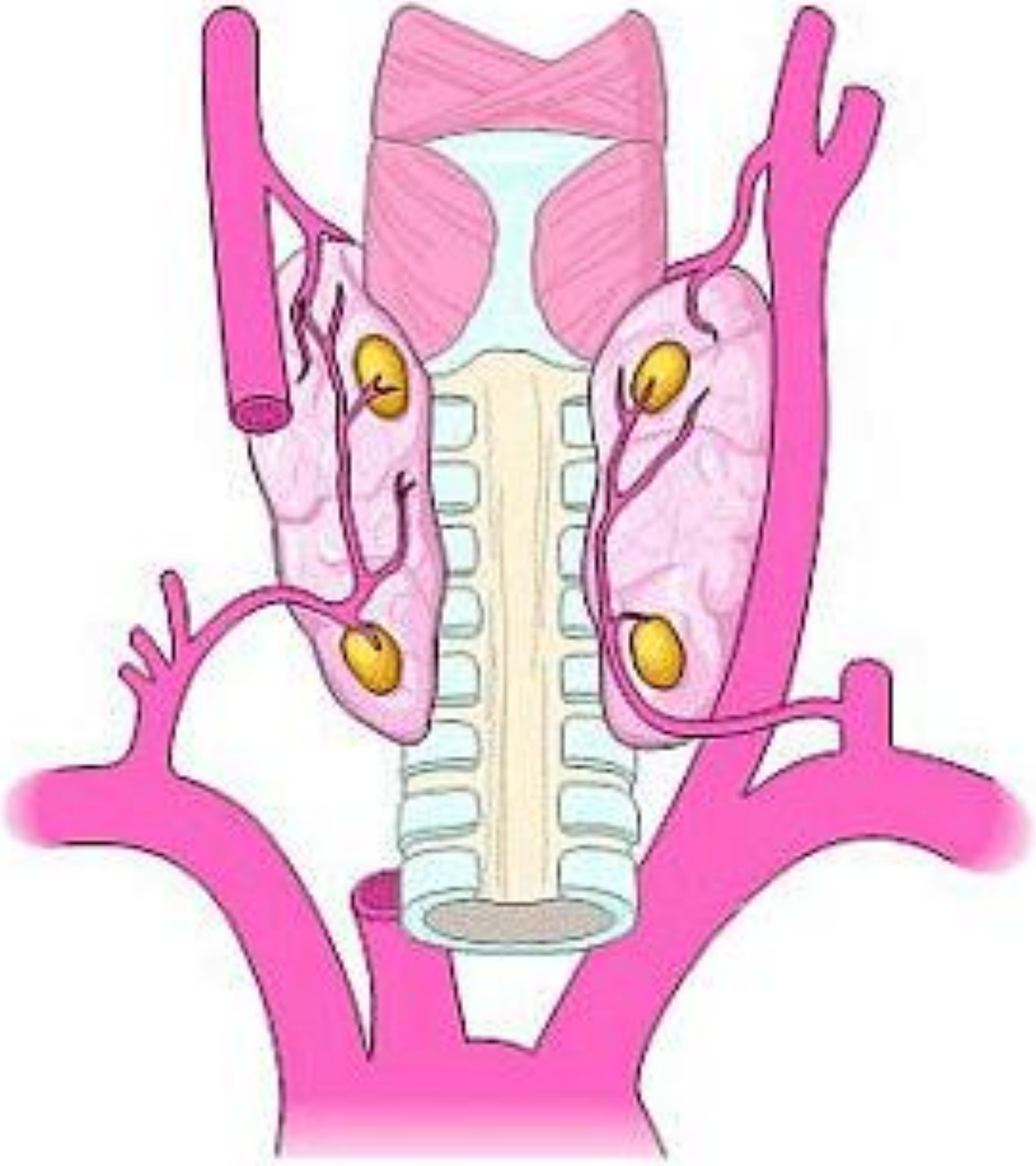

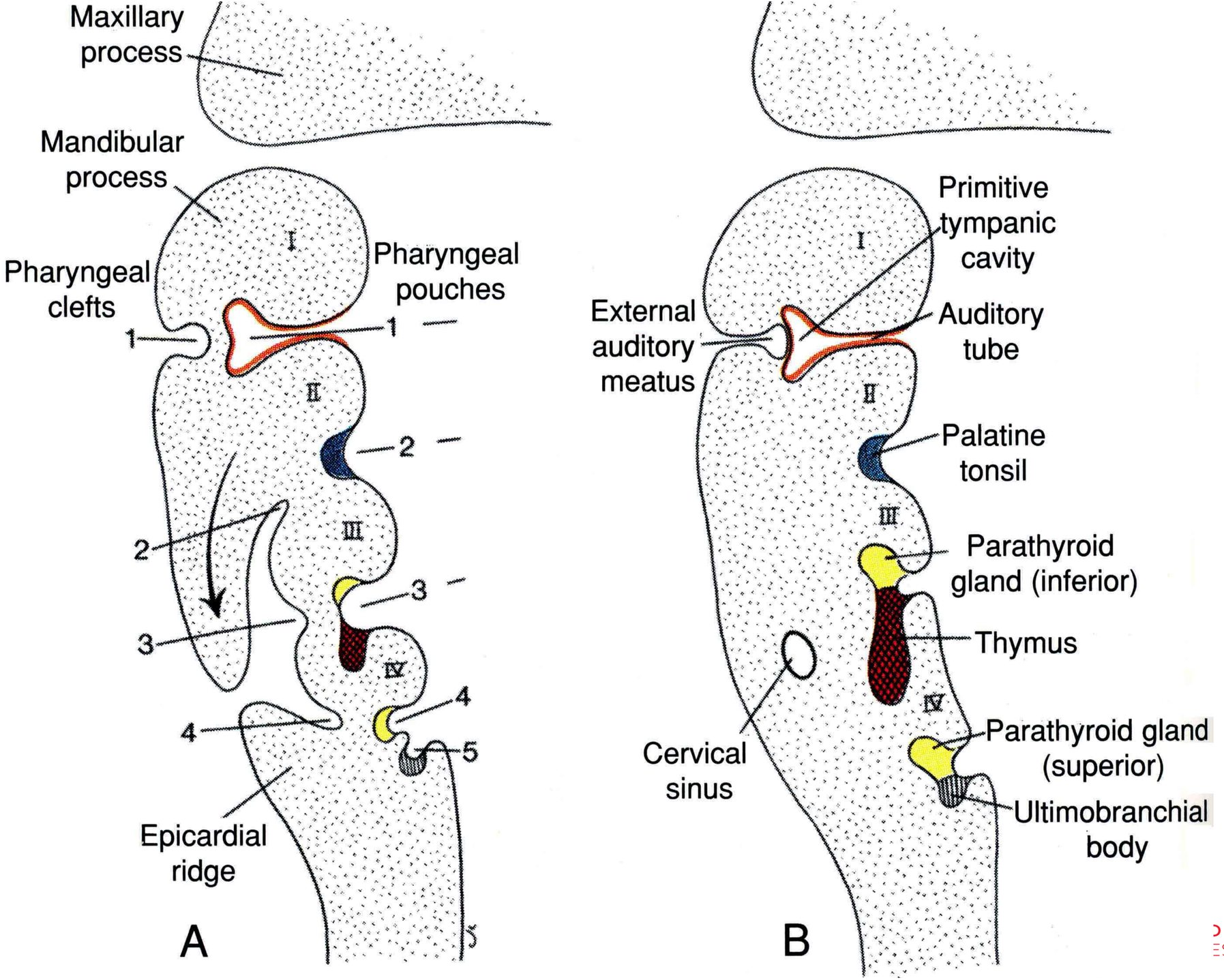

FACULTY OF MEDICINE
ES UNIVERSITY

Příštítná tělíska

- *glandula parathyroidea superior et inferior*
- 2 páry drobných kulovitých útvarů na zadní straně laloků štítné žlázy
- samostatné větve z a. thyroidea inferior
- úloha v metabolizmu kostí
- pouzdro + přepážky
- parenchym rozčleněn na trámce
- **hlavní buňky**
  - **parathormon (PTH)**
- oxyfilní buňky
  - silně acidofilní, mitochondrie, glykogen

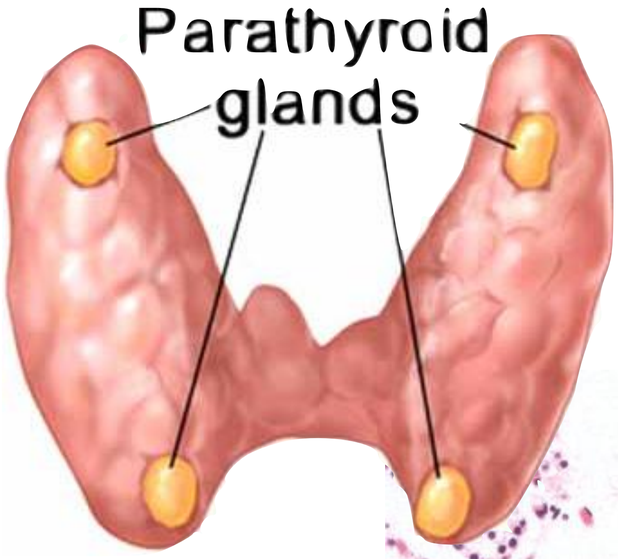

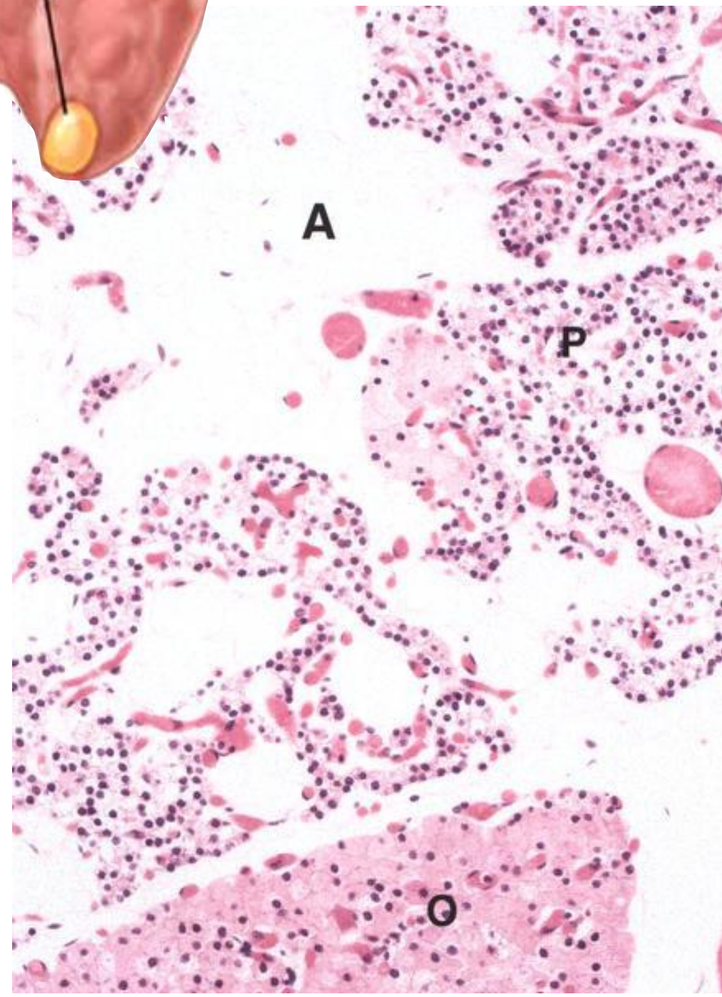

Parenchym: trabekulární epitel
Stroma: retikulární vazivo + tuk + fenestrované kapiláry

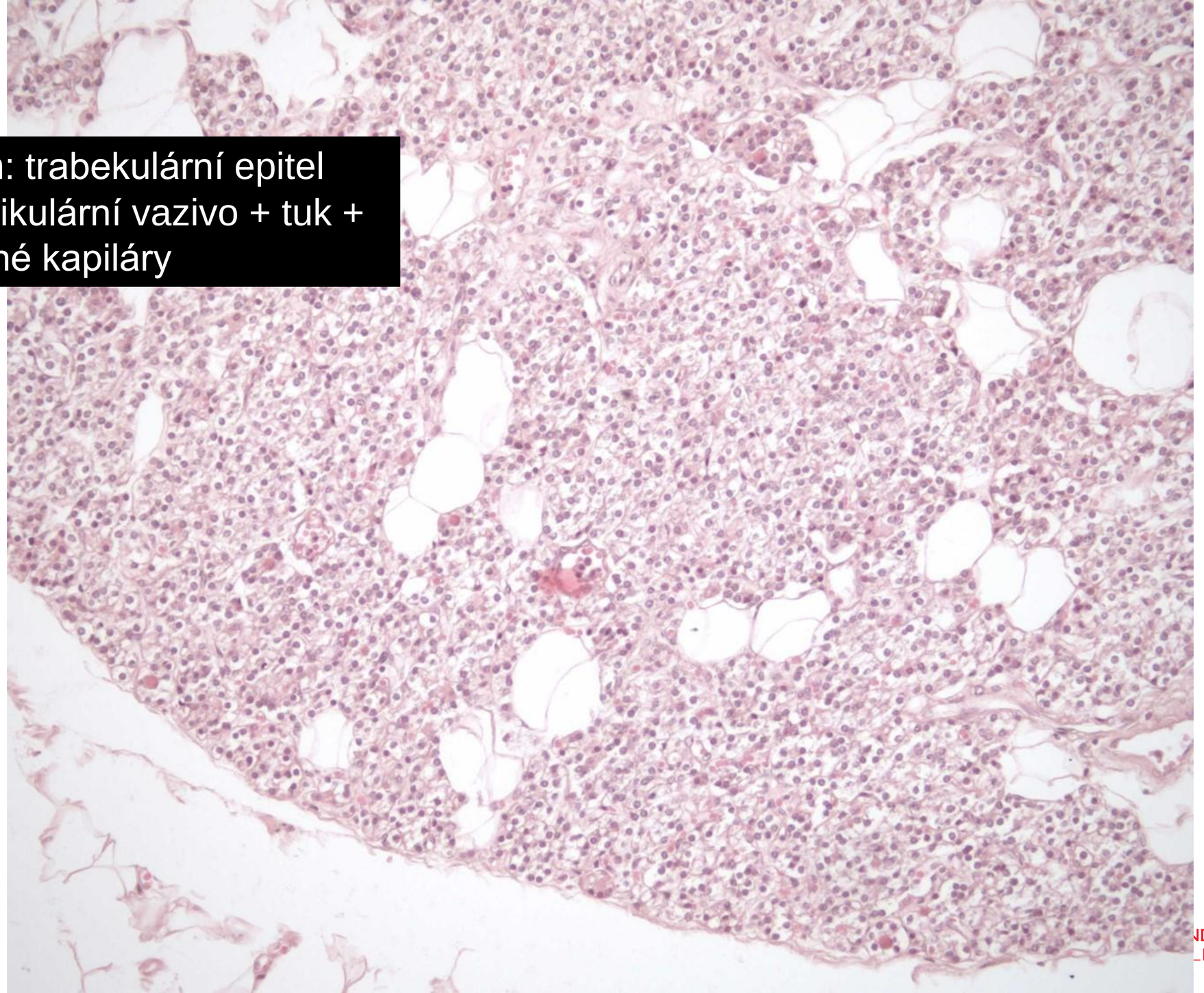

Hlavní buňky
PTH

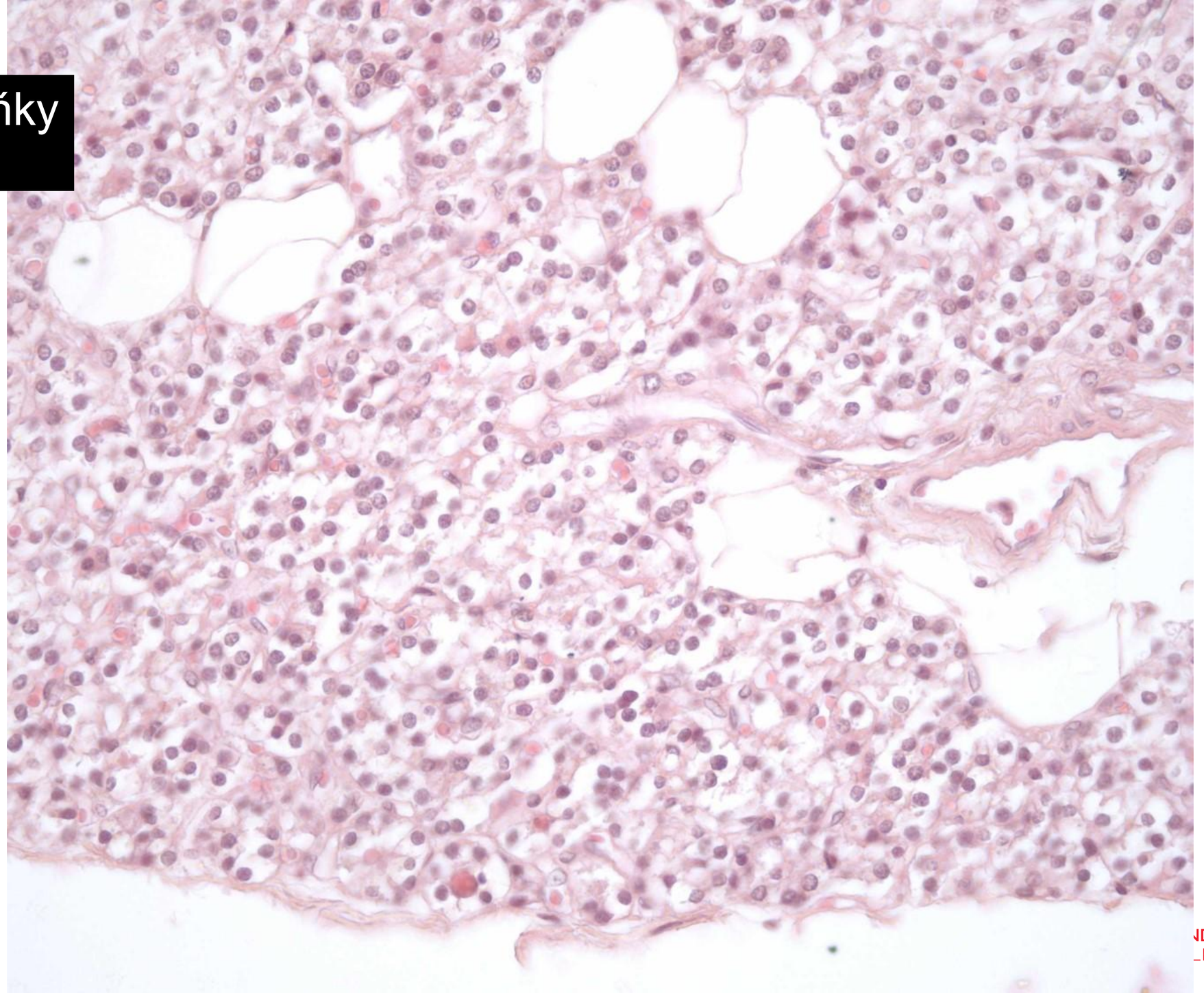

Regulation of PTH – Direct pathway

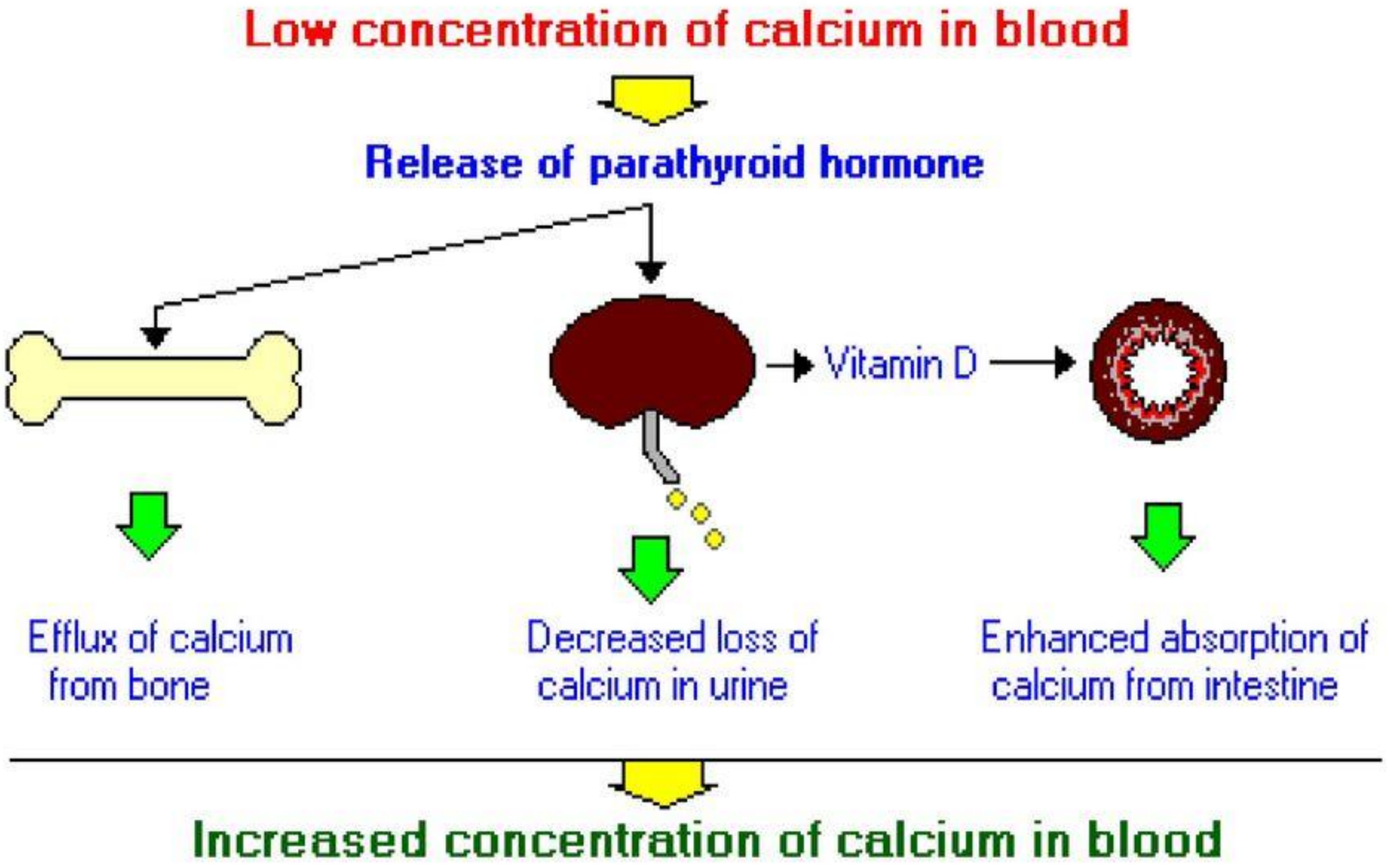

ULTY OF MEDICINE
IIVERSITY

Oxyfilní buňky - často tvoří ostrůvky

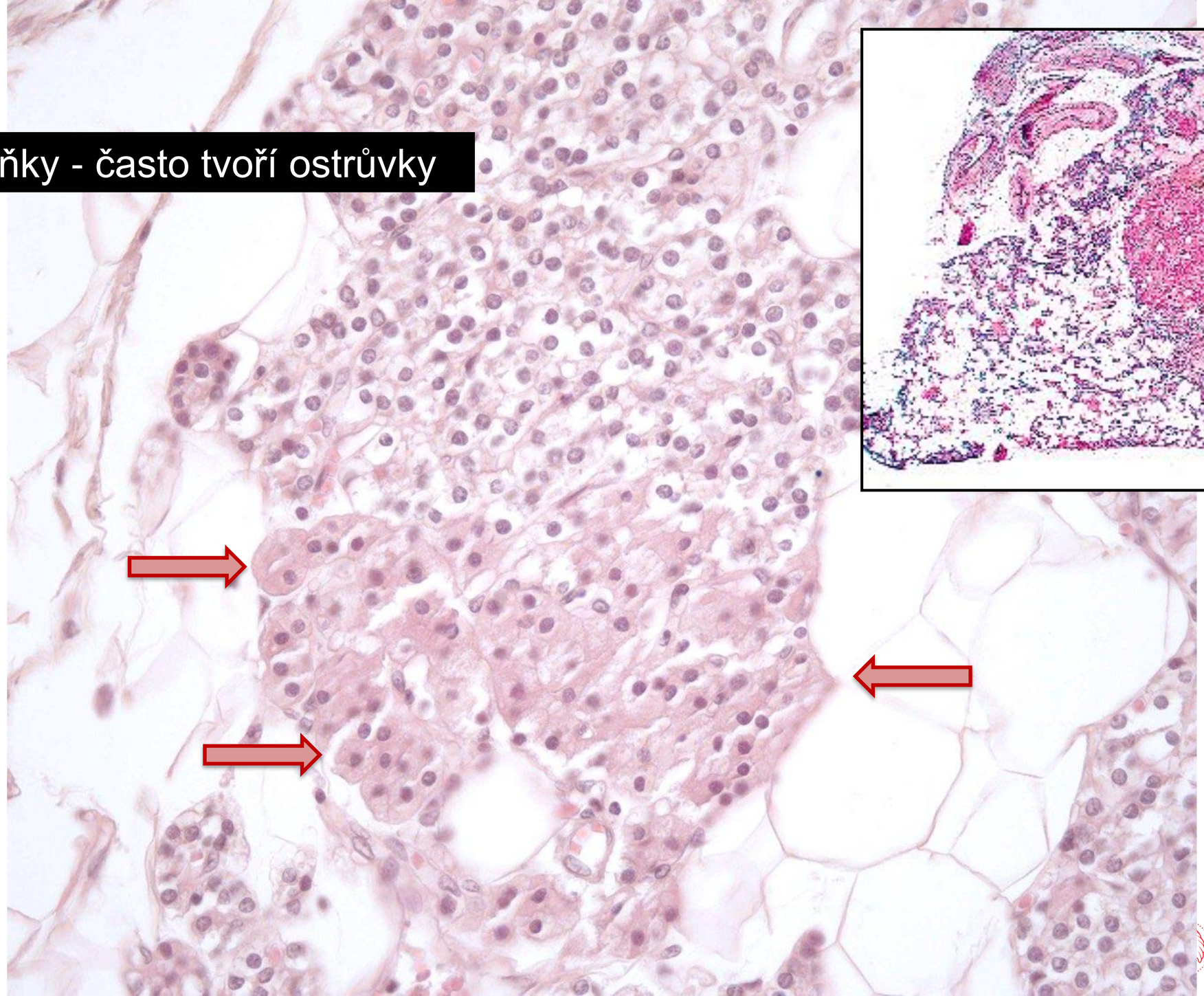

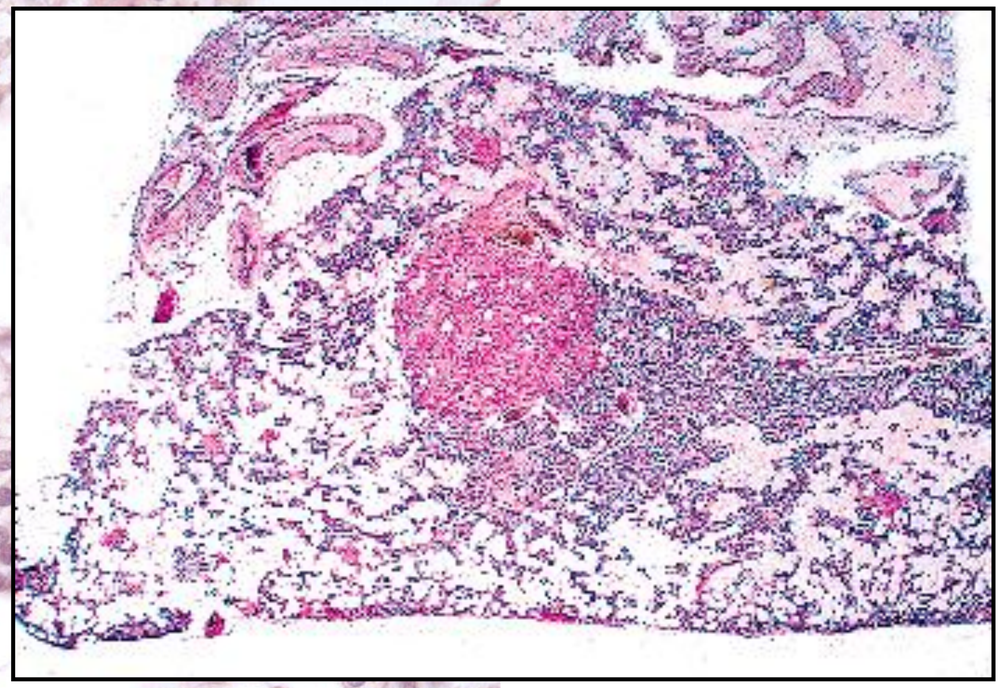

Nadledviny (glandulae suprarenales)



Nadledviny – anatomie

- retroperitoneálně
- výše T11-T12
- *facies anterior* + *posterior* + *renalis*
- *margo superior* + *medialis*
- *hilum*
  - na facies anterior – výstup v. suprarenalis
- *capsula* (vlastní)
- společné *corpus adiposum perirenale* + *fascia renalis* s ledvinou

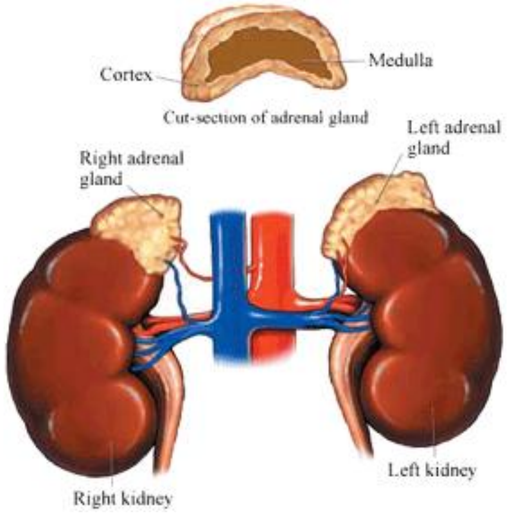

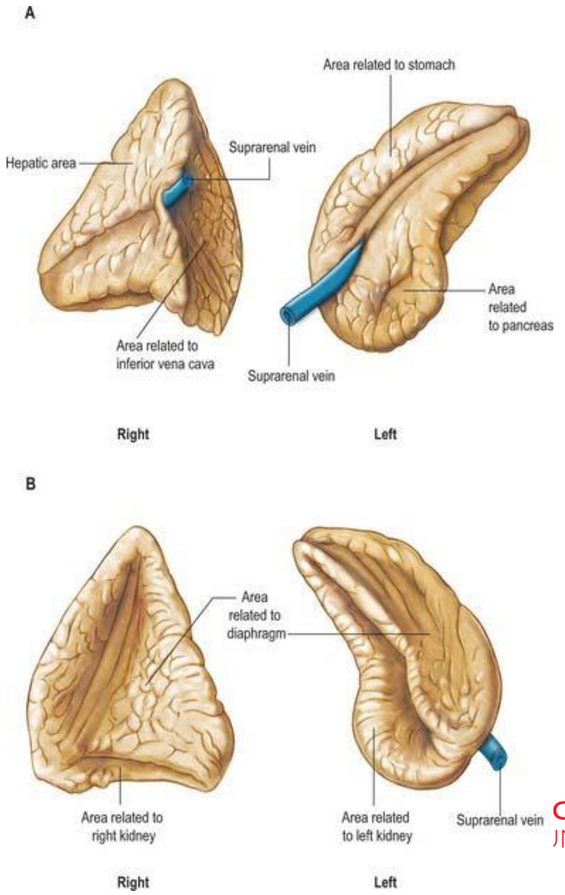

CULTY OF MEDICINE
JNIVERSITY

Nadledvina (*Glandula suprarenalis*)

„dvojitá žláza“
- dvě rozdílné tkáně: kůra a dřeň

- kůra nadledvin (*cortex*)
  - **mineralokortikoidy** – aldosteron
  - **glukokortikoidy** – kortizol, kortikosteron
  - **androgeny** – DEAS=dehydroepiandrosteron
- dřeň nadledvin (*medulla*)
  - **katecholaminy** – adrenalin, noradrenalin

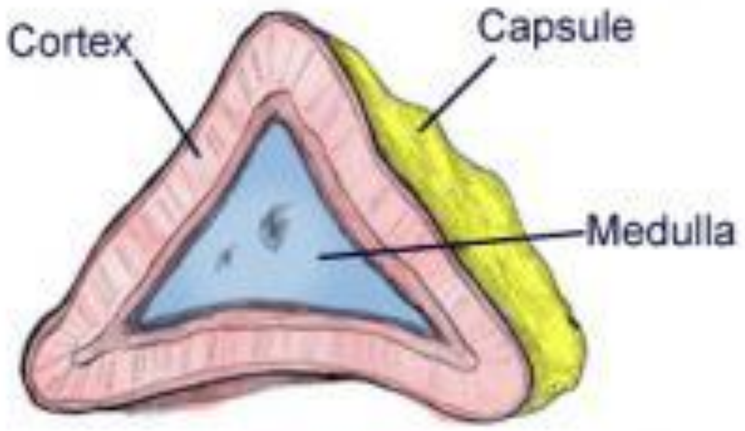

Transverse section

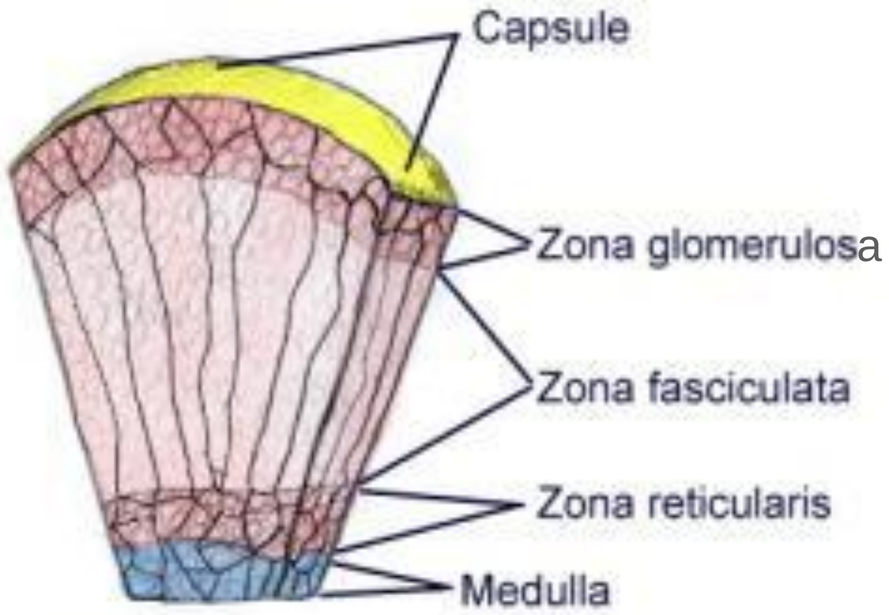

Microscopic section

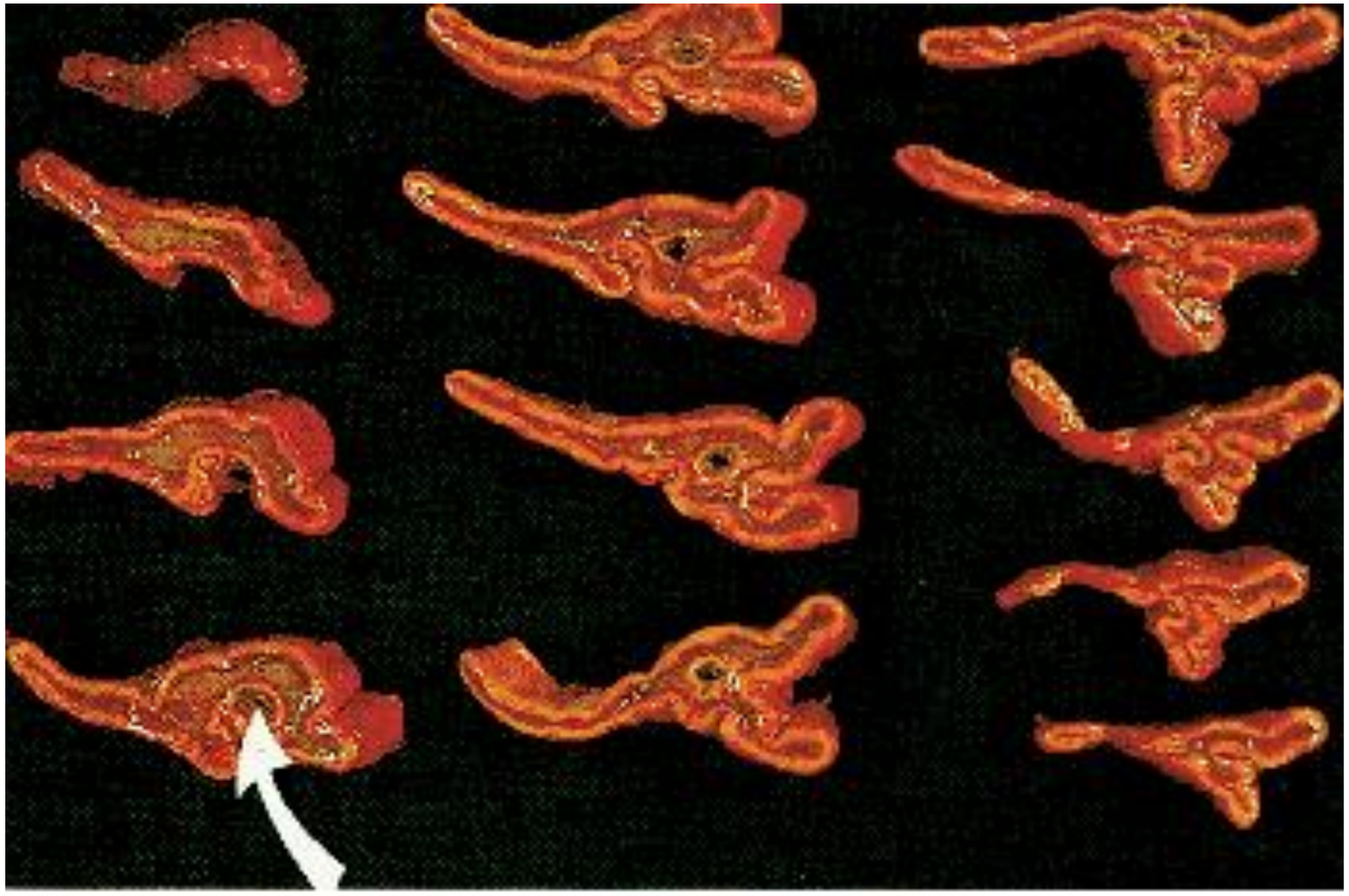

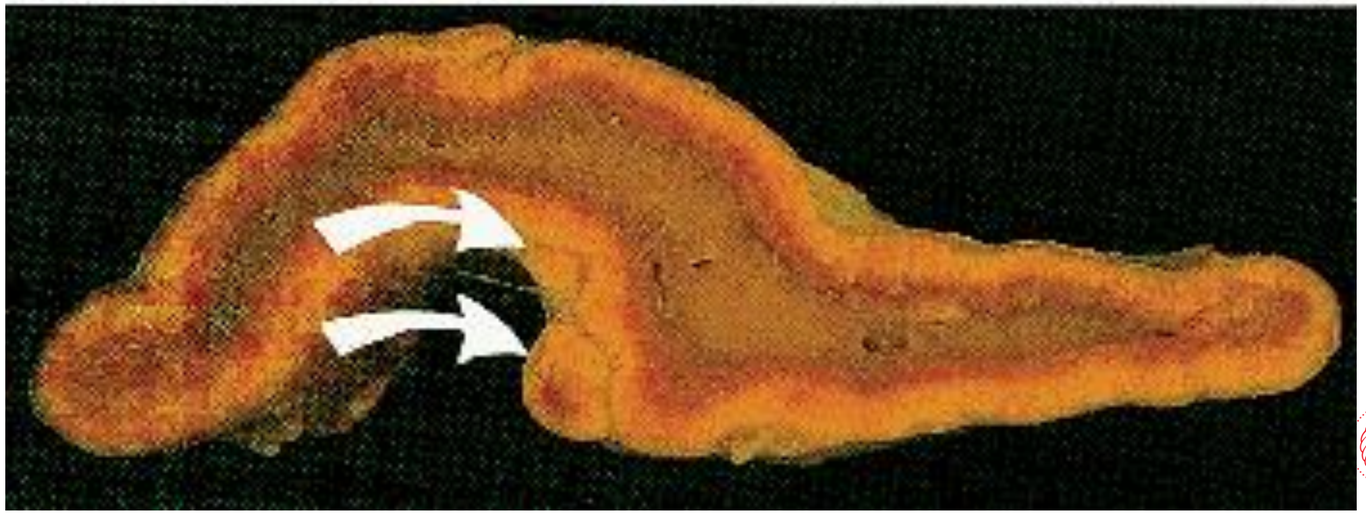

SECOND FACULTY OF MEDICINE
CHARLES UNIVERSITY

Nadledvina – vývoj

- <u>kůra</u>
  - z **coelomového epitelu (laterální somatický mezoderm)** mediálně od urogenitální lišty
  - proliferace, vcestovávání směrem k aortě
  - sekundární proliferace kůry → vznik definitivní kůry

- <u>dřeň</u>
  - původ z **neurální lišty**
  - ze základu ganglion coeliacum -> sympatogonie (neuroblasty a feochromocytoblasty)
  - vcestují do základu kůry

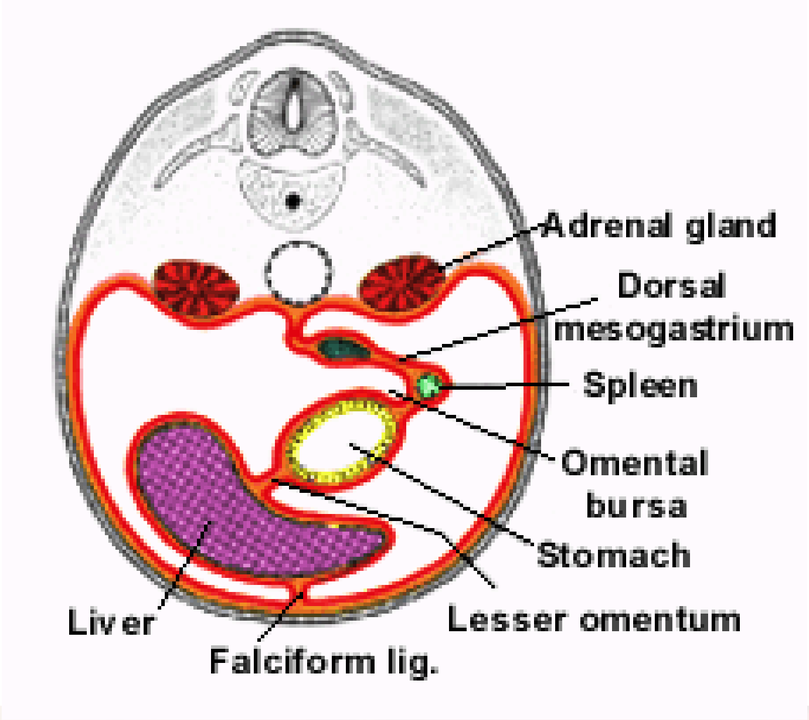

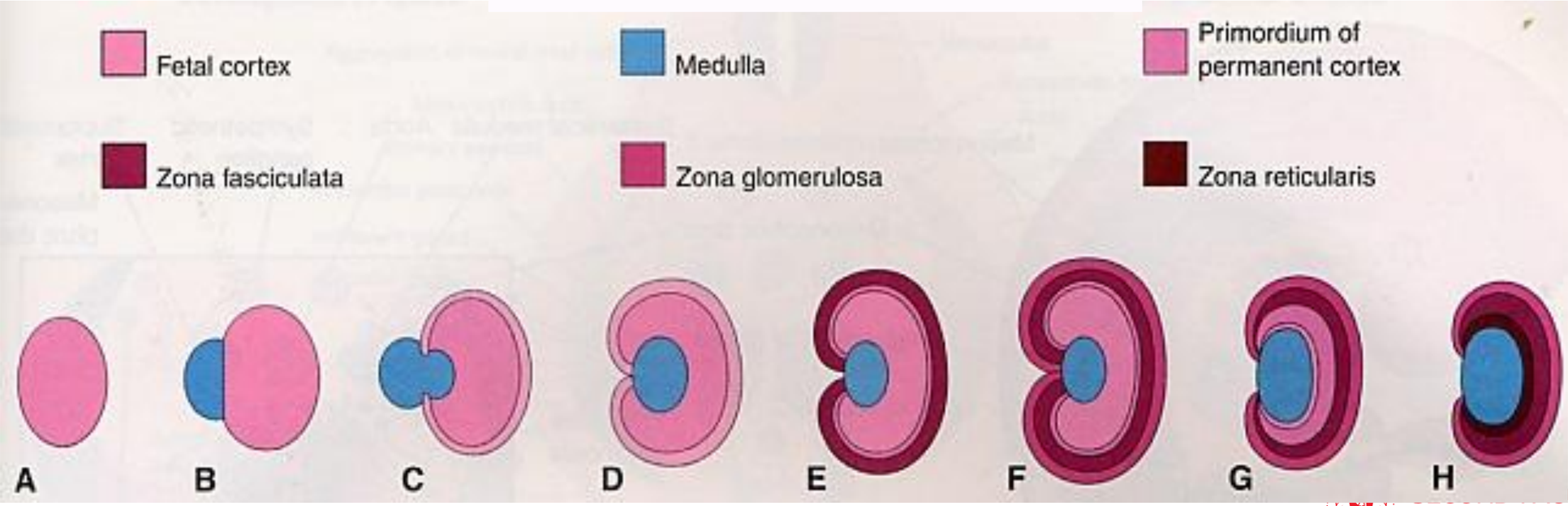

ULTY OF MEDICINE
CHARLES UNIVERSITY

Development of adrenal glands

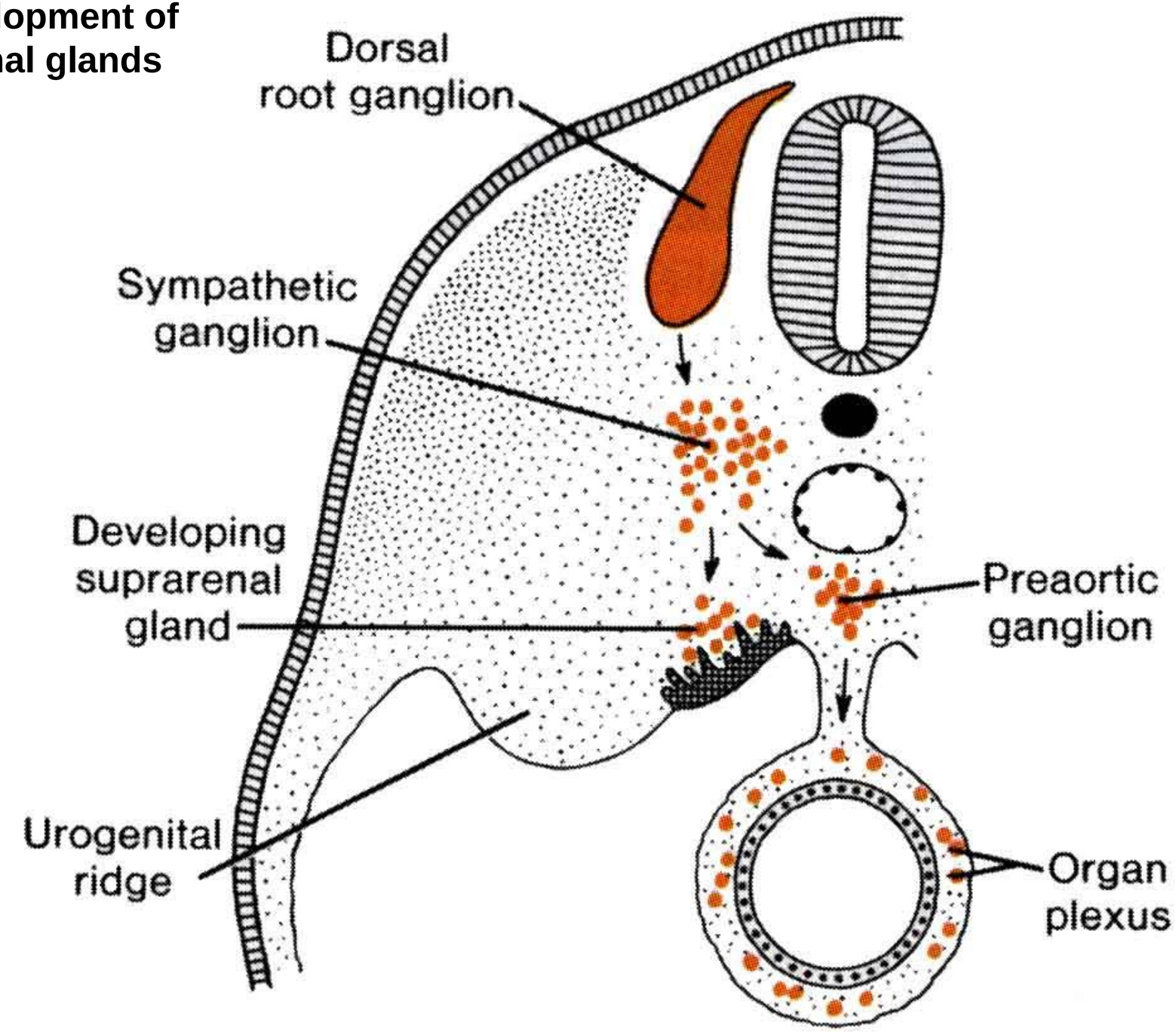

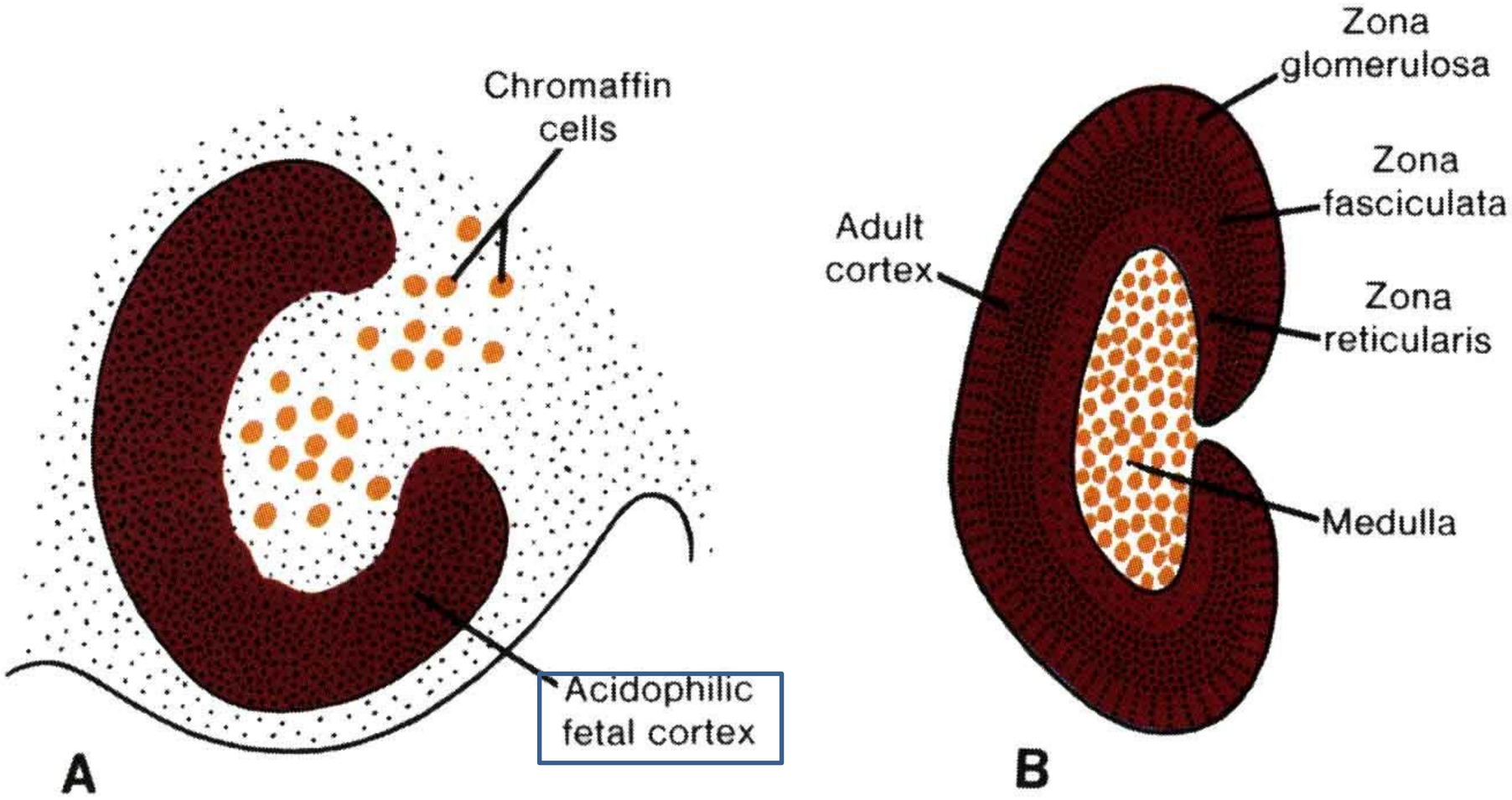
Chromaffin cells
Acidophilic fetal cortex
A
Zona glomerulosa
Zona fasciculata
Adult cortex
Zona reticularis
Medulla
B

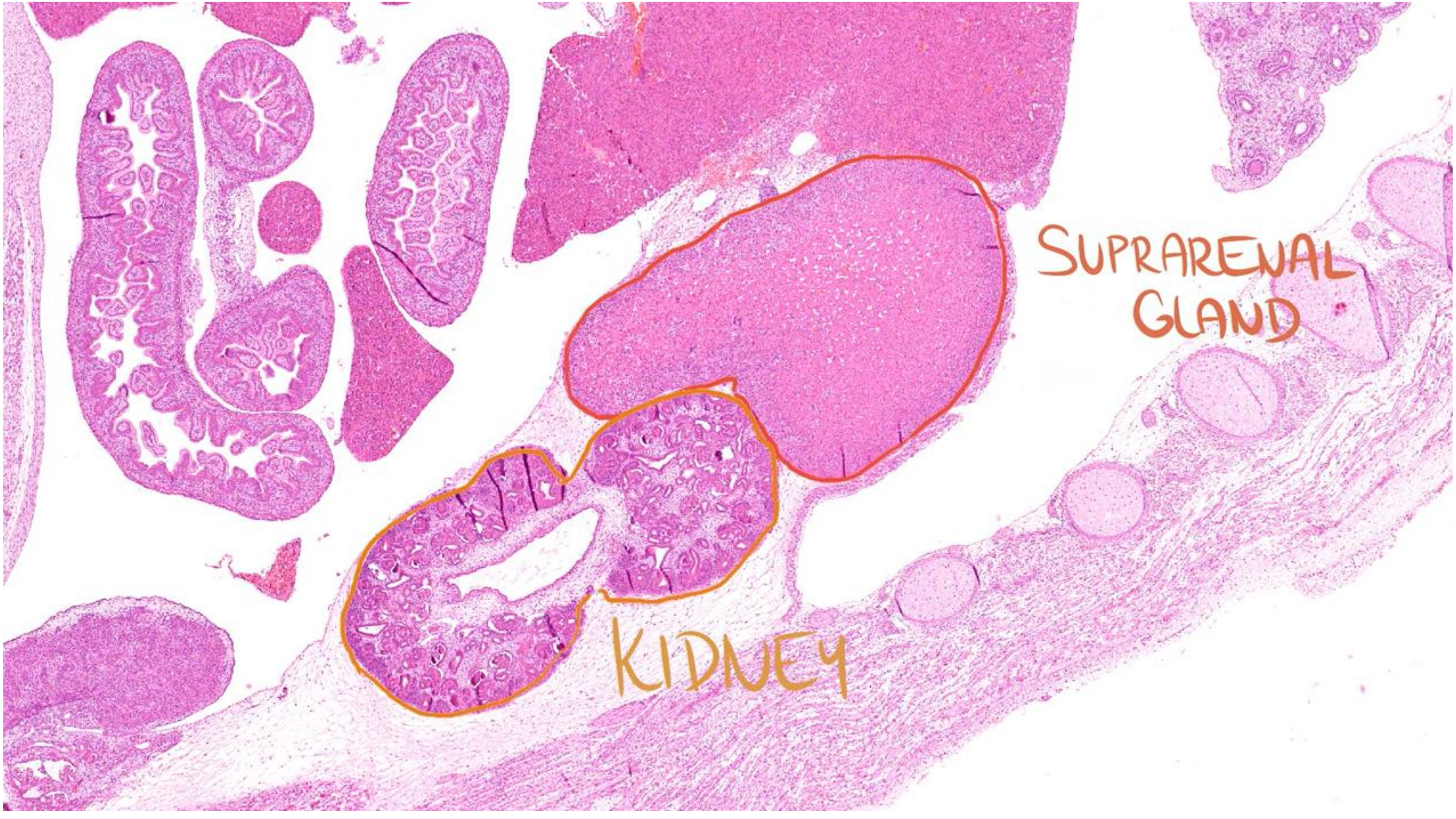
SUPRARENAL GLAND
KIDNEY

SUPRARENAL GLAND
EOSINOPHILIC CELLS
PRIMITIVE CORTEX
SURROUNDED BY
SECONDARY CORTEX
(DEFINITIVE)

novorozenec, 35t.
centrálně primární kůra (eozinofilní)

periferně lem sekundární kůry

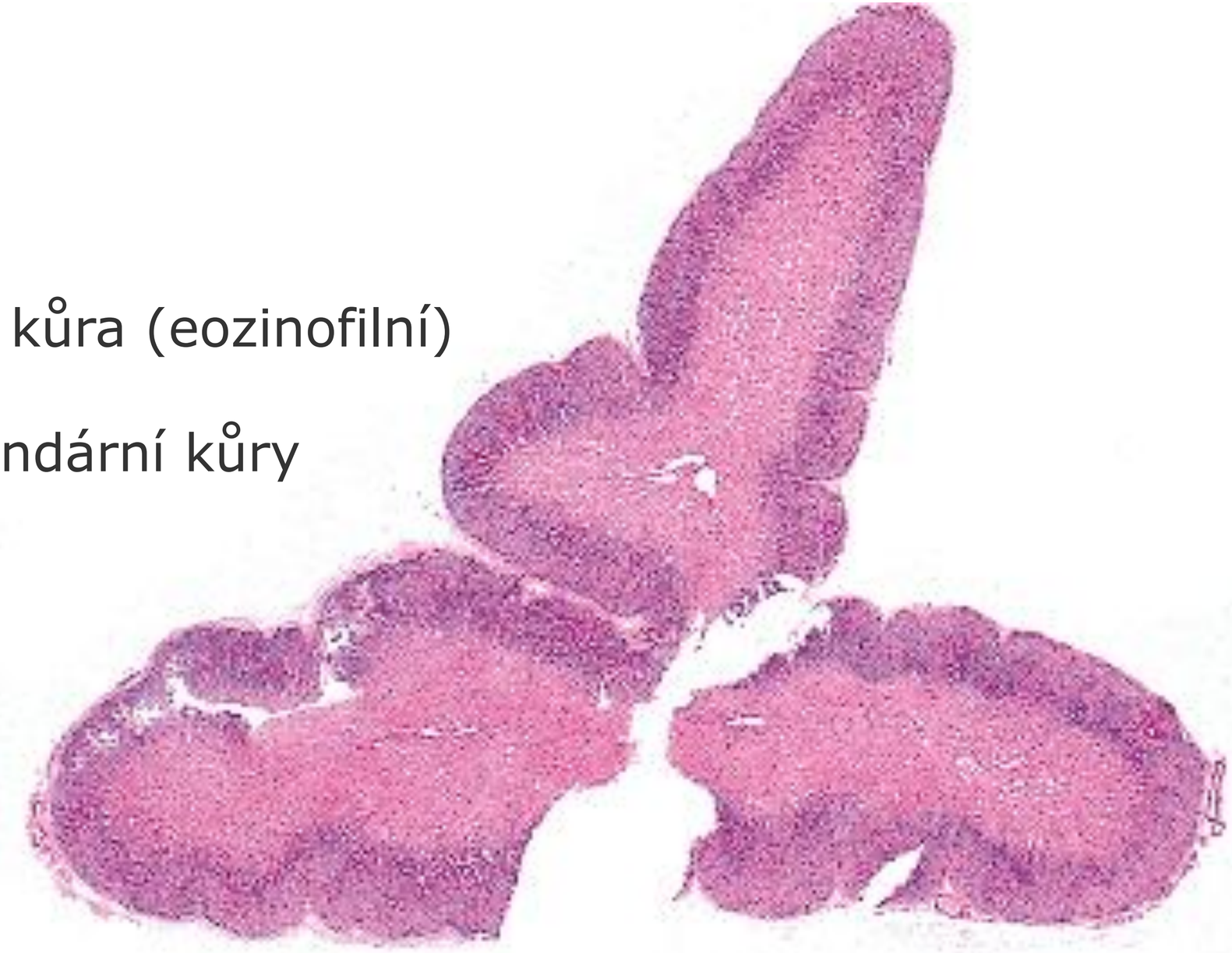

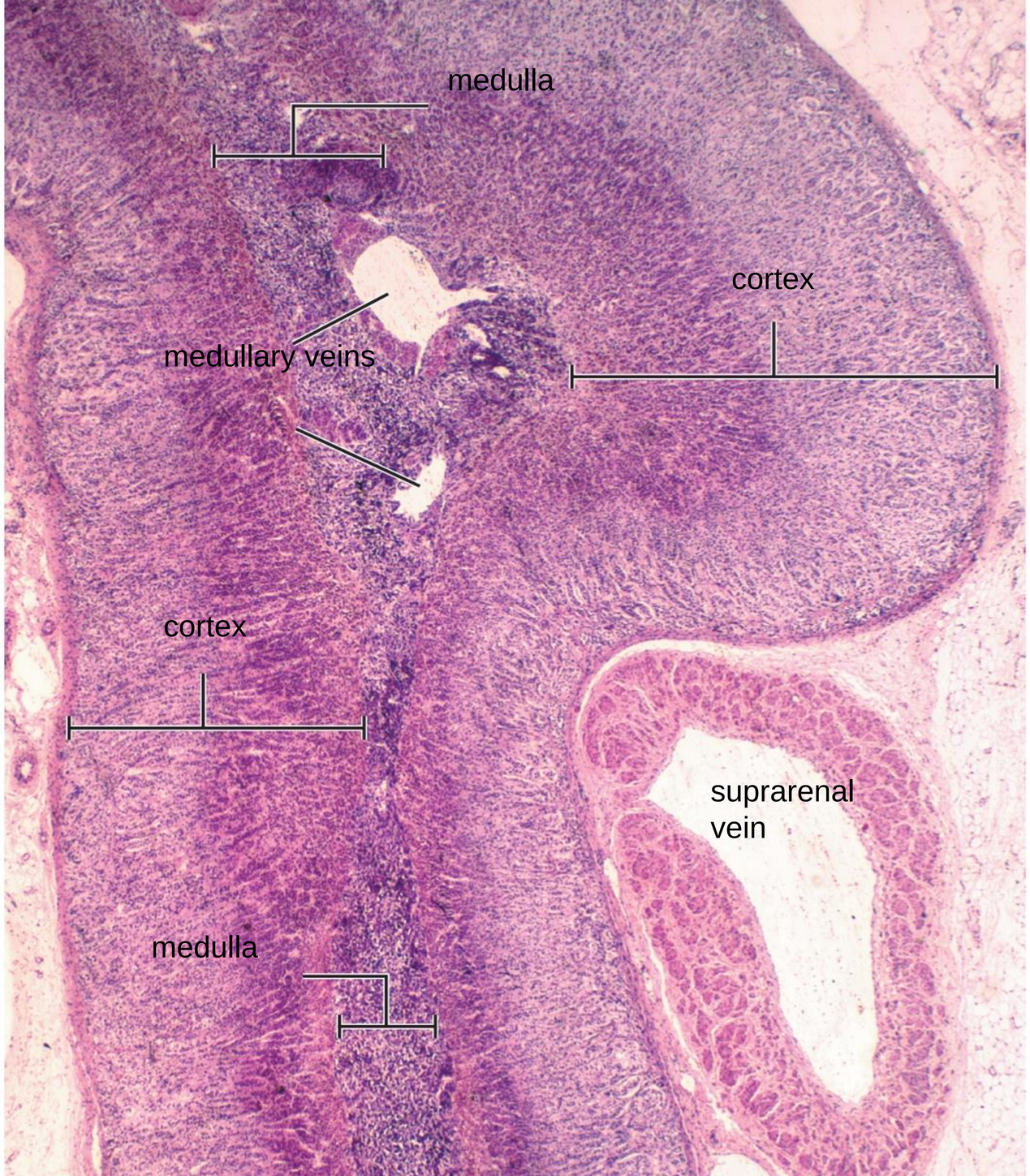

SECOND FACULTY OF MEDICINE
CHARLES UNIVERSITY

Nadledviny – krevní cévy

- a. suprarenalis superior (← a. phrenica inferior)
- a. suprarenalis media (← aorta abdominalis)
- a. suprarenalis inferior (← a. renalis)

→ subkapsulární pleteň, kapiláry a sinusoidy skrz kůru →

- žíly ze dřeně do v. centralis → v. suprarenalis → v. renalis sinistra / v. cava inferior vpravo

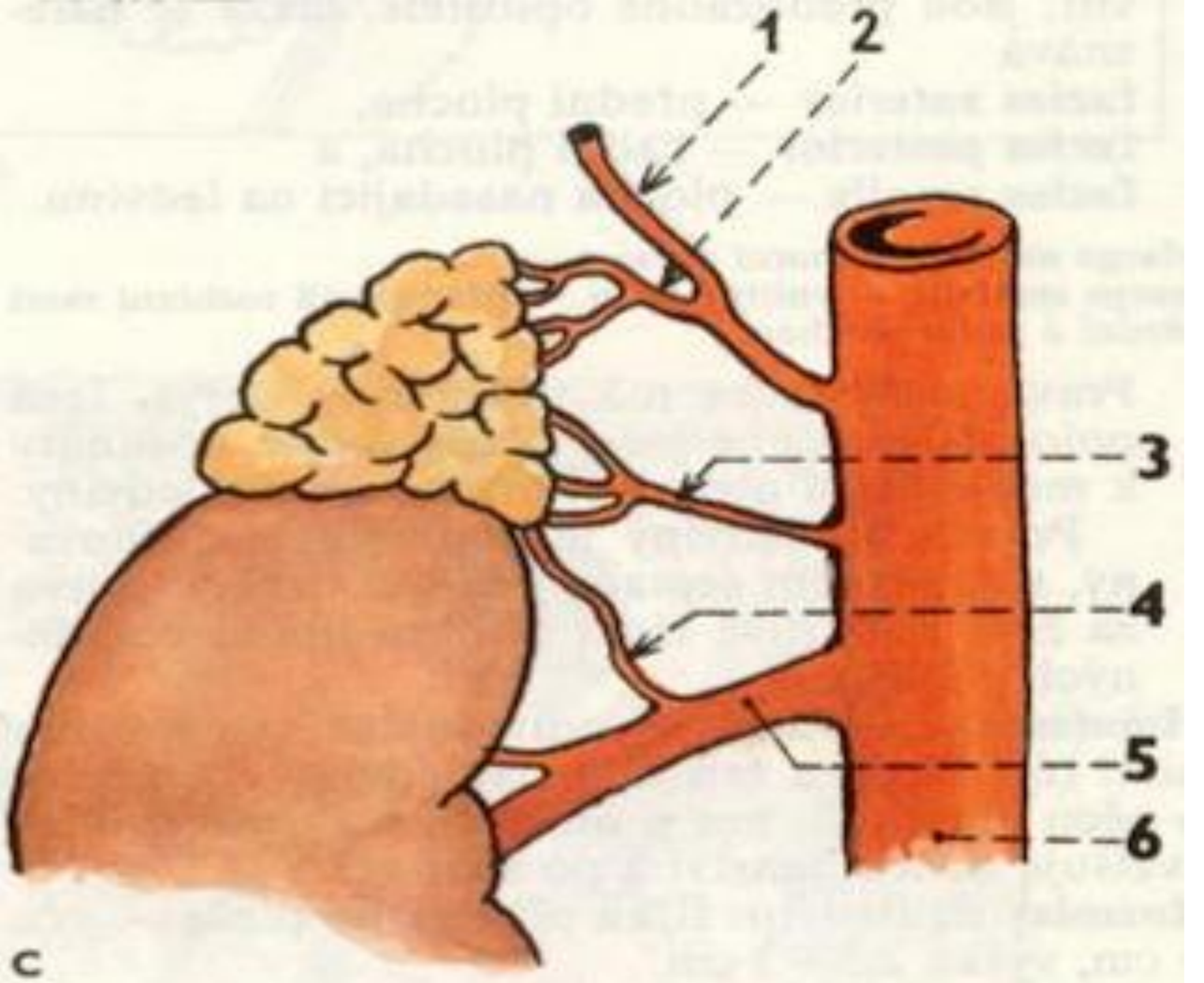

C. CÉVY NADLEDVINY (pravé strany)
1 / a. phrenica inferior (dextra)
2 / a. suprarenalis superior (dextra)
3 / a. suprarenalis media (dextra)
4 / a. suprarenalis inferior (dextra)
5 / a. renalis (dextra)
6 / aorta abdominalis

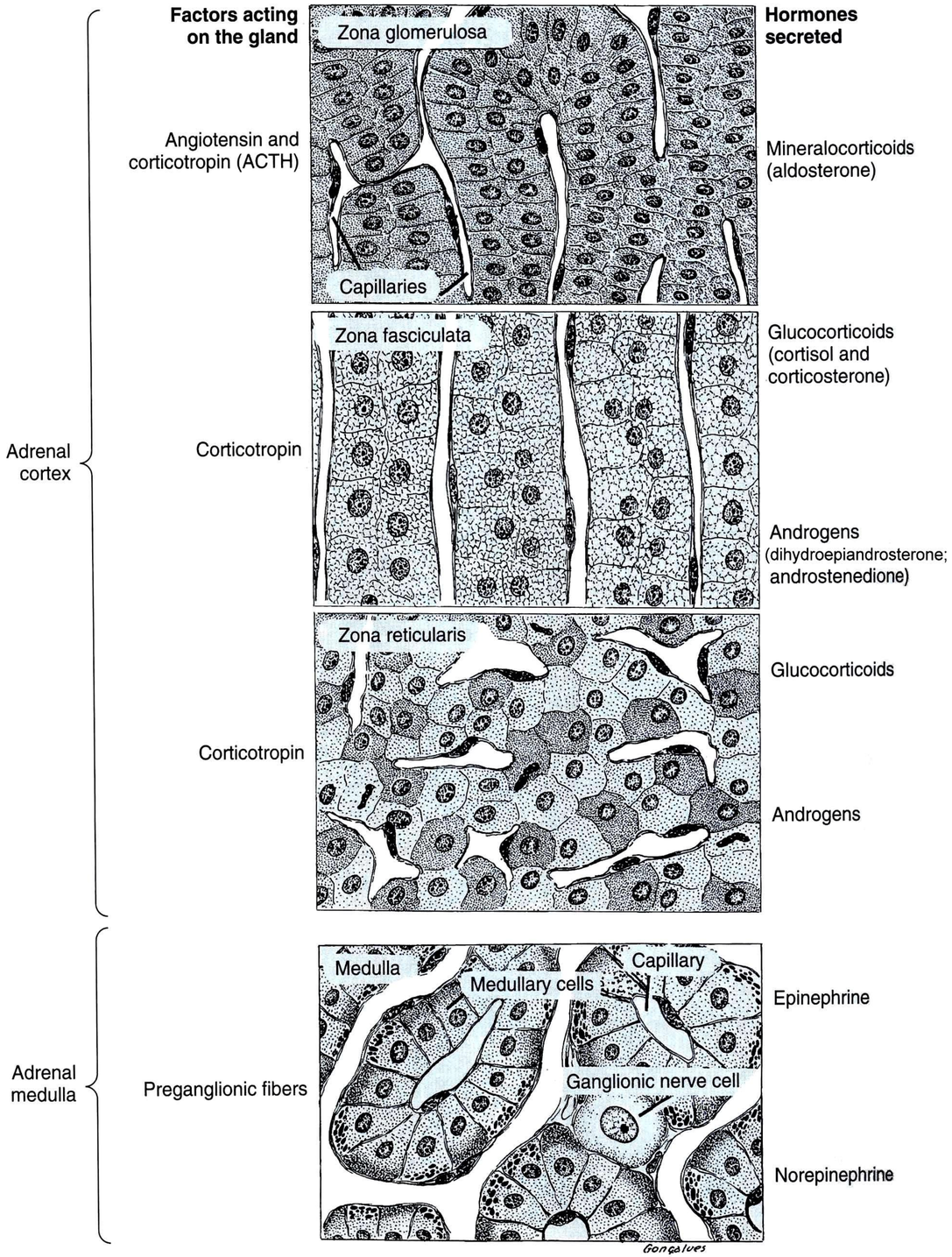
Factors acting on the gland
Hormones secreted
Zona glomerulosa
Angiotensin and corticotropin (ACTH)
Mineralocorticoids (aldosterone)
Capillaries
Zona fasciculata
Glucocorticoids (cortisol and corticosterone)
Adrenal cortex
Corticotropin
Androgens (dihydroepiandrosterone; androstenedione)
Zona reticularis
Glucocorticoids
Corticotropin
Androgens
Medulla
Capillary
Medullary cells
Epinephrine
Adrenal medulla
Preganglionic fibers
Ganglionic nerve cell
Norepinephrine
Gonçalves

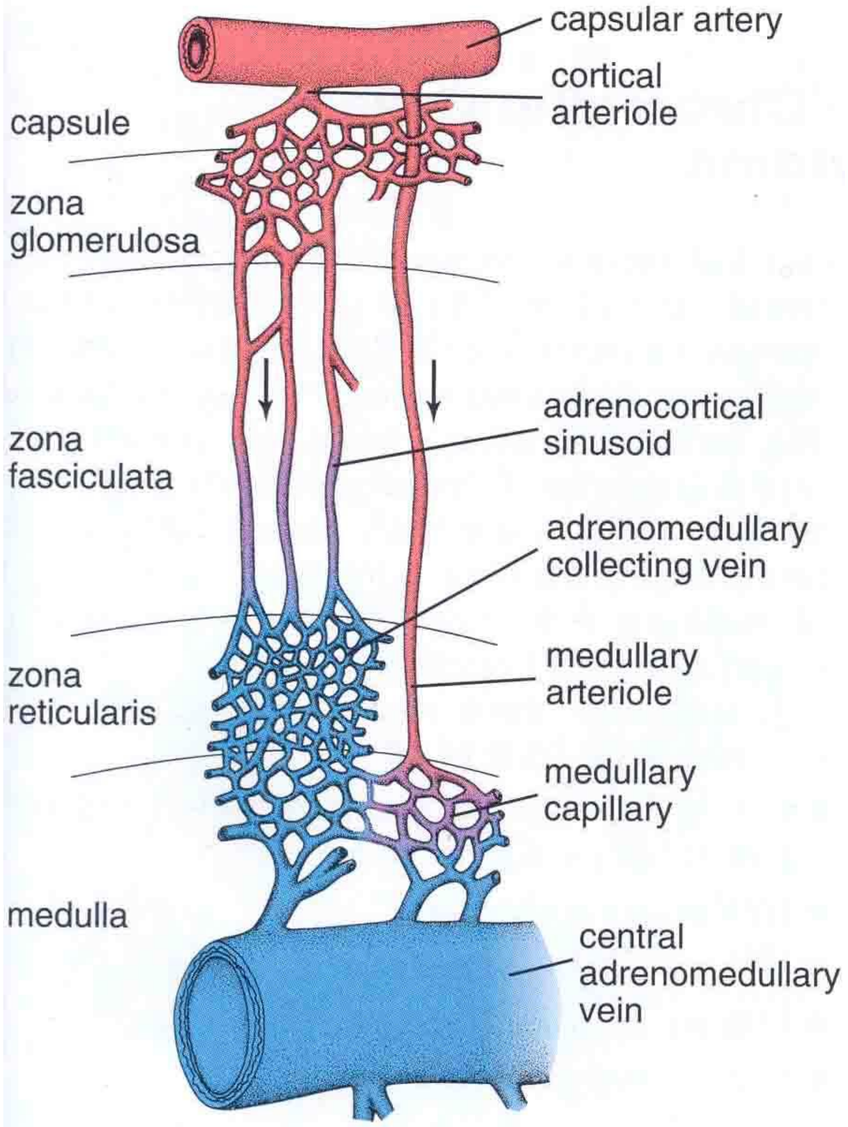
capsular artery
cortical arteriole
capsule
zona glomerulosa
zona fasciculata
adrenocortical sinusoid
adrenomedullary collecting vein
zona reticularis
medullary arteriole
medullary capillary
medulla
central adrenomedullary vein

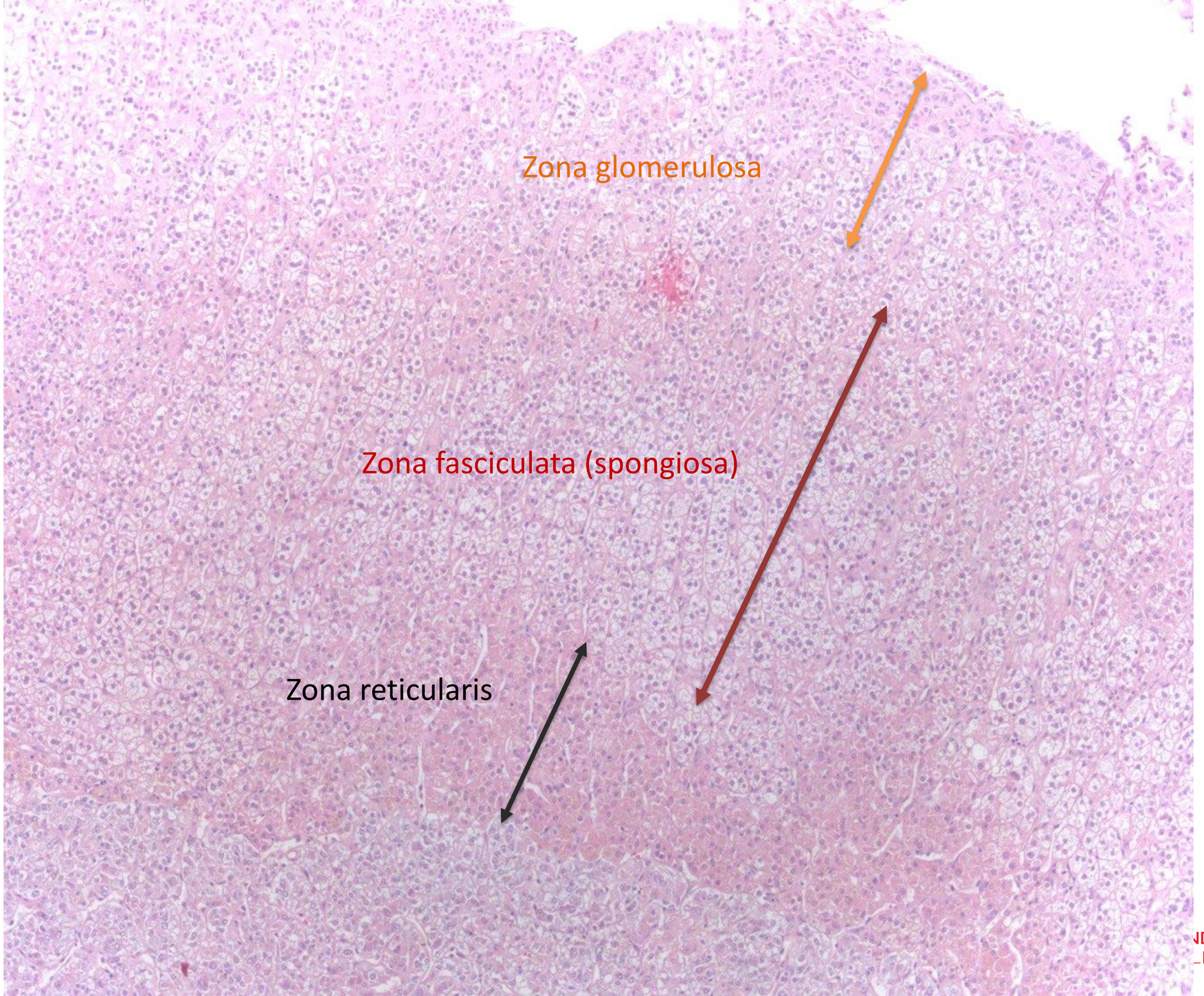

ND FACULTY OF MEDICINE
LES UNIVERSITY

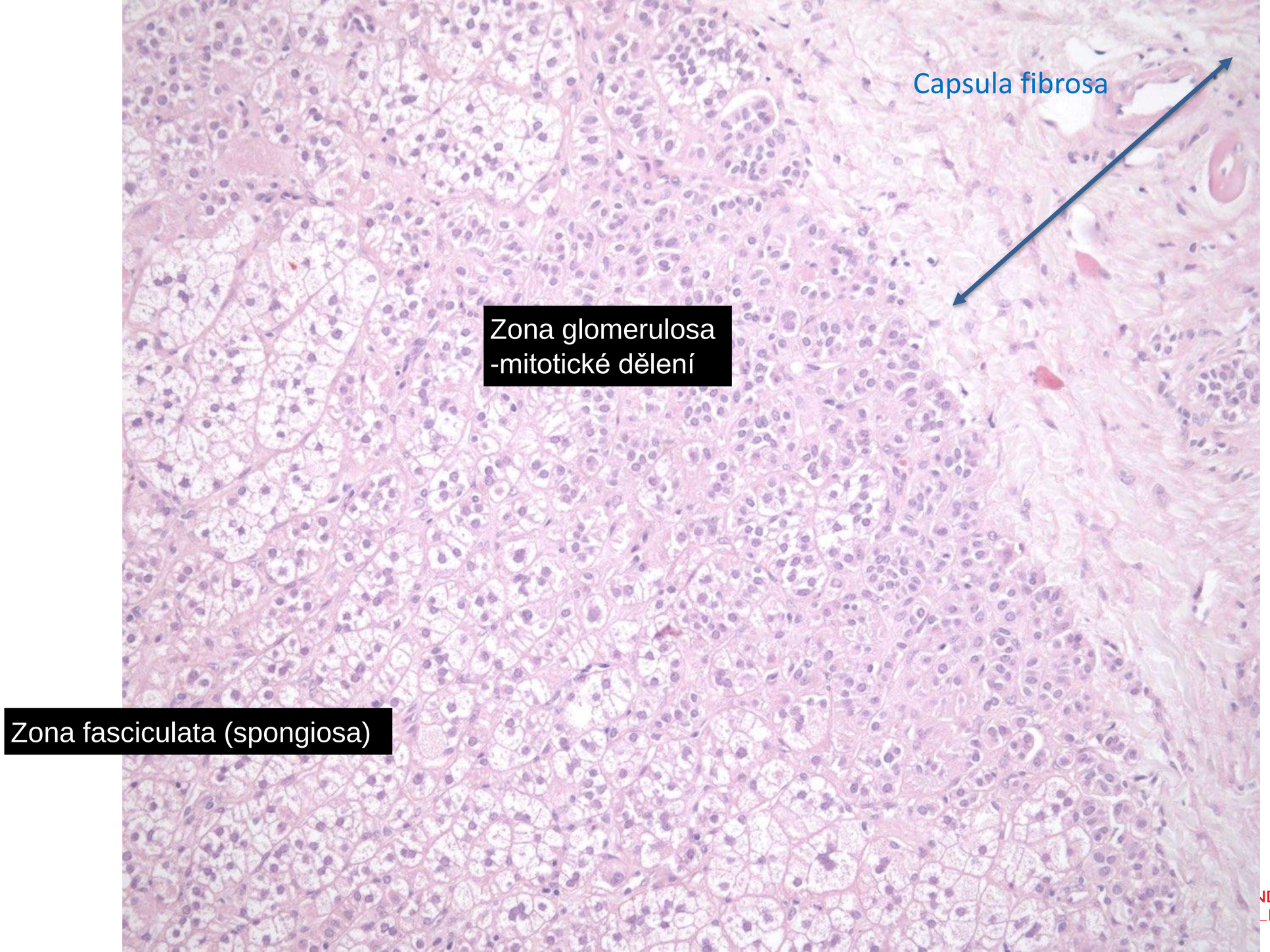

ND FACULTY OF MEDICINE
LES UNIVERSITY

Spongiocyty - zona fasciculata

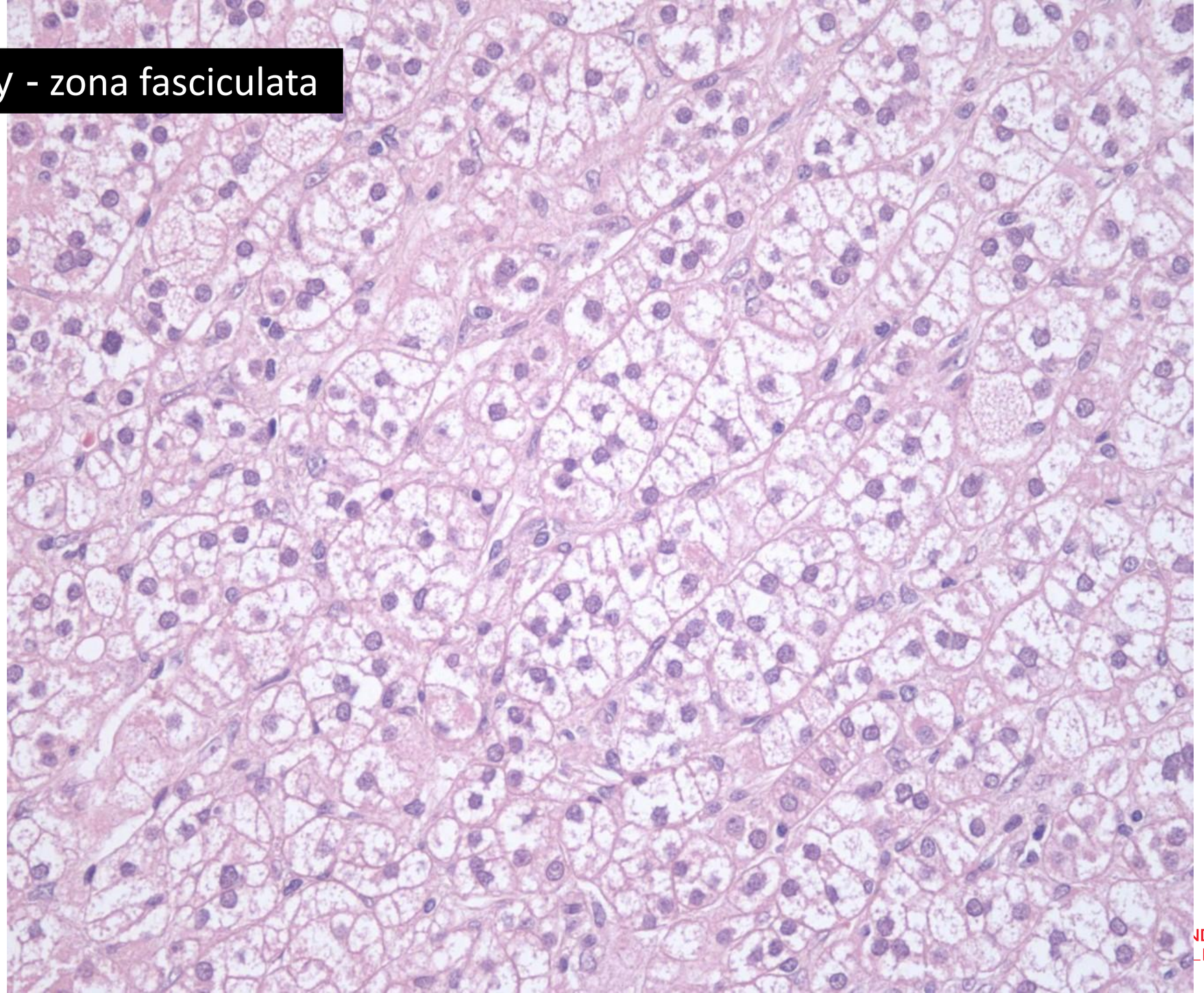

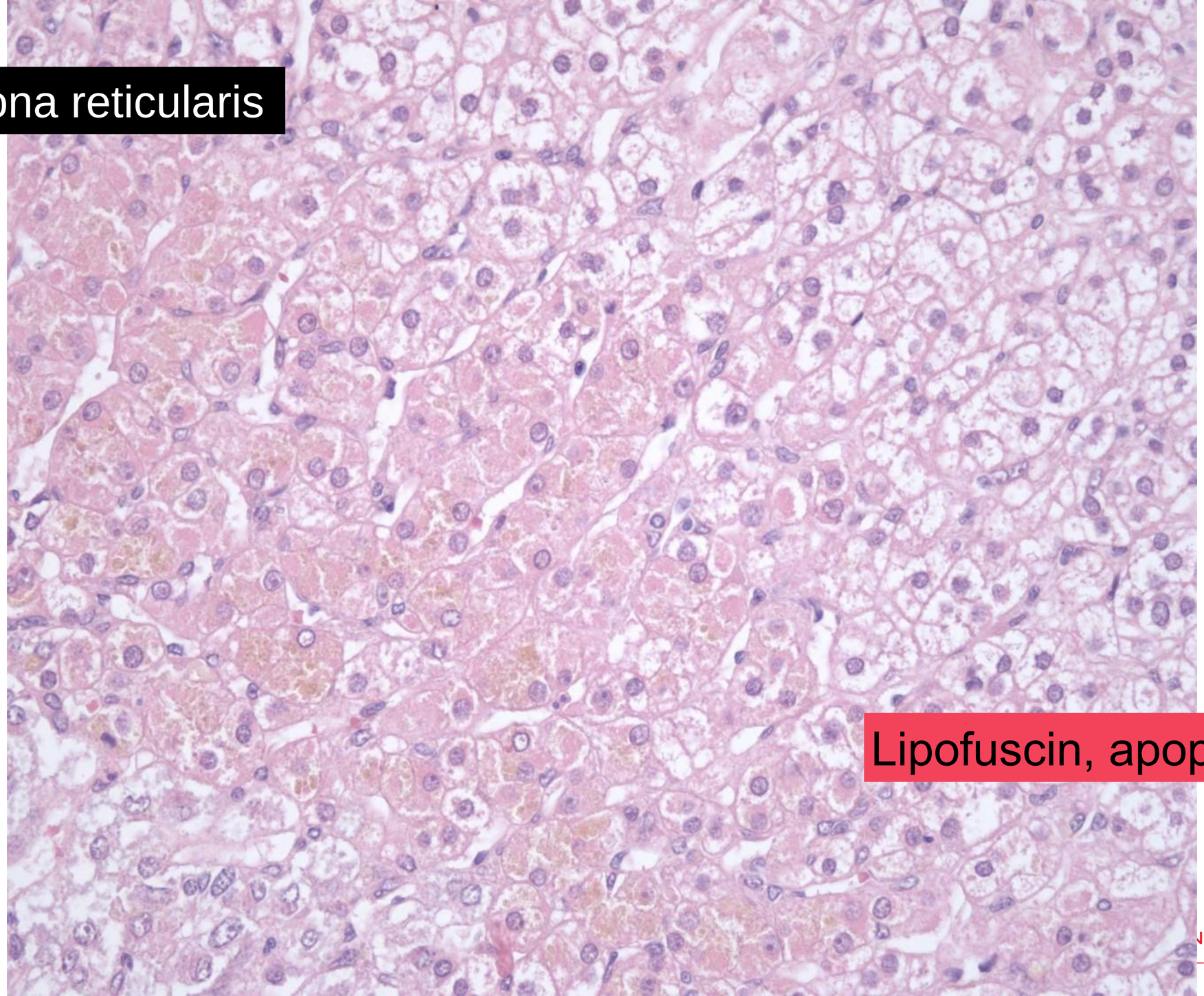

ND FACULTY OF MEDICINE
LES UNIVERSITY

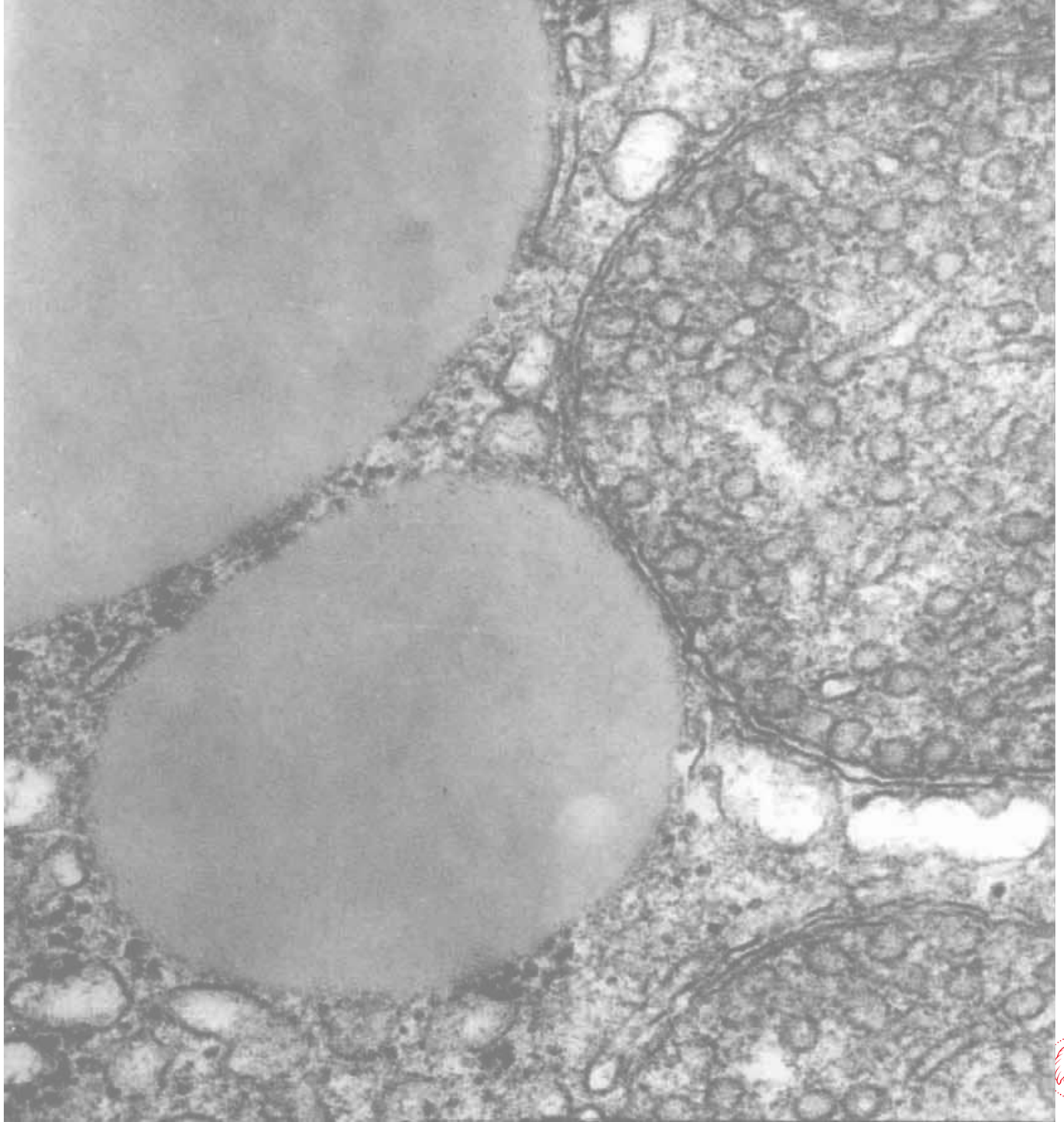

SECOND FACULTY OF MEDICINE
CHARLES UNIVERSITY

Nadledvina – dřeň

- anastomózující trámce polyedrických buněk (feochromocyty)
  - **adrenalin, noradrenalin**

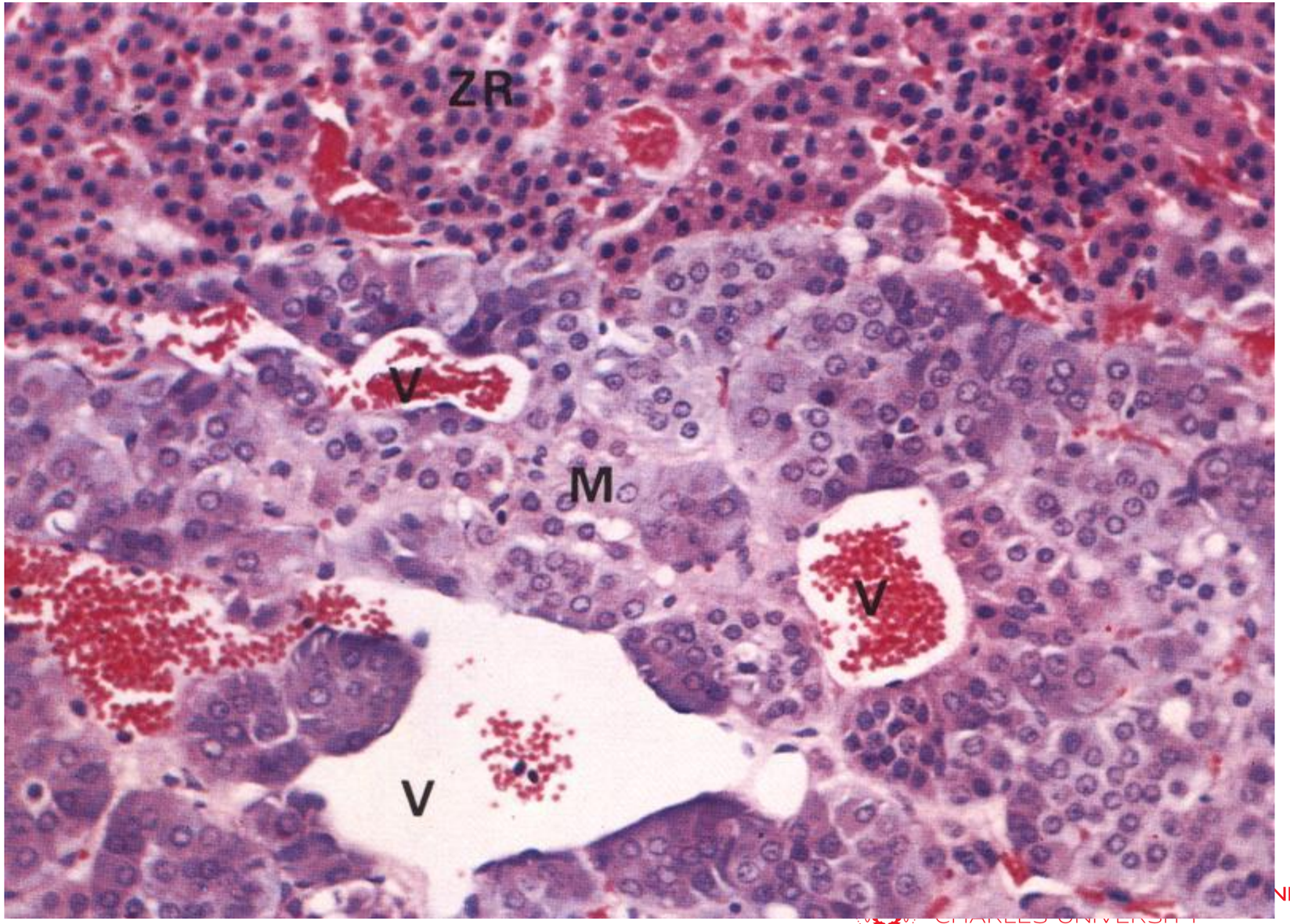

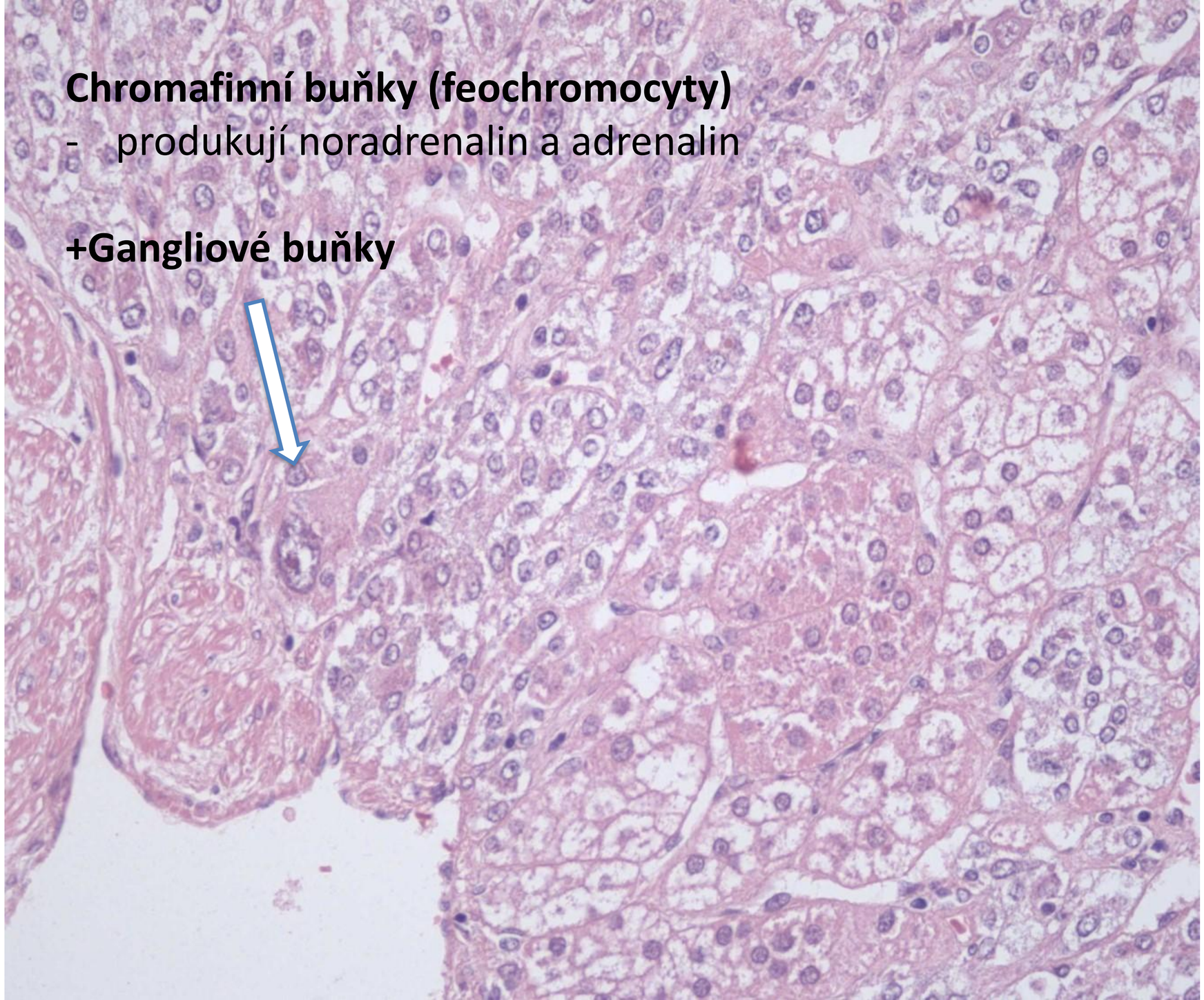

inervace cestou g.coeliacum

E = buňka produkující adrenalin
NE = buňka produkující noradrenalin



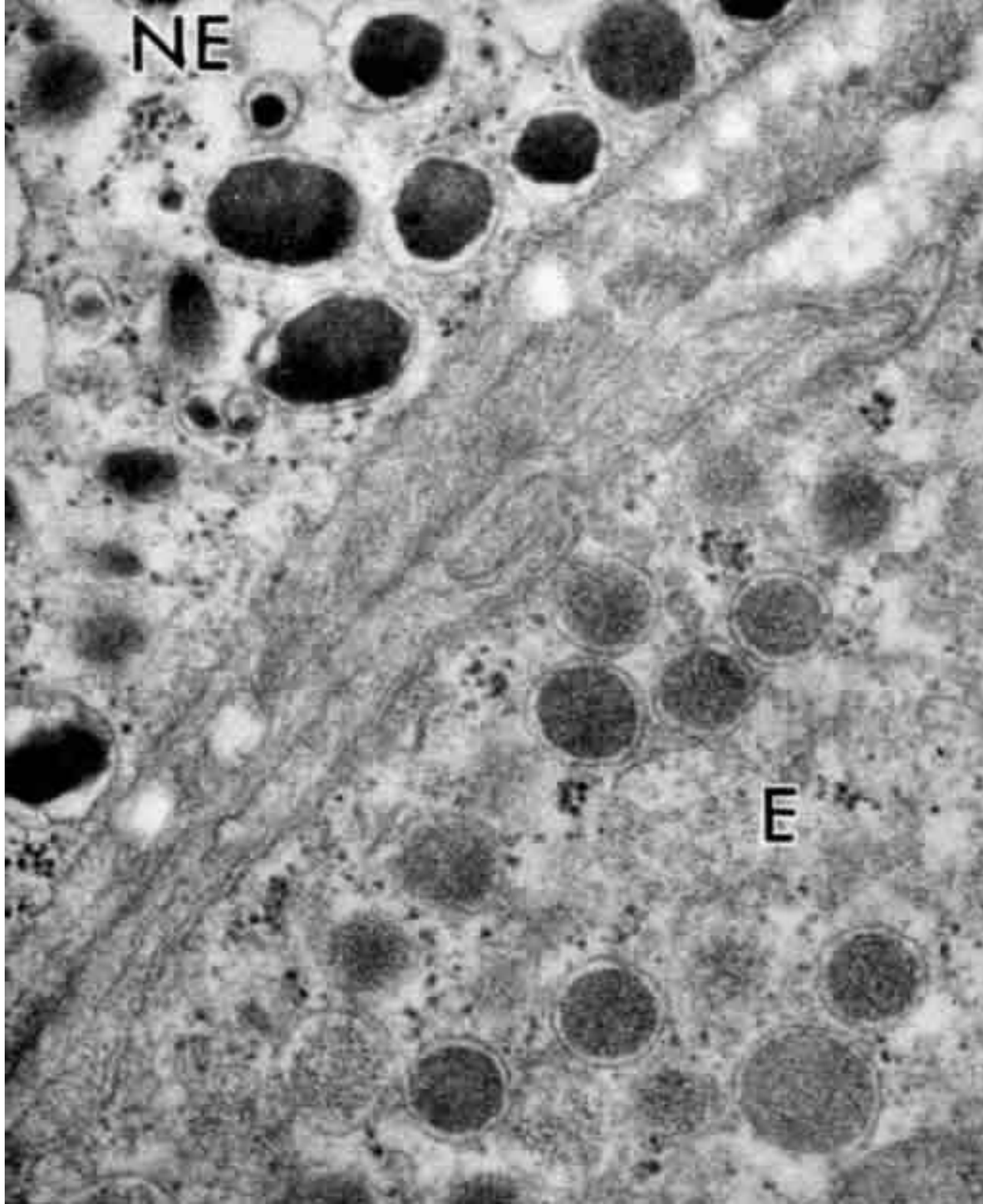

SYMPTOMS
of Cushing's syndrome

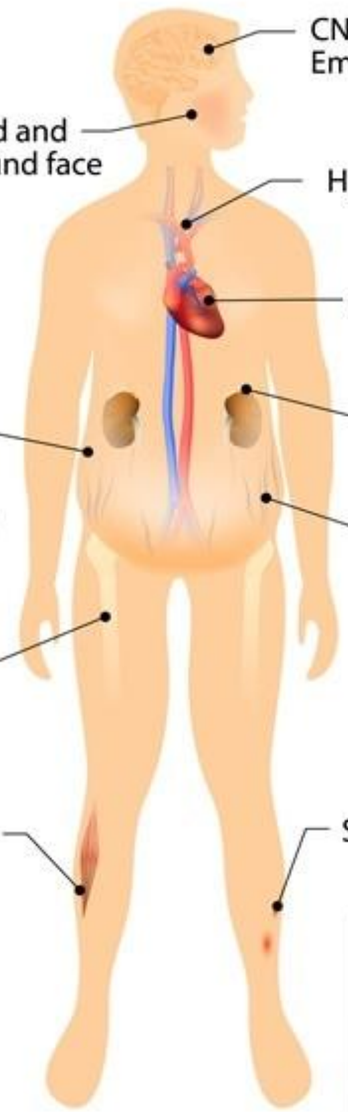

CNS irritability
Emotional disturbances

Red and round face

Hypertension

Cardiac hypertrophy

Obesity (fat deposition on abdomen and back of neck)

Hyperplasia, tumor

Purple striae

Osteoporosis

Muscle wasting

Skin ulcers

In females:
- amenorrhea, hirsutism

In males:
- erectile dysfunction

Addison's disease

Adrenal glands not produce sufficient steroid hormones

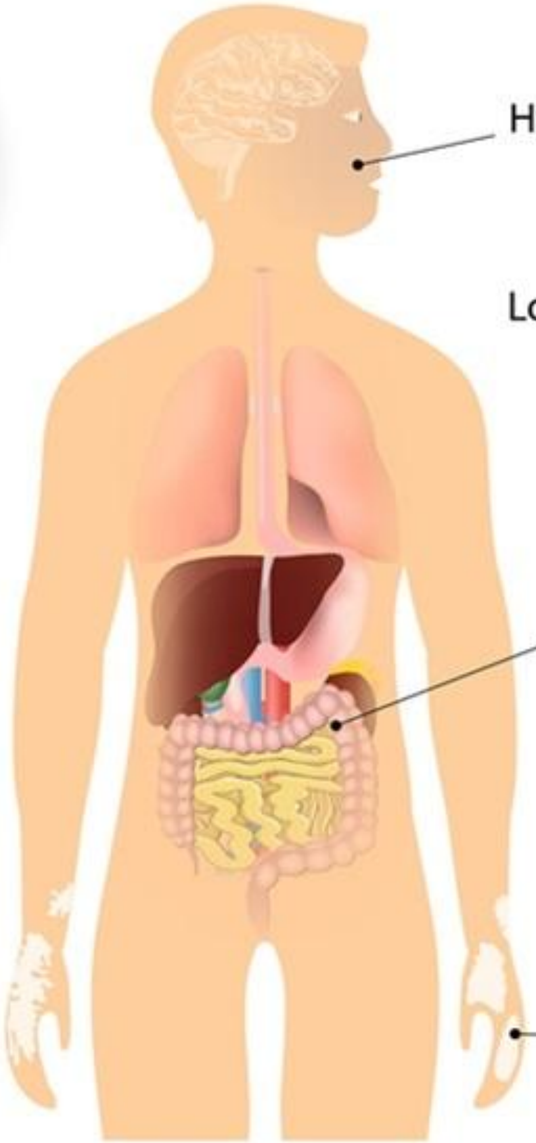

Skin
Hyperpigmentation

Low blood pressure
Weakness
Weight loss

Gastrointestinal
Nausea
Diarrhea
Vomiting
Constipation
Abdominal pain

Skin
Vitiligo

Adrenal crisis:
- fever;
- syncope;
- convulsions;
- hypoglycemia;
- hyponatremia;
- severe vomiting and diarrhea.

Pankreas – endokrinní část



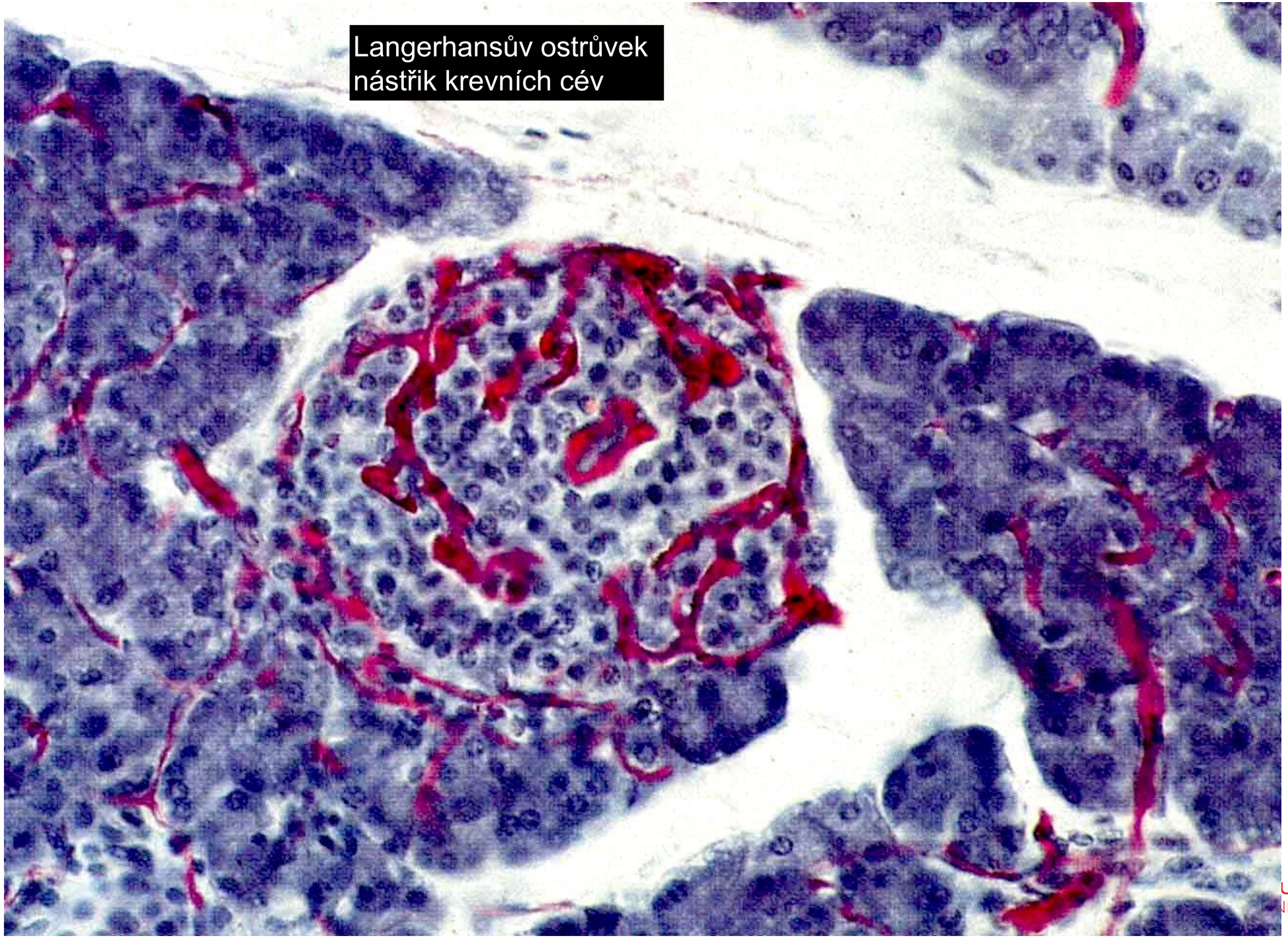

ULTY OF MEDICINE
IVERSITY

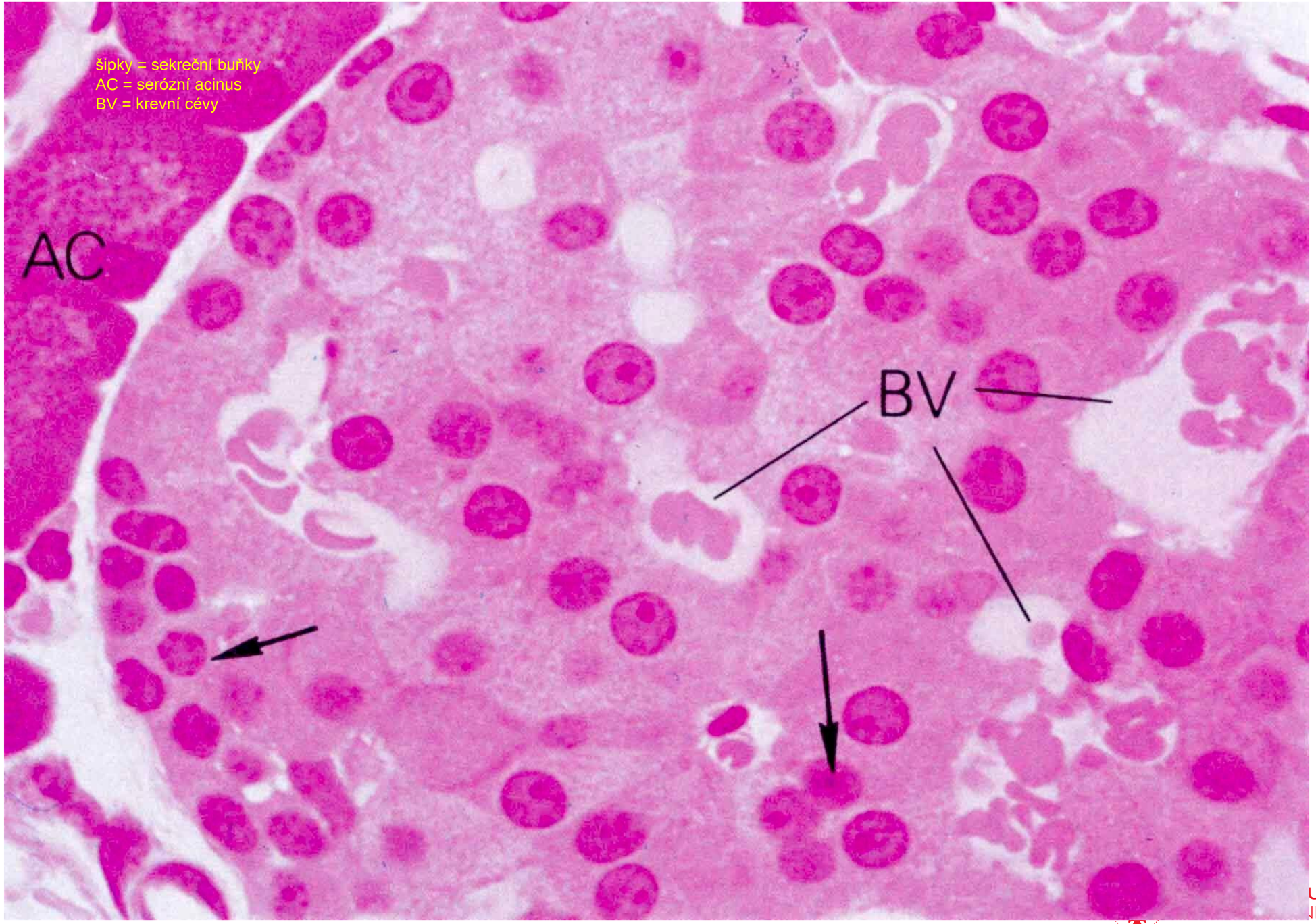

ULTY OF MEDICINE
NIVERSITY

Slinivkové (Langerhansovy) ostrůvky
typy buněk

- A-buňky
  - **glukagon** – hyperglykemicko-glykogenolytický faktor
- B-buňky
  - **inzulín** – hypoglykemický faktor
- D-buňky
  - jeden dlouhý výběžek buněk → parakrinní sekrece
  - **somatostatin**
- PP-buňky
  - **pankreatický polypeptid** → řízení exokrinní části slinivky

B buňky, asi 70 %, centrum, shluky

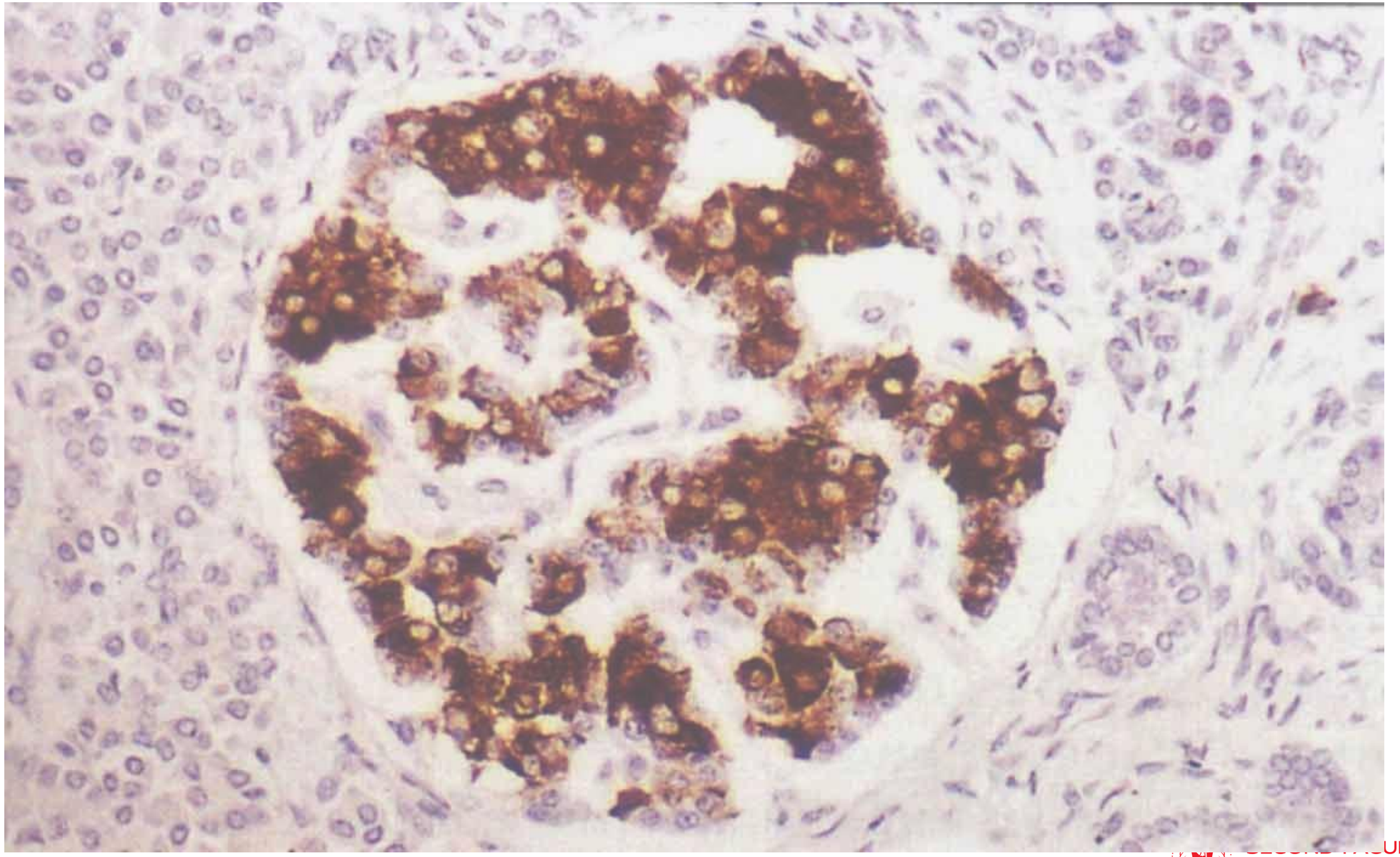

A buňky, do 20 %, periferie, ve vrstvách

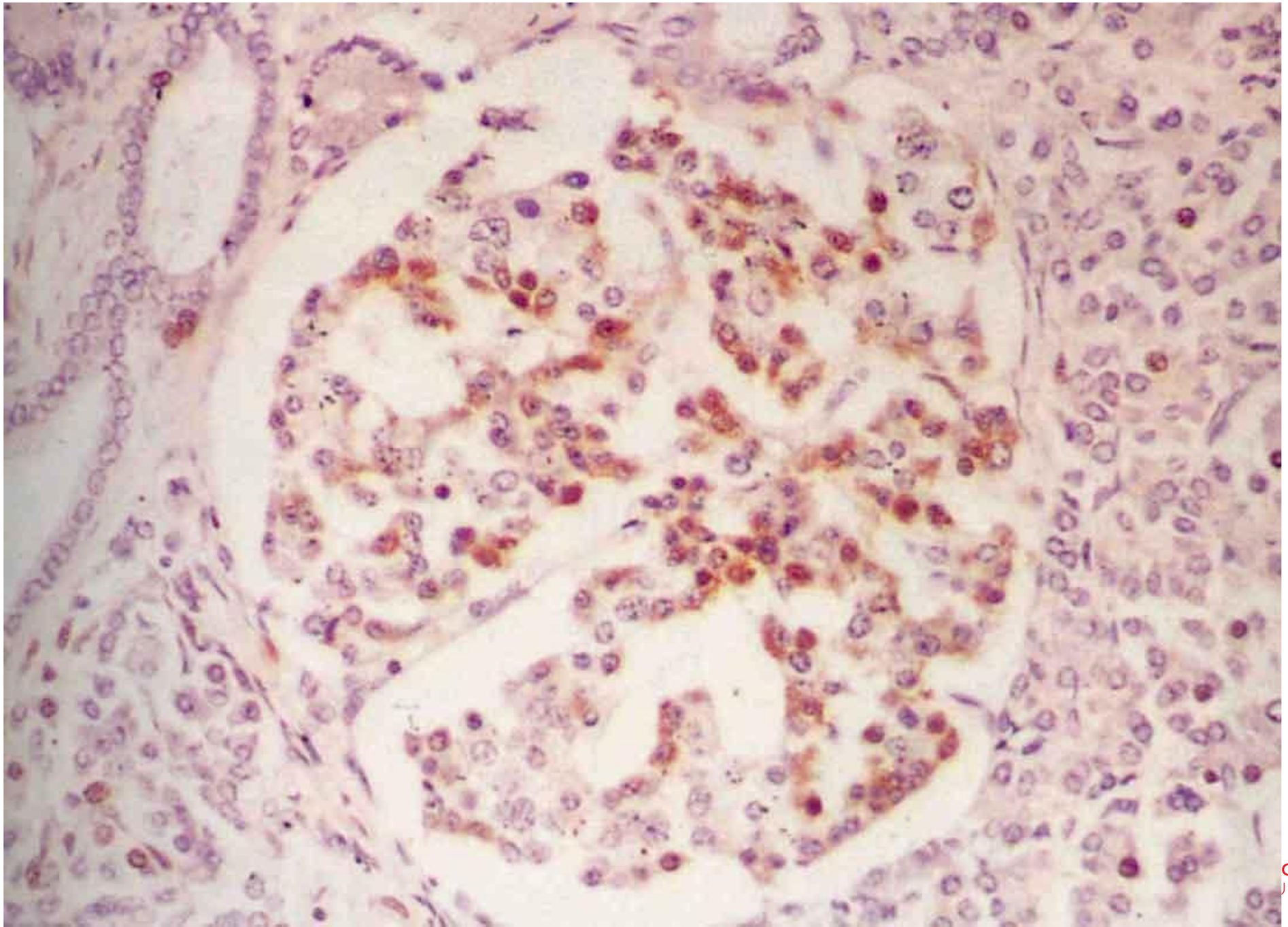

CULTY OF MEDICINE
UNIVERSITY

D buňky, do 5 %, roztroušeně

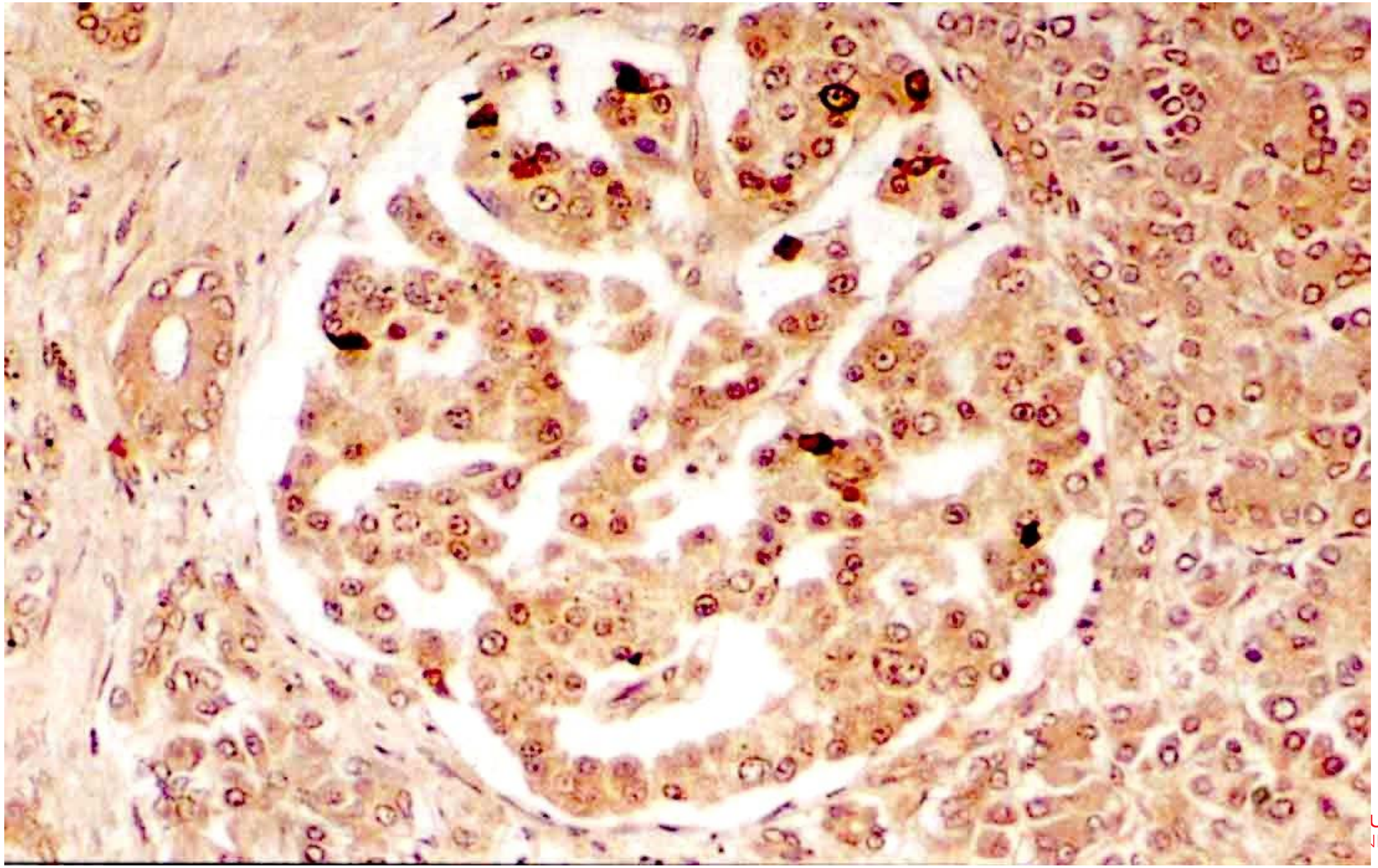

ULTY OF MEDICINE
IVERSITY

typ buňky	struktura granul	hormon
A	300 nm	glukagon
B	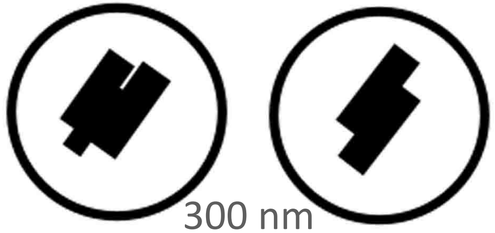 300 nm	insulin
D	250 nm	somatostatin
F	180 nm	pankreatický polypeptid

E (ghrelin), EC (substance P), D_1 (VIP), G (gastrin)

B buňka

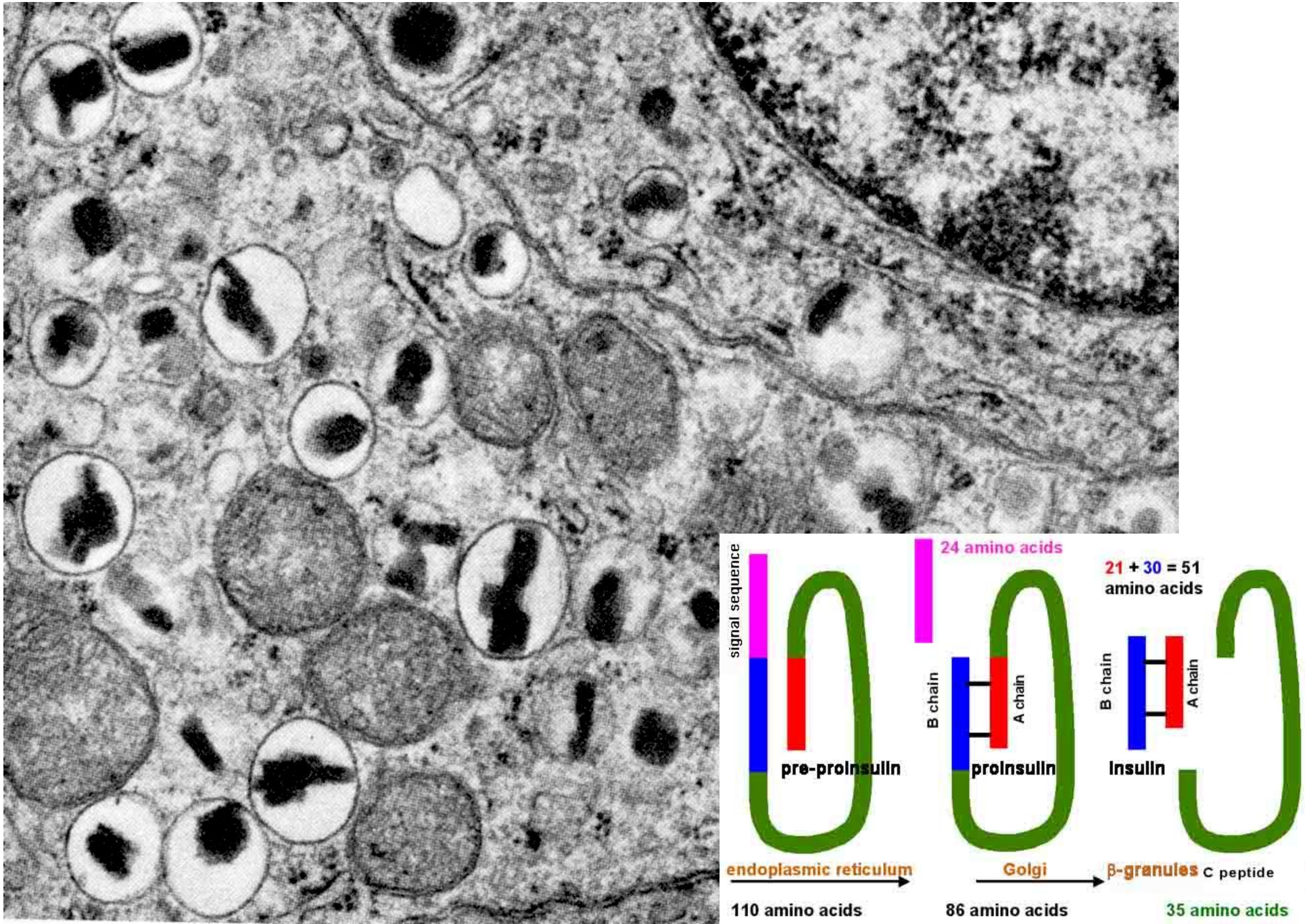

ULTY OF MEDICINE
IVERSITY

Diabetes mellitus

- = chronické metabolické onemocnění jehož hlavním a společným projevem je **hyperglykemie** vzniklá v důsledku absolutního či relativního **nedostatku inzulinu**.
- 1.typ = autoimunitní destrukce Langerhansových ostrůvků zánětem – nutnost inzulinoterapie prakticky od začátku onemocnění
- 2.typ = nedostatečná sekrece inzulinu a inzulinová rezistence v periferních tkáních (GLUT-4) receptory
- Skracuje život v průměru o 7let.
- Chronické i akutní komplikace jsou život ohrožující

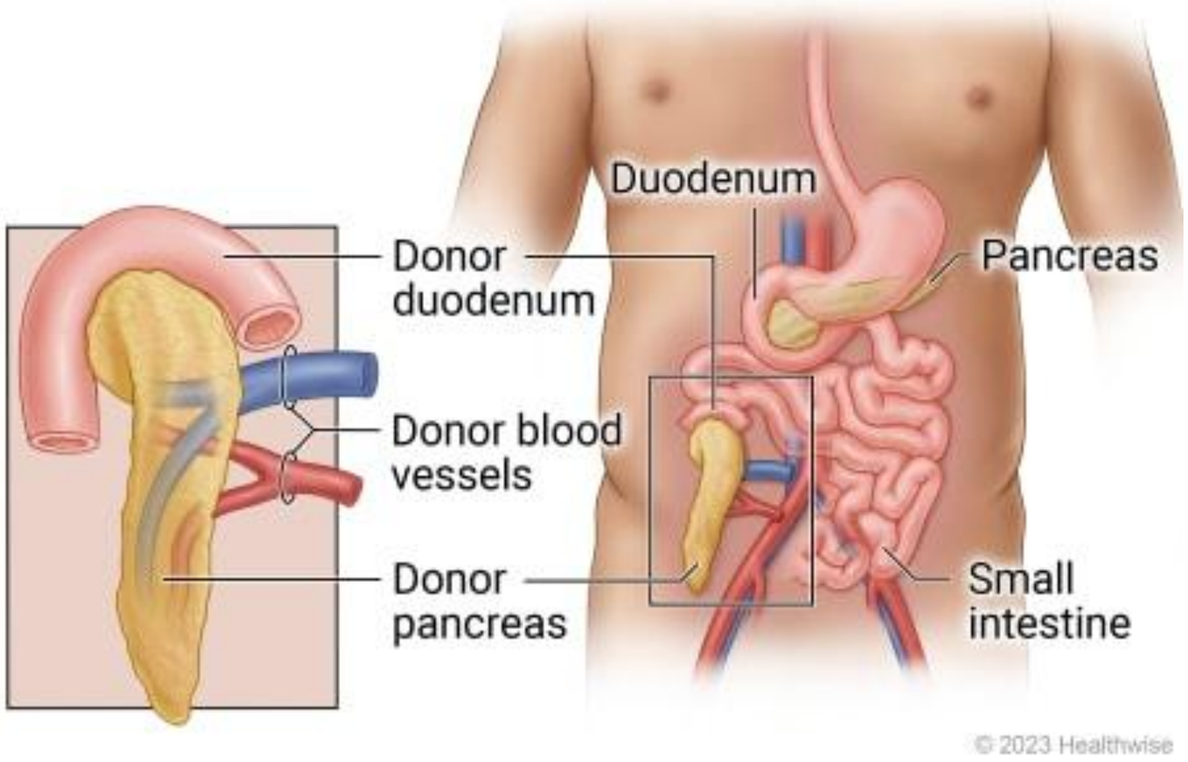
Duodenum
Donor duodenum
Pancreas
Donor blood vessels
Donor pancreas
Small intestine
© 2023 Healthwise

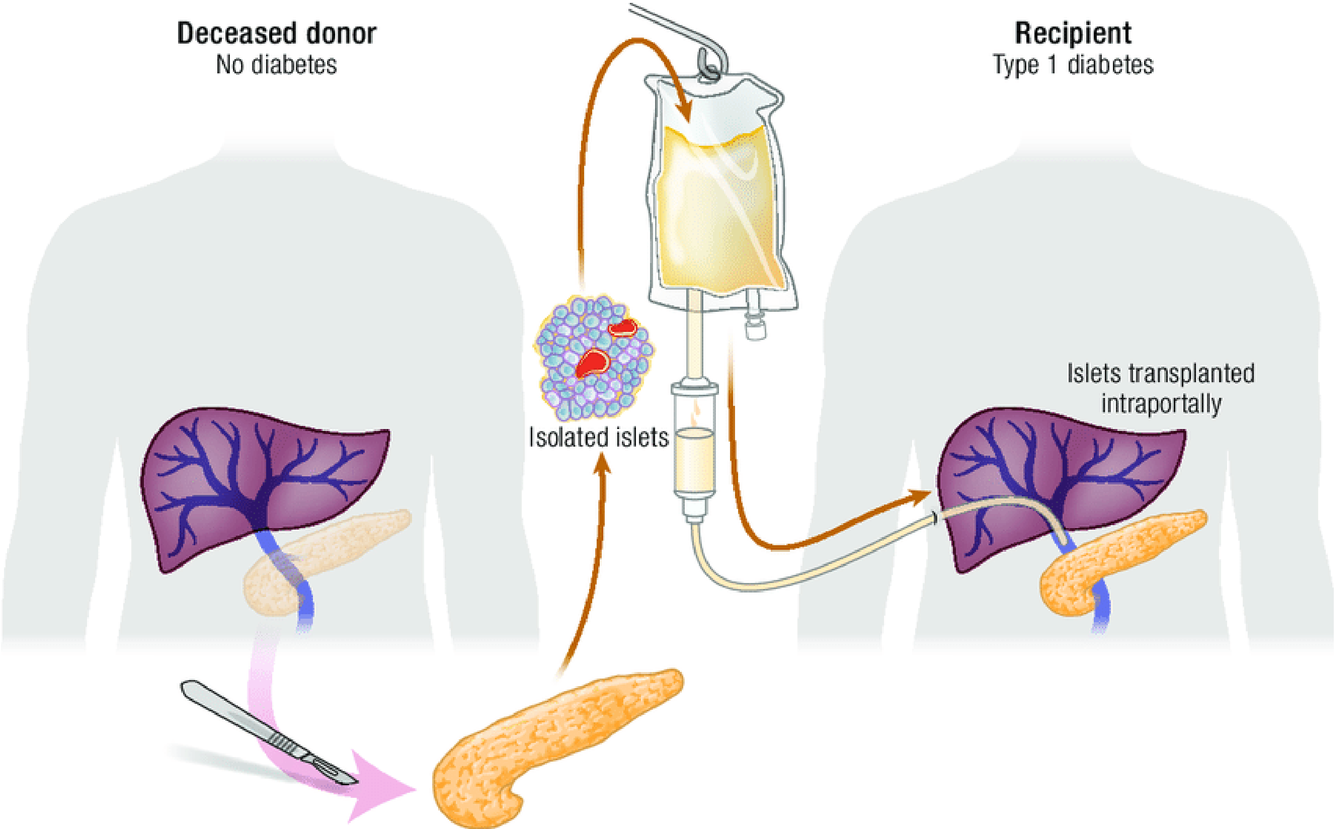
Deceased donor
No diabetes
Recipient
Type 1 diabetes
Isolated islets
Islets transplanted intraportally

Čas na otázky ☺