Pohlavní systém mužský

Kamila Procházková

A Little Known Fact

It took 100 years for men to realize that the brain is also important.

Organa genitalia masculina interna

- testis (*orchis*) = varle
- epididymis = nadvarle
- funiculus spermaticus
  semenný provazec
  - včetně ductus deferens (= chámovodu)
- glandula vesiculosa / seminalis (vesiculae seminales) = semenné váčky
- prostata = předstojná žláza
- glandula bulbourethralis = bulvotrubicová žláza

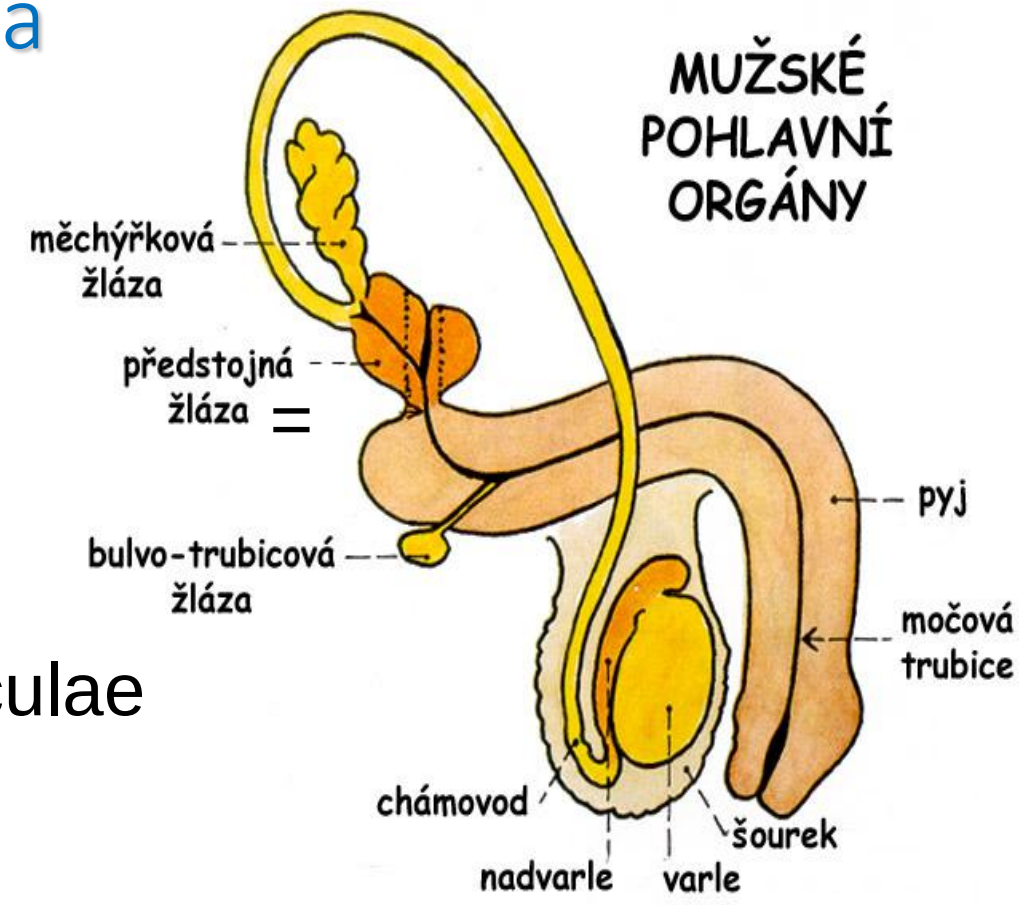

Organa genitalia masculina externa

- penis = pyj
- urethra masculina = mužská močová trubice
- scrotum = šourek

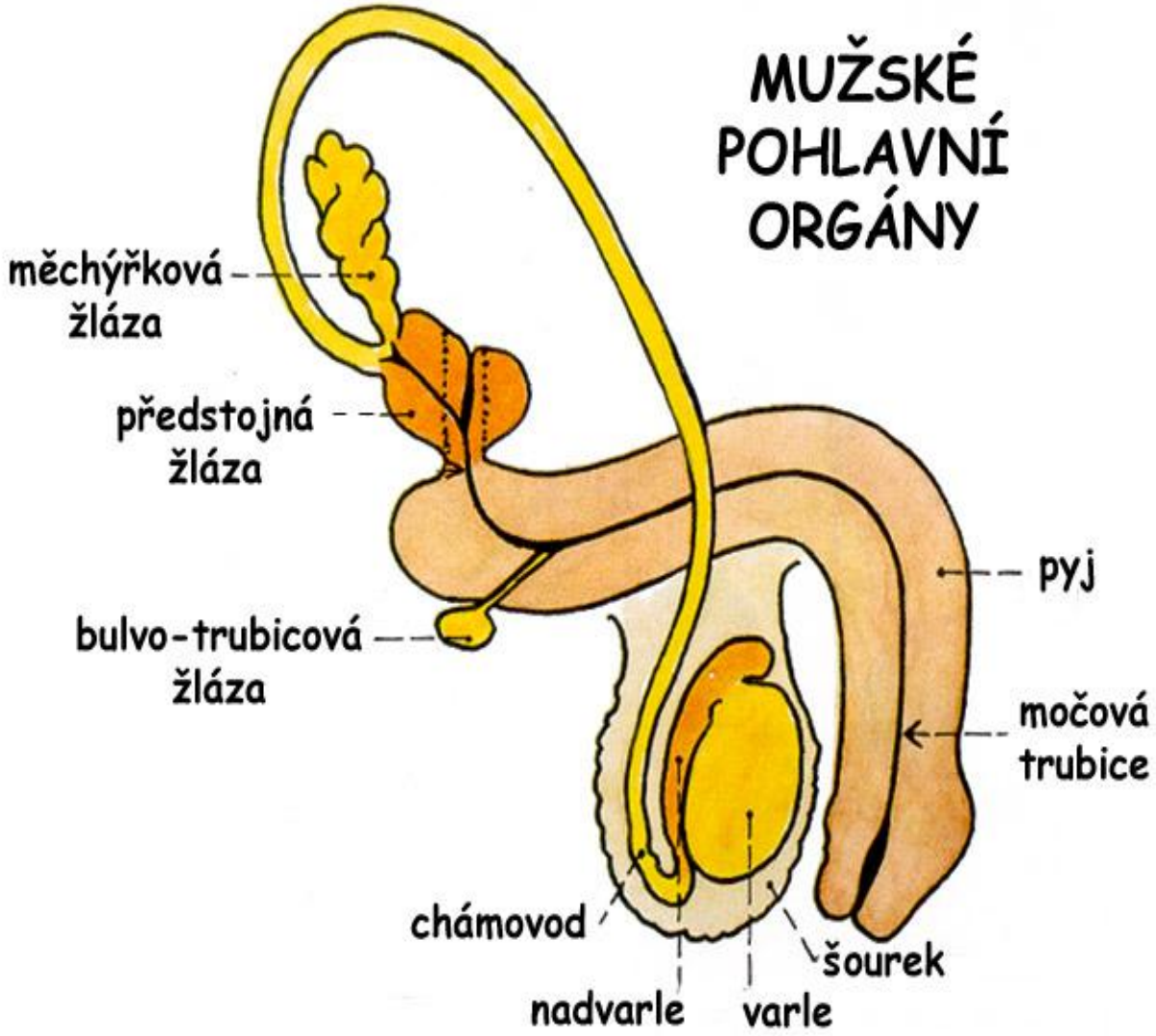

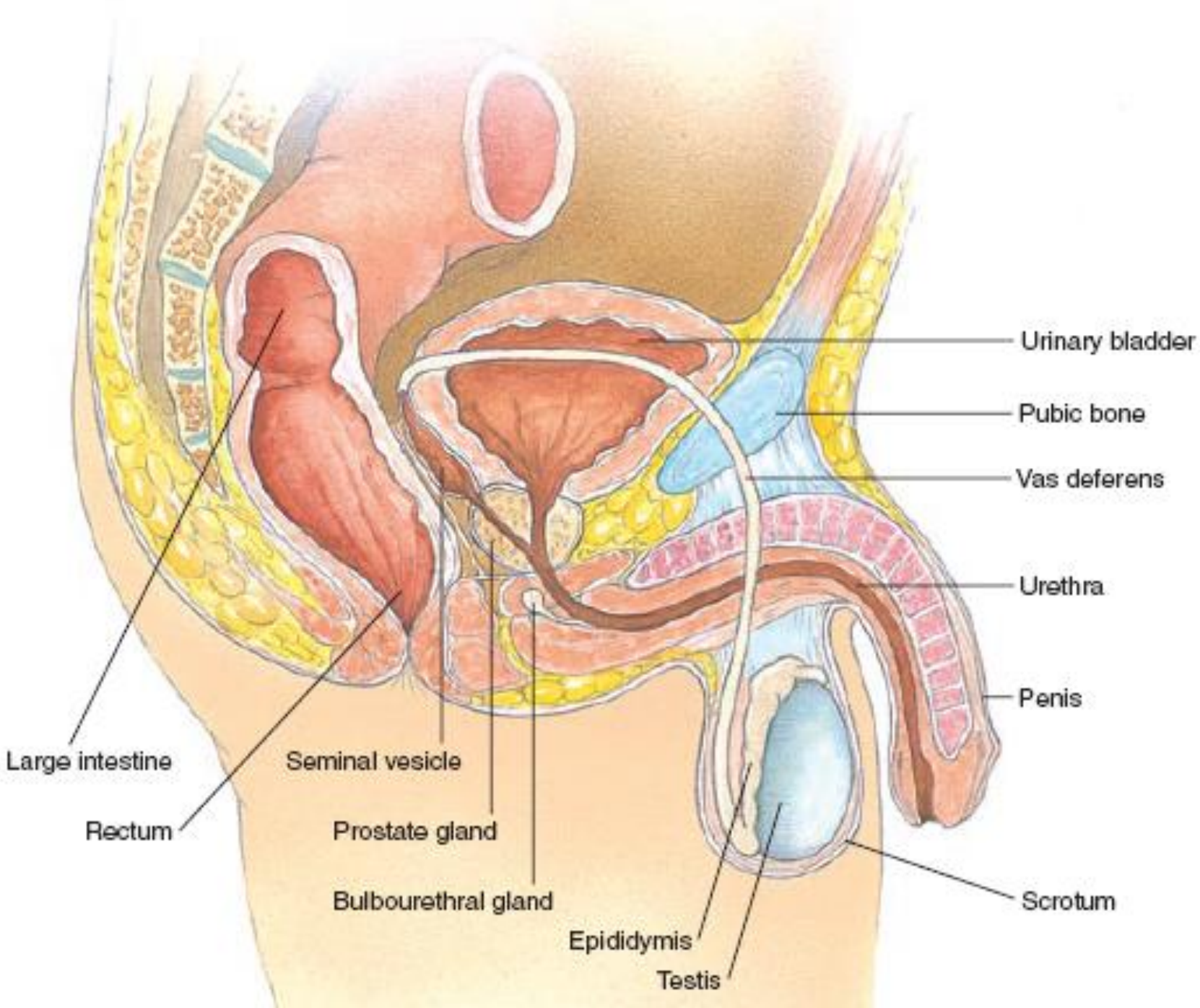
Urinary bladder
Pubic bone
Vas deferens
Urethra
Penis
Large intestine
Seminal vesicle
Rectum
Prostate gland
Bulbourethral gland
Scrotum
Epididymis
Testis

Organa genitalia masculina interna

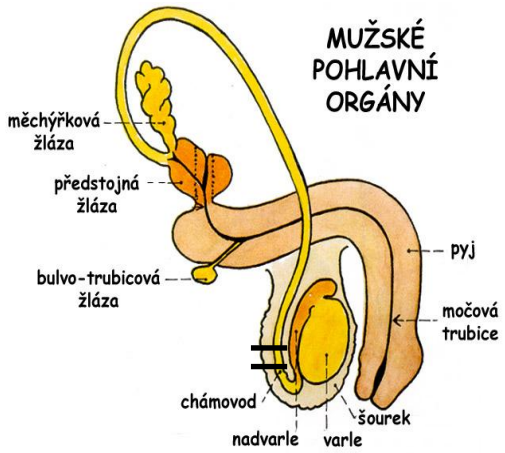

- testis (*orchis*) = varle
- epididymis = nadvarle
- funiculus spermaticus
  semenný provazec
  - včetně ductus deferens (= chámovodu)
- glandula vesiculosa / seminalis (vesiculae seminales) = semenné váčky
- prostata = předstojná žláza
- glandula bulbourethralis = bulvotrubicová žláza

Orchis

Orchis italica

Orchis italica – naked-man orchid

Orchis militaris

Varle = Testis

- vnější popis
  - extremitas superior
    + inferior
  - facies medialis
    + lateralis
  - margo anterior
    + posterior
- obaly a vrstvy
  - tunica vaginalis
    - lamina parietalis
    - cavitas vaginalis testis
    - lamina visceralis
  - tunica albuginea

100. Varle a nadvarle – testis et epididymis

1 Varle
Testis
2 Horní pól
Extremitas anterior
3 Přední okraj
Margo anterior
4 Zadní okraj
Margo posterior
5 Zevní plocha
Facies lateralis
6 Dolní pól
Extremitas inferior
7 Nadvarle
Epididymis
8 Hlava nadvarlete
Caput epididymidis
9 Tělo nadvarlete
Corpus epididymidis
10 Ocas nadvarlete
Cauda epididymidis
11 Chámovod
Ductus deferens
12 Šourkový vaz
Lig. scrotale (gubernaculum testis)

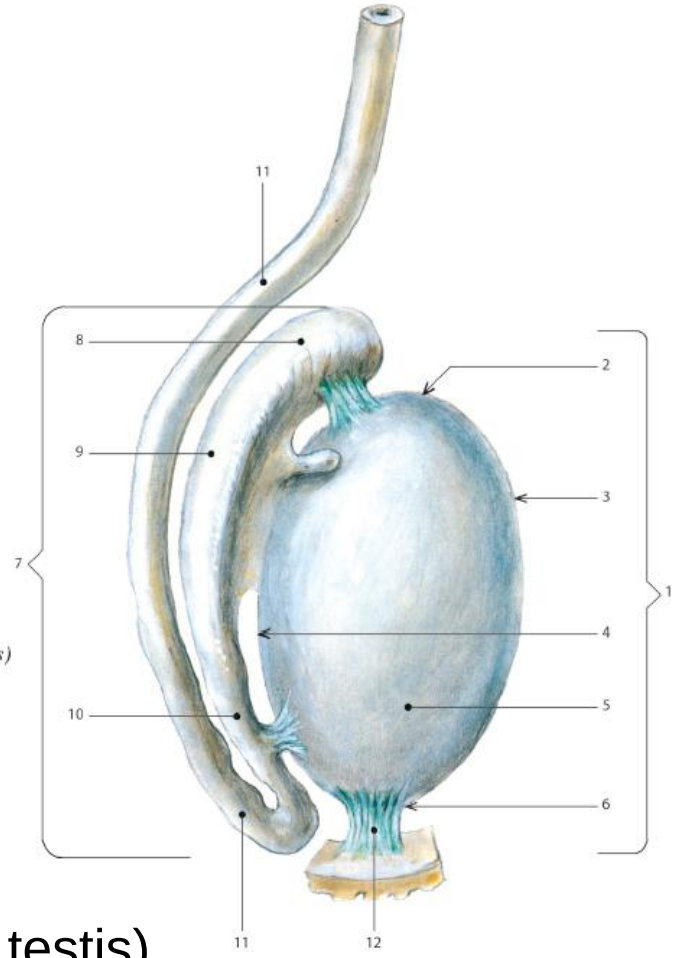

- vazy
  - lig. scrotale
    (zbytek po gubernaculum testis)
  - lig. epididymidis superius + inferius
- teplota: o 2°C nižší

https://is.muni.cz/do/fsps/e-learning/zaklady_anatomie/zakl_anatomie_II/pages/muzske_organy.html

Varle = Testis

- vnější popis
  - extremitas superior
    + inferior
  - facies medialis
    + lateralis
  - margo anterior
    + posterior
- obaly a vrstvy
  - tunica vaginalis
    - lamina parietalis
    - cavitas vaginalis testis
    - lamina visceralis
  - tunica albuginea

100. Varle a nadvarle – testis et epididymis

1 Varle
Testis
2 Horní pól
Extremitas anterior
3 Přední okraj
Margo anterior
4 Zadní okraj
Margo posterior
5 Zevní plocha
Facies lateralis
6 Dolní pól
Extremitas inferior
7 Nadvarle
Epididymis
8 Hlava nadvarlete
Caput epididymidis
9 Tělo nadvarlete
Corpus epididymidis
10 Ocas nadvarlete
Cauda epididymidis
11 Chámovod
Ductus deferens
12 Šourkový vaz
Lig. scrotale (gubernaculum testis)

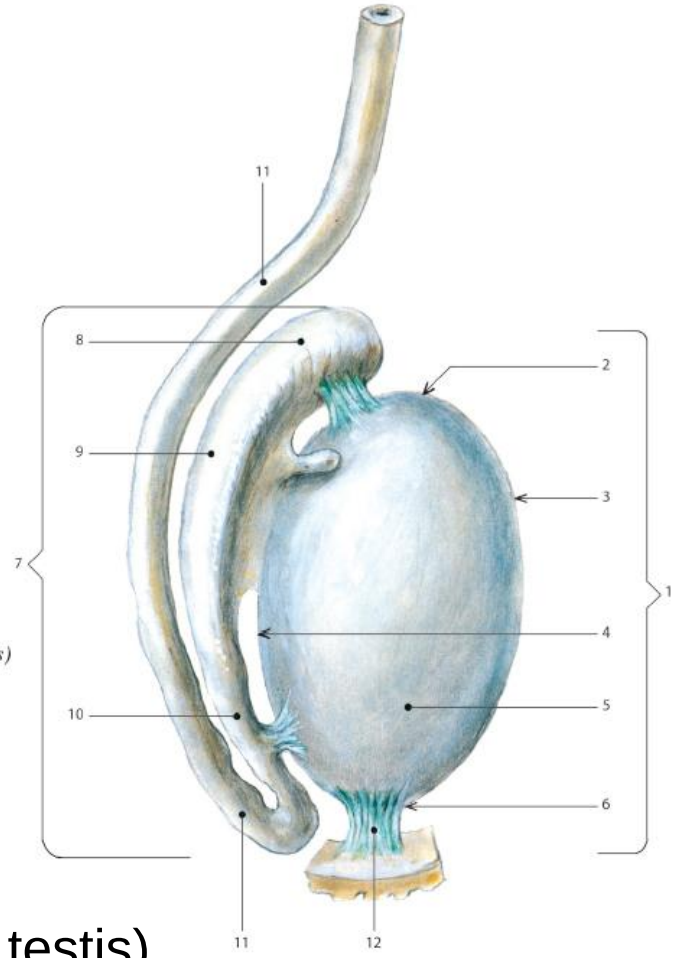

- vazy
  - lig. scrotale
    (zbytek po gubernaculum testis)
  - lig. epididymidis superius + inferius
- teplota: o 2°C nižší

https://is.muni.cz/do/fsps/e-learning/zaklady_anatomie/zakl_anatomie_II/pages/muzske_organy.html

Varle = Testis

- vnější popis
  - extremitas superior
    + inferior
  - facies medialis
    + lateralis
  - margo anterior
    + posterior
- obaly a vrstvy
  - tunica vaginalis
    - lamina parietalis
    - cavitas vaginalis testis
    - lamina visceralis
  - tunica albuginea

100. Varle a nadvarle – testis et epididymis

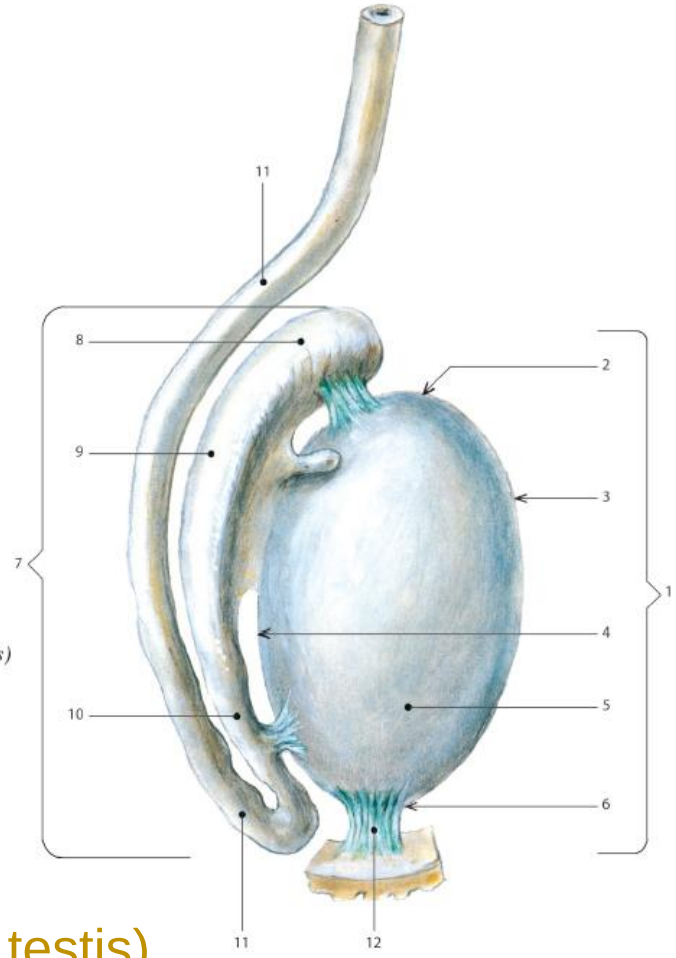

- vazy
  - lig. scrotale
    (zbytek po gubernaculum testis)
  - lig. epididymidis superius + inferius
- teplota: o 2°C nižší

https://is.muni.cz/do/fsps/e-learning/zaklady_anatomie/zakl_anatomie_II/pages/muzske_organy.html

Varle = Testis

- vnější popis
  - extremitas superior
    + inferior
  - facies medialis
    + lateralis
  - margo anterior
    + posterior
- obaly a vrstvy
  - tunica vaginalis
    - lamina parietalis
    - cavitas vaginalis testis
    - lamina visceralis
  - tunica albuginea

100. Varle a nadvarle – testis et epididymis

1 Varle
Testis
2 Horní pól
Extremitas anterior
3 Přední okraj
Margo anterior
4 Zadní okraj
Margo posterior
5 Zevní plocha
Facies lateralis
6 Dolní pól
Extremitas inferior
7 Nadvarle
Epididymis
8 Hlava nadvarlete
Caput epididymidis
9 Tělo nadvarlete
Corpus epididymidis
10 Ocas nadvarlete
Cauda epididymidis
11 Chámovod
Ductus deferens
12 Šourkový vaz
Lig. scrotale (gubernaculum testis)

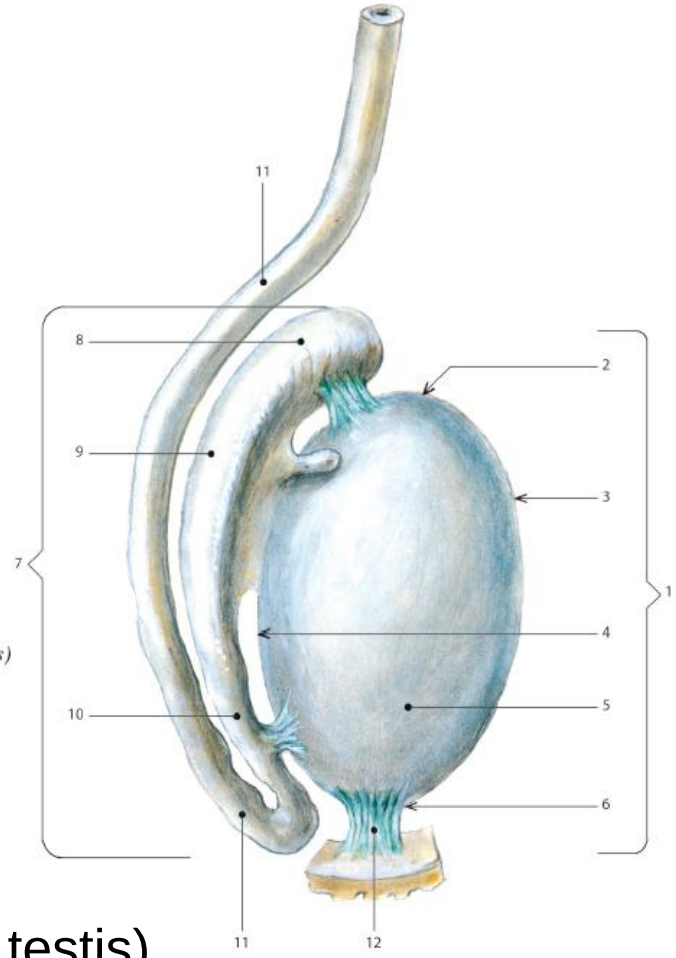

- vazy
  - lig. scrotale
    (zbytek po gubernaculum testis)
  - lig. epididymidis superius + inferius
- teplota: o 2°C nižší

https://is.muni.cz/do/fsps/e-learning/zaklady_anatomie/zakl_anatomie_II/pages/muzske_organy.html

obaly a vrstvy (varle je retroperitoneální)

tunica vaginalis (sestupující dvojlist peritonea – řídké kolagenní vazivo s elastickými vlákny, mesotel)

- lamina parietalis - periorchium
- cavitas vaginalis testis – cavum serosum scroti
- lamina visceralis - epiorchium

tunica albuginea

- husté kolagenní vazivo

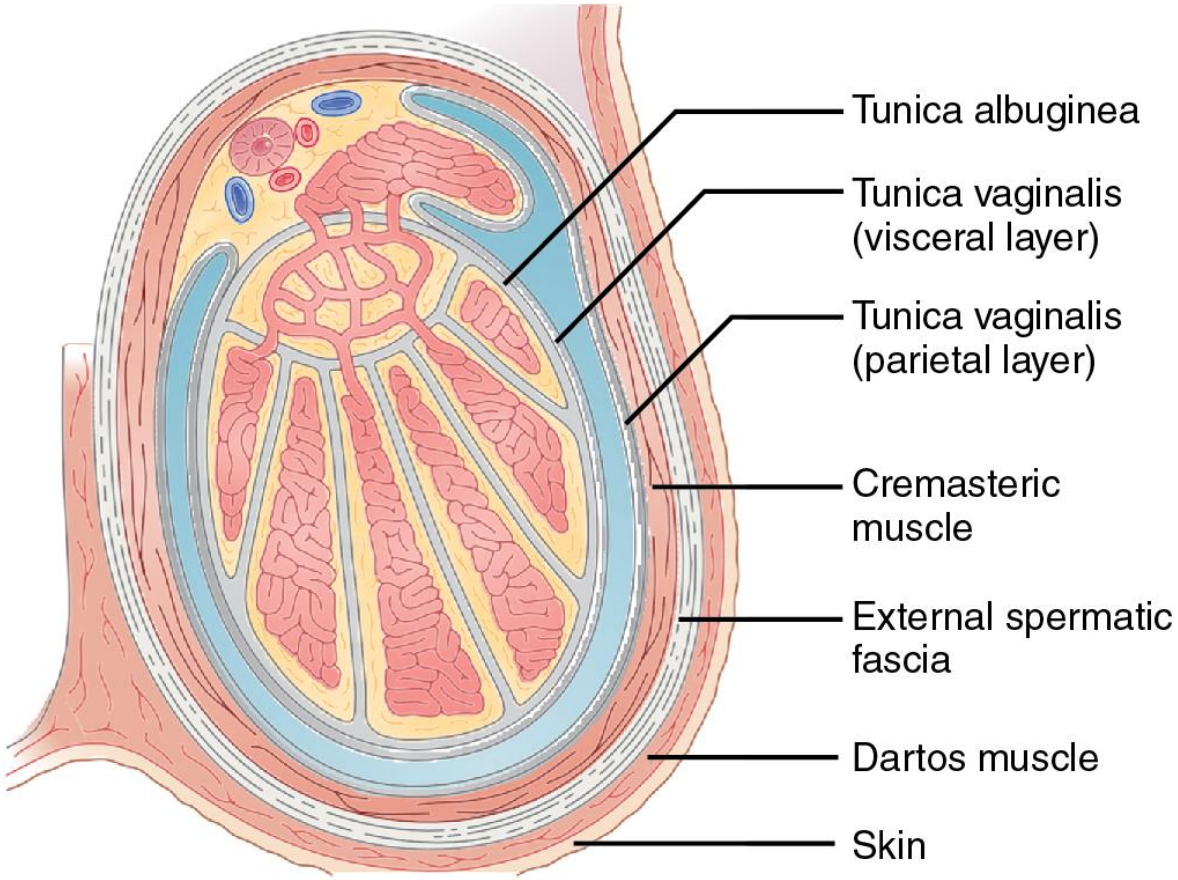

https://radiologykey.com/testicular-lesions/

Varle – *vnitřní stavba*

- tunica albuginea → septula
- tunica vasculosa
- parenchyma testis → lobuli testis (200-300)
- mediastinum testis
- tubuli seminiferi contorti (30-70 cm)
  - zárodečný epitel (složitý víceřadý)

→ tubuli recti testis → rete testis Halleri → ductus efferentes testis (již v hlavě nadvarlete)

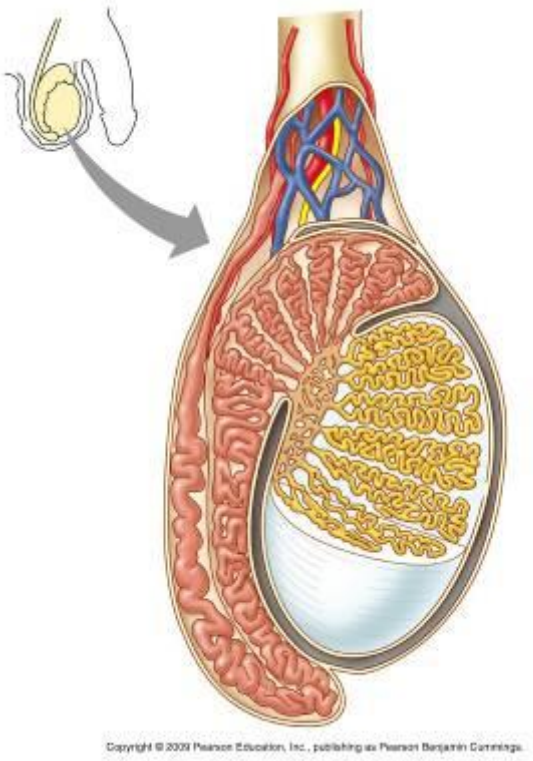

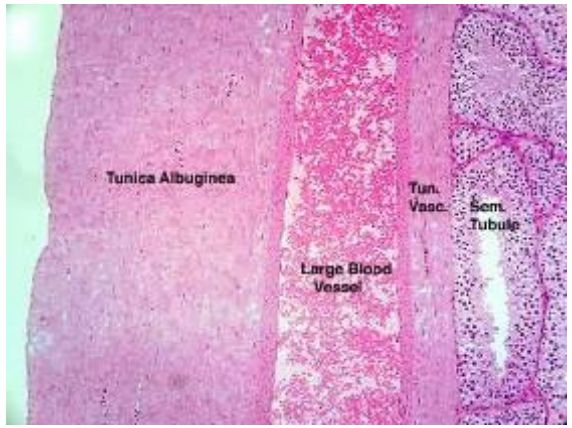

http://faculty.une.edu/com/abell/histo/histolab3f.htm

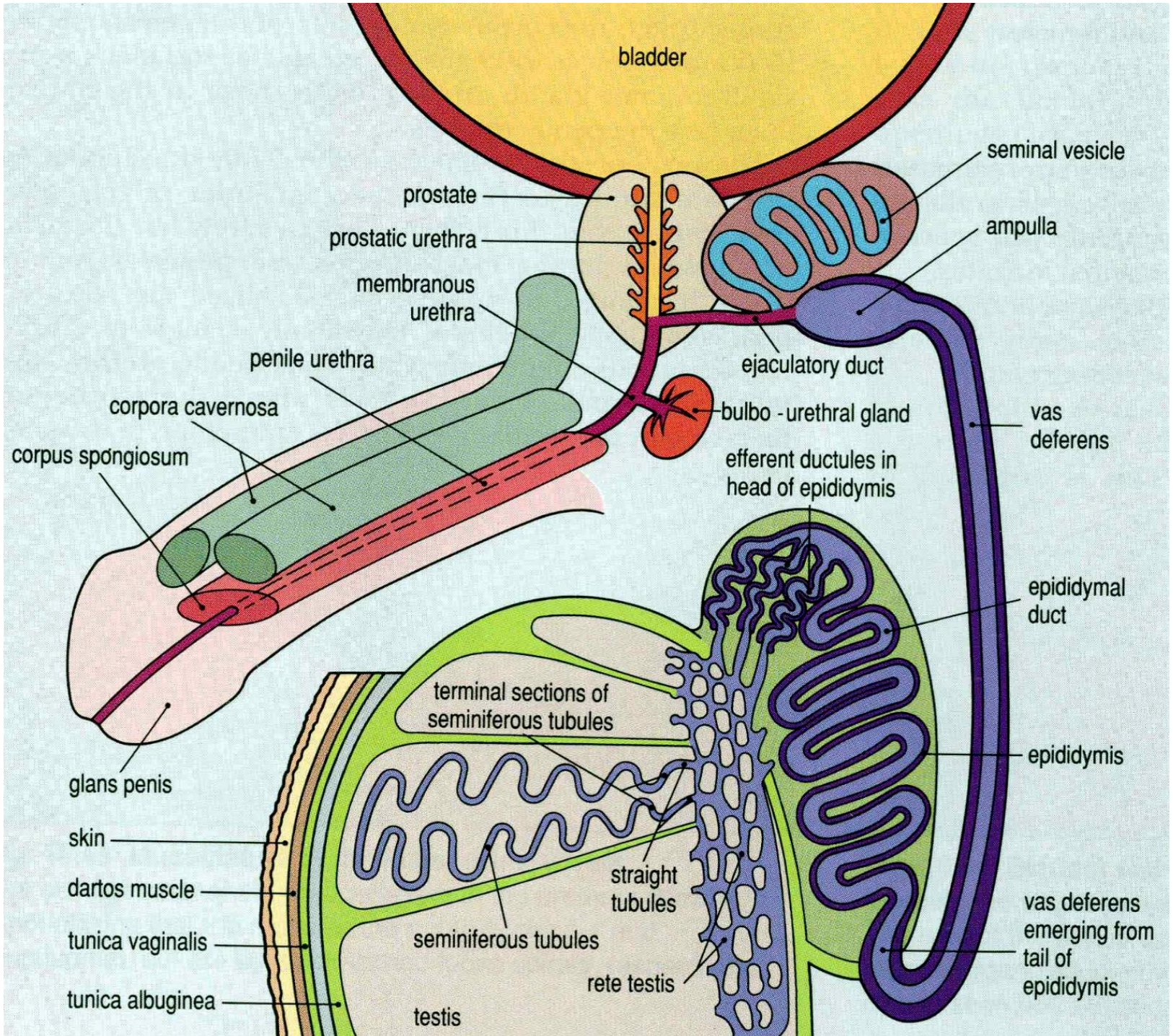
bladder
seminal vesicle
prostate
ampulla
prostatic urethra
membranous urethra
penile urethra
ejaculatory duct
corpora cavernosa
bulbo - urethral gland
vas deferens
corpus spongiosum
efferent ductules in head of epididymis
epididymal duct
terminal sections of seminiferous tubules
epididymis
glans penis
skin
straight tubules
dartos muscle
vas deferens emerging from tail of epididymis
tunica vaginalis
seminiferous tubules
rete testis
tunica albuginea
testis

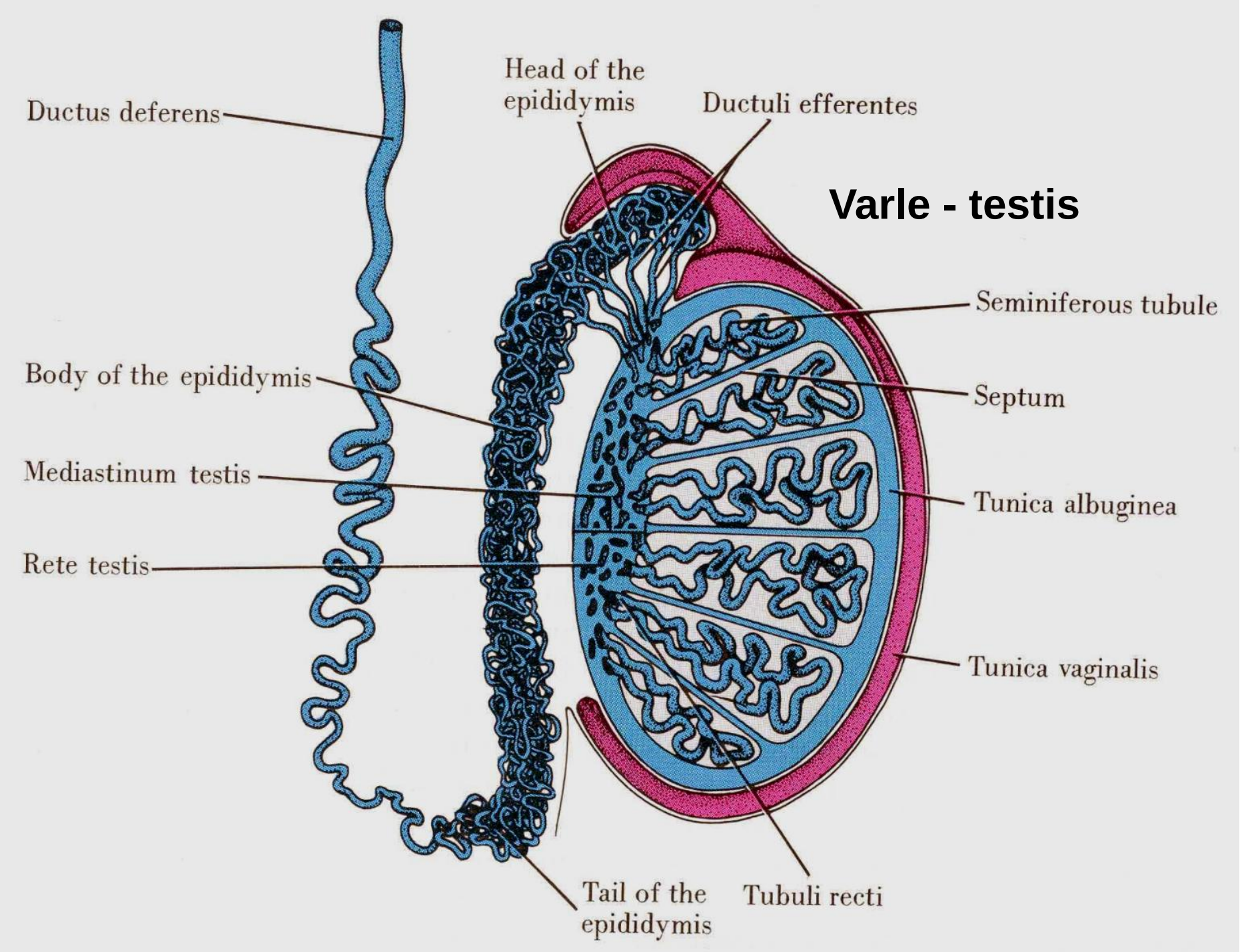
Varle - testis
Ductus deferens
Head of the epididymis
Ductuli efferentes
Seminiferous tubule
Body of the epididymis
Septum
Mediastinum testis
Tunica albuginea
Rete testis
Tunica vaginalis
Tail of the epididymis
Tubuli recti

Semenotvorné kanálky

- průsvit 150 - 250 µm
  - **Zárodečný (spermiogenní, semenný) epitel (složitý víceřadý)**
    – 80 µm vysoký
    - Zárodečné (spermiogenní) buňky
    - **Sertoliho** buňky (spojovací komplexy)

- bazální membrána
- LPM:
  – stratum myoideum
    - myoidní (peritubulární kontraktilní) buňky (myofibroblasty)
  – stratum fibrosum

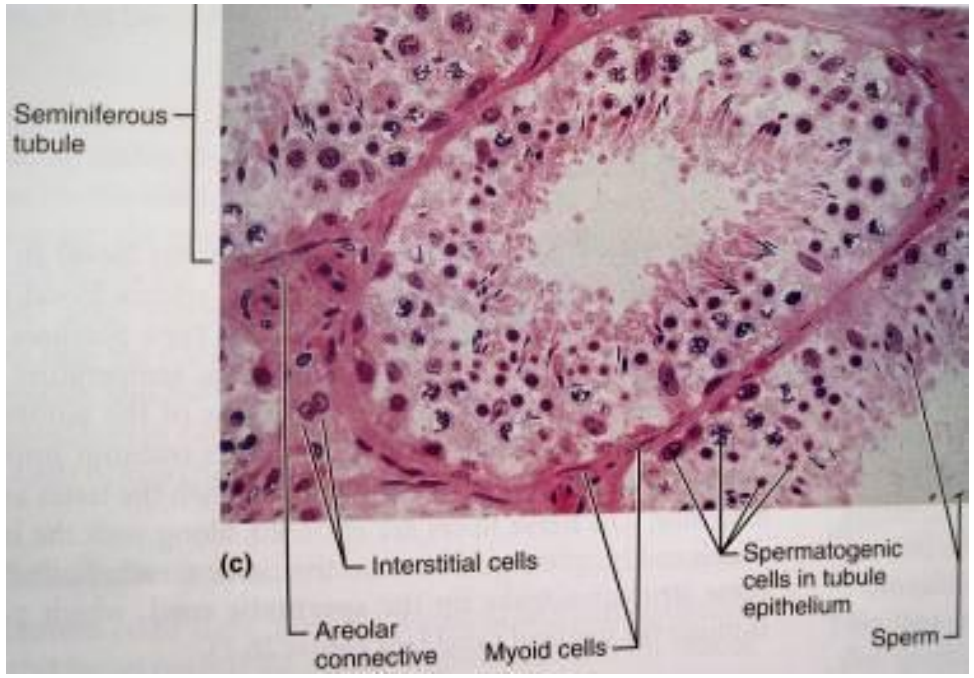

http://anatomyandphysiology2eportfolio.blogspot.cz/2011/02/objective-79-mommy-whats-that.html

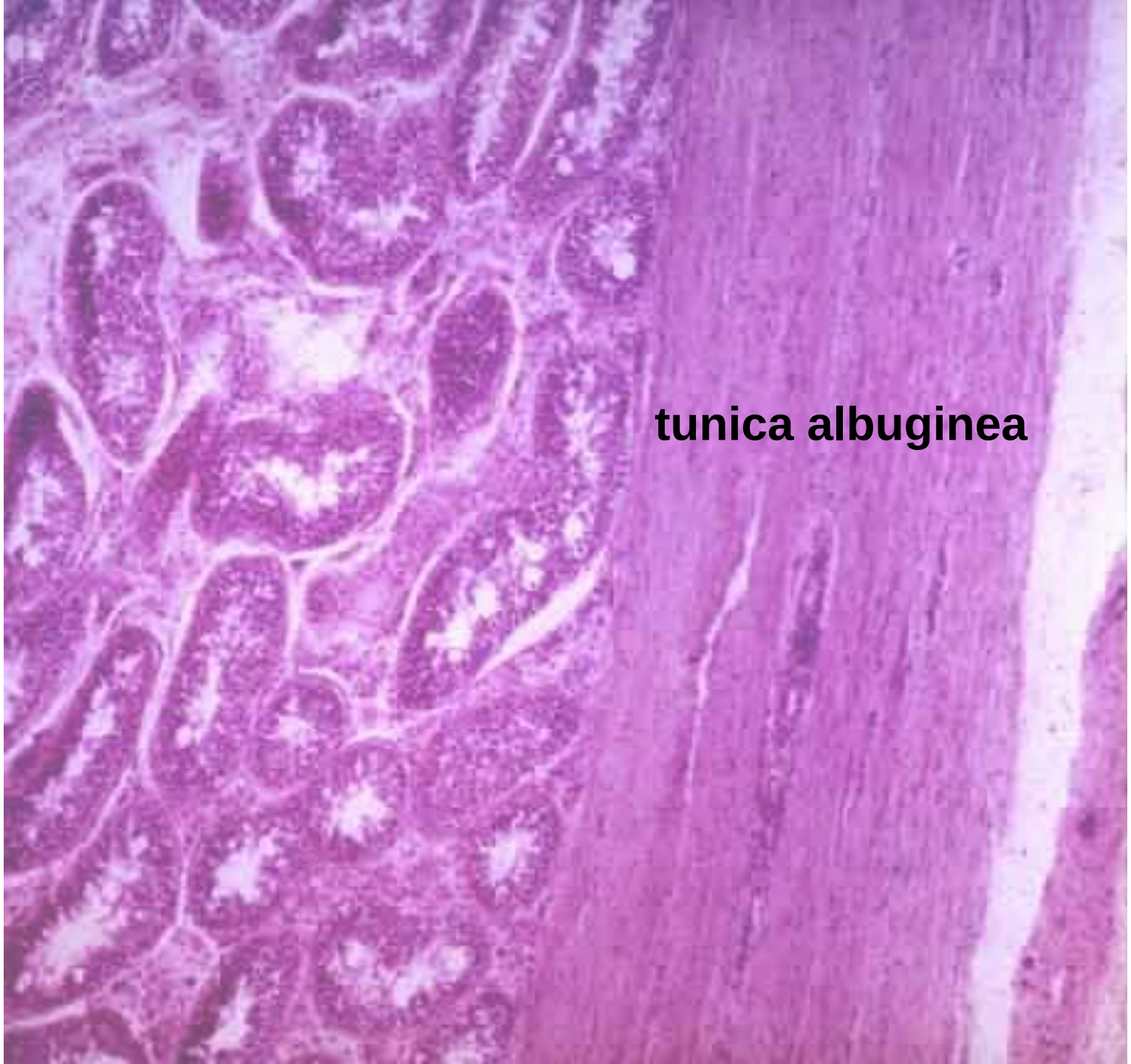
tunica albuginea

Tubuli seminiferi contorti

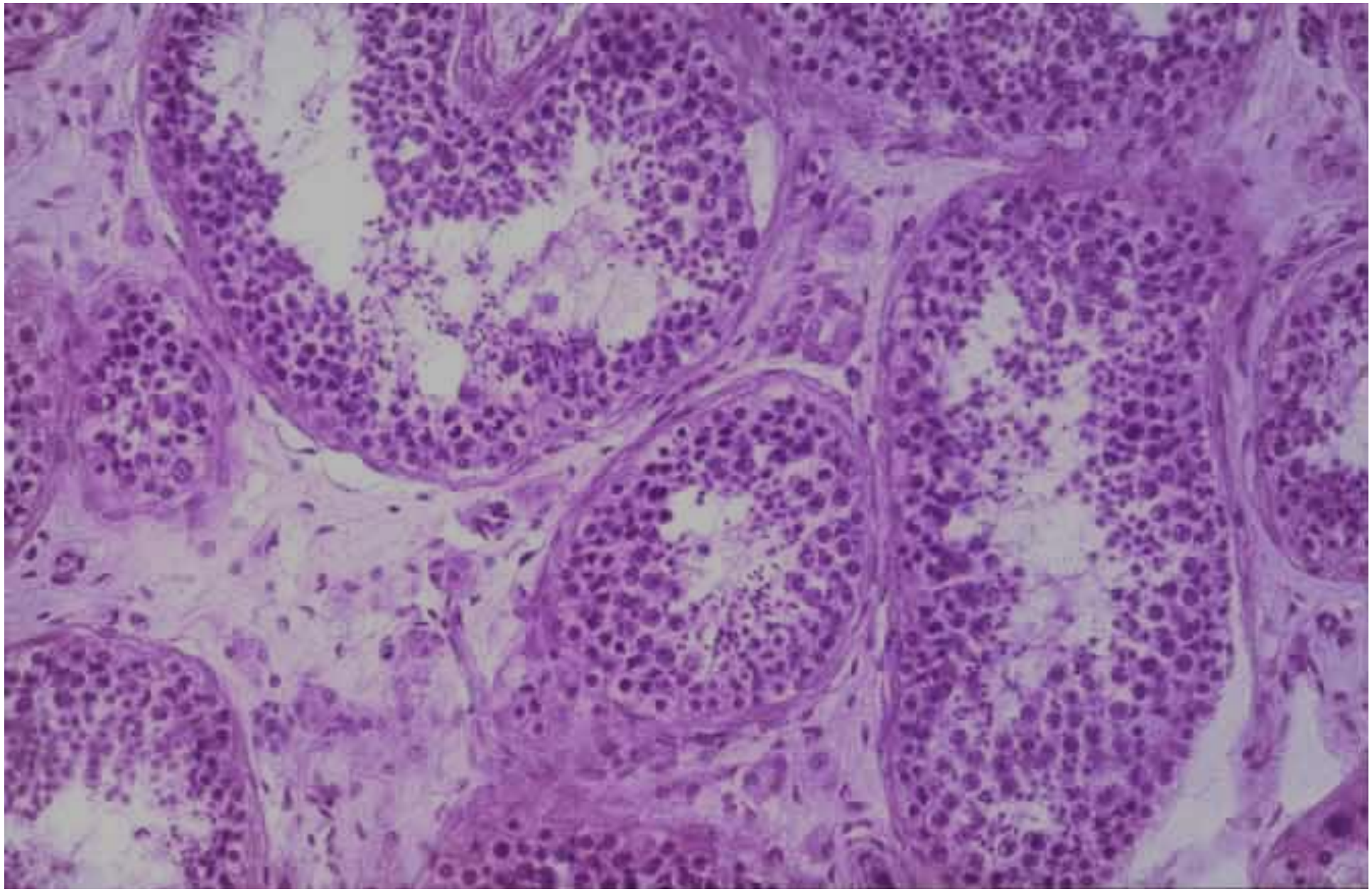

Zárodečný epitel
Epithelium spermatogenicum

- Vývoj spermií
- zárodečné buňky (*cellulae spermatogenicae*)
  - jednotlivá stadia vývoje spermií = **spermatogenesis**
    - Spermatocytogeneze

      (spermatogonie 2n → primární a sekundární spermatocyty → spermatidy n)
    - Spermatohistogeneze

      (spermiogeneze)
    - (spermatidy → spermie)

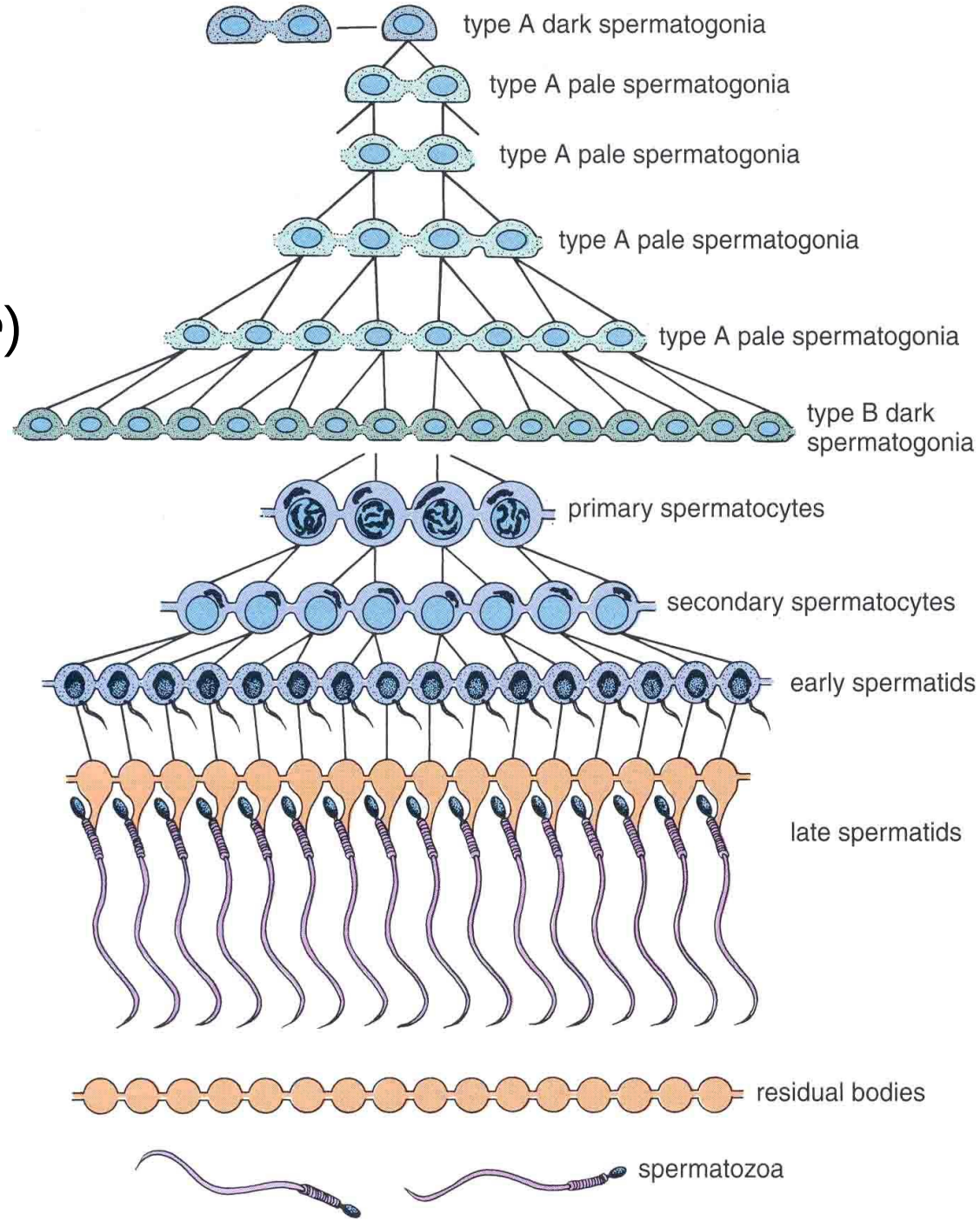

Zárodečný epitel
Epithelium spermatogenicum

- zárodečné buňky (*cellulae spermatogenicae*)
  - jednotlivá stadia vývoje spermií = **spermatogenesis**
  - 4-8 řad jader
    - spermatogonie (A a B)
      - u stěny kanálku, dělí se *mitoticky*
      - B pronikají do adluminálního kompartmentu
    - primární spermatocyty
      - dělí se v 1. *meiotickém* dělení
    - sekundární spermatocyty
      - dělí se 2. *meiotickém* dělení
    - spermatidy (*spermatidia*)
      - zrají a uvolňují se do nitra kanálků, odplaveny
  - šroubovitě uspořádány
  - **64 dní = spermatogenesis**

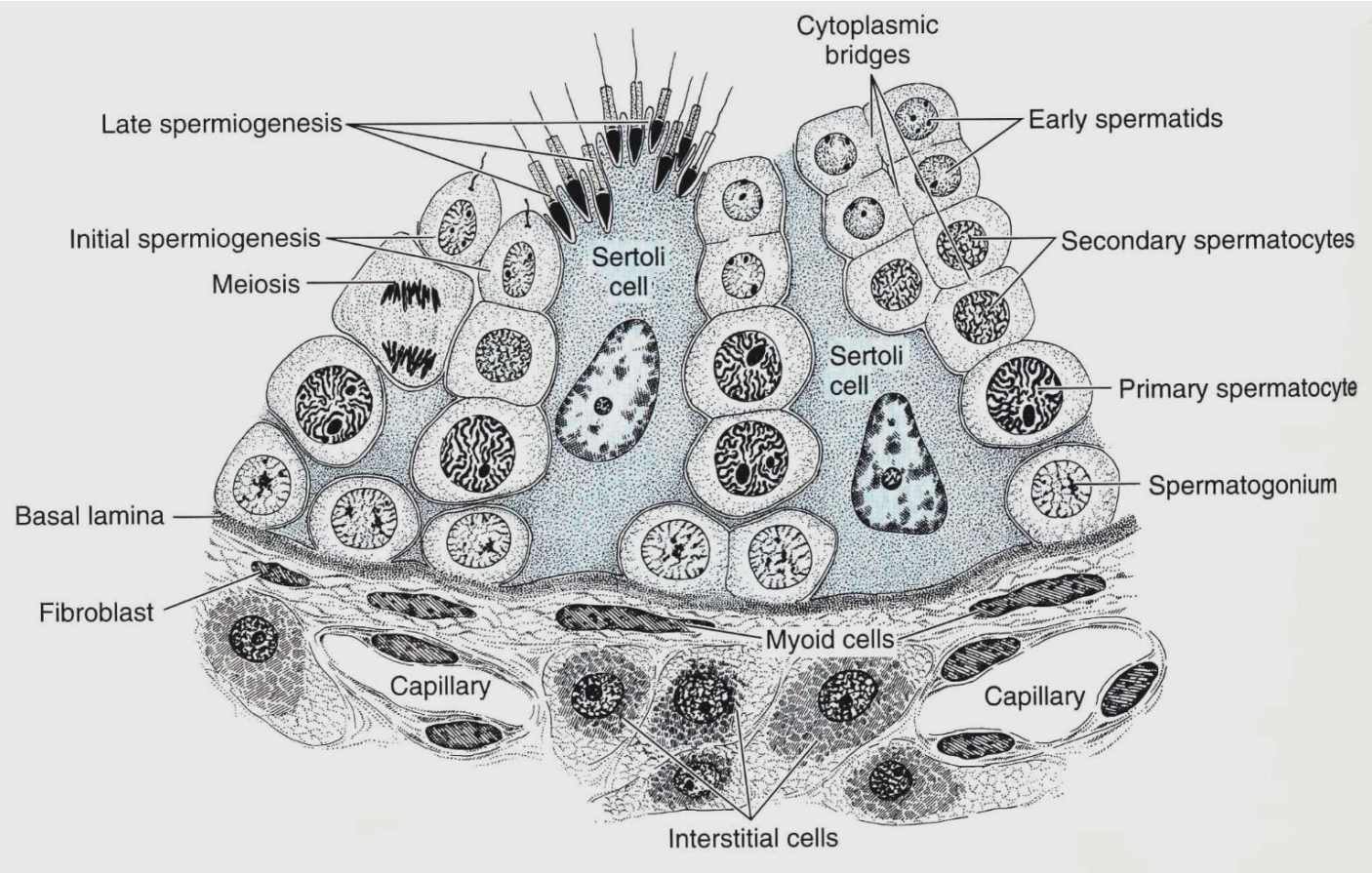

Spermatocytogeneze

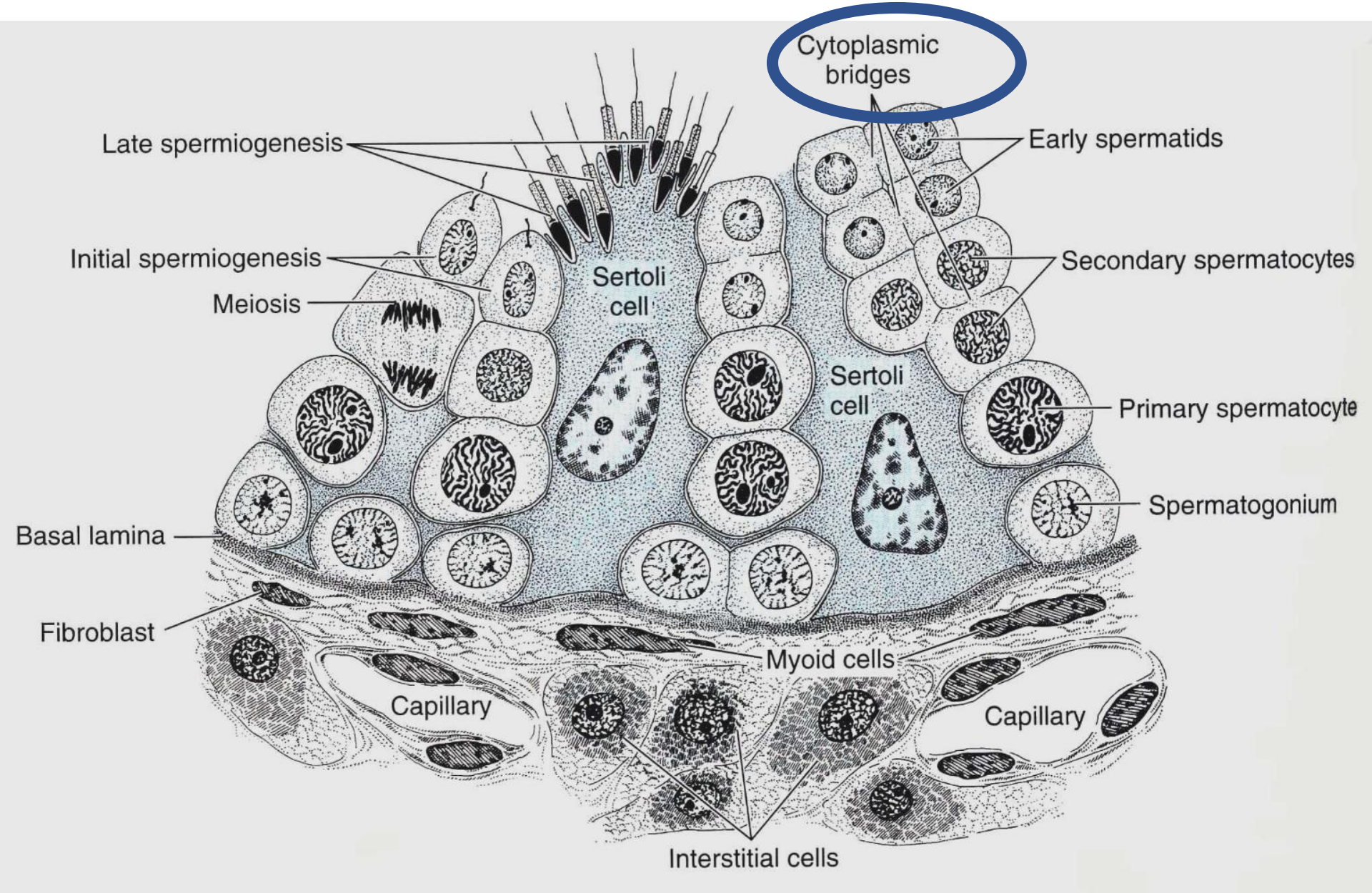

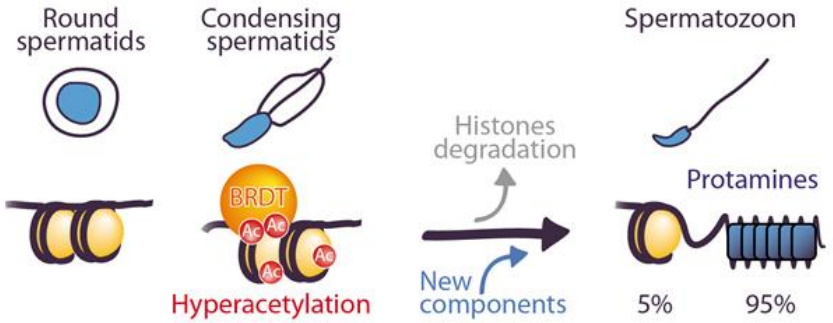

Spermatohistogeneze

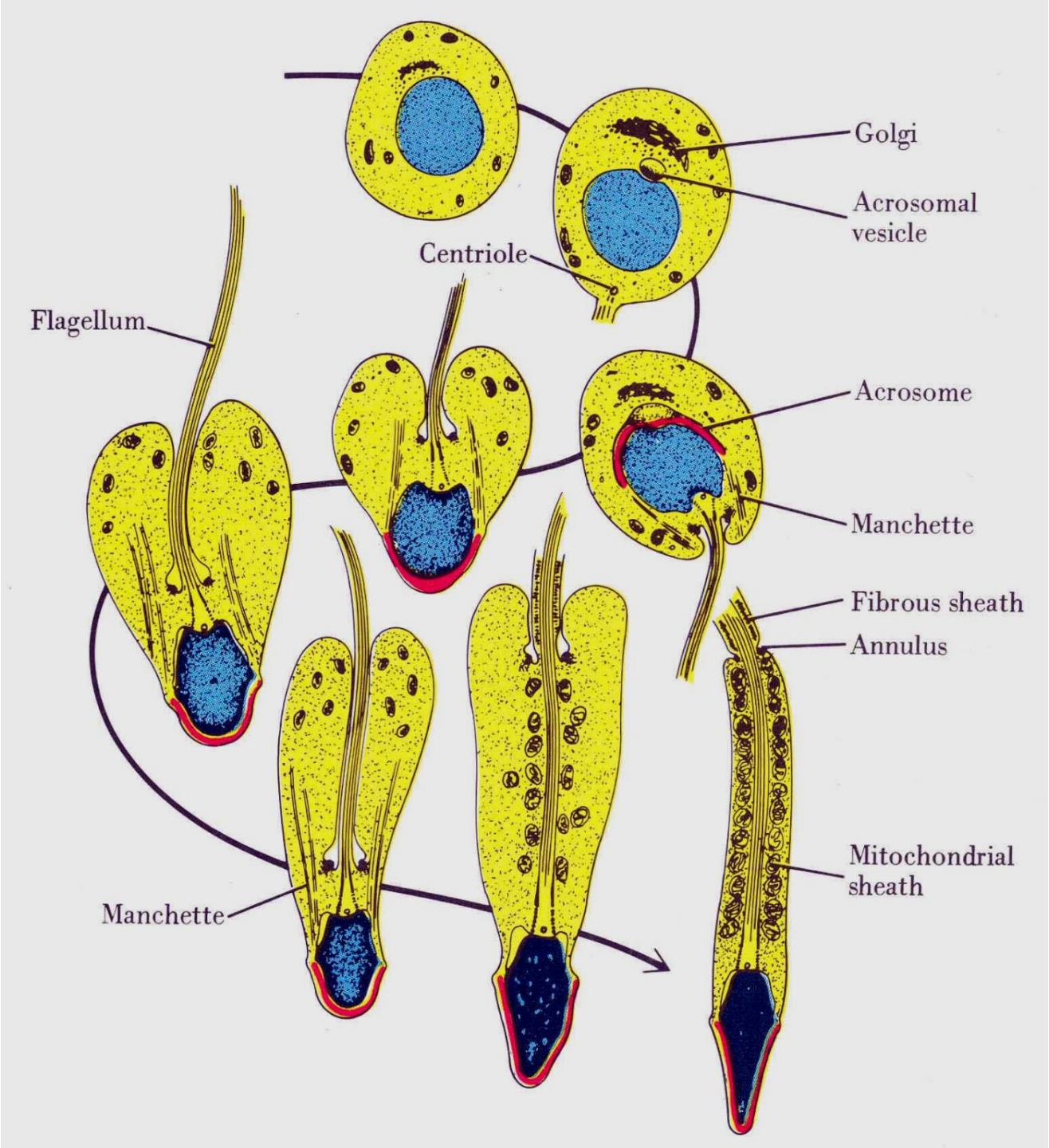

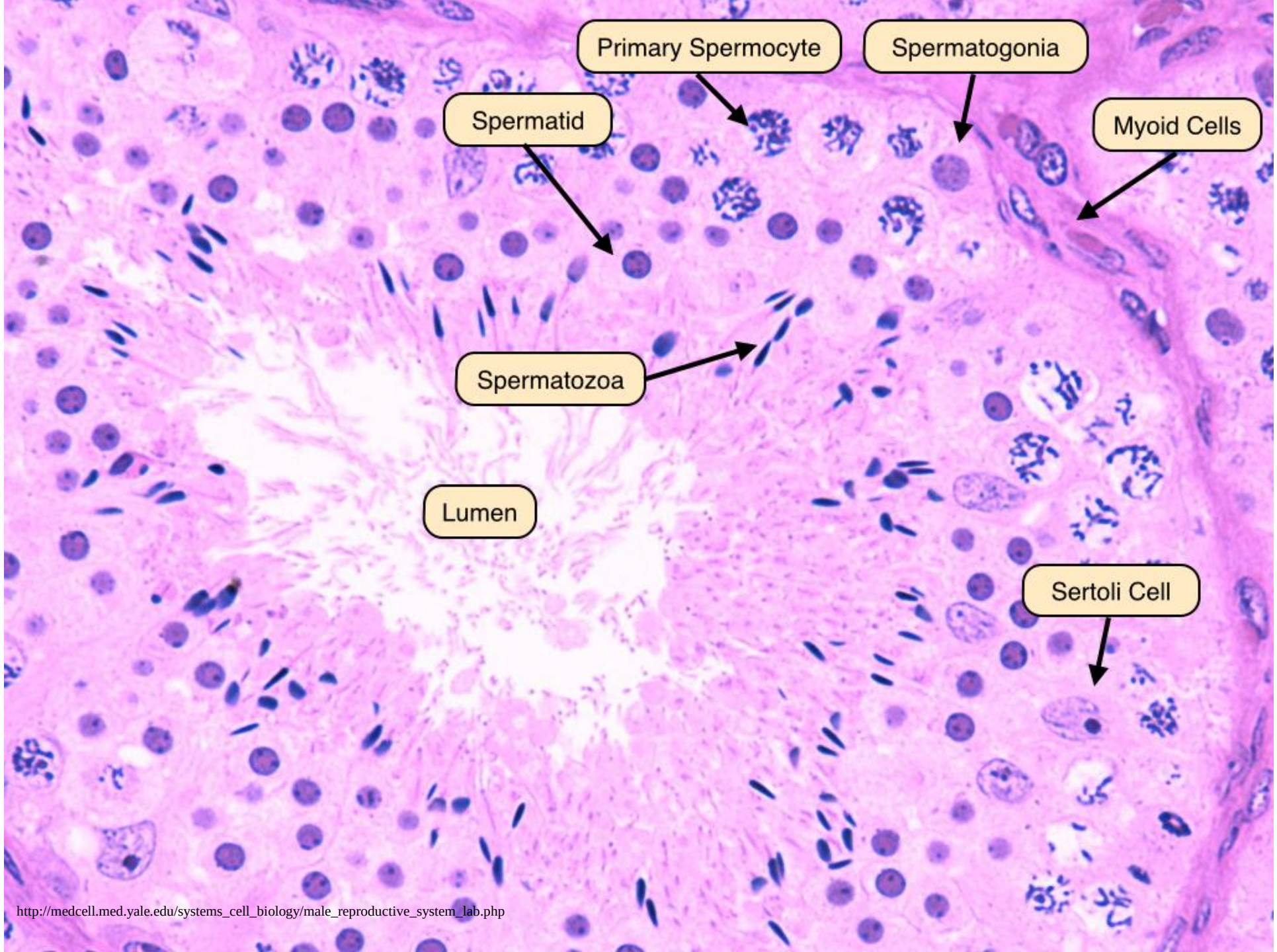

http://medcell.med.yale.edu/systems_cell_biology/male_reproductive_system_lab.php

Spermatogeneze

spermatocytogeneze

spermatohistogeneze

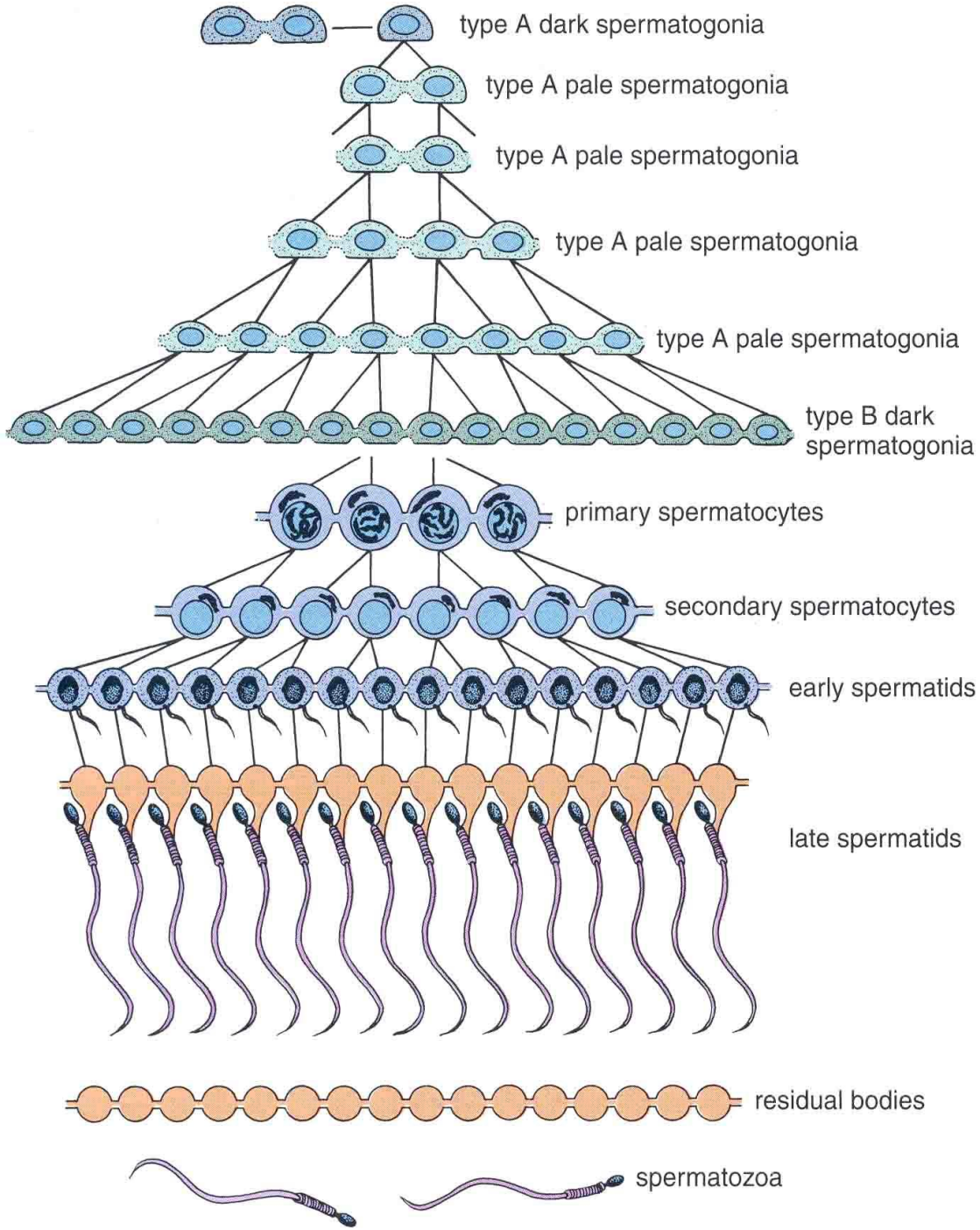

Spermatocytogeneze

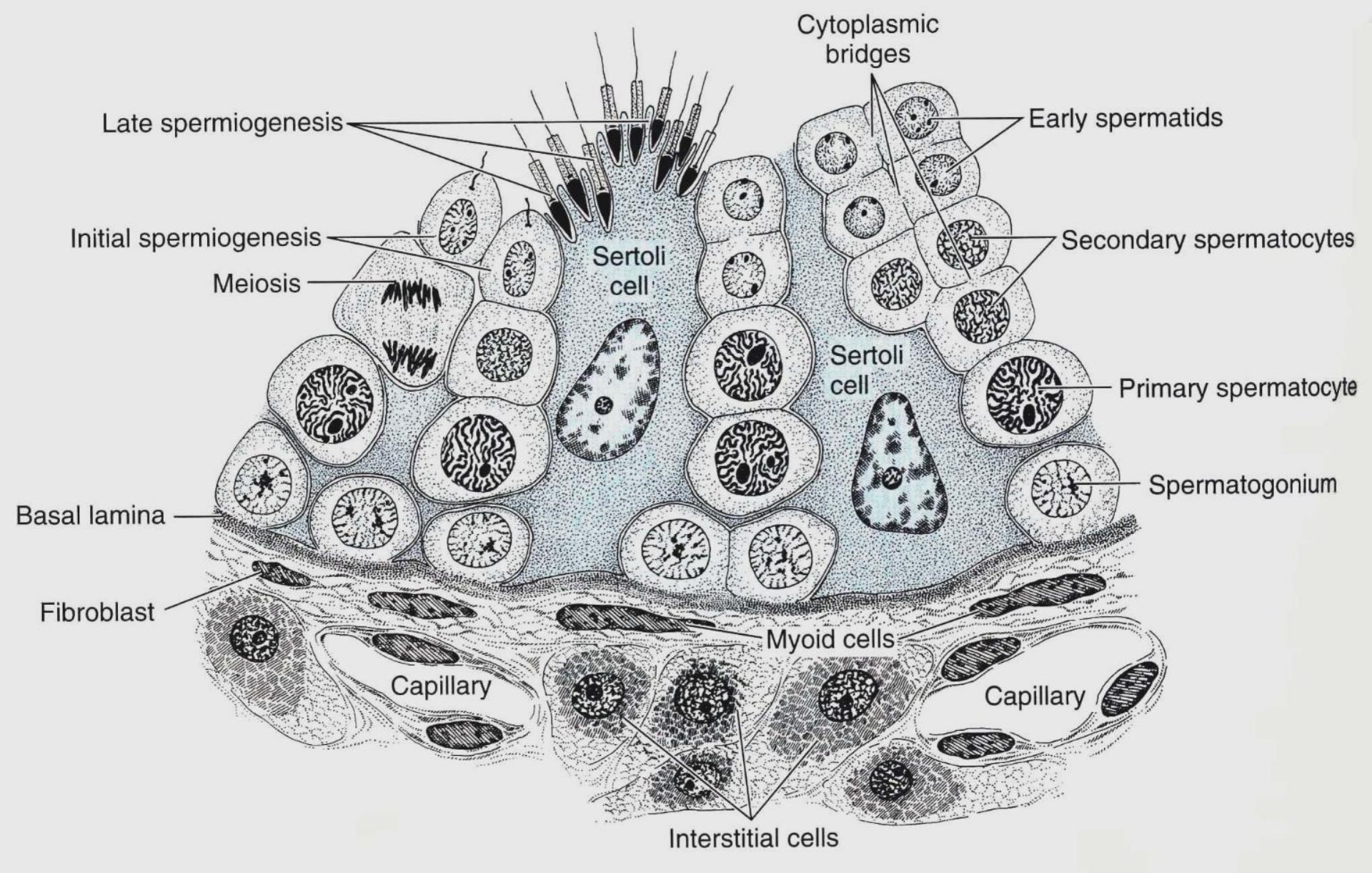

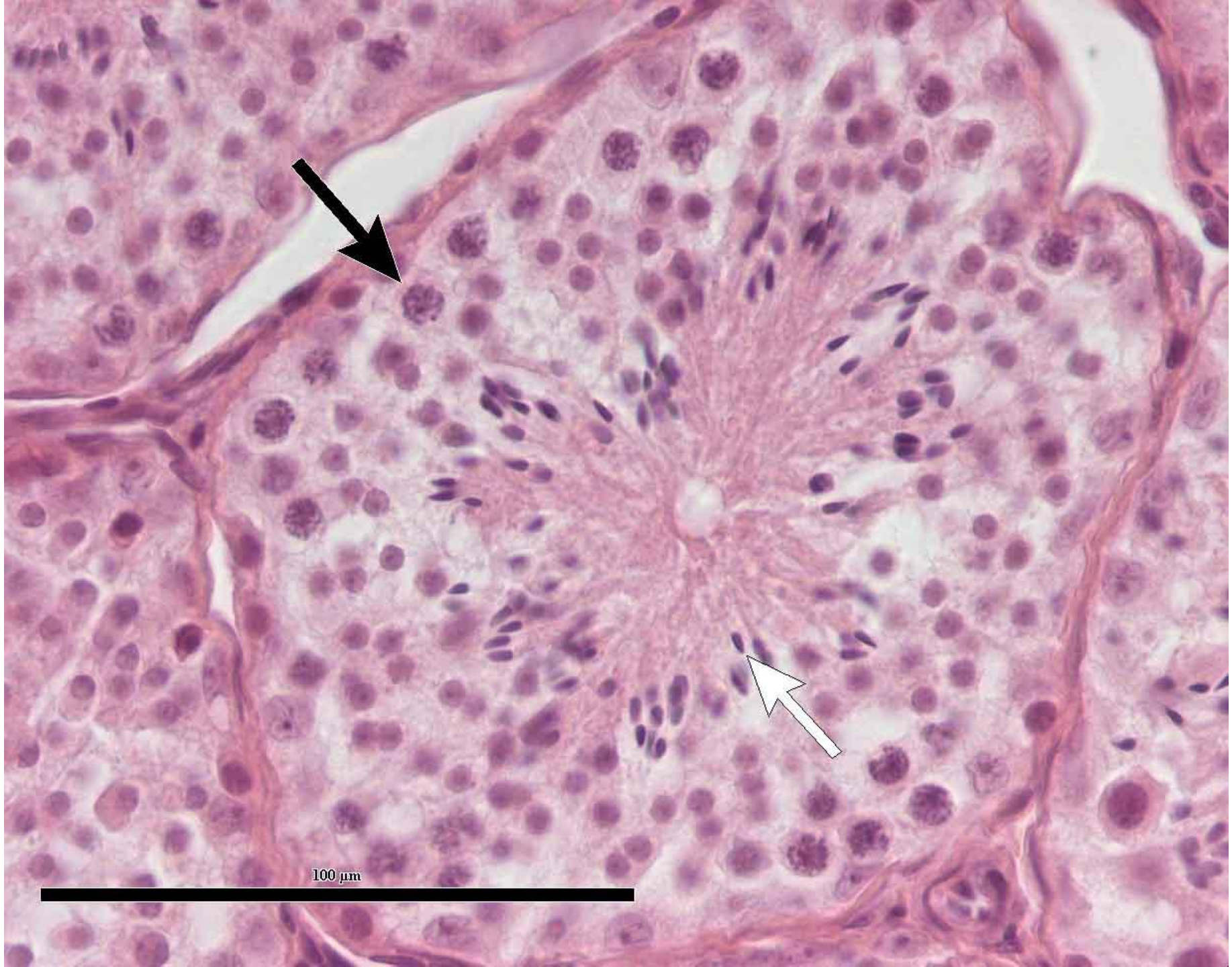
100 µm

Spermatocytogeneze

- Spermatogonie malé, kulaté, velké sférické jádro, hodně ribosomů) – v pubertě výhradně

  dceřinné buňky

  - Spermatogonie typu A s tmavými jádry (zůstávají)
  - Spermatogonie typu A se světlými jádry (množí se, můstky)

  Spermatogonie typu B (tmavší jádra)

  - Dělí se, zvětšují

  Spermatocyty I. řádu (primární spermatocyty)

  - Sférické; vstup do luminálního oddílu, meióza I. (profáze trvá 22 dní)

  Spermatocyty II. řádu (sekundární spermatocyty) – n

  - Malé sférické bb (10 – 12 um)., sférické jádro bez jadérka, hodně ribosomů; vstup do meiózy II. (bez S fáze)

  Spermatidy (7-8 um)

  - Vysoce kondenzovaný chromatin; zahájení spermatohistogeneze

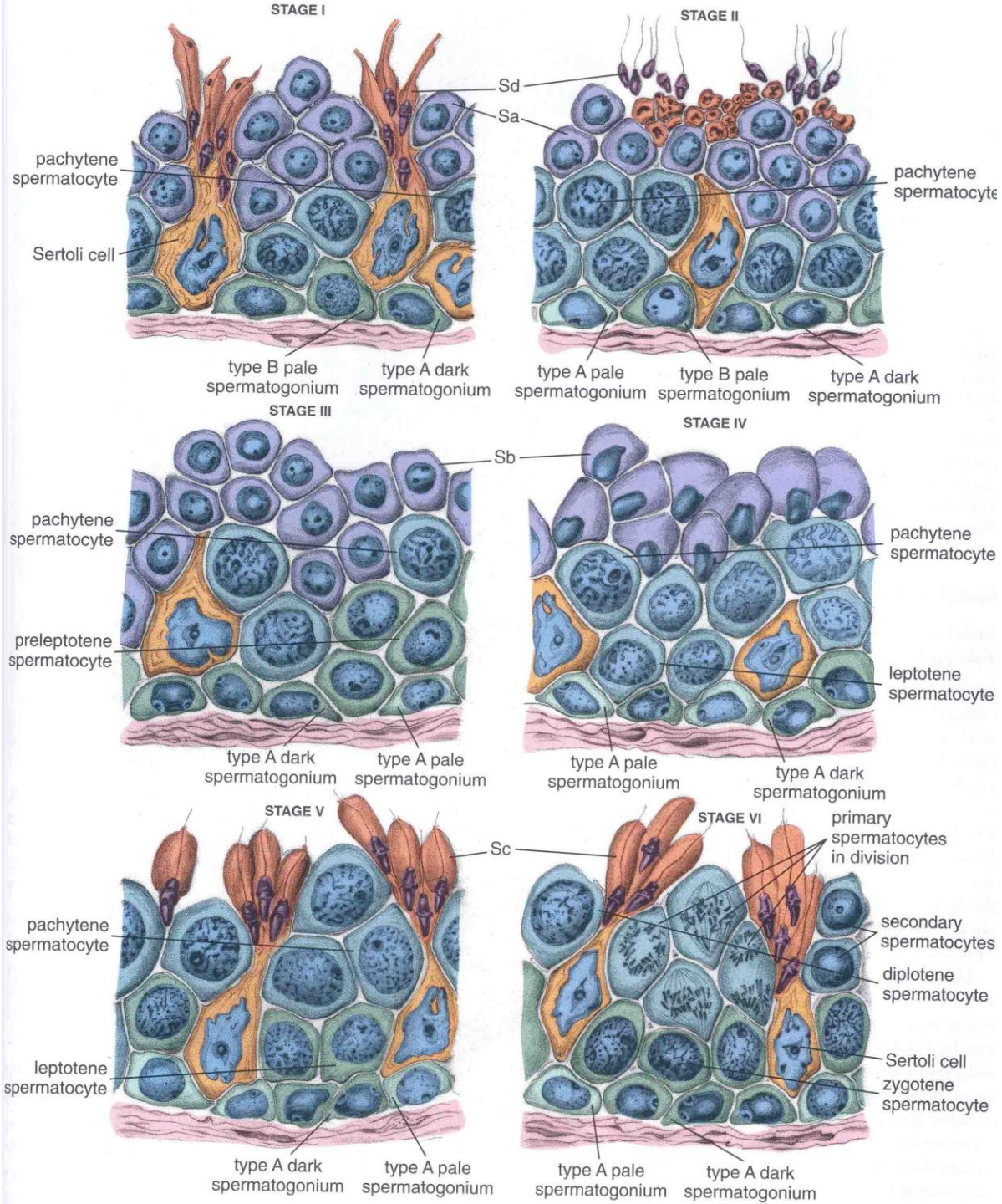
STAGE I
pachytene spermatocyte
Sertoli cell
type B pale spermatogonium
type A dark spermatogonium
STAGE II
Sd
Sa
pachytene spermatocyte
type A pale spermatogonium
type B pale spermatogonium
type A dark spermatogonium
STAGE III
pachytene spermatocyte
preleptotene spermatocyte
type A dark spermatogonium
type A pale spermatogonium
STAGE IV
Sb
pachytene spermatocyte
leptotene spermatocyte
type A pale spermatogonium
type A dark spermatogonium
STAGE V
Sc
pachytene spermatocyte
leptotene spermatocyte
type A dark spermatogonium
type A pale spermatogonium
STAGE VI
primary spermatocytes in division
secondary spermatocytes
diplotene spermatocyte
Sertoli cell
zygotene spermatocyte
type A pale spermatogonium
type A dark spermatogonium

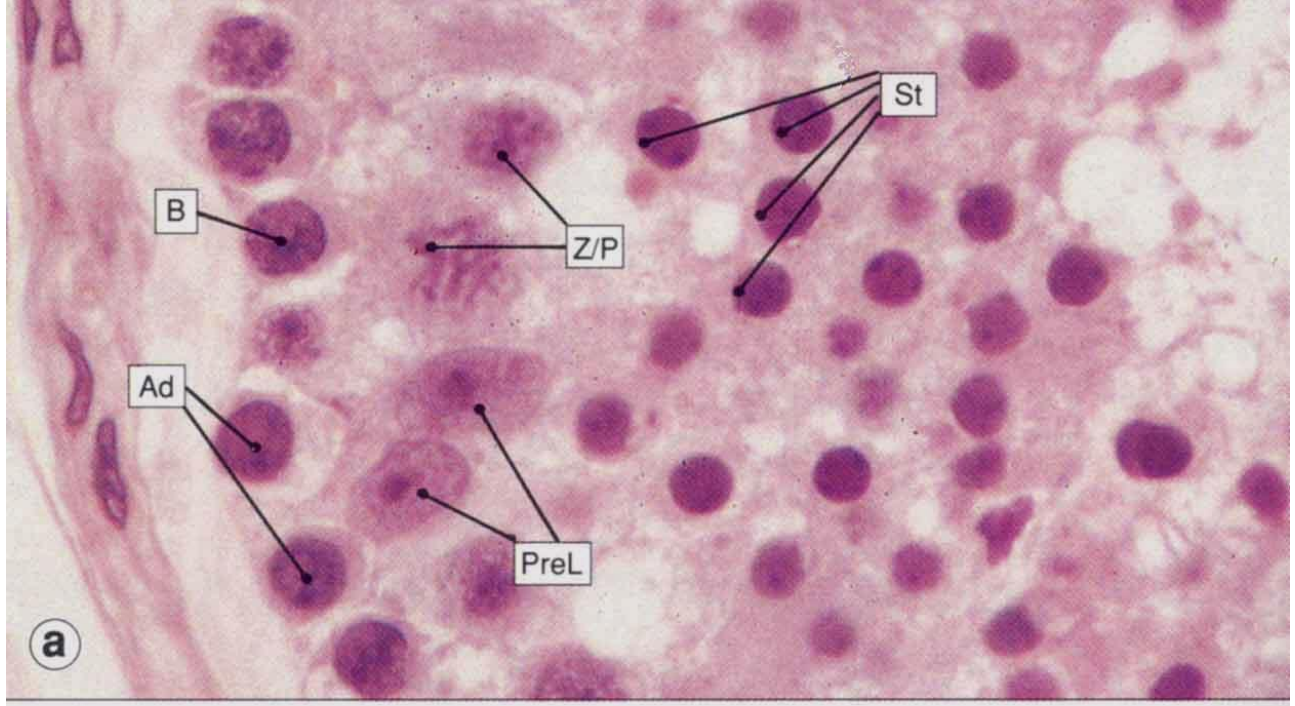
St
B
Z/P
Ad
PreL
a

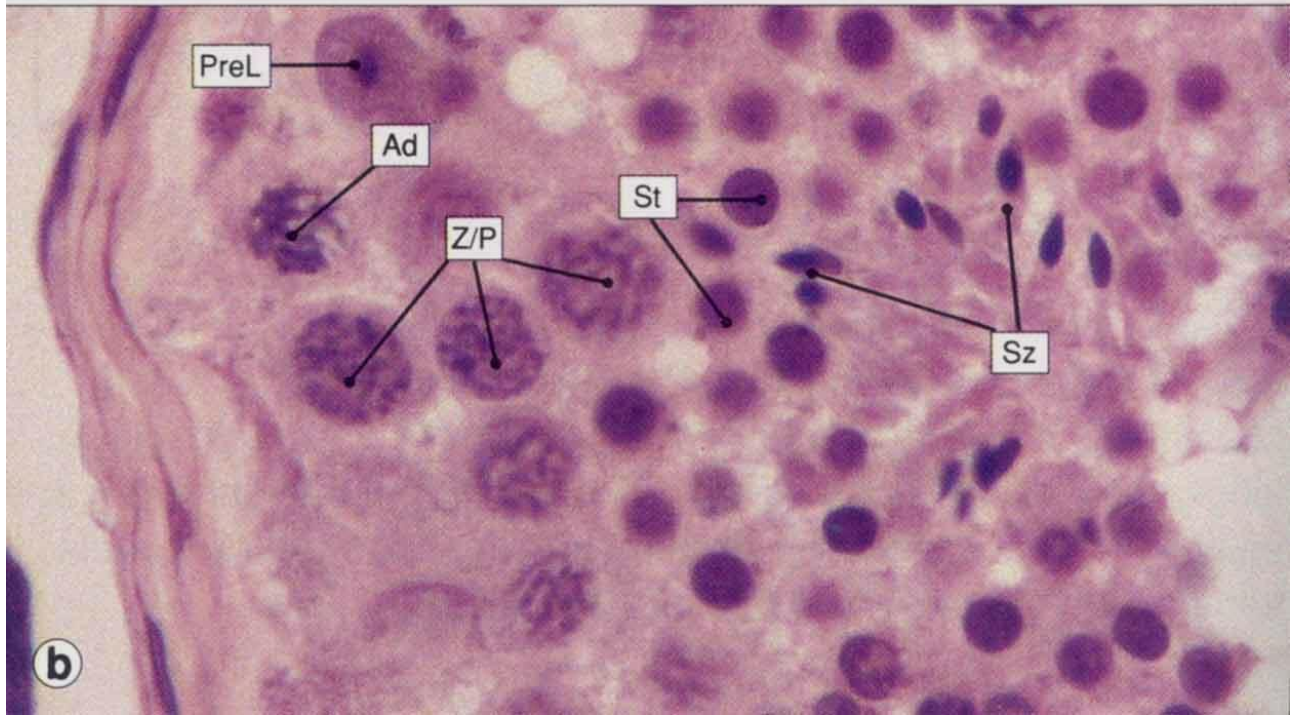
PreL
Ad
St
Z/P
Sz
b

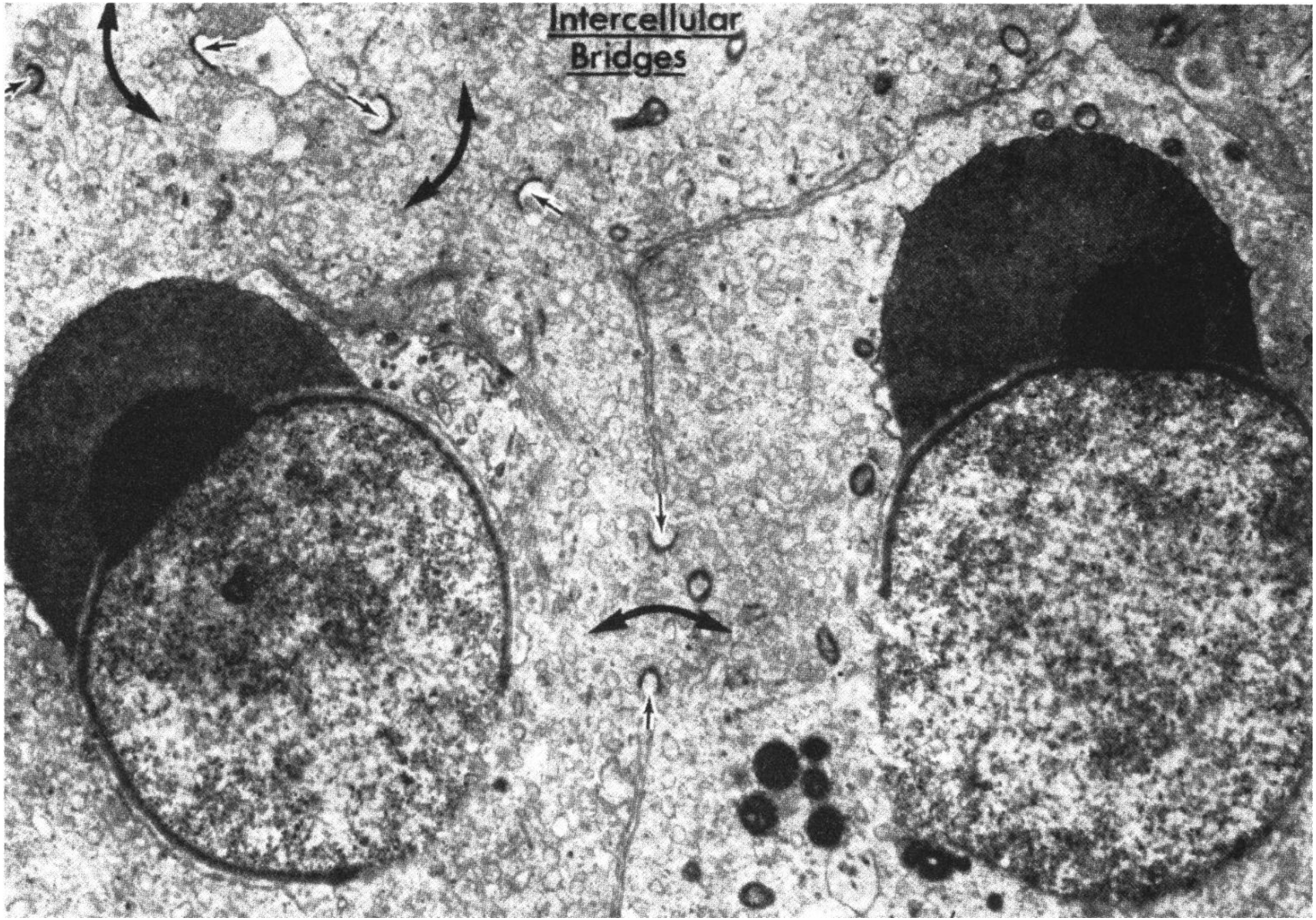
Intercellular
Bridges

Spermatohistogeneze

- Spermatidy (zanořené v membráně Sertoliho bb)

  změny

Spermatohistogeneze

- Spermatidy (zanořené v membráně Sertoliho bb)

změny tvaru a charakteru jádra (elongace jádra, nahrazení histonů protaminy → kondenzace, toroidy; mikrotubuly u dist. pólu – manžeta)

změny v oblasti Golgiho komplexu (PAS pozit. proakrosomální granula → akrosomální granulum v akrosom. váčku → přesun před jádro → akrosom)

- hyaluronidáza, neuraminidáza, kys. fosfatáza, akrosin
- distálně od akrosomu nukleární prstenec (glykoproteiny)

změny v uspořádání mitochondrií hromadění mitochondrií kolem začátku axonematu; ubiquitinace membrán)

odstranění přebytečné cytoplazmy reziduální – balanční tělísko)

vývoj bičíku

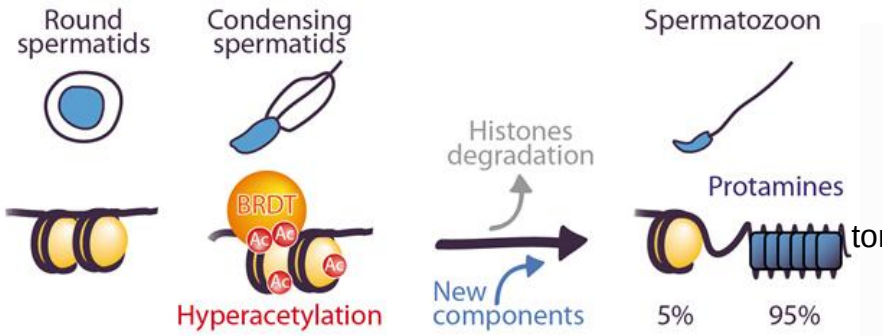
Round spermatids
Condensing spermatids
Spermatozoon
Histones degradation
Protamines
BRDT
Ac
Hyperacetylation
New components
5%
95%

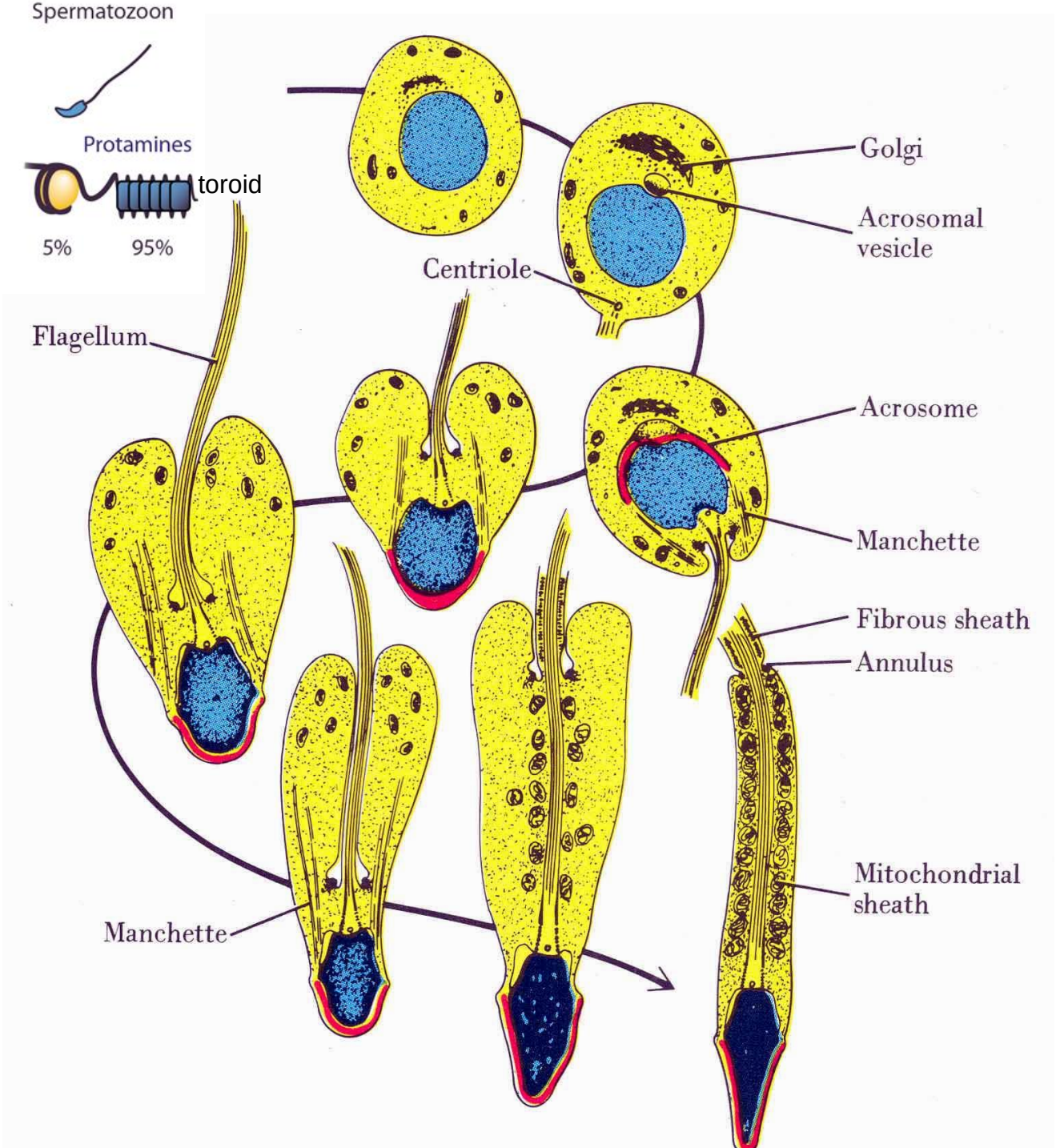
toroid
Golgi
Acrosomal vesicle
Centriole
Flagellum
Acrosome
Manchette
Fibrous sheath
Annulus
Mitochondrial sheath
Manchette

Vývoj bičíku

- Centrioly (migrace k opačnému pólu buňky než akrosom)
  - distální centriol (orientován podélně, → bazální tělísko, zahajuje tvorbu axonematu; invaginace membrány kolem vznikajícího bičíku s vrstvou glykoproteinů - anulus)
  - proximální centriol (orientován kolmo; kolem provazce ED proteinové substance s příčným pruhováním– základ segmentovaných chord)

po ukončení elongace buňky

- Mizí mikrotubulární manžeta
- Oddělují se balanční tělíska

Spermiogenesis

- kanálky nadvarlete
- spermatidy
  - kondenzovaný chromatin, ↑mitochondrií
  - Golgiho fáze
  - akrozomální fáze
  - maturační fáze
- od spermatogonie ke spermii: **64 ± 4,5 dne**
- cyklus semenotvorného epitelu: **16 ± 1 den**
  - doba, za kterou se v určitém místě epitelu znovu objeví určité vývojové stadium

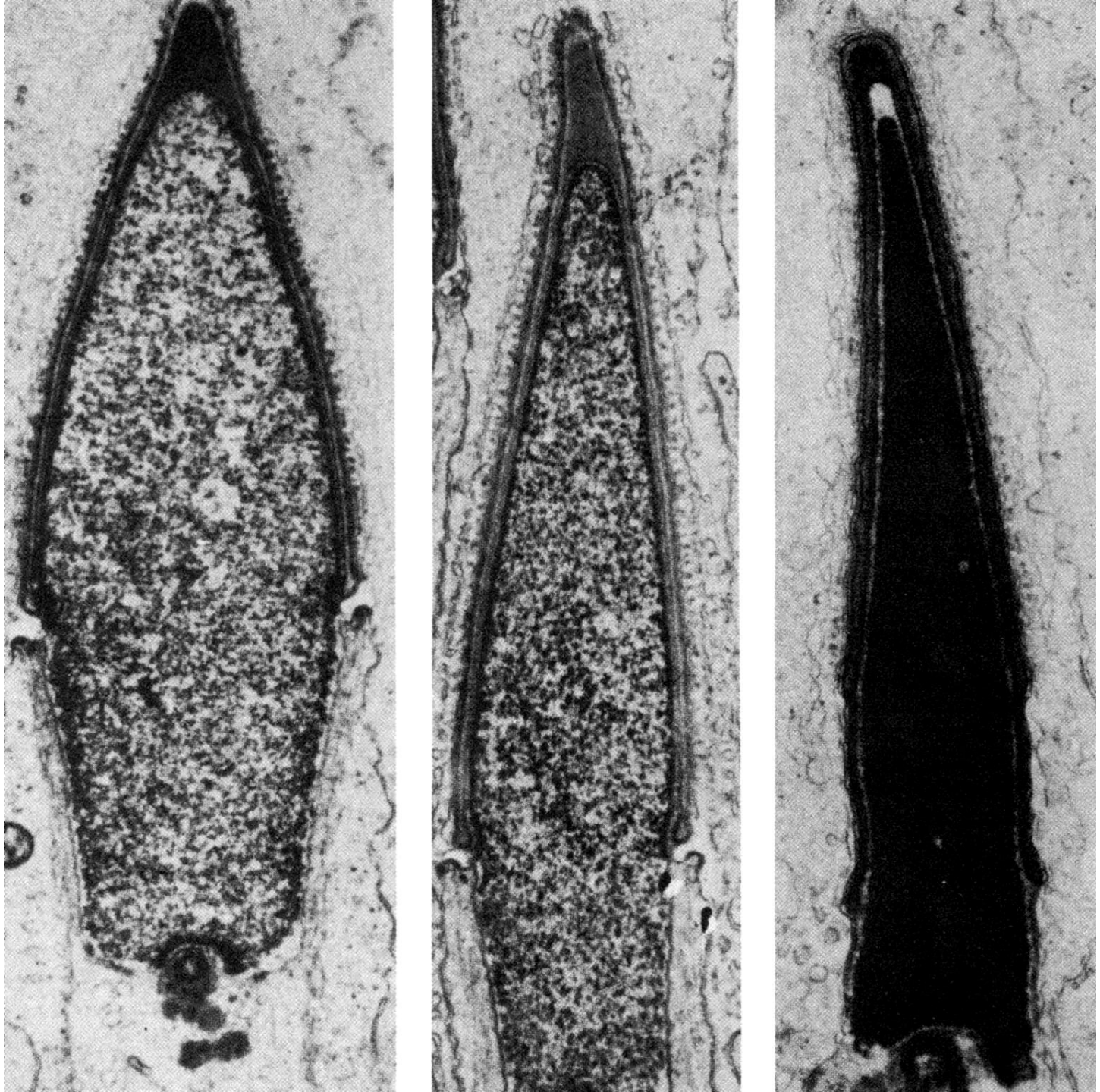

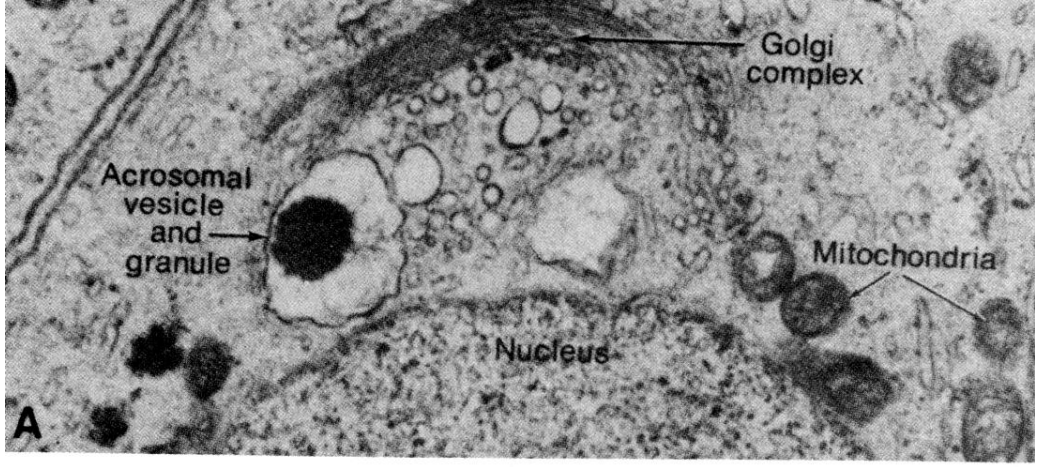
Golgi
complex
Acrosomal
vesicle
and
granule
Mitochondria
Nucleus
A

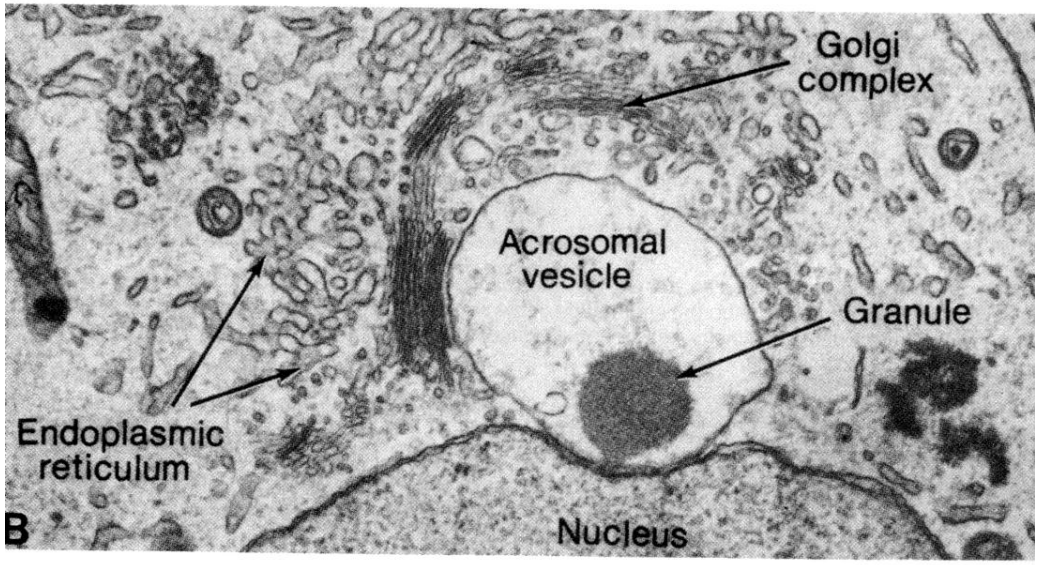
Golgi
complex
Acrosomal
vesicle
Granule
Endoplasmic
reticulum
B
Nucleus

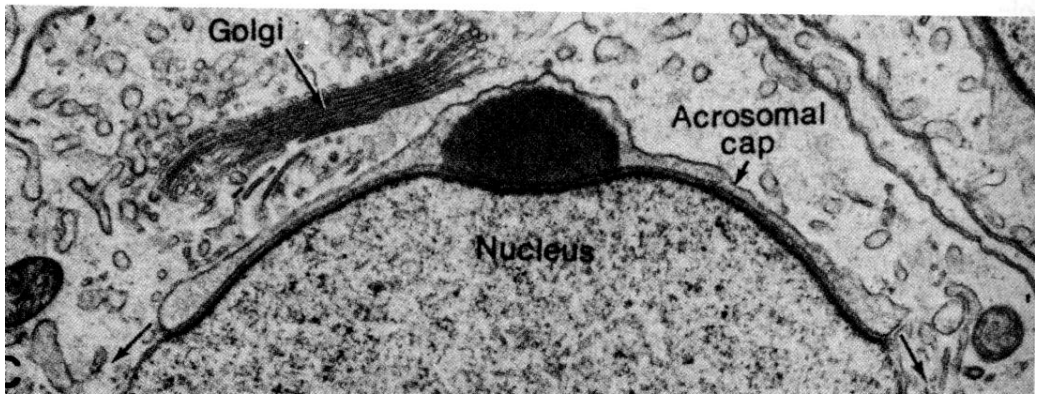
Golgi
Acrosomal
cap
Nucleus

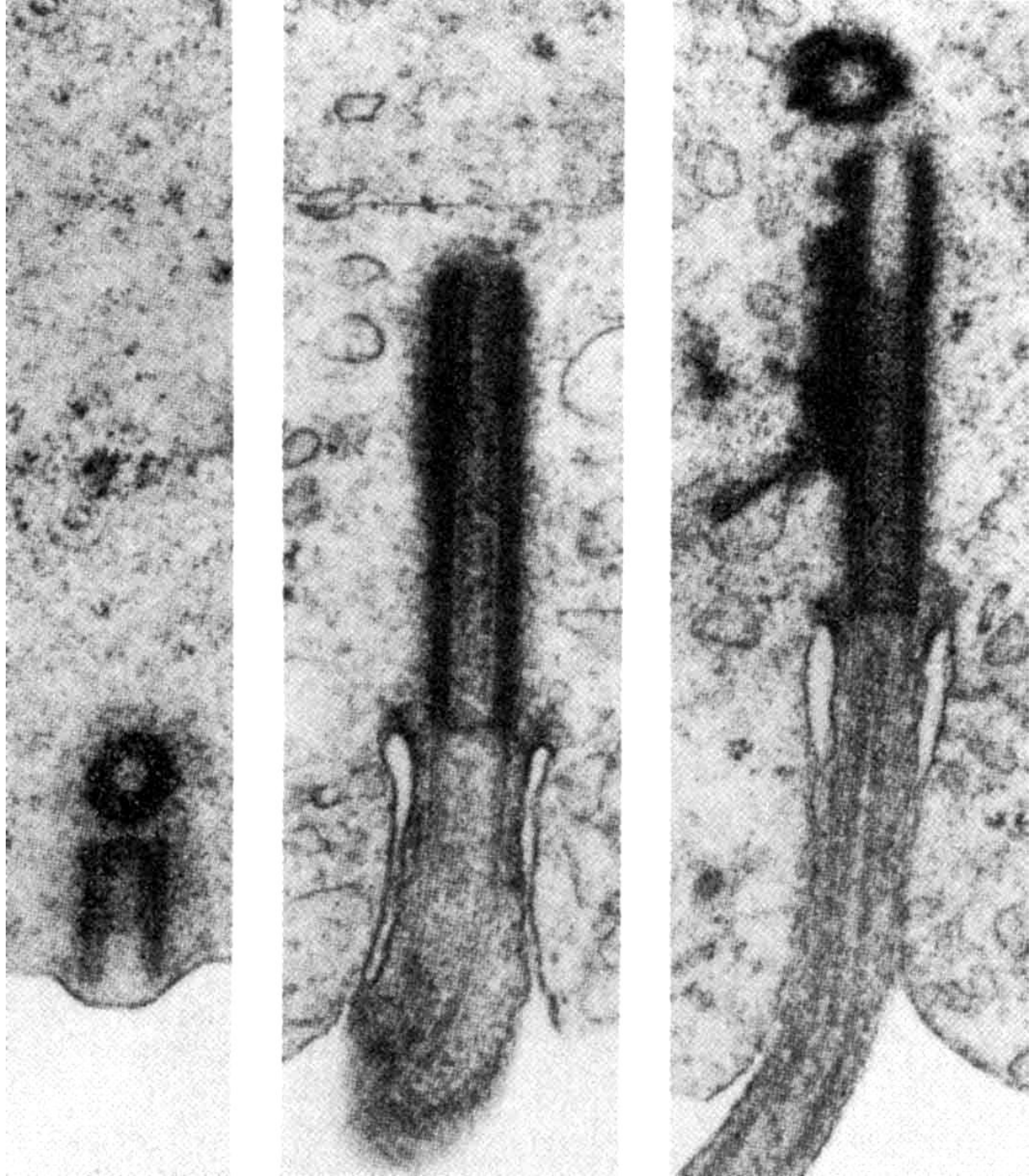

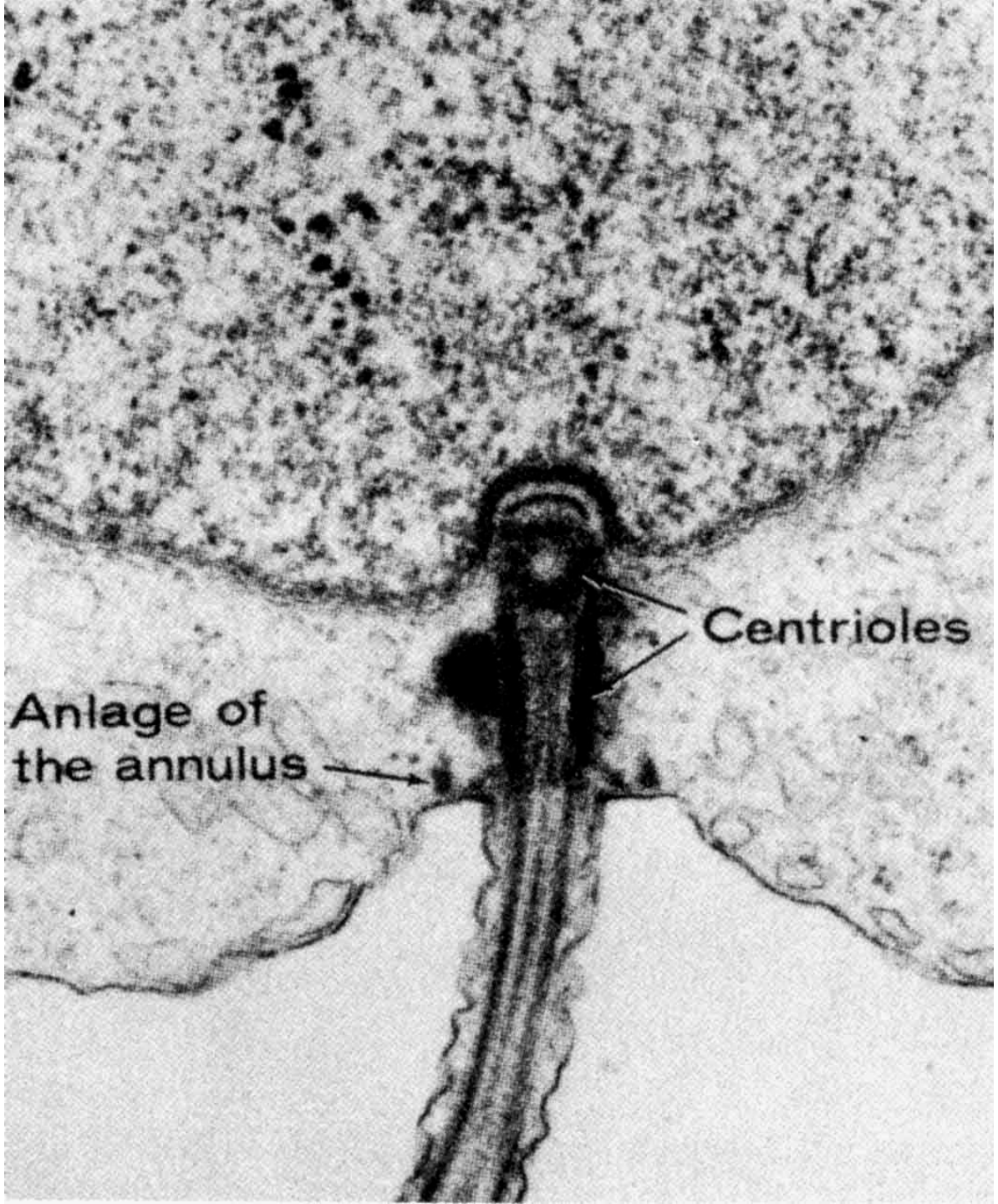
Centrioles
Anlage of
the annulus

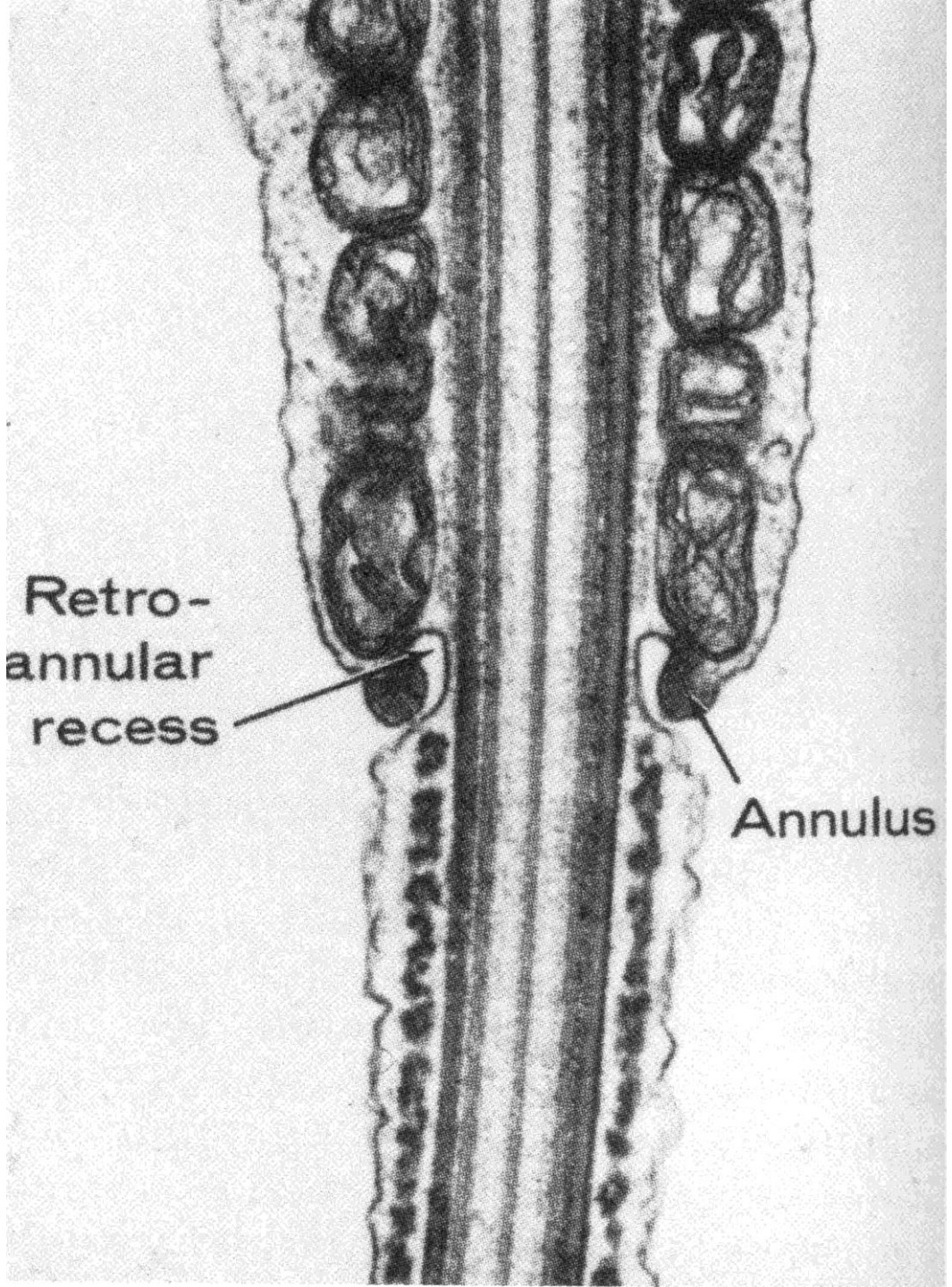
Retro-
annular
recess
Annulus

Spermie - spermatozoon

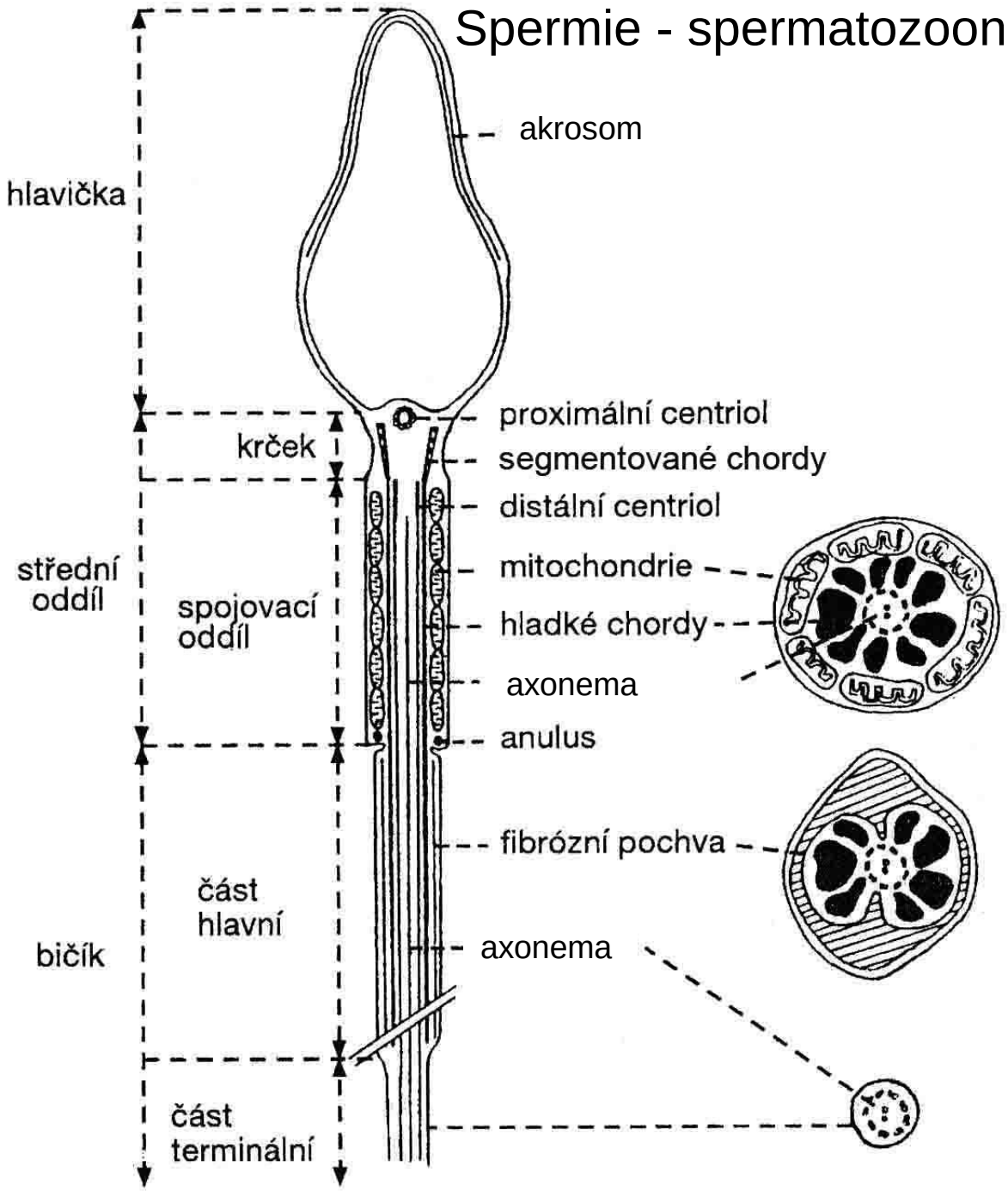

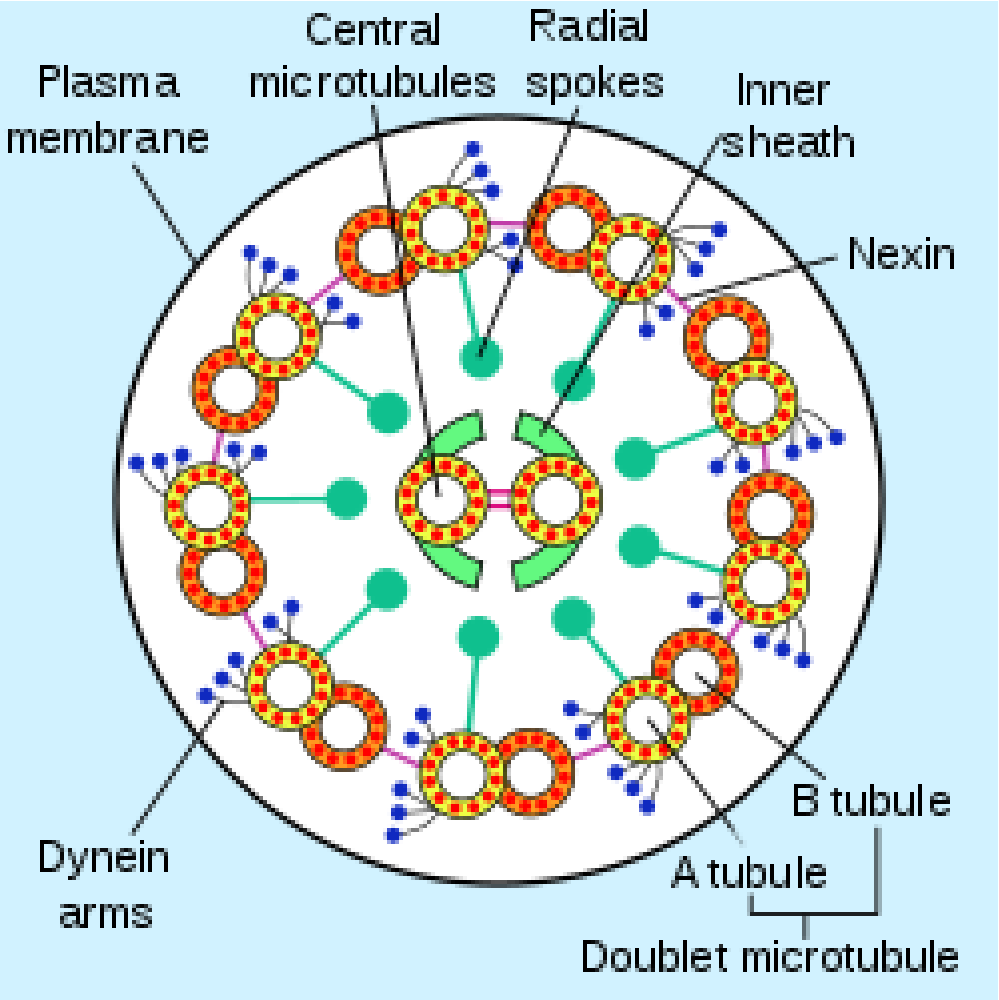

- Axonema (vazby dyneinových ramének)
- Hladké chordy
- Fibrózní pochva

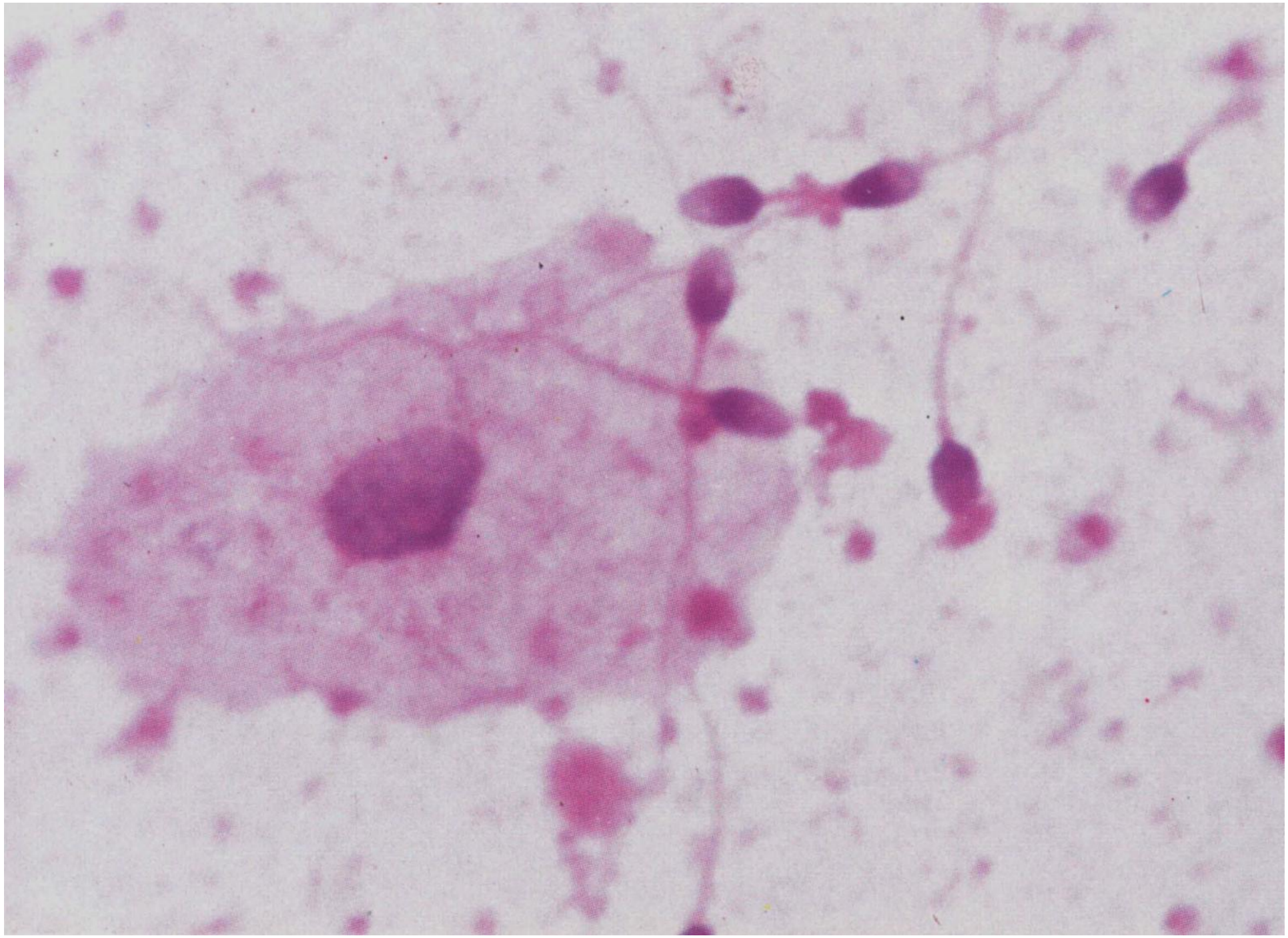

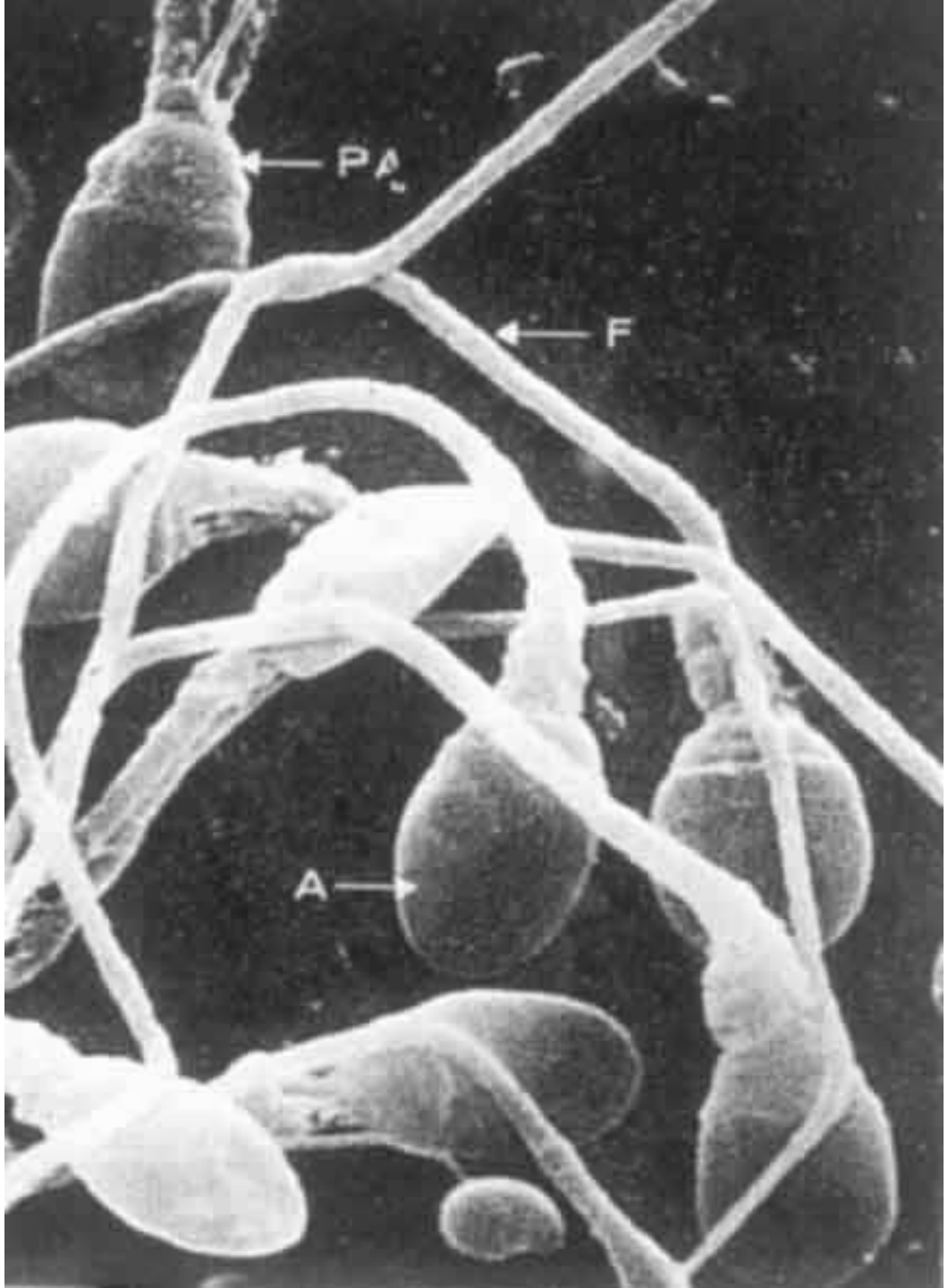
PA
F
A

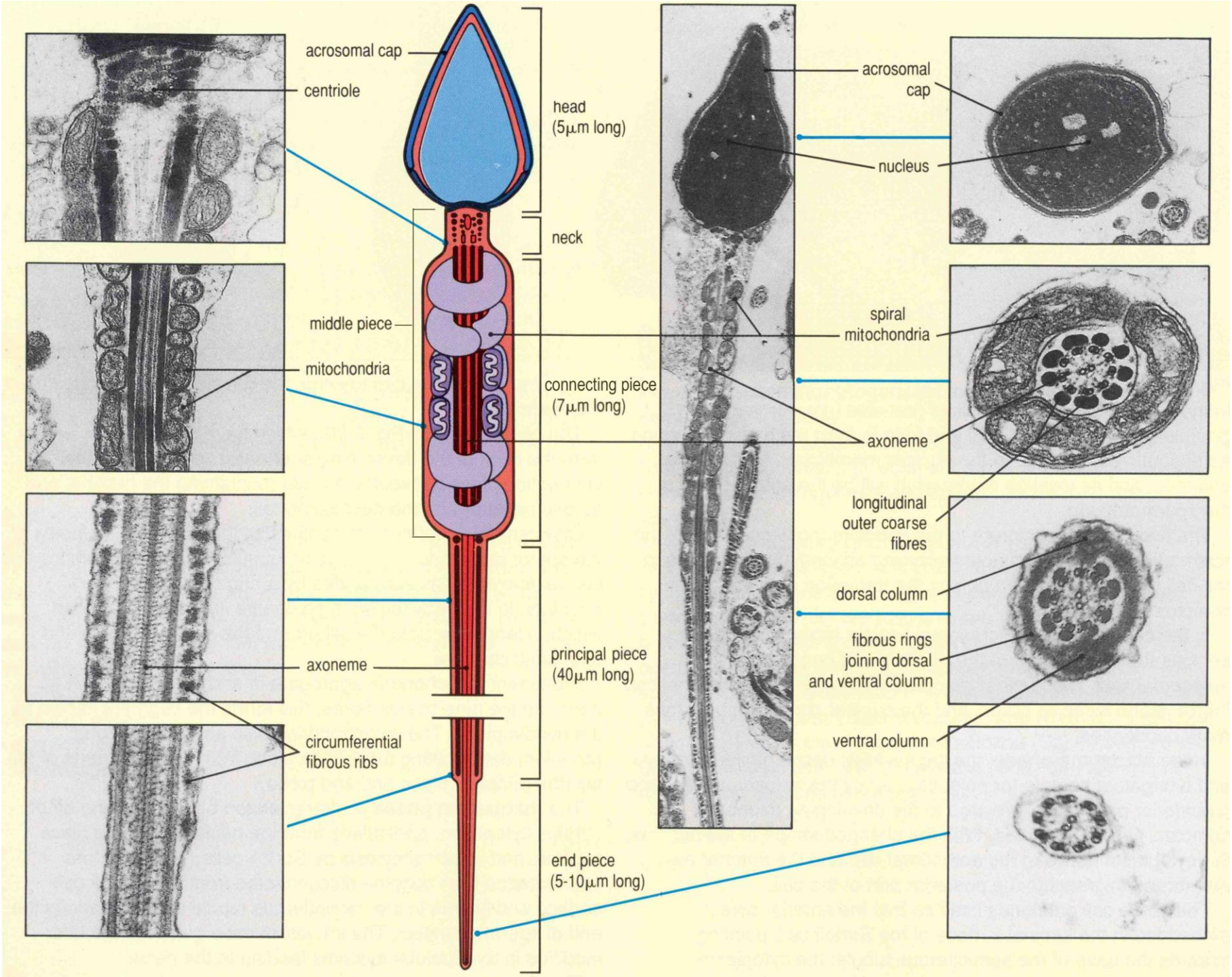
acrosomal cap
centriole
head
(5μm long)
neck
middle piece
mitochondria
connecting piece
(7μm long)
axoneme
principal piece
(40μm long)
circumferential
fibrous ribs
end piece
(5-10μm long)
acrosomal
cap
nucleus
spiral
mitochondria
axoneme
longitudinal
outer coarse
fibres
dorsal column
fibrous rings
joining dorsal
and ventral column
ventral column

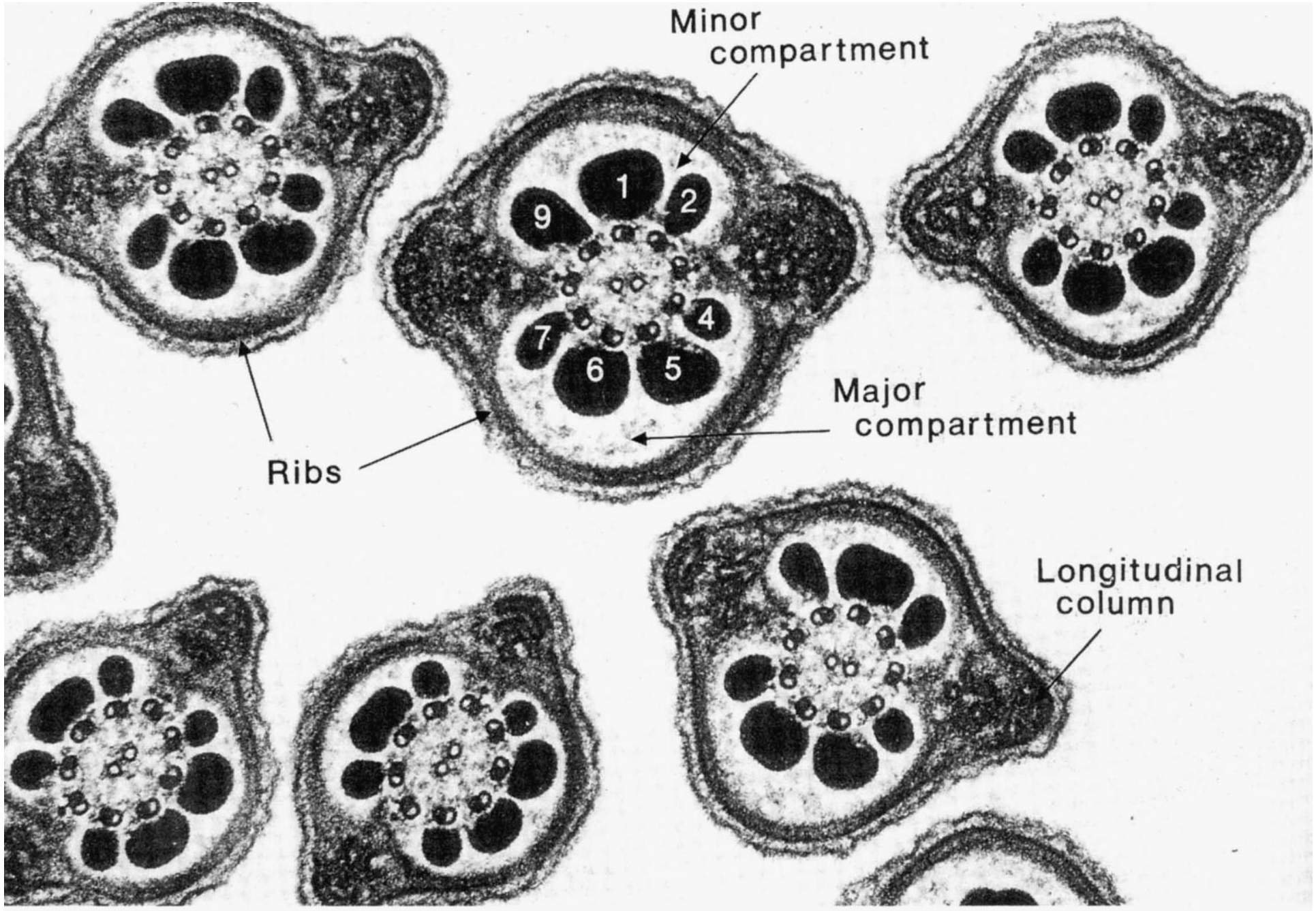
Minor
compartment
1
2
9
4
7
6
5
Major
compartment
Ribs
Longitudinal
column

Zrání spermie

- bezprostředně po ejakulaci nejsou schopné oplodnění (*fertilisatio*)
- **kapacitace – 7 hodin**
  - z povrchu akrozomu odstraněn obal
- akrozomální reakce
  - hyaluronidáza + akrozin umožní průchod spermii skrz corona radiata et zona pellucida vajíčka
- **životnost 48 hodin**
- **životnost vajíčka jen 24 hodin**

Sertoliho buňky
Sustenocyti (*Epithelocyti sustenantes*)

- obalují zrající spermatogenní buňky
- tvar podlouhlé pyramidy, jádro bazálně
- **hemato-testikulární bariéra** (*claustrum haematotesticulare*)
  - zonulae occludentes mezi buňkami
  - ochrana před cizorodými látkami
  - imunobiologické prostředí
- compartimentum adluminale (oddíl luminální)
  - specifické prostředí
- apparatus junctionalis sustentocyticus
  - tvořen zonulae occludentes mezi oběma kompartmenty
- compartimentum basale (oddíl bazální)
  - určen krevním prostředím

Sertoliho buňky
Sustenocyti (*Epithelocyti sustenantes*)

- **výživa a opora**
- fagocytóza reziduální tělíska vzniklá při zrání spermií)
- **testikulární tekutina**
- androgen-binding protein (ABP) váže testosteron a zvyšuje jeho nabídku v nitru kanálku
- **anti-müllerianský hormon** (AMH) = Müllerian inhibiting factor/ substance (MIF/MIS) vyvolává zánik ductus paramesonephricus Mülleri
- **inhibin** tlumí sekreci FSH
- krajně odolné proti všem nepříznivým vlivům včetně záření → nedělí se

Sertoliho buňky

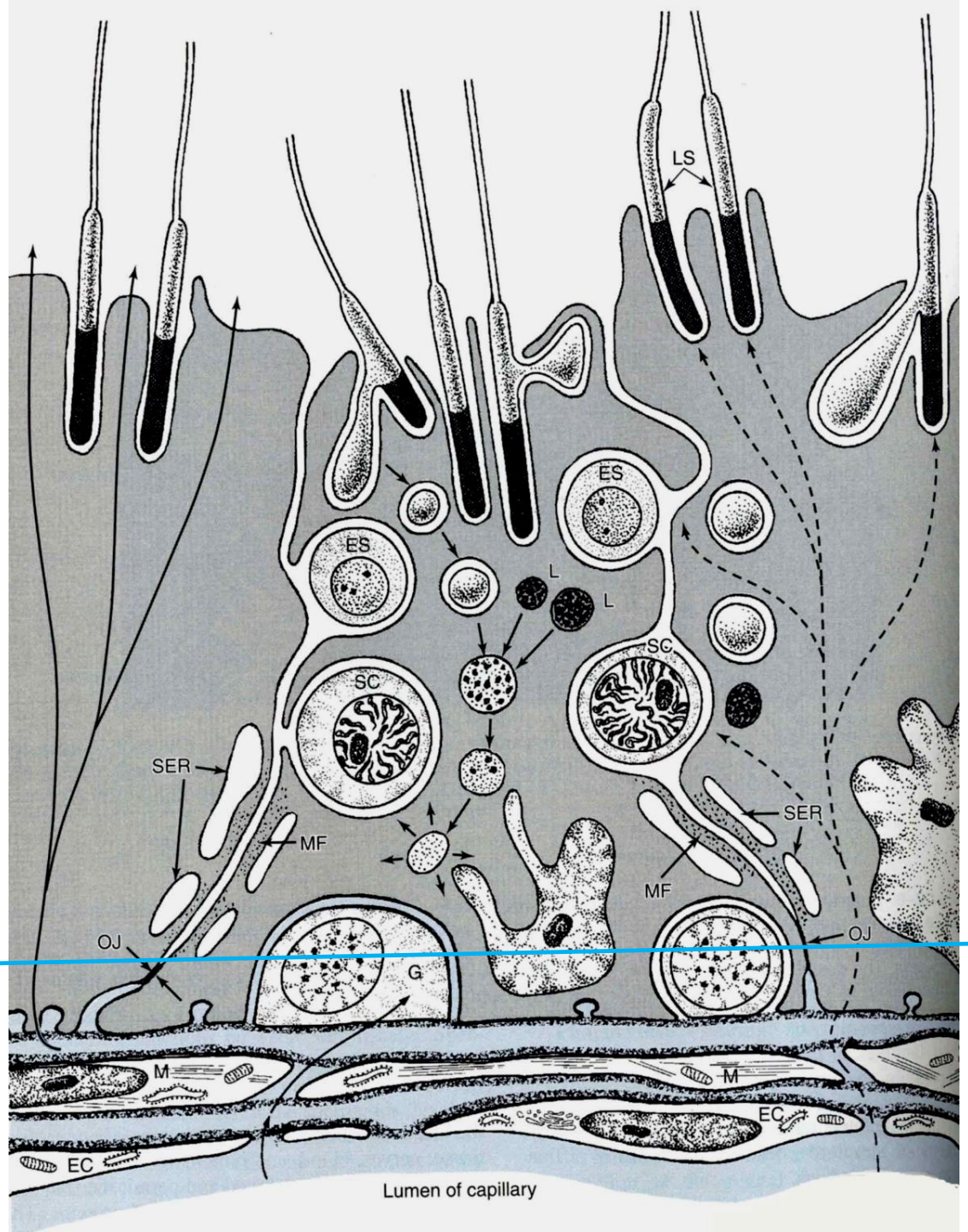

luminální oddíl

basální oddíl

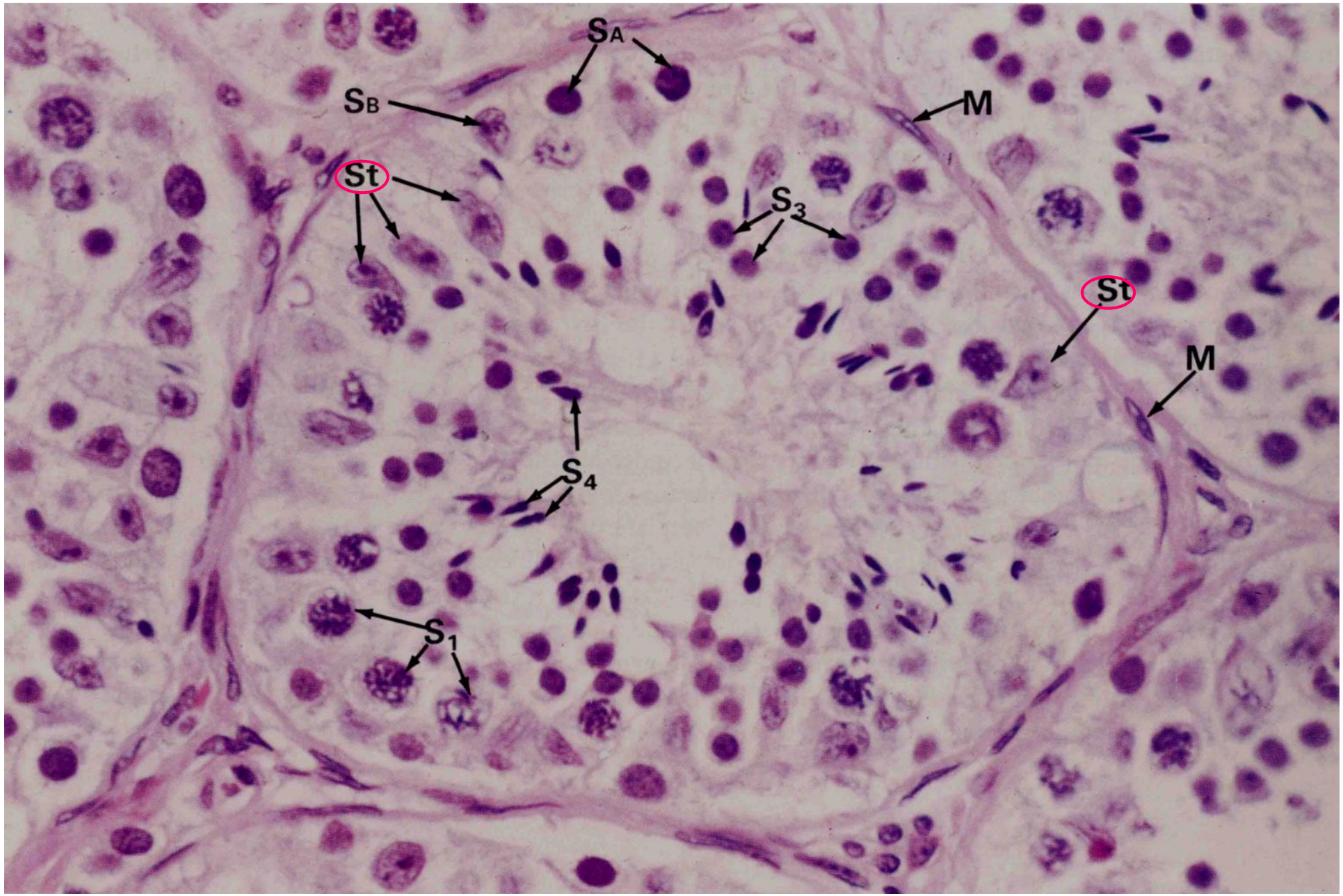
SA
SB
M
St
S3
St
M
S4
S1

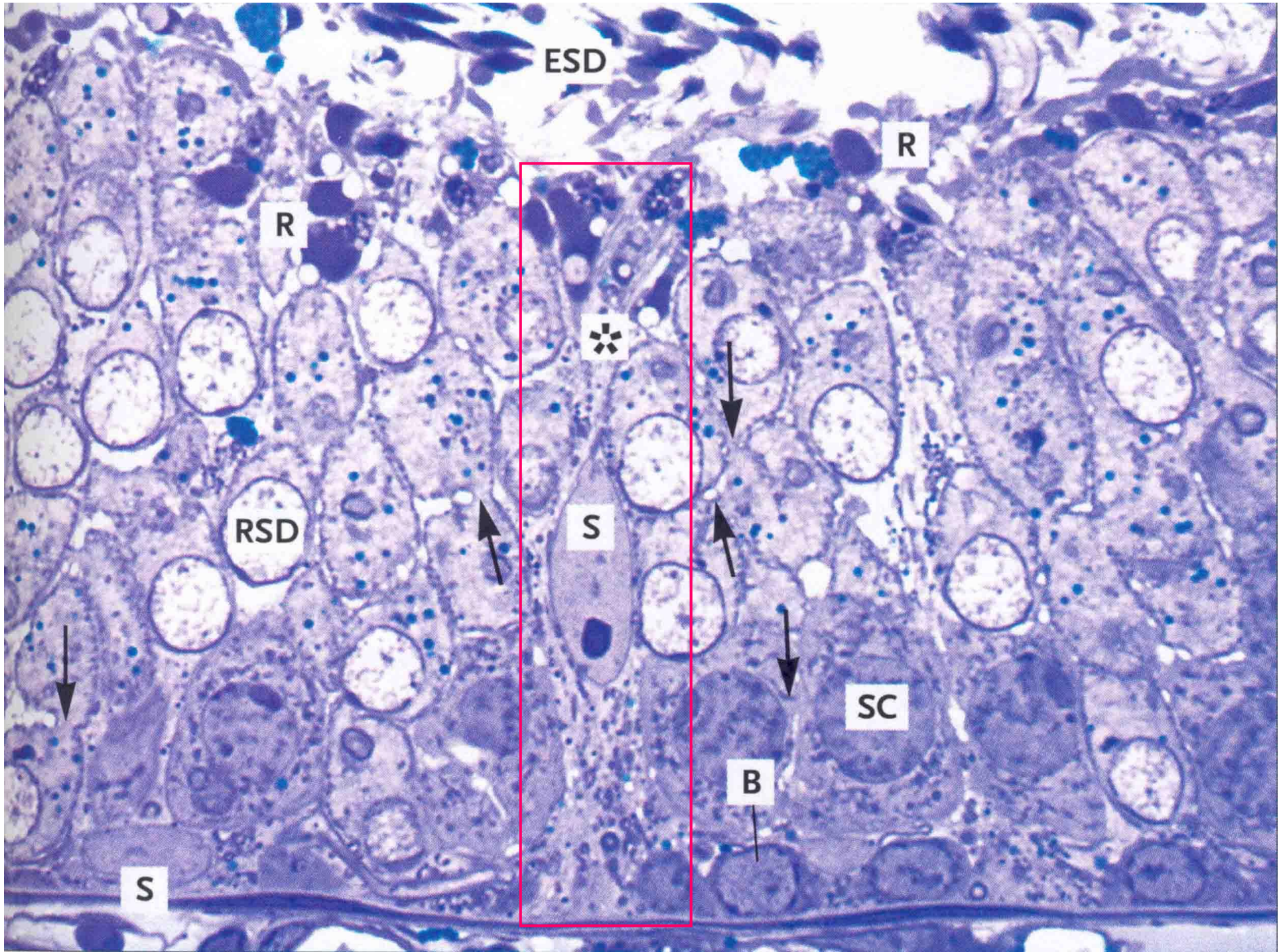
ESD
R
R
RSD
S
SC
B
S

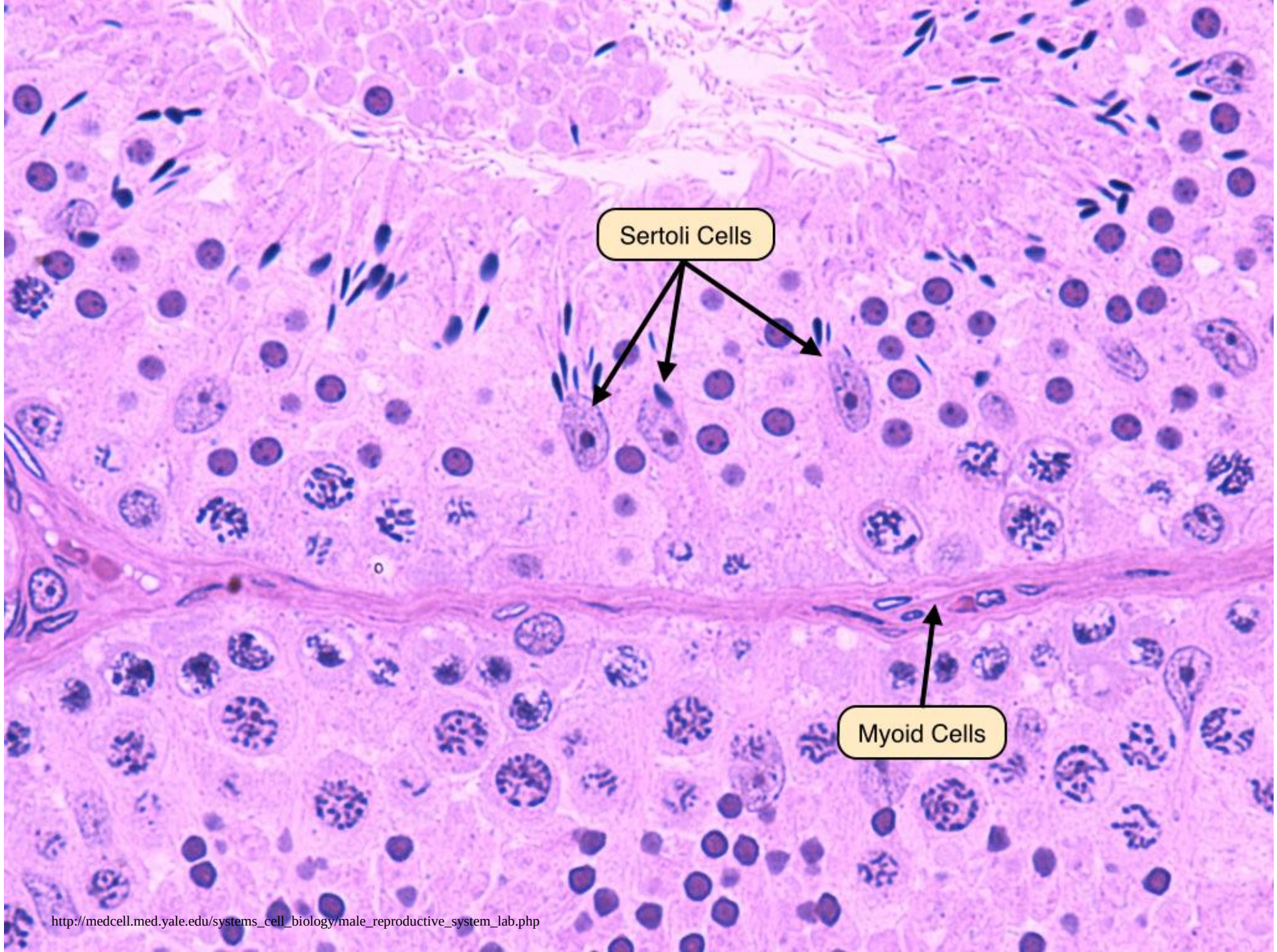

http://medcell.med.yale.edu/systems_cell_biology/male_reproductive_system_lab.php

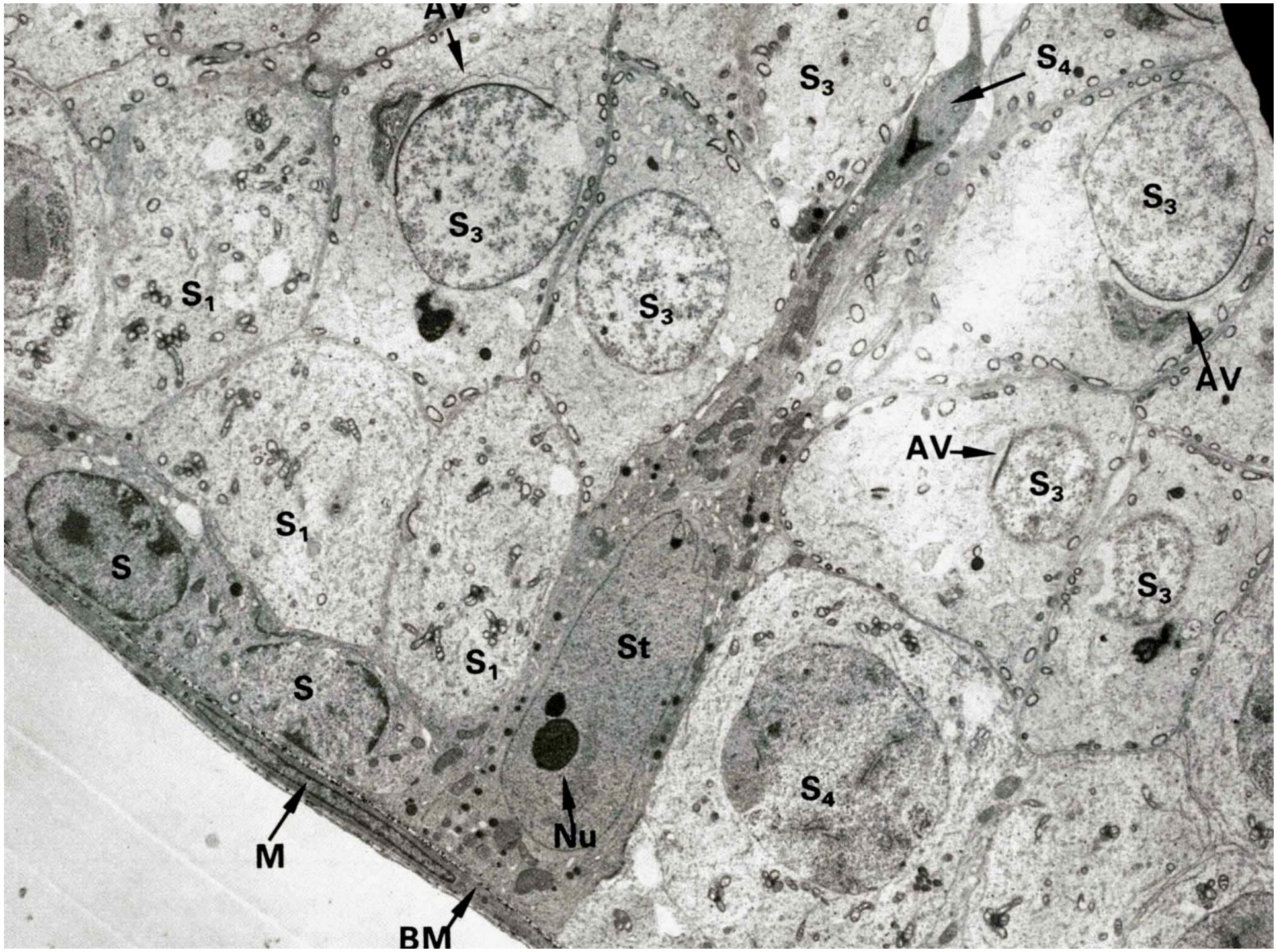
AV
S3
S4
S3
S3
S1
S3
AV
AV
S3
S1
S
S3
S1
St
S
S4
Nu
M
BM

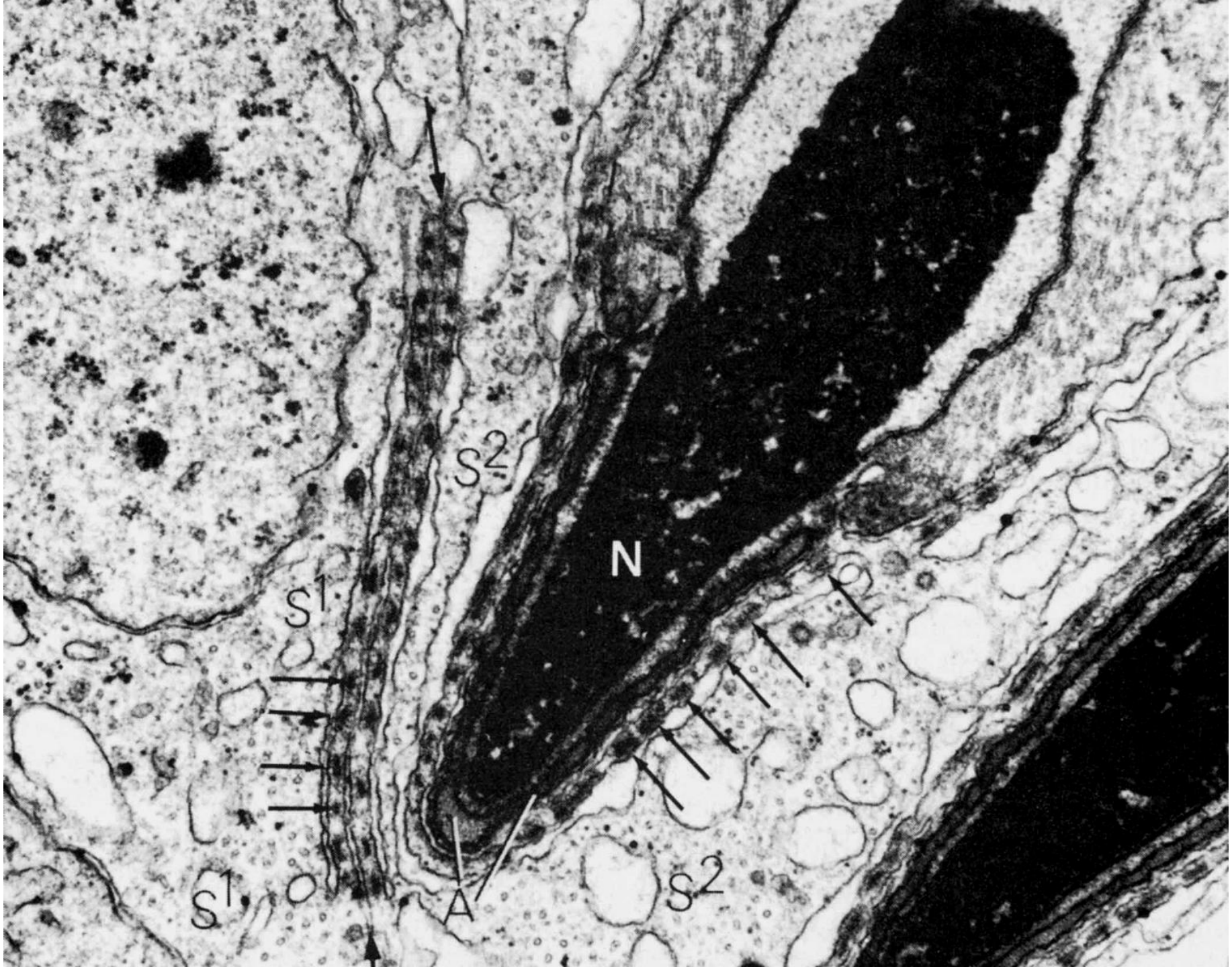
S2
N
S1
S1
A
S2

Charcotův-Böttcherův krystaloid

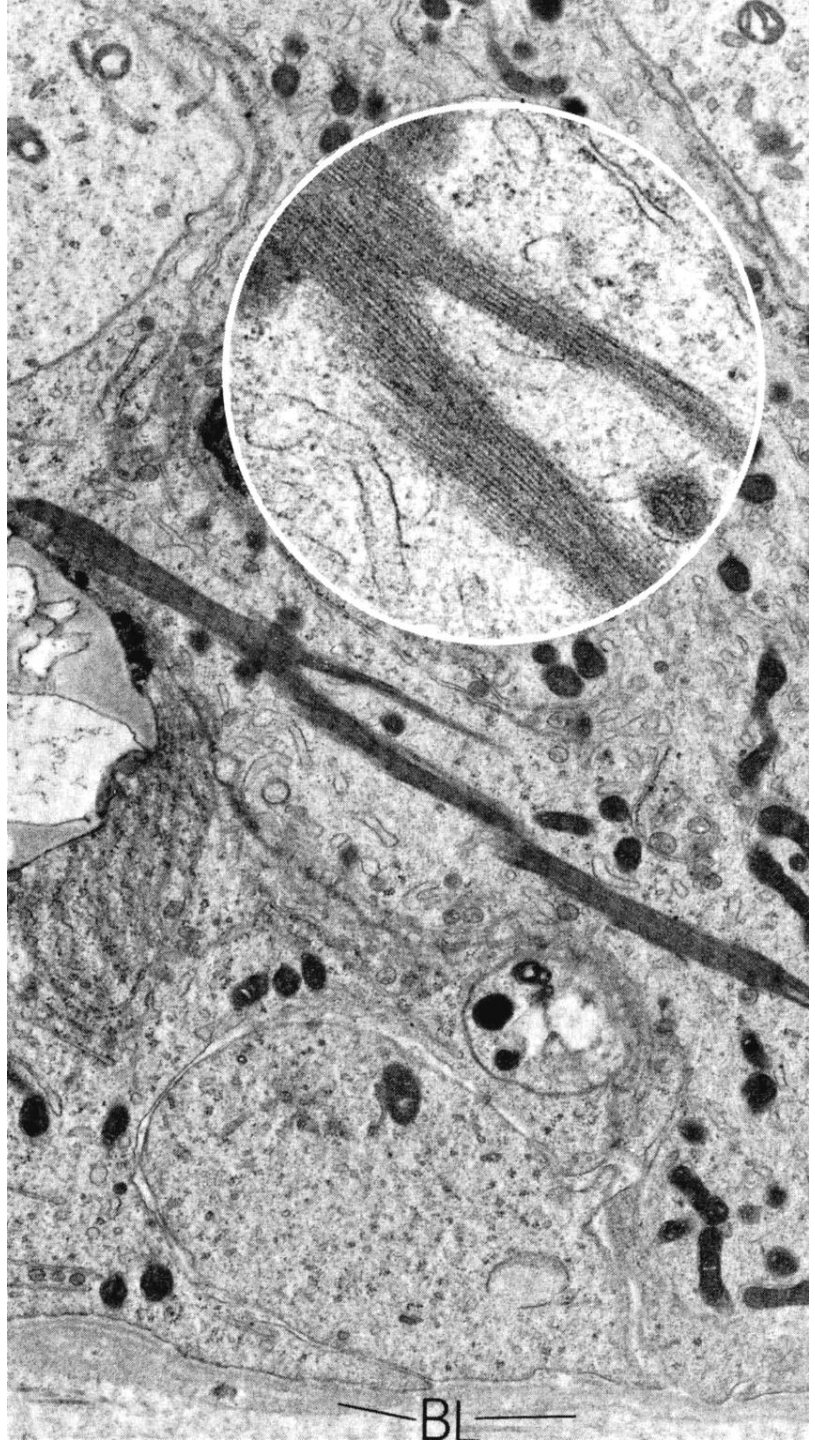

Intesticiální tkáň
Textus connectivus intertubularis

- **Leydigovy buňky** 15 – 20 um, polyedrické, eosinofilní; sférické velké jádro, velké SER, tubulární mitochondrie; lipidové kapénky, Reinkeho krystaloidy
  - **testosteron**
  - aktivní zejména mezi 8.-12. týdnem nitroděložního vývoje (vliv HCG)
    - zásadní význam pro diferenciaci pohlavních orgánů v mužský typ
  - opět aktivní od puberty (vliv LH)
    - vazba na ABP umožňuje jeho vysokou koncentraci v tubuli seminiferi → zdárný průběh spermiogeneze
    - sekundární pohlavní znaky
- Řídké kolagenní vazivo, fen. kapiláry, fibroblasty, žírné buňky, makrofágy

https://cz.vitamin360.com/p/universal-nutrition-animal-test-21-packs

Leydigovy intersticiální buňky

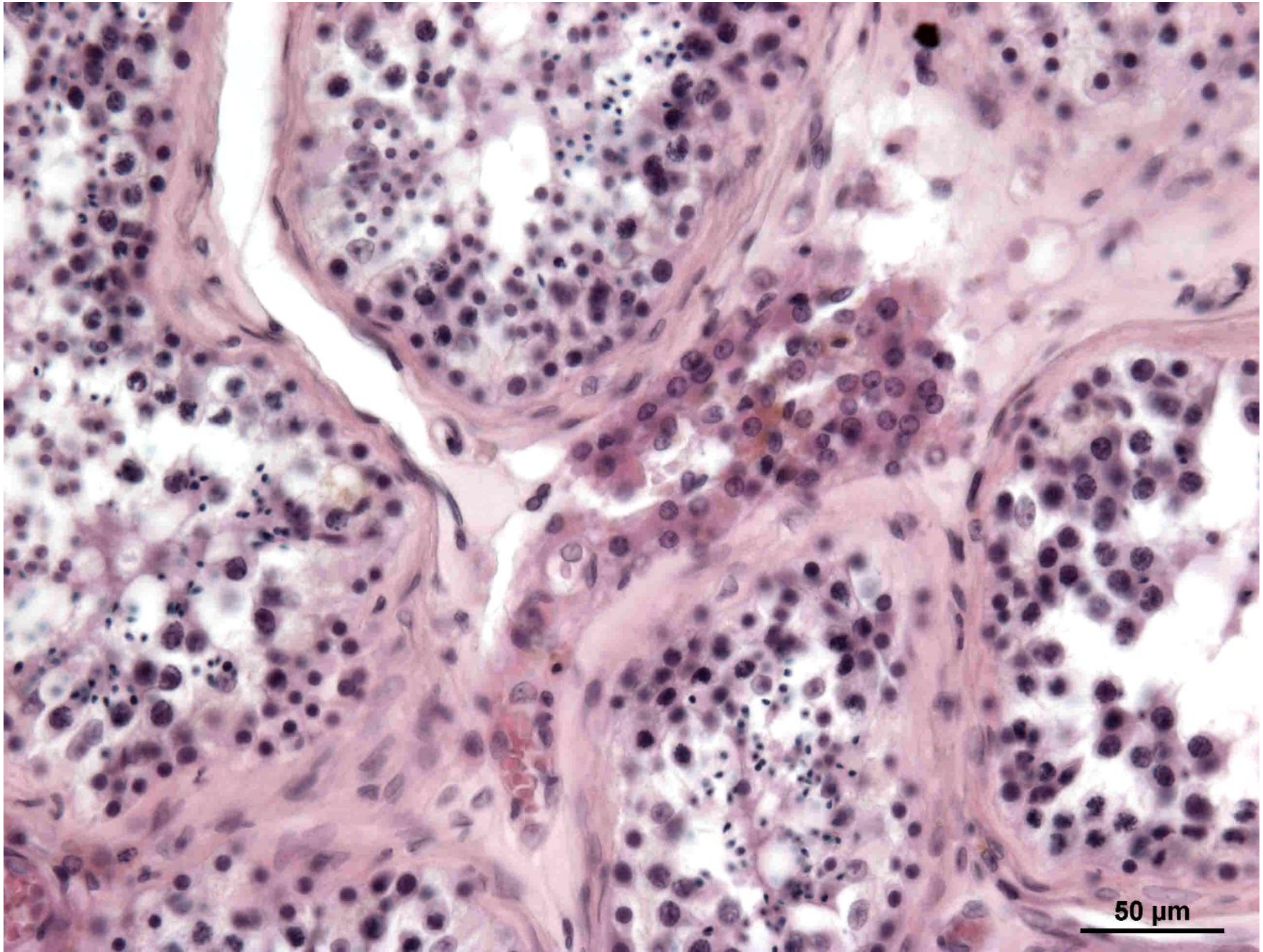

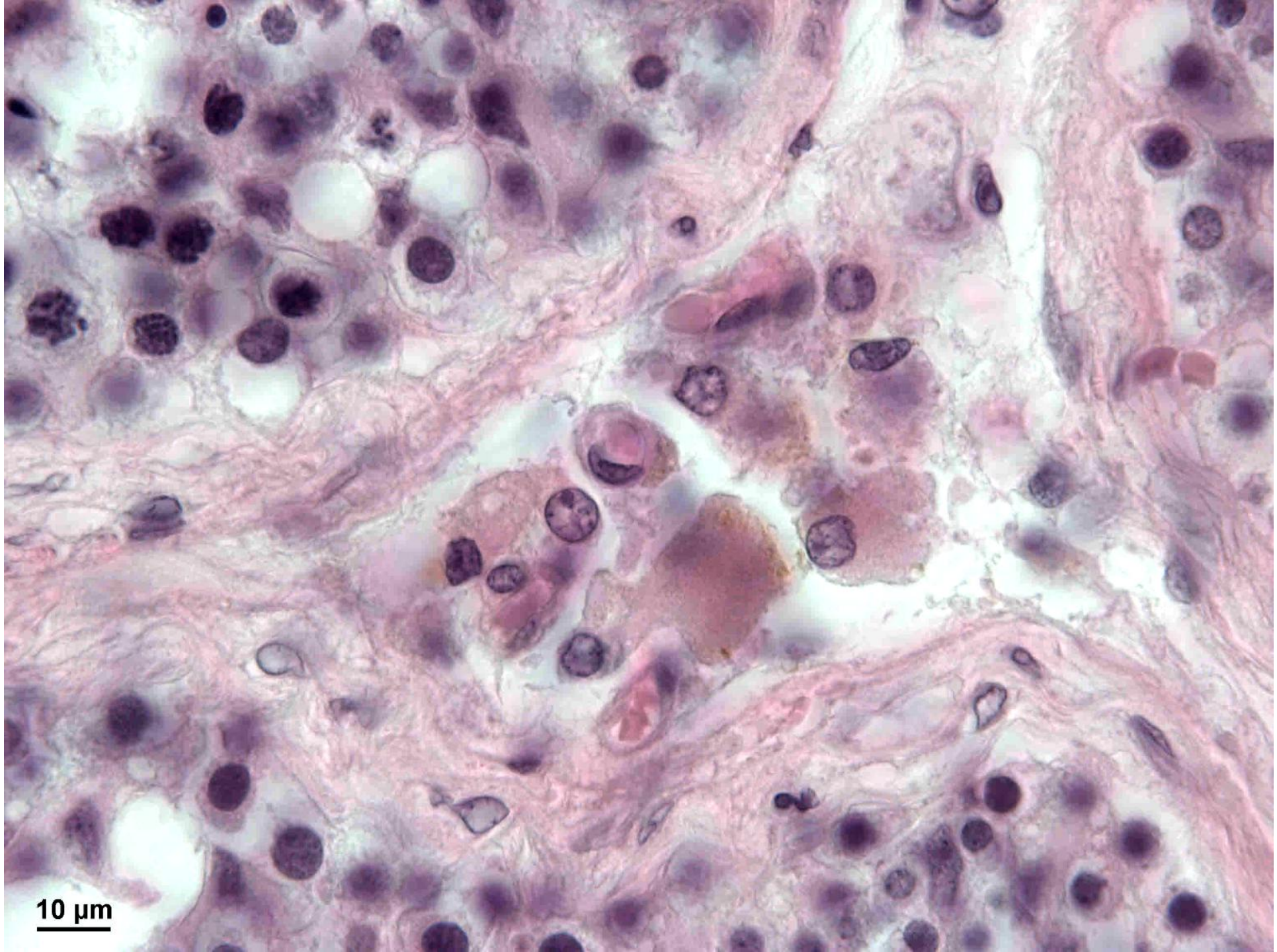
10 µm

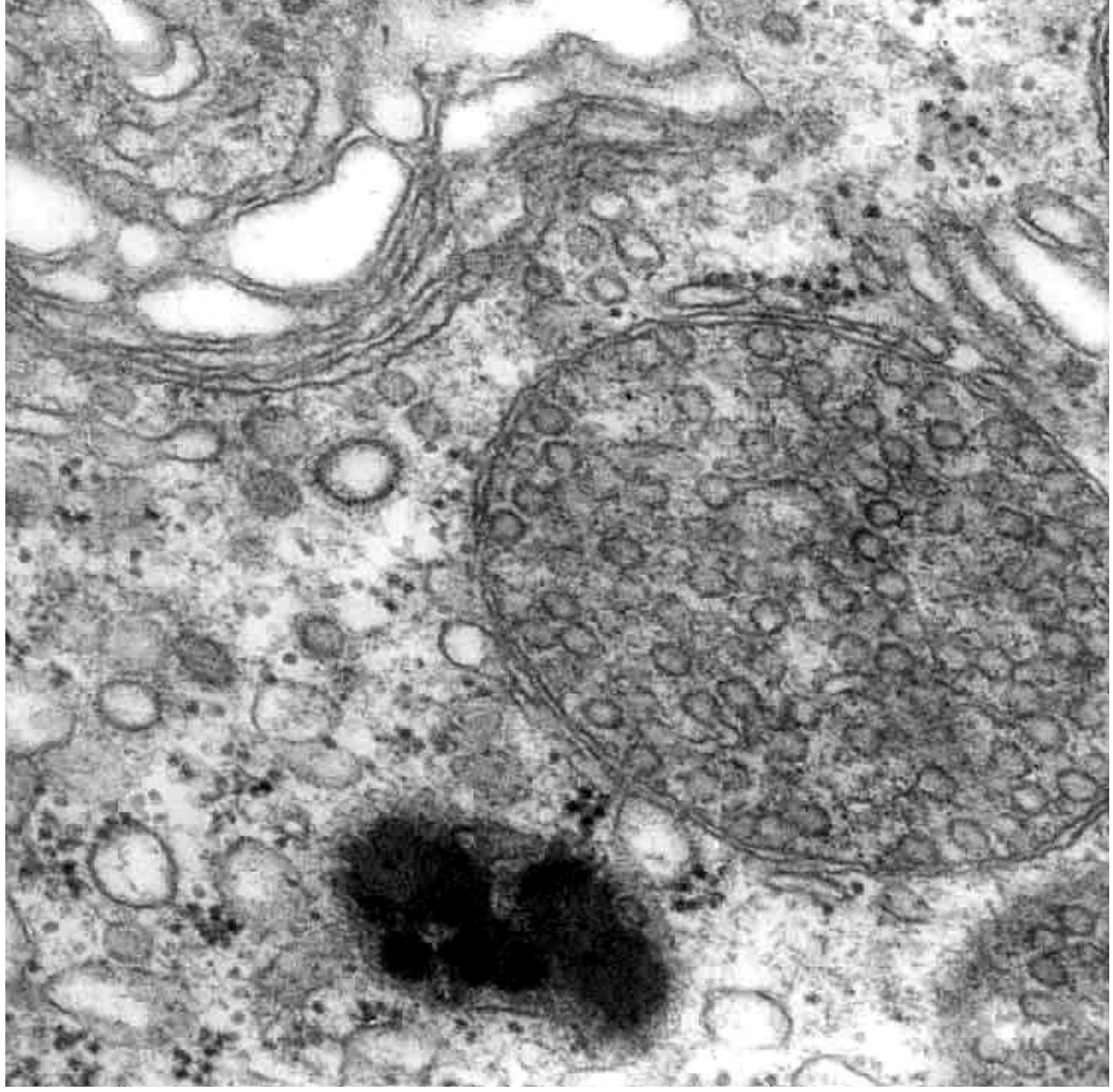

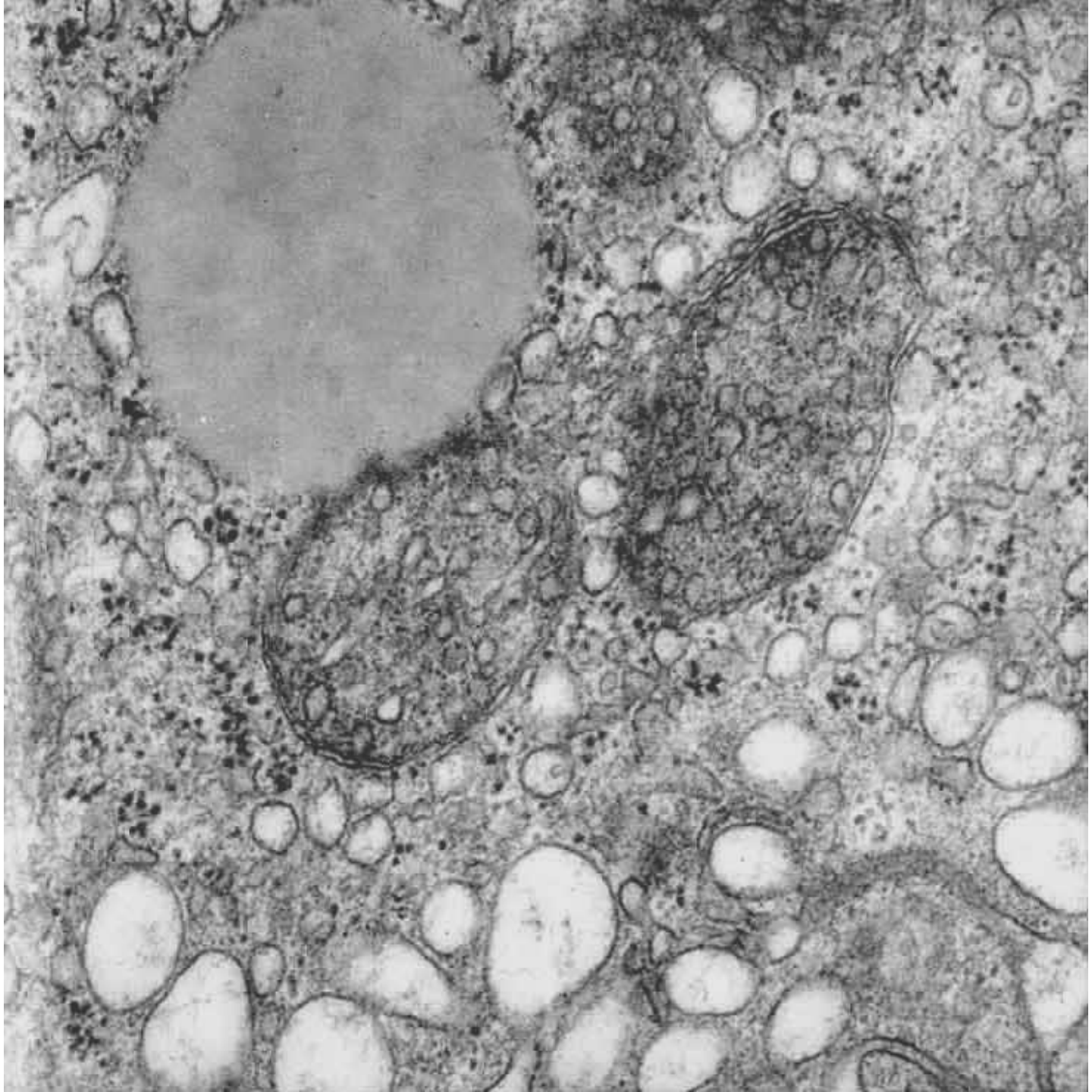

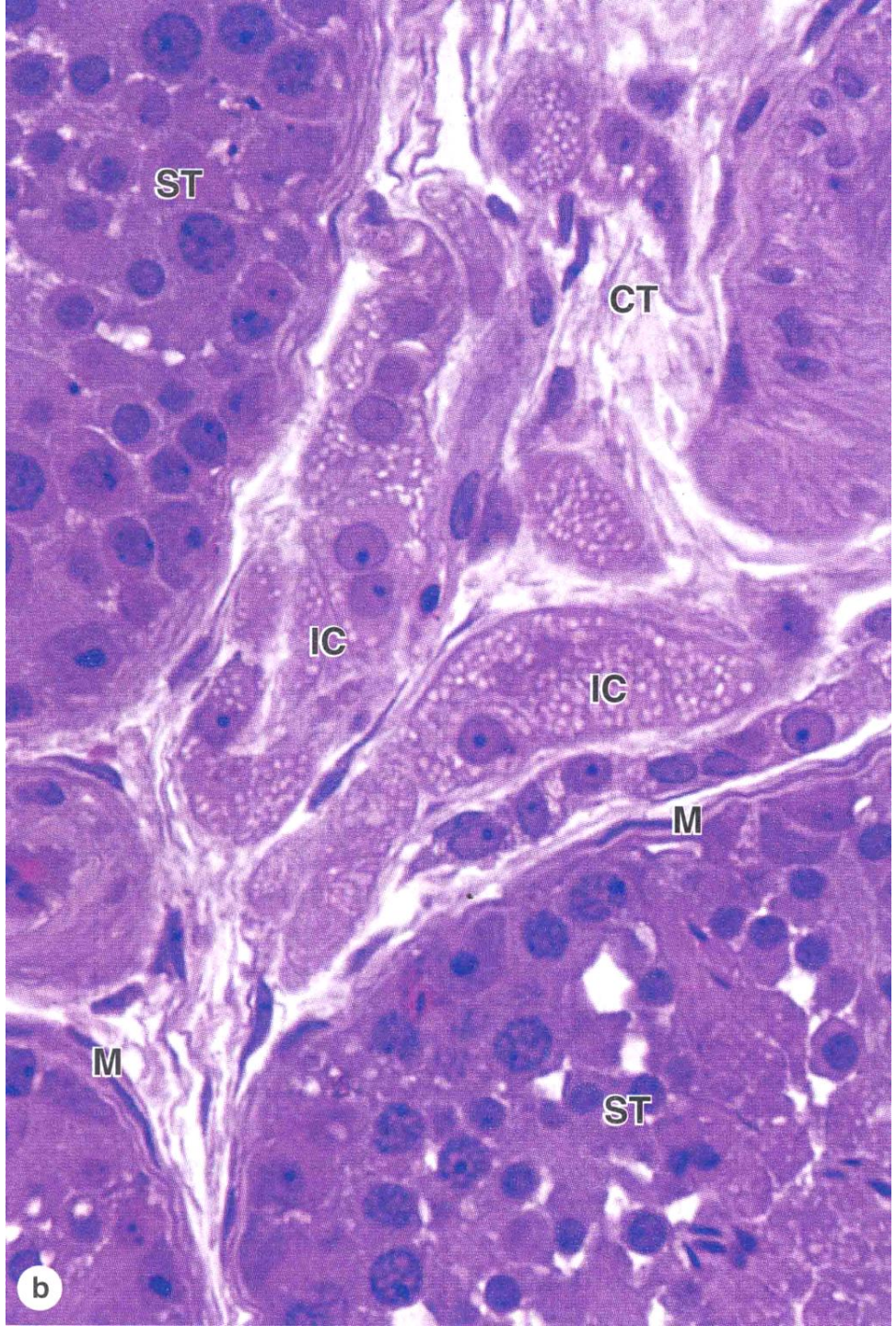
ST
CT
IC
IC
M
M
ST
b

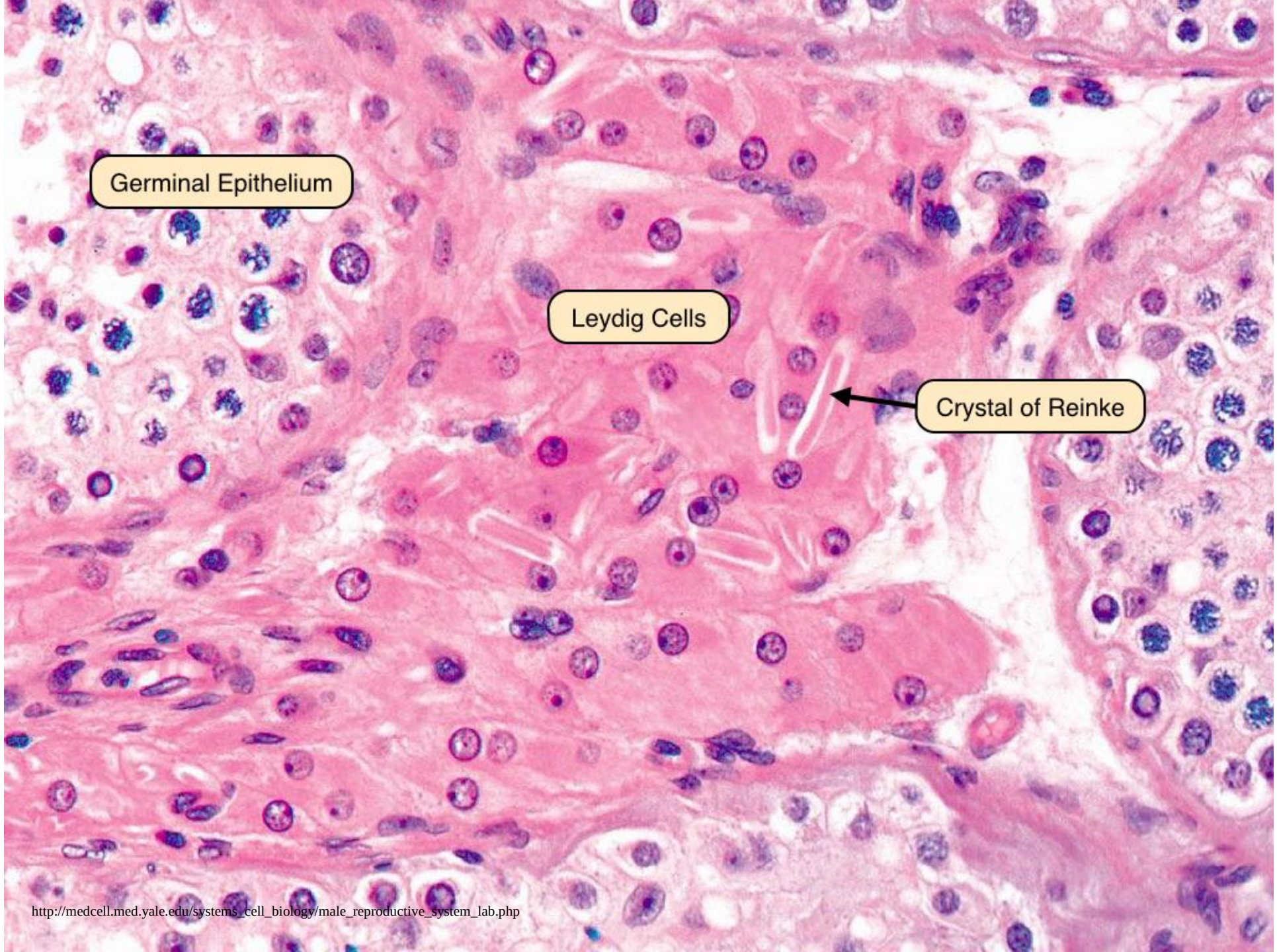

http://medcell.med.yale.edu/systems_cell_biology/male_reproductive_system_lab.php

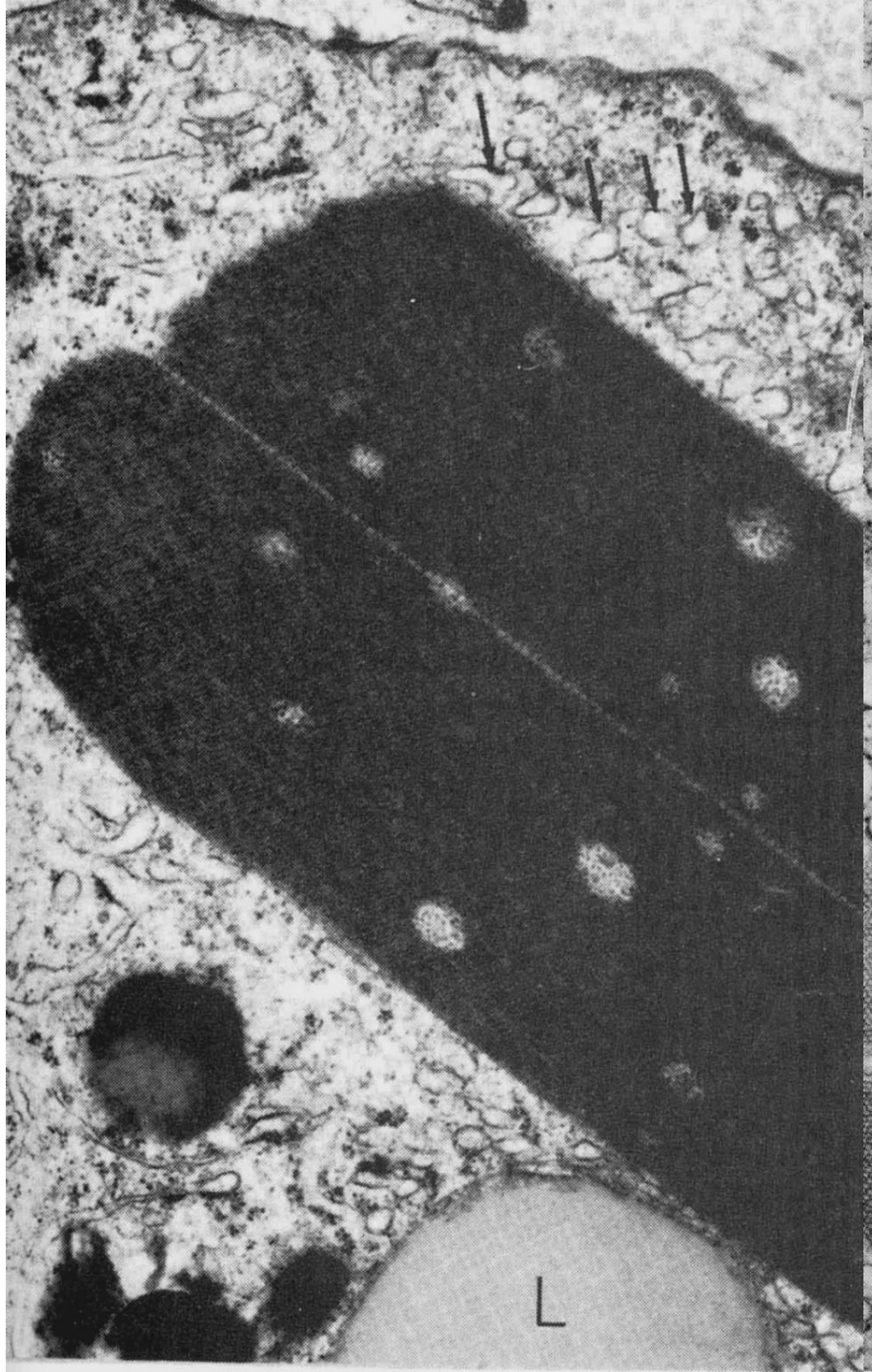
L

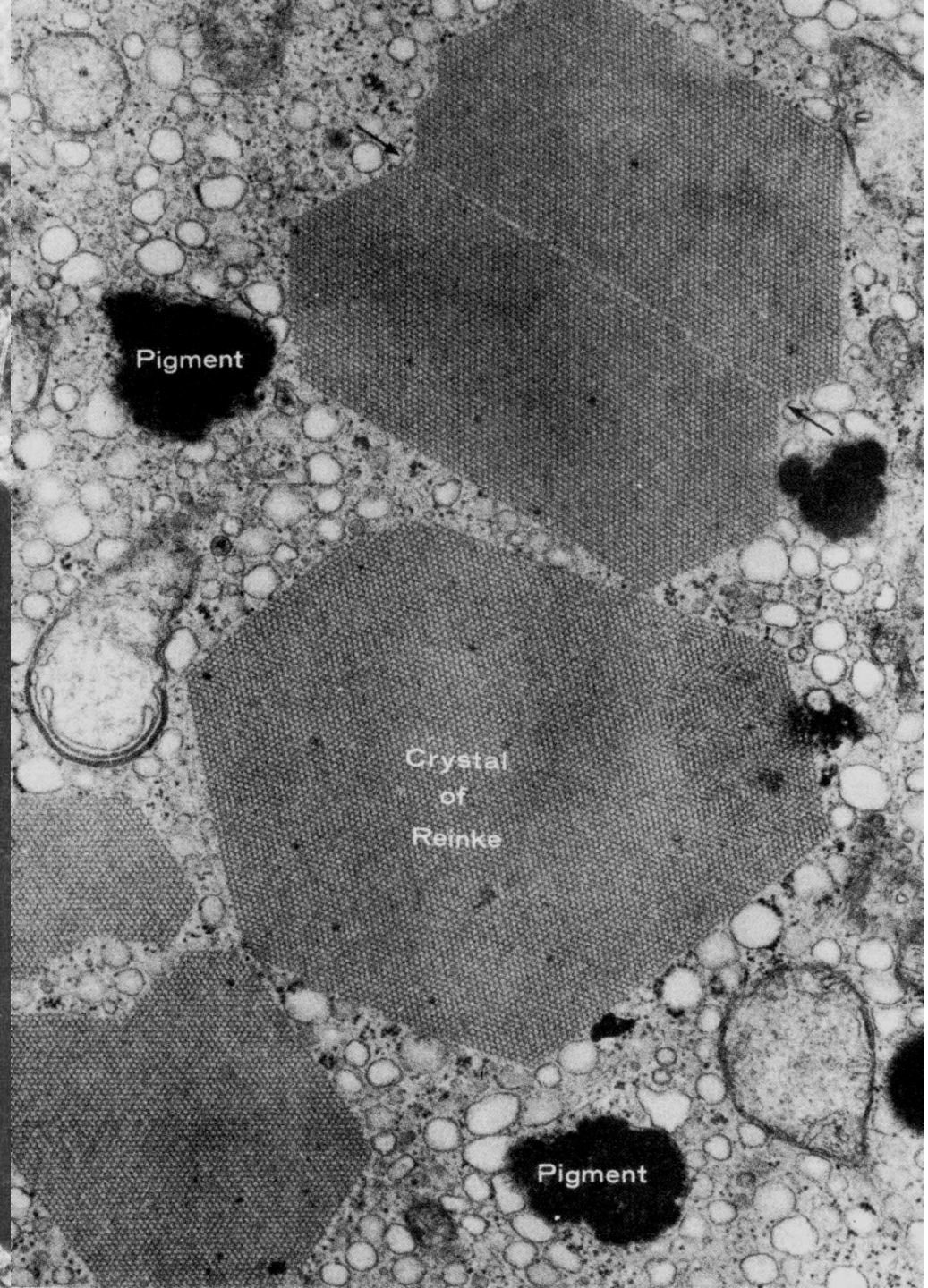
Pigment
Crystal
of
Reinke
Pigment

Reinkeho krystaloid

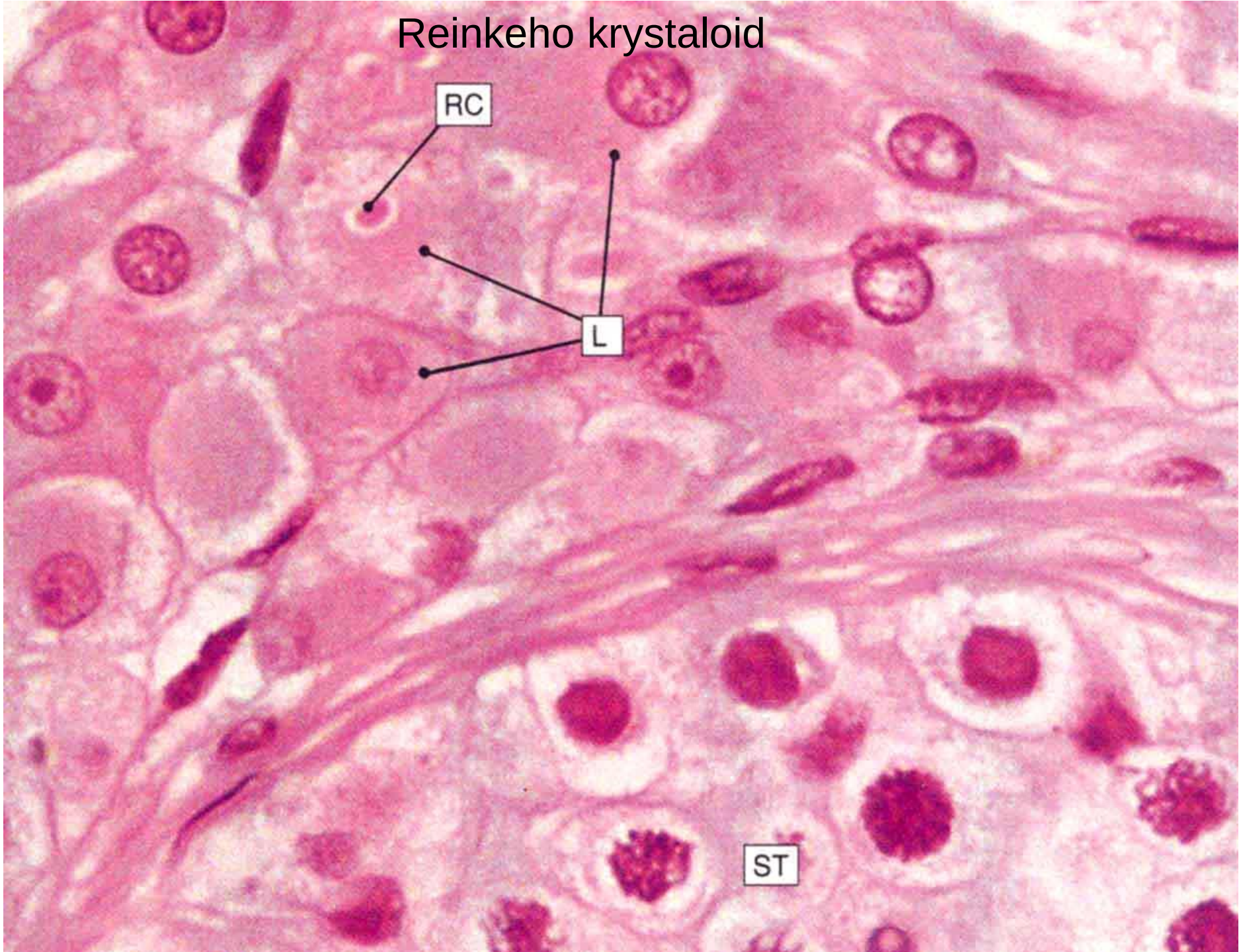

https://www.britannica.com/place/Virginia-state

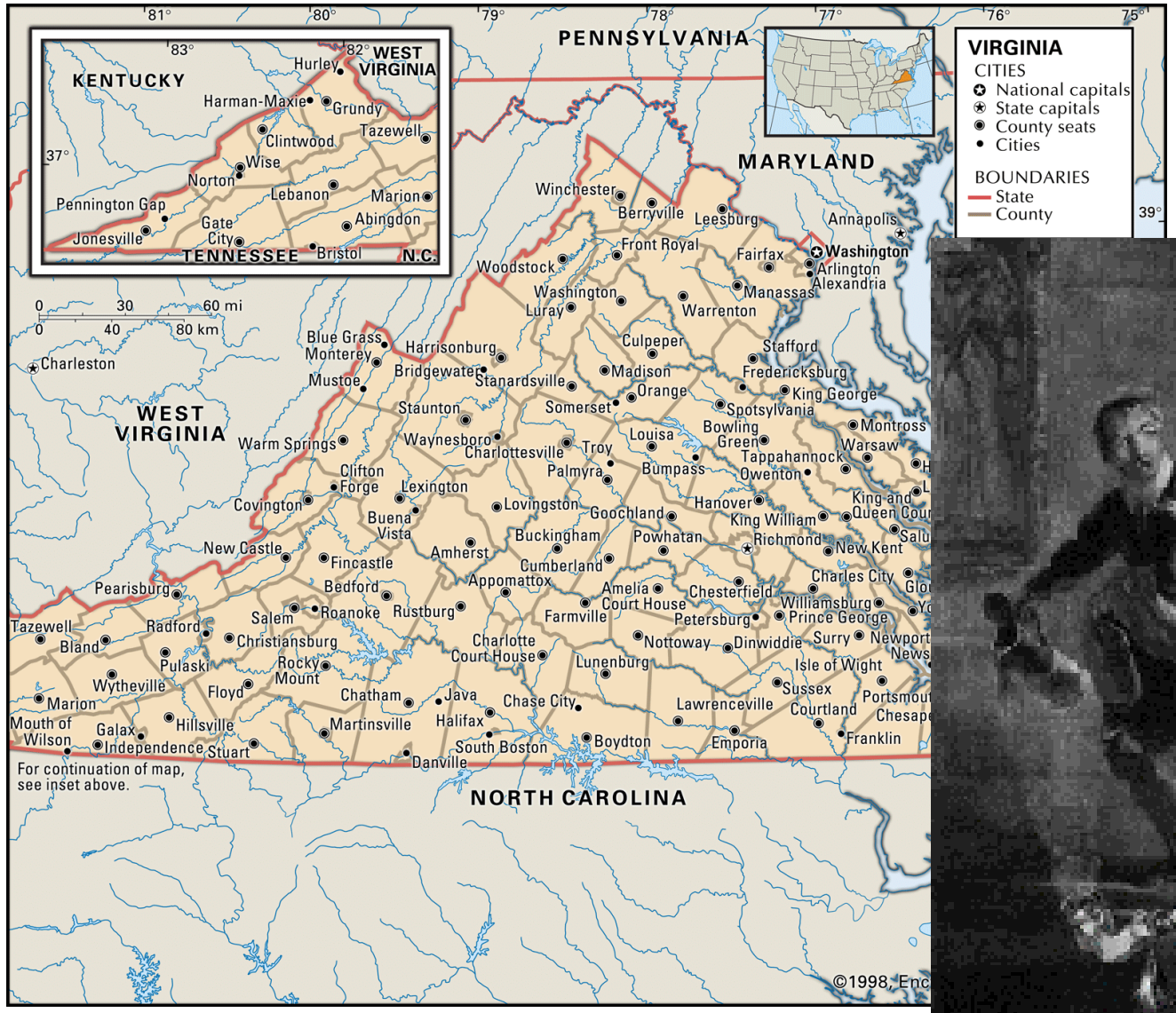

https://www.britannica.com/place/Virginia-state

https://blog.nationalarchives.gov.uk/walter-raleighs-execution-afterlife-archives/

https://www.britannica.com/place/Virginia-state

By Attributed to William Segar/ Attributed to George Gower/ Formerly attributed to Nicholas Hilliard
http://www.artfund.org/what-to-see/exhibitions/2013/10/10/elizabeth-i-and-her-people, Public Domain,
https://commons.wikimedia.org/w/index.php?curid=17871

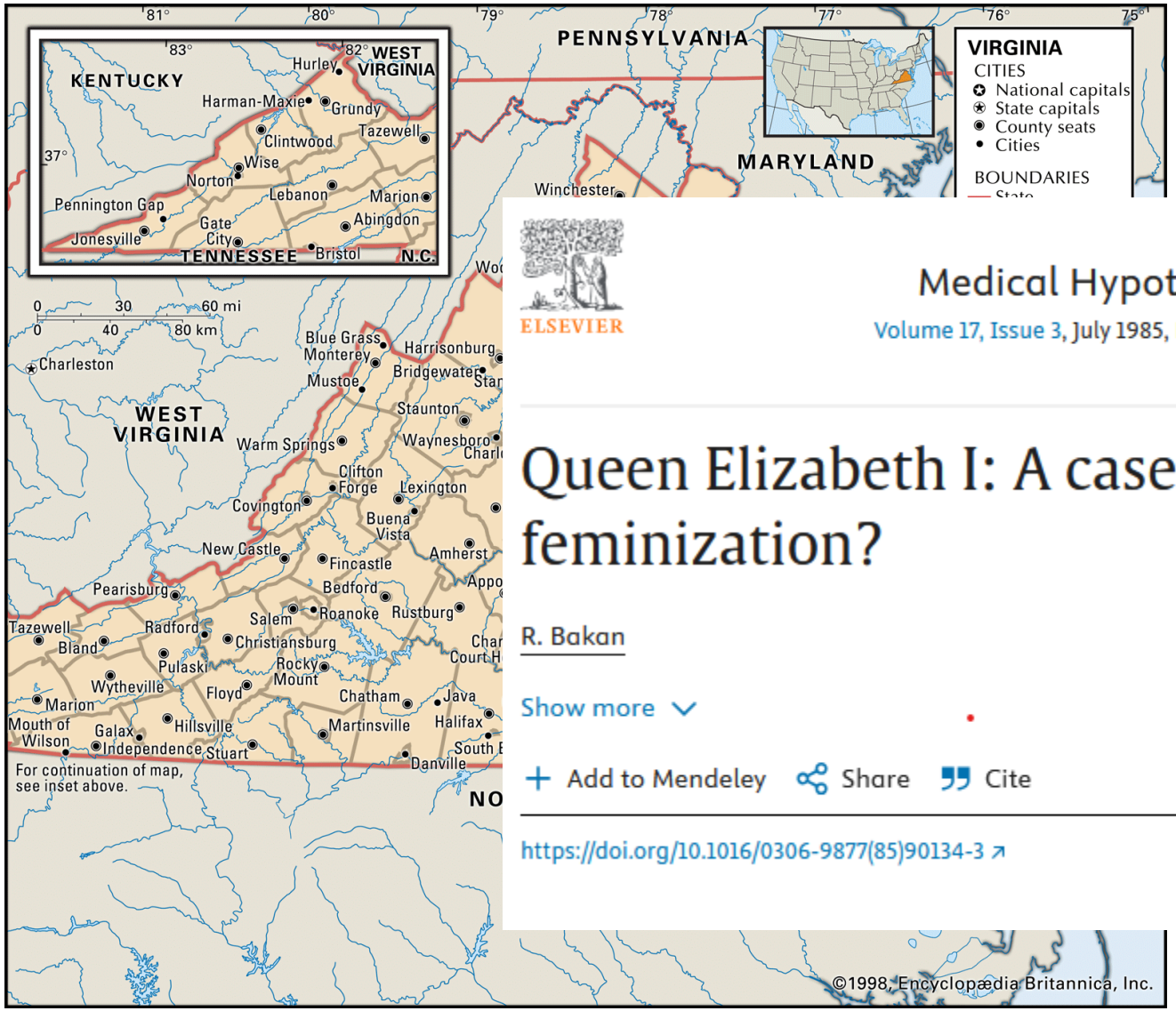

ELSEVIER

Medical Hypotheses

Volume 17, Issue 3, July 1985, Pages 277-284

Queen Elizabeth I: A case of testicular feminization?

R. Bakan

Show more

+ Add to Mendeley Share Cite

https://doi.org/10.1016/0306-9877(85)90134-3

Get rights and content

Full text access

By Attributed to William Segar/ Attributed to George Gower/ Formerly attributed to Nicholas Hilliard
http://www.artfund.org/what-to-see/exhibitions/2013/10/10/elizabeth-i-and-her-people, Public Domain,
https://commons.wikimedia.org/w/index.php?curid=17871

https://www.britannica.com/place/Virginia-state

Syndrom androgenové rezistence
AIS – androgen insensitivity syndrome

https://cz.vitamin360.com/p/universal-nutrition-animal-test-21-packs

By Attributed to William Segar/ Attributed to George Gower/ Formerly attributed to Nicholas Hilliard - http://www.artfund.org/what-to-see/exhibitions/2013/10/10/elizabeth-i-and-her-people, Public Domain, https://commons.wikimedia.org/w/index.php?curid=17871

Syndrom androgenové rezistence
AIS – androgen insensitivity syndrome

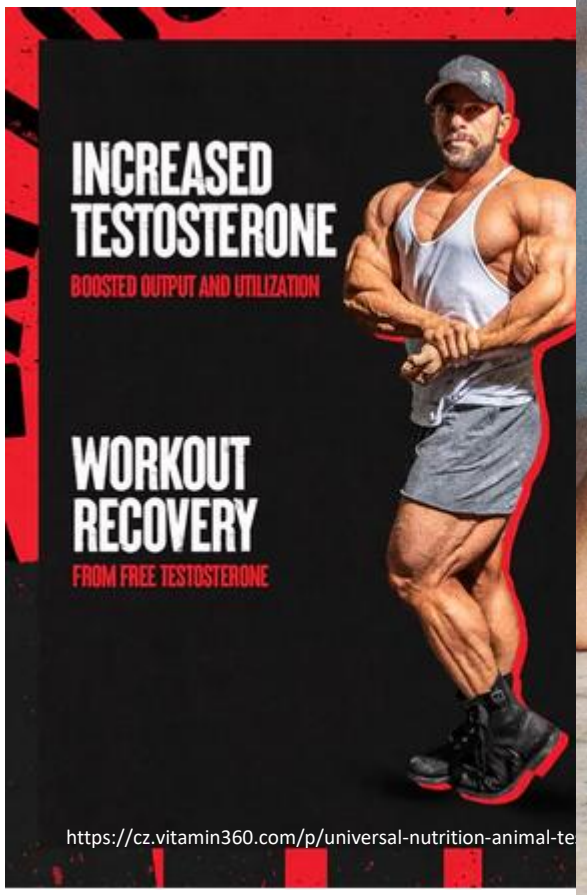

https://cz.vitamin360.com/p/universal-nutrition-animal-te

https://www.vogue.cz/clanek/society/martin-vasa/hanne-gaby-odiele-o-tom-co-to-znamena-byt-intersexualni

llam Segar/ Attributed to George Gower/ Formerly attributed to Nicholas
w.artfund.org/what-to-see/exhibitions/2013/10/10/elizabeth-i-and-her-
ain, https://commons.wikimedia.org/w/index.php?curid=17871

Mužské vývodné cesty pohlavní

- intratestikulární
  - tubuli recti
  - rete testis

- Extratestikulární
  - ductuli efferentes
  - ductus epididymidis
  - ductus deferens
  - ductus ejaculatorius

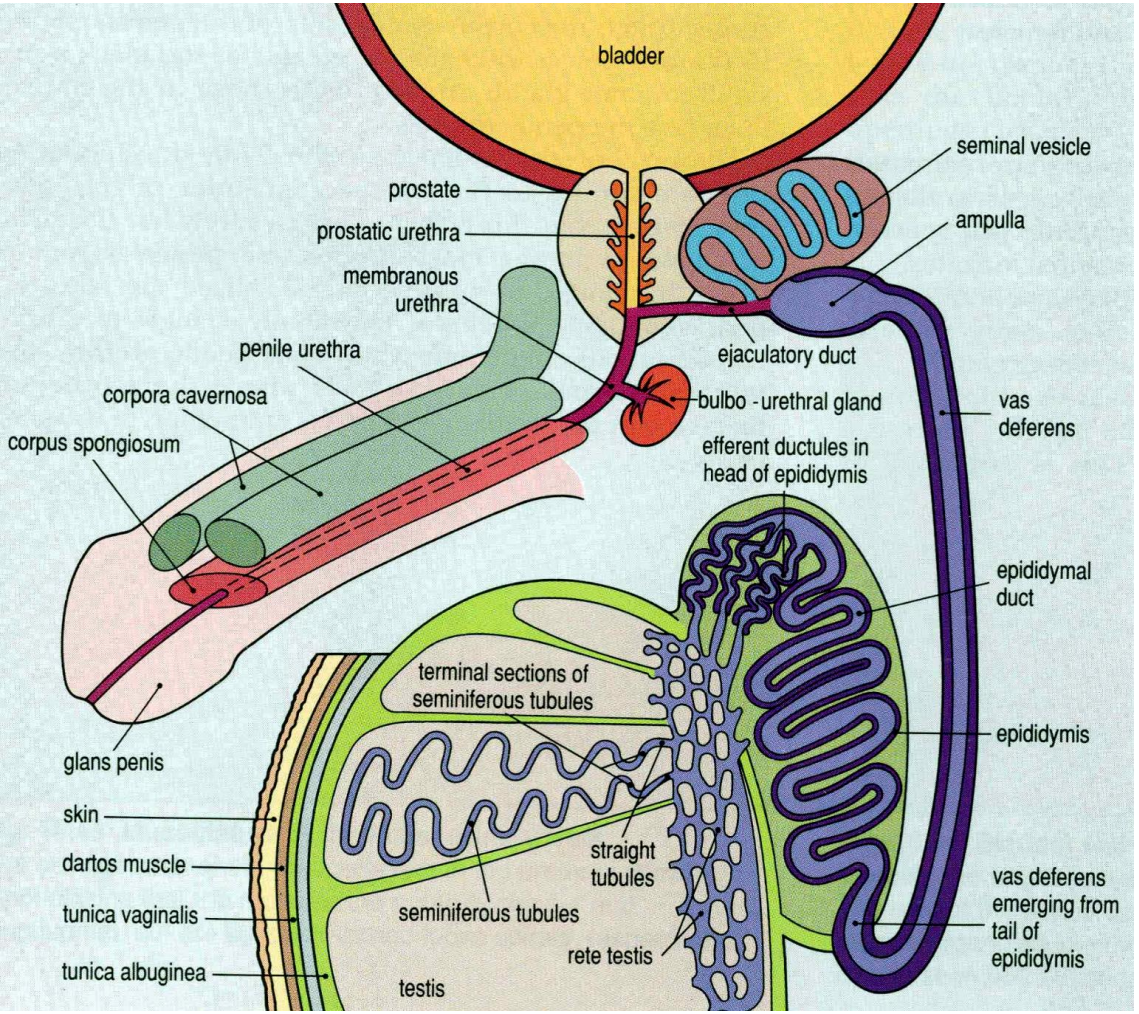

Vývodní pohlavní cesty 1.

- **tubuli recti testis**
  - jednovrstevný kubický epitel
- **rete testis**
  - jednovrstevný kubický (plochý až cylindrický)
- **ductuli efferentes testis**
  - jedno- až dvojřadý kubický až cylindrický epitel (*vlnitý, vroubkovaný reliéf*)
    - cylindrické - řasinky
    - kubické - mikroklky
  - 12 - 20 kanálků (12 cm)

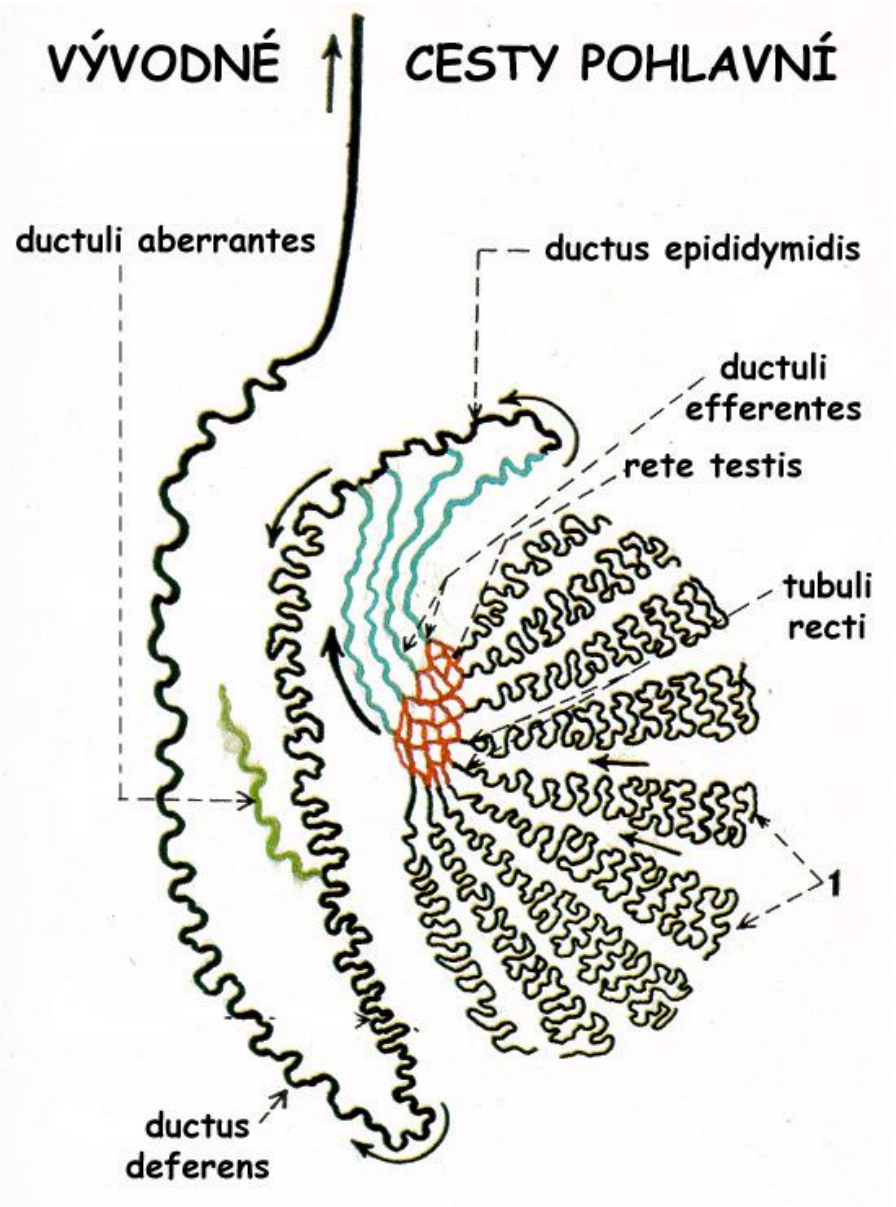

Vývodní pohlavní cesty 2.

- **ductus epididymidis**
  - dvojřadý cylindrický epitel
    - Malé bazální bb– kulaté
    - Cylindrické sahající k luminu – stereocilie
  - 4 - 6 m dlouhý mnohotně stočený
  - inhibice kapacitace (glycerolfosfocholin)
- **ductus deferens**
  - dvojřadý až víceřadý cylindrický epitel
    - vlásky (*stereocilia*)
  - silná svalová stěna
- **ductus ejaculatorius**
  - chybí svalová vrstva

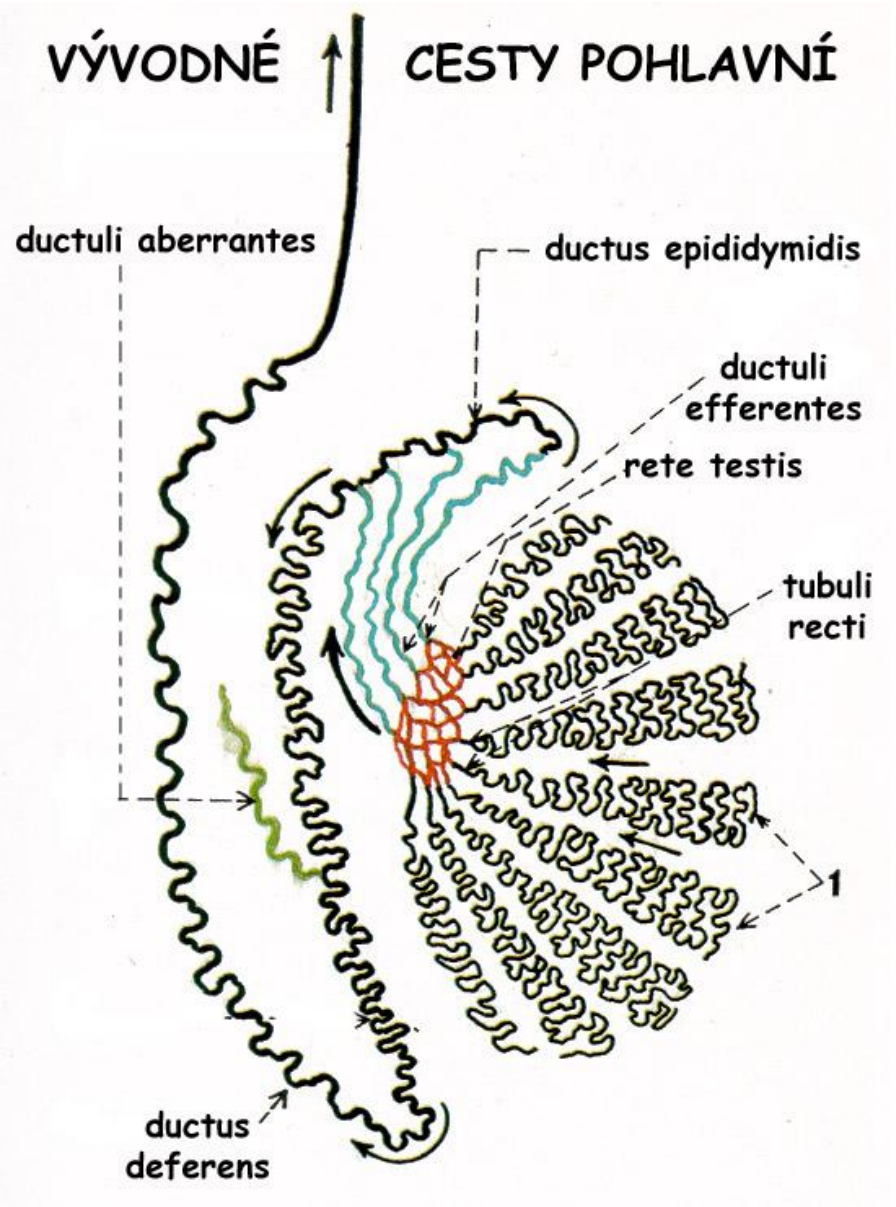

Nadvarle = Epididymis

- vnější popis
  - caput, corpus, cauda
- vnitřní popis
  - ductus epididymidis
  - lobuli epididymidis
- vazy
  - lig. epididymidis superius + inferius

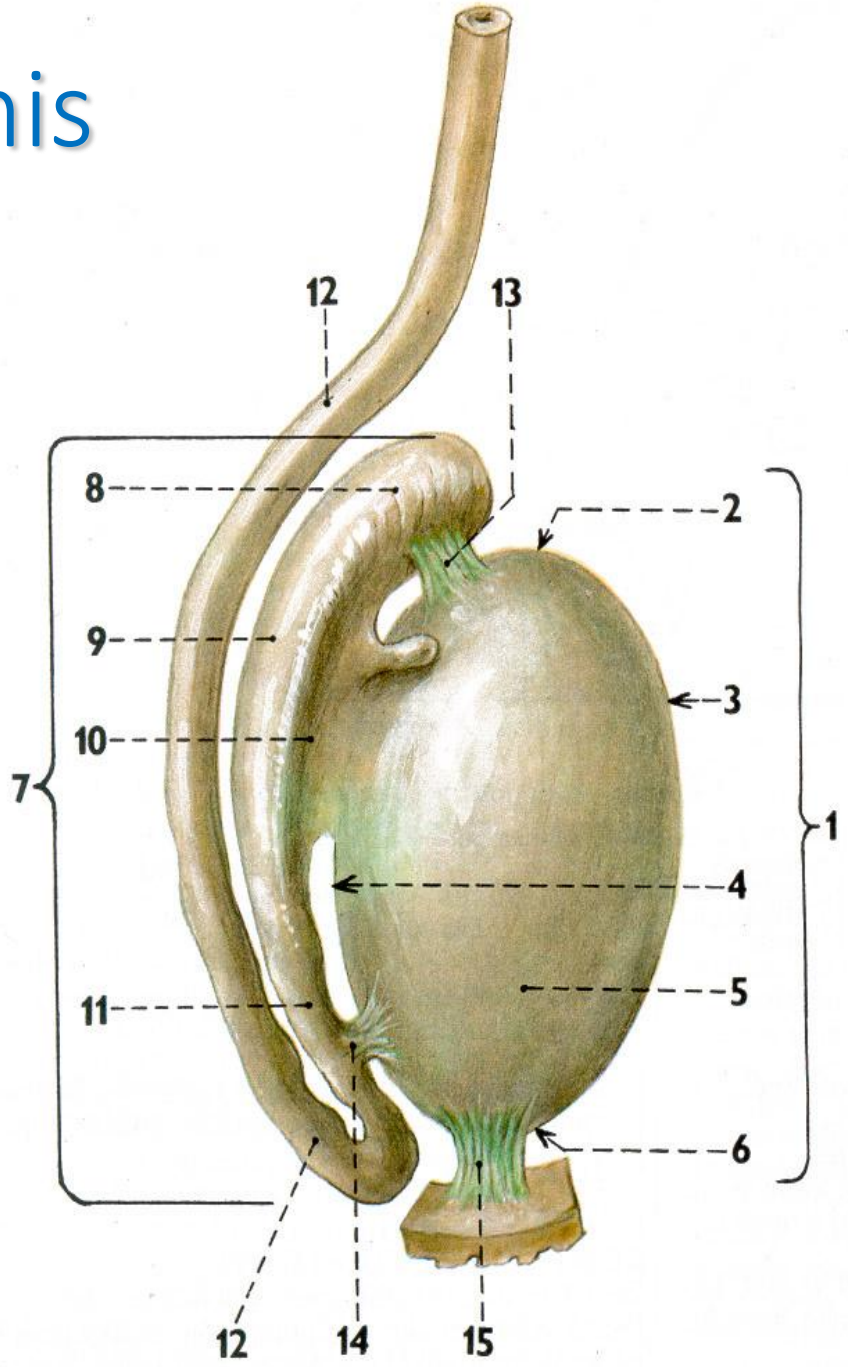

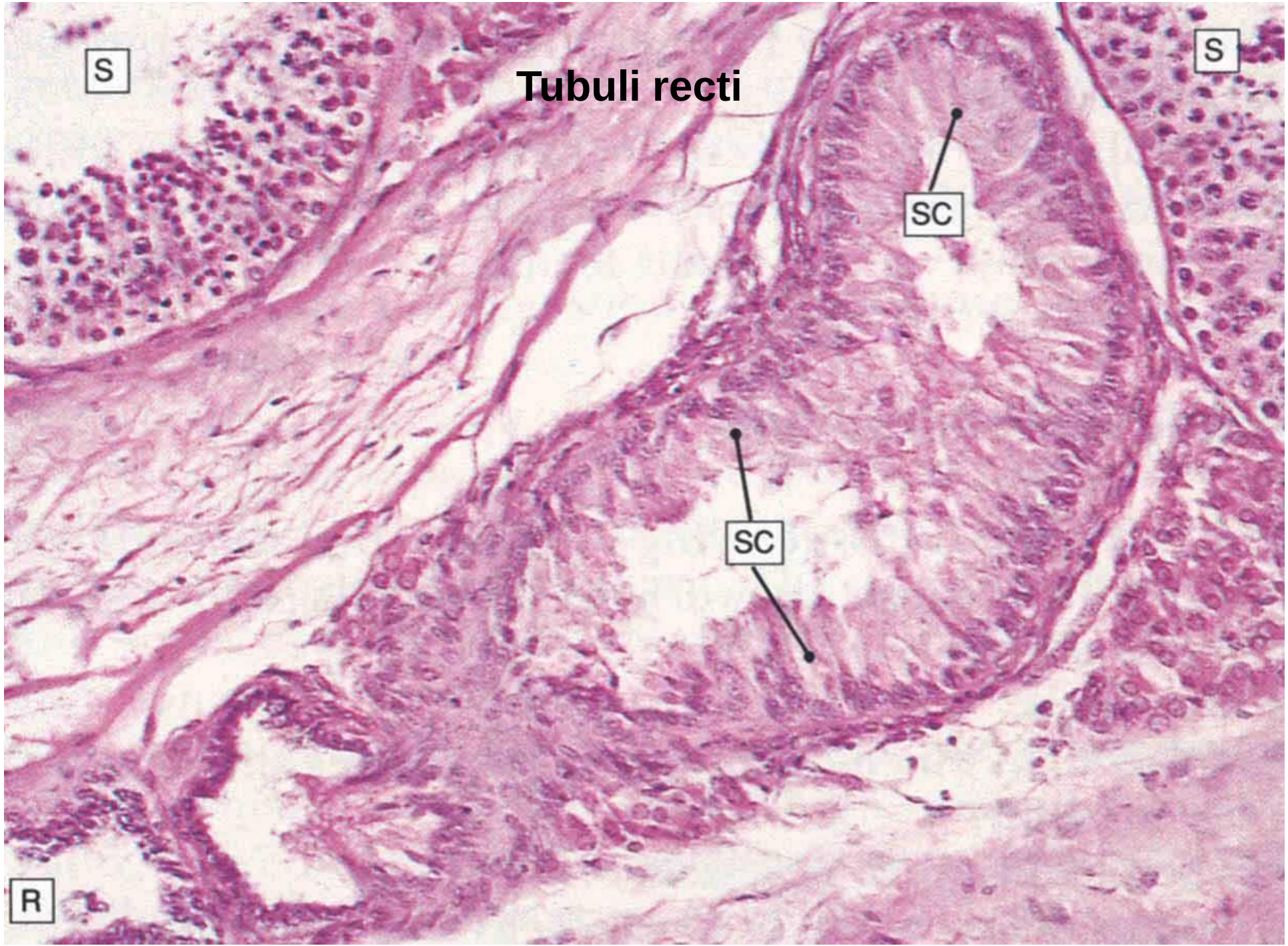
Tubuli recti
S
S
SC
SC
R

Rete testis

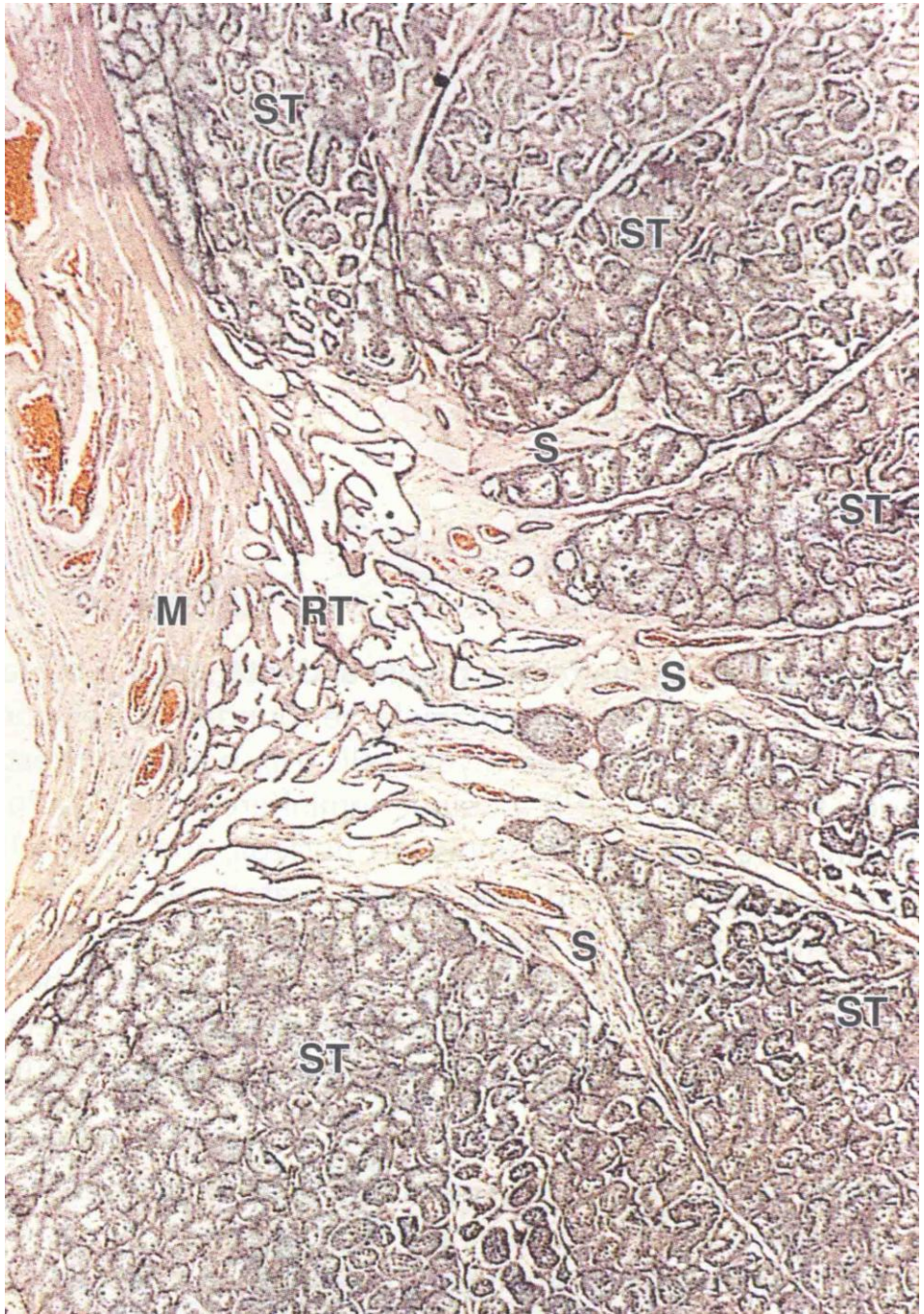

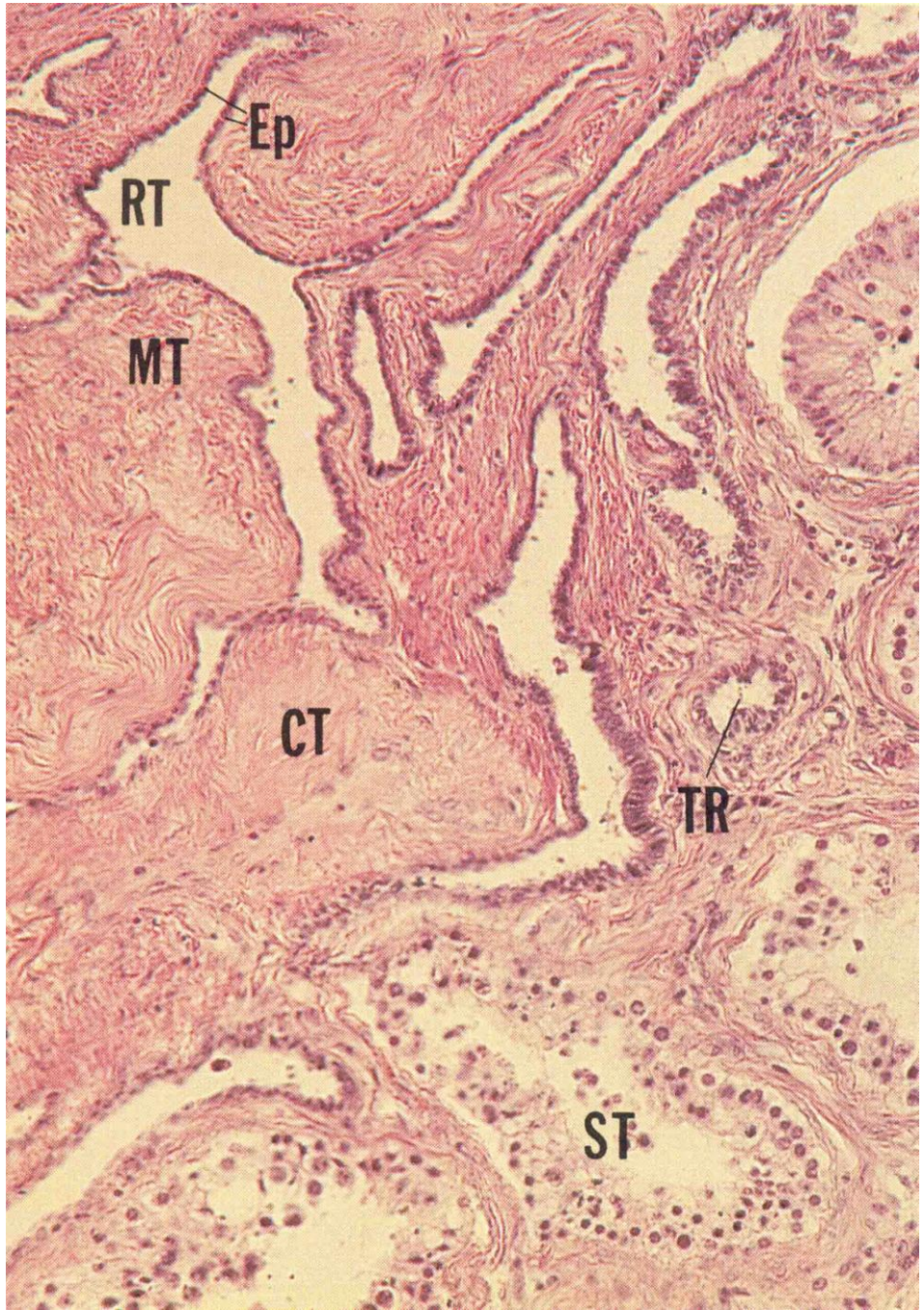

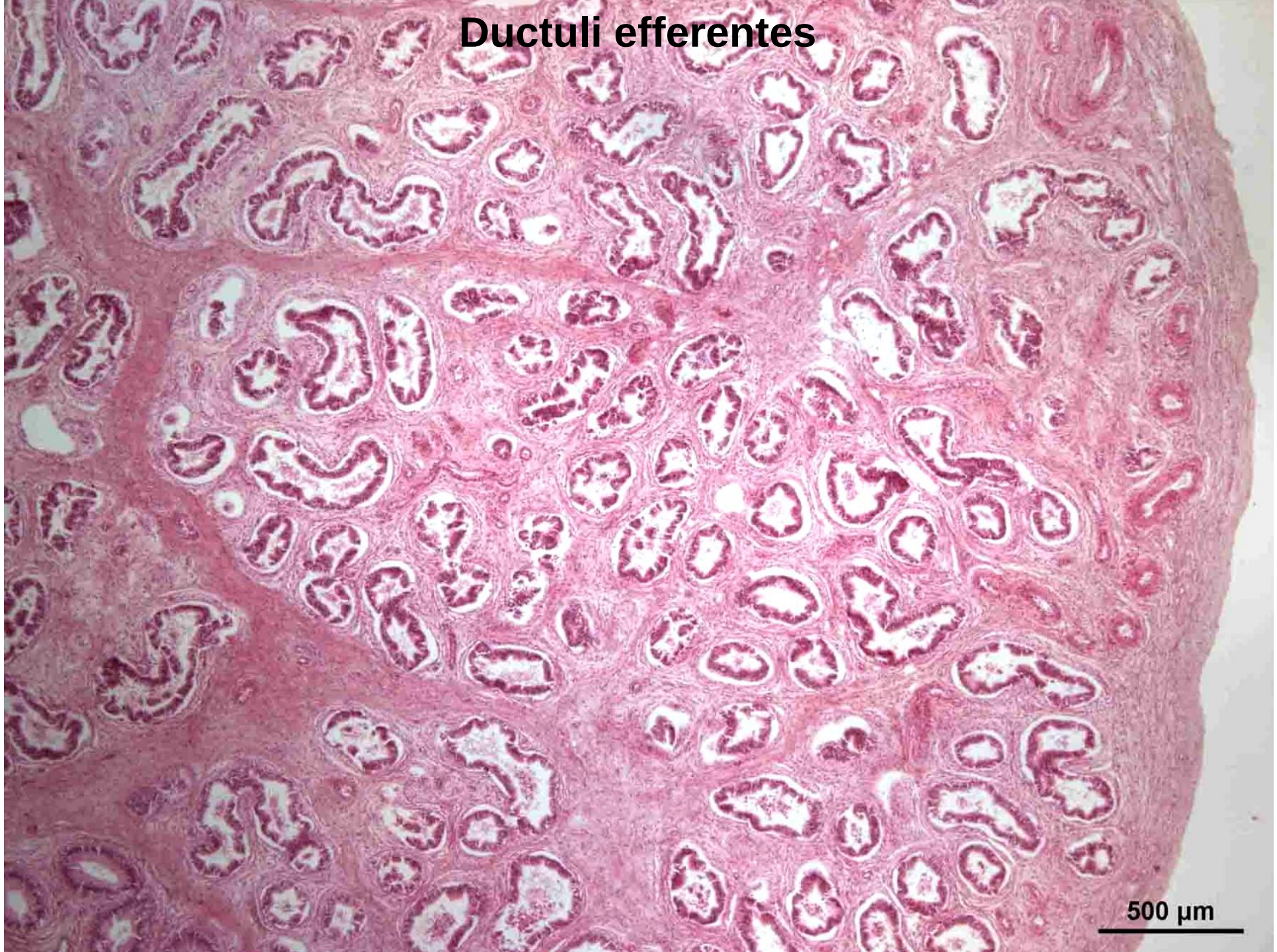
Ductuli efferentes
500 µm

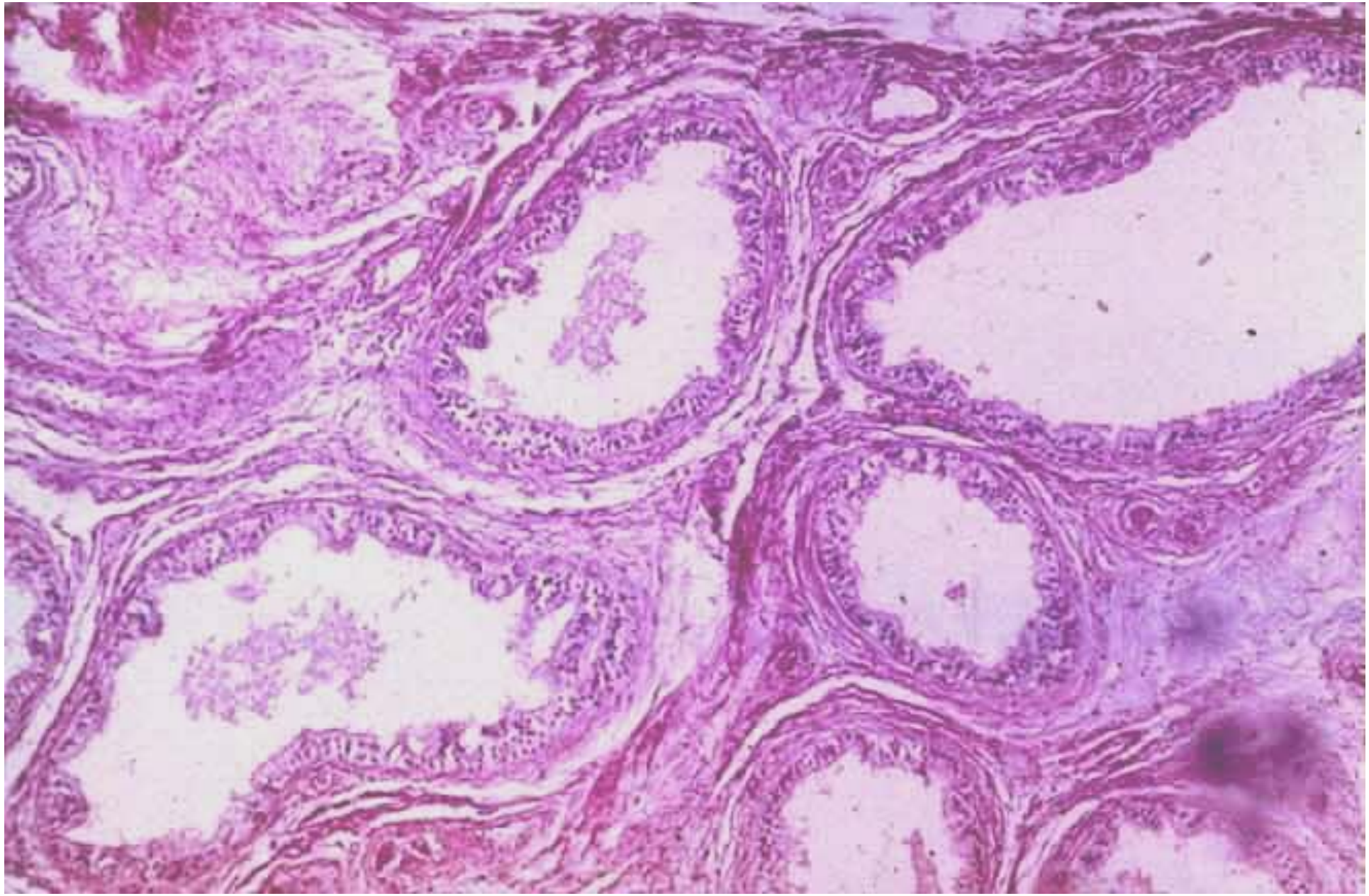

http://medcell.med.yale.edu/systems_cell_biology/male_reproductive_system_lab.php

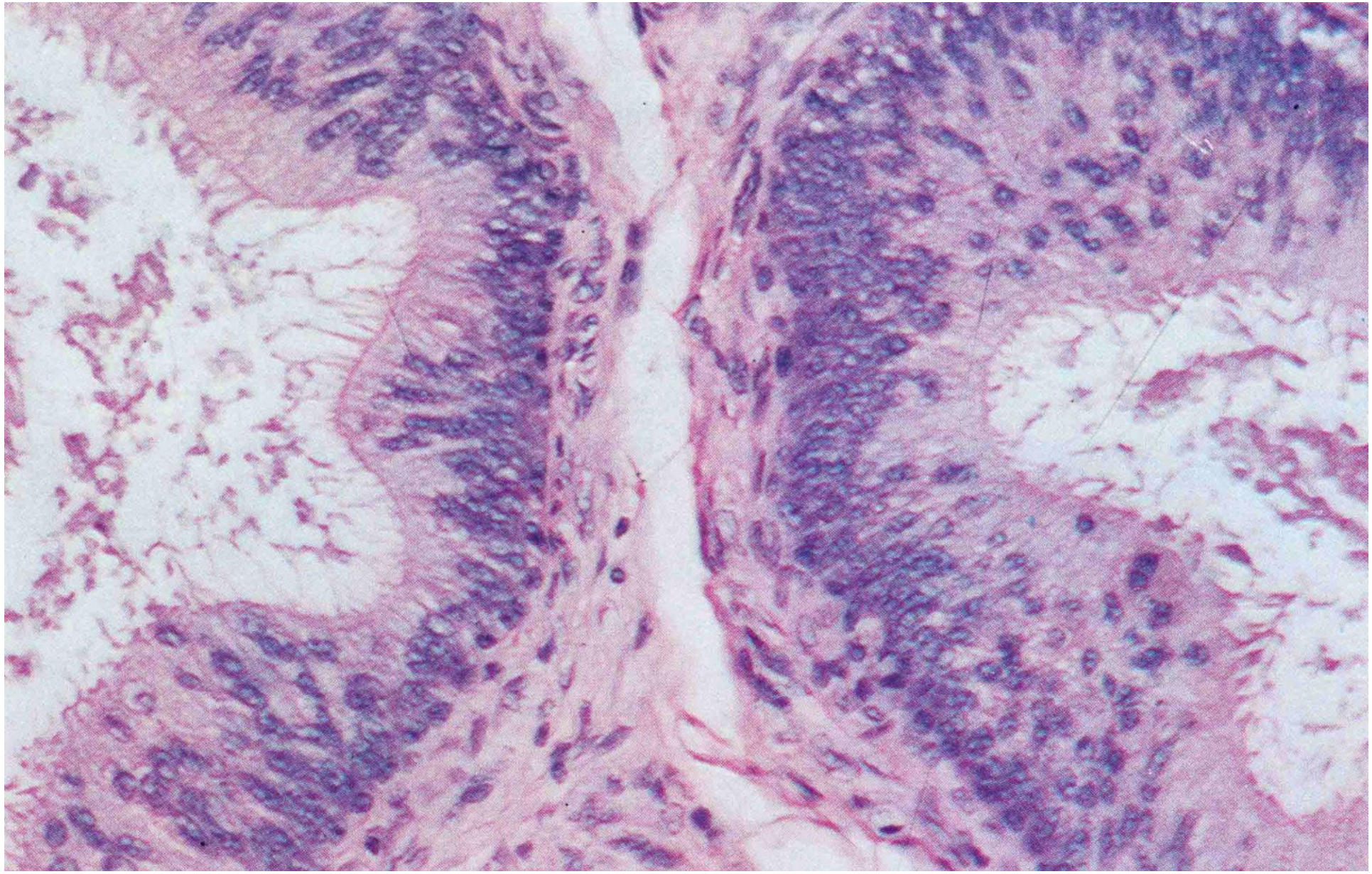


SM
E

Ductus epididymidis

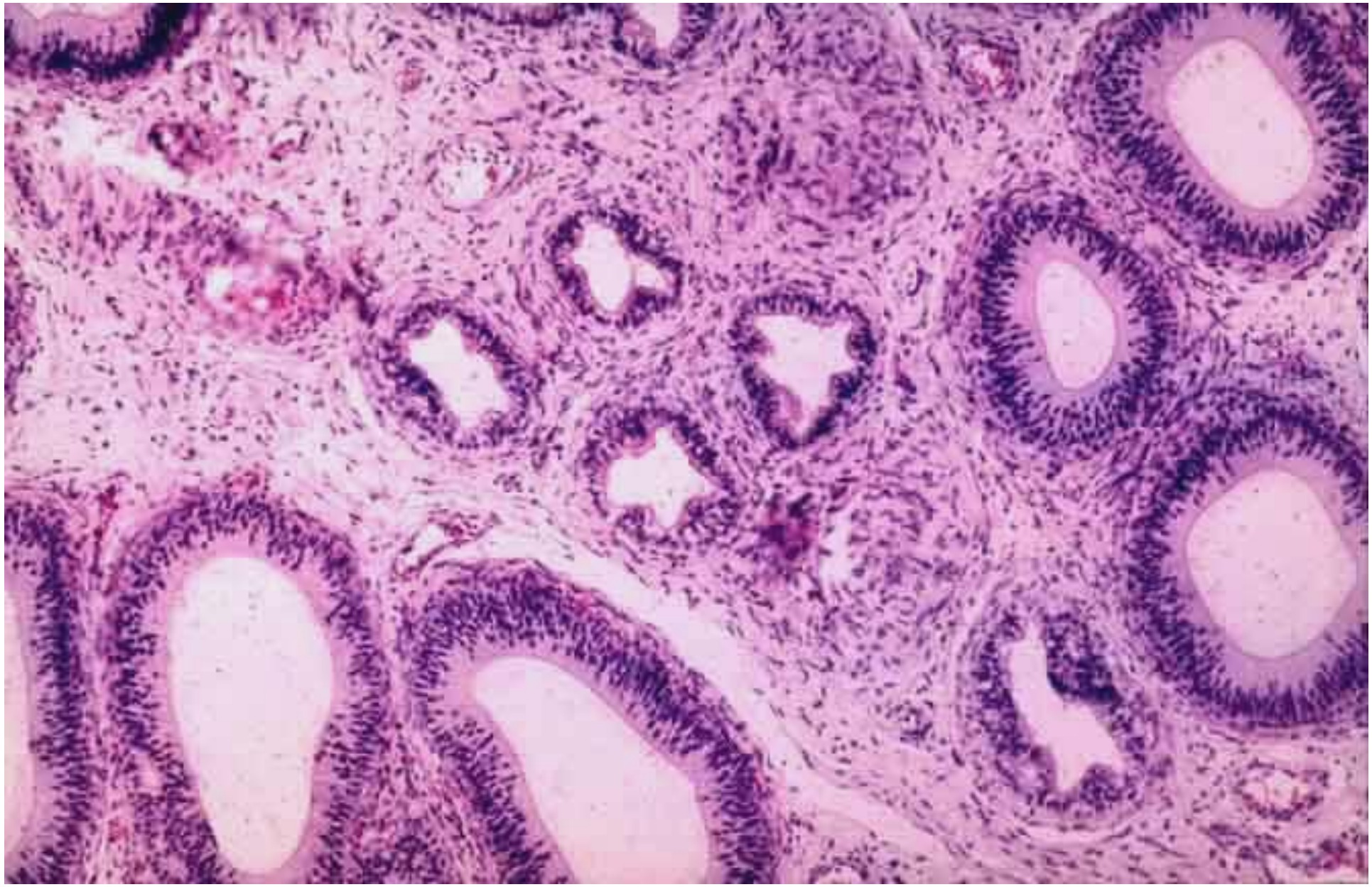

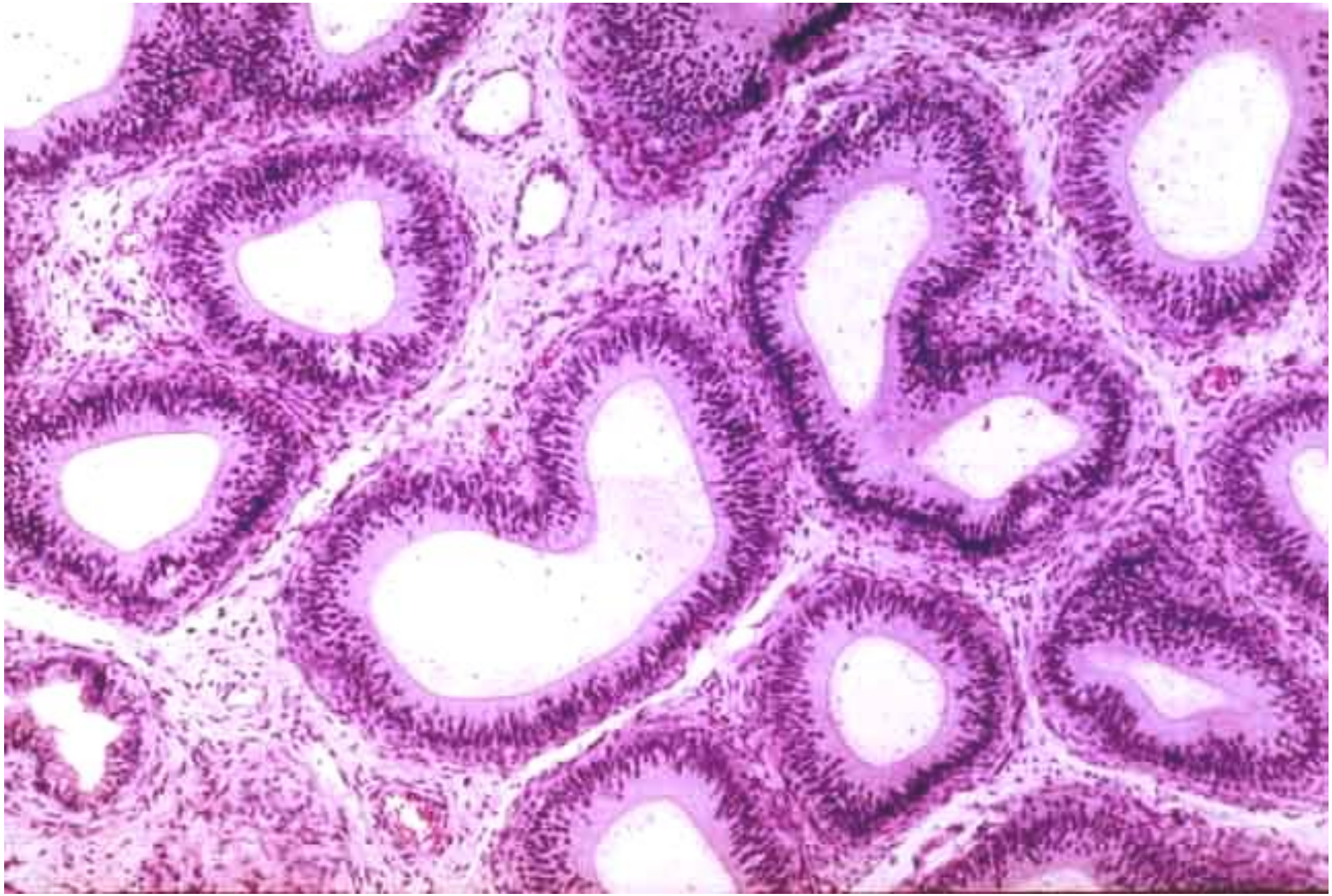

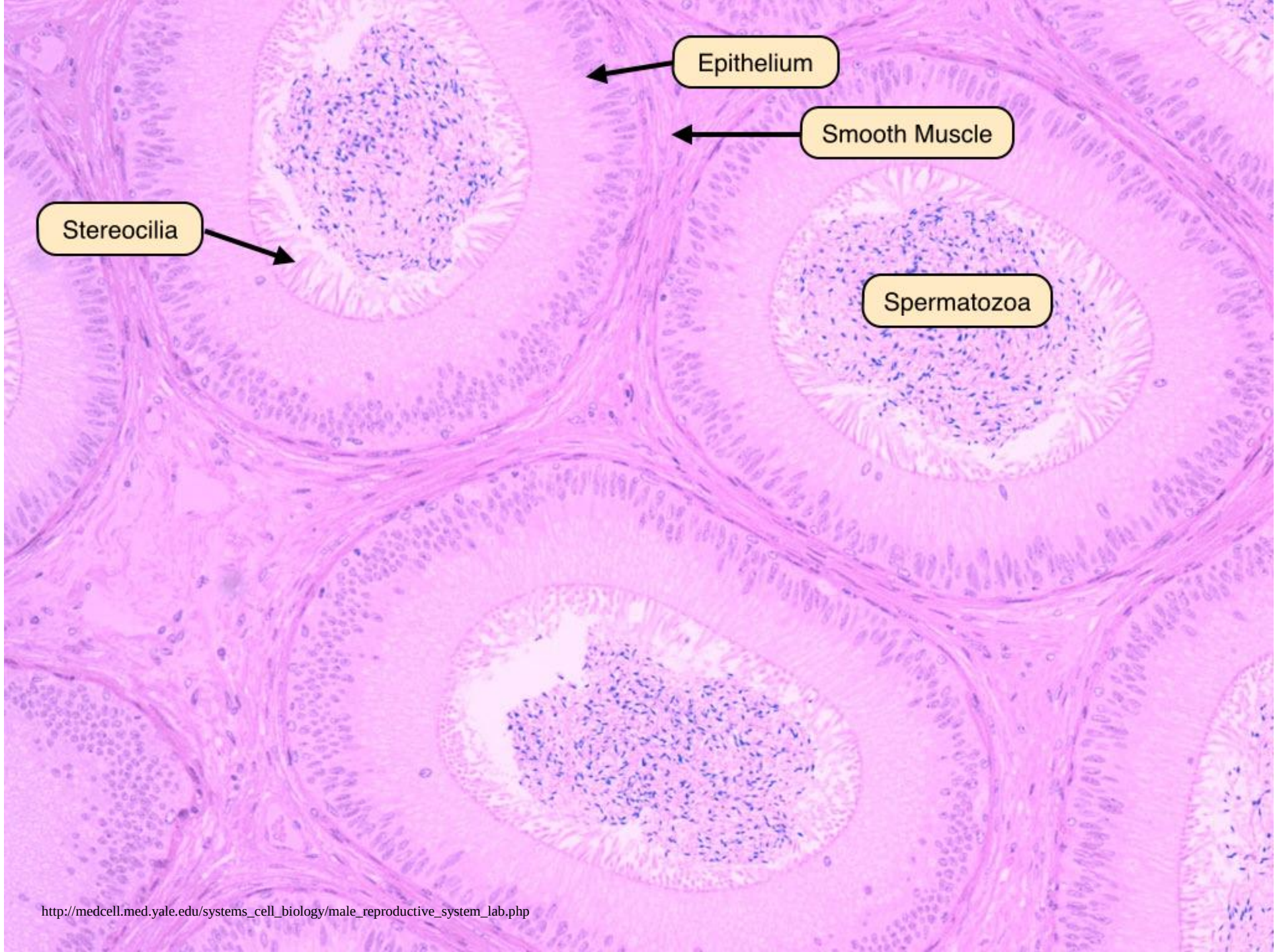

http://medcell.med.yale.edu/systems_cell_biology/male_reproductive_system_lab.php

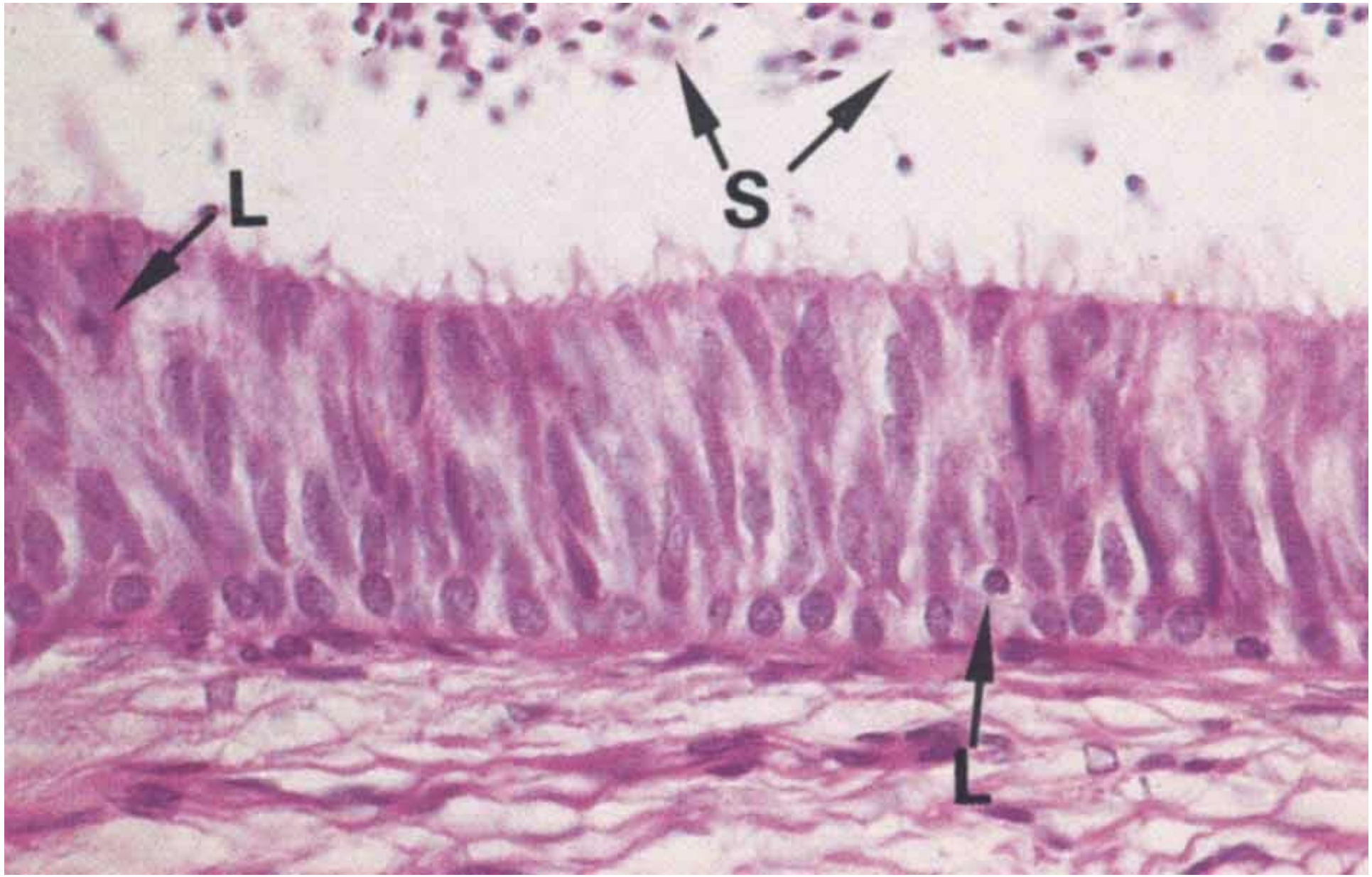
L
S
L

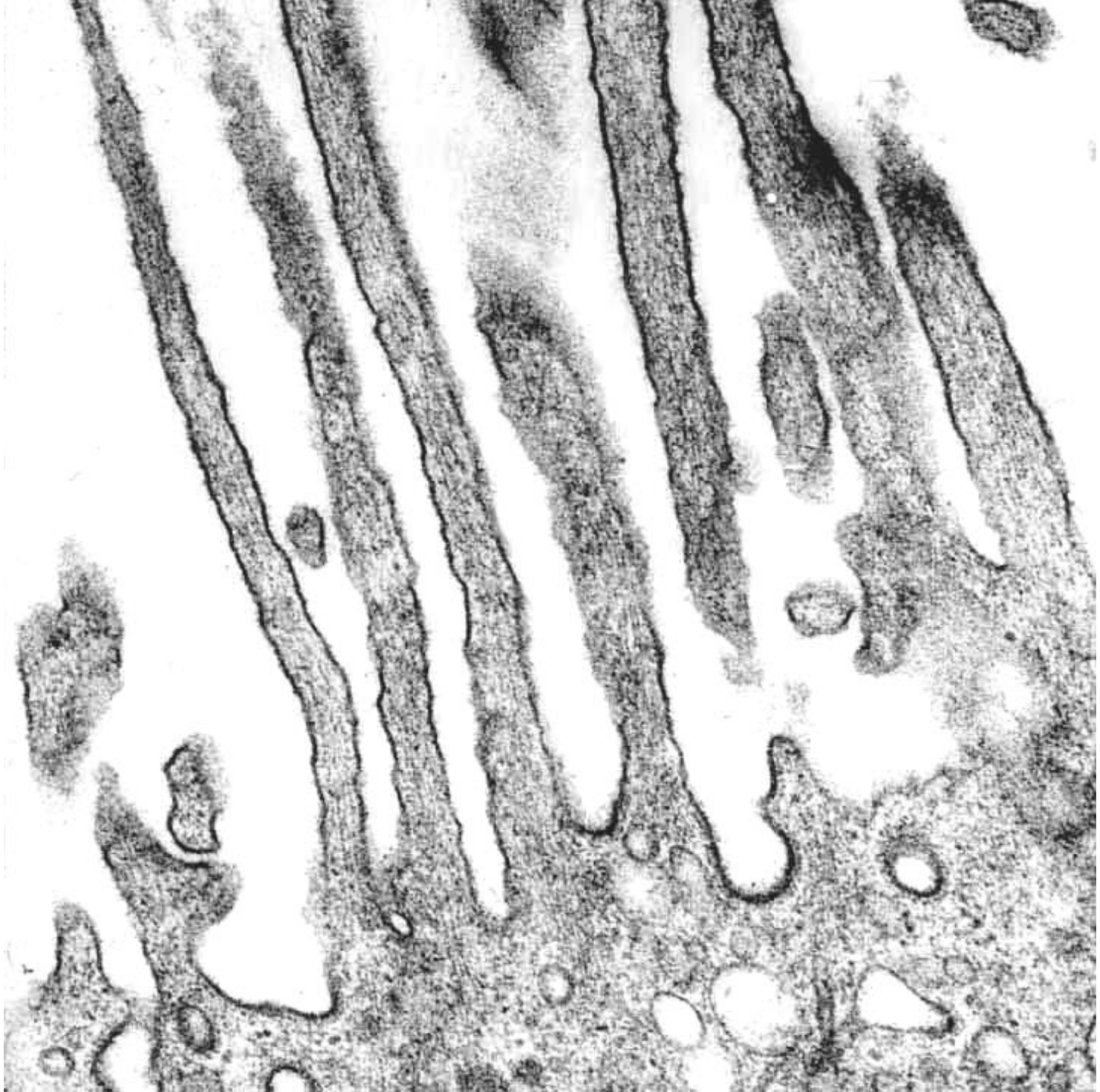

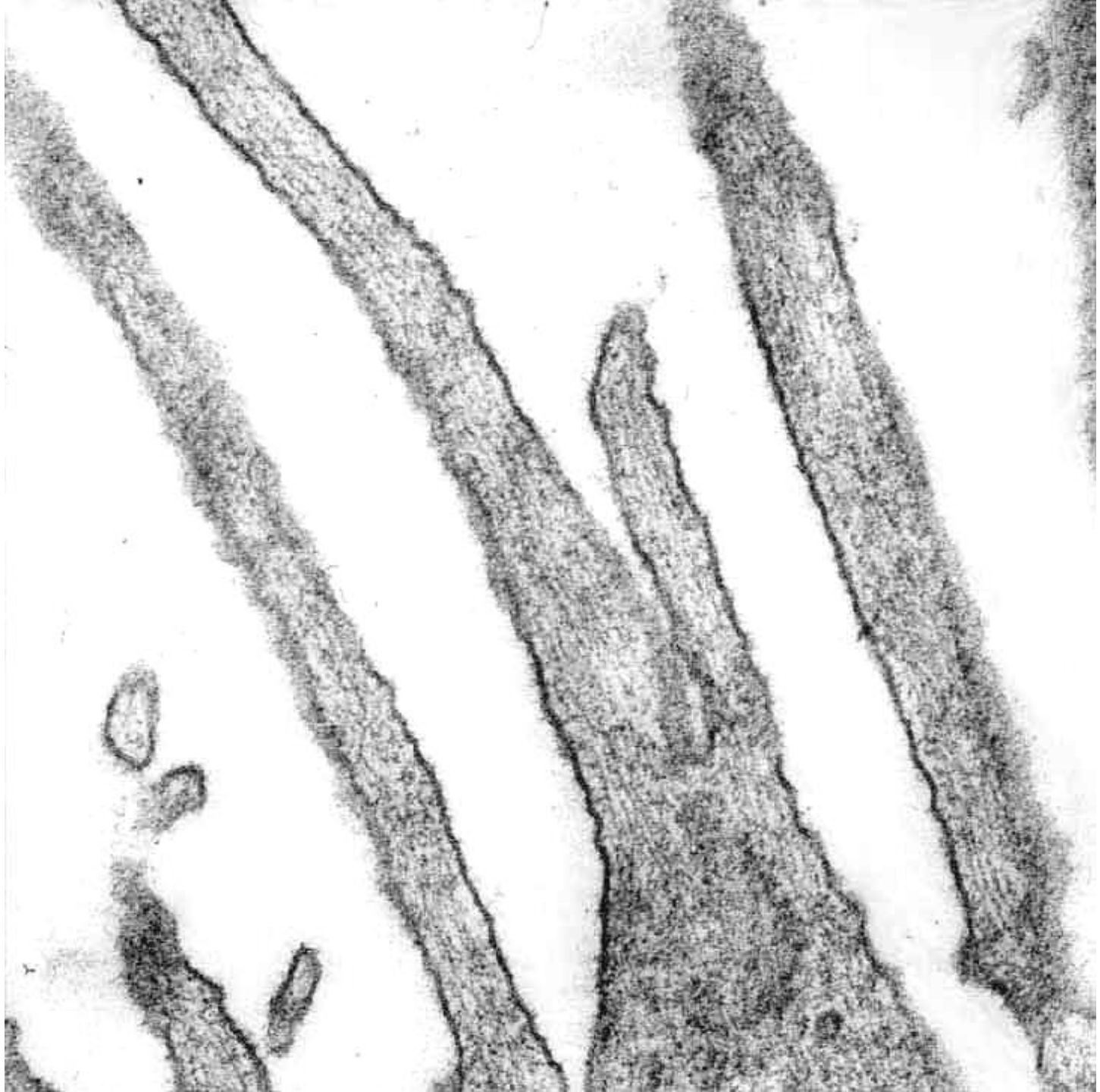

Věděli jste, že kdybyste vyndali z člověka všechny cévy a natáhli je do roviny za sebe, šli byste na hrozně dlouho do vězení ?

Varle a nadvarle

tepenné zásobení

- aorta abdominalis
  - → **a. testicularis**
    - větve vstupují do lalůčků z periferie (tunica vasculosa)

pomocné tepenné zásobení

- a. iliaca interna
  - → a. umbilicalis
    - → a. ductus deferentis
- a. iliaca externa
  - → a. epigastrica inf.
    - → a . cremasterica

vzájemné anastomózy

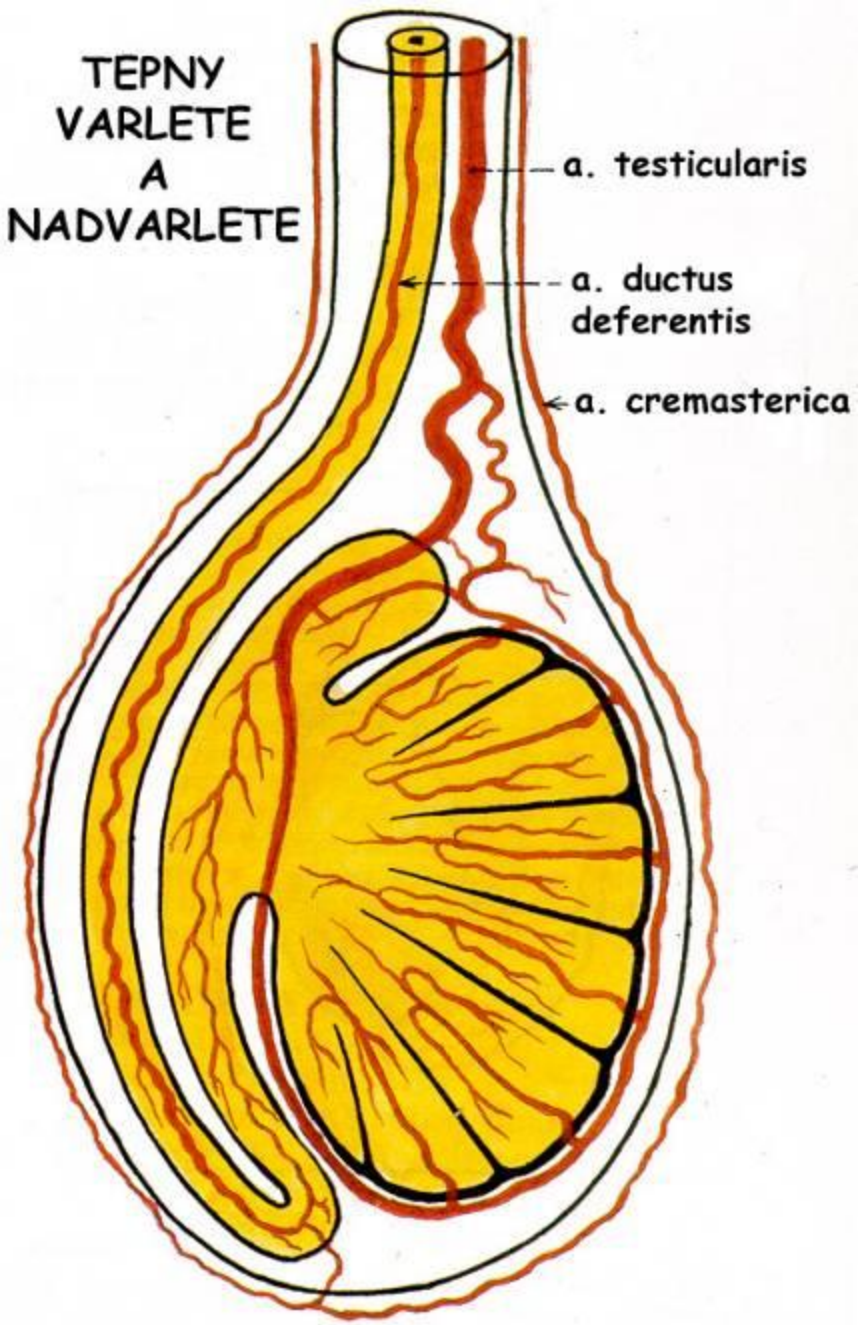

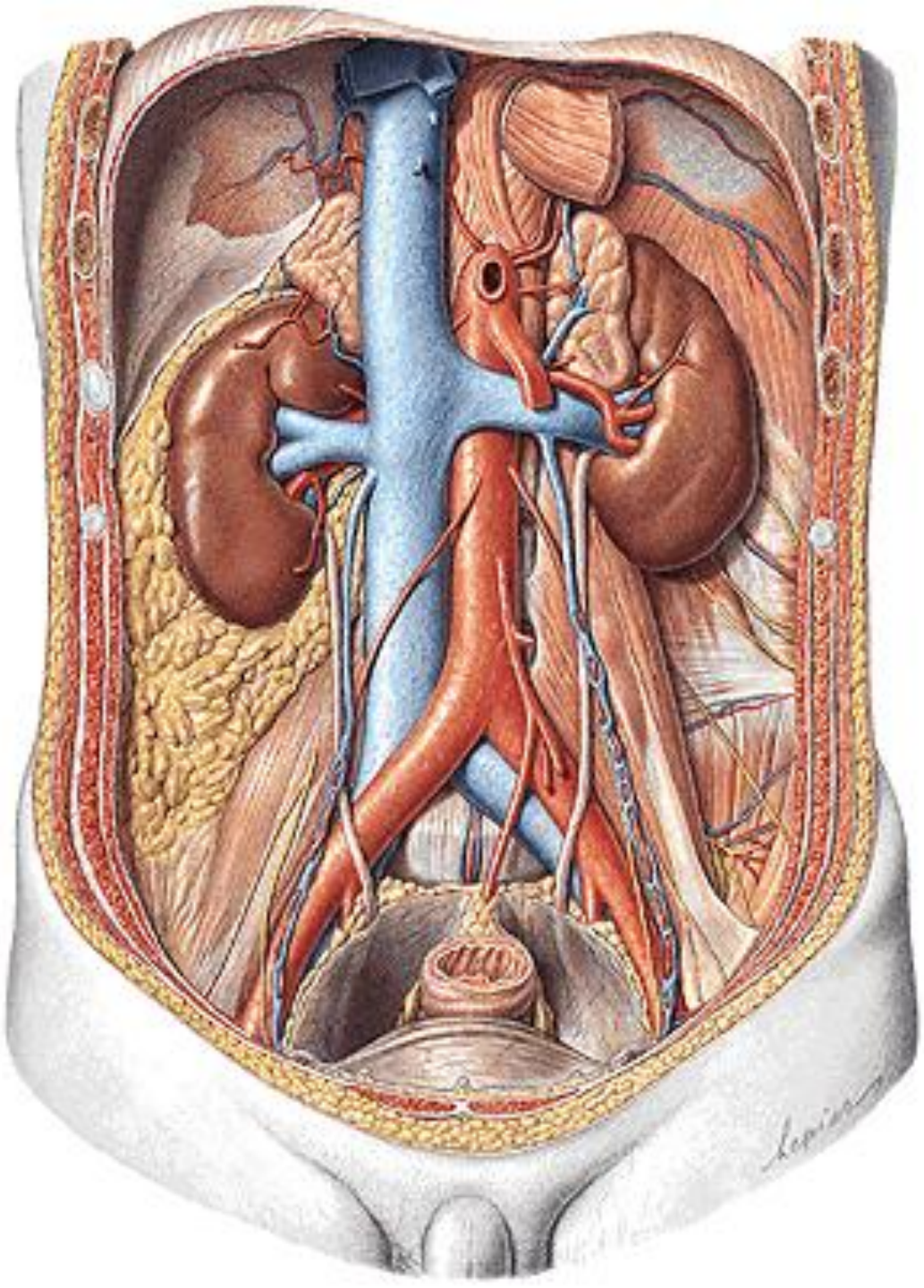

Varle a nadvarle

žilní, mízní a nervové zásobení

vše z/do úrovně L2

- <u>Žíly</u>:
  - rete testis → **plexus pampiniformis** → vv. testiculares → v. cava inf. (dx.) / v. renalis (sin.)
- <u>Míza</u>:
  - nodi lymphoidei lumbales
- <u>Nervy</u>:
  - plexus testicularis
    - *sympatikus* z plexus coeliacus + intermesentericus
    - *parasympatikus* z **n. vagus**

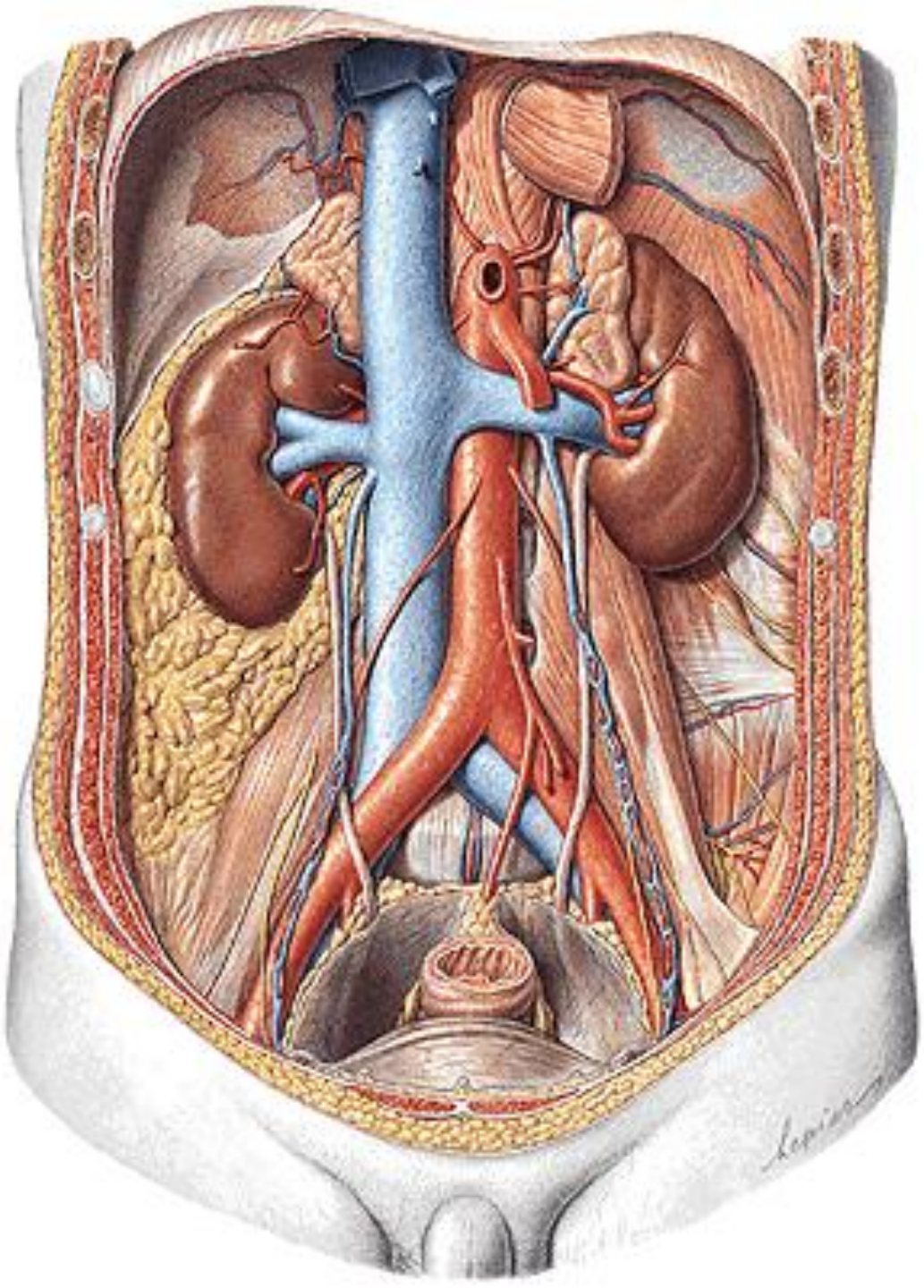

Protiproudový výměnný systém

Ochlazování arteriální krve pomocí plexus pampiniformis
/vývoj spermií – 35 °C)

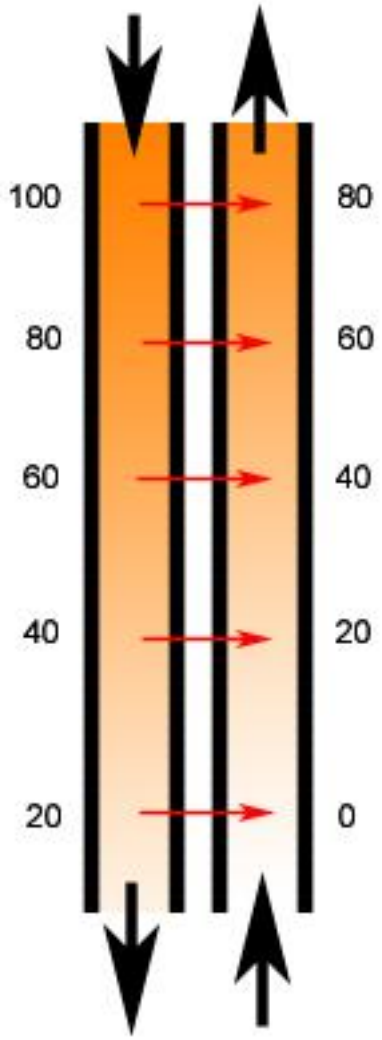

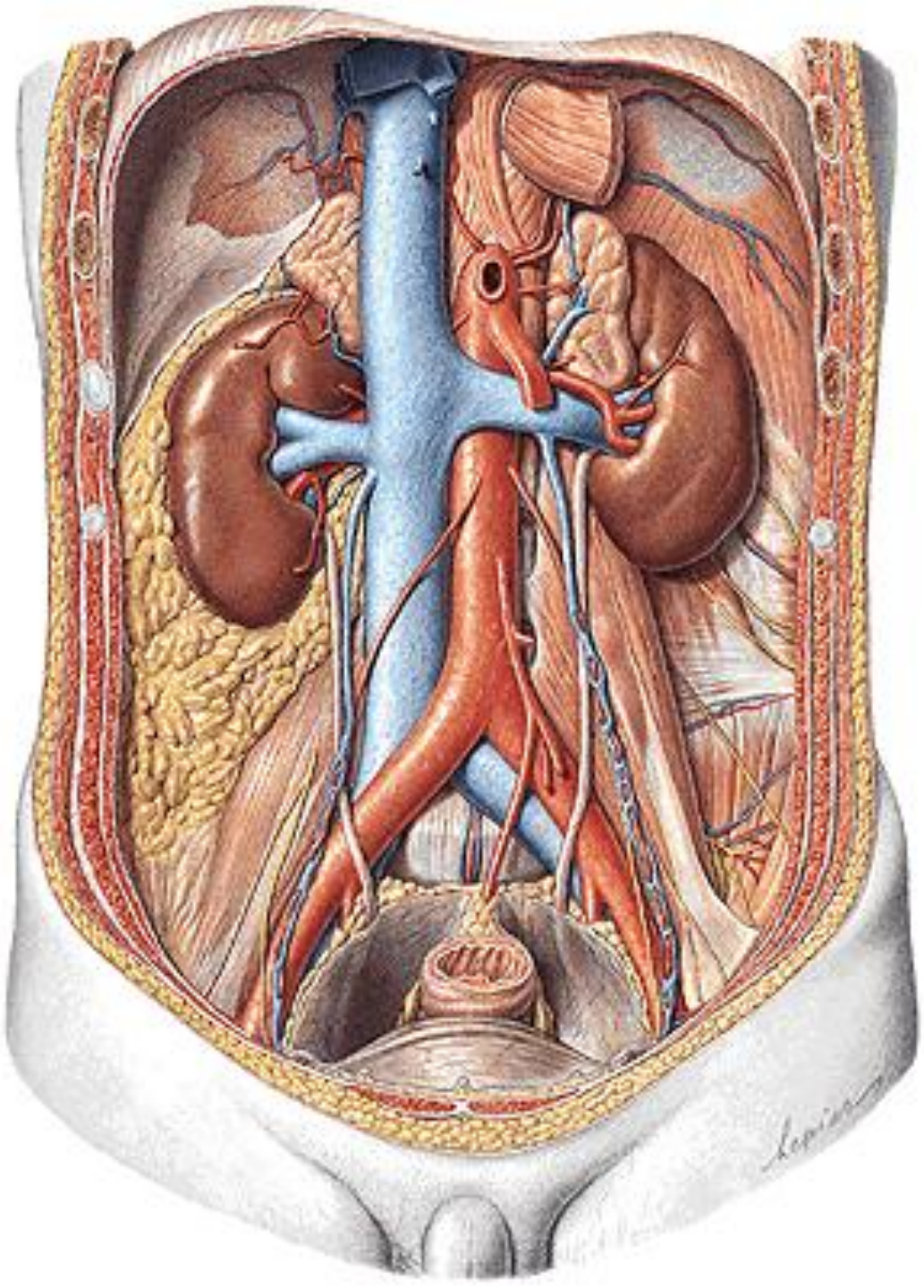

Šourek (*Scrotum*)

- popis: raphe, septum (úplné)
- stěna: deriváty břišní stěny + tunica dartos
- kůže: tenká pigmentovaná bez tukových buněk
- mazové a potní žlázy
- vrstva myofibroblastů v dermis → stahy
- tepny:
  a. femoralis → aa. pudendae ext.
  a. iliaca int. → a. pudenda int.
  a. cremasterica pro obaly
- žíly:
  vv. scrotales ant. → v. femoralis communis
  vv. scrotales post. → v. pudenda int.

Šourek – *inervace a míza*

Nervy:

- přední 1/3 – n. ilioinguinalis + r. genitalis n. genitofemoralis
- posterior 2/3 – n. pudendus + n. cutaneus femoris post.

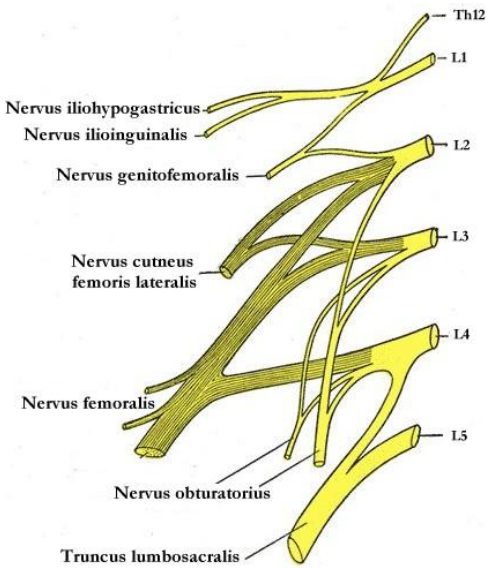

Míza: n.l. inguinales superficiales

nikdy neprovádět punkci varlete !!!

– nebezpečí **zavlečení nádorových buněk** do **jiné** tributární oblasti mízních uzlin !!!

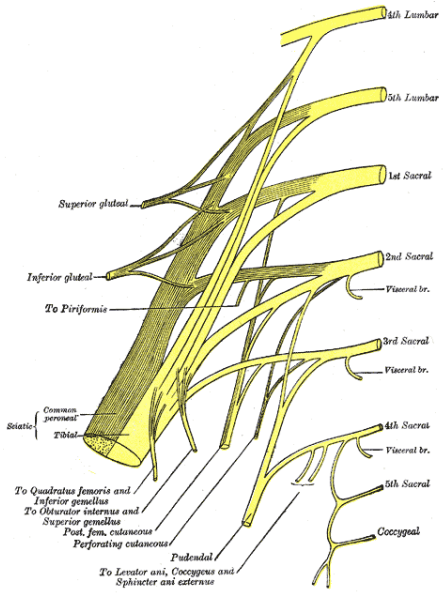

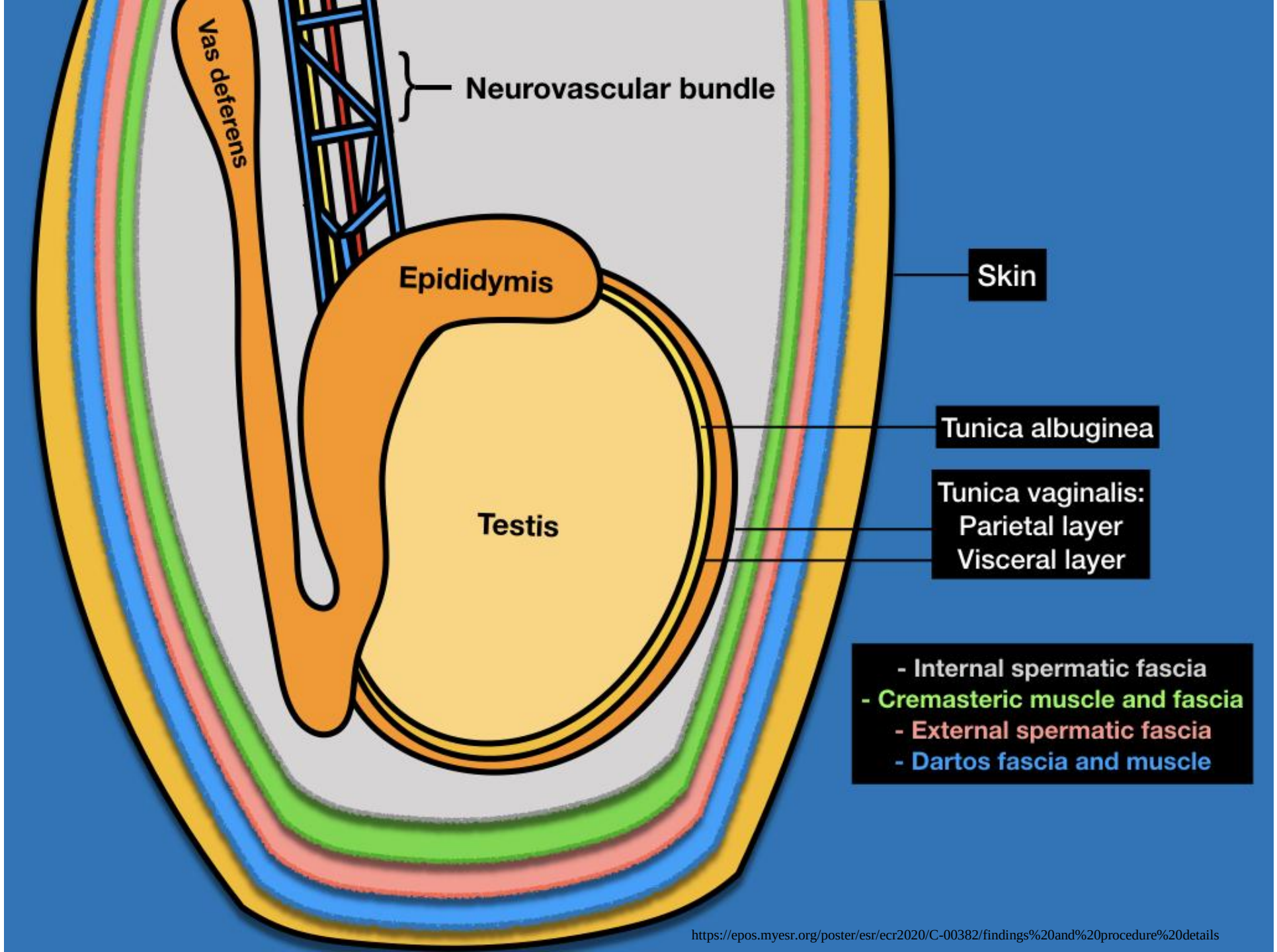

https://epos.myesr.org/poster/esr/ecr2020/C-00382/findings%20and%20procedure%20details

Břišní stěna x Vrstvy šourku

- kůže
- Camperova vazivová vrstva

- facia abd. subcutanea *Scarpae*
- fascia abd. superficialis
- mm. abdominis
- fascia transversalis
- peritoneum

- kůže

- tunica dartos

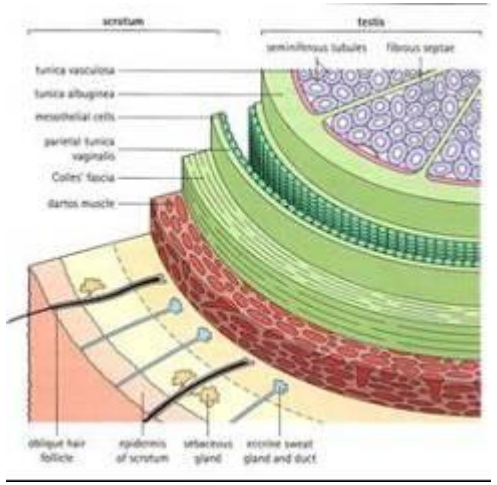

- fascia spermatica ext.
- m. cremaster + fascia cremasterica
- fascia spermatica int.
- tunica vaginalis testis
  - lamina parietalis = periorchium
  - lamina visceralis = epiorchium

Understanding layers of the spermatic cord from Deep inguinal ring to the Scrotum

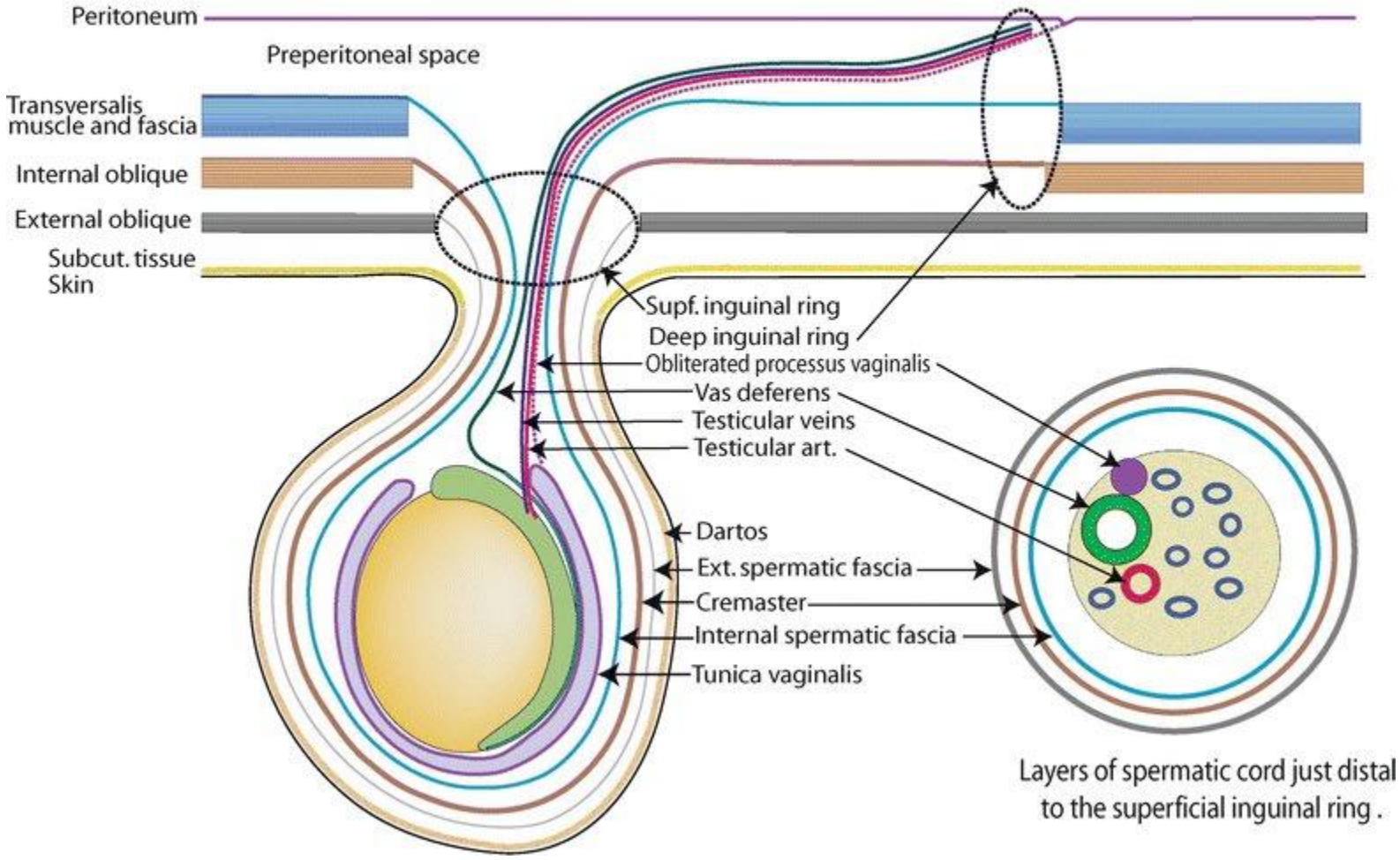

Harding JR. The case of the haunted scrotum. *J R Soc Med*. 1996;89(10):600.

https://www.ncbi.nlm.nih.gov/pmc/articles/PMC1295986/

The case of the haunted scrotum

A 45-year-old man was referred for investigation of an undescended right testis by computed tomography (CT). An ultrasound scan showed a normal testis and epididymis on the left side. The right testis was not visualized in the scrotal sac or in the right inguinal region. On CT scanning of the abdomen and pelvis, the right testis was not identified but the left side of the scrotum seemed to be occupied by a screaming ghost-like apparition (Figure 1). By chance, the distribution of normal anatomical structures within the left side of the scrotum had combined to produce this image. What of the undescended right testis? None was found. If you were a right testis, would you want to share the scrotum with that?

J R Harding
Consultant Radiologist, Royal Gwent Hospital, Newport, Gwent NP9 2UB, Wales

Figure 1 **Detail from left side of scrotum**